

Regional Anesthesia in Children

Cobos Anbuhl, Ane

Master's thesis / Diplomski rad

2024

Degree Grantor / Ustanova koja je dodijelila akademski / stručni stupanj: **University of Zagreb, School of Medicine / Sveučilište u Zagrebu, Medicinski fakultet**

Permanent link / Trajna poveznica: <https://um.nsk.hr/um:nbn:hr:105:102924>

Rights / Prava: [In copyright](#) / [Zaštićeno autorskim pravom.](#)

Download date / Datum preuzimanja: **2025-03-28**



Repository / Repozitorij:

[Dr Med - University of Zagreb School of Medicine
Digital Repository](#)



UNIVERSITY OF ZAGREB

SCHOOL OF MEDICINE

Ane Cobos Anbuhl

REGIONAL ANESTHESIA IN CHILDREN

Graduate Thesis



Zagreb, 2023/24

This graduate thesis was made at the Department of Anesthesiology, Reanimatology and Intensive Care Medicine and Pain Therapy, University Hospital Center Zagreb, mentored by Asst. Prof. Vilena Vrbanović Mijatović, PhD and was submitted for evaluation in the academic year 2023/24.

ABBREVIATIONS

AAGBI - Association of Anesthetists of Great Britain and Ireland

ABCDE - Airway, Breathing, Circulation, Disability, Exposure

ASA - American Society of Anesthesiologists

BLS - Basic Life Support

CNS - Central Nervous System

CO - Cardiac Output

CSA - Continuous spinal anesthesia

CSE - Combined Spinal-Epidural

CT - Computed Tomography

CYP450 - Cytochrome P450

CV - Cardiovascular

FNB - Femoral nerve block

GX - Glycinexylidide

IV - Intravenous

IVRA - Intravenous Regional Anesthesia

LAST - Local anesthetic systemic toxicity

MAC - Minimum Alveolar Concentration

MEGX - Monoethylglycinexylidide

Na - Sodium

Na channel - Sodium channels

PChE - Plasma Cholinesterase

PICU - Pediatric Intensive Care Unit

PNB - Peripheral nerve blocks

PPX - pipecolylxylidine

RR - Respiratory rate

S3-S4 - Sacral Spinal Vertebrae

SA - Spinal Anesthesia

SNB - Sciatic nerve block

TSA - Total Spinal Anesthesia

TAP - Transverse abdominal Plane

US – Ultrasound

CONTENTS

SUMMARY	- 5 -
SAŽETAK	- 6 -
1. INTRODUCTION.....	- 7 -
2. DIFFERENCES BETWEEN CHILDREN AND ADULTS.....	- 8 -
2.1. ANATOMY	- 8 -
2.2. NEWBORN ANATOMY	- 8 -
2.3. PHYSIOLOGY AND PHARMACOKINETICS	- 9 -
3. LOCAL ANESTHETICS IN PEDIATRIC PATIENTS	- 11 -
3.1. AMINO AMIDE ANESTHETICS	- 11 -
3.2. ESTER-TYPE LOCAL ANESTHETICS	- 13 -
3.3. DOSING OF ANESTHETICS IN PEDIATRICS	- 14 -
4. TYPES AND TECHNIQUES OF REGIONAL ANESTHESIA	- 15 -
4.1. NEURAXIAL ANESTHESIA	- 15 -
□ Epidural Anesthesia.....	- 16 -
□ Spinal Anesthesia	- 18 -
□ Combined of spinal and epidural anesthesia	- 19 -
4.2. PERIPHERAL BLOCKS.....	- 19 -
□ Brachial Plexus Block (BPB).....	- 20 -
□ Femoral Nerve Block	- 23 -
□ Sciatic nerve block	- 24 -
□ Peripheral Nerve Catheter Technique.....	- 25 -
4.3. REGIONAL ANESTHESIA TECHNIQUES IN PEDIATRIC PATIENTS	- 26 -
□ Ultrasound-guided Nerve Block Technique	- 26 -
□ Surface Mapping and Percutaneous Peripheral Nerve Stimulation	- 27 -
4.4. IVRA ANESTHESIA.....	- 27 -
5. COMPLICATIONS OF LOCAL ANESTHETICS IN PEDIATRIC PATIENTS	- 29 -
5.1. COMPLICATIONS STATISTICS	- 29 -
5.2. LOCAL ANESTHETIC SYSTEMIC TOXICITY	- 32 -
□ Symptoms.....	- 32 -
□ Management.....	- 33 -
□ Prevention.....	- 35 -
5.3. COMPLICATIONS ASSOCIATED WITH THE TECHNIQUE OF REGIONAL ANESTHESIA	- 35 -
□ Neurologic injury	- 36 -
□ Epidural and Spinal Hematoma.....	- 36 -
□ Infection	- 37 -
□ Hemodynamic Effects and Total Spinal Anesthesia.....	- 37 -
6. ADVANTAGES AND DISADVANTAGES OF REGIONAL ANESTHESIA	- 38 -
6.1. ADVANTAGES.....	- 38 -
6.2. DISADVANTAGES.....	- 39 -
REFERENCES	- 42 -
ACKNOWLEDGEMENTS	- 48 -
BIOGRAPHY	- 49 -

SUMMARY

Title: REGIONAL ANESTHESIA IN CHILDREN

Keywords: Regional Anesthesia, Pediatric, Local anesthetics, US-guided Nerve Block Technique.

Author: Ane Cobos

Regional anesthesia in pediatric patients presents an integral part of pediatric perioperative pain management. Pediatric regional anesthesia is both safe and efficacious when performed by experienced anesthesiologists. Careful choice of drugs, techniques, and corresponding doses is essential to ensure optimal results and minimize risks.

The anatomical and physiological differences between children and adults are an important consideration when administering anesthesia to children. Anesthetic doses and techniques need to be adjusted to accommodate ongoing growth and development, taking into account the child's age, weight, and emotional response.

Types of regional anesthesia performed in children are peripheral nerve blocks, epidurals, and spinal anesthesia. The ultrasound-guided technique is the golden standard for performing blocks.

SAŽETAK

Naslov: REGIONALNA ANESTEZIJA KOD DJECE

Ključne riječi: Regionalna anestezija, Pedijatrija, Lokalni anestetici, Tehnika živčane blokade pod kontrolom ultrazvuka

Autor: Ane Cobos

Regionalna anestezija kod pedijatrijskih pacijenata predstavlja sastavni dio perioperativnog zbrinjavanja boli. Pedijatrijska regionalna anestezija je sigurna i učinkovita kada je provode iskusni anesteziolozi. Pažljiv odabir lijekova, tehnika i odgovarajućih doza ključni su za postizanje optimalnih rezultata i snižavanje rizika.

Anatomske i fiziološke razlike između djece i odraslih važan su čimbenik prilikom primjene anestezije kod djece. Doze lijekova i tehnike treba prilagoditi djetetu s obzirom na kontinuirani rast i razvoj, uzimajući u obzir dob, težinu i emocionalni odgovor.

U djece se primjenjuju periferni blokovi epiduralna i spinalna anestezija, a primjena ultrazvuka se smatra zlatnim standardom u izvođenju blokova.

1. INTRODUCTION

Regional anesthesia in children represents a type of anesthesia within the domain of anesthesiology that addresses the care and management of children's unique physiological and psychological requirements. In recent years, there has been an emerging interest in regional anesthesia as an alternative or adjunct to general anesthesia in pediatric surgical procedures. This has been fueled by the desire to increase perioperative care and reduce undesirable systemic anesthesia side effects, in addition to improving overall patient outcomes (1).

Regional anesthesia refers to the selective administration of anesthetic agents in the area surrounding specific nerves or tissue regions that result in a reversible loss of sensation and motor function. By blocking specific nerves, pain is more precisely and effectively controlled, which is very beneficial in pediatric patients due to their sensitivity. While benefits have been well-illustrated in adults, the pediatric population presents unique challenges and opportunities for its application (2).

There are several medical situations where the usage of Regional Blocks is essential in order to provide analgesia and decrease the use of general anesthesia and its corresponding risks. Some examples of surgeries in which regional anesthesia may be profitable are Orthopedic surgeries, such as fracture reduction and fixation. Brachial or cervical plexus block might be used for upper extremity fractures. Sciatic nerve block (SNB) combined with femoral nerve block (FNB) for hip surgeries. Urological surgeries, such as circumcision, with a block of dorsal nerve of the penis. Abdominal surgeries, such as appendectomy, performing a Rectus sheet block or TAP block. Ophthalmological surgeries, proceeding to a peribulbar block in order to correct strabismus. The selection of the type of regional anesthesia depends on multiple factors, including, age, length, and complexity of the surgery (3).

Children differ from adults in terms of anatomy, physiology, and response to medications. Therefore, a thorough investigation into the safety and efficacy of regional anesthesia techniques is indicated for implementing their unique characteristics.

2. DIFFERENCES BETWEEN CHILDREN AND ADULTS

Regional anesthesia in children is based on the same key principles as in adults. However, there are important differences in the application and requirements for each group, based on the anatomical and physiological variations that have remarkable clinical significance. We describe the most prominent differences, pointing out the anatomical elements, physiology, pharmacokinetics, and their clinical significance (4).

2.1. Anatomy

Children have smaller anatomical structures including nerves, blood vessels, and the spinal canal, compared to adults, with the need for greater precision in performing regional blocks to account for the smaller dimensions (5,6).

Anatomical structures are also closer to the surface, making them easier to target when performing regional anesthesia. In addition to being anatomically closer to each other, as contours flatten during growth, nerves and blood vessels also come into closer proximity, complicating needle placement required during regional anesthesia procedures to target a desired nerve while reducing the risk for complications (6).

Having fewer adipose and connective tissue surrounding nerves and blood vessels compared to adults means children absorb local anesthetics differently, mostly altering the time course and effectiveness of regional blocks (5,6,7).

Myelination of nerves is not complete in children, particularly in newborns, and that can affect nerve impulse conduction and the response to regional anesthesia (6).

2.2. Newborn Anatomy

In newborns, in particular, understanding each distinct anatomical feature is a significant clinical consideration.

In newborns, the dural sac extends only to the S3-S4 level, and this knowledge can help determine the choice of the spinal or epidural level for a regional block. It is necessary to minimize the risk of spinal cord injury during anesthesiology procedures (6,7).

The iliac crest, often seen at a much lower vertebral level at L5-S1, is important as it guides the appropriate lumbar level selection for procedures involving the lower extremities; such data can minimize the potential for inadvertent complications (6,7).

The termination level of the spinal cord in newborns is L3 level, and this information is of supreme clinical importance. This fact, along with the data stated before, can help avoid using spinal anesthesia (SA) below the L4 level and thereby avoid the potentially catastrophic complications that can occur from anesthetic blockade in regions where the spinal cord terminates (6,7).

This level of precision is essential for reducing the risk of spinal cord injury and ensuring the safety and efficacy of regional anesthesia procedures in neonates. Adopting this anatomical awareness will enable healthcare providers to modify regional anesthesia approaches to suit the particularities of neonatal patients and thus enhance the quality of perioperative care in this vulnerable population (6,7).

2.3. Physiology and Pharmacokinetics

Regarding physiology and pharmacokinetics, there are some points and adjustments that need to be considered.

The sympathetic component in the lumbar region is relatively weak compared to the adults. This can influence the spread and effectiveness of local anesthesia. Since sympathetic nerves regulate blood vessel constriction and can affect the absorption of local anesthetics, their reduced activity in children may lead to altered distribution and duration of anesthesia. Impaired vasoconstriction, can lead to increased blood flow to the area, potentially accelerating the systemic absorption of the anesthetic agent and affecting its efficacy. It is important to look into recognition as this will help to manage hemodynamic changes more effectively for myocardial performance, and to ensure cardiovascular (CV) stability during and after procedure (9).

The sympathetic nervous system interacts with sensory nerves, modulating their activity and perception of pain. In children, the weaker sympathetic component may influence the sensory blockade achieved with local anesthesia. This can impact the extent and duration of pain relief provided by the anesthetic agent, potentially necessitating adjustments in dosage or technique to ensure adequate anesthesia (1,9)

Cardiac Output (CO) is greater compared to the adult. With increased CO, there is enhanced blood flow to the site of injection, leading to a quicker onset of action of the local anesthetic agent. This may result in faster anesthesia onset and a shorter time to achieve desired effects (4).

The increased respiratory rate (RR) will have an impact on the uptake and elimination of anesthetics. Higher RR enhances pulmonary ventilation, leading to a more rapid exchange of gases in the lungs. This increased ventilation results in a greater uptake of anesthetic agents from the alveoli into the bloodstream. As a result, anesthetics administered via inhalation are absorbed more quickly, leading to a faster onset of action (1,4).

With an increased respiratory rate, there is less time for equilibrium to be established between the alveolar partial pressure of the anesthetic and the arterial blood partial pressure. This leads to a lower alveolar partial pressure of the anesthetic agent, which in turn drives a steeper concentration gradient for diffusion from the alveoli into the bloodstream. Consequently, the uptake of anesthetic agents is enhanced (1,4).

Overall, this will influence the pharmacokinetics of anesthetic agents. Increased activity will be followed by an increased systemic absorption of the local anesthetic agents.

In pediatric patients the percentage of open channels is significantly higher compared to the adult, this may change the cardiac response to local anesthetic agents, which increases the risk of local anesthetic-induced cardiac toxicity. This is an important physiological difference and emphasizes the need for careful monitoring and dose titration to prevent adverse cardiac events during regional anesthesia in neonates and infants (9).

Hepatic metabolism of local anesthetics is not mature until approximately 9 months of age. The developmental timeline of hepatic metabolism affects the clearance and metabolism of local anesthetics, putting the patient at risk for accumulation of the drug, especially after repeated doses or continuous infusions (9).

Clinical implications include monitoring of plasma levels of the drugs, adjusting the dosage during subsequent infusions, allowing a rest period, or using an alternative local anesthetic, as appropriate, before using the drug again. This highlights the importance of vigilance for pediatric patients (9).

3. LOCAL ANESTHETICS IN PEDIATRIC PATIENTS

In pediatric regional anesthesia, different anesthetics can be used. These agents, designed to selectively block pain sensation in specific areas of the body, are used for surgical and invasive procedures in children (10).

The pharmacology presents unique particularities. The safety and efficacy of these agents require a detailed understanding of their properties, appropriate dosing, and specific considerations related to the age and development of the pediatric patient.

Local anesthetics can be divided into two main groups of drugs, Amino Esters and Amino Amides. The main goal of this anesthetic is to prevent depolarization of the cell membrane by binding to Sodium (Na) channels, inhibiting the generation and propagation of action potentials in neurons. (10)

There is a lack of pharmacokinetic data for local anesthetics in children, with a notable limitation in neonatal populations. Regrettably, it is within this specific age group that the vulnerability to local anesthetic drug toxicity is most pronounced (10).

3.1. Amino Amide Anesthetics

The most commonly used group of local anesthetics in pediatric practice is Amino Amide drugs. This group includes drugs such as lidocaine, bupivacaine, ropivacaine, and

levobupivacaine. These anesthetics act by inhibiting voltage-gated sodium channels, thus preventing the generation and propagation of action potentials in nerves. Sodium channel inhibition is the primary mechanism of action, which occurs in a dose-dependent, and reversible manner (10).

Sodium channels are protein structures integrated into the cell membrane. Amino amides bind to specific receptors within the sodium channels in their inactive state, preventing their transition to their active state which is required for the initiation of an action potential. Amino amides stabilize in their inactive conformation, limiting Na ion influx into the nerve cell, preventing depolarization and successive conduction. This blockade of sodium channels results in the loss of sensation and motor function that are observed in the areas where amino amide local anesthetics are administered (11).

It is important to consider the existence of factors that may influence both the depth and duration of anesthesia, concentration, and vascularity of tissue. Some compounds must transverse the lipid membranes to exert their pharmacological action and are not influenced by the pH of the corresponding tissues (10).

Concerning metabolism, these anesthetics are metabolized in the liver, through hepatic microsomal enzymes, such as cytochrome P450 (CYP450) enzymes. The primary metabolic pathway involves the biodegradation of these drugs into different metabolites, which are then excreted from the body through the kidneys in the form of urine (4).

In the case of lidocaine, CYP3A4 is the primary enzyme, and CYP1A2 to a lesser extent. The major metabolites of lidocaine include monoethylglycinexylidide (MEGX) and glycinexylidide (GX). However, Bupivacaine is metabolized similarly, primarily by CYP3A4 and CYP1A2, with secondary involvement of other CYP450 enzymes, but with different main metabolites, including pipecolylxylidine (PPX) and 3-hydroxybupivacaine (4).

In pediatric patients, the metabolism of amino amide local anesthetics can be influenced by age-related factors, such as liver maturation and function. Neonates and infants may have a reduced capacity to metabolize these drugs compared to older children and adults.

Age-related changes in fluid compartments significantly impact the pharmacokinetics of local anesthetics in pediatric patients. The volume of distribution at steady state is greater in infants than in adults, with shifts in body water content varying from 80% in premature neonates to 60% in older children. As local anesthetics are water-soluble, these changes in fluid compartment composition are crucial. Infants exhibit lower levels of local anesthetic-binding proteins, increasing the fraction of unbound drugs and raising the risk of toxicity. Although there's a postoperative increase in protective alpha-1-acid glycoprotein in neonates, the clearance of local anesthetics is reduced in those under 3 months, resulting in longer elimination half-lives compared to adults (4).

Therefore, careful consideration of dosage adjustments and monitoring is essential to ensure the safety and efficacy of local anesthetics in pediatric patients.

3.2. Ester-type Local Anesthetics

Ester-type Local Anesthetics are the least commonly used group of local anesthetics. In the past have been used in pediatric patients, as they have a short duration of their effects and a low risk of systemic toxicity compared to amino amide anesthetics (10). Nevertheless, their use has diminished over time, in preference for amino amides local anesthetic, which provide extended durations of action and a lower risk of allergic reactions (10)

This group of local anesthetics includes drugs such as procaine, 2-chloroprocaine, and tetracaine. Chloropropane, with its action of rapid hydrolysis, provides a quick onset and short duration of action, making it suitable for short procedures in children (10).

In contrast to amino amide drugs, amino esters are metabolized by plasma cholinesterase (PChE). This metabolic pathway is essential for the breakdown of ester components and its efficiency is dependent on the levels of PChE. Consequently, in the pediatric population, characterized by decreased levels of PChE, there is a potential for an elevation in the plasma concentration of these drugs, which may result in reaching toxic levels. Additionally, the presence of PChE enforces a restriction on the duration of action of these drugs, leading to a shortened period of activity (10).

The most commonly used in children are chloroprocaine and tetracaine. The primary application is as an adjuvant to enhance the efficacy and duration of SA when combined with other anesthetic agents, typically from the amide class, such as bupivacaine, lidocaine, or ropivacaine. Their role as adjuvants can help achieve better pain control, provide a denser block, and extend the duration of anesthesia, thus improving patient comfort and outcomes during and after surgical procedures. Tetracaine is especially applied in premature infants undergoing surgeries such as inguinal hernia repair (10,11).

3.3. Dosing of Anesthetics in Pediatrics

Dosing of local anesthetic among the pediatric population, shown in Table 1, is mainly dependent on the weight of the patient (1). The concentration and quantity of local anesthetics administered is an important state to take into account.

Local Anesthetic	Class	Maximum dose (mg/kg)	Duration of action (min)	Infusion (mg/kg/h)
Procaine	ester	10	60-90	-
2- Chloroprocaine	ester	20	30-60	-
Tetracaine	ester	1.5	180-600	-
Lidocaine	amide	5	90-200	-
Bupivacaine	amide	2.5	180-600	0.2-0.4
Ropivacaine	amide	2.5	180-600	0.2-0.5
Levobupivacaine	amide	2.5	180-600	0.2-0.5

Table 1 - Maximum recommended doses and approximate duration of action of commonly used local anesthetic agents.

For instance, a diluted form of a long-acting local anesthetic, such as 0.25% levobupivacaine, is frequently employed, particularly when the child is concurrently undergoing general anesthesia. In this context, the nerve block primarily serves for analgesic purposes (1).

Specific situations may need either lower or higher concentrations of the local anesthetic. Lower concentrations, like 0.125% levobupivacaine, prove beneficial in mitigating the

risk of toxicity in neonates and have the added advantage of being less likely to mask compartment syndrome or impede ambulation (1).

On the other hand, instances where a profound motor block is desired, such as in lower limb tendon transfer surgery for children with cerebral palsy, may call for the administration of higher concentrations of local anesthetics, such as 0.5% levobupivacaine (1).

4. TYPES AND TECHNIQUES OF REGIONAL ANESTHESIA

Regional anesthesia is a crucial technique in pediatric anesthetic practice, allowing for effective pain control and improving the surgical experience for younger patients (12). Within regional anesthesia, several specific techniques are included, such as neuraxial anesthesia and peripheral blocks, we will explore these fundamental techniques, highlighting their application, safety, and efficacy in the specific context of pediatric anesthesia (13).

4.1. Neuraxial Anesthesia

Neuraxial anesthesia refers to a group of techniques involving the administration of local anesthetics around the central nervous system's (CNS) nerves, specifically within the spinal canal (14). These techniques include Epidural Anesthesia, SA, and Combined spinal epidural (CSE), shown in Figure 1 (15).

Understanding the different types of nerve blockades is crucial in determining the appropriate technique and strategy based on the surgery or procedure that needs to be conducted. Tailoring the approach to the unique requirements of each case ensures effective pain management and optimal outcomes (13).

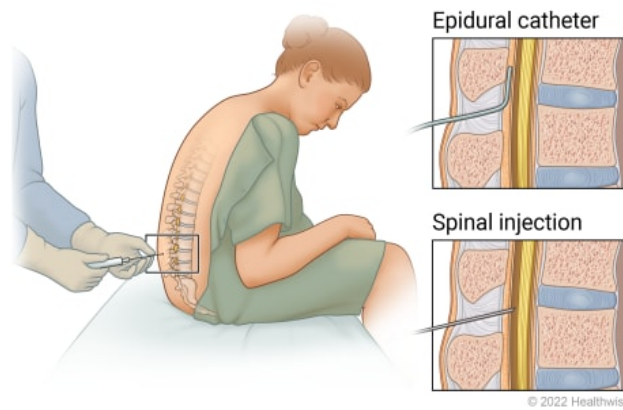


Figure 1 - Illustration of the Epidural and Spinal space. Image obtained from <https://www.saskhealthauthority.ca/your-health/conditions-diseases-services/healthline-online/acl7147>

Epidural Anesthesia

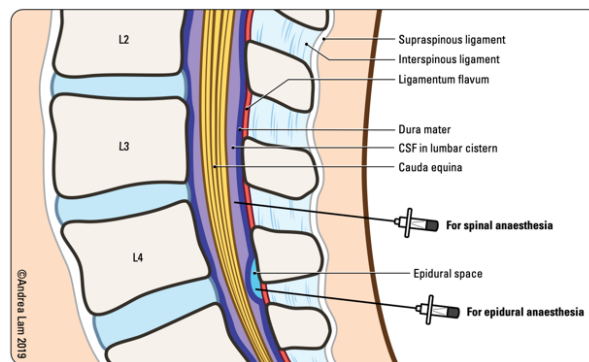


Figure 2 - Illustration of the Epidural and Spinal anatomy L3-L4. Image obtained from Toronto Notes [2020].pdf.

Epidural anesthesia is a type of regional anesthesia that consists of injecting one or more drugs in the epidural space surrounding the spinal cord to achieve a neuraxial block (16). Epidural space is considered a tissue plane between the dura mater, covering the spinal nerve, and the vertebrae of the spine, as shown in Figure 1 (17).

The goal of Epidural Anesthesia is to provide pain relief, by reducing or preventing impulse transmission to a certain region of the body (18).

The process of epidural anesthesia starts with the preparation of the patient, making sure the consent of the anesthesia is signed, and the monitorization of the vital signs. Subsequently, you put the patient in the correct position, usually placed in a position that allows adequate access to the spine, usually sitting or lying on their side with their back arched outward, fetal position (Figure 1). The skin should be cleaned with an antiseptic solution, and you start administering local anesthetics in the insertion area, with drugs such as Mepivacaine or Lidocaine, an immediate-acting drug that provides analgesia for the needle for the catheter. The intervertebral space L3-L4 is localized by palpating the posteriorsuperior iliac crest and drawing an imaginary line between them, and the location where the needle needs to be inserted is at the level where this line intersects with the vertebral collum (16).

Once localized, the anesthesiologist inserts an epidural needle into the epidural space, by crossing the ligamentum flavum, where a catheter is inserted through the needle, which is then removed. The catheter is attached to the skin and an initial dose of anesthetic is given to test its effectiveness, followed by additional doses as needed. Throughout the process, the patient's vital signs and comfort level are monitored to ensure the safety and effectiveness of anesthesia (16).

Initial blockade starts at the spinal roots followed by some degree of spinal cord anesthesia as local anesthesia diffuses into the subarachnoid space through the dura. The onset of significant blockade achieved with epidural anesthesia is typically 10-15 minutes. As a trade-off, onset is slower, and there are fewer rapid-onset side effects. The patient's position is less critical and the specific gravity of the solution does not matter (18).

Epidural Anesthesia is not complication-free, with the failure of the technique, hypotension, and bradycardia during the blockade of cardiac sympathetic, such as in a “high spinal” around the T2-4 level, being primary concerns (4).

Others include epidural or subarachnoid hematoma, accidental subarachnoid injection complicating a technique that can already result in SA with its complications, systemic toxicity secondary to accidental intravascular administration of local anesthetic, catheter-

related (shearing, kinking, vascular, subarachnoid misplacement) and infectious issues, and dural puncture themselves, demonstrating the need for vigilance and expertise (4).

Spinal Anesthesia

Spinal Anesthesia is a regional technique widely used in children to provide analgesia and anesthesia during specific surgical procedures (19).

For children, SA is implemented with specific precautions and adjustments due to unique anatomical and physiological differences compared to adults, as mentioned before. The dose of anesthetic is adjusted, and the child's age, weight, and height are considered to ensure safe and effective anesthesia (5).

This technique blocks the conduction of nerve impulses in the spinal cord, preventing the transmission of pain signals from the area of the body being operated on or treated. This approach involves administering an anesthetic agent, such as bupivacaine or lidocaine, directly into the subarachnoid space within the dural sac surrounding the spinal cord and nerve roots (20).

Spinal anesthesia can also affect neuromuscular transmission, resulting in the relaxation of muscles in the affected area. This is beneficial during surgical procedures, as it facilitates the surgeon's access to the area of interest (20).

Spinal anesthesia presents notable differences when compared to epidural anesthesia. One significant distinction is the rapid onset of spinal blockade, typically occurring within 2-5 minutes. This method proves highly effective, offering a quicker blockade than epidural anesthesia. The procedure is facilitated by visual confirmation of cerebrospinal fluid (CSF) flow, making it easier to perform (20).

Unlike with epidural anesthesia, with SA a smaller dose of local anesthetic is used, usually below the toxic intravenous threshold. Additionally, SA is not administered as a continuous infusion. An interesting aspect is the use of a hyperbaric local anesthetic solution, where the specific gravity is increased by mixing it with 10% dextrose. This

adjustment aids in enhancing the spread of the local anesthetic to dependent areas of the subarachnoid space (20).

Spinal anesthesia comes with potential complications that necessitate careful consideration. These complications may include the failure of the technique, hypotension, and bradycardia, such as in a "high spinal" scenario around the T2 - 4 level. Other possible complications involve epidural or subarachnoid hematoma, post-spinal headache due to CSF leak, transient paresthesia, spinal cord trauma, and infection (19,20).

A thorough understanding of these details is essential for healthcare professionals to ensure that the administration of SA is safe and effective.

Combined spinal and epidural anesthesia

Combined spinal and epidural anesthesia is a technique that combines the advantages of SA's rapid onset, reliable, and intense blockade with the flexibility afforded by an epidural catheter (21).

In a CSE procedure, the initial administration involves a spinal injection, providing a swift and potent anesthesia effect. Simultaneously, an epidural catheter is introduced, allowing for subsequent epidural anesthesia if needed. This dual approach grants healthcare providers the capability to adjust the anesthesia level as per the evolving requirements of the surgical or obstetric procedure, ensuring optimal pain management and patient comfort (21).

The CSE technique represents a versatile option in anesthesia practice, blending the strengths of both spinal and epidural approaches to cater to diverse clinical scenarios.

4.2. Peripheral Blocks

Peripheral nerve block (PNB) is a technique that achieves outstanding results. These blocks consist of administering local anesthetics near the corresponding peripheral

nerves, which innervate the area we want to suppress the transmission of pain and sensation, according to the surgical intervention we are performing (22).

Before performing PNB, it is essential to locate the specific nerve to be blocked (22). Different techniques can be used for this purpose, some of the common technique includes Surface Mapping and Percutaneous Peripheral Nerve Stimulation or Ultrasonography. Once located, the Peripheral Nerve Catheter technique is performed (4).

The most commonly used peripheral blocks in pediatrics include those targeting regions such as the femoral nerve, sciatic nerve, popliteal nerve, and brachial plexus (22).

Brachial Plexus Block (BPB)

Brachial plexus block is a regional anesthesia technique used to provide analgesia and anesthesia to the upper extremity (23). The brachial plexus is a network of nerves that supply sensation and motor control to the shoulder, arm, forearm, and hand, as shown in Figure 4 (23).

The point where the C5 and T1 spinal nerves converge is where the brachial plexus begins. These nerves compose the upper, middle, and lower trunks, which cross the subclavian artery and go between the scalene muscles towards the axilla. The radial and circumflex nerves originate from the posterior cord, which reorganizes into three cords or fascicles below the clavicle; the lateral cord, which is part of the median and musculocutaneous nerves; and the medial cord, which gives rise to the ulnar nerve and other nerves. Between these fascicles, the subclavian artery develops into the axillary artery (23).

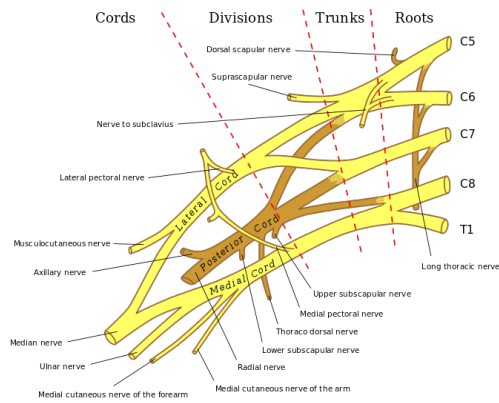


Figure 4 - Illustration of the brachial plexus. Image obtained from https://en.wikipedia.org/w/index.php?title=Brachial_plexus&oldid=1224394932.

The brachial plexus block can be performed in several ways, such as inter scalene, supraclavicular, infraclavicular, or axillary block, depending on the location and type of surgery. This block is commonly used in orthopedic surgeries, hand surgeries, trauma procedures, and other surgical interventions involving the upper extremity. It provides effective anesthesia and pain control in the area, allowing patients to undergo surgical procedures with less discomfort and a more comfortable recovery (27,28).

Supraclavicular brachial plexus block is a type of block that allows the brachial plexus to be approached in the most compressed and smallest area of its course, it is the ideal anatomical point to achieve a complete block of all the branches that make up the plexus. However, this block should only be performed with a US-guided technique because of the large number of important anatomical structures in its vicinity (22, 27).

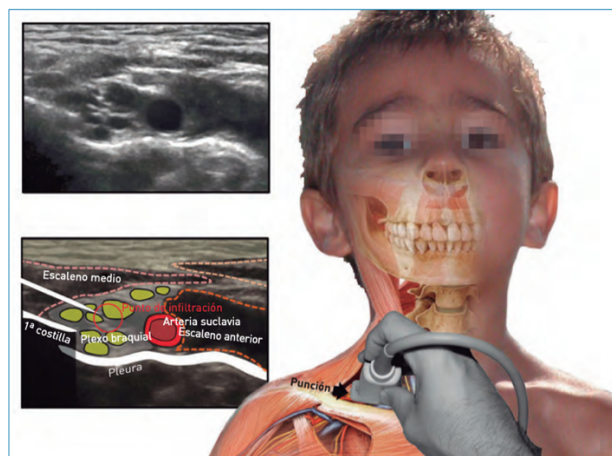


Figure 5 - Illustration of the brachial plexus for the Supraclavicular approach. Probe position and image in "cluster of grapes" lateral to artery subclavian and over the pleural dome. The puncture is performed in plane, from lateral to medial, depositing the local anesthetic on the deeper plexus Brachial to Improve the Trunk Lock lower (the most difficult to block with this boarding). Image obtained from Anesthesia regional. Bloqueos periféricos.pdf.

Regarding anatomy, shown in Figure 5, the transducer position is above and parallel to the clavicle, with a slight caudal tilt (22). The subclavian artery, a pulsatile, hypoechoic structure resting on the first rib or pleural dome, depending on the ultrasound (US) slice, is the essential landmark for the approach. The brachial plexus rests on the laterosuperior region of the artery and has a shape similar to a "bunch of grapes", considered a cluster of hypoechoic structures grouped in the form of a cluster. The puncture is performed flat, infiltrating 0.5 mL/kg of local anesthetic (22).

Infraclavicular brachial plexus block is a block that allows a more caudal approach to the brachial plexus and is at least as effective as the previous one, shown in Figure 6 (22); its indications are very similar to those of the supraclavicular approaches. As it is more superficial in children, it guarantees clearer images than in adults, which makes it easier to perform. As it is a clean area and easy to fix the catheter, it is a good option for continuous techniques (28).

The references for the puncture are the axillary artery and vein. The brachial plexus is attached to the external area of the artery, embracing it in the form of a crescent. The block is performed flat, infiltrating 0.5 mL/kg of local anesthetic (22).

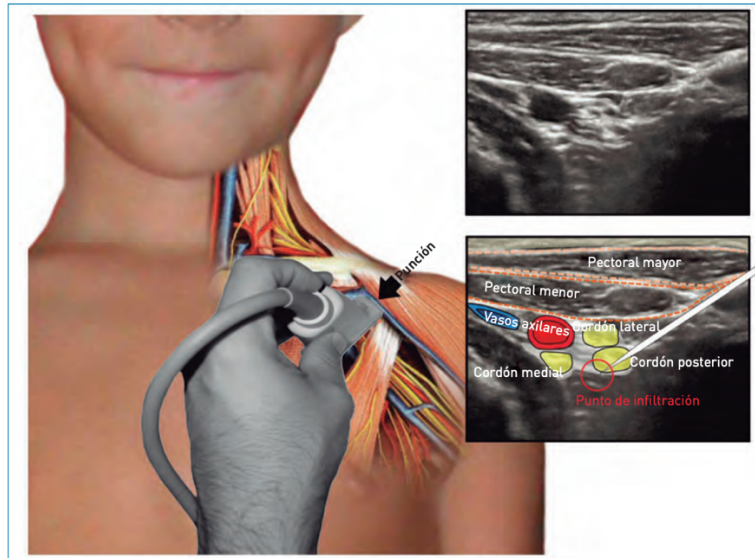

Figure 6 - Illustration of the brachial plexus for infraclavicular approach. Position Probe & Image Half-moon brachial plexus hugging to the axillary artery (lateral, posterior, and medial fasciculus). Flat puncture, trying to deposit the local anesthetic between the medial and posterior cord, in the Deepest plexus brachial. Image obtained from Anestesia regional. Bloqueos periféricos.pdf.

Femoral Nerve Block

The femoral nerve block is the most commonly performed lower extremity PNB in pediatric patients. FNB is not a complete block, it provides analgesia and anesthesia in the anterior thigh, and anterior aspect of the leg up to the knee without great technical and material requirements (24).

This block is mainly used for surgical procedures in areas, such as hip, femur, knee, or thigh surgeries. Surgical procedures include femoral fractures, osteotomies, correction of deformities, or fitting of orthopedic devices (22).

The femoral nerve block technique in children is usually performed with the patient in the supine position. The femoral nerve is identified and located anatomically, using the techniques mentioned below (25).

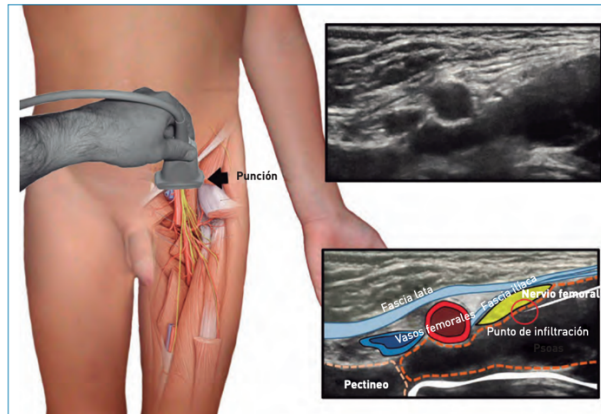


Figure 7 - Illustration of the Lumbar plexus with Femoral approach. Position the probe and image in the shape of an "eyebrow" arranged laterally to the femoral vessels. The puncture is performed from lateral to medial, depositing the anesthetic under the femoral nerve. Image obtained from Anestesia regional. Bloqueos periféricos.pdf.

Regarding the anatomy of the area, shown in Figure 7, the nerve is identified laterally to the artery, with the femoral vein medially to the artery (22). The psoas muscle is located below the vascular bundle because the femoral nerve is under the iliac fascia. Over the femoral vessels and iliac fascia, there is another fibrous layer called the fascia latae. The femoral nerve has an eyebrow-like shape beneath these layers. Near the femoral artery, there is a dense area of fat and tissue, which can easily be mistaken for the femoral nerve. The puncture is performed in flat position, infiltrating 0.3-0.4 mL/kg of local anesthetic (22, 28).

Sciatic nerve block

The sciatic nerve block is used in a variety of surgical interventions and therapeutic procedures to provide effective analgesia and anesthesia in the posterior thigh and leg region (29).

The sciatic nerve is a long, voluminous nerve. It runs along the entire length of the lower limb, taking up the sensation of a large part of the leg, from the knee to the foot. It can be approached at many points along its course, as shown in Figure 8, a rapid scan will easily detect it even in the absence of a major vascular structure to aid in identification (22). The

subgluteal level is where the probe is positioned, transverse to an imaginary lengthwise line that runs along the leg (22,30).

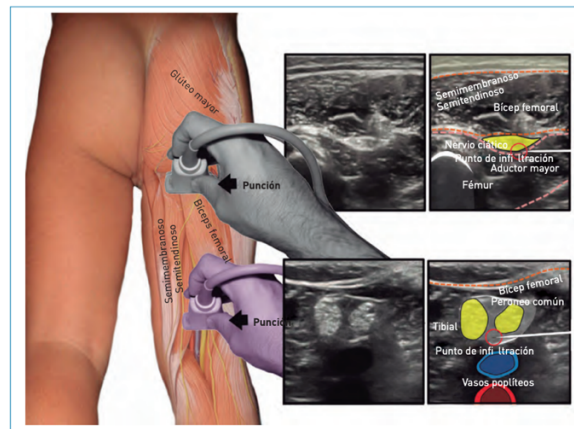


Figure 8 - Illustration of the Sciatic Nerve for subgluteal and popliteal approaches. Probe position, sonoanatomy, and point of view puncture of the femoral nerve at the subgluteal and popliteal level. The puncture should be performed at the lowest possible angle about the US probe, to allow better vision of the needle. Image obtained from Anestesia regional. Bloqueos periféricos.pdf.

The puncture is performed flat, infiltrating 0.25-0.3 mL/kg of local anesthetic. Examples of procedures where we use this technique include femur fracture reduction, cruciate ligament repair in the knee, foot and ankle surgeries such as clubfoot correction... This block allows adequate pain control during and after these surgeries, improving the pediatric patient experience and facilitating recovery.

Peripheral Nerve Catheter Technique

Catheter Techniques consist of the insertion of a catheter near a specific peripheral nerve to deliver local anesthetics continuously or intermittently. This is done to provide effective and prolonged analgesia to a specific area of the body, such as an extremity or anatomical region, during and after a surgical or painful procedure (22).

The technique takes advantage of the ability of peripheral nerves to transmit sensory and motor signals to and from the CNS. By placing a catheter near a nerve, local anesthetic

can be delivered directly to the area surrounding the nerve, thus blocking the transmission of pain from that region to the brain (23).

In pediatric patients, differences in pain tolerance and anxiety should be considered. It is important to ensure a comfortable and reassuring environment for the children, possibly with the use of appropriate distraction or sedation techniques. In children is recommended to start with easier sites for catheter insertion, such as the femoral nerve (23).

The insertion of the catheter is performed with the help of nerve localization techniques, such as nerve stimulation, US, or a combination of both. This ensures that the catheter is placed precisely and securely close to the target nerve (23).

Once the catheter is in place, it is connected to an infusion system that allows controlled administration of local anesthetics. This delivery can be continuous, providing constant analgesia over a prolonged period, or intermittent, allowing dosing as needed to maintain pain relief (22).

4.3. Regional Anesthesia Techniques in Pediatric Patients

Different techniques can be used for localization of the nerves that need to be blocked, some of the common techniques include Surface Mapping and Percutaneous Peripheral Nerve Stimulation or Ultrasonography (31, 32).

Ultrasound-guided Nerve Block Technique

Ultrasound has become an invaluable tool for nerve localization in regional anesthesia. It allows real-time visualization of anatomical structures, including peripheral nerves, which facilitates accurate identification of the target nerve and administration of local anesthetic. US is especially useful in pediatrics, where anatomical structures may be smaller and more difficult to palpate (31).

This technique has many advantages. Firstly, not requiring ionizing radiation, ensures a safe environment for patients. In addition, US takes advantage of the wide US windows

provided by the lower levels of ossification in pediatric patients, allowing a clearer visualization of the spine (31,33).

This technique enables the use of considerably lower doses of local anesthetic, significantly decreasing the risk of toxicity (31).

The ability to use small volumes of local anesthetic facilitates multiple blocks with the maximum dose of local anesthetic, thus maximizing pain control. Specifically in infants, where the anatomy is compact and the risk of damage is higher, visualization of the nerve and adjacent structures via US implies more safety to the procedure (31,33).

Surface Mapping and Percutaneous Peripheral Nerve Stimulation

In some cases, peripheral nerves may be palpated superficially on the surface of the skin, especially in areas where the nerves are close to superficial bony structures. Anatomical landmarks, such as bones, vessels, or muscles, can help guide the anesthesiologist in the precise location of the nerve (34).

After localizing the nerve, the Percutaneous Peripheral Nerve Stimulation technique can also be applied. It involves the use of a peripheral nerve stimulator to identify the target nerve and confirm its location. The stimulator sends small electrical currents to the nerve, resulting in an observable muscle response if the nerve is nearby. This can help locate the nerve and confirm its identity prior to administration of the local anesthetic (34).

4.4. IVRA Anesthesia

Intravenous regional anesthesia (IVRA) is a technique also called 'Bier Block' that consists of injecting the anesthetics in the venous system of the limb, which was previously isolated by tourniquet technique in order to achieve pain and sensation relief, shown in Figure 9 (37). Lately, IVRA has become an obsolete technique.

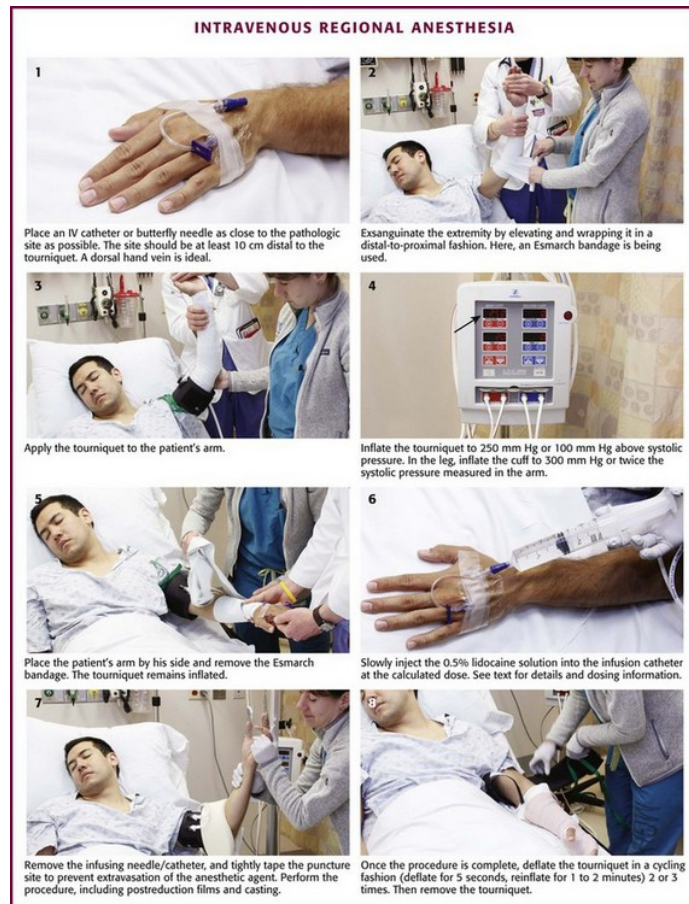

Figure 9 - Illustration of IVRA technique. Image obtained from <https://clinicalgate.com/intravenous-regional-anesthesia/>

We can distinguish two main groups depending on the extremity we want to isolate, Upper extremity, used in procedures such as ganglionectomy, or Lower extremity, any foot, ankle, or distal lower extremity orthopedic procedure (35).

The technique for IVRA for the upper extremity involves several key steps. Initially, an indwelling plastic catheter is inserted into a peripheral vein, reaching as far distally as possible. Simultaneously, a double-pneumatic tourniquet is placed on the upper arm's proximal cuff. To facilitate this process, the entire arm is elevated allowing passive exsanguination. An extra measure involves applying a rubber Esmarch bandage. The axillary artery is digitally occluded during these steps (35,36).

Once the proximal cuff is inflated and Esmarch bandage is removed, approximately 30–50 mL of 0.5% lidocaine HCl are injected through the indwelling plastic catheter. The specific volume administered depends on the size of the arm. Subsequently, the

intravenous cannula in the surgical extremity is withdrawn, and prompt pressure is applied. After 25–30 minutes after the onset of anesthesia or upon patient complaint of tourniquet pain, the distal cuff is inflated, and the proximal cuff is deflated aiming to minimize the development of tourniquet pain (35,36).

The main difference in IVRA between the upper and lower extremities is that IVRA technique for the lower extremity requires a higher amount of local anesthetic solutions, due to the evident size difference between vascular compartments (35,36).

Intravenous regional anesthesia used to be a viable option in the management of pediatric patients in traumatological procedures like the reduction of fractures, especially of the upper extremities. Innovations in regional anesthesia, together with concerns regarding complications such as tourniquet discomfort and the risk of systemic toxicity, have contributed to its declining use. Up-to-date alternatives with improved safety and efficacy for peripheral blocks have replaced IVRA in contemporary clinical practice (35,36).

5. COMPLICATIONS OF LOCAL ANESTHETICS IN PEDIATRIC PATIENTS

As we have been discussing throughout the research, pediatric patients are frequently given local anesthetics for a variety of medical treatments, ranging from basic dermatological procedures to major surgeries. Although pediatric patients encounter problems and challenges due to differences in physiology, anatomy, and pharmacokinetics, local anesthetics are generally considered safe and effective.

Despite their extensive usage, local anesthetics can have side effects that range from minor discomfort to serious systemic toxicity. Healthcare professionals must be aware of the possible side effects of local anesthetics in pediatric patients in order to guarantee safe administration and reduce risks (38).

5.1. Complications Statistics

The practice of regional anesthesia in children, although widely beneficial, is not without risks and complications. Statistics show that complications in this population group are rare, but can include events such as local anesthetic toxicity, neurological lesions, infections, and vascular complications (46).

The incidence of these complications varies depending on the type of regional block and the technique used. For example, peripheral blocks generally have a lower risk of serious complications compared to central blocks. Ongoing surveillance and specialized training in pediatric regional anesthesia techniques are essential to minimize these risks and ensure the safety and efficacy of procedures (38, 46).

A study conducted by the Pediatric Regional Anesthesia Network (PRAN) investigated the Use and Incidence of Complications of Pediatric Regional Anesthesia. The results showed during the initial 3-year study period, 14,917 regional blocks were performed in 13,725 patients. Most of these blocks (96%) were performed for elective surgeries. Regarding the physical status of the patients according to the American Society of Anesthesiologists (ASA) classification, 53% of the blocks were performed in ASA I patients, 30% in ASA II, 15% in ASA III, and 0.76% in ASA IV. Only one block was placed in one ASA V patient. The types of blockages, their number, and the incidence of complications are detailed in Figures 10 and 11 (46).

	Total blocks	None	Nerve stimulator	Fluoroscopy	Ultrasound	Epidurogram	Other
Caudal-sacral	274	241	0	8 (3%)	14 (5%)	15 (5%)	0
Caudal-lumbar	261	200	2	10 (4%)	20 (8%)	31 (12%)	0
Caudal-thoracic	195	107	1	25 (13%)	22 (11%)	48 (25%)	1
Lumbar	1518	1337	5	30 (2%)	24 (2%)	93 (6%)	0
Thoracic	695	587	3	23 (3%)	19 (3%)	58 (8%)	0
Totals	2946	2475	11	96 (3%)	99 (3%)	245 (8%)	1

Figure 10 - Postoperative Complications Measured. Image obtained from A Multi-Institutional Study of the Use and Incidence of Complications of Pediatric Regional Anesthesia. Anesth Analg. 2012.

	UUB	PB	EMB	CP	ADR	RP	NP	H	I	PO
Caudal-sacral	1	0	1	5	1	1	0	0	2	2
Caudal-lumbar	1	0	4	6	8	0	0	0	2	3
Caudal-thoracic	0	0	1	5	2	0	0	0	7	1
Lumbar	23	1	35	71	30	5	8	0	9	23
Thoracic	15	0	9	54	26	0	15	0	12	14
Totals	40	1	50	141	67	6	23	0	32	43

UUB = unintentional unilateral blockade; PB = prolonged blockade; EMB = excessive motor blockade; CP = catheter problem (dislodgment, occlusion); ADR = adverse drug reaction; RP = respiratory problem; NP = neurological problem; H = hematoma; I = infection; PO = postoperative other.

Figure 11 - Intraoperative Complications Measure. Image obtained from A Multi-Institutional Study of the Use and Incidence of Complications of Pediatric Regional Anesthesia. Anesth Analg. 2012.

No deaths or serious complications with sequelae lasting longer than 3 months were reported (95% CI 0–2:10,000). The distribution of the types of blockages among the different centers is shown in Figure 12 (46).

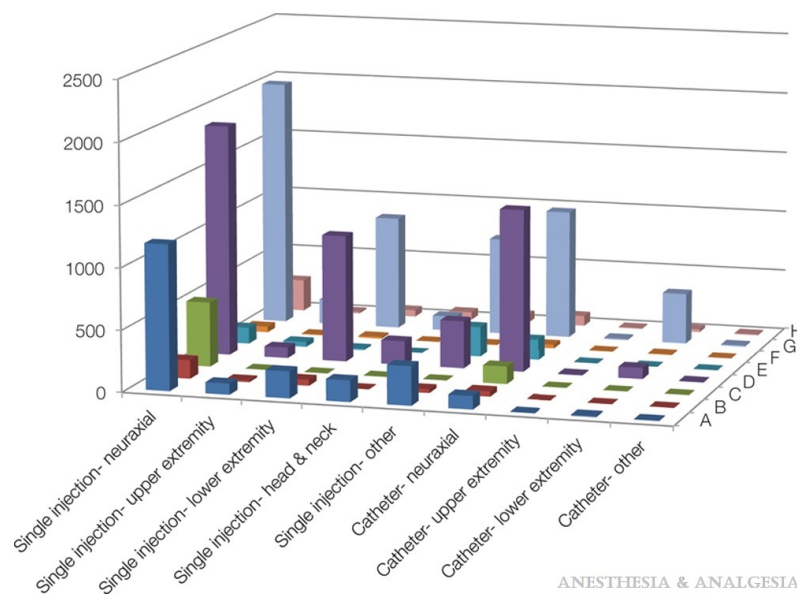


Figure 12 - Distribution of blocks by study site. Each letter refers to a single study center and was assigned randomly (i.e., the order does not correspond to the list of study centers in the Appendix). Image obtained from A Multi-Institutional Study of the Use and Incidence of Complications of Pediatric Regional Anesthesia. Anesth Analg. 2012.

In general, Pediatric Regional Anesthesia is safe, with a low risk for complications. A large prospective cohort study involving almost 15,000 pediatric blocks from multiple academic medical centers showed that most complications occurred during needle or catheter placement, with no long-term effects reported. The PRAN data from pediatric institutions in the US indicate safety comparable to other audits. Issues with catheters, possibly due to their size, connectors, fixation methods, or the novelty of peripheral nerve catheters, emphasize the need for better catheter stability. The thorough auditing process ensures these data provide a reliable estimate of complication rates. As the PRAN

database expands, it will play a vital role in risk assessment and organizing future large-scale clinical studies in pediatric regional anesthesia (38, 46).

5.2. Local Anesthetic Systemic Toxicity

In children, toxicity of local anesthetics mainly affects the heart and CNS. There are also allergic reactions, predominantly to local ester anesthetic solutions (39).

The pharmacokinetic differences already discussed, together with the immaturity of the blood-brain barrier, may increase the likelihood of neonates developing CNS toxicity. However, early signs and symptoms of systemic toxicity may be masked by co-administration of general anesthesia.

Symptoms

The toxicity of local anesthetics in pediatrics can manifest itself with various effects on the CNS and CV system (41).

Central Nervous System

Symptoms include dizziness and lightheadedness, which disoriented children with balance problems. In addition, visual and auditory disturbances can be present, such as blurred vision or decreased hearing acuity. These may have an impact on the child's ability to adequately perceive the environment (41).

Common symptoms of CNS toxicity of local anesthetics include muscle spasms and tremors, which manifest as involuntary and uncontrollable movements in different parts of the body. Toxicity can cause generalized convulsions in severe cases, which is a medical emergency and requires immediate intervention to avoid dangerous complications (41).

Cardiovascular System

Toxicity can also be manifested with direct adverse effects on the CV System, including a range of alterations in cardiac function and vascular tone (4).

This includes a rapid and depressed phase of repolarization of the Purkinje fibers, which may increase the likelihood of cardiac arrhythmias. A depressed spontaneous firing of the sinoatrial node is also observed, which may alter the heart rhythm. Myocardial contractility decreases because of negative inotropic effects on the heart muscle. This harms the heart's ability to pump blood efficiently. In addition, this decrease in contractility may be caused by a change in calcium influx. At low concentrations of local anesthetics vasoconstriction in vascular tone is observed, while at higher concentrations vasodilatation occurs. This may alter pulmonary vascular resistance, which may affect the cardiopulmonary function of patients (41)

Healthcare professionals must be alert and aware of these signs and symptoms in pediatric patients receiving local anesthetics for early detection and appropriate management.

Management

In pediatric practice, early detection and effective management of LAST is essential, especially because of the possibility that early signs and symptoms may be masked by the simultaneous administration of general anesthesia. If toxicity is suspected, it is essential to discontinue administration of the local anesthetic immediately. Basic life support (BLS) should be initiated. It is crucial to ensure full ventilation of the patient with oxygen and IV access to medications (41).

In case of seizures, should be controlled with benzodiazepines or other anesthetic agents. Advanced life support should be initiated immediately in case of cardiac arrest (41).

In case of arrhythmias, it is important to be aware that are often difficult to control and therefore resuscitation should be continued. Lipid administration should also be considered, following the protocol, shown in Figure 13, established by the Association of Anesthetists of Great Britain and Ireland (AAGBI (40).

AAGBI Safety Guideline

Management of Severe Local Anaesthetic Toxicity



1 Recognition	Signs of severe toxicity: <ul style="list-style-type: none"> • Sudden alteration in mental status, severe agitation or loss of consciousness, with or without tonic-clonic convulsions • Cardiovascular collapse: sinus bradycardia, conduction blocks, asystole and ventricular tachyarrhythmias may all occur • Local anaesthetic (LA) toxicity may occur some time after an initial injection 	
2 Immediate management	<ul style="list-style-type: none"> • Stop injecting the LA • Call for help • Maintain the airway and, if necessary, secure it with a tracheal tube • Give 100% oxygen and ensure adequate lung ventilation (hyperventilation may help by increasing plasma pH in the presence of metabolic acidosis) • Confirm or establish intravenous access • Control seizures: give a benzodiazepine, thiopental or propofol in small incremental doses • Assess cardiovascular status throughout • Consider drawing blood for analysis, but do not delay definitive treatment to do this 	
3 Treatment	IN CIRCULATORY ARREST <ul style="list-style-type: none"> • Start cardiopulmonary resuscitation (CPR) using standard protocols • Manage arrhythmias using the same protocols, recognising that arrhythmias may be very refractory to treatment • Consider the use of cardiopulmonary bypass if available GIVE INTRAVENOUS LIPID EMULSION (following the regimen overleaf) <ul style="list-style-type: none"> • Continue CPR throughout treatment with lipid emulsion • Recovery from LA-induced cardiac arrest may take >1 h • Propofol is not a suitable substitute for lipid emulsion • Lidocaine should not be used as an anti-arrhythmic therapy 	WITHOUT CIRCULATORY ARREST Use conventional therapies to treat: <ul style="list-style-type: none"> • hypotension, • bradycardia, • tachyarrhythmia CONSIDER INTRAVENOUS LIPID EMULSION (following the regimen overleaf) <ul style="list-style-type: none"> • Propofol is not a suitable substitute for lipid emulsion • Lidocaine should not be used as an anti-arrhythmic therapy
4 Follow-up	<ul style="list-style-type: none"> • Arrange safe transfer to a clinical area with appropriate equipment and suitable staff until sustained recovery is achieved • Exclude pancreatitis by regular clinical review, including daily amylase or lipase assays for two days • Report cases as follows: <ul style="list-style-type: none"> in the United Kingdom to the National Patient Safety Agency (via www.npsa.nhs.uk) in the Republic of Ireland to the Irish Medicines Board (via www.imb.ie) <p>If Lipid has been given, please also report its use to the international registry at www.lipidregistry.org. Details may also be posted at www.lipidrescue.org</p>	

Intralipid is kept in the Resuscitation Trolleys for Main Theatres, Out-patients Theatres, DCN theatres & EBU Theatres.

AAGBI Safety Guideline: Management of Severe Local Anaesthetic Toxicity (2016). The Association of Anaesthetists of Great Britain

Figure 13 – AAGBI Safety guidelines protocol. Image obtained from <https://roa.ac.uk/sites/default/files/documents/2019-11/3%20Checking%20Anaesthetic%20Equipment%20-%202012.pdf>

AAGBI consists of immediate initial administration of intravenous lipid bolus as part of the treatment. Lipids act as a 'sink' for local anesthetics, reducing their concentration in the blood circulation and limiting their toxic effect. This approach is based on the theory that local anesthetics are lipophilic and therefore bind to lipids in the bloodstream, decreasing their availability to cause adverse effects (40, 41).

If, after five minutes, the condition fails to improve or if CV stability has not been restored, give a maximum of two repeat boluses of the same amount. Three boluses in total, including the first one, should be given a maximum, with a 5-minute interval in between each. Furthermore, maintain the infusion at the same pace for another five

minutes, but if the CV stability doesn't improve, increase the rate to 30 ml/kg/h. Continue the infusion until the maximal dosage of lipid emulsion has been reached or until stable CV function has been restored. The implementation of this protocol helps healthcare professionals to effectively address LAST and improve outcomes in affected patients (40).

Prevention

To prevent systemic toxicity in children, several points need to be considered. It is advisable to use less toxic drugs, such as levobupivacaine or ropivacaine, and it is recommended not to exceed the maximum dose, especially in neonates, where it is prudent to reduce the dose by half (39, 41)

During anesthetic use, it is essential to inject small doses and aspirate repeatedly. US helps to see the injections and allows lower doses of drugs to be administered. Limit newborn infusions to 48 hours and use caution with repeated doses. Although this is limited by the type of general anesthetic given, a test dose of epinephrine may be considered to detect an intravascular injection (41).

It is essential to continuously monitor all children receiving local anesthetic solutions, especially during continuous infusions, to detect any adverse effects promptly, regardless of the technique used.

5.3. Complications associated with the technique of Regional Anesthesia

Regional anesthesia is a technique used to provide analgesia and anesthesia during surgical procedures and pain management. Although considered safe and effective, it is not without potential complications.

These complications can range from minor side effects to serious adverse events requiring immediate medical intervention. Including, neurological injury, epidural hematoma, infection, or hemodynamic effects... (38)

It is crucial to understand the potential complications associated with regional anesthesia in order to identify and manage them appropriately, thus ensuring the safety and well-being of patients.

Neurologic injury

Neurological injury is a serious complication associated with regional anesthesia. It can occur as a result of different reasons, injection of anesthetic into the spinal canal, direct injury to nerves during insertion of an epidural catheter, compression of nerves due to accumulation of blood or cerebrospinal fluid in the epidural space, etc. (44,45).

Neurological damage may manifest as weakness, numbness, tingling, or even paralysis in the lower extremities or the affected area. Injury, although rare, can have serious effects and requires immediate medical attention for evaluation and appropriate management (44, 45).

Epidural and Spinal Hematoma

Another serious complication that can arise because of regional anesthesia is epidural and spinal hematoma. This problem, although not very common, occurs when blood accumulates in the epidural or spinal space, compressing the spinal cord or nerve roots, which can cause severe neurological symptoms. Accidental puncture of the dura during the procedure or injury to a blood vessel during epidural catheter insertion can also cause an epidural hematoma (44, 45).

Symptoms may include severe pain in the back or injection area, weakness, numbness, difficulty walking, loss of bladder or bowel control, and even paralysis.

Immediate medical evaluation is required when an epidural hematoma is suspected and, in some cases, urgent surgical intervention may be required to relieve pressure on the spinal cord and prevent permanent neurological damage.

Infection

Infection is another complication associated with epidural anesthesia. It can occur as a result of manipulation of the epidural catheter insertion site or the introduction of the contaminated catheter (1).

Symptoms of epidural infections include persistent pain at the puncture site, fever, localized swelling, redness, and, in severe cases, the formation of epidural abscesses. Depending on the type of microorganism, these infections may be bacterial, fungal, or viral and may require treatment with antibiotics, antifungals, or antivirals (44).

In extreme cases, removal of the epidural catheter and surgical drainage of the abscess may be necessary to avoid further complications.

Hemodynamic Effects and Total Spinal Anesthesia

Hemodynamic instabilities and TSA are complications that may arise as a consequence of regional anesthesia. These complications may manifest as a drop in blood pressure or an adverse reaction to the anesthetic administered, which may result in hypotension or even hypovolemic shock (1).

TSA, also known as 'high spinal block', is an extreme form of anesthesia that can occur when injected in the wrong location, injecting it too high in the spine, resulting in a total loss of sensation and movement below the level of injection. These complications can be serious and require immediate intervention to stabilize the patient (45).

Healthcare providers need to be aware of the possibility of all side effects while administering epidural anesthesia and take precautions to reduce patient risk. In order to provide the safety and well-being of patients receiving epidural anesthesia, it is crucial that medical professionals have sufficient training in order to rapidly identify and manage any indications of neurological compromise (45).

6. ADVANTAGES AND DISADVANTAGES OF REGIONAL ANESTHESIA

Regional anesthesia in children implies several advantages compared to general anesthesia, making it more valuable and useful in pediatric care. Includes both patient and hospital benefits (47).

6.1. Advantages

Firstly, superior analgesia, resulting from the use of regional anesthesia contributes to an easier and calmer experience for both, pediatric patients and caregivers. It also contributes to the reduction of surgical stress, crucial in the vulnerable pediatric group, ensuring a more positive surgical experience and potentially expediting recovery (4).

Additionally, the utilization of regional anesthesia is associated with a lower incidence of postoperative nausea and vomiting, addressing common concerns in pediatric surgical settings. The reduction of postoperative pain is another noteworthy benefit, fostering improved overall comfort and facilitating a smoother recovery process (48,49).

Furthermore, regional anesthesia has been linked to a lower occurrence of respiratory complications, reducing the requirement for postoperative ventilator support, a valuable outcome, especially for neonates and infants undergoing upper abdominal and thoracic surgery. Promoting optimal respiratory function during and after surgery (48,49).

This technique significantly reduces the need for opioids, mitigating the potential risks associated with opioid use in children, such as respiratory depression and sedation. This not only contributes to enhanced safety but also aligns with the growing emphasis on minimizing opioid-related complications (48,49).

Moreover, Hemodynamic stability is a notable advantage, especially in children up to 8 years of age undergoing regional anesthesia, such as PNB. Instances of significant hypotension are rare, contributing to a stable hemodynamic profile during the procedure. Overall, the multifaceted advantages of regional anesthesia underscore its role as a beneficial strategy in optimizing perioperative outcomes for children. The advantages of regional anesthesia in children extend beyond the patient to benefit hospital management.

Pain-free children are notably easier to nurse, reducing the labor intensity of caregiving tasks and facilitating smoother patient care (48,49).

The reduced Minimum Alveolar Concentration (MAC) in regional anesthesia not only benefits the patient but also contributes to rapid discharge from the first-stage recovery. This expedited recovery process enhances overall efficiency in managing pediatric patients (4).

A significant advantage for hospitals is the decreased requirement for postoperative ventilatory support. This is particularly valuable in situations where there is limited support available in the Pediatric Intensive Care Unit (PICU). Moreover, the overall length of stay is reduced, streamlining the hospitalization process and optimizing resource utilization (48,49).

6.2. Disadvantages

While offering all these advantages, it is also important to acknowledge potential disadvantages and challenges that the pediatric population might face.

First, the administration of regional anesthesia in children requires experts and precision for the corresponding technique, improper technique could lead to dangerous and life-long complications such as nerve damage or vascular injury, as mentioned in the previous chapters. Pediatric patients may also experience discomfort, nervousness, or anxiety during the placement of regional blocks, which can be challenging for both the child and the healthcare providers involved (1).

Additionally, there is a risk of local anesthetic systemic toxicity (LAST), although this is not that common, but is still something we need to keep as a consideration (41).

Furthermore, the suitability of regional anesthesia in pediatric patients can vary based on the nature of the surgical procedure and specific patient conditions. Some surgical scenarios may present challenges or limitations for the effective application of regional anesthesia in children (48). For example, certain emergency procedures or surgeries

requiring rapid onset of anesthesia might not be conducive to the time it takes to perform regional blocks and wait for their onset. In such cases, general anesthesia may be preferred for its quicker induction and more predictable control over the depth of anesthesia (48,49).

Additionally, the location and type of surgery can influence the feasibility of regional anesthesia. Procedures involving multiple anatomical sites or extensive areas may be challenging to cover adequately with regional techniques. For instance, a complex abdominal surgery involving multiple quadrants may need a combination of regional and general anesthesia or may lean towards general anesthesia for simplicity (48,49).

Furthermore, some medical conditions or anatomical variations in pediatric patients may limit the appropriateness of regional techniques. Conditions such as bleeding disorders, infections at the injection site, or pre-existing neurological conditions may pose contraindications or increase the risk of complications associated with regional anesthesia. In some cases, the duration of the block may not align with the entirety of the postoperative period, needing additional analgesic interventions. Moreover, the potential for delayed mobilization or weakness in the limbs after certain regional techniques may impact postoperative recovery (48,49).

Finally, individual patient variability in response to regional anesthesia may pose challenges in predicting the effectiveness and duration of the block. Recognizing these disadvantages underscores the importance of careful patient selection, skilled administration, and a comprehensive understanding of both the benefits and limitations of regional anesthesia in pediatric care (48,49).

CONCLUSION

Regional anesthesia in pediatric patients is a safe, useful, beneficial, and effective technique that provides excellent analgesia, and postoperative pain control, reduces the need for opioids, and minimizes the secondary effects associated with general anesthesia. A coordinated and comprehensive approach is crucial. The appropriate use of regional anesthesia, under the supervision of experienced pediatric anesthesiologists, can significantly improve the surgical experience and recovery of pediatric patients, contributing to high-quality, child-centered care.

REFERENCES

1. NYSORA. NYSORA. 2018 [cited 2024 Jun 11]. Regional Anesthesia in Pediatric Patients: General Considerations. Available from: <https://www.nysora.com/topics/sub-specialties/pediatric-anesthesia/regional-anesthesia-pediatric-patients-general-considerations/>
2. Feehan T, Packiasabapathy S. Pediatric Regional Anesthesia. In: StatPearls [Internet]. Treasure Island (FL): StatPearls Publishing; 2024 [cited 2024 Jun 11]. Available from: <http://www.ncbi.nlm.nih.gov/books/NBK572106/>
3. Shah RD, Suresh S. Applications of regional anaesthesia in paediatrics. *Br J Anaesth*. 2013 Dec;111 Suppl 1:i114-124.
4. how-children-are-different-anatomical-and-physiological-differences.pdf [Internet]. [cited 2024 Jun 11]. Available from: https://www.childrens.health.qld.gov.au/__data/assets/pdf_file/0031/179725/how-children-are-different-anatomical-and-physiological-differences.pdf
5. Hadzic A, editor. Textbook of regional anesthesia and acute pain management. Second edition. New York: McGraw-Hill Education; 2017.
6. Stringer MD. Anatomy of the Infant and Child. In: Puri P, editor. Pediatric Surgery [Internet]. Berlin, Heidelberg: Springer; 2017 [cited 2024 Jun 11]. p. 1–19. Available from: https://doi.org/10.1007/978-3-642-38482-0_5-1
7. Huelke DF. An Overview of Anatomical Considerations of Infants and Children in the Adult World of Automobile Safety Design. *Annu Proc Assoc Adv Automot Med*. 1998;42:93–113.
8. Snyder BA. Regional anesthesia in the pediatric patient. *Nurse Anesth*. 1990 Mar;1(1):16–20.
9. Anderson BJ, Chojnowska EI. Pharmacokinetics and the drugs used in pediatric regional anesthesia. *Tech Reg Anesth Pain Manag*. 1999 Jul 1;3(3):129–37.

10. NYSORA. NYSORA. 2018 [cited 2024 Jun 11]. Clinical Pharmacology of Local Anesthetics. Available from: <https://www.nysora.com/topics/pharmacology/clinical-pharmacology-local-anesthetics/>
11. Camfield AS, McCutchan A. Local Anesthetics in Children. In: StatPearls [Internet]. Treasure Island (FL): StatPearls Publishing; 2024 [cited 2024 Jun 11]. Available from: <http://www.ncbi.nlm.nih.gov/books/NBK572090/>
12. Dalens B. Pediatric Regional Anesthesia. Routledge; 2019. 504 p.
13. Regional Anesthetic Blocks - Abstract - Europe PMC [Internet]. [cited 2024 Jun 11]. Available from: <https://europepmc.org/article/NBK/nbk563238>
14. Walker SM, Yaksh TL. Neuraxial Analgesia In Neonates And Infants: Review of Clinical and Preclinical Strategies for the Development of Safety and Efficacy Data. *Anesth Analg*. 2012 Sep;115(3):638.
15. Spinal and Epidural Anesthesia | SaskHealthAuthority [Internet]. [cited 2024 Jun 11]. Available from: <https://www.saskhealthauthority.ca/your-health/conditions-diseases-services/healthline-online/acl7147>
16. Cleveland Clinic [Internet]. [cited 2024 Jun 11]. Epidural: What It Is, Procedure, Risks & Side Effects. Available from: <https://my.clevelandclinic.org/health/treatments/21896-epidural>
17. Toronto Notes [2020].pdf.
18. Epidural Anesthesia and Analgesia - NYSORA [Internet]. [cited 2024 Jun 11]. Available from: <https://www.nysora.com/topics/regional-anesthesia-for-specific-surgical-procedures/abdomen/epidural-anesthesia-analgesia/>
19. Olawin AM, Das JM. Spinal Anesthesia. In: StatPearls [Internet]. Treasure Island (FL): StatPearls Publishing; 2024 [cited 2024 Jun 11]. Available from: <http://www.ncbi.nlm.nih.gov/books/NBK537299/>

20. Operater. NYSORA. 2018 [cited 2024 Jun 11]. Spinal Anesthesia. Available from: <https://www.nysora.com/techniques/neuraxial-and-perineuraxial-techniques/spinal-anesthesia-2/>
21. Operater. NYSORA. 2018 [cited 2024 Jun 11]. Combined Spinal-Epidural Anesthesia. Available from: <https://www.nysora.com/topics/regional-anesthesia-for-specific-surgical-procedures/abdomen/combined-spinal-epidural-anesthesia/>
22. Anesthesia regional. Bloqueos periféricos.pdf.
23. Dadure C, Capdevila X. Peripheral catheter techniques. Paediatr Anaesth. 2012 Jan;22(1):93–101.
24. NYSORA. NYSORA. 2018 [cited 2024 Jun 11]. Femoral Nerve Block - Landmarks and Nerve Stimulator Technique. Available from: <https://www.nysora.com/techniques/lower-extremity/femoral/femoral-nerve-block/>
25. Operater. NYSORA. 2018 [cited 2024 Jun 11]. Ultrasound-Guided Femoral Nerve Block. Available from: <https://www.nysora.com/techniques/lower-extremity/ultrasound-guided-femoral-nerve-block/>
26. Brachial plexus. In: Wikipedia [Internet]. 2024 [cited 2024 Jun 11]. Available from: https://en.wikipedia.org/w/index.php?title=Brachial_plexus&oldid=1224394932
27. Operater. NYSORA. 2018 [cited 2024 Jun 11]. Ultrasound-Guided Supraclavicular Brachial Plexus Nerve Block. Available from: <https://www.nysora.com/topics/regional-anesthesia-for-specific-surgical-procedures/upper-extremity-regional-anesthesia-for-specific-surgical-procedures/anesthesia-and-analgesia-for-elbow-and-forearm-procedures/ultrasound-guided-supraclavicular-brachial-plexus-block/>
28. Operater. NYSORA. 2018 [cited 2024 Jun 11]. Ultrasound-Guided Interscalene Brachial Plexus Nerve Block. Available from: <https://www.nysora.com/techniques/upper-extremity/intescalene/ultrasound-guided-interscalene-brachial-plexus-block/>

29. NYSORA. NYSORA. 2018 [cited 2024 Jun 11]. Sciatic Nerve Block - Landmarks and Nerve Stimulator Technique. Available from: <https://www.nysora.com/techniques/lower-extremity/sciatic-nerve-block/>
30. Operater. NYSORA. 2018 [cited 2024 Jun 11]. Ultrasound-Guided Sciatic Nerve Block. Available from: <https://www.nysora.com/topics/regional-anesthesia-for-specific-surgical-procedures/lower-extremity-regional-anesthesia-for-specific-surgical-procedures/foot-and-ankle/ultrasound-guided-sciatic-nerve-block-2/>
31. Tsui BCH, Suresh S, editors. Pediatric Atlas of Ultrasound- and Nerve Stimulation-Guided Regional Anesthesia [Internet]. New York, NY: Springer New York; 2016 [cited 2024 Jun 10]. Available from: <https://link.springer.com/10.1007/978-0-387-79964-3>
32. Sahin L, Soydinc MH, Sen E, Cavus O, Sahin M. Comparison of 3 different regional block techniques in pediatric patients. A prospective randomized single-blinded study. Saudi Med J. 2017 Sep;38(9):952–9.
33. Operater. NYSORA. 2018 [cited 2024 Jun 11]. Introduction to Ultrasound-Guided Regional Anesthesia. Available from: <https://www.nysora.com/topics/equipment/introduction-ultrasound-guided-regional-anesthesia/>
34. NYSORA. NYSORA. 2018 [cited 2024 Jun 11]. Electrical Nerve Stimulators and Localization of Peripheral Nerves. Available from: <https://www.nysora.com/topics/equipment/electrical-nerve-stimulators-localization-peripheral-nerves/>
35. Operater. NYSORA. 2018 [cited 2024 Jun 11]. Intravenous Regional Block for Upper and Lower Extremity Surgery. Available from: <https://www.nysora.com/techniques/intravenous-regional-anesthesia/intravenous-regional-block-upper-lower-extremity-surgery/>
36. Vaughn N, Rajan N, Darowish M. Intravenous Regional Anesthesia Using a Forearm Tourniquet: A Safe and Effective Technique for Outpatient Hand Procedures. Hand N Y N. 2020 May;15(3):353–9.

37. <https://clinicalgate.com/intravenous-regional-anesthesia/>
38. Walker BJ, Long JB, Sathyamoorthy M, Birstler J, Wolf C, Bosenberg AT, et al. Complications in Pediatric Regional Anesthesia: An Analysis of More than 100,000 Blocks from the Pediatric Regional Anesthesia Network. *Anesthesiology*. 2018 Oct 1;129(4):721–32.
39. Dickerson DM, Apfelbaum JL. Local anesthetic systemic toxicity. *Aesthet Surg J*. 2014 Sep;34(7):1111–9.
40. Anaesthesia ^a 2012 The Association of Anaesthetists of Great Britain and Ireland. <https://rcoa.ac.uk/sites/default/files/documents/2019-11/3%20Checking%20Anaesthetic%20Equipment%20-%202012.pdf>
41. Mahajan A, Derian A. Local Anesthetic Toxicity. In: StatPearls [Internet]. Treasure Island (FL): StatPearls Publishing; 2024 [cited 2024 Jun 11]. Available from: <http://www.ncbi.nlm.nih.gov/books/NBK499964/>
42. NYSORA. NYSORA. 2018 [cited 2024 Jun 11]. Regional Anesthesia and Systemic Disease. Available from: <https://www.nysora.com/topics/sub-specialties/comorbidities/regional-anesthesia-systemic-disease/>
43. Campos MG, Peixoto AR, Fonseca S, Santos F, Pinho C, Leite D. Assessment of main complications of regional anesthesia recorded in an acute pain unit in a tertiary care university hospital: a retrospective cohort. *Braz J Anesthesiol Elsevier*. 2022;72(5):605–13.
44. nhs.uk [Internet]. 2018 [cited 2024 Jun 11]. Side effects of an epidural. Available from: <https://www.nhs.uk/conditions/epidural/side-effects/>
45. Medicine LibreTexts [Internet]. 2021 [cited 2024 Jun 11]. 5.2: Complications of Spinal Anesthesia. Available from: [https://med.libretexts.org/Under_Construction/Developing_Anaesthesia_\(Pescod\)/05%3A_Obstetrics_and_Gynaecology/5.02%3A_New_Page](https://med.libretexts.org/Under_Construction/Developing_Anaesthesia_(Pescod)/05%3A_Obstetrics_and_Gynaecology/5.02%3A_New_Page)
46. Polaner DM, Taenzer AH, Walker BJ, Bosenberg A, Krane EJ, Suresh S, et al. Pediatric Regional Anesthesia Network (PRAN): A Multi-Institutional Study of the

Use and Incidence of Complications of Pediatric Regional Anesthesia. *Anesth Analg*. 2012 Dec;115(6):1353–64.

47. ASRA Pain Medicine [Internet]. [cited 2024 Jun 11]. Risks and benefits. Available from: <https://www.asra.com/patient-information/regional-anesthesia/risks-and-benefits>

48. ResearchGate [Internet]. [cited 2024 Jun 11]. Advantages and disadvantages of regional anesthesia compared to general... Available from: https://www.researchgate.net/figure/Advantages-and-disadvantages-of-regional-anesthesia-compared-to-general-anesthesia_tbl3_357466182

49. Yartsev A. Advantages and disadvantages of regional anaesthesia in ICU | Deranged Physiology [Internet]. [cited 2024 Jun 11]. Available from: <https://derangedphysiology.com/main/required-reading/trauma-burns-and-drowning/Chapter 5.2.2/advantages-and-disadvantages-regional-anaesthesia-icu>

ACKNOWLEDGEMENTS

I would like to thank my mentor, Professor Vilena Vrbanovic Mijatovic, PhD, who provided me with much patience, guidance, and understanding in writing this. Her expertise and mentoring have been invaluable not only for the completion of this thesis but also for my personal development in the context of a research environment.

I am immensely grateful to my parents Helen and Juanma, my brother Natxo, my boyfriend Jose Angel, and my family for supporting me during the past 6 years and always encouraging me to give the best of myself. Without their unwavering support, love, and encouragement, I would not have been able to complete this journey.

My thanks and appreciation also go to my colleagues and friends, my friends in Spain who have supported me during the past 6 years, providing encouragement and strength throughout this journey. They have been a constant source of motivation. Additionally, I am profoundly grateful for the new friends I have made during my time in Croatia and at the medical faculty. Your friendship and support have been invaluable, and I will always cherish the memories and bonds we have created. Thank you for being an integral part of this incredible journey.

BIOGRAPHY

Ane Cobos Anbuhl was born on October 29th, 1999, in Bilbao, Spain. She attended "Ayalde" high school in Bilbao. Ane's studies focused on Biology, Chemistry, Mathematics, and English. After graduating from high school, she started her studies at the School of Medicine, University of Zagreb. She was enrolled at the University of Zagreb, School of Medicine, Croatia between 2018-2024