

S2k guidelines on diagnosis and treatment of linear IgA dermatosis initiated by the European Academy of Dermatology and Venereology

Caux, Frédéric; Patsatsi, Aikaterini; Karakioulaki, Meropi; Antiga, Emiliano; Baselga, Eulalia; Borradori, Luca; Caproni, Marzia; Cardones, Adela R.; Chandran, Nisha Suyien; Dräger, Sören; ...

Source / Izvornik: **Journal of the European Academy of Dermatology and Venereology, 2024, 38, 1006 - 1023**

Journal article, Published version

Rad u časopisu, Objavljena verzija rada (izdavačev PDF)

<https://doi.org/10.1111/jdv.19880>

Permanent link / Trajna poveznica: <https://um.nsk.hr/um:nbn:hr:105:385625>

Rights / Prava: [Attribution-NonCommercial-NoDerivatives 4.0 International/Imenovanje-Nekomercijalno-Bez prerada 4.0 međunarodna](#)

Download date / Datum preuzimanja: **2024-12-29**
















Repository / Repozitorij:

[Dr Med - University of Zagreb School of Medicine Digital Repository](#)



GUIDELINES

S2k guidelines on diagnosis and treatment of linear IgA dermatosis initiated by the European Academy of Dermatology and Venereology

Frédéric Caux¹  | Aikaterini Patsatsi²  | Meropi Karakioulaki³ | Emiliano Antiga⁴  | Eulalia Baselga⁵ | Luca Borradori⁶  | Marzia Caproni⁴  | Adela R. Cardones⁷ | Nisha Suyien Chandran⁸ | Sören Dräger⁹ | Kossara Drenovska¹⁰  | Matthias Goebeler¹¹ | Claudia Günther¹² | Silke C. Hofmann¹³  | Dimitrios Ioannides¹⁴  | Pascal Joly¹⁵  | Branka Marinović¹⁶ | Elena Biancamaria Mariotti⁴  | Angelo Valerio Marzano^{17,18}  | Kimberly D. Morel¹⁹ | Dedee F. Murrell²⁰ | Catherine Prost¹ | Miklós Sárdy^{21,22}  | Jane Setterfield^{23,24} | Dusan Skiljevic²⁵ | Soner Uzun²⁶ | Snejina Vassileva¹⁰ | Giovanna Zambruno²⁷ | Enno Schmidt⁹ 

Correspondence

Aikaterini Patsatsi, Autoimmune Bullous Diseases Unit, 2nd Department of Dermatology, Papageorgiou Hospital, Aristotle University School of Medicine, Thessaloniki, Greece.
Email: apatsats@auth.gr and katerinapatsatsi@gmail.com

Abstract

Introduction: Linear IgA dermatosis (LAD) is a rare subepidermal autoimmune bullous disease (AIBD) defined by predominant or exclusive immune deposits of immunoglobulin A at the basement membrane zone of skin or mucous membranes. This disorder is a rare, clinically and immunologically heterogeneous disease occurring both in children and in adults. The aim of this project is to present the main clinical features of LAD, to propose a diagnostic algorithm and provide management guidelines based primarily on experts' opinion because of the lack of large methodologically sound clinical studies.

Methods: These guidelines were initiated by the European Academy of Dermatology and Venereology (EADV) Task Force Autoimmune Bullous Diseases (AIBD). To achieve a broad consensus for these S2k consensus-based guidelines, a total of 29 experts from different countries, both European and non-European, including dermatologists, paediatric dermatologists and paediatricians were invited. All members of the guidelines committee agreed to develop consensus-based (S2k) guidelines. Prior to a first virtual consensus meeting, each of the invited authors elaborated a section of the present guidelines focusing on a selected topic, based on the relevant literature. All drafts were circulated among members of the writing group, and recommendations were discussed and voted during two hybrid consensus meetings.

Results: The guidelines summarize evidence-based and expert opinion-based recommendations (S2 level) on the diagnosis and treatment of LAD.

Conclusion: These guidelines will support dermatologists to improve their knowledge on the diagnosis and management of LAD.

Frédéric Caux and Aikaterini Patsatsi shared first co-authorship.

For Affiliation refer page on 1018

This is an open access article under the terms of the [Creative Commons Attribution-NonCommercial-NoDerivs](https://creativecommons.org/licenses/by-nc-nd/4.0/) License, which permits use and distribution in any medium, provided the original work is properly cited, the use is non-commercial and no modifications or adaptations are made.

© 2024 The Authors. *Journal of the European Academy of Dermatology and Venereology* published by John Wiley & Sons Ltd on behalf of European Academy of Dermatology and Venereology.

INTRODUCTION

Linear IgA dermatosis (LAD) is a rare subepidermal autoimmune bullous disorder (AIBD) defined by predominant or exclusive immune deposits of immunoglobulin A (IgA) at the basement membrane zone (BMZ) of skin or mucous membranes. This disorder is a rare, clinically and immunologically heterogeneous disease occurring both in children and in adults. It may develop spontaneously or be drug-induced. LAD was first differentiated from bullous pemphigoid (BP) and dermatitis herpetiformis (DH) in 1976 by Jablonska et al.¹ The same group demonstrated that some children have a blistering disease with continuous IgA deposits along the BMZ which was neither BP, nor DH and introduced the term linear IgA dermatosis of childhood, also known as chronic bullous disease of childhood.² The term linear IgA dermatosis in adults was also coined in 1979. The terms LAD, linear IgA dermatosis of childhood, chronic bullous disease of childhood, linear IgA disease and linear IgA dermatosis in adults denote the same condition.

The cutaneous manifestations of LAD are variable. Peripheral vesiculation on erythematous macules or plaques, known as a 'string of pearls', is a characteristic clinical sign but is not always encountered and not pathognomonic for LAD. Several target antigens are recognized by autoantibodies, the main one being BP180 (full length, NC16A region, LABD97, LAD-1). BP230 is occasionally recognized in conjunction with BP180 and individual patients with predominant or exclusive IgA reactivity against laminin-332, p200 antigen and type VII collagen have rarely been described. In line, ultrastructural localization of immune deposits may occur at the *lamina lucida*, the *lamina densa*, or within the *lamina lucida* and the *sublamina densa* region.³

The aim of this project is to present the main clinical features of LAD in children and in adults, to propose a diagnostic algorithm and provide management guidelines based primarily on experts' opinion because of the lack of large methodologically sound clinical studies.

METHODOLOGY OF GUIDELINE PREPARATION

These guidelines were initiated by the European Academy of Dermatology and Venereology (EADV) Task Force Autoimmune Bullous Diseases (AIBD), and the writing group was formed at the Task Force meeting during the 29th EADV Annual Congress 2020.

TABLE 1 Grades (levels) of recommendation in these guidelines.

Grade (level) of recommendation	Syntax	
Very strong recommendation (it is practically obligatory)	It is necessary	↑↑↑
Strong recommendation (some exceptions are acceptable)	It is recommended	↑↑
Less strong recommendation (one has to consider it but exceptions are not rare)	May be recommended	↑
Weak recommendation (it is allowed but it is not recommended as a rule)	May be considered	↑
Rejection (not recommended)	It is not recommended or it is contraindicated	↓

To achieve a broad consensus, a total of 29 experts from different countries, both European and non-European, including dermatologists, paediatric dermatologists and paediatricians were invited. All members of the guidelines committee agreed to develop consensus-based (S2k) guidelines, according to the recommendations of the Association of the Scientific Medical Societies in Germany (AWMF; <https://www.verwaltung.awmf.org/en/clinical-practice-guidelines/awmf-guidance/cpg-development.html>). Prior to the first Consensus Virtual Meeting, each of the invited authors elaborated a section of the present guidelines focusing on a selected topic, based on the relevant literature. The first draft was discussed and corrected by all members of the guidelines committee prior to a hybrid Consensus Meeting held during the 31st EADV Annual Congress 2022.

During the second Consensus Meeting, all topics and questions were addressed before voting. Then, members of the writing group voted on all recommendations with 'agree', 'not agree' or 'abstention'. Recommendations with <70% agreement were rephrased, and voting was repeated.

To standardize the grade (level) of recommendations throughout this document, the following expressions were used (Table 1). For better visualization, levels were also labelled with colour-coded arrows. The consensus level was visualized by representative pie charts as shown in Table 2.

EPIDEMIOLOGY

LAD is a rare blistering autoimmune disease with two peaks of incidence according to age: one in adults aged between 60 and 65, and one in childhood. It is regarded as the most frequent AIBD in children.⁴ Moreover, several cases of neonatal LAD have been reported, most of them associated with severe upper airway involvement and some with additional eye lesions.⁵

The overall incidence of LAD ranges from 0.25 to 1.0/million/year.⁶⁻¹⁰ The incidence appears to be higher in developing

TABLE 2 Levels of consensus in these guidelines.

Level of consensus	Symbol
Strong consensus (agreement of >95% of participants)	
Consensus (agreement of >75-95% of participants)	
Agreement of the majority (agreement of 50-75% of participants)	

countries.^{11–17} Its prevalence has been calculated to be 10.3/million inhabitants in Germany in 2014.¹⁸ The prevalence in minors was shown to be higher (24.5/million minors).¹⁹ Due to lack of larger studies, data about gender predominance are inconclusive. While a female predominance was observed in some reports,^{4,19} other case series suggested that male patients are more frequently affected than females, at least in the paediatric and drug-induced variants.^{20–23}

GENETICS

So far, there have been only few studies focused on the genetic background of patients affected by LAD. LAD is significantly associated with the expression of the human lymphocyte antigens (HLA) Cw7, B8 and DR3 and DQ2.²⁴ DR2 is present in most of the non-DR3 patients, while DR1, DR4 and C4 are less frequently expressed.²⁴ According to the age of onset, different HLA-genotypes are found.²⁴ Specifically, in childhood LAD, a significantly increased frequency of the HLA-Cw7, -B8, -DR3 and -DQ2 haplotype was described.²⁴ In contrast, in adult LAD, HLA-Cw7 was the only significantly increased HLA-antigen.²⁴ Expression of the haplotypes -B8, -DR3 and -DQ2 might favour early disease development.²⁴ In both adult and childhood LAD, the disease is associated with a TNF2 haplotype. In patients expressing the TNF2 haplotype, the duration of LAD appeared to be longer than in those expressing a TNF1 allele.²⁴ HLA-haplotypes in LAD patients differ according to the ethnic background.¹⁴ Further epidemiological studies are needed to better substantiate these data.

PATHOPHYSIOLOGY

LAD is an immunologically heterogeneous condition. IgA autoantibodies from LAD sera bind to different proteins involved in promoting dermo-epidermal and/or epithelial-stromal cohesion. While the isotype-specific immunoregulation responsible for the characteristic IgA response in LAD remains to be elucidated, a significant subgroup of LAD patients also exhibits a concomitant IgG response to the same autoantigens.^{25,26}

Immunoelectron microscopy studies in LAD have shown that immunoreactants exhibit different ultrastructural localizations. In most cases, IgA antibodies are bound to the uppermost part of the *lamina lucida* and to the basal surface of the hemidesmosomes. Less frequently, IgA deposits are found within the *lamina densa* and *sublamina densa* regions. Finally, in a few cases, a so-called 'mirror' image pattern is observed with immunoreactants deposited on each side of the *lamina densa*.^{27,28} These variable patterns, which are also observed when sera are tested by indirect immunofluorescence microscopy (IIF) using salt-split normal human skin, reflect the presence of different antigenic targets in LAD.

Biochemically, most IgA autoantibodies from LAD sera characteristically bind to a 97-kDa protein and/or a

120-kDa protein, which are called LABD97 and LAD-1, respectively.^{29,30} These two antigens represent proteolytic products of the extracellular domain of the BP antigen 180 (BP180, also called BPAG2 or type XVII collagen). The latter is a type II transmembrane hemidesmosomal protein with a large collagenous extracellular region.^{31,32} The ectodomain of BP180 is proteolytically cleaved close to the transmembrane domain from the keratinocyte cell surface by distinct membrane-anchored metalloproteinases of the ADAM (a disintegrin and metalloproteinase) family.³³ LAD-1 lacks the N-terminal portion of the shed BP180 ectodomain, whereas LABD97 is produced by further cleavage of LAD-1 within the non-collagenous (NC) 4 domain of its C-terminal region.^{30,34} Thus, LABD97 lacks parts of the N- and C-terminal portions of the BP180 ectodomain. Plasmin is also able to cleave the ectodomain of BP180 into the LABD97 antigen in an ADAM-independent manner during inflammation.³⁵ The exact N-terminus of LABD97 may thus vary according to its proteolytic processing.^{34,36} In contrast to BP, in which IgG antibodies preferentially target full-length BP180 as well as the 120 kDa soluble extracellular domain with immunodominant antigenic determinants contained in a distinct portion of NC16A domain, IgA autoantibodies from LAD sera less frequently recognize full-length BP180 and the NC16A domain of BP180, but bind in up to 50% of cases to the soluble LAD-1 antigen.^{25,26,37,38} Hence, processing of the BP180 ectodomain is necessary for the exposure of neo-epitopes specifically recognized by IgA autoantibodies and thus critically contributes to the pathogenesis of LAD.³⁹ The role of the physiologic shedding of the BP180 ectodomain remains unclear but might have an impact on keratinocyte adhesion, differentiation or migration.^{33,40} In LAD sera, IgA reactivity with full-length BP180 or the BP180 NC16A domain is observed in 30%–40% of cases^{35,38,41} while binding to the BP antigen 230 (BP230 or BPAG1-epithelial isoform), an intracellular hemidesmosomal protein, is observed in only 10%–20% of cases.^{38,41}

In a small subset of LAD sera, IgA autoantibodies have been shown to specifically bind to type VII collagen, the constituent of anchoring fibrils. The latter reactivity most likely accounts for the *sublamina densa* type of LAD^{42,43} and is now called IgA epidermolysis bullosa acquisita (EBA). These patients are presently classified as having EBA due to their reactivity against type VII collagen and are excluded from the group of LADs.

Finally, there are few reports which have shown that LAD sera also rarely react with laminin-332 or laminin- γ 1.^{44–47} The presence of reactivities with different autoantigens as found in some LAD sera most likely reflects an intermolecular epitope spreading phenomenon.

The direct pathogenic role of IgA anti-LAD-1 and anti-LABD97 autoantibodies has not been yet unequivocally demonstrated. IgA antibodies bound to the dermo-epidermal junction (DEJ) are potentially able to activate the alternative complement pathway, triggering thereby an inflammatory response. IgA can further directly bind to specific Fc alpha receptors present on myeloid cells such as

neutrophils, eosinophils and monocytes, and activates these cells.^{48,49} In lesional skin obtained from LAD patients, the inflammatory cell infiltrate is predominantly composed of neutrophils, eosinophils and T cells with a TH2-dominated cytokine pattern. The tissue damage most likely results from proteases, including plasmin and neutrophil elastases as well as reactive oxygen species derived from neutrophils, eosinophils and mast cells.^{49,50}

In a mouse model, passive transfer of an IgA monoclonal antibody to LABD97 into severe combined immunodeficient mice with human skin transplant resulted in the binding of IgA to the human DEJ, which in turn led to inflammation and subepidermal split formation.⁵¹ This observation provides support to the idea that IgA antibodies directly contribute to tissue damage.

IgA can interact with the Fc receptor Fc α RI (CD89) on immune cells, such as neutrophils.⁵² A novel LAD model in genetically modified mice that express human Fc α RI and generate human IgA demonstrated that repeated injections of human anti-BP180 IgA resulted in neutrophil activation and extravasation from blood vessels into skin tissue, massive neutrophil accumulation, severe tissue damage and subepidermal blister formation.⁵² Administration of anti-Fc α RI monoclonal antibodies prevented the disease and was able to resolve the existing chronic inflammation and tissue damage.⁵²

DRUG ASSOCIATION

Several drugs appear to have the ability of triggering LAD,^{49,53–55} among which vancomycin is the most frequent.⁵⁵ Drug-induced LAD (DILAD) has been described in adults and, less frequently, in children. In approximately one third of patients, the onset of LAD appears to be induced by exposure to other drugs than vancomycin^{56,57} (Table 3).

Different pathogenic mechanisms have been discussed and hypothesized in the development of DILAD. A recent study focusing on vancomycin-induced LAD cases has provided evidence that LAD sera either acquire reactivity or show an increased reactivity with type VII collagen in the presence of vancomycin.⁵⁵ Vancomycin appears thus to enhance IgA reactivity with type VII collagen rather than modifying the autoantigen. These findings give new insights into mechanisms by which drugs may specifically contribute to the occurrence of DILAD and, in general, induce autoimmunity. However, as mentioned above, DILAD with reactivity against type VII

collagen is excluded from the group of LAD and should be classified as drug-induced IgA EBA.

Most cases of vancomycin-induced LAD have been consistently associated with its intravenous administration.⁵⁸ Vancomycin-impregnated devices used in arthroplasty (e.g., vancomycin-impregnated cement spacer or bone cement) have also been reported to trigger LAD.^{59,60} The development of vancomycin-induced LAD does not appear to be dose-dependent.⁶¹

CLINICAL FEATURES

Neonates and children

Childhood LAD most frequently occurs between the age of 2–6 years. It may appear after viral infections or routine childhood vaccinations.⁶² Lesions begin as vesicles on an erythematous base and rapidly fill with fluid to expand into tense bullae. Often, there is an annular pattern with an expanding edge of small bullae joining together (Figure 1), with an arrangement described as ‘a string of pearls’.^{63–66} The periorificial areas, the face, neck and groin/perianal are commonly involved sites in children. The scalp, palms and soles may be also involved.⁶²

The rare cases of neonatal LAD favour the mucous membranes, and it is a much more severe disease than all other neonatal AIBDs.⁶⁵ In neonates, the lesions develop either at birth or within the first 2–4 weeks thereafter.^{65,67–72} The oral and respiratory mucosae are often involved. Ocular involvement

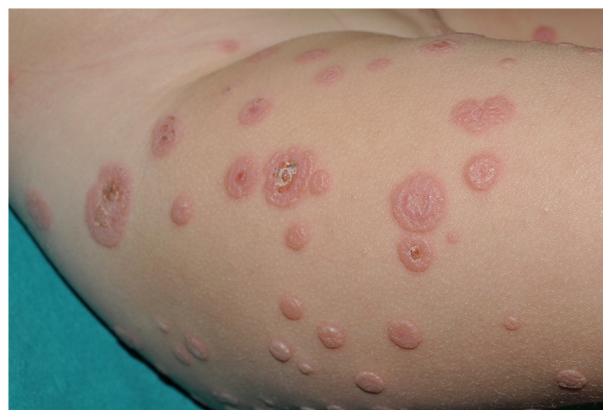

FIGURE 1 Typical annular vesicles clustered on the thighs of a young child (Image courtesy of Antonio Torello, Spain).

TABLE 3 Non-exhaustive list of drugs reported in DILAD.^{49,54,58–64}

Antibiotics: vancomycin, trimethoprim-sulfamethoxazole, penicillins, cephalosporins
Non-steroidal anti-inflammatory drugs: diclofenac, piroxicam, naproxen, acetaminophen
Antihypertensives: captopril, candesartan, verapamil, amlodipine
Antiarrhythmic: amiodarone
Diuretics: furosemide
Statins: atorvastatin
Anticonvulsants: phenytoin, vigabatrin
Vaccines: influenza, COVID-19

may present as sterile conjunctivitis. Fever may occur.⁶⁹ Males are predominantly affected by far (19:1 over females).⁶²

Adults

LAD in adults typically presents with polymorphic annular and polycyclic erythematous urticarial papules and plaques and widespread vesicles and blisters with rosette configuration ('string of pearls' sign). The eruptions often favour the trunk, extremities, palms, soles and spares the head and neck. Additional mucosal involvement occurs in a minority of patients although cutaneous lesions are always predominating.

Drug-induced LAD

Although the overall clinical presentation may not substantially differ between the idiopathic form and DILAD in a number of patients,^{73,74} there are some distinct features in LAD which may be suggestive for a drug trigger (Table 4).

The eruption in DILAD typically appear within 9 days (median time) after exposure to the incriminated drug, even if the drug has been in the meantime discontinued. Nonetheless, DILAD has also occurred anecdotally within a few hours or 1 day after drug administration, such as with vancomycin.

DIFFERENTIAL DIAGNOSIS OF LAD

LAD needs to be differentiated from other dermatoses characterized by pruritus, blisters and erosions particularly where there is deposition of linear IgA at the DEJ. The conditions described below are important differentials (Table 5).

The differentiation of LAD from bullous impetigo, certain variants of prurigo and nummular eczema, lichen

planus, as well as atypical forms of erythema multiforme, Stevens–Johnson syndrome (SJS), toxic epidermal necrolysis (TEN) may sometimes pose a challenge, particularly in case of DILAD. The latter may mimic severe drug eruptions.

DIF and IIF on salt-split skin and, when required, ELISA and immunoblot are necessary to diagnose and differentiate LAD from other AIBDs (Table 5).

DIAGNOSIS

Histology

The histological features of LAD most commonly comprise subepidermal splitting with a neutrophil-predominant infiltrate.^{20,75} In some cases, fibrin deposition and leukocytoclasia in the dermal papillary tips (a feature also present in DH) can also be found.⁷⁵ The dermal infiltrate consists predominantly of neutrophils but in up to 60% of cases may also contain some eosinophils.³

TABLE 4 Clinical features suggestive of a drug origin of LAD.








• Positive Nikolsky sign	
• Presence of large erosions	
• SJS/TEN-like clinical appearance	
• Flaccid bullae with skin sloughing	
• Palmo-plantar involvement with bullous lesions, haemorrhagic lesions mimicking vasculitis and/or targetoid, erythema multiforme-like lesions	
• Morbilliform eruption	
• Oral or conjunctival mucosal involvement	

TABLE 5 Differential diagnoses for LAD. 

Main differential diagnoses for LAD: autoimmune bullous diseases
Bullous pemphigoid (mainly IgG reactivity)
Epicutaneous bullous pemphigoid (reactivity against type VII collagen)
Mucous membrane pemphigoid (predominant mucosal involvement)
Dermatitis herpetiformis
Pemphigus group: pemphigus vulgaris, pemphigus foliaceus, pemphigus herpetiformis (IgG reactivity against desmosomal antigens)
Intercellular IgA epidermal dermatoses (IgA pemphigus)
Paraneoplastic pemphigus/ paraneoplastic autoimmune multiorgan syndrome (PNP/PAMS)
Subcorneal pustulosis (Sneddon-Wilkinson disease)
Main differential diagnoses for LAD: other dermatoses
Bullous impetigo (detection of <i>Staphylococcus aureus</i>)
Bullous tinea corporis (positive mycological findings)
Varicella/zoster infection (positive varicella/zoster PCR)
Sexual abuse in case of genital involvement (negative serology)
Nummular eczema / chronic prurigo (negative serology)
Erosive lichen planus (negative serology)
Erythema multiforme, Stevens-Johnson syndrome, toxic epidermal necrolysis (negative serology)

Direct immunofluorescence microscopy

Linear deposits of IgA along the DEJ are the characteristic finding as detected by direct immunofluorescence microscopy (DIF) of perilesional skin. Approximately 20% of patients may also have granular IgA deposition at the DEJ.⁷⁶ Furthermore, concomitant linear deposits of C3 and, less frequently, of IgG are occasionally also found.⁷⁵ The labelling intensity of IgG is weaker than that of IgA. When both IgG and IgA deposits are found with similar staining intensity, the distinction of LAD from BP and other subepidermal AIBD such as EBA becomes challenging.^{66,77–79} Although some authors have proposed to describe these cases as having linear IgA/IgG disease,⁷⁷ the latter concept remains questionable. Along this line, it may be hypothesized that LAD and BP represent a spectrum of an anti-BP180 pemphigoid disorder. This view is supported by the observation that the serum anti-DEJ autoantibody isotype is related to the patients' age, that is IgA anti-DEJ reactivity is associated with younger age and IgG anti-DEJ reactivity preferentially seen in older patients.¹¹

The serration pattern analysis by DIF allows to distinguish an n- or u-serrated linear pattern of IgA and/or IgG deposits along the DEJ.⁸⁰ An n-serrated pattern is typically observed in skin biopsy specimens obtained from patients with the most common *lamina lucida* subtype of LAD as well as in BP and most cases of mucous membrane pemphigoid (MMP). In contrast, a u-serrated pattern is typical for the rare *sublamina densa* type of LAD (now classified as IgA EBA) and some cases of MMP.

Indirect immunofluorescence microscopy

Circulating IgA autoantibodies against the DEJ are detectable in up to 70% of cases by IIF using either monkey oesophagus or, preferably, salt-split normal human skin. Use of the latter allows to increase sensitivity.^{20,38,41,81} LAD serum autoantibodies usually bind to the epidermal side of salt-split skin. Both IgA and IgG labelling can also be observed in LAD as well as in BP and MMP. If available, the BIOCHIP mosaic-based IIF assay represents a useful diagnostic tool, particularly for screening.^{80,82} However, its use has not been validated in a larger LAD cohort yet.

Western blot/immunoblotting

Immunoblotting studies using epidermal extract or concentrated conditioned supernatant of cultured keratinocytes typically reveal IgA reactivity with LAD-1, the proteolytically cleaved extracellular domain of BP180, and/or LABD97, a smaller derivative of the latter. LAD-1 and LABD97 represent the two major target antigens of LAD.^{29,30,38,83,84} Some LAD sera also recognize full-length BP180, BP180 NC16A or BP230.^{85–87} LAD sera also rarely react with laminin-332, p200 antigen and type VII collagen.^{88–90}

Immunoelectron microscopy

Direct immunoelectron microscopy demonstrates IgA immune deposits at different ultrastructural levels: (i) hemidesmosomes and upper *lamina lucida*, (ii) *lamina densa*, or (iii) *lamina lucida* and under *lamina densa* ('mirror' image).²⁸

Diagnostic criteria

It is recommended to make the diagnosis of LAD if criteria 1 and 2 are fulfilled:

1. Clinical manifestations compatible with LAD. Mucous membrane involvement must not be predominant over skin involvement. 🟢 ↑↑↑
2. Positive DIF showing solely linear deposits of IgA along the DEJ, or of both IgA and IgG. In the latter case, fluorescence intensity of the IgA deposits must be stronger than that of IgG. 🟢 ↑↑↑

Diagnosis when DIF is negative or not possible

In case DIF (criterion 2) is negative, it is necessary to repeat the biopsy for DIF. If DIF is repeatedly negative or not possible to be performed on site, it is recommended to make the diagnosis if at least one of the following criteria is fulfilled:

- Clinical manifestations compatible with LAD (non-predominant mucous membrane involvement) and positive IIF using salt-split normal human skin demonstrating IgA binding to the epidermal side or a combined epidermal-dermal staining 🟢 ↑↑↑
- Clinical manifestations compatible with LAD (non-predominant mucous membrane involvement) and in case of negative DIF and IIF on salt-split skin:
 - positive western blot detection of IgA autoantibodies against LAD-1, LABD97, BP180, BP230, laminin 332 and/or the p200 antigen 🟢 ↑↑↑
 - positive modified ELISA kit based on secondary anti-human IgA antibodies against LAD-1, LABD97, BP180, BP230, laminin 332 and/or the p200 antigen 🟢 ↑↑↑

Algorithm for the diagnosis of LAD

The recommended algorithm for the diagnosis of LAD is shown in [Figure 2](#).

When repeated DIF and IIF on salt-split skin are negative, western blotting should be performed in case of high clinical suspicion (exclusion of differential diagnosis).

If LAD patients have IgA autoantibodies against type VII collagen, it is recommended to classify them as IgA EBA 🟢 ↑↑↑.

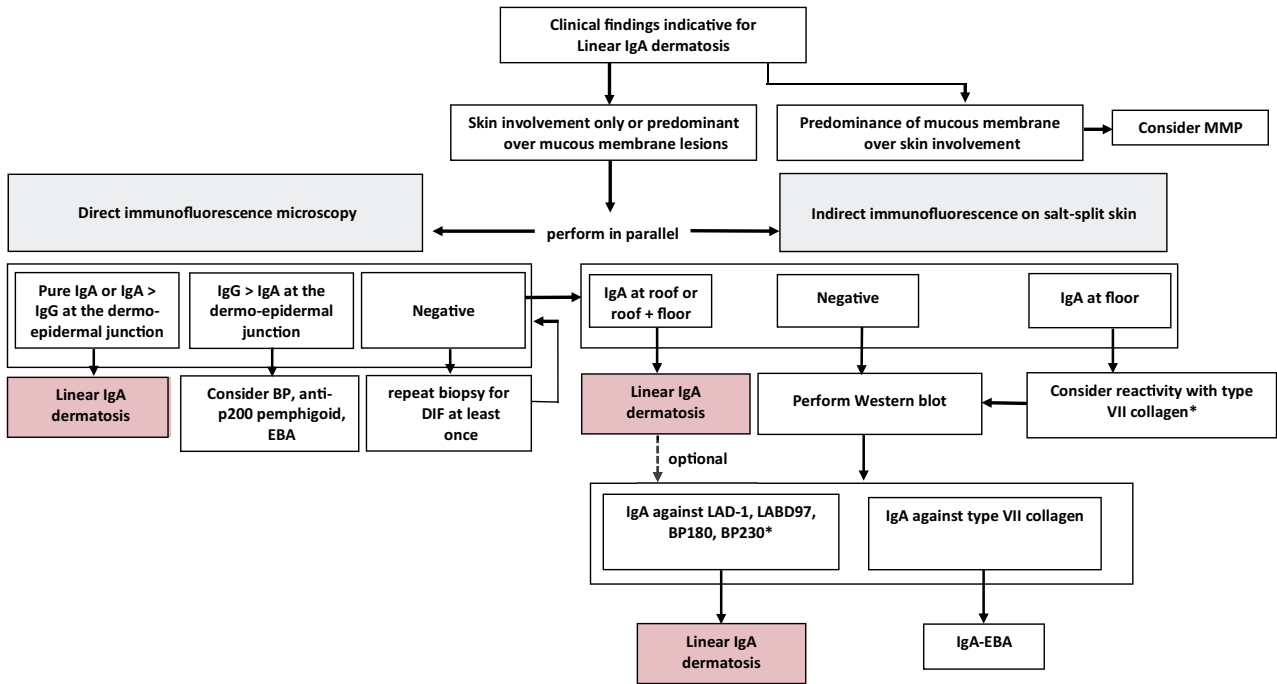


FIGURE 2 Diagnostic algorithm for linear IgA dermatosis. BP, bullous pemphigoid; DIF, direct immunofluorescence; EBA, epidermolysis bullosa acquisita; MMP, mucous membrane pemphigoid. *In isolated cases, IgA reactivity against laminin 332 and the p200 antigen has been described.

TABLE 6 Assessment for comorbidities and potentially causative trigger factors.

• A drug trigger is necessary to be considered in each case of LAD, especially in adult patients with comorbidities		↑↑↑
• Ulcerative colitis may precede or coincide with the development of LAD skin lesions. Work up is necessary		↑↑↑
• Investigation for potentially culprit drugs is recommended and if there is a suspected induction it is necessary that the drug is withdrawn		↑↑↑
• Work up for an underlying infection, e.g., <i>Helicobacter pylori</i> gastritis, may be considered		↑
• In adult patients with LAD, it is necessary to perform a standard age-appropriate malignancy screening for an underlying cancer (lymphoproliferative diseases, visceral neoplasms), especially if medical history is suggestive (e.g., unintended weight loss)		↑↑↑
• Due to possible LAD complications or associations with other autoimmune or malignant diseases, some additional consultations with rheumatologist, gastroenterologist, hematologist, ophthalmologist, etc. may be considered at diagnosis and during follow-up		↑

WORK UP BEFORE INITIATION OF THERAPY

Assessment for comorbidity and potentially causative trigger factors

LAD usually develops spontaneously, but it may be associated with certain medications (see above) or underlying diseases (Table 6):

Ulcerative colitis has been described in 7% of British LAD patients,^{81,91} and up to now more than 30 cases with concurrent occurrence of both diseases have been published.^{41,92} Usually, the diagnosis of ulcerative colitis precedes the development of skin lesions or the diagnosis is made simultaneously. Complete remission of LAD after colectomy has been described.^{38,82,93,94}

Underlying infection, for example, *Helicobacter pylori* gastritis, has been described to precede the onset of LAD.^{30,95}

Underlying malignancy is rarely associated with LAD. There are anecdotal reports of *lymphoproliferative diseases* (Non-Hodgkin lymphoma, leukaemia) as well as visceral neoplasms (e.g., bladder, thyroid, renal and oesophageal cancer) in association with LAD.^{83,84,96,97}

DILAD

Histopathology of skin biopsy of DILAD shows subepidermal splitting with typically a predominantly neutrophilic dermal infiltrate that may be intermingled by eosinophils. DIF of perilesional skin demonstrates only IgA deposits and no concomitant

IgG and/or C3 at the DEJ. IIF using monkey oesophagus or normal salt-split human skin is often negative.

If a medication is suspected to be responsible for LAD drug causality assessment has to be performed. A Naranjo probability score consisting of 10 questions could be used and causality is probable if the score is >4.²¹ Provocation tests are usually not performed; in a few cases, drug rechallenge was associated with a relapse of the eruption.²¹ A rapid drug withdrawal of the putative trigger is important. DILAD (including drug-induced IgA EBA) is thought to have a favourable course with remission in at least 75% of cases when the culprit drug is omitted. A subset of the latter had not even received any specific treatment.²¹ However, DILAD can persist for several weeks or even show relapses despite drug withdrawal.

TREATMENT

Data on the effectiveness of treatments in LAD are based on case series, retrospective single-centre studies, anecdotal case reports or expert opinion. In the majority of cases, a systemic treatment is needed (Table 7).

There is a clinical consensus that dapson is the first choice for LAD treatment, being repeatedly reported to be the most effective drug in managing this condition with excellent initial responses and long-term remissions. Although dapson is sufficient as monotherapy in most cases, it can be combined with other drugs for better results in recalcitrant cases. Those include sulfonamides (sulfapyridine, sulfasalazine and sulfamethoxyypyridazine), which are generally considered alternatives to dapson and may be used alone or in association with it and systemic or topical corticosteroids, the use of which may be required especially in situations where side effects limit the recommended daily dose of dapson.⁹⁸ Combination with immunosuppressants, such as azathioprine, mycophenolate mofetil,^{99,100} ciclosporine, cyclophosphamide and topical tacrolimus may be necessary in some cases.

There are cases which have been managed avoiding the use of dapson, for example by applying pulsed corticosteroids,¹⁰¹ colchicine,¹⁰² antibiotics, such as erythromycin, the combination of tetracycline and niacinamide (nicotinamide),¹⁰³ trimethoprim-sulfamethoxazole and oxacillin,¹⁰⁴ but also intravenous immunoglobulin and immunoadsorption.^{105,106} A few case reports described the use of rituximab.¹⁰⁷

Systemic therapy is required until patients achieve complete clinical remission, after which maintenance of the drug dosage should be adjusted according to the clinical evaluation of (muco)-cutaneous lesions. In case of recurrence, systemic therapy should be restarted and continued over weeks or months after the complete disappearance of all lesions.¹⁰⁵ To guide cessation of dapson therapy, repeating DIF microscopy may be considered and dapson discontinued in case of negative DIF.¹⁰⁸

TABLE 7 Treatment options reported in the literature for LAD.

Pharmacological treatments			
First line	Dapsone +/- topical corticosteroids		↑↑↑
	Second line	Sulfapyridine	
	Sulfasalazine		↑↑↑
	Systemic corticosteroids*		↑↑↑
	Erythromycin		↑
	Colchicine		↑↑
	Dicloxacillin		↑↑
	Flucoxacillin		↑↑
	Trimethoprim-sulfamethoxazole		↑↑
	Tetracycline and niacinamide		↑↑
Third line	Sulfamethoxyypyridazine*		↑↑↑
	Mycophenolates*		↑↑↑
	Azathioprine*		↑↑↑
	IV immunoglobulins		↑↑↑
	Ciclosporin		↑↑↑
	Methotrexate		↑↑↑
	Infliximab		↑↑
	Etanercept		↑↑
	Rituximab		↑↑↑
	Omalizumab		↑
	Cyclophosphamide**		↑

*As monotherapy or in association with dapson.

**Cyclophosphamide may be considered as a last resource, only in case of contraindication or failure of previously reported treatment approaches in adults, while it is contraindicated in children.

General recommendations

DILAD may be identified both with Naranjo score and a close temporal relationship between drug introduction and rash development or rash disappearance upon drug withdrawal.

Topical treatments in association with systemic therapy should be carefully explained to the patient. Patients should be aware of the importance of monitoring emergence of new bullae and erosions, even by counting them (Table 8). It should be explained how to manage them in the earlier steps: that is begin by gently applying a desiccant solution to the exudative areas, followed by using bath products that

TABLE 8 General recommendations and patient support groups.

<ul style="list-style-type: none"> It is necessary to inform the patient and/or parents about the chronicity of the disease and educate them to promptly recognize new lesions, emphasising that relapses may occur in different sites from the ones initially involved 	↑↑↑
<ul style="list-style-type: none"> It is recommended to inform the patient and/or parents about patient support groups. : <ul style="list-style-type: none"> IPPF (International pemphigus and pemphigoid foundation, USA) ANPPI (Italian National Association Pemphigus-Pemphigoid) APPF (Association Pemphigus-Pemphigoïde France) UNIAMO (Rare Diseases Italian Federation onlus) Australasian Blistering Diseases Foundation PEMfriends, Pemphigus and Pemphigoid patient support group (UK) Pemphigus and Pemphigoid- Selbsthilfegruppe (https://pemphigus-pemphigoid-selbsthilfe.de/), Germany 	↑↑

contain antiseptics and/or wheat starch. If dealing with widespread erosive lesions, consider using non-adhesive dressings to cover them. This helps to minimize the risk of additional blistering and infection, reduces discomfort and promotes the healing process. For addressing erosive lesions, topical corticosteroids like betamethasone dipropionate can be employed. Oral mucosa lesions may be treated, if accessible, directly applying a combination of topical high potency corticosteroids and adhesive paste. Dental procedures should be avoided during acute phases of the disease.¹⁰⁸

Patient support groups

Herein are reported some European support groups for patients affected by LAD (Table 8).



Dapsone

Dapsone (4,4-diaminodiphenyl sulfone) is an antibiotic and anti-inflammatory compound commonly used for the treatment of neutrophil-mediated dermatoses, including DH, as well as diseases characterized by neutrophil adherence to IgA.¹⁰⁹

It is the treatment of choice for LAD (Table 9). When it leads to a partial response, other drugs may be used in combination with dapsone.^{110,111}




After the appropriate confirmatory diagnosis of LAD oral dapsone could be administered at a starting dose of 50–100 mg/day, a dosage to be adapted to the therapeutic response and to be maintained until the disease is controlled.¹⁰⁸ Other authors recommend that it should be started at a lower dose (25 mg/day in adults) and then gradually increased according to the clinical condition, particularly by

TABLE 9 Dapsone is the first-line treatment for LAD.

<ul style="list-style-type: none"> Dapsone is recommended as first-line treatment for LAD in all patients with normal G6PD activity.* 		↑↑↑
<ul style="list-style-type: none"> It is necessary to determine G6PD activity before initiation of dapsone. 		↑↑↑

*Unless allergies against dapsone or sulfones are known.

TABLE 10 Optimal dose of dapsone.

<ul style="list-style-type: none"> It is recommended to use a starting dose of dapsone of 25–50 mg/day in adults, 0.5–1 mg/kg in children. If adequate preparations are not available for children, then a drug compounding is recommended. 		↑↑↑
<ul style="list-style-type: none"> It is recommended to reach a daily dose of dapsone of 0.5–2 mg/kg in adults. 		↑↑
<ul style="list-style-type: none"> Treatment discontinuation may be considered when negative DIF is obtained from a previously positive lesion site. 		↑

the emergence of new lesions, at weekly intervals to a dose of 100–200 mg/day.^{105,112}

The majority of patients with cutaneous disease respond effectively to dapsone as a first-line therapy at dosages of 50–200 mg/day. This response is usually rapid and occurs within some days.¹¹³ Adverse effects to dapsone usually manifest when a daily dose of 100 mg is reached with the need to reduce it to 50 mg/day.^{98,109} Hence, it may be safer to start with a dose of 25 mg daily and then to gradually increase it according to the individual response in order to detect early possible idiosyncratic reactions and manifestations of intolerance. This may be particularly true for elderly patients who are anaemic, have ischaemic heart disease or suffer from a reduced lung capacity. However, in young adults without comorbidity an initial dose of 50 mg may be appropriate. Then, the dosage could be adjusted according to the actual weight, considering 0.5–2 mg/kg/day as the optimum dosage. In children, doses of up to 3 mg/kg/day may be recommended to achieve an optimal clinical effect (Table 10).

Dapsone exhibits good bioavailability, but serum levels can have a wide variation; therefore, measuring serum dapsone levels as a guide to therapy has little value. There is wide variability in the half-life of dapsone (10–50 h), but it is reported that the vast majority of patients are best managed on a single daily dose.¹¹²

The side effects of dapsone may be categorized as pharmacologic (dose-dependent) and allergic (idiosyncratic). Among dose-related side effects, the most common is haemolysis which typically results in a reduction of haemoglobin levels by 15–20 g/L. Therefore, it is advisable to maintain a baseline haemoglobin level within the normal range. Since dapsone is a strong oxidizer, it may produce severe haemolysis which is caused by the metabolite hydroxylamine in patients with glucose-6-phosphate-dehydrogenase (G6PD) deficiency. Therefore, patients should be screened for G6PD deficiency

before starting dapsone therapy. Assessment of G6PD deficiency is possible by detection of enzymatic activity (by spectrophotometric testing, fluorescence testing or formazan-based spot testing) or by molecular analysis for mutations of the gene encoding G6PD.¹¹⁴ Methaemoglobinaemia occurs in less than 15%; at high dose, it may become symptomatic with the development of cyanosis, weakness, headaches, dyspnoea and tachycardia. It is inevitable during dapsone treatment and may be considered a marker for regular drug intake. In adults, methaemoglobin levels of up to 7% can be tolerated unless clinical symptoms appear. To reduce haemolysis and methaemoglobinaemia and treat associated headaches, ascorbic acid (at least 500 mg a day) or vitamin E (400 mg 3 times a day) may be recommended additionally.

Other less frequent side effects include a sensory and motor neuropathy, toxic hepatitis and cholestatic jaundice, and hypoalbuminaemia or eosinophilic pneumonia.^{112,115} Idiosyncratic side effects may present as psychiatric symptoms, infectious mononucleosis-like syndrome, exfoliative dermatitis, erythema multiforme, erythema nodosum and urticaria. Dapsone hypersensitivity syndrome is a rare idiosyncratic adverse reaction that manifests with the clinical triad of fever, rash and internal organ involvement, the last of which may be fatal. In a similar fashion, unpredictable agranulocytosis can occur.¹¹⁶

Patients on dapsone therapy should have a baseline complete blood count (CBC), liver function tests and a G6PD level. Hypo- or agranulocytosis may emerge within the first 3 months of treatment, possibly due to low activity of the N-acetyltransferase-2 enzyme.¹¹⁷ Hence, blood cell count should be checked weekly for the first month, every 2 weeks for the next 2 months, and at least every 3 months thereafter.

TABLE 11 The following clinical and laboratory examinations before and during dapsone therapy are recommended.

Frequency	Recommended examinations
Baseline	History and clinical review CBC Liver function panel Renal function panel Blood G6PD level (if not available, reduced starting dapsone dose is recommended)
First month: weekly	History and clinical review CBC including reticulocyte count
Second and third month: every two weeks	MetHb if daily dose > 150 mg
First three months: every two weeks	CBC including reticulocyte count Liver function panel Renal function panel
Every third month	History and clinical review including peripheral motor neurological examination CBC including reticulocyte count Liver function panel Renal function panel

Abbreviations: CBC, complete blood counts; MetHb, methaemoglobin level.

A chemistry profile should be repeated every 6 months to monitor for possible hepatotoxicity, changes in renal function and hypoalbuminaemia (Table 11).¹¹² Dose-related side effects are more frequent in patients with G6PD deficiency, comorbidity reducing tissue oxygenation and in the elderly. Thus, in patients with comorbidity or abnormal laboratory values, more frequent follow-ups, dose reduction of dapsone or interruption of therapy may be recommended.¹¹⁸

Regarding its teratogenic risk dapsone is classified as B2 according to the *Australian Drug Evaluation Committee*, thus being a drug for which no sufficient data concerning assumption during pregnancy with respect to, for example, malformations, direct and indirect toxic effects on the foetus, and serious problems during labour have not been clearly reported yet. Therefore, although it is known that it can cross the placenta and it is secreted into breast milk, dapsone is generally regarded to be safe for both mother and foetus. Nevertheless, there is a theoretic risk of methaemoglobinaemia and mild haemolytic anaemia, leading to hypoxia.¹¹⁹ Case reports of LAD analysing the use of dapsone during pregnancy document that there is a general clinical improvement, even after reducing or discontinuing it.

Main contraindications for dapsone include G6PD deficiency, allergy to sulfonamides, anaemia, neutropenia, significant cardiopulmonary disease, significant liver or renal function impairment, frequent and/or severe headaches, and peripheral motor or sensory neuropathy (Table 11).

Sulfonamides

Sulfonamides, including sulfapyridine, sulfasalazine and sulfamethoxyypyridazine, are alternatives to dapsone and may be used alone or in combination with it. They are regarded to be less effective than dapsone and are less available; their use is rare in Europe.^{105,118} The range of dose administration is wide, as it is reported to be of 15–60 mg/kg/day (3–6 g/day).¹⁰⁸ Doses in children are 100–200 mg/kg daily in three to six divided doses.^{22,120} The three drugs have similar profiles concerning adverse effects (anaplastic anaemia, agranulocytosis, thrombocytopenia, haemolysis, leukopenia, hepatotoxicity, hypersensitivity pneumonitis, lupus-like syndrome, pancreatitis, nephrolithiasis, urticaria, erythema multiforme, SJS, allergic vasculitis, fever).

Corticosteroids

In mild forms of adult LAD, topical corticosteroids can be used alone without the need for systemic treatments. In more severe disease states, they can be combined with systemic treatment to limit therapy doses. Potent topical corticosteroids such as clobetasol propionate are generally preferred.^{49,105,113}

Systemic corticosteroids may be a primary option when dapsone or sulfonamides cannot be used because of their significant potential side effects (for example, in G6PD deficiency, dapsone hypersensitivity, severe anaemia or organ failure).¹⁰¹

For patients who are refractory to dapsone therapy or those who are achieving only partial response, prednisolone may be tried in combination with dapsone at doses of 0.5 mg/kg daily (mild to moderate doses) to achieve optimal control.^{22,110,113} Systemic corticosteroids may be an option for combination therapy in patients with mucous membrane involvement, typically refractory to dapsone monotherapy.¹¹³ Moreover, systemic corticosteroid therapy, alone or sometimes in combination with immunosuppressants, may be necessary in severe disease in which there is no adequate response to dapsone.^{105,108}

In LAD developing during pregnancy, systemic prednisolone may be the initial treatment before adding dapsone.¹²¹

Other treatments

Patients with LAD most often respond dramatically to dapsone or sulfapyridine alone. In patients who are intolerant to these medications or experiencing recalcitrant LAD, second-line therapeutic agents may be considered.

Colchicine has been reported to be an efficacious and well-tolerated treatment for numerous dermatologic diseases including LAD.¹²² However, the data on treatment of LAD with colchicine are mostly limited to case reports or small case series. Some authors have achieved satisfactory results with 0.5 mg of colchicine twice daily in childhood LAD cases,^{123–125} but experience in adult patients is scarce. There are some adult LAD case reports that colchicine treatment, administered at doses of 0.5 mg 1–3 times a day, effectively and safely suppresses symptoms for months without relapses, starting within 5–10 days.^{102,126,127} Colchicine is generally well tolerated. Side effects are dose-dependent and include nausea, vomiting, abdominal pain and diarrhoea. Leukopenia and agranulocytosis are rare.

The combination of *tetracycline and niacinamide* (syn. nicotinamide) has been reported to be useful in the treatment of BP and other AIBD.^{128–130} Tetracycline 500 mg t.i.d. and niacinamide 600 mg t.i.d. provided complete or almost complete remission within 2–3 weeks in some patients with LAD.^{103,131,132} A combination of tetracycline and niacinamide seems to have a safety profile broader than that of dapsone or prednisone therapy.^{129,130} Niacinamide alone has been used with success in very young patients in whom there is a relative contraindication for using tetracyclines.¹³³ Therefore, it may be considered as an alternative in cases of LAD that have contraindications for dapsone and prednisone, for children and for mild disease.

Trimethoprim-sulfamethoxazole and *topical tacrolimus* were reported to be helpful when used in conjunction with other immunosuppressants as second-line adjuvants.

Mycophenoles: They include mycophenolate mofetil and mycophenolic acid, administered orally at dosages of 2 and 1.44 g/day, respectively.^{134,135} There are few case reports describing the use of mycophenoles in LAD treatment.^{99,100,136} Some authors suggest raising daily dose by 1 capsule per week for better gastrointestinal tolerance. Adverse effects

to be considered are the following: anaemia, leukopenia, blurred vision, abdominal pain, gastrointestinal haemorrhage, nausea, diarrhoea, dyspnoea, haematuria, hypertension, tachyarrhythmia, acne, hepatotoxicity and arthralgia.

Intravenous immunoglobulins (IVIg): In a case series, monthly cycles of IVIg were administered along with colchicine and prednisone 15 mg/day. There was a good response and prednisone could be tapered until discontinuation after 5 cycles of treatment. The recommended dose is 2 g/kg given over 3–5 days in monthly intervals.¹³⁷ Potentially severe side effects in older patients, especially the risk of acute renal failure, must be considered. Anaphylactic reactions can occur in individuals deficient in IgA, but this is extremely rare in LAD. Other potential adverse effects are headache, back pain, chills, flushing, fever, myalgia, nausea, thrombophlebitis, aseptic meningitis, hypertension and congestive heart failure.¹⁰⁶

Azathioprine: It is started for the first week at 50 mg/day to detect idiosyncratic reactions [and in this case stop immediately, regardless of thiopurine methyltransferase (TPMT) results] and then increased to the desired dose considering 1–2.5 mg/kg/day and according to TPMT activity.^{49,138} Before initiating azathioprine, TPMT functional tests or genotyping are recommended since polymorphisms may lead to reduced enzymatic activity and increased toxicity (leukopenia). Low TPMT activity warrants dose adjustments (30%–80% of the normal dose). If such tests are not available, then a starting dose of maximum 50 mg/day is recommended which can be gradually increased after a few weeks if there are no dangerous changes in the CBC. Patients with a homozygous *NUDT15* (415C>T) mutation carry a higher risk of azathioprine-induced myelosuppression.^{93,94,139,140} Dose reduction to 20%–40% of the normal dose is necessary in patients treated with azathioprine and allopurinol, but it is recommended not to prescribe these two drugs together.

Cyclosporin: Its maintenance dosage is 2–5 mg/kg/day. Potential adverse effects include nephrotoxicity, high blood pressure and neurotoxicity.⁴⁹ It is contraindicated above the age of 60.

Cyclophosphamide: It is only for the treatment of refractory cases in adults. It could be used in adults at a dose of 500 mg as IV bolus or given orally at 2 mg/kg/day.¹³⁸ Potential adverse effects include leukopenia, nausea, headache, hair loss, haemorrhagic colitis, haemorrhagic cystitis, bladder fibrosis, interstitial pulmonary fibrosis, amenorrhoea and malignancy, particularly bladder cancer.⁴⁹

Methotrexate: According to the experience of the authors, methotrexate may be effective in a dose between 15 and 20 mg/week. It is a relatively safe option in the elderly with normal renal function. In a case of LAD associated with ulcerative colitis long-term 22.5 mg/week methotrexate administration was reported as an effective treatment to control both LAD and gastrointestinal issues.¹⁴¹

Biologics

Biologics may be considered an alternative in difficult-to-treat cases of LAD, non-responding to conventional therapies

and in the case of contraindications to standard therapies, either as add-on therapy or as monotherapy. They might be used when LAD is associated with concomitant and possibly trigger diseases for which biologics are validated therapies.¹⁴² In the literature, there are no reports of rituximab, etanercept or infliximab to treat children with LAD.

Infliximab: Although infliximab has been reported to induce LAD, probably as a paradoxical reaction, there is one report on infliximab having a marked effect on LAD in a patient with ulcerative colitis.¹⁴² This might be due to infliximab directly antagonizing the increased levels of TNF- α present in LAD, as reported by Caproni et al.⁵⁰

Etanercept: A case of an extensive DILAD mimicking TEN was reported to having improved and rapidly resolved after withdrawal of the offending drug and etanercept treatment.¹⁴³

Rituximab: Three patients with refractory LAD were effectively treated by rituximab, whereas one patient was unresponsive to this biologic.^{144,145}

Omalizumab: Omalizumab was effective in one case report of refractory LAD with relapse after cessation of this biologic and resolution upon reintroduction of omalizumab.¹⁴⁶

Treatment of DILAD

Discontinuation of the offending medication may produce remission of DILAD. Typically, cessation of new lesion formation is observed 1–3 days after drug withdrawal and old lesions resolve within 2–7 weeks. In serious and persistent cases, additional therapy with dapsone, systemic corticosteroids (prednisone or prednisolone) 0.5 mg/kg to 1 mg/kg/day and/or topical glucocorticoids, colchicine or IVIG may be required to stop progression of the disease.¹⁴⁷

Treatment strategies

First-line treatment of LAD is dapsone. In case of absence of control despite an adequate dose of dapsone or if it is contraindicated, a second-line drug is given and a third-line drug may be necessary in refractory LAD. Upon disease control, the dosage of dapsone is decreased until the minimum dose to avoid relapse is reached.

PROGNOSIS

Children

Childhood LAD is rare in Caucasian populations but more common in Asians and Africans, most likely because of the linkage with distinct HLA genes conferring susceptibility. Since African and many Asian populations have a high percentage of minors, the relative frequency of LAD is higher in these countries compared to Western communities. The disease is usually sudden in onset and worse during the first ‘attack’. Thereafter, it may become chronic and relapse.

Prognosis of LAD in children is generally favourable. It typically persists for months to several years prior to resolution (3–5 years). LAD resolves in most children prior to puberty. Related data are mostly based on small case series or single case reports. For example, the mean initial treatment time to achieve remission for a cohort of children with LAD in Denmark was 3.2 years (range 2–6 years),²² while a series from Tunisia demonstrated a duration of 15 months (range 3 months–4 years) in 60% of patients (16/25).¹⁴⁸ In the same cohort, 30% of patients (8/25) had persistent disease after 18 months of treatment (range 12–24 months).¹⁴⁸ A series of 16 paediatric LAD patients from Kuwait showed all to be in remission and off treatment on follow-up, though this ranged widely from 2.5 to 156 months.²³ Complete remission off therapy was also seen in the majority (60%) of a small cohort of five paediatric LAD patients from Singapore at follow-up (range 2–51 months).¹⁴⁹ In the largest case series of 38 Italian LAD patients (27 adults, 11 children), possible differences in prognosis between adults and children were compared.²⁰ Relapses were rarely observed in either adults or children (4 adults, 1 child), with no statistically significant differences between adults and children.²⁰ None of the patients with relapsed disease were taking medication for their LAD at the moment of relapse.²⁰

Neonatal LAD has been associated with severe mucosal involvement and respiratory failure.^{67,72,150} Neonatal LAD was first reported by Hruza et al. in 1993.⁶⁷ Recently, a case of neonatal LAD has been shown to be due to passive transfer of pathogenic IgA from the asymptomatic mother via breast milk.¹⁵¹ Breastfeeding interruption led to disease remission in the newborn and may be considered in neonates with suspected LAD.¹⁵¹

Even though LAD is generally regarded to resolve spontaneously within months to years, usually by puberty, persistence beyond puberty has been described. Some cases that have been in remission for many years may relapse after respiratory or other infections.¹⁵² Permanent sequelae, including blindness and dysphagia, have been rarely described.⁶³

Adults

LAD in adults has the reputation of being a rare but benign disease. Data on the long-term outcomes and prognosis of idiopathic LAD in adults are contradictory compared to its favourable evolution in childhood. Difficulty in the proper evaluation of its natural course in adults is explained with its rarity, controversial definition and lack of long-term follow-up.

Analysis of isolated clinical cases and small case series reported favourable outcome for most patients with clinical remission occurring after a mean of 5.6 years (range between 10 months –11 years).¹⁵³ Similarly, a retrospective Scandinavian LAD series found that the duration of the disease was long, and most adult cases could be effectively controlled with a mean duration of treatment of 4.1 years (range 1 month – 22 years, median 2 years).²² No statistically

significant difference was described in the treatment response between childhood and adult types of the disease, as well as between the IgA versus IgA/G types, or epidermal versus dermal types in larger cohorts of LAD patients from Japan and Italy.^{20,154}

Other reports detected less frequent remissions in adult LAD, persistent course and a mean duration of disease of 7 years (range 2–40 years).⁴ Difficulty in determining the duration of treatment was related to the fact that most cases relapsed during tapering of the medication and required a new dose increase.⁹⁸

In an attempt to identify clinical and immunological factors predictive of complete remission, the analysis of 72 idiopathic LAD cases found that one third of the patients achieved sustained complete remission while two-thirds had chronic or relapsing disease. Major risk factors for persistent disease were age <70 years and presence of mucous membrane involvement (Table 12). On the contrary, age >70 years and absence of mucosal lesions were significantly associated with occurrence of complete remission.⁴¹ No prognostic immunological factors were identified by immunofluorescence, immunoblotting or immunoelectron microscopy. Younger age and mucosal involvement may be suggestive for both treating physicians and patients of a significantly higher risk of a chronic evolution and prolonged treatment.¹⁵⁵ Thus, the patient's phenotype is relevant for choosing the therapeutic strategy. Other reports do not detect correlation between clinical severity and disease chronicity.¹⁰⁵

DILAD in adults is usually reported to have favourable outcome with spontaneous regression of the lesions within days or weeks after withdrawal of therapy and reappearance of the eruption on reintroduction of the culprit drug.^{153,156} A worse prognosis can be expected in older patients or in those with severe comorbidity, but not as a direct result of the DILAD.¹⁵⁷ Severe course and poor prognosis were also observed in 20% of the drug-induced cases, especially those related to vancomycin and clinically mimicking toxic epidermal necrolysis.²¹

Like with many autoimmune diseases, vaccination against SARS-CoV-2 during the COVID-19 pandemic has led to reports on vaccine-induced LAD.^{158,159}

TABLE 12 Prognostic factors predictive for LAD chronicity in adults.






• Age < 70 years		↑
• Presence of mucous membrane involvement		↑

TABLE 13 Future perspective and gaps in knowledge.

• Demonstration of effectiveness of antibiotics in juvenile LAD	
• Sequence of the drugs in case of inefficacy or incomplete efficacy of dapsone	
• Choice of a specific treatment depending on the clinical/ immunological type of LAD	

In conclusion, LAD in adults has a longer and more persistent course as compared to the childhood type and prognosis depends on the patients' phenotype.

FUTURE PERSPECTIVE AND GAPS IN KNOWLEDGE

Several gaps of knowledge exist and need further investigations (Table 13).

AFFILIATIONS

- Department of Dermatology and Referral Center for Autoimmune Bullous Diseases, Groupe Hospitalier Paris Seine-Saint-Denis, AP-HP and University Paris 13, Bobigny, France
- Autoimmune Bullous Diseases Unit, 2nd Department of Dermatology, Aristotle University School of Medicine, Papageorgiou General Hospital, Thessaloniki, Greece
- Department of Dermatology and Venereology, Medical Center, University Hospital Freiburg, Freiburg, Germany
- Department of Health Sciences, Section of Dermatology, Azienda USL Toscana Centro, Rare Diseases Unit, European Reference Network-Skin Member, University of Florence, Florence, Italy
- Department of Dermatology, Hospital Sant Joan de Deu, Barcelona, Spain
- Department of Dermatology, University of Bern, Inselspital, Berne, Switzerland
- Division of Dermatology, Department of Internal Medicine, University of Kansas Medical Center, Kansas City, Kansas, USA
- Division of Dermatology, Department of Medicine, National University Hospital, Singapore, Singapore
- Department of Dermatology, Lübeck Institute of Experimental Dermatology (LIED), University of Lübeck, Lübeck, Germany
- Department of Dermatology and Venereology, University Hospital "Alexandrovska", Medical University-Sofia, Sofia, Bulgaria
- Department of Dermatology, Venereology and Allergology, University Hospital Würzburg, Würzburg, Germany
- Department of Dermatology, University Hospital, Technical University Dresden, Dresden, Germany
- Department of Dermatology, Allergy and Dermatocurgery, Helios University Hospital Wuppertal, University Witten-Herdecke, Wuppertal, Germany
- 1st Department of Dermatology, Aristotle University School of Medicine, Hospital of Skin and Venereal Diseases, Thessaloniki, Greece
- Department of Dermatology, Rouen University Hospital, INSERM 1234, Normandie University, Rouen, France
- Department of Dermatology and Venereology, University Hospital Centre Zagreb, School of Medicine, University of Zagreb, Zagreb, Croatia
- Dermatology Unit, Fondazione IRCCS Ca' Granda Ospedale Maggiore Policlinico, Milan, Italy
- Department of Pathophysiology and Transplantation, Università degli Studi di Milano, Milan, Italy
- Departments of Dermatology and Pediatrics at Columbia University Medical Center, Vagelos College of Physicians and Surgeons, New York, New York, USA
- Department of Dermatology, St George Hospital, University of New South Wales, Sydney, New South Wales, Australia
- Department of Dermatology, Venereology and Dermatooncology, Semmelweis University, Budapest, Hungary
- Department of Dermatology and Allergy, University Hospital, LMU, Munich, Germany
- St John's Institute of Dermatology, Guy's and St Thomas' NHS Foundation Trust, London, UK
- Centre for Host-Microbiome Interactions, King's College London Faculty of Dentistry, Oral & Craniofacial Sciences, London, UK
- Department of Dermatovenereology, Faculty of Medicine, University of Belgrade, Belgrade, Serbia
- Department of Dermatology, Akdeniz University Faculty of Medicine, Antalya, Turkey
- Genodermatosis Unit, Translational Pediatrics and Clinical Genetics Research Division, Bambino Gesù Children's Hospital, IRCCS, Rome, Italy

ACKNOWLEDGEMENTS

Many thanks to Prof. Angelo Valerio Marzano for hosting the hybrid Consensus meeting in his department of Dermatology in Milan in September 2022.

FUNDING INFORMATION

The EADV did not yield financial support for the consensus meetings.

CONFLICT OF INTEREST STATEMENT

Conflict of interest related to these guidelines is given in Table S1.

DATA AVAILABILITY STATEMENT

Data sharing is not applicable to this article as no new data were created or analyzed in this study.

ETHICS STATEMENT

The patients in this manuscript have given written informed consent to publication of their images.

ORCID

Frédéric Caux  <https://orcid.org/0000-0001-9552-0882>


Aikaterini Patsatsi  <https://orcid.org/0000-0001-9616-2001>

Emiliano Antiga  <https://orcid.org/0000-0001-7787-4433>

Luca Borradori  <https://orcid.org/0000-0003-0424-6297>

Marzia Caproni  <https://orcid.org/0000-0002-7471-3471>

Kossara Drenovska  <https://orcid.org/0000-0002-8254-1630>

Silke C. Hofmann  <https://orcid.org/0000-0002-4221-386X>

Dimitrios Ioannides  <https://orcid.org/0000-0002-8997-9889>

Pascal Joly  <https://orcid.org/0000-0002-5734-0255>

Elena Biancamaria Mariotti  <https://orcid.org/0000-0003-0388-1037>

Angelo Valerio Marzano  <https://orcid.org/0000-0002-8160-4169>

Miklós Sárdy  <https://orcid.org/0000-0003-4306-5093>

Enno Schmidt  <https://orcid.org/0000-0002-1206-8913>

REFERENCES

- Jablonska S, Chorzelski TP, Beutner EH, Maciejowska E, Rzeska G. Dermatitis herpetiformis and bullous pemphigoid. Intermediate and mixed forms. *Arch Dermatol*. 1976;112(1):45–8.
- Chorzelski TP, Jablonska S. IgA linear dermatosis of childhood (chronic bullous disease of childhood). *Br J Dermatol*. 1979;101(5):535–42.
- Venning VA. Linear IgA disease: clinical presentation, diagnosis, and pathogenesis. *Immunol Allergy Clin North Am*. 2012;32(2):245–53, vi.
- Wojnarowska F, Marsden RA, Bhogal B, Black MM. Chronic bullous disease of childhood, childhood cicatricial pemphigoid, and linear IgA disease of adults. A comparative study demonstrating clinical and immunopathologic overlap. *J Am Acad Dermatol*. 1988;19(5 Pt 1):792–805.
- Giraud L, Welfringer-Morin A, Boccarda O, Frassati-Biaggi A, Leclerc-Mercier S, Grootenboer-Mignot S, et al. Neonatal and self-healing linear immunoglobulin A dermatosis. *J Eur Acad Dermatol Venereol*. 2020;34(2):e86–e87.
- Zillikens D, Wever S, Roth A, Weidenthaler-Barth B, Hashimoto T, Brocker EB. Incidence of autoimmune subepidermal blistering dermatoses in a region of central Germany. *Arch Dermatol*. 1995;131(8):957–8.
- van Beek N, Weidinger A, Schneider SW, Kleinheinz A, Glaser R, Holsche MM, et al. Incidence of pemphigoid diseases in Northern Germany in 2016 – first data from the Schleswig-Holstein Registry of Autoimmune Bullous Diseases. *J Eur Acad Dermatol Venereol*. 2021;35(5):1197–202.
- Bertram F, Brocker EB, Zillikens D, Schmidt E. Prospective analysis of the incidence of autoimmune bullous disorders in Lower Franconia, Germany. *J Dtsch Dermatol Ges*. 2009;7(5):434–40.
- Nanda A, Dvorak R, Al-Saeed K, Al-Sabah H, Alsaleh QA. Spectrum of autoimmune bullous diseases in Kuwait. *Int J Dermatol*. 2004;43(12):876–81.
- Wong SN, Chua SH. Spectrum of subepidermal immunobullous disorders seen at the National Skin Centre, Singapore: a 2-year review. *Br J Dermatol*. 2002;147(3):476–80.
- Mulyowa GK, Jaeger G, Kabakyenga J, Brocker EB, Zillikens D, Schmidt E. Autoimmune subepidermal blistering diseases in Uganda: correlation of autoantibody class with age of patients. *Int J Dermatol*. 2006;45(9):1047–52.
- Adam BA. Bullous diseases in Malaysia: epidemiology and natural history. *Int J Dermatol*. 1992;31(1):42–5.
- Mahe A, Flageul B, Bobin P. [Bullous IgA linear dermatosis of children in Mali]. *Ann Dermatol Venereol*. 1996;123(9):544–8.
- Aboobaker J, Wojnarowska FT, Bhogal B, Black MM. Chronic bullous dermatosis of childhood – clinical and immunological features seen in African patients. *Clin Exp Dermatol*. 1991;16(3):160–4.
- Denguezli M, Ben Nejma B, Nouira R, Korbi S, Bardi R, Ayed K, et al. [IgA linear bullous dermatosis in children. A series of 12 Tunisian patients]. *Ann Dermatol Venereol*. 1994;121(12):888–92.
- Piamphongsant T, Sirimachan S, Himmunknan P. Juvenile blistering diseases: the problems of diagnosis and treatment. *Asian Pac J Allergy Immunol*. 1986;4(2):133–7.
- Ajithkumar K, Kurian S, Jacob M, Pulimood S. Linear IgA bullous dermatosis in south India. *Int J Dermatol*. 1997;36(3):191–3.
- Hubner F, Recke A, Zillikens D, Linder R, Schmidt E. Prevalence and age distribution of pemphigus and pemphigoid diseases in Germany. *J Invest Dermatol*. 2016;136(12):2495–8.
- Hubner F, Konig IR, Holsche MM, Zillikens D, Linder R, Schmidt E. Prevalence and age distribution of pemphigus and pemphigoid diseases among paediatric patients in Germany. *J Eur Acad Dermatol Venereol*. 2020;34(11):2600–5.
- Genovese G, Venegoni L, Fanoni D, Muratori S, Berti E, Marzano AV. Linear IgA bullous dermatosis in adults and children: a clinical and immunopathological study of 38 patients. *Orphanet J Rare Dis*. 2019;14(1):115.
- Garel B, Ingen-Housz-Oro S, Afriat D, Prost-Squarcioni C, Tetart F, Bensaid B, et al. Drug-induced linear immunoglobulin A bullous dermatosis: a French retrospective pharmacovigilance study of 69 cases. *Br J Clin Pharmacol*. 2019;85(3):570–9.
- Lings K, Bygum A. Linear IgA bullous dermatosis: a retrospective study of 23 patients in Denmark. *Acta Derm Venereol*. 2015;95(4):466–71.
- Nanda A, Lazarevic V, Rajy JM, Almasry IM, AlSabah H, Allafi A. Spectrum of autoimmune bullous diseases among children in Kuwait. *Pediatr Dermatol*. 2021;38(1):50–7.
- Collier PM, Wojnarowska F, Welsh K, McGuire W, Black MM. Adult linear IgA disease and chronic bullous disease of childhood: the association with human lymphocyte antigens Cw7, B8, DR3 and tumour necrosis factor influences disease expression. *Br J Dermatol*. 1999;141(5):867–75.
- Kromminga A, Scheckenbach C, Georgi M, Hagel C, Arndt R, Christophers E, et al. Patients with bullous pemphigoid and linear IgA disease show a dual IgA and IgG autoimmune response to BP180. *J Autoimmun*. 2000;15(3):293–300.
- Schumann H, Baetge J, Tasanen K, Wojnarowska F, Schacke H, Zillikens D, et al. The shed ectodomain of collagen XVII/BP180 is targeted by autoantibodies in different blistering skin diseases. *Am J Pathol*. 2000;156(2):685–95.
- Zhou S, Ferguson DJ, Allen J, Wojnarowska F. The localization of target antigens and autoantibodies in linear IgA disease is variable:

- correlation of immunogold electron microscopy and immunoblotting. *Br J Dermatol.* 1998;139(4):591–7.
28. Prost C, De Leca AC, Combemale P, Labeille B, Martin N, Cosnes A, et al. Diagnosis of adult linear IgA dermatosis by immunoelectron microscopy in 16 patients with linear IgA deposits. *J Invest Dermatol.* 1989;92(1):39–45.
 29. Zone JJ, Taylor TB, Kadunce DP, Meyer LJ. Identification of the cutaneous basement membrane zone antigen and isolation of antibody in linear immunoglobulin A bullous dermatosis. *J Clin Invest.* 1990;85(3):812–20.
 30. Marinkovich MP, Taylor TB, Keene DR, Burgeson RE, Zone JJ. LAD-1, the linear IgA bullous dermatosis autoantigen, is a novel 120-kDa anchoring filament protein synthesized by epidermal cells. *J Invest Dermatol.* 1996;106(4):734–8.
 31. Giudice GJ, Emery DJ, Diaz LA. Cloning and primary structural analysis of the bullous pemphigoid autoantigen BP180. *J Invest Dermatol.* 1992;99(3):243–50.
 32. Hopkinson SB, Riddelle KS, Jones JC. Cytoplasmic domain of the 180-kDa bullous pemphigoid antigen, a hemidesmosomal component: molecular and cell biologic characterization. *J Invest Dermatol.* 1992;99(3):264–70.
 33. Franzke CW, Tasanen K, Schacke H, Zhou Z, Tryggvason K, Mauch C, et al. Transmembrane collagen XVII, an epithelial adhesion protein, is shed from the cell surface by ADAMs. *EMBO J.* 2002;21(19):5026–35.
 34. Hirako Y, Usukura J, Uematsu J, Hashimoto T, Kitajima Y, Owaribe K. Cleavage of BP180, a 180-kDa bullous pemphigoid antigen, yields a 120-kDa collagenous extracellular polypeptide. *J Biol Chem.* 1998;273(16):9711–7.
 35. Hofmann SC, Voith U, Schonau V, Sorokin L, Bruckner-Tuderman L, Franzke CW. Plasmin plays a role in the in vitro generation of the linear IgA dermatosis antigen LADB97. *J Invest Dermatol.* 2009;129(7):1730–9.
 36. Hirako Y, Nishizawa Y, Sitaru C, Opitz A, Marcus K, Meyer HE, et al. The 97-kDa (LADB97) and 120-kDa (LAD-1) fragments of bullous pemphigoid antigen 180/type XVII collagen have different N-termini. *J Invest Dermatol.* 2003;121(6):1554–6.
 37. Roh JY, Yee C, Lazarova Z, Hall RP, Yancey KB. The 120-kDa soluble ectodomain of type XVII collagen is recognized by autoantibodies in patients with pemphigoid and linear IgA dermatosis. *Br J Dermatol.* 2000;143(1):104–11.
 38. Cozzani E, Di Zenzo G, Gasparini G, Saleme A, Agnoletti AF, Vassallo C, et al. Autoantibody profile of a cohort of 54 Italian patients with linear IgA bullous dermatosis: LAD-1 denoted as a major auto-antigen of the lamina lucida subtype. *Acta Derm Venereol.* 2020;100(4):adv00070.
 39. Hashimoto T, Ishii N, Tsuruta D. Production of Neoepitopes by dynamic structural changes on BP180/type XVII collagen. *J Invest Dermatol.* 2017;137(12):2462–4.
 40. Tasanen K, Tunggal L, Chometon G, Bruckner-Tuderman L, Aumailley M. Keratinocytes from patients lacking collagen XVII display a migratory phenotype. *Am J Pathol.* 2004;164(6):2027–38.
 41. Gottlieb J, Ingen-Housz-Oro S, Alexandre M, Grootenboer-Mignot S, Aucouturier F, Sbidian E, et al. Idiopathic linear IgA bullous dermatosis: prognostic factors based on a case series of 72 adults. *Br J Dermatol.* 2017;177(1):212–22.
 42. Tsuchisaka A, Ohara K, Ishii N, Nguyen NT, Marinkovich MP, Hashimoto T. Type VII collagen is the major autoantigen for sublamina densa-type linear IgA bullous dermatosis. *J Invest Dermatol.* 2015;135(2):626–9.
 43. Utsunomiya N, Chino T, Oyama N, Utsunomiya A, Yamaguchi Y, Takashima W, et al. Sublamina densa-type linear IgA bullous dermatosis with IgA autoantibodies specific for type VII collagen: a case report and clinicopathological review of 32 cases. *Dermatol Online J.* 2017;23(11):13030/qt7gj3j797.
 44. Sakaguchi M, Bito T, Oda Y, Kikusawa A, Nishigori C, Munetsugu T, et al. Three cases of linear IgA/IgG bullous dermatosis showing IgA and IgG reactivity with multiple antigens, particularly laminin-332. *JAMA Dermatol.* 2013;149(11):1308–13.
 45. El-Domyati M, Abdel-Wahab H, Ahmad H. Immunohistochemical localization of basement membrane laminin 5 and collagen IV in adult linear IgA disease. *Int J Dermatol.* 2015;54(8):922–8.
 46. Li X, Tsuchisaka A, Qian H, Teye K, Ishii N, Sogame R, et al. Linear IgA/IgG bullous dermatosis reacts with multiple laminins and integrins. *Eur J Dermatol.* 2015;25(5):418–23.
 47. Matsudate Y, Yamasaki K, Ujiie H, Iwata H, Kubo Y. Linear immunoglobulin A/immunoglobulin G bullous dermatosis with autoantibodies to LAD-1 and laminin-gamma1. *Clin Exp Dermatol.* 2019;44(3):e44–e46.
 48. Morton HC, van Egmond M, van de Winkel JG. Structure and function of human IgA Fc receptors (Fc alpha R). *Crit Rev Immunol.* 1996;16(4):423–40.
 49. Fortuna G, Marinkovich MP. Linear immunoglobulin A bullous dermatosis. *Clin Dermatol.* 2012;30(1):38–50.
 50. Caproni M, Rolfo S, Bernacchi E, Bianchi B, Brazzini B, Fabbri P. The role of lymphocytes, granulocytes, mast cells and their related cytokines in lesional skin of linear IgA bullous dermatosis. *Br J Dermatol.* 1999;140(6):1072–8.
 51. Zone JJ, Egan CA, Taylor TB, Meyer LJ. IgA autoimmune disorders: development of a passive transfer mouse model. *J Invest Dermatol Symp Proc.* 2004;9(1):47–51.
 52. Bos A, Aleyd E, van der Steen LPE, Winter PJ, Heemskerk N, Pouw SM, et al. Anti-FcalphaRI monoclonal antibodies resolve IgA autoantibody-mediated disease. *Front Immunol.* 2022;13:732977.
 53. Ho YH, Chiu YW, Liu HN. Piperacillin-Tazobactam-induced linear IgA bullous dermatosis supported by a T-cell activation assay. *Ann Dermatol.* 2018;30(5):588–91.
 54. Adler NR, McLean CA, Aung AK, Goh MS. Piperacillin-tazobactam-induced linear IgA bullous dermatosis presenting clinically as Stevens-Johnson syndrome/toxic epidermal necrolysis overlap. *Clin Exp Dermatol.* 2017;42(3):299–302.
 55. Yamagami J, Nakamura Y, Nagao K, Funakoshi T, Takahashi H, Tanikawa A, et al. Vancomycin mediates IgA autoreactivity in drug-induced linear IgA bullous dermatosis. *J Invest Dermatol.* 2018;138(7):1473–80.
 56. Phyu H, Kobayashi T, Rastogi P, Cho C. Vancomycin-induced linear immunoglobulin A bullous dermatosis. *BMJ Case Rep.* 2019;12:e233281.
 57. Corra A, Bonciolini V, Quintarelli L, Verdelli A, Caproni M. Linear IGA bullous dermatosis potentially triggered by vaccination. *Int J Immunopathol Pharmacol.* 2022;36:20587384211021218.
 58. Eisendle K, Bonatti H, Sepp N, Hopfl R. Vancomycin-induced linear IgA bullous dermatosis in an immunosuppressed transplant recipient. *J Eur Acad Dermatol Venereol.* 2007;21(7):996–7.
 59. Gurung P, Yaakub A, Patel P, Ramaiya A, Tan E. Response to "Linear IgA bullous dermatosis protracted by vancomycin-loaded bone cement". *JAAD Case Rep.* 2019;5(10):904–5.
 60. Nartker N, Kudlak N, Crowe D. Linear IgA bullous dermatosis protracted by vancomycin-loaded bone cement. *JAAD Case Rep.* 2019;5(3):234–6.
 61. Neugebauer BI, Negron G, Pelton S, Plunkett RW, Beutner EH, Magnusson R. Bullous skin disease: an unusual allergic reaction to vancomycin. *Am J Med Sci.* 2002;323(5):273–8.
 62. Wilson A, Murrell DF. Clinical features of chronic bullous dermatosis of childhood. *Clin Exp Dermatol.* 2022;47(5):873–81.
 63. Mintz EM, Morel KD. Clinical features, diagnosis, and pathogenesis of chronic bullous disease of childhood. *Dermatol Clin.* 2011;29(3):459–62, ix.
 64. Tate C, Christian W, Newell L. Chronic bullous dermatosis of childhood and the string of pearls sign. *J Pediatr.* 2018;202:325–325.e1.
 65. Zhao CY, Chiang YZ, Murrell DF. Neonatal autoimmune blistering disease: a systematic review. *Pediatr Dermatol.* 2016;33(4):367–74.
 66. Becker M, Schumacher N, Schmidt E, Zillikens D, Sadik CD. Evaluation and comparison of clinical and laboratory characteristics of patients with IgA epidermolysis bullosa acquisita, linear IgA

- bullous dermatosis, and IgG epidermolysis bullosa acquisita. *JAMA Dermatol.* 2021;157(8):917–23.
67. Hruza LL, Mallory SB, Fitzgibbons J, Mallory GB Jr. Linear IgA bullous dermatosis in a neonate. *Pediatr Dermatol.* 1993;10(2):171–6.
 68. Lee SY, Leung CY, Leung CW, Chow CB, Leung KM, Lee QU. Linear IgA bullous dermatosis in a neonate. *Arch Dis Child Fetal Neonatal Ed.* 2004;89(3):F280.
 69. Gluth MB, Witman PM, Thompson DM. Upper aerodigestive tract complications in a neonate with linear IgA bullous dermatosis. *Int J Pediatr Otorhinolaryngol.* 2004;68(7):965–70.
 70. Akin MA, Gunes T, Akyn L, Ohyama B, Kontas O, Hashimoto T. A newborn with bullous pemphigoid associated with linear IgA bullous dermatosis. *Acta Dermatovenerol Alp Pannonica Adriat.* 2009;18(2):66–70.
 71. Julapalli MR, Brandon KL, Rosales CM, Grover RK, Plunkett RW, Metry DW. Neonatal linear immunoglobulin A bullous dermatosis: a rare presentation. *Pediatr Dermatol.* 2012;29(5):610–3.
 72. Kishida Y, Kameyama J, Nei M, Hashimoto T, Baba K. Linear IgA bullous dermatosis of neonatal onset: case report and review of the literature. *Acta Paediatr.* 2004;93(6):850–2.
 73. Collier PM, Wojnarowska F. Drug-induced linear immunoglobulin A disease. *Clin Dermatol.* 1993;11(4):529–33.
 74. Navi D, Michael DJ, Fazel N. Drug-induced linear IgA bullous dermatosis. *Dermatol Online J.* 2006;12(5):12.
 75. Blenkinsopp WK, Haffenden GP, Fry L, Leonard JN. Histology of linear IgA disease, dermatitis herpetiformis, and bullous pemphigoid. *Am J Dermatopathol.* 1983;5(6):547–54.
 76. Egan CA, Taylor TB, Meyer LJ, Petersen MJ, Zone JJ. The immunoglobulin A antibody response in clinical subsets of mucous membrane pemphigoid. *Dermatology.* 1999;198(4):330–5.
 77. Inamura E, Nishie W, Yamaguchi Y, Fujimura Y, Ujiie H, Natsuga K, et al. Linear IgA/IgG bullous dermatosis with autoantibodies directing the native and processed forms of BP180. *Br J Dermatol.* 2020;182(4):1061–2.
 78. Letko E, Bhol K, Anzaar F, Perez VL, Ahmed AR, Foster CS. Chronic cicatrizing conjunctivitis in a patient with epidermolysis bullosa acquisita. *Arch Ophthalmol.* 2006;124(11):1615–8.
 79. Shimanovich I, Skrobek C, Rose C, Nie Z, Hashimoto T, Brocker EB, et al. Pemphigoid gestationis with predominant involvement of oral mucous membranes and IgA autoantibodies targeting the C-terminus of BP180. *J Am Acad Dermatol.* 2002;47(5):780–4.
 80. Vodegel RM, Jonkman MF, Pas HH, de Jong MC. U-serrated immunodeposition pattern differentiates type VII collagen targeting bullous diseases from other subepidermal bullous autoimmune diseases. *Br J Dermatol.* 2004;151(1):112–8.
 81. Ohata C, Ishii N, Koga H, Nakama T. A clinical and serological study of linear IgA bullous dermatosis without linear immunoglobulin deposition other than IgA at the basement membrane zone using direct immunofluorescence. *Br J Dermatol.* 2017;177(1):152–7.
 82. van Beek N, Rentsch K, Probst C, Komorowski L, Kasperkiewicz M, Fechner K, et al. Serological diagnosis of autoimmune bullous skin diseases: prospective comparison of the BIOCHIP mosaic-based indirect immunofluorescence technique with the conventional multi-step single test strategy. *Orphanet J Rare Dis.* 2012;7:49.
 83. Zone JJ, Taylor TB, Kadunce DP, Chorzelski TP, Schachner LA, Huff JC, et al. IgA antibodies in chronic bullous disease of childhood react with 97 kDa basement membrane zone protein. *J Invest Dermatol.* 1996;106(6):1277–80.
 84. Zone JJ, Taylor TB, Meyer LJ, Petersen MJ. The 97 kDa linear IgA bullous disease antigen is identical to a portion of the extracellular domain of the 180 kDa bullous pemphigoid antigen, BPAg2. *J Invest Dermatol.* 1998;110(3):207–10.
 85. Kromminga A, Sitaru C, Hagel C, Herzog S, Zillikens D. Development of an ELISA for the detection of autoantibodies to BP230. *Clin Immunol.* 2004;111(1):146–52.
 86. Zillikens D, Mascaro JM, Rose PA, Liu Z, Ewing SM, Caux F, et al. A highly sensitive enzyme-linked immunosorbent assay for the detection of circulating anti-BP180 autoantibodies in patients with bullous pemphigoid. *J Invest Dermatol.* 1997;109(5):679–83.
 87. Csorba K, Schmidt S, Florea F, Ishii N, Hashimoto T, Hertl M, et al. Development of an ELISA for sensitive and specific detection of IgA autoantibodies against BP180 in pemphigoid diseases. *Orphanet J Rare Dis.* 2011;6:31.
 88. Egan CA, Yee C, Zillikens D, Yancey KB. Anti-p200 pemphigoid: diagnosis and treatment of a case presenting as an inflammatory subepidermal blistering disease. *J Am Acad Dermatol.* 2002;46(5):786–9.
 89. Dainichi T, Kurono S, Ohyama B, Ishii N, Sanzen N, Hayashi M, et al. Anti-laminin gamma-1 pemphigoid. *Proc Natl Acad Sci US A.* 2009;106(8):2800–5.
 90. Saschenbrecker S, Karl I, Komorowski L, Probst C, Dahnrich C, Fechner K, et al. Serological diagnosis of autoimmune bullous skin diseases. *Front Immunol.* 2019;10:1974.
 91. Paige DG, Leonard JN, Wojnarowska F, Fry L. Linear IgA disease and ulcerative colitis. *Br J Dermatol.* 1997;136(5):779–82.
 92. Sonoyama H, Mishima Y, Ishihara S, Oshima N, Moriyama I, Kawashima K, et al. Ten-year follow-up study of linear immunoglobulin A dermatosis complicated with ulcerative colitis. *Clin J Gastroenterol.* 2020;13(2):164–9.
 93. Vargas TJ, Fialho M, Santos LT, Rodrigues PA, Vargas AL, Sousa MA. Linear IgA dermatosis associated with ulcerative colitis: complete and sustained remission after total colectomy. *An Bras Dermatol.* 2013;88(4):600–3.
 94. Caldarella G, Annese V, Bossa F, Pellicano R. Linear IgA bullous dermatosis and ulcerative colitis treated by proctocolectomy. *Eur J Dermatol.* 2009;19(6):651.
 95. Guarneri C, Ceccarelli M, Rinaldi L, Cacopardo B, Nunnari G, Guarneri F. *Helicobacter pylori* and skin disorders: a comprehensive review of the available literature. *Eur Rev Med Pharmacol Sci.* 2020;24(23):12267–87.
 96. Kartan S, Shi VY, Clark AK, Chan LS. Paraneoplastic pemphigus and autoimmune blistering diseases associated with neoplasm: characteristics, diagnosis, associated neoplasms, proposed pathogenesis. *Treatment Am J Clin Dermatol.* 2017;18(1):105–26.
 97. Colmant C, Camboni A, Dekeuleener V, Marot L, Dachelet C, Baeck M. Linear IgA dermatosis in association with angioimmunoblastic T-cell lymphoma infiltrating the skin: a case report with literature review. *J Cutan Pathol.* 2020;47(3):251–6.
 98. Machado TYS, Enokihara M, Iida TM, Porro AM. Adult linear IgA bullous dermatosis: report of three cases. *An Bras Dermatol.* 2018;93(3):435–7.
 99. Passos L, Rabelo RF, Matsuo C, Santos M, Talhari S, Talhari C. Linear IgA/IgG bullous dermatosis: successful treatment with dapsone and mycophenolate mofetil. *An Bras Dermatol.* 2011;86(4):747–50.
 100. Marzano AV, Ramoni S, Spinelli D, Alessi E, Berti E. Refractory linear IgA bullous dermatosis successfully treated with mycophenolate sodium. *J Dermatolog Treat.* 2008;19(6):364–7.
 101. Verma R, Vasudevan B, Sagar A, Pragasam V, Deb P, Choden G. A case of linear immunoglobulin A disease with dapsone hypersensitivity and its management strategies. *Indian J Dermatol Venereol Leprol.* 2013;79(6):833–5.
 102. Hernandez-Machin B, Penate Y, Baez B, Borrego L. Linear IgA bullous dermatosis of adults treated with colchicine. *Actas Dermosifiliogr.* 2006;97(8):549–50.
 103. Shan XF, Zhang FR, Tian HQ, Wang N, Zhou SJ, Wang GJ. A case of linear IgA dermatosis successfully treated with tetracycline and niacinamide. *Int J Dermatol.* 2016;55(4):e216–e217.
 104. Peterson JD, Chan LS. Linear IgA bullous dermatosis responsive to trimethoprim-sulfamethoxazole. *Clin Exp Dermatol.* 2007;32(6):756–8.
 105. Vale E, Dimatos OC, Porro AM, Santi CG. Consensus on the treatment of autoimmune bullous dermatoses: dermatitis herpetiformis and linear IgA bullous dermatosis – Brazilian Society of Dermatology. *An Bras Dermatol.* 2019;94(2 Suppl 1):48–55.

106. Segura S, Iranzo P, Martinez-de Pablo I, Mascaro JM Jr, Alsina M, Herrero J, et al. High-dose intravenous immunoglobulins for the treatment of autoimmune mucocutaneous blistering diseases: evaluation of its use in 19 cases. *J Am Acad Dermatol.* 2007;56(6):960–7.
107. Kaya Islamoglu ZG, Akyurek FT. A case of recalcitrant linear IgA bullous dermatosis: successfully treated with rituximab. *Dermatol Ther.* 2019;32(3):e12911.
108. Ingen-Housz-Oro S, Bernard P, Bedane C, Prost C, Joly P, Centres de reference des maladies bulleuses auto-immunes, et al. [Linear IgA dermatosis. Guidelines for the diagnosis and treatment. Centres de reference des maladies bulleuses auto-immunes. Societe Francaise de Dermatologie]. *Ann Dermatol Venerol.* 2011;138(3):267–70.
109. Urosevic-Maiwald M, Kerl K, Harr T, Bogdan AI. Dapsone-induced erythema multiforme with neutropenia in a patient with linear IgA dermatosis: case report and review of the literature. *Int J Dermatol.* 2013;52(11):1369–71.
110. Kasperkiewicz M, Zillikens D, Schmidt E. Pemphigoid diseases: pathogenesis, diagnosis, and treatment. *Autoimmunity.* 2012;45(1):55–70.
111. Montagnon CM, Tolkachjov SN, Murrell DF, Camilleri MJ, Lehman JS. Subepithelial autoimmune blistering dermatoses: clinical features and diagnosis. *J Am Acad Dermatol.* 2021;85(1):1–14.
112. Egan CA, Zone JJ. Linear IgA bullous dermatosis. *Int J Dermatol.* 1999;38(11):818–27.
113. Ng SY, Venning VV. Management of linear IgA disease. *Dermatol Clin.* 2011;29(4):629–30.
114. Piette EW, Werth VP. Dapsone in the management of autoimmune bullous diseases. *Immunol Allergy Clin North Am.* 2012;32(2):317–22. vii.
115. Meinzer F, Lehmann P, Hofmann SC. Eosinophile Pneumonie als Komplikation einer mit Dapsone therapierten linearen IgA-Dermatose. *J Dtsch Dermatol Ges.* 2016;14(12):1307–9.
116. Antiga E, Maglie R, Quintarelli L, Verdelli A, Bonciani D, Bonciolini V, et al. Dermatitis herpetiformis: novel perspectives. *Front Immunol.* 2019;10:1290.
117. Potocnjak I, Likic R, Simic I, Juricic Nahal D, Cegec I, Ganoci L, et al. Dapsone-induced agranulocytosis-possible involvement of low-activity N-acetyltransferase 2. *Fundam Clin Pharmacol.* 2017;31(5):580–6.
118. Gorog A, Antiga E, Caproni M, Cianchini G, De D, Dmochowski M, et al. S2k guidelines (consensus statement) for diagnosis and therapy of dermatitis herpetiformis initiated by the European Academy of Dermatology and Venereology (EADV). *J Eur Acad Dermatol Venerol.* 2021;35(6):1251–77.
119. Collier PM, Kelly SE, Wojnarowska F. Linear IgA disease and pregnancy. *J Am Acad Dermatol.* 1994;30(3):407–11.
120. Tomecki KJ. Chronic bullous dermatosis of childhood. *South Med J.* 1983;76(5):651–3.
121. Ikkaku N, Tateishi C, Oda Y, Tsuruta D, Horikawa T. Linear immunoglobulin A bullous dermatosis developing during late pregnancy. *J Dermatol.* 2017;44(3):e44–e45.
122. Dasgeb B, Kornreich D, McGuinn K, Okon L, Brownell I, Sackett DL. Colchicine: an ancient drug with novel applications. *Br J Dermatol.* 2018;178(2):350–6.
123. Jablonska S. The therapies for linear IgA bullous dermatosis of childhood. *Pediatr Dermatol.* 1999;16(5):415.
124. Ang P, Tay YK. Treatment of linear IgA bullous dermatosis of childhood with colchicine. *Pediatr Dermatol.* 1999;16(1):50–2.
125. Zeharia A, Hodak E, Mukamel M, Danziger Y, Mimouni M. Successful treatment of chronic bullous dermatosis of childhood with colchicine. *J Am Acad Dermatol.* 1994;30(4):660–1.
126. Benbenisty KM, Bowman PH, Davis LS. Localized linear IgA disease responding to colchicine. *Int J Dermatol.* 2002;41(1):56–8.
127. Aram H. Linear IgA bullous dermatosis. Successful treatment with colchicine. *Arch Dermatol.* 1984;120(7):960–1.
128. Chaidemenos GC. Tetracycline and niacinamide in the treatment of blistering skin diseases. *Clin Dermatol.* 2001;19(6):781–5.
129. Chalmers JR, Wojnarowska F, Kirtschig G, Mason J, Childs M, Whitham D, et al. A randomised controlled trial to compare the safety, effectiveness and cost-effectiveness of doxycycline (200 mg/day) with that of oral prednisolone (0.5 mg/kg/day) for initial treatment of bullous pemphigoid: the Bullous Pemphigoid Steroids and Tetracyclines (BLISTER) trial. *Health Technol Assess.* 2017;21(10):1–90.
130. Jin XX, Wang X, Shan Y, Li SZ, Xu Q, Jin HZ, et al. Efficacy and safety of tetracyclines for pemphigoid: a systematic review and meta-analysis. *Arch Dermatol Res.* 2022;314(2):191–201.
131. Chaffins ML, Collison D, Fivenson DP. Treatment of pemphigus and linear IgA dermatosis with nicotinamide and tetracycline: a review of 13 cases. *J Am Acad Dermatol.* 1993;28(6):998–1000.
132. Peoples D, Fivenson DP. Linear IgA bullous dermatosis: successful treatment with tetracycline and nicotinamide. *J Am Acad Dermatol.* 1992;26(3 Pt 2):498–9.
133. Cui YX, Yang BQ, Zhou GZ, Zhang FR. Childhood linear IgA bullous dermatosis successfully treated with oral nicotinamide. *Clin Exp Dermatol.* 2016;41(7):816–8.
134. Beissert S, Werfel T, Frieling U, Bohm M, Sticherling M, Stadler R, et al. A comparison of oral methylprednisolone plus azathioprine or mycophenolate mofetil for the treatment of bullous pemphigoid. *Arch Dermatol.* 2007;143(12):1536–42.
135. Bystryń JC. Comparative effectiveness of azathioprine or mycophenolate mofetil as an adjuvant for the treatment of bullous pemphigoid. *Arch Dermatol.* 2008;144(7):946.
136. Glaser R, Sticherling M. Successful treatment of linear IgA bullous dermatosis with mycophenolate mofetil. *Acta Derm Venerol.* 2002;82(4):308–9.
137. Enk A, Fierlbeck G, French L, Hertl M, Messer G, Meurer M, et al. Use of high-dose immunoglobulins in dermatology. *J Dtsch Dermatol Ges.* 2009;7(9):806–12.
138. Zone JJ. Clinical spectrum, pathogenesis and treatment of linear IgA bullous dermatosis. *J Dermatol.* 2001;28(11):651–3.
139. Schaeffeler E, Jaeger SU, Klumpp V, Yang JJ, Igel S, Hinze L, et al. Impact of NUDT15 genetics on severe thiopurine-related hematotoxicity in patients with European ancestry. *Genet Med.* 2019;21(9):2145–50.
140. Chen ZY, Zhu YH, Zhou LY, Shi WQ, Qin Z, Wu B, et al. Association between genetic polymorphisms of metabolic enzymes and azathioprine-induced myelosuppression in 1,419 Chinese patients: a retrospective study. *Front Pharmacol.* 2021;12:672769.
141. Yetto T, Burns C. Linear IgA bullous dermatosis associated with ulcerative proctitis: treatment challenge. *Dermatol Online J.* 2018;24(7):13030/qt46421332.
142. Yamada S, Makino T, Jinnin M, Sakai K, Fukushima S, Inoue Y, et al. Association of linear IgA bullous disease with ulcerative colitis: a case of successful treatment with infliximab. *Dermatology.* 2013;227(4):295–8.
143. Prieto-Barrios M, Velasco-Tamariz V, Tous-Romero F, Burillo-Martinez S, Zarco-Olivo C, Rodriguez-Peralto JL, et al. Linear immunoglobulin A dermatosis mimicking toxic epidermal necrolysis: a case report of etanercept treatment. *Br J Dermatol.* 2018;178(3):786–9.
144. Pinard C, Hebert V, Lecuyer M, Sacre L, Joly P. Linear IgA bullous dermatosis treated with rituximab. *JAAD Case Rep.* 2019;5(2):124–6.
145. Lamberts A, Euverman HI, Terra JB, Jonkman MF, Horvath B. Effectiveness and safety of rituximab in recalcitrant pemphigoid diseases. *Front Immunol.* 2018;9:248.
146. Maalouf NS, Hanna D. Linear IgA bullous dermatosis successfully treated with omalizumab: a case report. *JAAD Case Rep.* 2019;5(11):966–9.
147. Lammer J, Hein R, Roenneberg S, Biedermann T, Volz T. Drug-induced linear IgA bullous dermatosis: a case report and review of the literature. *Acta Derm Venerol.* 2019;99(6):508–15.
148. Kenani N, Mebazaa A, Denguezli M, Ghariani N, Sriha B, Belajouza C, et al. Childhood linear IgA bullous dermatosis in Tunisia. *Pediatr Dermatol.* 2009;26(1):28–33.

149. Kong YL, Lim YL, Chandran NS. Retrospective study on autoimmune blistering disease in paediatric patients. *Pediatr Dermatol*. 2015;32(6):845–52.
150. Salud CM, Nicolas ME. Chronic bullous disease of childhood and pneumonia in a neonate with VATERL association and hypoplastic paranasal sinuses. *J Am Acad Dermatol*. 2010;62(5):895–6.
151. Egami S, Suzuki C, Kurihara Y, Yamagami J, Kubo A, Funakoshi T, et al. Neonatal linear IgA bullous dermatosis mediated by breast milk-borne maternal IgA. *JAMA Dermatol*. 2021;157(9):1107–11.
152. Diaz MS, Morita L, Ferrari B, Sartori S, Greco MF, Sobrevias Bonells L, et al. Linear IgA bullous dermatosis: a series of 17 cases. *Actas Dermosifiliogr (Engl Ed)*. 2019;110(8):673–80.
153. Chorzelski TP, Jablonska S, Maciejowska E. Linear IgA bullous dermatosis of adults. *Clin Dermatol*. 1991;9(3):383–92.
154. Horiguchi Y, Ikoma A, Sakai R, Masatsugu A, Ohta M, Hashimoto T. Linear IgA dermatosis: report of an infantile case and analysis of 213 cases in Japan. *J Dermatol*. 2008;35(11):737–43.
155. Ishii N. Prognostic factors of patients with linear IgA bullous dermatosis. *Br J Dermatol*. 2017;177(1):16–7.
156. Ingen-Housz-Oro S. [Linear IgA bullous dermatosis: a review]. *Ann Dermatol Venereol*. 2011;138(3):214–20.
157. Kakar R, Paugh H, Jaworsky C. Linear IgA bullous disease presenting as toxic epidermal necrolysis: a case report and review of the literature. *Dermatology*. 2013;227(3):209–13.
158. Alberta-Wszolek L, Mousette AM, Mahalingam M, Levin NA. Linear IgA bullous dermatosis following influenza vaccination. *Dermatol Online J*. 2009;15(11):3.
159. Han J, Russo G, Stratman S, Psomadakis CE, Rigo R, Owji S, et al. Toxic epidermal necrolysis-like linear IgA bullous dermatosis after third Moderna COVID-19 vaccine in the setting of oral terbinafine. *JAAD Case Rep*. 2022;24:101–4.

SUPPORTING INFORMATION

Additional supporting information can be found online in the Supporting Information section at the end of this article.

How to cite this article: Caux F, Patsatsi A, Karakioulaki M, Antiga E, Baselga E, Borradori L, et al. S2k guidelines on diagnosis and treatment of linear IgA dermatosis initiated by the European Academy of Dermatology and Venereology. *J Eur Acad Dermatol Venereol*. 2024;38:1006–1023. <https://doi.org/10.1111/jdv.19880>