

Ekvivalent: Karcinom prostate s komponentom nalik na Panethove stanice - prikaz slučaja

Šojat, Josip

Professional thesis / Završni specijalistički

2024

Degree Grantor / Ustanova koja je dodijelila akademski / stručni stupanj: **University of Zagreb, School of Medicine / Sveučilište u Zagrebu, Medicinski fakultet**

Permanent link / Trajna poveznica: <https://um.nsk.hr/um:nbn:hr:105:086473>

Rights / Prava: [In copyright](#) / [Zaštićeno autorskim pravom.](#)

Download date / Datum preuzimanja: **2025-01-19**



Repository / Repozitorij:

[Dr Med - University of Zagreb School of Medicine Digital Repository](#)



Sveučilište u Zagrebu Medicinski fakultet

Josip Šojat, dr.med.

Karcinom prostate s komponentom nalik na Panethove stanice-
prikaz slučaja

Završni specijalistički rad

Zagreb, travanj, 2023.

KLINIČKI BOLNIČKI CENTAR SESTRE
MILOSRDNICE

KLINIČKI ZAVOD ZA PATOLOGIJU I
CITOLOGIJU "LJUDEVIT JURAK"

Prof.dr.sc. Božo Krušlin

REDNI BROJ RADA: _____

PANETH CELL-LIKE COMPONENT IN PROSTATE CANCER - CASE REPORT

Josip Šojat¹, Bernardica Jurić², Šoip Šoipi³, Monika Ulamec^{2,4} and Božo Krušlin^{2,4}

¹Department of Pathology and Cytology, Dr. Ivo Pedišić Sisak General Hospital, Sisak, Croatia;

²Ljudevit Jurak Department of Pathology and Cytology, Sestre milosrdnice University Hospital Center, Zagreb, Croatia; ³Department of Urology, Sestre milosrdnice University Hospital Center, Zagreb, Croatia;

⁴Department of Pathology, School of Medicine, University of Zagreb, Zagreb, Croatia

SUMMARY – Prostate adenocarcinoma with Paneth cell-like neuroendocrine differentiation is a rare entity. Foci of scattered cells and small clusters are found in the majority of described cases, although cases with predominant Paneth cell-like features have also been recorded. These cells contain eosinophilic cytoplasmic inclusions and lack androgen receptors, and are consequently immune to hormone therapy. It is, therefore, important for pathologists to recognize them. According to literature, clinical outcome depends on the standard grading of the conventional prostate cancer component. We report a case of a 54 year-old patient with prostatic adenocarcinoma showing Paneth cell-like neuroendocrine differentiation.

Key words: *Prostate; Adenocarcinoma; Paneth cells*

Introduction

Adenocarcinoma of the prostate is the second most common cancer in men, with the majority of cases detected after the age of 60. The most common adenocarcinoma of the prostate is acinar, but there are rare types of adenocarcinoma such as those with neuroendocrine (NE) differentiation. The significance of these tumor subtypes lies in their potential resistance to current therapies. The carcinoma with Paneth cell-like cells (PCLC) is one of the tumors in the group of tumors with NE differentiation. These cells are distinguished by prominent eosinophilic cytoplasmic. PCLC may be present in well-formed glands of Gleason pattern 3, but can also be found in cords of cells with bland cytology that would typically be defined as Gleason pattern 5¹. It can be detected by standard microscopic analysis and immunohistochemistry staining

with neuroendocrine markers such as synaptophysin and chromogranin A. Here we report a case of high Gleason score prostate cancer with strong Paneth cell-like differentiation.

Case report

Fifty four year old man appeared to have a high serum prostatic-specific antigen (PSA) level (71.45ng/ml) and F/T PSA ratio (13.4) in his regular physical examination. Fine needle core biopsy of the prostate was performed. Histological examination revealed adenocarcinoma, Gleason score 8 (5+3), group 4, according to WHO 2016 classification. The patient underwent radical prostatectomy at Sestre milosrdnice University Hospital Center. The histopathologic analysis of paraffin-embedded specimens revealed diffuse spread of the tumor in both lobes. Tumor was composed of solid, glomeruloid, cribriform and glandular structures aligned partly by tumor cells with prominent red nucleoli and partly by round to pyramidal cells with markedly eosinophilic granular cytoplasm. The later component was consistent with pathological

Correspondence to: *Božo Krušlin, MD, PhD, Professor of pathology, Ljudevit Jurak Department of Cytology and Pathology, University Hospital Center Sestre milosrdnice, Vinogradska 29, Zagreb, Croatia*

e-mail: bozo.kruslin@kbcsm.hr

Received March 23, 2018, accepted May 30, 2018

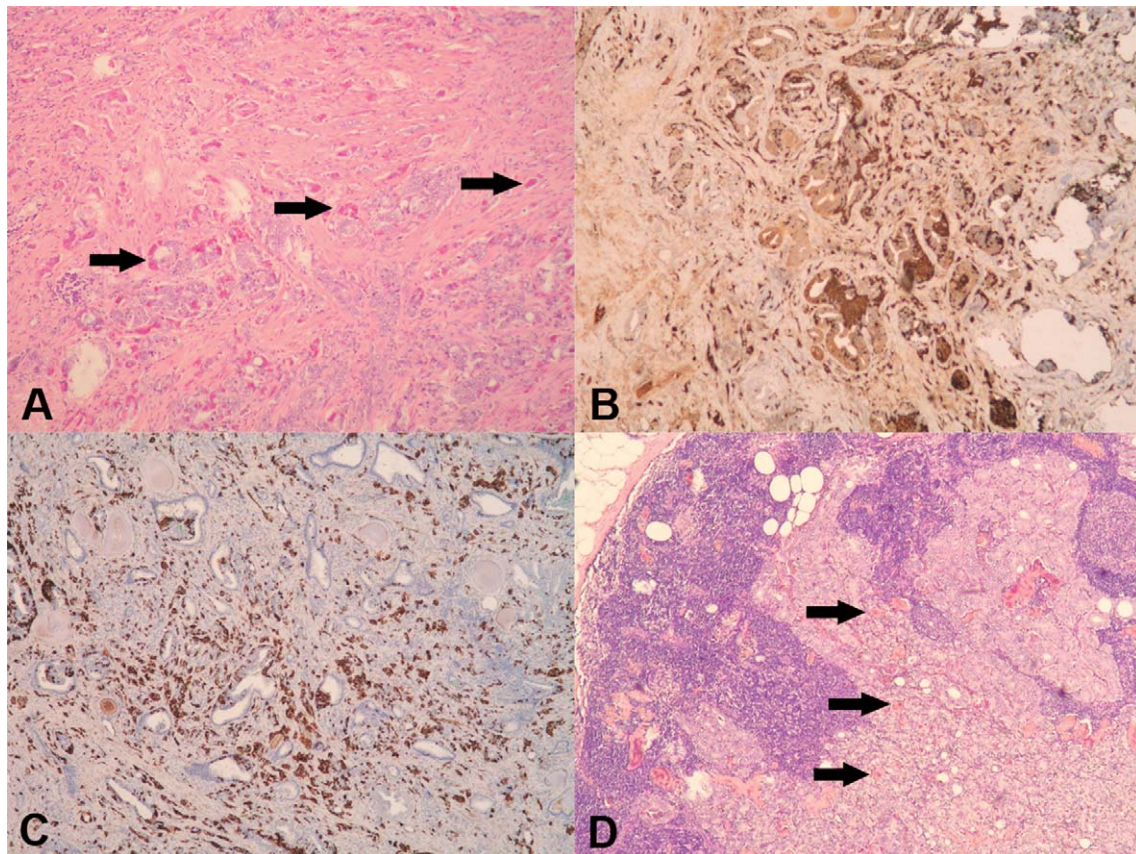


Fig. 1. A. Microscopic appearance of prostate cancer with abundant Paneth cell-like differentiation (arrows), (HEx200); B. Cells are immunohistochemically positive for chromogranin A (100x); C. and synaptophysin (100x); D. Tumor metastatic to lymph node with scattered Paneth cell-like cells (arrows).

features of Paneth cell-like carcinoma cells (Fig. 1A). Immunohistochemical analysis demonstrated positivity for chromogranin A and synaptophysin in PCLC (Fig. 1 B,C). Perineural and lymph capillary invasion was found, as well as extension through the prostatic capsule into periprostatic fat. Lymph nodes of para-aortic and pelvic regions were tumor positive (Fig. 1D). Only a few scattered Paneth cell-like cells were found microscopically in lymph node metastases. Three years after the initial surgery, chemotherapy, radiotherapy and hormone therapy (6 cycles with docetaxel and prednisone), the patient was diagnosed with metastatic disease in Th12 vertebra. It was poorly differentiated adenocarcinoma, without visible Paneth cell-like component. The patient underwent six more chemotherapy cycles with carboplatin. The illness was complicated by pneumonia and the patient was treated with ceftriaxone. The patient is currently alive and well, without recurrence 38 months from the diagnosis.

Discussion

NE component of normal prostate tissue consists of a small subset of cells, randomly scattered within the epithelium of the prostate gland. These cells contain a variety of peptide hormones, lie on the basal cell layer between secretory cells and are not reliably recognizable by hematoxylin and eosin (HE) examination. Immunohistochemistry may shed light on NE differentiation, most often with synaptophysin, chromogranin A and CD56. Neuroendocrine cells in the prostate regulate growth and differentiation in addition to the exocrine secretory process of the prostate gland.²⁻⁴

PCLC are distinct cells, easily noticeable by light microscopy at HE slides. They contain eosinophilic cytoplasmic inclusions and, unlike true Paneth cells, lack lysozyme, but express neuroendocrine markers and show neurosecretory granules on electron microscopy, which makes them more similar to the cells of the dif-

fuse neuroendocrine system.²⁻⁴ In the prostate, the presence of PCLC has been documented in benign prostatic glands, prostatic intraepithelial neoplasia, and prostate cancer. It was considered rare in both benign and malignant prostatic diseases, but Adlakha and Bostwick showed in their study that PCLC is more common than previously thought, and although it represents neuroendocrine differentiation, it is not associated with tumor grade or pathologic stage⁵.

According to literature, focal neuroendocrine differentiation is extensive in up to 5% of prostate cancers. It is considered to be associated with poor prognosis, especially with high grade NE carcinoma component (35% survival rate in 2 years in cases with neuroendocrine differentiation vs. 97% survival rate in 2 years in cases without it)^{3,4}. This may be due to high tumor level neuroendocrine cell products which stimulate growth and lack androgen receptors in neuroendocrine cells, subsequently with low therapy response^{3,4}.

Specific characteristics of neuroendocrine differentiation in prostate cancer were ignored until 2013. Then a new refined histological classification was proposed by the Prostate Cancer Foundation. It implemented newly acquired clinical and molecular data. Prostate cancer with Paneth cell-like neuroendocrine differentiation was singled out as a distinct category, which is generally considered to have a favorable prognosis⁶. The new classification was partially accepted by WHO in 2016. It distinguishes adenocarcinoma with Paneth cell-like neuroendocrine differentiation as a separate entity, along with the usual adenocarcinoma with neuroendocrine differentiation, well-differentiated neuroendocrine tumor, small cell neuroendocrine carcinoma and large cell neuroendocrine carcinoma¹.

It is still important to emphasize that there are limited data on the prognostic importance of the Paneth cell-like differentiation. According to most authors, Paneth cell-like appearance of prostatic carcinoma cells should be recognized and considered as a sign of neuroendocrine differentiation due to the possible association with resistance to hormone therapy, since androgen receptors are not expressed by benign or malignant prostatic neuroendocrine cells²⁻⁷.

In 2006, Tamas and Epstein demonstrated that Paneth cell-like differentiation foci should not be assigned to Gleason score, since the clinical outcome depends on standard parameters, i.e. grading of the conventional prostate adenocarcinoma component⁷.

In a recent study of 25 prostatic adenocarcinomas with Paneth cell-like neuroendocrine differentiation, 45% showed amplification of the Aurora Kinase A (AURKA) gene, which was associated with a higher percentage of Paneth cell-like neuroendocrine differentiation throughout the tumor, ductal features and a higher Gleason score. AURKA has been found to be overexpressed in castrate-resistant prostate cancer with neuroendocrine differentiation and the hormone-naïve primary tumor. Authors suggested that AURKA amplification may be used as a biomarker and a treatment target for an aggressive form of prostate cancer related to androgen deprivation therapy⁸.

In conclusion, it is important for a pathologist to be aware of possible neuroendocrine differentiation in prostate cancer due to resistance to conventional hormonal chemotherapy, as well as possible aggressive forms of cancers with NE differentiation. Paneth cell-like NE differentiation in prostate cancer is not related to aggressive form of cancer. AURKA gene could be a potential target for therapy of this tumor subtypes.

Acknowledgments

The authors declare that there is no conflict of interest regarding the publication of this article.

The authors received no funding for preparing this manuscript.

References

1. Moch H., Humphrey PA, Ulbright TM, Reuter VE (editors). WHO Classification of Tumours of the Urinary System and Male Genital Organs, International Agency for Research on Cancer, Lyon, 2016.
2. Nakamura Y, Fujishima F, Watanabe M, Taniuchi S, Ishida K, Ishidoya S, *et al.* A case of prostatic adenocarcinoma with Paneth cell-like appearance. *Pol J Pathol.* 2011;1: 60–64.
3. Fernandes RC, Matsushita MM, Mauad T and Nascimento Saldiva PH. Prostate carcinoma with neuroendocrine differentiation: case report and literature review. *Rev. Hosp. Clín. Fac. Med. S. Paulo.* 2001; 56 (5): 153-158.
4. Fine SW. Neuroendocrine tumors of the prostate. *Mod Pathol.* 2018; 31: S122-132.
5. Adlakha H, Bostwick DG. Paneth cell-like change in prostatic adenocarcinoma represents neuroendocrine differentiation: Report of 30 cases. *Hum Pathol.* 1994;25(2):135-139 doi: org/10.1016/0046-8177(94)90268-2.
6. Epstein JI, Amin MB, Beltran H, Lotan TL, Mosquera JM, Reuter VE *et al.* Proposed Morphologic Classification of Pros-

- tate Cancer With Neuroendocrine Differentiation. *Am J Surg Pathol.* 2014; 38(6): 756-767.
7. Tamas EF, Epstein JI. Prognostic Significance of Paneth Cell-like Neuroendocrine Differentiation in Adenocarcinoma of the Prostate. *Am J Surg Pathol.* 2006; 30(8): 980-985.
 8. Park K, Chen Z, MacDonald TY, Siddiqui J, Ye H, Erbersdobler A *et al.* Prostate cancer with Paneth cell-like neuroendocrine differentiation has recognizable histomorphology and harbors AURKA gene amplification. *Hum Pathol.* 2014;45(10):2136-2143. doi:10.1016/j.humpath.2014.06.008.

Sažetak

KARCINOM PROSTATE S KOMPONENTOM NALIK NA PANETHOVE STANICE
- PRIKAZ SLUČAJA

J. Šojat, B. Jurić, Š. Šoipi, M. Ulamec i B. Kruslin

Adenokarcinom prostate s neuroendokrinom diferencijacijom u obliku komponente koja nalikuje Panethovim stanicama je vrlo rijedak entitet. Raspršene neuroendokrine stanice nalik Panethovima mogu se naći u većini opisanih slučajeva, iako se nalaze i primjeri s predominantnom komponentom navedenih stanica. One sadrže eozinofilne citoplazmatske inkluzije, a nedostaju im androgeni receptori te su stoga imuni na hormonsku terapiju, a što je jedan od glavnih razloga da ih patolozi prepoznaju. Prema dostupnoj literaturi, klinički ishod takvih tumora ovisi o standardnim parametrima, ponajprije o gradusu konvencionalne komponente karcinoma prostate. Ovdje opisujemo 54-godišnjeg bolesnika s adenokarcinomom prostate koji pokazuje neuroendokrinu diferencijaciju tipa stanica nalik Panethovim.

Ključne riječi: *Prostata; Adenokarcinom; Panethove stanice*

ŽIVOTOPIS

IME I PREZIME: Josip Šojat, dr.med.,specijalist patologije i citologije

DATUM I MJESTO ROĐENJA: 04.03.1985, Zagreb

ADRESA STANOVANJA: Nikole Tesle 27, 10410 Velika Gorica

E-mail: josipsojat31s@gmail.com

TELEFON: 0955056712

OBRAZOVANJE (kronološki od novijeg k starijem datumu):

- 2015.-2021.- specijalistički staz i položen specijalistički ispit 27.09.2021.
- 2003.-2010. - studij medicine na Medicinskom fakultetu u Zagrebu
- 1999.-2003.- III Gimnazija u Zagrebu
- 1991.-1999.- osnovna škola u Zagrebu

RADNO ISKUSTVO (kronološki od novijeg k starijem datumu)

- 2015.- danas- OB dr. Ivo Pedišić u Sisku, Odjel za patologiju i citologiju
- 2012.-2015.- ambulante opće medicine (D.Zdenčina, Petrinja, Gorje Bazje i Gospić)
- 2010.-2011. - staž u Klinici za psihijatriju Vrapče

**POPIS RADOVA I SUDJELOVANJA NA STRUČNIM I ZNANSTVENIM
AKTIVNOSTIMA:**

- Šojat J, Jurić B, Šoipi Š, Krušlin B. Paneth cell- like component in prostate cancer- case report/karcinom prostate s komponentom nalik na Panethove stanice- prikaz slučaja.Acta Clin Croat, 2018 (Suppl 1); 57:85-8
- Jurić B, Šojat J, Brnadic I, Krušlin B. Mixed adenoneuroendocrine carcinoma (collision tumor) of the gastrointestinal tract: A case report Endocrine Oncol Metabol 2018;4:30-3