

Cutaneous Metastases as a First Sign of Gastric Adenocarcinoma

Prtajin, Marta; Ledić Drvar, Daniela; Štulhofer Buzina, Daška; Jurakić Tončić, Ružica; Ilić, Ivana; Čeović, Romana

Source / Izvornik: **Dermatology Practical & Conceptual, 2024, 14**

Journal article, Published version

Rad u časopisu, Objavljena verzija rada (izdavačev PDF)

<https://doi.org/10.5826/dpc.1402a67>

Permanent link / Trajna poveznica: <https://urn.nsk.hr/urn:nbn:hr:105:180165>

Rights / Prava: [Attribution-NonCommercial 4.0 International/Imenovanje-Nekomercijalno 4.0 međunarodna](#)

Download date / Datum preuzimanja: **2025-03-15**



Repository / Repozitorij:

[Dr Med - University of Zagreb School of Medicine Digital Repository](#)



Cutaneous Metastases as a First Sign of Gastric Adenocarcinoma

Marta Prtajin¹, Daniela Ledić Drvar¹, Daška Štulhofer Buzina¹, Ružica Jurakić Tončić¹, Ivana Ilić², Romana Čević¹

¹ Department of Dermatology and Venereology, University Hospital Centre Zagreb, School of Medicine, University of Zagreb, Zagreb, Croatia

² Department of Pathology and Cytology, University Hospital Centre Zagreb, School of Medicine, University of Zagreb, Zagreb, Croatia

Citation: Prtajin M, Ledić Drvar D, Štulhofer Buzina D, Jurakić Tončić R, Ilić I, Čević R. Cutaneous Metastases as a First Sign of Gastric Adenocarcinoma. *Dermatol Pract Concept*. 2024;14(2):e2024067. DOI: <https://doi.org/10.5826/dpc.1402a67>

Accepted: October 23, 2023; **Published:** April 2024

Copyright: ©2024 Prtajin et al. This is an open-access article distributed under the terms of the Creative Commons Attribution-NonCommercial License (BY-NC-4.0), <https://creativecommons.org/licenses/by-nc/4.0/>, which permits unrestricted noncommercial use, distribution, and reproduction in any medium, provided the original authors and source are credited.

Funding: None.

Competing Interests: None.

Authorship: All authors have contributed significantly to this publication.

Corresponding Author: Professor Romana Čević, MD PhD, Department of Dermatology and Venereology, University Hospital Centre Zagreb, School of Medicine, University of Zagreb Kišpatićeva 12, 10000 Zagreb, Croatia. E-mail: romana.ceovic@gmail.com

Case Presentation

A 61-year-old female patient was referred to our department with newly developed erythematous nodules on the skin of the back of her neck (Figure 1A). Concurrently, she reported unintentional weight loss, faster intestine transit time, and painful gastric spasms. She had no severe diseases history. After a year of extensive diagnostic procedures, she was diagnosed with diffuse gastric adenocarcinoma. Histopathological examination of her skin biopsy revealed cutaneous metastasis, which was confirmed with cytokeratin (CK)-7 immunohistochemical positivity (Figure 1B). Over the following year and a half, our patient underwent surgery, followed by several chemotherapy cycles. Multiple cutaneous metastases on her trunk were treated with radiotherapy, resulting in severe post-irradiation reaction. Unfortunately, despite all treatment, she passed away.

Teaching Point

Cutaneous metastasis may be the first sign of a silent primary tumor [1]. Metastatic dissemination to the skin occurs by lymphatic or hematogenous spread, direct contiguity, pericytic mimicry, or iatrogenic implantation. Metastases may appear before primary tumor identification in approximately 10% and simultaneously in 25.1% cases, but generally later in the disease course [2]. Lung cancer is accountable for most cases in men and breast cancer in women. Cutaneous metastases mostly present as nodules [1,2]. Some gastrointestinal tumors may give metastases to the umbilicus, presenting as Sister Mary Joseph nodule [1]. Clinical morphology, location, and histopathological and immunohistochemical findings of cutaneous metastases alongside patient's sex and age are essential for diagnosing primary neoplasm [2]. Dermatologists have an important role in early recognition and differentiation of correct diagnosis [1].

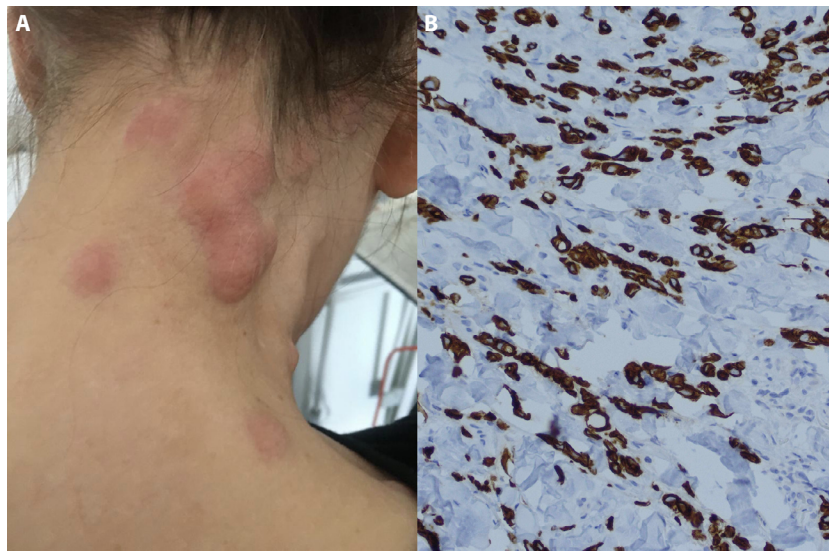


Figure 1. (A) Clinical presentation. (B) Positive immunohistochemical staining for CK-7.

References

1. Ledić Drvar D, Pašić A, Manola I, Radoš J, Dobrić I, Lončarić D. A Eleven-Year Retrospective Study of Metastatic Carcinomas of the Skin: Own Experience. *Acta Dermatovenerol Croat.* 2005;13(3):160-167. PMID: 16146618.
2. Sittart JA, Senise M. Cutaneous metastasis from internal carcinomas: a review of 45 years. *An Bras Dermatol.* 2013;88(4):541-544. DOI: 10.1590/abd1806-4841.20131165. PMID: 24068124.