

Interventional methods in musculoskeletal system

Raillo Espinosa de los Monteros, Jose Antonio

Master's thesis / Diplomski rad

2018

Degree Grantor / Ustanova koja je dodijelila akademski / stručni stupanj: **University of Zagreb, School of Medicine / Sveučilište u Zagrebu, Medicinski fakultet**

Permanent link / Trajna poveznica: <https://um.nsk.hr/um:nbn:hr:105:409450>

Rights / Prava: [In copyright](#)/[Zaštićeno autorskim pravom.](#)

Download date / Datum preuzimanja: **2024-07-13**



Repository / Repozitorij:

[Dr Med - University of Zagreb School of Medicine Digital Repository](#)



UNIVERSITY OF ZAGREB
SCHOOL OF MEDICINE

Jose Antonio Raillo Espinosa de los Monteros

**INTERVENTIONAL METHODS IN
MUSCULOSKELETAL SYSTEM**

Graduate Thesis



Zagreb, 2018.

The author declares no conflict of interest regarding this paper.

This graduate thesis was made at the Department Radiology, Dubrava Hospital mentored by assistant professor Gordana Ivanac and was submitted for evaluation in academic year 2017/2018.

Mentor: assistant professor Gordana Ivanac

ABBREVIATIONS:

MSK: Musculoskeletal

IR: Intervention Radiology

CT: Computed Tomography

MRI: Magnetic Resonance Imaging

FC: Fluoroscopy

US: Ultrasonography

IA: Intra-articular

IAI: Intra-articular injection

OA: Osteo-arthritis

HA: Hyaluronic Acid

CS: Corticosteroid

SF: Synovial Fluid

MST: Modified Stem Cells

CONTENTS

Summary	5
Sažetak	6
1. Introduction	7
2. Review of Different Technologies	10
2.1. Fluoroscopy	10
2.2. Computed Tomography	11
2.3. Magnetic Resonance Imaging	12
2.4. Ultrasonography	13
3. Diagnostic Procedures	14
3.1. Arthrocentesis	14
3.2. Synovial Liquid Aspiration.....	15
3.3. Image Guided Biopsies	16
3.3.1. Bone Biopsy	17
3.3.2. Muscular Biopsy	17
4. Therapeutic Procedures	18
4.1. Joint Fluid Drawing.....	18
4.2. Intra-articular Injections	19
4.3. Vascular Procedures	22
5. Conclusion	23
Acknowledgement	25
References	26
Biography	32

SUMMARY

Title: Interventional methods in musculoskeletal system

Author: Jose Antonio Raillo Espinosa de los Monteros

The field of Interventional Radiology keeps growing and developing each year. The different health systems all over the world try to implement this subspecialty in most major hospitals due to its reliability, safety and efficacy. Growing demand is making it possible to bring down the prices of the technologies necessary for good practice. Moreover, due to globalisation and the consequent exchange of data allows different institutions to intercommunicate and get conclusions in much efficient manner. It is difficult to make a distinction between both, Diagnostic and Intervention Radiology, since both subspecialties overlap bringing together a group of professionals that can at the same time analyse some pathology and fix it if possible. Many open surgical interventions are being substituted by small closed radiologic interventions decreasing the cost and improving the patient outcomes. In the musculoskeletal system the appliances of interventional radiology are many but must be remarked its great utility in percutaneous biopsies and intra-articular injections with different drugs. There is a whole set of medical instruments used by radiologist which is yearly updated due to new studies that show better or lower performance depending on the intervention carried out. Radiology is without doubt playing a major role on the medical panorama, the biggest burden is to make these technologies available for a bigger sector of the population and not just for developed countries.

This paper describes the division of this subspecialty and gives a general scope of the different procedures existing without going to deep into the many technical aspects that each one carries.

Keywords: interventional radiology, musculoskeletal system, percutaneous, biopsy, intra-articular

SAŽETAK

Titula: Intervencijske metode u muskuloskeletnom sustavu

Autor: Jose Antonio Raillo Espinosa de los Monteros

Područje Intervencijske radiologije raste i razvija se svake godine. Različiti zdravstveni sustavi širom svijeta pokušavaju implementirati ovu subspecijalnost u većini velikih bolnica zbog svoje pouzdanosti, sigurnosti i učinkovitosti. Rastuća potražnja omogućava smanjenje cijena tehnologija potrebnih za dobru praksu. Štoviše, zbog globalizacije i posljedične razmjene podataka omogućuje različitim institucijama međusobno komuniciranje i dobivanje zaključaka na učinkovit način. Teško je napraviti razliku između dijagnostičkih i intervencijskih radiologija, budući da se oba podskupina preklapaju, okupljajući skupinu stručnjaka koji istodobno mogu analizirati neke patologije i ukloniti ih ako je moguće. Mnoge otvorene kirurške intervencije zamjenjuju se malim zatvorenim radiološkim zahvatima, smanjuju troškove i poboljšavaju ishode pacijenata. U sustavu mišićno-koštanog sustava aparati intervencijske radiologije su mnogi, ali treba primijetiti njegovu veliku korisnost u perkutanim biopsijama i intraartikularnim injekcijama s različitim lijekovima. Postoji cijeli niz medicinskih instrumenata koji koristi radiolog koji se godišnje ažurira zbog novih studija koje pokazuju bolju ili manju učinkovitost ovisno o izvršenoj intervenciji. Radiologija bez sumnje igra veliku ulogu u medicinskoj panorami, najveći teret je omogućiti dostupnost tih tehnologija za veći sektor stanovništva, a ne samo za razvijene zemlje.

Ovaj rad opisuje podjelu ove subspecijalnosti i daje opći opseg različitih postojećih postupaka bez da ide duboko u mnoge tehničke aspekte koje svaka nosi.

.Ključne riječi: intervencijska radiologija, mišićno-koštani sustav, perkutana, biopsija, intraartikularna

1. Introduction

Interventional radiology has a prominent position in the healthcare field of the twenty-first century, a time when many innovations in assessment tools for physicians are increasing the quality of care for patients significantly. Interventional radiology (IR) encompasses a wide range of methods that use radiological guidance for medical practice. Some examples of IR include fluoroscopy, computed tomography (CT), magnetic resonance imaging (MRI), ultrasound techniques, and other innovative measures, among others [1].

These innovations provide physicians with a wide range of useful information for making an accurate diagnosis and allow the patients to also be included in the treatment plans available. These factors all have brought various techniques associated with IR into the forefront of medical technology of the 21st century, a general diagnostic tool that is likely to continue within this framework of the medical field for many years to come [1]

There are many reasons why IR became more prevalent among the mainstream of healthcare practices; the most important reason is due to a higher level of knowledge about its use as evidence-based research and scientific knowledge increased through research studies conducted throughout the latter half of the 20th century. Koenig et al. [2] trace the development of image-guided biopsy procedures for musculoskeletal lesions to 1997, at which time radiologists opted for either computer tomography (CT) or MRI, depending on their preference. As more hospitals began to introduce IR within the general framework of healthcare practices, a growing sense of interest and confidence among the general public developed as well. Education training programs for students also have developed along with these advances, although Brown et al. [3] indicated in a 2004 report that they had not yet been coordinated to meet the growing demand. These sociocultural factors have had a significant effect on the growth of computerized medical practices, where people today may

feel less concern about the outcome due to a higher level of accuracy that goes along with IR diagnosis and subsequent treatment plans.

The first procedure used in the early development of interventional radiology occurred on January 16, 1964, when the IR pioneer Charles Dotter practiced successfully on an 82-year old woman who refused a leg amputation even though she had gangrene and very painful leg ischemia [4]. While the traditional surgical method would have saved her from pain as well as prolonging her life at least a few more years, this brave woman was prepared to be the first person in history who underwent a very untested and even controversial approach to her serious medical challenges. The point in relaying this narrative is to illustrate the importance of the physician's communication style, which sometimes may mean the difference between success and failure. It is very important for patients to trust and have confidence in their doctors, especially in the case of elderly clients who have been through a lifetime of challenges already and who may be quite frail. At any rate, Dotter "percutaneously dilated a tight, localized stenosis of the superficial femoral artery (SFA)...after successful dilation of the stenosis with a guide wire and coaxial Teflon catheters, the circulation returned to her leg" [4]. Even at the age of 82 and not in the best physical health, this woman did walk again comfortably and provided the world with an example of the future—a time when modern medical breakthroughs may seem like an everyday occurrence that people take for granted.

As the American Board of Radiology highlighted in a recent discussion [5], there are several subspecialties in the field of radiology, including palliative medicine, neuroradiology, nuclear radiology, pain medicine, interventional radiology, and pediatric radiology. Within the past few years, interventional radiology has earned its deserved status as its own specialty area, due to the complex procedures that have been developed [5]. For example, IR currently includes using Y-90 radioembolization on patients who have liver cancer. As Fellows

explains, this procedure “allows for higher doses of radiation to be delivered since it is a targeted therapy.” In an interview with a prominent interventional radiologist and director of clinical trials and research center in California, Mahmood Razavi, MD highlights the importance of the profession: “interventional radiologists are experts at reading x-rays, CT scans, and MRIs, but more importantly, they treat the disease they're seeing on the images.” IR techniques are used in many specialty areas of medicine, including biopsy measures that previously required exploratory surgery and other invasive procedures. As the 21st century evolves, the growing uses of IR continue to have an amazing effect on the quality of healthcare and life extension possibilities [6].

As Logan et. al [7] pointed out as early as the 1990s, many musculoskeletal biopsy procedures related to IR were performed on an out-patient basis, providing a safer, more cost-effective treatment method from the outset. Even at that time, the computerized methods used for biopsy were known to increase the degree of accuracy to around 60-95% [7]. They have increased in scope and practice with every new technological advancement in medical research over the course of more than two decades with a rapidity that possibly could not have been imagined. The IR methods used in hospital settings and clinician offices have a more inviting feel for patients that includes a full screen monitor for them to see what the radiologist sees.

In this review will be described this subspecialty on the musculoskeletal system. A subspecialty that on its beginning addressed only plain x ray on the joints but with the introduction of contrast elements during the 60s new anatomical pathologies could be identified such as lesions on menisci and osteochondral tissue.

The start of imaging guided procedure in the musculoskeletal system thus started with the injection of contrast iodine by arthrocentesis and its observation under fluoroscopy (FC).

The vast majority of these procedures are performed under US guiding due to its availability,

low cost and real time imaging generated.

It is also important to remind that puncture, like any other medical intervention, carries some sort of risk such as hematoma and infection. Therefore, the interventional radiologist will inform the patient about the possible complications and get the signed consent before it takes place and take all the measures to decrease the chances of complication.

2.Review of Different Technologies

2.1 Fluoroscopy

Fluoroscopy allows physicians to visualize the reproductive, digestive, urinary, respiratory, and musculoskeletal systems. Bones, joints, and muscles can be visualized as well as solid organs such as the kidneys, heart, and lungs[8]. This imaging modality is often used for lumbar puncture, interventional radiology and neuroradiology procedures, anesthetic injections into the spine or joints, percutaneous vertebroplasty, and other issues of the musculoskeletal system [8].

The topic of fluoroscopy has been an important one for researchers from various perspectives throughout the past several years. In 2001, Sofka, Collins, and Adler discussed the areas of debate that were prevalent at that time [9]. According to their assessment, fluoroscopy was of limited use for patients presented with a disease of the muscles and tendons. They also discussed the disadvantages of conventional computer tomography (CT), including the difficulty of guiding the needle into a small target such as a tendon sheath [9].

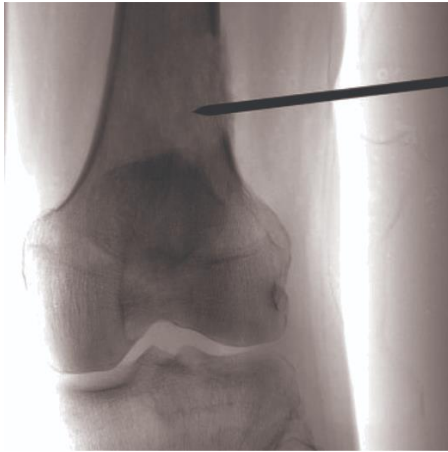

Fig1. FC guided biopsy [47]

2.2 Computed Tomography (CT)

Unlike radiographs, CT images allow the visualization of soft tissues, organs, bones, and blood vessels with accuracy [10].

Technological advancements have developed cryoprobes that can be utilized percutaneously and guided throughout the body with image guidance[11]. Probes of the current generation work with room temperature argon delivered via sealed insulated probes that allows for fast cooling through the Joule-Thompson effect – cooling through rapid expansion [11]. The use of the modern cryoprobe has been matched with image guidance to perform minimally invasive insertion through the body and monitoring of the target zone to ensure adequate tissue coverage of the treated area and to prevent ablation of healthy tissues [11]. Ultrasound and MRI can be used for this technique, but CT is the most commonly imaging technique for musculoskeletal tumours. Ultrasound cannot penetrate and visualize bone structures and MRIs include magnetic fields and therefore some limitations [11].

2.3 Magnetic Resonance Image (MRI)

While the early MRIs were based on closed-bore MR systems, structures throughout the musculoskeletal system are more readily accessed by using vertically open MR units [12].

MRI allows for real time tracking of any interventional device via external sensors [12]. Using mathematical triangulation, the advancement of a device is improved above visual detection [12]. Fixed sensors recognize signals from light-emitting diodes that are placed on the interventional device. Radiofrequency is also used as guidance through triangulation of a local receiver coil on the interventional device. Signals are recorded, and location of the device is plotted on an image that was previously recorded. Due to image distortion that can occur and the inability to see the entire device in these external reference methods, the interventional device should be rigid [12]. Fiducial markers and anatomical landmarks can be used as self-referenced techniques to guide procedures with less distortion [12]. Utilizing the MRI hardware for MR tracking is considered to include no distortion at all. Augmented reality guidance displays the data regarding the procedure direction on the patient display rather than on a separate screen[12]. In this system, images are taken immediately before the procedure begins and are displayed for reference of anatomy overlaid on the patient. Procedure times have been compared to those completed with fluoroscopic and CT guidance [12].

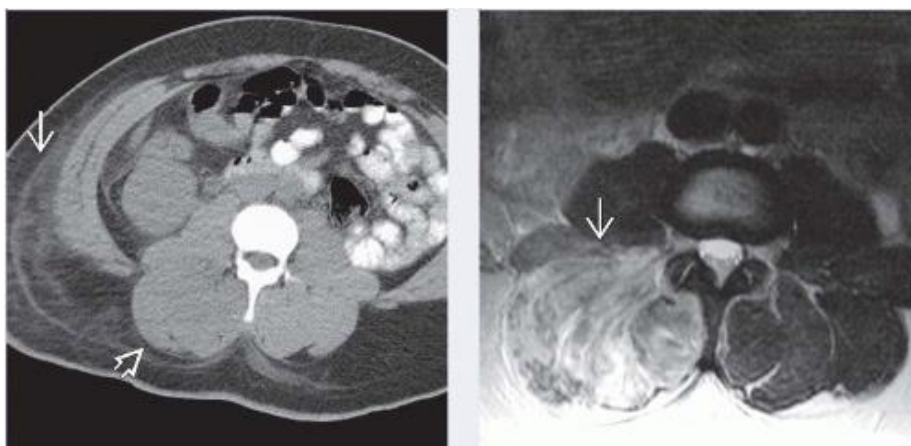


Fig 2. Rhabdomyolysis: Left CT/Right: MR T2 [48]

2.4 Ultrasound (US) – Guided

As Wakefield pointed out over a decade ago, the use of ultrasound for the investigation and management of patients with musculoskeletal disease had already been around for 30 years or longer [13].

The development of IR has been steadily growing since at least the 1980s, with only a few debatable issues that have caused some concern overall. For example, in the 1990s, the medical research available at that time began to focus on the value of sonography guidance to replace computed tomography (CT). As Dodd and other researchers Dodd, et al. [14] and Rubens, et al. [15] recommended, sonographic guidance should be considered as an alternative due to various concerns—including considerations of cost and time factors. These recommendations highlight the advantages of IR that have become increasingly important for the advancement of medical technology in the 21st century.

Musculoskeletal ultrasound techniques are used by rheumatologists to assess the degree of inflammation of various joints in the body, which are methods that have been adopted increasing on a worldwide basis [16] [17]. Besides rheumatoid arthritis (RA), there are many musculoskeletal conditions that also may be more accurately diagnosed using modern techniques of MRI and other IR technologies. As Tzortziou, Morrissey, and Underwood [18] highlighted in their 2008 article on specific management skills for physicians, having a knowledgeable interventional radiologist on hand for a variety of patient needs will improve patient outcomes overall.

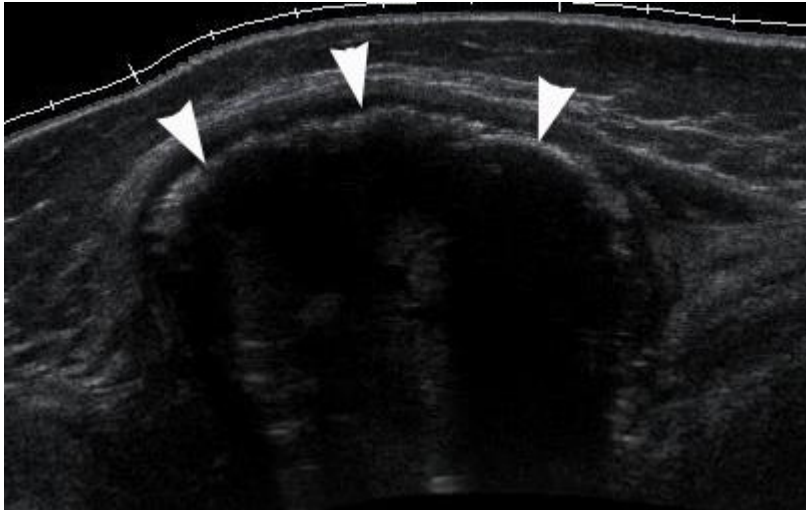


Fig 3. Myositis ossificans. Arrows confirm calcification [49]

3.Diagnostic procedures

3.1. Arthrocentesis

Nowadays they are performed with CT or MRI together with the injection of contrast agent under FC guidance. The contrast material is injected intra-articular and can be iodinated, paramagnetic or saline, depending on the technology to be used. They both provide excellent image resolution and can be used in different situations determined by the disease or the patient personal condition such as pacemaker [7] [19].

The implementation of “Lidocaine Test” has been also useful in diagnosing the origin of the pain. Local anesthetic lidocaine is delivered at the same time of arthrocentesis specially in the hip. Pain dissipation after the procedure gives important information about the diagnosis and correlates with the severity of the disease. It is used for other anatomical structures and joints but deserves important mention psoas peri-tendinitis, whose diagnosis is clinic, however, lidocaine test confirms it [19] [20].

3.2 Synovial liquid aspiration

This technique is performed under US guidance avoiding to damage vascular or nervous structures and the most common indications are suspicion of gout, crystal precipitating arthritis or septic arthritis.

US examination and image guiding on aspiration procedures can have benefits compared with other techniques. First, the joint is visualized to make sure the presence of fluid. In this way we can avoid potential trauma of a joint that does not contain effusion.

Besides joint effusions, US can show other types of fluid accumulation like bursitis and soft-tissue abscesses [20]. Some of these abscesses can be discovered upon physical examination but in patients with superimposed inflammation, edema or obesity might be impossible to identify.

In this case US allows the clinician the detection without the risking of contaminating and aseptic joint that can be present on blind aspiration. [20]

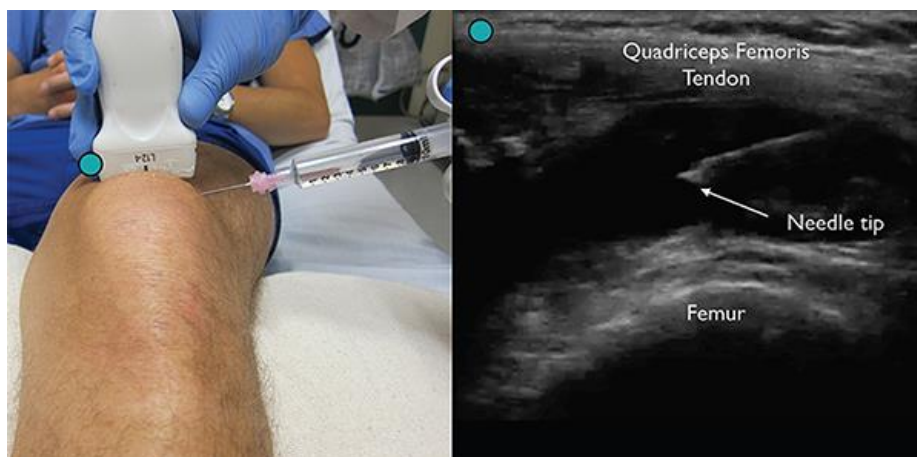

Fig 4. [50] US guided needle aspiration

3.3 Image Guided Biopsies

MSK biopsies with guiding instruments are safe and effective reaching an accuracy up to 97% [21]. CT and US are the modalities chosen to perform such procedures and different needles and techniques are available to help the radiologist during each intervention, the type of needle will most of the times be determined by the type of tissue and localization of the tissue to be sampled. The most common causes for biopsy are differentiation of primary from secondary neoplasm, antibiotic resistant infections to isolate the specimen and elaborate a targeted therapy. [21]

Biopsies are only required when the histopathological features obtained from it will affect the patient outcome. This mean that any lesion that has been described as a benign by both clinical and imaging should not be biopsied. [21]

In the following table are shown the indications and contraindications for MSK biopsies:

Indications	Contraindications
<ul style="list-style-type: none">-Definitive diagnosis of a bone or soft tissue lesion with aggressive imaging features-Determination of a bone or soft tissue lesion with indeterminate imaging features- Confirm or exclude a metastasis in a patient with known primary malignancy-Isolation of microorganisms in a musculoskeletal infection-Exclude or confirm an underlying lesion causing a pathological fracture	<ul style="list-style-type: none">-Acute or ongoing non-MSK infection-Bleeding diathesis- Inaccessible site or uncooperative patient

Fig 5 [51].

3.3.1. Bone biopsy

The vast majority of them are done with CT on both axial and peripheral skeleton through percutaneous interventions. Due to its low complication rate and high accuracy this is the best cost-effective method compared with open biopsy [21]. The risks include hemorrhage, neurapraxia and infections with an incidence from 0 to 10% compared with 16% for open biopsies [22].

The closest percutaneous access point to the lesion does not have to be by default the best one since it can involve crossing of important anatomical structures and compartments [50].

There is always risk of tumor cell spreading and therefore the tissue around the needle track will be resected [22].

3.3.2. Muscular and soft tissue biopsy

With percutaneous puncture is also the method of choice in most hospitals. It does not require hospitalisation, it is not too painful and causes no scar. The tissue obtained is enough to make a complete study and the biopsy can be again easily obtained in case of wrong tissue selection. Moreover, different non-adjacent areas can be examined. The main indication is for the diagnosis of muscular disorders such as Duchenne [23]. It is also important for identification of multifocal processes such as vasculitis or polymyositis and in general any condition that require multiple repeated biopsies. It is the method of choice among the adult population but it is contraindicated in young infants [23]. Most muscular percutaneous biopsies are done with US guidance. Those lesions that due to their echogenicity to close structures are difficult to differentiate should be visualized with MRI or CT.

The biopsy is done once an electromyographic study has been performed on the patient assessing the most adequate muscle and side. Then local anaesthesia of the skin and aponeurotic surrounding tissue is performed and an incision of 2-3mm is done [24]. A 4 mm

diameter needle is introduced until reaching the muscle, passing the through the fascia and then the central cylinder is extracted and aspirated [24].

4. Therapeutic Procedures

4.1 Joint fluid drawing

Joint fluid drawing is a relieving procedure used to remove the fluid that surrounds the joint for two purposes: to relieve the swelling and to analyze fluid for diagnosing the patient's disorder [25].

Most of these drainages will consist on hematomas and seromas evacuation from posttraumatic origin or fluid collection in areas adjacent to hip prosthesis. In these cases, US will be used for guiding [26].

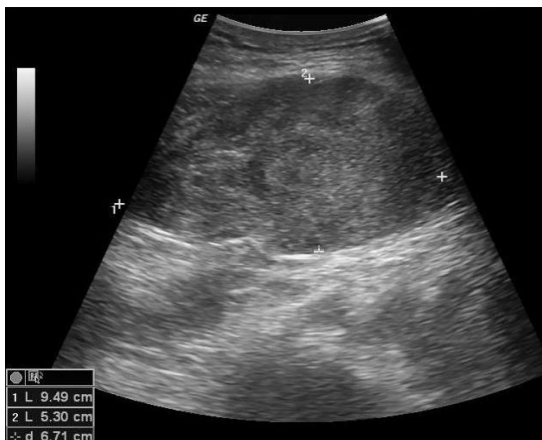

Fig 6. [52] Hematoma in gluteus

When there is fistula suspicion, iodide contrast should be used under FC guidance to obtain better characterization, localization and depth of the cavity [26].

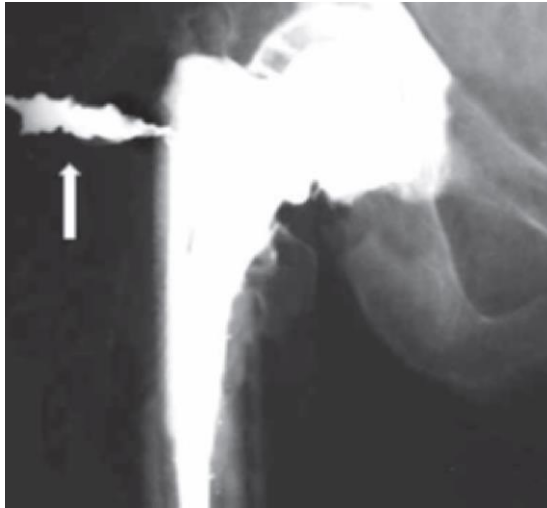


Fig 7. [53] FC fistula to the skin

4.2 Intra-articular injections:

Palpation guided anatomical intra-articular injections (IAI) can easily cause wrong needle placing. It is extremely useful in this procedure the use of US, that gives an accuracy of 95,8% versus 77,8% of anatomical, palpation technique improving cost effectiveness and improving the patient outcomes [27]. The major contraindication for IAI is septic arthritis. There are different substances and drugs that can be injected intra-articular (IA) as a solution for pain. This kind of remedy is usually used when the patient fails to respond to conservative treatment with painkillers but also as a first line treatment, depending on the age, joint and condition of the affected patient.

The most common joints where IAI are done are tarsal, ankle, knee, hip and wrist. There also different pathological processes that can suggest the use of IAI but in this review we will focus on Osteoarthritis (OA), being the most common joint disease [26].

OA is not just a degenerative disease caused by ageing, it is a much complex conditions that involves different pathological processes and chemical mediators that cause primarily cartilage destruction but also produce synovitis, subchondral bone remodeling, menisci ligaments degeneration and joint capsule hypertrophy [28]. The main complaint of the

patients is pain.

Following paragraphs will mention different substances used on the treatment of OA by IAI:

A. Corticosteroids: until today the mechanism of action of CS is being investigated but different studies show that what influences the motus in OA is its acting on CS receptor decreasing permeability of the vessels and therefore preventing the accumulation of inflammatory cells [29]. It was mentioned before the lidocaine test as a measure of immediate pain relieve resulting from the anesthetic but delayed pain relieving also occurs with the use of corticosteroid after two weeks from the intervention happens in 70 % of patients with OA. [30][31]. The use of intra-articular CS shows particular benefit on OA flare, decreasing considerably inflammation and pain and increasing joint mobility [30]. Moreover, corticosteroid can be also injected on bursae and areas adjacent to the tendon in different inflammatory conditions [26].

B. Hyaluronic acid (HA): it is a glycosaminoglycan occurring naturally on the human body and one of the main components of synovial fluid. It works as a lubricant by increasing viscosity during slow joint movements and as mechanical force absorber during faster joint movements [32]. During the pathological process of OA the amount and quality of HA is reduced within the joint causing increased friction and contributing to its degeneration. IAI of HA causes a temporal recover of the viscoelastic properties of the affected SF, that is why is called viscosupplementation [33].

C. Plasma rich in platelets (PRP): this substance is obtained from a concentrate of platelet having five times the normal amount in blood. Platelets contain high amount of growth factors and bioactive molecules. These group of molecules understandably are responsible of the different results observed after PRP administration and are: chondrogenesis, angiogenesis, antiinflammation and consequently pain relieving [34] [35].

Egemen et al. [36] concluded after different reviews on IAI that these are safe procedures and benefit the patient outcome. However, more research should be carried to identify the real effects from the placebo. Depending on the patient characteristic and resources some basic guidelines can be elaborated for the use of the mentioned:

CS are practical in acute synovitis in patients who are not suitable for operation. Their effect is short term and mostly limited to OA flares [36].

HA is a better option on obese patients exceeding the 60 years of age and extremity malalignment and bring a long-term effect profile [36].

PRP is generally used in younger patients, without obesity nor extremity malalignment. It is also used on patients older than 60 and obese followed by a one dose of HA 3 weeks later [36].

D. Modified Stem Cells (MSC): a review study carried by Wayne Yuk-wai Lee et al [37] concluded that MSC therapies have been victorious in moderate cartilage regeneration and pain relieve but has not proved long term improvement on OA patients related to original hyaline cartilage [37]. The trials were too short to conclude remarkable regeneration and in some of the patient autologous stem cells with lower proliferation were used causing inconsistency between the trials [37]. However, advances in both, OA pathogenesis and MSC can increase the therapeutic opportunities in the upcoming years.

E. Polidocanol Injection: complain of painful tendon is a common thing, specially among those who do sport regularly. The true origin of this pain has not been completely discovered yet. However, by using Doppler US and immunohistochemical tendon biopsies a relation has been founded between neurovascular ingrowth in areas where there is pain [38]. After few clinical studies using US guided polidocanol injections in areas of

neovascularisation can be concluded that this agent is good in short and middle term. After two years of follow up tendon size regress and consequently the pain [38].

4.3 Vascular Intervention

We all have heard about stenting of occluded or narrowed vessels but since this is more in the field of vascular radiology we will not talk about it in this review. However, in the next paragraph will be described a novel technique for prevention of vessel occlusion developed in the last years and with increasing use in the medical scope.

Another relieving procedure that utilizes interventional radiology is endovenous laser treatment (EVLT). This is a novel technique to reduce the risk of occlusion of the incompetent greater saphenous vein (GSV)[39]. A study of 84 patients with GSV exhibiting signs of reflux of blood at the saphenofemoral junction into the GSV underwent endovenous pulses of laser energy [39]. Evaluated with serial duplex ultrasonography at months 1, 3, 6, and 9, the patients proved that the reflux was closed in 99% of cases and evaluated in a prospective, nonrandomized, consecutive enrollment multicenter study. Patients were evaluated at 1 week and at 1, 3, 6, and 9 months to determine efficacy and complications. This reliefation technique is effective in short term for varicose veins and long-term studies are called for [39].

There is a whole set of interventions for the vertebral column but due to its proximity with the spine procedures are performed by neurosurgeons and neuroradiologists so it will not be discussed in this review.

5. Conclusion

Regardless of the specific condition, intervention radiology is becoming an increasingly important and viable option for treatments in patients who seek professional advice. These methods have a strong role in providing patients with a more realistic sense of hope for long-range recovery—a directional tendency that has been supported by evidence-based research and practical applications in a wide range of medical healthcare settings [40] [41] [42] [43].

Studies continue to increase in regional medical centers all around the globe. They are not limited according to topic or specialty area, nor do they have a limited access where only the select few may read the results and incorporate their findings into their own medical practices. Instead, open access to medical journal studies have increased the advancements of IR and other important areas of the professional community of scientists significantly. For example, in the Italian studies that Silvestri et al. [44] referred to in their journal article, there were a number of new approaches to the problems associated with joint pain tendons, bones, discs, and muscles. While each research study directed their findings according to a particular area of interest, all of them together signify an increasingly collaborative approach to the issues which are so devastating for people who suffer from a variety of musculoskeletal conditions [44] [45] [46]. Synthesizing the various components of research studies conducted on a worldwide basis is a significant factor for developing entirely new approaches to medicine, which currently has a central role in IR technologies.

Although there are hundreds of innovative ways to use interventional radiology within the current framework of medical understanding, each person who will opt to study in the medical field, and especially in IR, also will have a unique contribution for the 21st century. These exciting opportunities provide a positive outlook on the future, one that may also be fraught with significant challenges that are sometimes overwhelming. However, the way a

person approaches the future depends on many factors that can be researched according to many limitless opportunities never before achieved in the history of humankind. In many ways, people living today are on the frontier of a time and place that is truly amazing. These times include innovative technologies and approaches to medicine that have never been achieved before, which is largely possible due to the ways that people living all around the globe today now have communication technologies for sharing their ideas. These possibilities open up new doors for a generation that has grown up to expect technology as an available resource; yet the potentialities of these scientific advances have barely been tapped to-date.

Acknowledgements

I would like to thank all the colleges from all over the World I have met in the last six years, they have given me another perspective and opened my mind. Of course, I can't forget my parents and Katharina for all the unconditional support provided during the good and the bad times, in every aspect.

References

- [1] Puchner, R. y otros, 2016. Interface management between general practitioners and rheumatologists - Results of a survey defining a concept for future joint recommendations.
- [2] Koenig, C. y otros, 2001. MR-guided biopsy of musculoskeletal lesions in the low-field system. *Journal of Magnetic Resonance Imaging*, 13(5), pp. 761-768.
- [3] 3. Brown, A. y otros, 2004. Practice training, and assessment among expert performing musculoskeletal ultrasonography: toward the development of an international consensus of education standards for ultrasonography for rheumatologists. *Arthritis Care & Research*, 51(6), pp. 1018-1022.
- [4] Rosch, J., Keller, F. & Kaufman, J., 2003. The birth, early years, and future of interventional radiology.. *Journal of Vascular and Interventional Radiology*, 14(7), pp. 841-853.
- [5] American Board of Radiology, 2017. Subspecialties. Available at: <https://www.theabr.org/interventional-radiology/subspecialties>
- [6] Fellows, J., 2014. Interventional radiology no longer a sub-specialty. Available at: <http://www.healthleadersmedia.com/physician-leaders/interventional-radiology-no-longer-sub-specialty?page=0%2C2>
- [7] Logan, P. y otros, 1996. Image-guided percutaneous biopsy of musculoskeletal tumors: an algorithm for selection of specific biopsy techniques. *American Journal of Roentgenology*, 166(1), pp. 137-141.
- [8] Johns Hopkins Medicine, s.f. Fluoroscopy Procedure. Available at: https://www.hopkinsmedicine.org/healthlibrary/test_procedures/orthopaedic/fluoroscopy_procedure_92,P07662

- [9] Sofka, C., Collins, A. & Adler, R., 2001. Use of ultrasonographic guidance in interventional musculoskeletal procedures: a review from a single insitution.. *Journal of Ultrasound in Medicine*, 20(1), pp. 21-26.
- [10] U.S. Food and Drug Administration, 2018. Computed Tomography (CT). Available at:
<https://www.fda.gov/RadiationEmittingProducts/RadiationEmittingProductsandProcedures/MedicalImaging/MedicalX-Rays/ucm115317.htm#2>
- [11] Rose, P. & Morris, J., 2015. Cryosurgery/cryoablation in musculoskeletal neoplasms: history and state of the art. *Curr Rev Musculoskelet Med*, pp. 353-360.
- [12] Smith, K. & Carrino, J., 2008. MRI-Guided Interventions of the Musculoskeletal Sytem. *Journal of Magnetic Resonance Imaging*, 1 Feb, 27(2), pp. 339-346.
- [13] Wakefield, R. y otros, 2005. Musculoskeletal ultrasound including definitions for ultrasonographic pathology. *The Journal of Rheumatology*, 32(12), pp. 2485-2487.
- [14] Dodd, G. y otros, 1996. Sonography: the undiscovered jewel of interventional radiology. *Radiographics*, 16(6), pp. 1271-1288.
- [15] Rubens, D., Fultz, P., Gottlieb, R. & Rubin, S., 1997. Effective ultrasonographically guided intervention for diagnosis of musculoskeletal lesions.. *Journal of ultrasound in medicine*, 16(12), pp. 831-842
- [16] Naredo, E. y otros, 2008. Recommendations for the content and conduct of European League Against Rheumatism (EULAR) musculoskeletal ultrasound courses.. *Annals of the rheumatic diseases*, 67(7), pp. 1017-1022.
- [17] Wakefield, R. y otros, 2005. Musculoskeletal ultrasound including definitions for ultrasonographic pathology. *The Journal of Rheumatology*, 32(12), pp. 2485-2487.
- [18] Tzortziou, V. & Morrissey, D., 2008. Professional interventions for general practioners on the management of musculoskeletal conditions. *The Cochrane Library*.

- [19] Drakonaki EE1, Kho JS, Sharp RJ, Ostlere SJ. Efficacy of ultrasound-guided steroid injections for pain management of midfoot joint degenerative disease.
- [20] Fessell1, J. A. Jacobson1, J. Craig2, G. Habra2, A. Prasad2, A. Radliff2 and M. T. van Holsbeeck Using Sonography to Reveal and Aspirate Joint Effusions D. P.
- [21] Afshin Gangi M.D., Ph.D. Image-Guided Musculoskeletal Biopsies
- [22] Roberts CC1, Morrison WB, Leslie KO, Carrino JA, Lozevski JL, Liu PT. Assessment of bone biopsy needles for sample size, specimen quality and ease of use.
Department of Radiology, Mayo Clinic College of Medicine
- [23] Cecilia Ridaura-Sanz. Biopsia muscular Acta Pediatr Mex 2008;29(6):347-54
- [24] Emilio Salinero1, Ángel Esteban21 Servicio de Anatomía Patológica. 2 Servicio de Neurofisiología. Biopsia muscular percutánea con aspiración. Utilidad y ventajas sobre la biopsia quirúrgica
- [25] Hopkins, J., 2018. Joint Aspiration. Available at:
https://www.hopkinsmedicine.org/healthlibrary/test_procedures/orthopaedic/joint_aspiration_92,P07680
- [26] Sara Muñoz. Procedimientos intervencionales musculoesqueléticos Musculoskeletal interventional procedures . C.H.1 [https://doi.org/10.1016/S0716-8640\(13\)70134-2](https://doi.org/10.1016/S0716-8640(13)70134-2)
- [27] Berkoff DJ1, Miller LE, Block JE. Clinical utility of ultrasound guidance for intra-articular knee injections: a review.
- [28] Martel-Pelletier J, Boileau C, Pelletier JP, Roughley PJ. Cartilage in normal and osteoarthritis conditions. Best Pract Res Clin Rheumatol. 2008;22:351–384.
- [29] Ostergaard M, Halberg P. Intra-articular corticosteroids in arthritic disease: a guide to treatment. BioDrugs. 1998;9:95–103
- [30] Efficacy of ultrasound-guided steroid injections for pain management of midfoot joint degenerative disease. Drakonaki EE1, Kho JS, Sharp RJ, Ostlere SJ.

- [31] Rozental TD, Sculco TP. Intra-articular corticosteroids: an updated overview. *Am J Orthop (Belle Mead NJ)* 2000;29:18–23.
- [32] Brockmeier SF, Shaffer BS. Viscosupplementation therapy for osteoarthritis. *Sports Med Arthrosc.* 2006;14:155–162.
- [33] Balazs EA, Denlinger JL. Viscosupplementation: a new concept in the treatment of osteoarthritis. *J Rheumatol Suppl.* 1993;39:3–9.
- [34] Woodall J, Tucci M, Mishra A, Benghuzzi H. Cellular effects of platelet rich plasma: a study on HL-60 macrophage-like cells. *Biomed Sci Instrum.* 2007;43:266–271.
- [35] Drengk A, Zapf A, Stürmer EK, Stürmer KM, Frosch KH. Influence of platelet-rich plasma on chondrogenic differentiation and proliferation of chondrocytes and mesenchymal stem cells. *Cells Tissues Organs.* 2009;189:317–326.
- [36] Egemen Ayhan, Hayrettin Kesmezacar, and Isik Akgun. Intraarticular injections (corticosteroid, hyaluronic acid, platelet rich plasma) for the knee osteoarthritis
- [37] Wayne Yuk-wai Leea,b,c,* , Bin Wang Cartilage repair by mesenchymal stem cells: Clinical trial update and perspectives.
- [38] Alfredson H1, Lorentzon R. Sclerosing polidocanol injections of small vessels to treat the chronic painful tendon. *Cardiovasc Hematol Agents Med Chem.* 2007 Apr;5(2):97-100.
- [39] Miln, R., Zimmet, S., Isaacs, M. & Forrestal, M., 2001. Endovenous Laser Treatment of the Incompetent Greater Saphenous Vein. *Journal of Vascular and Interventional Radiology*, pp. 1167-1171.
- [40] O'Sullivan, P., 2005. Diagnosis and classification of chronic low back pain disorders: maladaptive movement and motor control impairments as underlying mechanism.. *Manual Therapy*, 10(4), pp. 242-255.

- [41] Taggart, A. y otros, 2005. Musculoskeletal ultrasound training in rheumatology: the Belfast experience. *Rheumatology*, 45(1), pp. 102-105.
- [42] Carlson, S. y otros, 2001. Benefits and safety of CT fluoroscopy in interventional radiologic procedures. *Radiology*, 219(2), pp. 515-520.
- [43] Guitierrez, M. y otros, 2015. International Consensus of ultrasound lesions in gout: results of Delphi process and web-reliability exercise.. *Rheumatology*, 54(10), pp. 1797-1802.
- [44] Silvestri, E. y otros, 2018. Interventional therapeutic procedures in the musculoskeletal system: an Italian Survey by the Italian College of Musculoskeletal Radiology. *La radiologia Medica*, 123(4), pp. 314-321.
- [45] Sartoris, R., Orlandi, D. & Corazza, A., 2017. In vivo feasibility of real-time MR-US fusion imaging lumbar facet joint injections.. *J Ultrasound*, Volumen 20, pp. 23-31
- [46] Barile, A., La Marra, A. & Arrigioni, F., 2016. Anaesthetics, steroids and platelet-rich plasma (PRP) in ultrasound-guided musculoskeletal procedures. *Br J Radiol*, Volumen 89, p. 20150355.
- [47] Fig 1. <http://jbstjournal.com/wp-content/uploads/2015/05/Featured2.jpg>
- [48] Fig 2. <https://radiologykey.com/wp-content/uploads/2016/09/RHABDOMYOLYSIS-FF1.gif>
- [49] Fig3.
https://posterng.netkey.at/esr/viewing/index.php?module=viewimage&task=&mediafile_id=676262&201605040310.gif
- [50] Fig 4. <http://www.acepnow.com/article/how-to-perform-ultrasound-guided-knee-arthrocentesis/?singlepage=1&theme=print-friendly>
- [51] Fig 5. *Semin Intervent Radiol*. 2010 Jun; 27(2): 191–198. doi: 10.1055/s-0030-1253517

- [52] Fig 6. <https://www.e-ultrasonography.org/m/journal/view.php?number=81>
- [53] Fig 7. Procedimientos intervencionales musculoesqueléticos Musculoskeletal interventional procedures .Sara MuñozC.H.1 [https://doi.org/10.1016/S0716-8640\(13\)70134-2](https://doi.org/10.1016/S0716-8640(13)70134-2)

Biography:

Jose Antonio Raillo Espinosa de los Monteros was born in Córdoba, Spain and moved at the age of four to Sevilla, capital of the andalusian province. He studied sciences in high school. At the age of eighteen he went to study a premedical course in McDaniels College, Budapest and started his medical degree in the student city of Pécs in the year 2011. After visiting Zagreb he decided to move to the Croatian capital and continue his studies there. During the year 2016 he also started a business in the medic-aesthetic field, which has to combine with his studies.

His hobbies included travelling, playing pool and good food among others.