

# Primary spontaneous pneumothorax: diagnosis, complication, treatment

---

**Daulatzai, Mirwais**

**Master's thesis / Diplomski rad**

**2019**

*Degree Grantor / Ustanova koja je dodijelila akademski / stručni stupanj:* **University of Zagreb, School of Medicine / Sveučilište u Zagrebu, Medicinski fakultet**

*Permanent link / Trajna poveznica:* <https://um.nsk.hr/um:nbn:hr:105:676152>

*Rights / Prava:* [In copyright](#) / [Zaštićeno autorskim pravom.](#)

*Download date / Datum preuzimanja:* **2024-07-17**



*Repository / Repozitorij:*

[Dr Med - University of Zagreb School of Medicine Digital Repository](#)



UNIVERSITY OF ZAGREB  
SCHOOL OF MEDICINE

**Mirwais Daulatzai**

**Primary spontaneous pneumothorax:  
diagnosis,  
complication, treatment**

**GRADUATE THESIS**



**Zagreb, 2019.**

This graduate thesis was made at the Department of Internal Medicine, University Hospital Centre Sisters of Charity, Zagreb, Croatia, mentored by Professor Vesna Degoricija, MD, PhD and was submitted for evaluation in the academic year of 2018/2019.

**ABBREVIATIONS:**

PSP: Primary spontaneous pneumothorax

BTS: British Thoracic Society

NA: Needle Aspiration

VATS : Video-assisted Thoracoscopic Surgery

PACS: Picture Archiving and Communication System

ACCP: American college of chest physicians

US: Ultrasound

eFAST: Focused assessment with sonography in trauma

## **Contents**

<b>Abstract</b> .....	<b>1</b>
<b>Sažetak</b> .....	<b>2</b>
<b>History</b> .....	<b>3</b>
<b>Anatomy</b> .....	<b>3</b>
Pleura .....	4
<b>PRIMARY SPONTANEOUS PNEUMOTHORAX</b> .....	<b>4</b>
Bleb .....	5
Bulla/bullae .....	6
<b>PRIMARY SPONTANEOUS PNEUMOTHORAX: DIAGNOSIS</b> .....	<b>7</b>
Standard erect PA chest x-ray.....	7
Ultrasound scanning (US).....	9
Digital imaging .....	10
CT scanning .....	10
<b>PRIMARY SPONTANEOUS PNEUMOTHORAX: COMPLICATIONS</b> ....	<b>11</b>
<b>PRIMARY SPONTANEOUS PNEUMOTHORAX: TREATMENT</b> .....	<b>13</b>
Chemical Pleurodesis .....	16
Video-assisted Thoracoscopic Surgery (VATS) .....	17
<b>Acknowledgment</b> .....	<b>19</b>
<b>REFERENCES:</b> .....	<b>20</b>

# **Abstract**

**Title: Primary Spontaneous Pneumothorax: Diagnosis, Complication, Treatment**

**Author: Mirwais Daulatzai**

Today, the etiology of primary spontaneous pneumothorax (PSP) in the most cases can be identified which has led to its better understanding and management. It is mainly caused by the rupture of a small subpleural emphysematous vesicle (designated a bleb) or of a subpleural paraseptal emphysematous lesion (designated a bulla). The most effective diagnostic procedure amongst numerous imaging modalities is the ultrasound using Daniel Lichtenstein's method. This imaging technique is the gold standard for clinicians to detect pneumothorax. Complications associated with PSP are low with first-time diagnosis and it includes prolong air leakage (7% to 14%) with conservative treatment. However, there are procedural and non-procedural complications and all of which can lead to recurrent form of pneumothorax. The treatment options depend on various factors including patients' current health status, age, type and size of the pneumothorax on CT scan, complications, severity of symptoms and indicators of acute illness. Treatment of PSP range from conservative to immediate needle decompression or insertion of a chest tube. Latest modalities of treatment of PSP include the use of video-assisted thoracoscopic surgery (VATS) and in some cases chemical pleurodesis.

**Key words:**

Pneumothorax, pleural cavity, treatment, Complications, CTS, CXR, chest tube drainage, video-assisted thoracoscopic surgery

# Sažetak

**Mirwais Daulatzai**

**Naslov: Primarni spontani pneumotoraks: Dijagnoza, komplikacije, liječenje**

Danas se etiologija primarnog spontanog pneumotoraksa (PSP) u većini slučajeva može otkriti što je dovelo do boljeg shvaćanja i zbrinjavanja ovog oblika pneumotoraksa. Najčešće je uzrokovan rupturom malog subpleuralnog emfizematoznog mjehurića (tzv. bleba) ili subpleuralne paraseptalne emfizematske lezije (tzv. *bullae*). Najučinkovitija dijagnostička pretraga među brojnim radiološkim modalitetima je ultrazvuk, korištenjem Daniel Lichtensteinove metode. Ova radiološka metoda predstavlja „zlatni standard“ i metodu izbora kojom liječnici mogu otkriti pneumotoraks. Komplikacije povezane s PSP-om su rijetke s prvom epizodom i uključuju produljeno curenje zraka (7 do 14%) s konzervativnim liječenjem. Međutim, postoje proceduralne i neproceduralne komplikacije koje sve mogu dovesti do recidivirajućeg pneumotoraksa. Metode liječenja ovise o mnogo čimbenika, uključujući trenutno pacijentovo zdravstveno stanje, dob, tip i veličinu pneumotoraksa na CT-u, ozbiljnost simptoma te pokazatelje akutne bolesti. Metode zbrinjavanja sežu od konzervativnog liječenja do hitne dekompresije iglom ili uvođenja torakalnog drena. Najnovije metode liječenja PSP-a uključuju uporabu video-asistirane torakoskopske kirurgije (VATS) i u nekim slučajevima kemijsku pleurodezu.

## **Ključne riječi:**

Pneumotoraks, pleuralni prostor, liječenje, komplikacije, CTS, RTG, torakalni dren, video-asistirana torakoskopska kirurgija

## **History**

Primary spontaneous pneumothorax (PSP) is a common disease that affects million around the world. Air leaking into the pleural cavity was first described by Itard in 1803 and then followed by Laennec in 1819. 'Pneumothorax simple' was a medical term given to patients without any detrimental health; however, at that time, tuberculosis-based pneumothorax was rife and it was described as the secondary form (1). In 1947, Miller explained the pathogenesis of PSP. Miller established anatomical differentiation between a bleb and a bullous emphysema (2). In 1967, Reid divided bullous emphysema into three different types. In type 1, a small amount of lung tissue that is hyperinflated and pedunculated but do not contain lung parenchyma. In type 2, a small amount of lung tissue that is sessile and contains vanishing lung parenchyma. Lastly, in type 3, a relatively large of amount of hyperinflated lung tissue found in the pulmonary hilum with irregular margins and vanishing lung parenchyma (2).

## **Anatomy**

Humans have a pair of lungs, situated in the thoracic cavity and each positioned on either side of the mediastinum. The lungs are protected and enclosed inside sheath of pleural membrane - a sheath of serous membrane. The external surface of the lungs is shaped in accordance to the internal shape of the thoracic cavity. Inferiorly, the base (diaphragmatic surface) of the lungs are conformed by the diaphragm creating concave surface. Laterally and superiorly, the thoracic wall conforms its shape and whilst medially (mediastinal surface), structures of the mediastinum conforms its medial shape. The costal surface of lungs is shaped convex resting on the ribs. The hilum of the lungs can be found on the medial surface of the lungs which has the entry point to the lungs for several structures, i.e., a collection of vessels and bronchi. These structures connect the lungs to the necessary surrounding internal organs. The mediastinal surface of the lungs are indented by the external shape of the heart leaving cardiac impression on them. Moreover, other impressions are caused by the azygos vein, right subclavian artery and esophagus. However, several grooves are imprinted particularly on the left lung from aortic arch, left subclavian artery and thoracic artery (3).



## **Lung lobes and fissures**

Both lungs are divided into lobes implemented by deep fissures. Two lobes form the left lung - superior and inferior portions. Whilst the right lung is divided into superior, middle and inferior lobes. The superior and inferior lobes of the right lung are divided by the oblique fissure, running diagonally from posterosuperior to anteroinferior. The horizontal fissure divides the superior lobe from middle. An oblique fissure divides the left lung into two lobes (3).

## **Pleura**

The serous membrane which covers and surrounds the lungs and thoracic cavity in a continuous fashion meet at the hilum of the lungs. For each lung, the membrane is divided into two parts; the parietal pleura is bound to the peripheral wall of the thoracic cavity, whilst the visceral pleural covers the external surface of each lung tightly. A pleural cavity is formed between these two layers which contain serous fluid needed for smooth gliding of the expanding lungs during respiration thereby reducing friction activity (3).

## **PRIMARY SPONTANEOUS PNEUMOTHORAX**

Primary spontaneous pneumothorax (PSP) is defined as a pneumothorax without obvious underlying lung disease, most commonly occurring in young, tall, lean males. It is a collection of air in pleural spaces. Air can escape into the pleural spaces due to rupture of pathological blebs and bullae. Sudden onset of sharp, unilateral chest pain and dyspnea are the predominant clinical features during the onset. Moreover, attenuated breathing sound and hyperresonant sound by percussion can be heard. Although it is rare with PSP, in some instances a one-way valve can form near the subpleural lesion. This valve allows air to pass from the lungs into the chest cavity and thereafter causing tension pneumothorax by shifting and compressing the major vessels in the surround area, which can have a fatal outcome. During PSP, hypoxemia is observed in

patient in the form of cyanosis and hypercapnia is sometimes encountered with confusion (4)(5).

PSP is a significant global health problem, with a reported incidence of 18-28/100 000 cases per annum for men and 1.2-6/100 000 for women (5). Smoking directly increases the risk of contracting a first spontaneous pneumothorax among men and women by 22% and 9% respectively. Furthermore, those who smoke more than 10 cigarettes a day have 20-fold rise in risk for PSP over comparable non-smokers. Smoking a pack of cigarettes, a day increases the risk by 100-fold demonstrating greater-than-linear effect (6). Unfortunately, it is estimated that around 80-86% of young individuals continue to smoke after their first occurrence of PSP despite the apparent evidence between smoking and pneumothorax. The risk of recurrence of PSP is as high as 54% within the first 4 years, with isolated risk factors including smoking, tall stature. There is no evidence that physical activity causes the rupture of bullae or blebs leading to PSP, although it can be counterintuitive. The onset of PSP can occur equally during sedentary lifestyle (4)(5).

With regard to the etiology of PSP, anatomical abnormalities are commonly demonstrated at the apex of the lung. The gradient of negative pleural pressure rises towards the apex, especially in tall, slimmer individuals. Therefore, the alveoli at the apices of the lungs have greater distending pressure than the alveoli at the base. Emphysema-like changes, including subpleural blebs and bullae were found in 50-90% of PSP patients on high resolution computed tomography (CT) scanning and in 76-100% of PSP patients during video-assisted thoracoscopic surgery (VATS) or thoracotomy. Recently, pleural porosities have been shown around the lesions with autofluorescence studies, which are usually invisible with white light.

### **Bleb**

A bleb (subpleural emphysematous vesicle) is caused by alveolar rupturing and disintegration. Inspired air travel through the interlobular septum that divides the secondary pulmonary lobules to the subpleural region. This subpleural region is displaced and emphysematous vesicle is thus formed. Chest CT scans normally shows thin-walled cystic air space that are contiguous with the

surrounding pleura. Unlike a bulla, which is a distal acinar emphysematous lung lesion, a bleb is usually 1-2cm long in diameter. Imperatively, radiologists discourage other physicians from classifying the distinction between a bleb and a bulla due to the fact that there is little clinical importance (7)(8).

### **Bulla/bullae**

A bulla (subpleural emphysematous bulla) is an airspace usually several centimeters in diameter. They are sharply demarcated by a thin wall, which are smooth, rounded and fragile to rupture. On chest CT, subpleural emphysematous bulla appear as a focal lucency occurring predominantly in the lung apices. It is known that cigarette smoking destroys lung parenchyma and therefore allows multiple bullae to coalesce and show signs of pulmonary emphysema. However, if the distension of an emphysematous bulla continues to grow over time it can lead to the extreme thinning of the wall. This thinning of the pleural structure is evident in type I bullae and in some areas of type II bullae. Moreover, histological examination has shown the absence of pleural mesothelial cells. Therefore, it can be concluded that there is a clear correlation between the reduction in mesothelial cells and the distension of emphysematous bullae leading to a reduction in the surface tension of their walls (7)(8), which can be explained by Laplace’s law.

Table 1: List of common findings during surgical exploration.

1	Scarring of the lung in the apical region. Possibly caused by bronchioloalveolar fistula with fibrotic tissue surrounding the lesion.
2	Single or multiple blebs smaller (<2cm diameter)
3	Single or multiple bullae (>2cm diameter)
4	A giant bulla in one or more lung lobes
5	Bilaterally multiple bullae
6	Lobar emphysema
7	multiloculated membranous chronic pneumothorax that can affect most of the pleural cavity
8	Spontaneous hemopneumothorax during lung collapse due to rupture of cord-shaped vascularized pleuropulmonary adhesions
Adapted from Lyra RDM. Etiology of primary spontaneous pneumothorax. Jornal Brasileiro de Pneumologia. 2016.	

# PRIMARY SPONTANEOUS PNEUMOTHORAX: DIAGNOSIS

Clinically it is imperative for physicians to recognize pneumothorax immediately rather than distinguishing between a bleb or bulla according to radiologist. The diagnosis of PSP is usually recognized and confirmed by imaging techniques. Additionally, clinicians can also gain information about the size of the pneumothorax and therefore clinical evaluation should be the main management strategy. Table 2 below shows the various methods that can be used to asses for PSP. However, majority of the imaging modalities are not in practice. CT scanning has paved the way forward taking over the traditional standard erect PA chest x-ray.

Table 2: Various imaging modalities have been employed for the diagnosis and management of pneumothorax.

<b>1</b>	Standard erect PA chest x-ray
<b>2</b>	Lateral x-rays
<b>3</b>	Expiratory films
<b>4</b>	Supine and lateral decubitus x-rays
<b>5</b>	Ultrasound scanning
<b>6</b>	Digital imaging
<b>7</b>	CT scanning

## Standard erect PA chest x-ray

Primary spontaneous pneumothorax can be diagnosed with standard erect chest x-ray. It has been the mainstay diagnostic procedure and clinical management for many years, although CXR has limitations such as the difficulty in accurately quantifying pneumothorax size. It tends to underestimate the size of the PSP because CXR a two-dimensional image while the pleural cavity is a three-dimensional structure. Inspiratory x-ray are valued more than expiratory x-rays, whereas expiratory x-rays are used for follow-up. Supine and lateral decubitus x-rays are usually employed for trauma patients due to the fact that they cannot be moved. However, in the last decade there has been major technological advances that has resulted in the advent of digital chest imaging. The conventional chest films are rarely in clinical practice in the modern healthcare systems. The diagnostic characteristics are displacement of the pleural line in reflection to the surrounding borders. In the costophrenic angle, air-fluid level is visible in 50% of cases. Unfortunately for standard CXR this is occasionally the only apparent abnormality.

Lateral x-rays may provide additional information, however, likewise it is no longer routinely used in everyday clinical practice. If there are any suspicion for PSP it is absolutely vital for the patient that CT scan of chest is followed through (9).

Table 3: Table of calculated pneumothorax sizes using Rhea and Collins' formula.

Sum of interpleural distances (cm)	Estimated % pneumothorax	Sum of interpleural distances (cm)	Estimated % pneumothorax
1	8.9	9	46.5
2	13.6	10	51.2
3	18.3	11	55.9
4	23	12	60.6
5	27.7	13	65.3
6	32.4	14	70
7	37.1	15	74.7
8	41.8	16	79.4

Adapted from Anne-Maree Kelly et al., Comparison between two methods for estimating pneumothorax size from chest X-rays. *Respiratory Medicine*. 2006.

$$\left( \frac{V_{\text{hemithorax}} - V_{\text{lung}}}{V_{\text{hemithorax}}} \right) \times 100.$$

Fig 1: Rhea and Collins' formula for calculating the percentage of pneumothoraces. Adapted from Anne-Maree Kelly et al., Comparison between two methods for estimating pneumothorax size from chest X-rays. *Respiratory Medicine*. 2006.

According to a study (10) published in 2005, a group pulmonologist tested the formula (figure 1) to justify how accurate were the results. They compared the estimated size of spontaneous pneumothoraces using the established Rhea inter-pleural distances method with the CT-derived Collins method. They concluded that the Rhea method for estimating pneumothorax size is acceptably accurate for smaller pneumothoraces but may significantly under-estimate the size of larger pneumothoraces. Table 3 above shows gross percentage results of pneumothoraces according to the formula.

## **Ultrasound scanning (US)**

During a traumatic incident, a patient cannot be mobile and thus specific features on ultrasound scanning are difficult to diagnose during PSP. previously, it was agreed that air was a strong reflector for US waves which have the same acoustic properties as water. therefore, US waves reflect from the lung surface making it difficult to investigate the structure of lung parenchyma using this image modality. this was the sole reason for the negligence of US in the lung field.

Today, in emergency care medicine, US has a major role to play in diagnosis of various conditions alongside PSP. The medical and scientific work by Daniel Lichtenstein proved that US, in fact, has to be the initial diagnostic procedure in PSP. The concept of lung US is based on artifacts gathered from parietal or visceral pleural lines. The way it works is very simple in theory but practically it requires practice to familiarise oneself. If the lungs are ventilated, lung sliding signs can be visualised during the movements of the lungs during breathing whilst the US probe is placed in the intercostal space. Due to the reverberation of the US between the pleural line and US probe, imperfect mirror images of thoracic wall are generated and shown on the screen. During the exploration, physicians search for sea-shore sign generated in M mode. The pleural line, called A lines, which are separated by same distance as the width of the thoracic wall. During PSP, a collection of air in pleural spaces is found abnormally. Air escape into the pleural spaces due to rupture of pathological blebs and bullae. Ultrasound waves are reflected by the surface of the free air under the parietal pleura, so no waves reach the lung surface. Thus lung sliding sign cannot be demonstrated (27) (28).

The sensitivity of US is almost 100% in PSP, demonstrated as more sensitive than CXR. US is robust, compact and portable giving it the advantage of point-of-care method suitable in- or out-of-hospital assesment of traumatised victims, as well as a first screening method to detect PSP emergency department. Physicians in the emergency ward are educated to perform Focused assessment with sonography in trauma (Efast) with the aim to find free fluid and Pneumothorax in these patients .

## **Digital imaging**

In the last decade, conventional film-based chest x-rays have been replaced with digital radiography, especially in the developed countries. There are considerable amount of advantages, i.e., magnification, measurement and contrast manipulation, building digital archive and reproduction. For clinical researchers, digital archive empowers further advantages in conducting future reviews and research. Needless to say, there are few disadvantages to digital imaging, i.e., screen size, pixel count, contrast and luminescence may not be of highest quality and thus there is decline in diagnostic sensitivity.

## **CT scanning**

This imaging technique used to be the gold standard in the diagnostic procedures of PSP. CT imaging allows clinicians to detect pneumothoraces and evaluate their sizes. It can also be essential in the presence of surgical emphysema, bullous lung pathology, identifying aberrant chest drain placement or other lung abnormalities. However, practical limitations makes it difficult for its general use as the initial diagnostic modality. It is important to notice that the size of the PSP does not reflect well with the clinical manifestations (11). Thus, the clinical evaluation far outweighs the size of the PSP in the management strategy. Guidelines from the 2003 British Thoracic Society recommended a more accurate manner of size measurement than its previous outdated guidelines in 1993, using the cube function of two simple measurements; and by volume a 2cm radiographic PSP approximates to 50% pneumothorax. the issue with this approach is that some some pneumothoraces are localized (rather than uniform), so that measurement ratios cannot be applied (11).

In reality, the shape of the collapsed lung(s) cannot be assumed to remain constant. Using the new PACS system, the measurement of the ratio of the lung to the hemithorax diameter is relatively precise and easy. Once physicians are familiar with PACS auxiliary functions, they can use a cursor and apply measurements. The choice of a 2cm depth is a compromise between the theoretical risk of needle trauma with a shallower pneumothorax and the significant volume and length of time to spontaneous resolution of a greater depth of pneumothorax. Assuming a

symmetrical pattern of lung collapse, then this measure is normally taken from the chest wall to the outer edge of the lung at the level of the hilum. Guidelines from the USA estimated the volume of a pneumothorax by measuring the distance from the lung apex to the cupola. However, this method tends to overestimate the volume in a localised apical pneumothorax (12).

## **PRIMARY SPONTANEOUS PNEUMOTHORAX: COMPLICATIONS**

There are many complications associated with PSP, some of which are more significant than others. However, prolonged air leakage as well as recurrent forms of pneumothorax continue to be problematic. Moreover, choosing the right therapy can be challenging since there are various approaches. A single dominant algorithm does not exist across the developed countries. Many factors affect the outcome of any therapy and therefore complications could arise inevitably. Nevertheless, complications of PSP can be categorized into procedural, non-procedural and technical. Firstly, procedural complications included penetration to the internal vital organs such as the lungs, heart and its important surrounding vessels, blood-filled spleen and liver and stomach. On the other hand, non-procedural complications included empyema directly resulting from pleural infection and emphysema due to surgical mishap. The final category of complications of PSP is technical. During treatment of PSP, drainage tubes can be malpositioned, kinked or clamped resulting in inadequate desired outcome (13). Fortunately, procedural complications are rare, for example, negative pressure suction applied on the drainage system causing possible re-expansion lung edema is seen in only 5% of the cases (13)(14).

Needless to say, a patient with cystic fibrosis would be more prone to complications than an ordinary patient without any pulmonary or any other diseases. For example, a patient with cystic fibrosis has higher complications with chemical pleurodesis. Cystic changes in lungs would cause the introduction of blood in an otherwise sterile cavity leading to an increased risk of infections (14).



Prolonged air leakage is the most common complication, range from 7% to 14%, following thoracoscopic treatment for PSP, and the optimal management is rarely mentioned. Recently, a study reported that chemical pleurodesis using minocycline were effective to cease air leakage for patients of PSP with prolonged air leakage after thoracoscopic surgery. Moreover, pleurodesis approach has a high success rate if the patients have shorter duration of post pleurodesis chest drainage and postoperative hospital stay. This success rate has been well documented in comparisons to those undergoing minocycline pleurodesis. VATS alone was associated with significant reduction of complications compared with almost others procedures treated patients with recurrent or persistent PSP (15).

# PRIMARY SPONTANEOUS PNEUMOTHORAX: TREATMENT

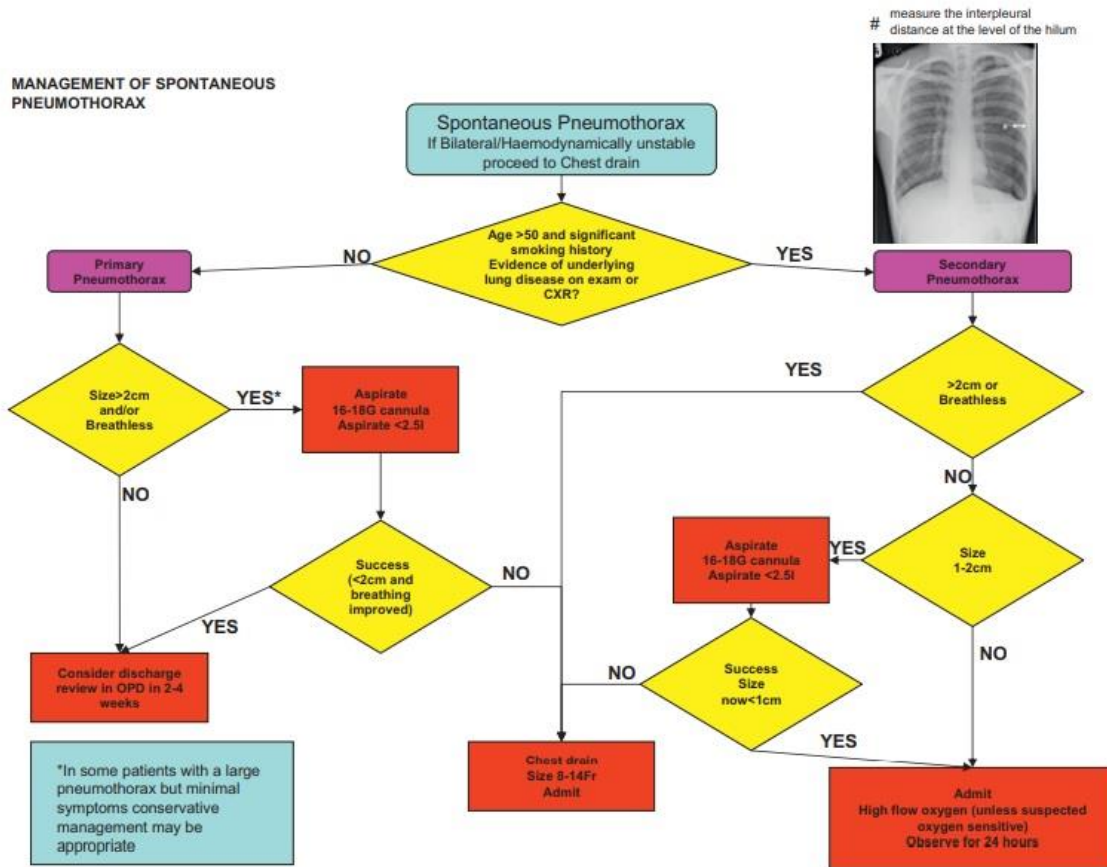


Fig. 2 Flow chart for the management of spontaneous pneumothorax. Adapted from Macduff A, et al., Management of spontaneous pneumothorax: British Thoracic Society pleural disease guideline 2010.

Primary spontaneous pneumothorax occurs in patients without any significant underlying lung disease. Although histological abnormalities are present with individuals who smoke cigarettes, they have not been manifested by symptoms or loss of function. A universally acceptable flow chart (figure 2) in the management of PSP is produced by the British Thoracic Society. However, it is not necessarily being adapted into different hospitals across the developing countries. PSP is a condition that has many factors influencing patients' outcome. Factors that are important in the decision-making process are the presence of significant breathlessness and the size of the pneumothorax.

The rate at which PSP resolution/reabsorption is between 1.25% and 2.2% of the volume of the hemithorax every 24 h, estimated from CT volumetry. A complete PSP might be expected to take up to 6 weeks to resolve spontaneously and, conceivably. But in the presence of a persistent air leak it can take longer. PSP with minimal signs and symptoms with small pneumothoraces has been shown to be safe, and can be managed in the outpatient clinical setting providing they seek medical attention if symptoms worsen. From 80% of pneumothoraces estimated, 15% have no persistent air leak (4)(5)(16).

There is no evidence that prescribing analgesia would improve the associated pain. However, appropriate analgesia is recommended. If a patient is hospitalized for observation, supplemental high flow oxygen should be given where feasible. Needless to say, those patients with symptomatic PSP require treatment immediately because observation alone is inadequate for hypoxic breathless patients who require active intervention. In this acute phase, physicians should starting with needle aspiration or chest drain insertion without delay (5)(18).

For every clinician, it is imperative to realize that breathlessness in a patient with a small PSP may lead to tension pneumothorax, which can have a fatal outcome if not treated promptly. Supplemental high flow oxygen corrects the arterial hypoxemia and it has a fourfold rise in the rate of PSP resolution. Occasionally, there is continuous air leak which is due to the fact that there is a reduction of partial pressure of nitrogen in the pleural space relative to oxygen, which is more readily absorbed. Also, a similar effect in the pleural capillaries creates a more favorable resorption gradient (17).

Once conservative treatment has failed or if the PSP is large (>50%) or if PSP is associated with breathlessness, then some guidelines recommend either needle aspiration (NA) or the insertion of a chest tube. Local anesthetic is used before inserting a three-way tap allowing the removal of air trapped in the pleural cavity. If successful, the remainder of the treatment can be conservative thereafter with hospital discharge. According to a study (18) a successful aspiration would be a significant reduction in the size of the pneumothorax on a subsequent CXR. This form of traditional treatment has shown more 50% success rate. In comparison to tube drainage, NA has

been superior form of first-line of treatment. It reduces the number of people requiring hospital stay and without increasing the risk of complications. However, recently seldinger chest drains (catheter) have entered widespread. A randomized controlled trial in a Kuwaiti population has confirmed equivalence between NA and chest tube drain, also a reduction in hospital admission and length of stay compared to NA (19). If aspiration is the chosen form of treatment, then up to 2.5 liters of can be aspirated. However, further re-expansion being unlikely because of the likely presence of a persistent air leak.

There are guidelines that encourage insertion of small-bore (<14 F) Seldinger chest drains and may be regarded as a simpler option to NA. Small-bore chest drains have been shown to have a similar success rate to larger drains while being less painful (20)(21). The choice of initial intervention for PSP should take into account operator experience and patient choice; NA is less painful than chest drain insertion (22) but failure in approximately one-third of patients will require a second procedure.

Table 4: Therapeutic options in cases of primary spontaneous pneumothorax, from conservative treatment to more invasive therapies.

Conservative	Intermediate	Invasive
Observation	Pleurodesis	Pleurectomy
Conservative treatment	Cauterisation	Bullectomy
Aspiration	Pleural abrasion	VATS
Tube drainage		Thoracotomy
Medical thoracoscopy		

VATS: video-assisted thoracoscopic surgery.

Adapted from Macduff A, Management of spontaneous pneumothorax: British Thoracic Society pleural disease guideline 2010. Thorax. 2010.

### Chemical Pleurodesis

If the NA or insertion of small-bore (<14 F) Seldinger chest drains do not eradicate PSP, chemical pleurodesis procedure is taken into consideration (23). Pleurodesis is a procedure that eliminates the pleural space and by attaching the lung to the chest cavity. The first objective is to resect any visible bullae or blebs on the visceral pleura and also to obliterate emphysema-like changes or pleural porosities under the surface of the visceral pleura. The second objective is to create a symphysis between the two opposing pleural surfaces as an additional means of preventing recurrence (23) (24).

Using thoracotomy procedure, a surgeon identifies any source of air leakage and stapling the unwanted blebs and bullae followed by pleurectomy. Upon stapling the lesions, the surgeon would then strip off the pleural lining of the outer plural layer and cause pleural abrasion of inner layer, which would allow the lung to adhere to the chest wall. Lastly, during the healing process the physician would pay attention to whether the pleural space has been successfully obliterated. Post-thoracotomy pain is common and administration of analgesia would be recommended. The recurrence rate is approximately 1% according to several studies. An experienced surgeon dealing with pneumothorax would sometimes chose either pleurectomy or pleural abrasion solely though there may be slight advantages of pleurectomy over pleural abrasion. However, a

combination of the two is often used. Unfortunately, there is a paucity of good comparative case-controlled studies in this area. In recent years, less invasive procedures using VATS have become more popular with lower morbidity although with slightly higher recurrence rates (25) (26).

### **Video-assisted Thoracoscopic Surgery (VATS)**

During the early parts of 1990s, video-assisted-thoracoscopic surgery (VATS) has replaced the traditional thoracotomy. Perhaps there were many advantages; both for the patients and the physicians. The implementation of endoscopic tools and instruments into the surgical field was not easy at first, but as soon as physicians practiced using the levers it became easier. This radical change – adaptation of endoscopy, improvement and implementation of video cameras paved the way forward in the general surgical field. The advantages for using VATS were that it was less invasive, had rapid recovery time for the patient and less hospital stay, minimum loss of blood and much more. Imperatively, in contrast with invasive thoracoscopy, VATS retained all the diagnostic and therapeutic potentials. Instead of a large incision and opening of the chest cavity, VATS allows the surgeons to carry out the intrathoracic procedures. Using VATS, the endoscopic staplers resect apical lesions easily and comfortably depending on surgeons VATS expertise. Once the lesions are stapled, the surgeon wanders around in the near vicinity of the lung to find any abnormal lesions that was undetected at first using the miniature camera.

Thoracotomy is seldom used at present, whilst most reports demonstrate the use of VAT in the treatment of PSP since the 1990s. Needless to say, open procedures have been reserved for particular occasions if not abandoned completely. Recently, a survey illustrated that members of the ACCP (American college of chest physicians) preferred VATS diagnostic and treatment approach to intrathoracic lesions (subpleural emphysematous vesicle and subpleural paraseptal emphysematous lesion) compared thoracotomy in the treatment of PSP (26).

However, the latest British Thoracic Society (BTS) guidelines consider invasive thoracotomy and pleurectomy as the procedures of choice, as they show the lowest recurrence rate. The BTS considers VATS procedure as an alternative strategy due to the lack of large controlled clinical trials. Although the recurrence rate is slightly higher in VATS compared to thoracoscopy, VATS

produces smaller scars in the skin, offer shorter in-hospital stay, far less analgesic requirement for postoperative pain control, and reduce risk of lung problems after surgery. Using insufflation of talc, VATS can also offer and achieve chemical pleurodesis. Talc activates an inflammatory reaction that causes the adherence of the two surfaces and obliterate the pleural surface (18).

## **Acknowledgment**

I would like to acknowledge my mentor Professor Vesna Degoricija, MD, PhD from the Department of Internal Medicine, University Hospital Centre Sisters of Charity, Zagreb, Croatia, for mentoring me on this thesis. I am gratefully indebted for her support, valuable comments, corrections and feedback on this thesis.

I would also like to express my very profound gratitude to my parents, family and friends for providing me with unfailing support and continuous encouragement throughout the years of medical studies. This accomplishment would not have been possible without them.



## REFERENCES:

1. Laennec RTH. Traite´ du diagnostic des maladies des poumons et du coeur. Tome Second, Paris: Brosson and Chaude´, 1819. (4)
2. Miller WS. The Pleura. In: Miller WS, editor. The Lung. 2nd ed. Springfield, IL: Charles C. Thomas; 1947. p.145-58
3. Kahle W, Platzer W, Fritsch H, Kühnel Wolfgang, Frotscher M. Color atlas of human anatomy. Stuttgart: Thieme; 2015.
4. Bobbio A, Dechartres A, Bouam S, Damotte D, Rabbat A, Regnard J-F, et al. Epidemiology of spontaneous pneumothorax: gender-related differences. *Thorax*. 2015;70(7):653–8.
5. Macduff A, Arnold A, Harvey J. Management of spontaneous pneumothorax: British Thoracic Society pleural disease guideline 2010. *Thorax*. 2010;65(Suppl 2):ii18–ii31.
6. Grippi MA. Fishmans pulmonary diseases and disorders. New York: McGraw-Hill Education; 2015.
7. Lyra RDM. Etiology of primary spontaneous pneumothorax. *Jornal Brasileiro de Pneumologia*. 2016;42(3):222–6.
8. Ohata M, Suzuki H. Pathogenesis of Spontaneous Pneumothorax. *Chest*. 1980;77(6):771–6.
9. Glazer HS, Anderson DJ, Wilson BS, Molina PL, Sagel SS. Pneumothorax: appearance on lateral chest radiographs. *Radiology*. 1989;173(3):707–11.
10. Kelly A-M, Weldon D, Tsang AY, Graham CA. Comparison between two methods for estimating pneumothorax size from chest X-rays. *Respiratory Medicine*. 2006;100(8):1356–9.

11. Henry M. BTS guidelines for the management of spontaneous pneumothorax. *Thorax*. 2003;58(90002):39ii–52.
12. Simple aspiration versus intercostal tube drainage for primary spontaneous Baumann MH, Strange C, Heffner JE, et al. Management of spontaneous pneumothorax. An American College of Chest Physicians Delphi Consensus statement. *Chest* 2001;119:590e602. (1L).
13. Ransdell HT. Management of Spontaneous Pneumothorax. *Archives of Surgery*. 1963;87(6):1023.
14. Walker S, White P, Maskell N. Recurrence rates in primary spontaneous pneumothorax: results of systematic review. *Pleural and Mediastinal Malignancies*. 2018;
15. Wait MA, Nogare ARD. Treatment of AIDS-Related Spontaneous Pneumothorax. *Chest*. 1994;106(3):693–6.
16. Macduff A, Arnold A, Harvey J. Management of spontaneous pneumothorax: British Thoracic Society pleural disease guideline 2010. *Thorax*. 2010;65(Suppl 2):ii18–ii31.
17. Maslanka AM. Civilian spontaneous pneumothorax: Treatment options and long-term results. *The Journal of Emergency Medicine*. 1990;8(6):798.
18. Ray P. Faculty of 1000 evaluation for Aspiration versus tube drainage in primary spontaneous pneumothorax: a randomised study. F1000 - Post-publication peer review of the biomedical literature. 2006;
19. Clementsen P, Evald T, Grode G, Hansen M, Jacobsen G, Faurschou P. Treatment of malignant pleural effusion: pleurodesis using a small percutaneous catheter. A prospective randomized study. *Respiratory Medicine*. 1998;92(3):593–6.
20. Akowuah E, Ho EC, George R, Brennan K, Tennant S, Braidley P, et al. Less pain with flexible fluted silicone chest drains than with conventional rigid chest tubes after cardiac surgery. *The Journal of Thoracic and Cardiovascular Surgery*. 2002;124(5):1027–8.

21. Carson-Chahhoud KV, Wakai A, Agteren JEV, Smith BJ, McCabe G, Brinn MP, et al. Simple aspiration versus intercostal tube drainage for primary spontaneous pneumothorax in adults. *Cochrane Database of Systematic Reviews*. 2017;
22. Lewis K. Efficacy and Complications of Small-Bore, Wire-Guided Chest Drains. *Yearbook of Pulmonary Disease*. 2008;2008:168–70.
23. Funaki B. Pneumothorax Treated by Small-Bore Chest Tube. *Seminars in Interventional Radiology*. 2007;24(2):272–6
24. Brande PVD, Staelens I. Chemical Pleurodesis in Primary Spontaneous Pneumothorax. *The Thoracic and Cardiovascular Surgeon*. 1989;37(03):180–2.
25. Torre M, Grassi M, Nerli FP, et al. Nd-Yag laser pleurodesis via thoracoscopy. *Chest* 1994;106:338e41. (3).
26. Funaki B. Pneumothorax treated by small-bore chest tube. *Semin Intervent Radiol* 2007;24:272e6.
27. Lichtenstein DA, Menu Y. A bedside ultrasound sign ruling out pneumothorax in the critically ill. Lung sliding. *Chest*. 1995; 108(5): 1345-8
28. Lichtenstein DA. Ultrasound in the management of the thoracic disease. *Crit Care Med*. 2007;35(5. Suppl):S250-61.