

Mixed Type Haemangioma of the Inferior Turbinate: A Rare Cause of Epistaxis

Penezić, Ana; Čupić, Hrvoje; Baudoin, Tomislav

Source / Izvornik: *Indian Journal of Otolaryngology and Head & Neck Surgery*, 2016, 71, 1695 - 1698

Journal article, Published version

Rad u časopisu, Objavljena verzija rada (izdavačev PDF)

<https://doi.org/10.1007/s12070-016-0975-3>

Permanent link / Trajna poveznica: <https://urn.nsk.hr/urn:nbn:hr:105:914863>

Rights / Prava: [In copyright](#)

Download date / Datum preuzimanja: **2022-07-07**



Repository / Repozitorij:

[Dr Med - University of Zagreb School of Medicine
Digital Repository](#)



Mixed Type Haemangioma of the Inferior Turbinate: A Rare Cause of Epistaxis

Ana Penezić¹ · Hrvoje Čupić² · Tomislav Baudoin¹

Received: 23 March 2015 / Accepted: 16 March 2016 / Published online: 29 March 2016
© Association of Otolaryngologists of India 2016

Abstract Haemangiomas of the nasal cavity are rare benign tumours which usually arise in the Kiesselbach triangle of the septum. Mostly they are seen in young population with peak age 20 years. Epistaxis is the most common symptom in these patients. We present a case of a 62-year-old woman with recurrent epistaxis. On examination she had had an obstruction of both nasal cavities. Computed tomography imaging demonstrated a well-defined tumour originating from the posterior tip of the right inferior turbinate, passing into the nasopharynx. The tumour was managed via endoscopic endonasal approach. The histological analysis revealed a tumour tissue with the appearance of a cavernous haemangioma as well as capillary haemangioma. A focus of intravascular endothelial papillary hyperplasia was also observed. In patients with endonasal benign tumours choice of surgical approach depends on the exact location of the tumour and suspected pathology. The transnasal endoscopic approach and bipolar cautery resection enable adequate exposure and visualization of the tumour, control of bleeding and complete removal of the tumour.

Keywords Cavernous haemangioma · Nasal cavity · Nasopharynx · Endoscopic surgery · Epistaxis

✉ Ana Penezić
apangercic@gmail.com

¹ Department of Otorhinolaryngology and Head and Neck Surgery, University Hospital Center “Sestre Milosrdnice”, School of Medicine, University of Zagreb, Vinogradska cesta 29, 10 000 Zagreb, Croatia

² Department of Pathology, University Hospital Center “Sestre Milosrdnice”, School of Medicine, University of Zagreb, Zagreb, Croatia

Introduction

Haemangiomas of the nasal cavity and paranasal sinuses are rare benign tumours. In nasal cavity about 80 % of haemangiomas arise from the nasal septum in the Kiesselbach triangle and only 15 % arise from the lateral wall of the nasal cavity [1–3]. Haemangiomas in the nasal cavity can arise from mucosa and should be differentiated from those which are primary osseous lesions, because the symptoms and surgical approach are different [4]. In this article we present the case of large inferior turbinate haemangioma in elderly patient with recurrent unilateral epistaxis.

Case Report

A 62-year old female patient was admitted to our hospital from other institution with history of difficulties with breathing through nose and recurrent epistaxis in the past 4 months. In anterior rhinoscopy there was coagulum in her right nasal cavity and deviation of septum to the left. Endoscopically in the right nasal cavity there was a coagulum behind which was tumour obturating choana. In the left nasal cavity there was also tumorous mass which had obturated cavity and choana same as right (Fig. 1). Oropharyngoscopically there was a tumour protruding from nasopharynx into the oropharynx, pushing soft palate anteriorly, lying on the mucosa of posterior oropharyngeal wall and going below the uvula.

MSCT scan of head and neck (together with paranasal sinuses) was showing tumorous mass which had been vertically lying from roof of epipharynx to the soft palate (5 cm length, AP 2 cm, LL 2 cm), had had postcontrast imbibition and was well-defined. The tumour was in close

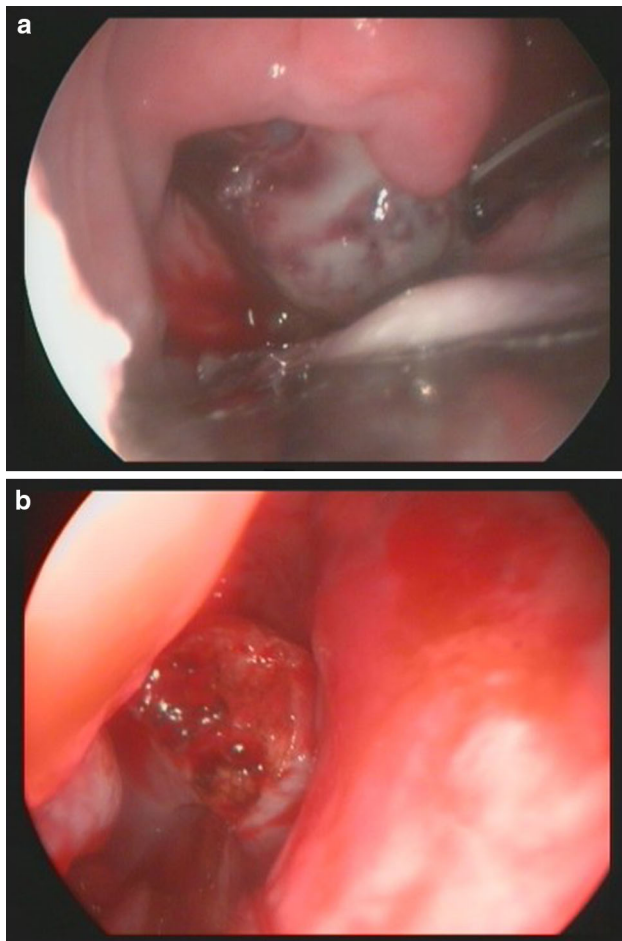


Fig. 1 **a** Haemangioma visible in the oropharynx, **b** haemangioma resected from the inferior turbinate protruding through the right choana

contact with both inferior turbinates. Inside the tumour vid flow signals were seen. MR angiography revealed vascular tumour in nasal cavity and origin of the tumour on the posterior tip of the inferior turbinate (Fig. 2).

Endonasal biopsy was already done in patient in county hospital and tumor tissue was sent on histological analysis. The histological analysis of endonasal biopsy revealed tumor tissue with appearance of a cavernous haemangioma characterized by multiple dilated thin-walled vascular channels, and appearance of capillary haemangioma, both lined with endothelial cells without atypia and no mitotic activity. There is also one focus of intravascular endothelial papillary hyperplasia, while the some of the vessels was filled with thrombus (Fig. 3).

On the 4th day of admission the resection of haemangioma was done. The origin of the haemangioma was at the posterior tip of the right inferior turbinate, where the cut was made and then had been extracted via mouth and oropharynx. Both of the inferior turbinates had polypoid

changes of posterior tips which had been resected and the radiofrequent mucotomy of them had been done in the end.

Discussion

Haemangiomas frequently occur in the head and neck region, but location at the nose and paranasal sinuses are rare. There are three types of haemangiomas according to the histological classification depending on the dominant vessel size at microscopy: capillary, cavernous and mixed types [1–3, 5]. Histologically, cavernous hemangiomas appear as closely packed, dilated vascular channels lined with a layer of flattened endothelial cells [1–3]. Capillary hemangiomas are more common in nasal cavity and usually arise from nasal septum, while cavernous hemangiomas are more likely to be found on the lateral wall of nasal cavity [4, 5].

Cavernous haemangiomas usually present at age of forty, while capillary types are predominant in younger population, with peak incidence in 15 years. Although both types of haemangiomas are not frequent in population aged above 60 years, they should be considered as a potentially important and treatable cause of unilateral epistaxis, as in our case [1]. In clinical picture unilateral epistaxis is predominant symptom, but haemoptysis and signs of nasal obstruction [1]. Repeating unilateral epistaxis which was seen in our patient should always raise suspicion on nasal malignancy, and besides anterior rhinoscopy, optic examination of the both nasal cavities should be performed. Vascular tumours of the nasal cavity will appear as unilateral, hemorrhagic mass, purple or red coloured, which will bleed easily on touch [1, 3, 4]. The definitive diagnosis is made by histological confirmation of the specimen, prior which radiological investigations should be done. Imaging techniques such as computerized tomography scan and magnetic resonance scan will reveal anatomical localization and extension of the tumour [3, 4]. Taking the specimen for histological analysis prior the operation carries high risk of bleeding for patient, so preoperative arteriography with embolization may be choice in larger tumours [6, 7]. With the aid of the arterial embolization, haemorrhage during surgical intervention could be minimized [8, 9].

In the case of our patient we hadn't performed angiography with sclerosation/embolization of feeding vessel (A. sphenopalatina) before the surgical intervention. We used trans-nasal endoscopic approach with cauterization of the feeding vessel, which is also commonly used for resecting haemangiomas [1–6]. With this approach we located the origin of the tumour at the posterior pole of the right inferior turbinate, and with the cauterization of the underlying mucosa we successfully made this tumorous mass movable. We also cauterized the posterior pole of the

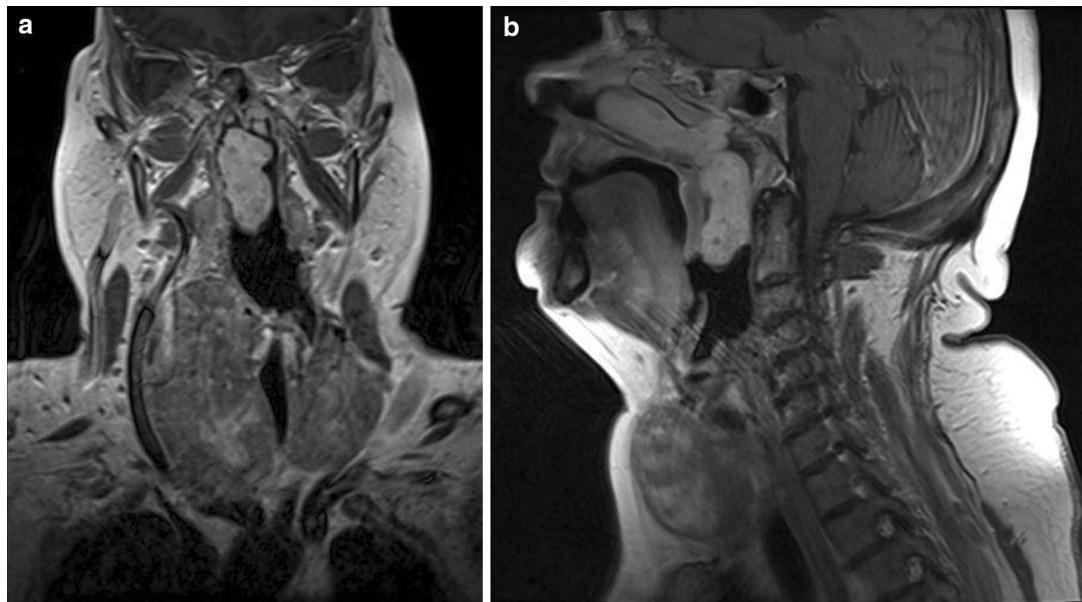


Fig. 2 Computed tomography identifying the nasopharyngeal haemangioma: **a** coronal section, **b** sagittal section

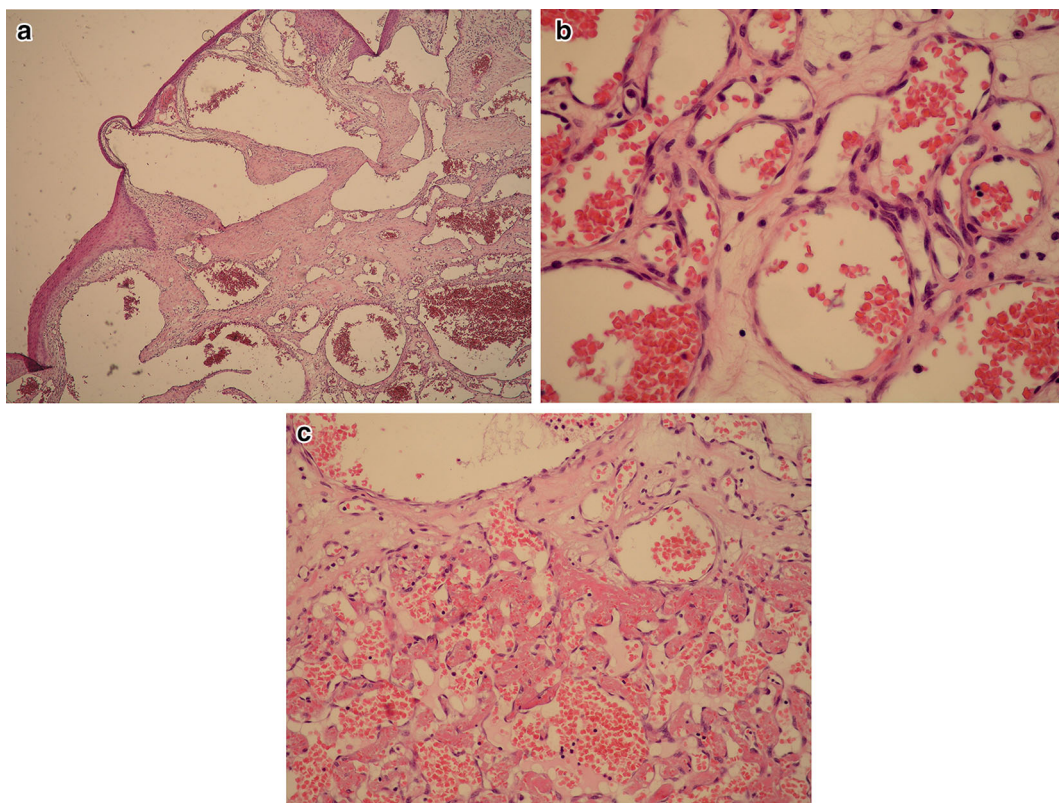


Fig. 3 a Histological pattern of a cavernous haemangioma with dilated thin-walled vascular channels lined by a flattened endothelium, H&E $\times 4$, **b** histological pattern of capillary haemangioma with aggregates of closely packed, thin-walled and blood filled capillaries lined by a flattened endothelium. The vessels are separated by scant connective tissue stroma, H&E $\times 400$, **c** intravascular endothelial

papillary hyperplasia (IPEH) with multiple small, delicate papillary structures projecting into the lumen and lined by single layer of plump or attenuated endothelial cells surrounding a collagenized core, H&E $\times 200$

inferior turbinate in the left nasal cavity and the moved tumour through the nasopharynx into the oropharynx. Because of the size of the tumour was deliberated through the mouth. Our patient showed no recurrence of the tumour in the postoperative 18 months period, and the histology confirmed mucous type of haemangioma with both cavernous and capillary component, and no invasion of the underlying bone of the inferior turbinate.

Alternative methods such as embolization, corticosteroid therapy, sclerosing solutions, cryotherapy, resection using YAG laser have been described for managing haemangiomas [4]. In our case these methods would be doubtful because of the size and the location of the tumour.

Our case shows that every patient is unique and requires careful planning of the intervention. Surgical intervention of the nasal haemangioma should be based on suspected pathology and patients' underlying conditions, as well as on proven reliability to visualize the origin of the tumour, to control the bleeding during the procedure and to completely remove the tumour and prevent short term recurrence. Although not characteristic for age group above 60 years, vascular sinonasal malignancies may be important and treatable cause of epistaxis.

Conclusion

Endoscopic approach is nowadays considered as standard procedure in excision of nasal haemangiomas. Mixed type haemangiomas are possible cause of unilateral epistaxis in elderly patients.

References

1. Iwata N, Hattori K, Nakagawa T, Tsujimura T (2002) Hemangioma of the nasal cavity: a clinicopathologic study. *Auris Nasus Larynx* 29(4):335–339
2. Gourin CG, Millay DJ (2000) Pathology forum: quiz case 3. Diagnosis: cavernous hemangioma of the nasal bones. *Arch Otolaryngol Head Neck Surg* 126(7):902–906-7
3. Çaylaklı F, Çağıcı AC, Hürcan C, Bal N, Kizilkiliç O, Kiroglu F (2008) Cavernous hemangioma of the middle turbinate: a case report. *Ear Nose Throat J* 87(7):391–393
4. Archontaki M et al (2008) Cavernous hemangioma of the left nasal cavity. *Acta Otorhinolaryngol Ital* 28:309–311
5. Batsakis JG, Rice DH (1981) The pathology of head and neck tumors: vasoformative tumors, part 9A. *Head Neck Surg* 3:231–239
6. Bakhos D, Lescanne E, Legeais M, Beutter P, Morinière S (2008) Cavernous hemangioma of the nasal cavity. *Ann Otolaryngol Chir Cervicofac* 125(2):94–97
7. Citardi MJ, Batra PS (2008) The nose and paranasal sinuses. In: Lee KJ (ed) *Essential otolaryngology: head and neck surgery*, 9th edn. McGraw-Hill Companies Inc., New York, pp 394–395
8. Kim HJ, Kim JH, Kim JH, Hwang EG (1995) Bone erosion caused by sinonasal cavernous hemangioma: CT findings in two patients. *Am J Neuroradiol* 16:1176–1178
9. Hayden RE, Luna M, Goepfert H (1980) Hemangiomas of the sphenoid sinus. *Otolaryngol Head Neck Surg* 88:136–138