

Supracondylar humeral fracture in the pediatric population

Vigneron, Charlotte Julie Marion

Master's thesis / Diplomski rad

2014

Degree Grantor / Ustanova koja je dodijelila akademski / stručni stupanj: **University of Zagreb, School of Medicine / Sveučilište u Zagrebu, Medicinski fakultet**

Permanent link / Trajna poveznica: <https://um.nsk.hr/um:nbn:hr:105:806867>

Rights / Prava: [In copyright](#) / [Zaštićeno autorskim pravom.](#)

Download date / Datum preuzimanja: **2024-07-28**



Repository / Repozitorij:

[Dr Med - University of Zagreb School of Medicine Digital Repository](#)



**UNIVERSITY OF ZAGREB
SCHOOL OF MEDICINE**

Charlotte Julie Marion Vigneron

**SUPRACONDYLAR HUMERAL FRACTURE
IN THE PEDIATRIC POPULATION: ROLE OF
THE PHYSIOTHERAPY**

GRADUATION THESIS



Zagreb, 2014

This Graduate thesis was made at the Department of Paediatric Surgery, University Hospital Center Rebro, Zagreb, mentored by Professor Luetic, Dr. Med. and was submitted for evaluation during the academic year 2013/2014.

TABLE OF CONTENT

1. SUMMARY.....	i
2. INTRODUCTION.....	1
3. CONTENT.....	8
3.1. Epidemiology and mechanism of trauma.....	8
3.2. Relevant anatomy and ossification of paediatric elbow.....	11
3.3. Diagnosis and imaging of supracondylar humerus fracture in children.....	14
3.4. Associated injuries and complications.....	20
4. TREATMENT.....	24
5. PHYSIOTHERAPY.....	30
6. FOLLOW UP.....	38
7. DISCUSSION.....	40
8. CONCLUSION.....	42
9. ACKNOWLEDGMENT.....	43
10. BIBLIOGRAPHY.....	44
11. BIOGRAPHY.....	48

1. SUMMARY

In the overall pattern of fractures of the extremities in the paediatric age group, supracondylar fractures are the second most common fracture. Not only are they common but also they are often associated with complications such as vascular and nerve injuries and had a greater rate of poor results than any other type of extremity fracture. The bony architecture of the supracondylar area of the humerus and laxity of the ligamentous structures in children are the major factor in producing supracondylar fractures in paediatric age. X-ray differentiation and classification of the various types of supracondylar fractures can be difficult but enables the physician to make a decision about treatment and provide some type of prognosis. Careful initial clinical examination to determine the integrity of the neurovascular structures is imperative for any further treatment. The method of treatment depends on the degree and type of displacement. The treatment of each type of fracture, indication for operative management and complications is detailed and summarized. Supracondylar fracture is an injury with great magnitude and a considerable soft tissue injury. Although the metaphyseal bone in paediatric age is healing rapidly, after removal of the cast after three weeks, loss of range of motion is common. The major functional problem appears to be changes in elbow mobility, either loss of flexion or loss of extension or hyperextension. Active range of motion is started at the child's own pace followed by physiotherapy. The goals of physical therapy are rapid recovery of motion and avoidance of late complications. Physical therapy procedures used in the elbow rehabilitation are described. Children receiving physical therapy are expected to achieve a more rapid return of normal elbow range of motion.

Keywords: Supracondylar humerus fractures, Children, Treatment, Physiotherapy

2. INTRODUCTION

A fracture is a break of continuity in the structural continuance of the bone.

Fractures are most common in youth and in the elderly with variation in incidence and etiologies.

The former are more at risk of practicing activities that will result in a high-energy trauma, especially toddlers and adolescents.

In addition, their bone structure, up to fully growth, is different, more prone to fracture and they are different type of fracture according to the age population.

Whereas the latter, would include etiologies like osteoporosis, malignancy, osteopenia or stress fracture, which would result in a fracture due to low-energy trauma.

Indeed, the growing bone is made of several parts; epiphysis, physis or growth plate, metaphysis, diaphysis and periosteum (1).

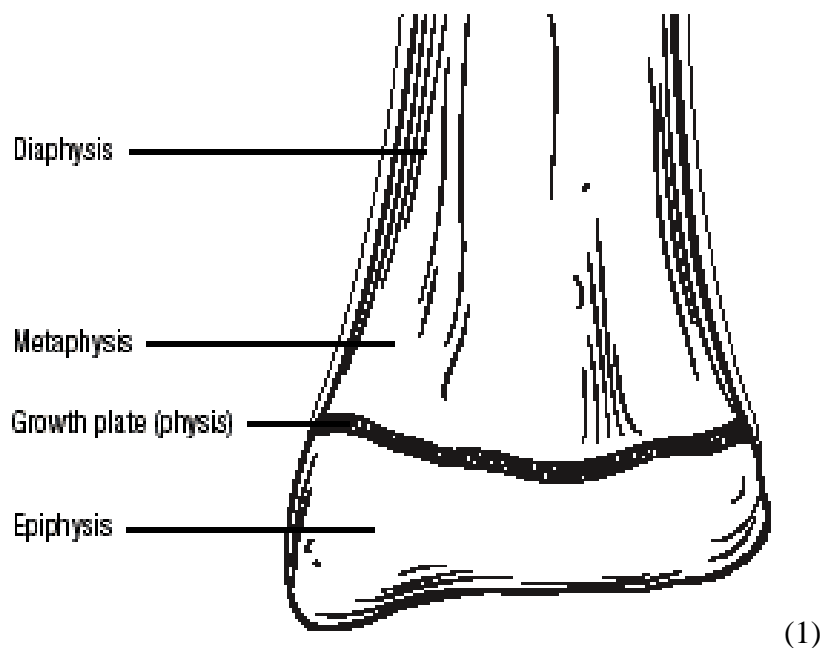


Figure 1: The anatomy of a growing bone

The injury pattern in growing bone is quite different than in a fused and fully-grown bone. The bone tends to bow rather than break. The osteoid density of a child's bone is less than an adult's, it has more water and is mechanically less resistant (2). The bone is more porous than the adult bone because the Haversian canals occupy a much greater part of the bone.

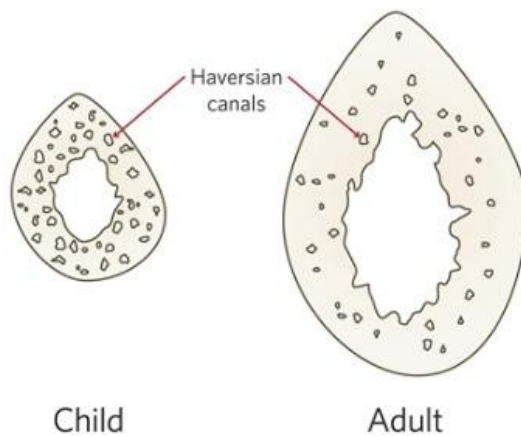


Figure 2: The Haversian canals occupy a larger space in bone of a child.

This is one of the principal reasons a child's bone can bend more than an adult's bone (3).

The ability to bend before breaking leads to unique fracture patterns in children. The compressive force is responsible for a “Torus” fracture or “Buckle” fracture, these most commonly occur in the distal metaphysis, where porosity is greatest.



(3)

Figure 3: buckle injury outline

A force to the side of the bone may cause break in only one cortex, which create a “Greenstick” fracture while the other cortex only bends, in other words, it occurs when there is sufficient energy to start a fracture but insufficient energy to complete it. The cortex fails on the tension side and the cortex on the compression side bends but remains intact (3).

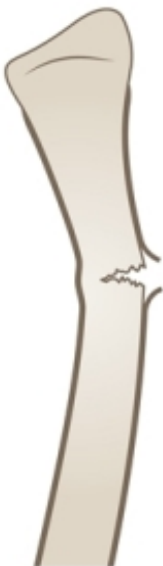
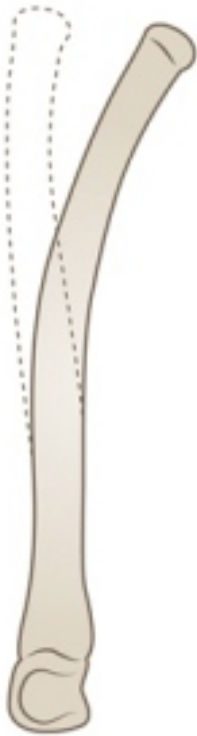
Figure 4: “Greenstick” fracture outline

In very young children, neither cortex may break and this can result in a Plastic deformation (1). Long bones may bend without breaking the cortex. Their bones can be bent to 45 degrees before the cortex is disrupted and a greenstick or a complete fracture occurs. The bones most commonly affected by plastic bowing are the ulna and fibula.



(3)

Figure 5: plastic deformation

In addition there are also complete fractures where both cortexes are disrupted; same as in adult's fractures.

These descriptions are true for every bone fracture in the paediatric population.

Also there are fractures involving the growth plate or fracture with an epiphysis disruption, organized according to the famous Salter-Harris classification, as follow, which give a prognosis on the residual growth from the beginning (2).



Figure 6: Salter-Harris growth plate fracture classification

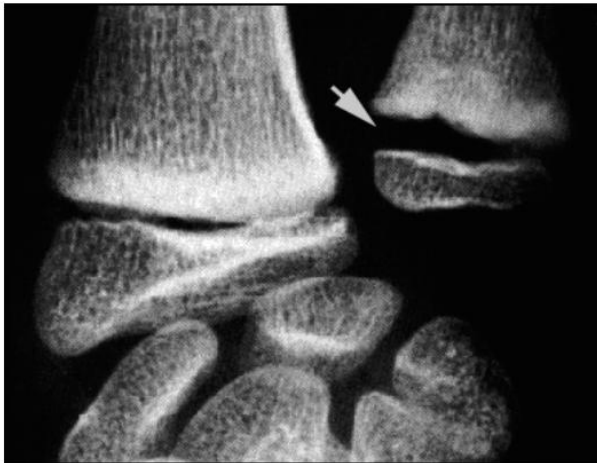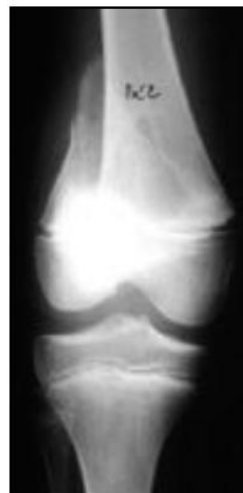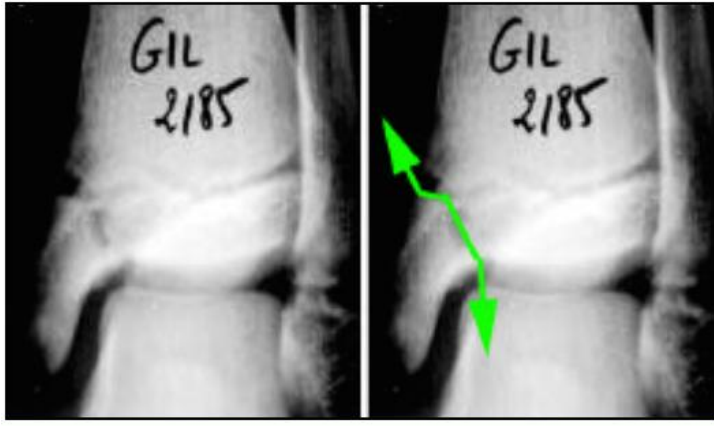


Figure 7: Salter-Harris classification, radiographic view

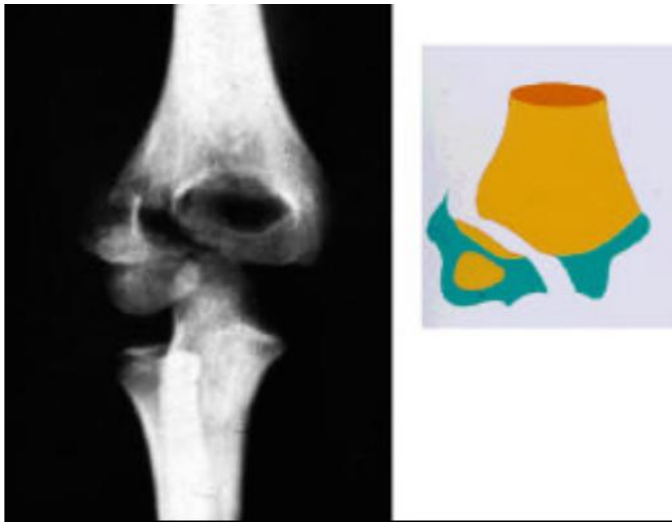
Type 1: epiphysis slit only, excellent prognosis



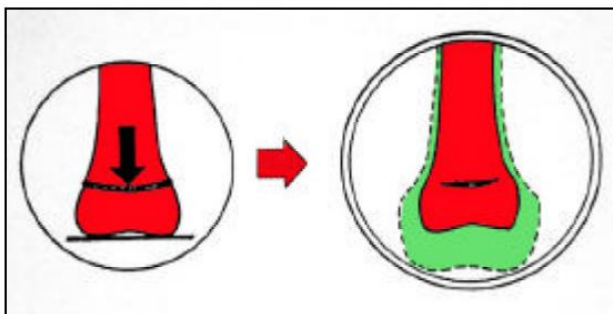
Type 2: fracture through epiphyseal plate with a triangle of shaft attached, good prognosis



Type 3: fracture through epiphysis, extending through epiphyseal plate, growth can be compromised, especially if the reduction was not complete



Type 4: fracture of the epiphysis and shaft, crossing the epiphyseal plate, bad prognosis



Type 5: complete compression of the epiphyseal plate, diagnosis a-posteriori, when the growth defect arises

Supracondylar humeral fractures are the most common fracture around the elbow in the paediatric population.

They are the result of a fall on an outstretched arm and are seen primarily in the first decade of life (4). They are diagnostically challenging and can result in severe acute and long-term complications.

The diagnosis of these fractures can be subtle and, if missed, can result in vascular, structural, or neurologic injuries. Prompt diagnosis and treatment of these injuries is important to improved clinical outcome. The emergency physician needs to remain vigilant for this diagnosis to avoid this orthopaedic pitfall (4). An understanding of the fracture presentation, anatomic details, and surgical applications can optimize the chances for successful outcomes.

This is why this paper focuses on this specific area of paediatric orthopaedics and traumatology.

Post-traumatic physiotherapy is a well-known associated measure to any kind of post-treatment of a fracture in the adult population; it is even vital to recuperate a fully functioning limb.

However, little is known about the place of physical therapy in the paediatric patients? Only a few articles were found about this subject.

More specifically, the indications for physiotherapy after supracondylar humeral fractures in children are not clear in the literature (5).

With this in mind, the review will try to understand the role and necessity of the post-fracture physiotherapy in these patients, more specifically in the supracondylar humeral fractures.

3. CONTENT

3.1 - Epidemiology and mechanism of trauma

Fractures in children are the least common type of injury presenting at the Emergency department, the most common being less grievous injuries such as sprains, dislocations, wounds or superficial contusions. (6)

However, fractures are still a significant problem in childhood, with around one-third of boys and girls sustaining at least one fracture before 17 years of age. Rates are higher among boys than girls, and male incidence rates peak later than those among females. At their childhood peak, the incidence of fractures (boys, 3%; girls, 1.5%) is only surpassed at 85 years of age among women and never among men (7).

The peak incidence occurred at 11–12 years in girls and at 13–14 years in boys, with a male-to-female incidence ratio of 1.5 (8).

Upper extremity fractures are more common than lower extremity fractures in children (9).

The site most commonly affected in both genders is the forearm, radius and/or ulna (7). The most common type of injury mechanism is falling (8) but there are variations in mechanisms and activities at injury with age, and over time (8)

Supracondylar fractures comprise 65-75% of all elbow fractures in children (9).

They mostly occur between the ages of 5 and 10 with the peak incidence occurring between 5-8 years of age (after this, dislocations become more frequent)(9). These injuries are more frequent in males and on the non-dominant side.

Several mechanisms of traumatism have been sorted out, while most of them recall a fall or direct hit on the injury site (proximal humeral fracture, lateral humeral condyle fracture); they tend to be more complicated for supracondylar fracture:

- Hyperextension occurs during a Fall On Outstretched Hand (FOOSH), the elbow become locked in extension, which indirectly puts force on the distal humerus and displaces it posteriorly; this can occur with or without a valgus or varus force. This “extension” type of injury accounts for 95% of the cases (9, 10).

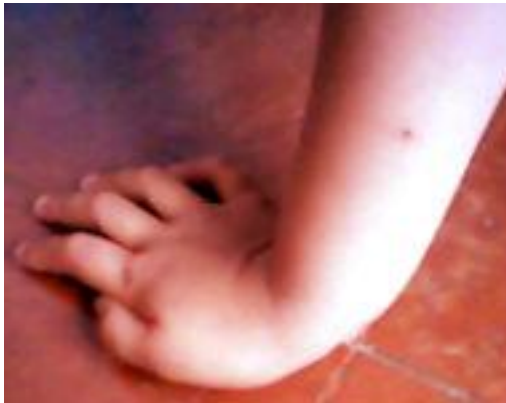

Figure 7: FOOSH Injury

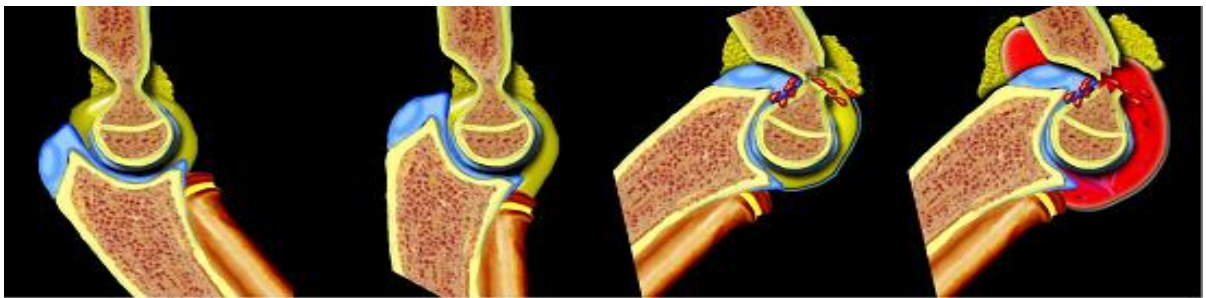

Figure 8: Mechanism of a Hyperextension injury

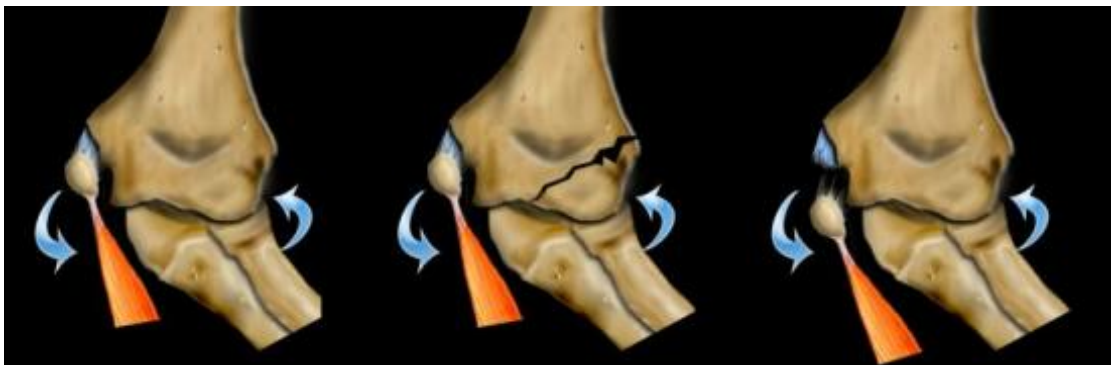

Figure 9: Mechanism in extreme Valgus, resulting in condyle fracture, ligament disruption

(Photos from the radiology Assistant)(11)

- Children younger than 3 years usually incur this injury from falling from a height of less than 3 feet
- Older children sustain fractures from falls from greater heights off of playground equipment
- If the hand is in a supinated position, then a postero-lateral displacement occurs
- If the hand is pronated, then a posteromedial displacement occurs (more common)
- Direct trauma or a fall onto a flexed elbow seldom occurs resulting in a 'flexion' type injury (5%) with anterior displacement (9, 10).

3.2 Relevant anatomy and ossification of paediatric elbow

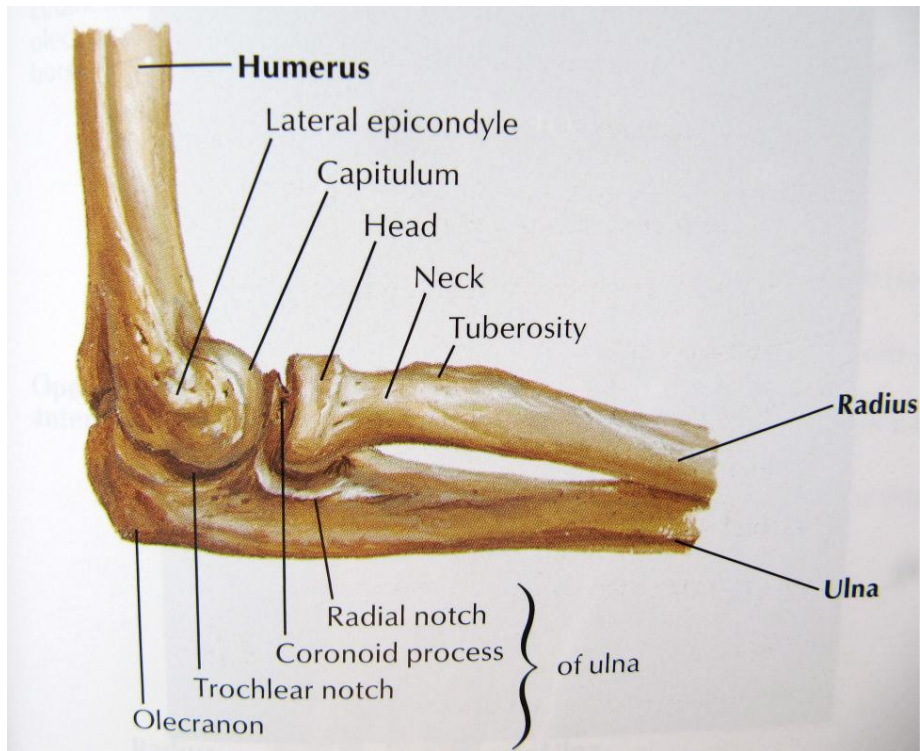


Figure 10: Basic anatomy of the elbow

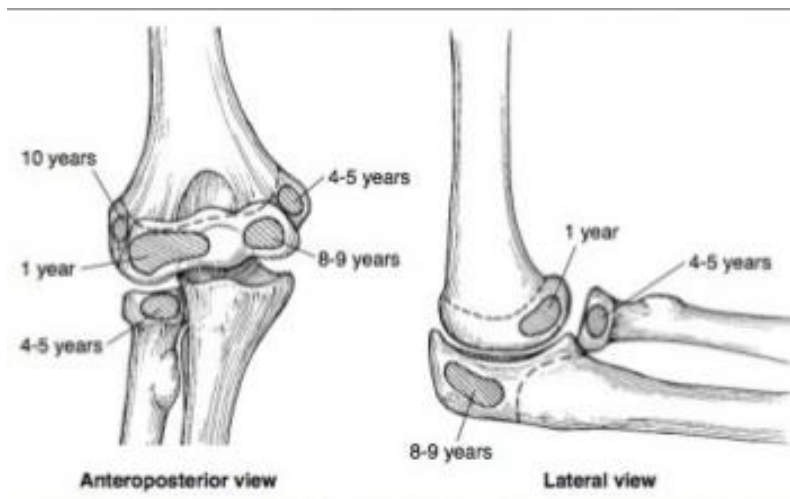


Figure 11: Ossification centres

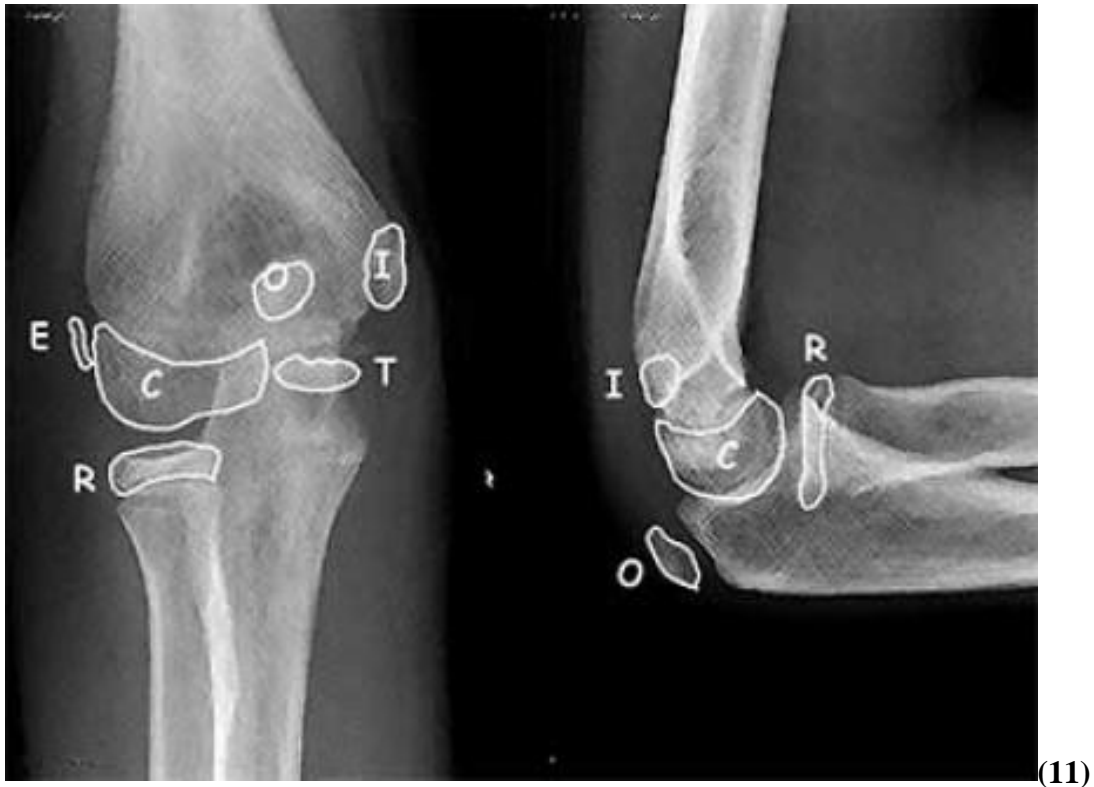

Figure 12: ossifications centres, radiographic view

There are 6 ossification centres around the elbow joint. They appear and fuse to the adjacent bones at different ages.

It is important to know the sequence of appearance since the ossification centres always appear in a strict order and to be able to distinguish a fracture from a normal finding, since they could be mistaken for a fracture. The ages may vary and ossification centres often appear earlier in females (9), usually occurs at 1-3-5-7-9-11 years old. (12)

This order of appearance is specified in the mnemonic **C-R-I-T-O-E** (Capitellum - Radius - Internal or medial epicondyle - Trochlea - Olecranon - External or lateral epicondyle).

On the anatomy of the radiography of a child elbow the main relationship to look for is the following:

- The capitellum should always aligns with the radial head if not, it is necessary to evocate an elbow dislocation, a lateral condyle fracture or a Monteggia fracture (12).

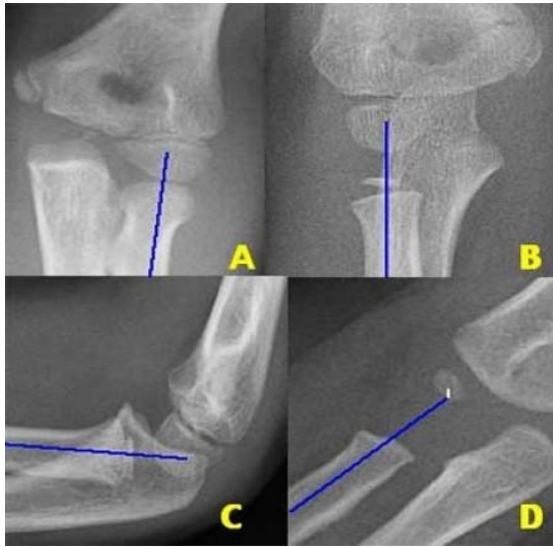


Figure 13: Radiocapitellar line

A line drawn through the centre of the radial neck should pass through the centre of the capitellum, whatever the positioning of the patient, since the radius articulates with the capitellum.

In dislocation of the radius this line will not pass through the centre of the capitellum(11).

3.3 Diagnosis and Imaging of supracondylar fracture in children

It is essential to obtain a thorough explanation for the fracture in order to distinguish accidental from non-accidental injuries (pathological fractures, child abuse) but also to learn about the patient history in order to give the best care possible (2).

A full patient history should be realized, including asking for previous diseases, vaccinations, if the child is taking any medications, what sport does he play, the time of his last meal (2). A thorough anamnesis should be done, the time of the fall/trauma, the mechanism, if there has been any loss of consciousness, if the parents or himself is able to offer appropriate explanations, the location of the pain, if he heard a cracking noise, and if he is able to move the limb by himself (2).

Then a full physical examination should be perform, especially if the child is an infant, (a trauma can always hide another trauma), which should start with observation of the child as a whole and then reduce to the lesion and look for localized swelling, ecchymosis, deformity, and other skin changes or abrasions at the fracture site, signs and symptoms of compartment syndrome (detailed later) such as intense pain upon mild extension or stretching of the fingers, paresthesia/numbness, but persistence of a pulse and pallor which would results in an extreme medical emergency (9).

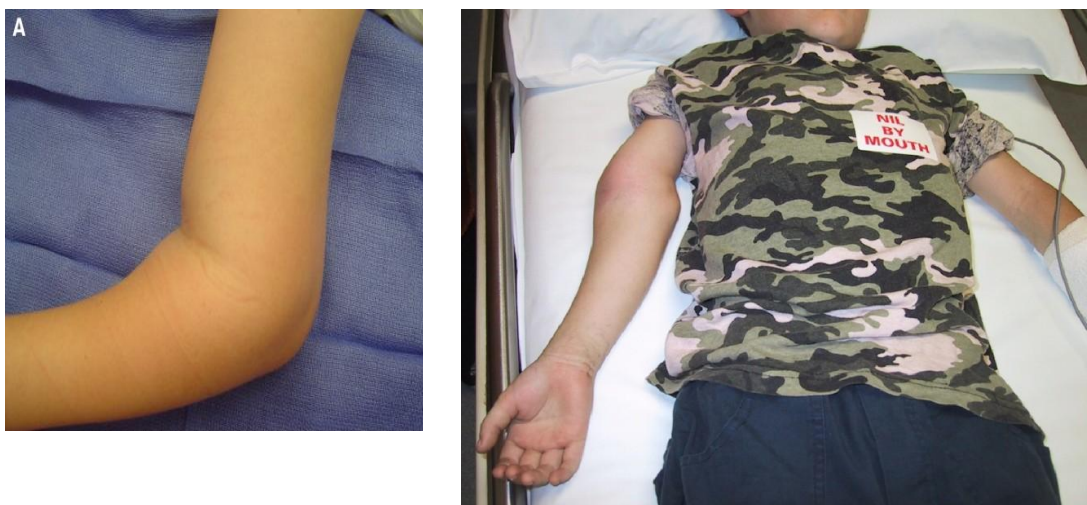

Figure 14: Just by observation, diagnosis of fracture can be evocated

Upon palpation, isolation of the approximate painful area should be made.

A neurological exam should eliminate any nerve paralysis by testing the sensitivity and the muscle activity;

The radial nerve is assessed with wrist extension and sensitivity in the dorsal aspect of the first web space;

The median nerve injury could be found with the patient's ability to make the "ok sign" and sensitivity over the palmar tip of the index finger;

Finally the ulnar nerve injury is evaluated with strength testing of intrinsic muscles of the hand and sensation over the palmar tip of the fifth finger.

The palpation of all the pulses, bilaterally, to evaluate their symmetry should be done, specifically the radial pulse and brachial pulse, in order to look for a possible vascular lesion. The Allen's test can be performed for the radial and ulnar arteries (9).

The joint testing could be done however in most cases this is almost impossible due to the pain the child is in, and is therefore done in the operating room or strong sedation.

Diagnosis of any fracture should be made through clinical findings and a radiography evaluation is necessary in order to confirm it.

On the radiographic point of view, if there is only minimal or no displacement these fractures can be occult on radiographs.

The only sign will be a positive fat pad sign.

Usually there is some displacement and the anterior humeral line will not pass through the centre of the capitellum but through the anterior third or even anterior to the capitellum (figure 17A).

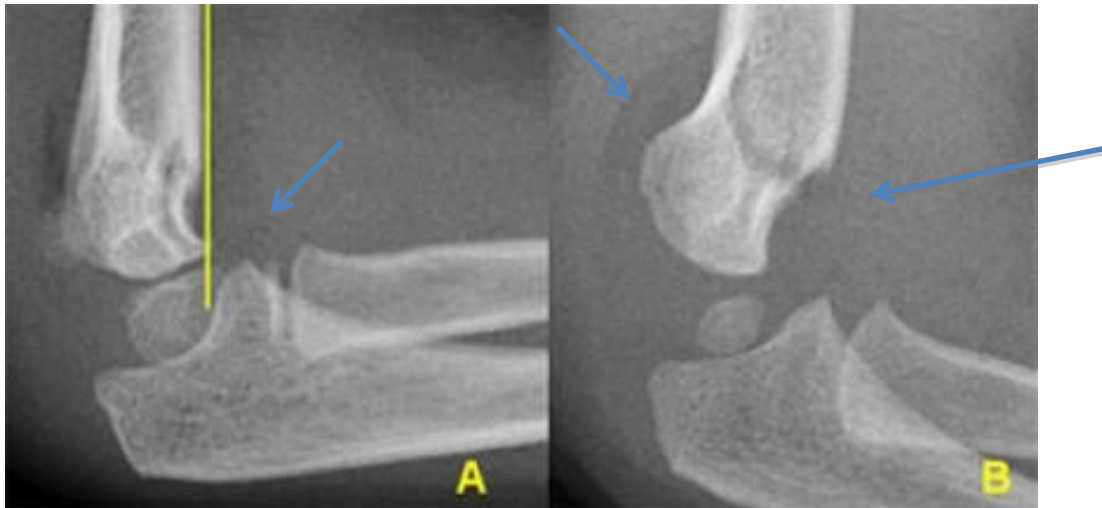


Figure 15: Supracondylar fractures. In A the anterior humeral line passes through the anterior third of the capitellum and in B even more anteriorly. Notice positive posterior fat pad sign (blue arrows) in both cases

Different types of supracondylar fracture are sorted out according to radiological classification, the Gartland classification.

Supracondylar fractures: Gartland classification	
1. Minimally displaced fracture	
2. Displaced distal fragment	- Intact posterior cortex
3. Complete displacement	- Posteromedial (75%) posterolateral (25%)

Gartland Type I fractures are often difficult to see on X-rays since there is only minimal displacement.

Most of these fractures consist of greenstick or torus fractures.

The only clue to the diagnosis may be a positive fat pad sign. These patients are treated with casting. In Gartland type II fractures there is displacement but the posterior cortex is intact. There may be some rotation (11).

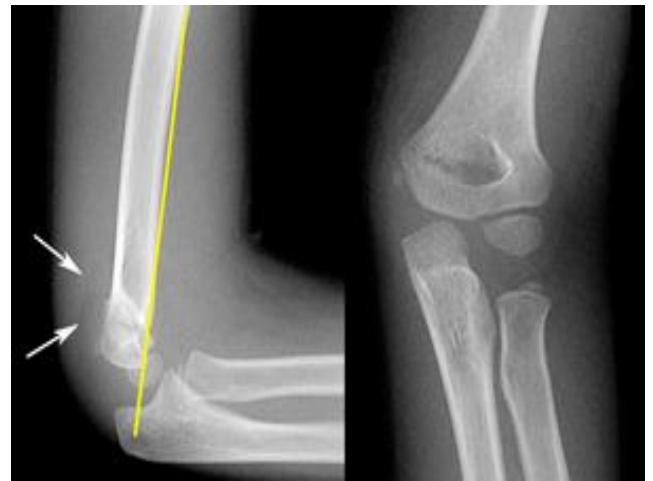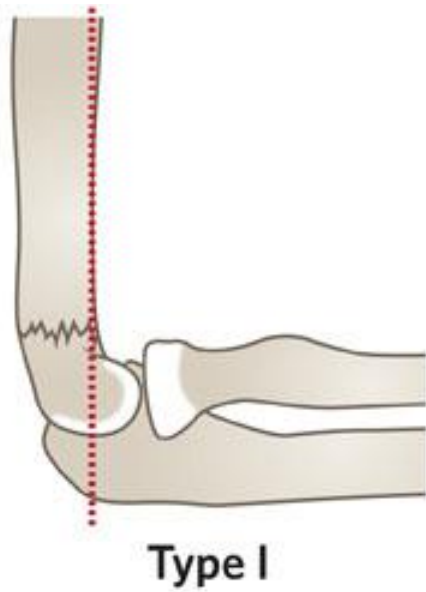


Figure 16: Lateral and AP x-ray of three-year-old girl with Gartland type I supracondylar fracture. In Gartland type I fractures, the anterior humeral line (yellow line) passes through the middle of the capitellum. These fractures may be difficult to see on plain x-ray. A fracture should be suspected if anterior and/or posterior fat pad signs (arrows) are present (seen on lateral x-ray, white arrows)(13).

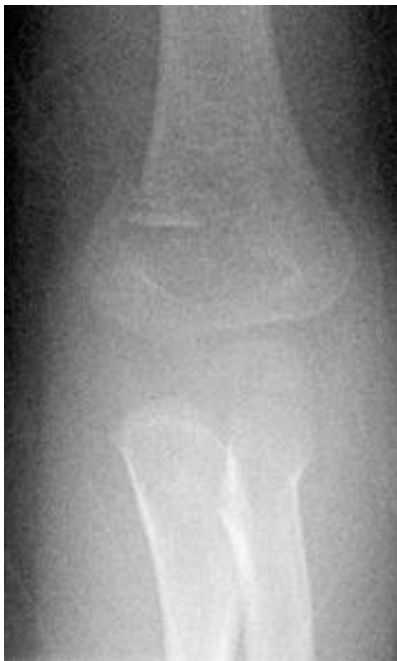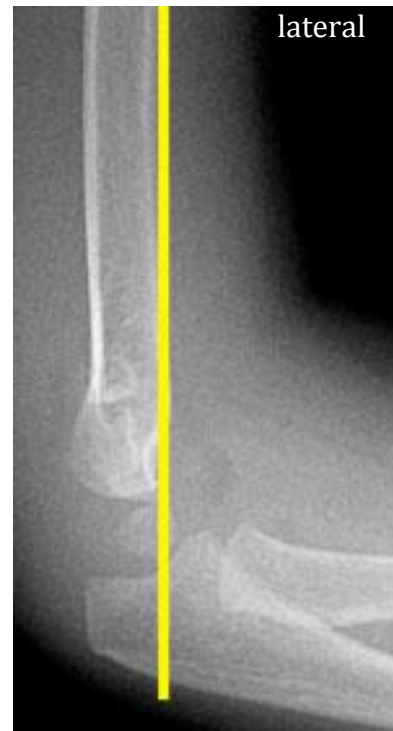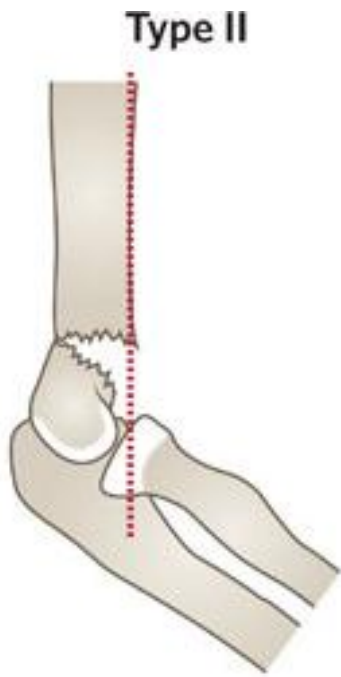


Figure 17: Lateral and AP view of two year old girl with Gartland type II supracondylar fracture. On lateral view the anterior humeral line is anterior to the middle of capitellum. On the AP view, fracture lines can be seen through the metaphyseal bone of the distal humerus on either side of the olecranon fossa.

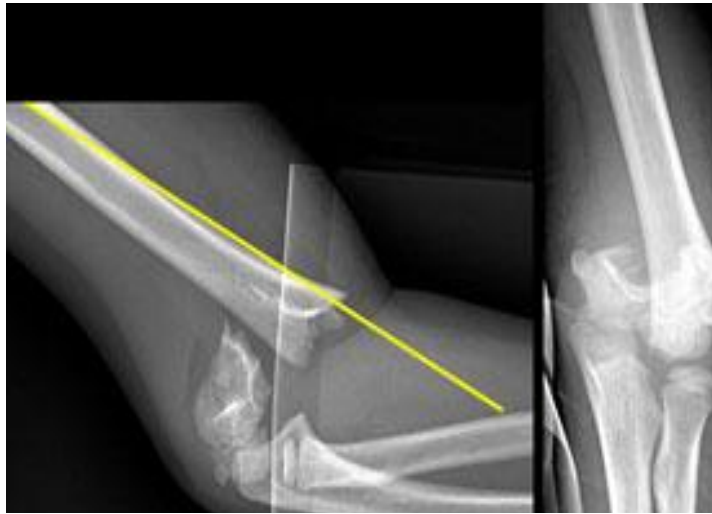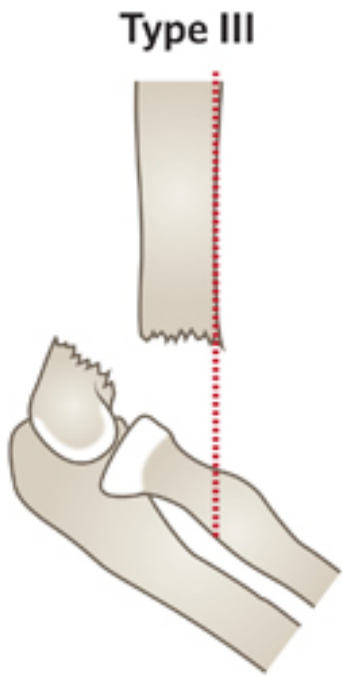


Figure 18: Gartland type III supracondylar fracture of six-year-old girl. Complete rupture of the periosteum and full displacement of the humerus shaft from its head(13).

3.4 - Associated injuries and complications

Supracondylar fractures are severe fracture purveyor of numerous complications.

They can be classified according to the time at which they occur, from the moment of the trauma until later on, few months, and years later.

We can distinguished acute complications from immobilization and delayed ones.

Acute Complications:

They should be diagnosed at the moment of the supracondylar fracture diagnosis, during the physical examination.

They can be neurological (14), as explained earlier, with a compression of the median nerve, lesions to the ulnar or radial nerve being less common.

Vascular (14) complications can also occurs due to the anatomical structure that enter in close contact during the fracture, the brachial artery can be perforated or ruptured if the trauma was violent enough.

At last, fortunately, exceptional, an opened fracture can happen and then produce a cutaneous wound classified according to Gustilo table.

Immobilization complications:

Secondary displacement can arises; usually the bones come back to the initial displacement, it occurs specifically if the fracture was treated orthopedically, as a rate as high as 10%.

From this emanate the necessity of repeated radiological control during the consolidating phase and callus formation.

A much more severe, engaging the vital prognosis complication is the compartment syndrome; it can occurs when the fracture is immobilized in a cast; however the presence of the cast is not necessary.

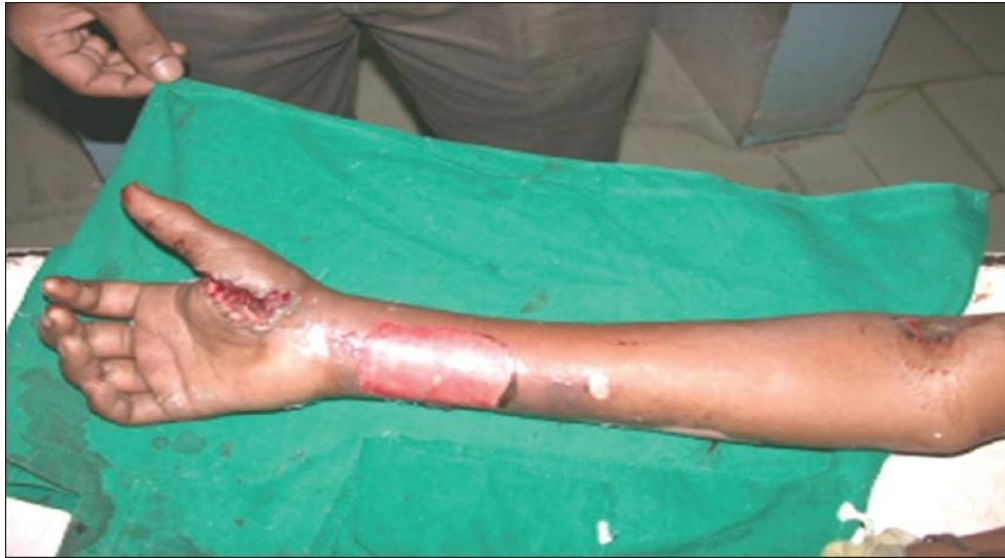This should be kept in mind at all time, at 6, 24, 48 hours post-reduction, for any limb placed under a cast, any symptoms should make the doctor cut through the cast.

The first sign of compartment syndrome is disproportionate pain requiring increasing doses of pain medication (15).

Edema, paresthesia, cyanosis, extreme and intense pain of the muscle compartment of the forearm and the presence of a pulse should make the diagnosis. No complementary test should be ordered.

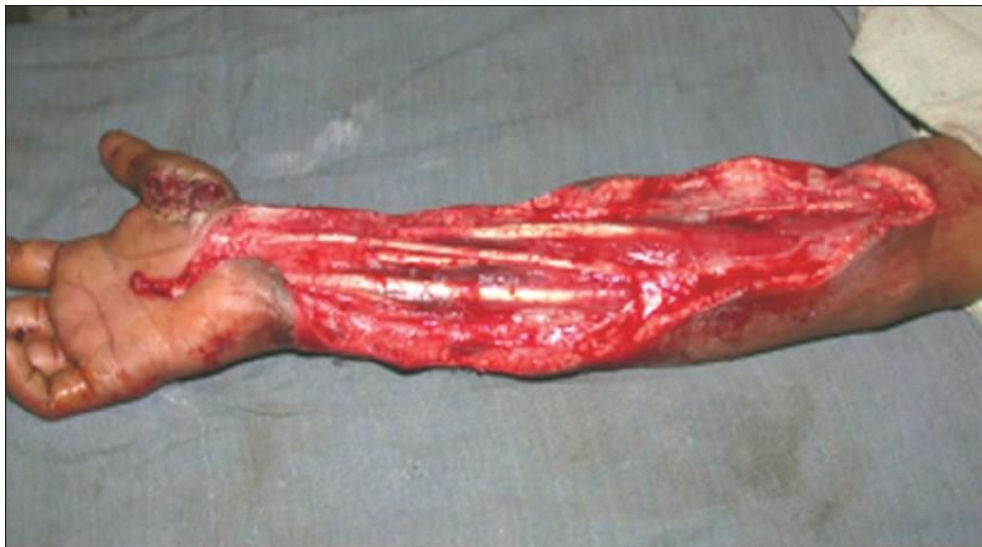A forearm fasciotomy should be performed in emergency.

Compartment syndrome showing tense muscles of the forearm



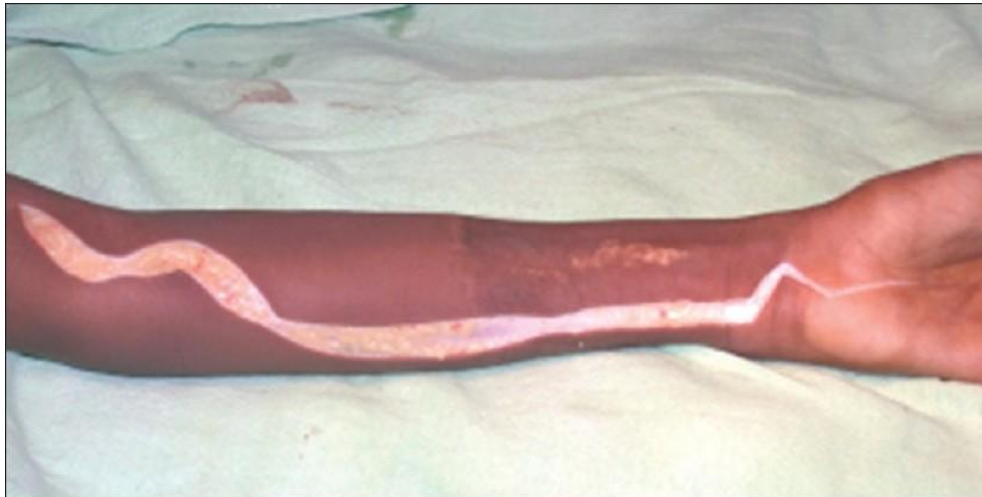(16)

**Same patient after a fasciotomy of the compartment of the forearm;
The forearm are decompressed by a comprehensive incision**



(16)

Path of the fasciotomy



(16)

Figure 19: photos of an upper arm with compartment syndrome and its treatment, fasciotomy.

Delayed complications:

Volkman's contracture can result from a neglected compartment syndrome or a bleeding. It consists of a definitive deformation of the wrist and the fingers, which take the appearance of a claw.

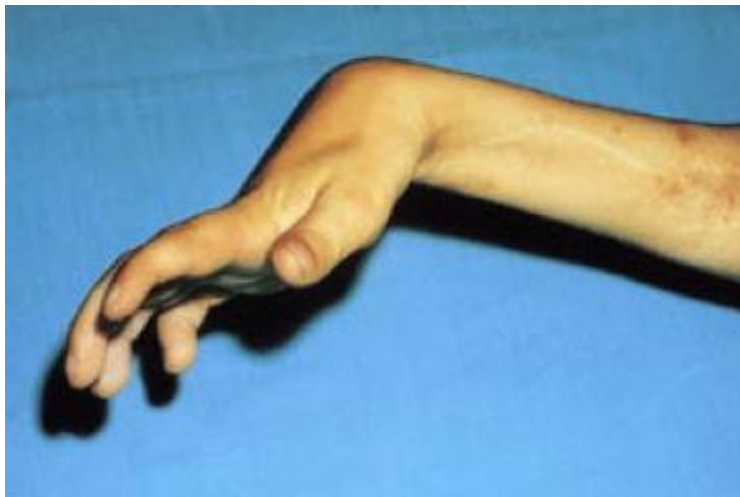

Figure 20: Volkman's contracture

Vicious callus is a common complication of supracondylar fracture, usually occurring because of insufficient reduction or secondary displacement. This will trigger a deformation of the elbow in a cubitus varus. Fortunately, this spontaneously resolves because of bone remodelling.

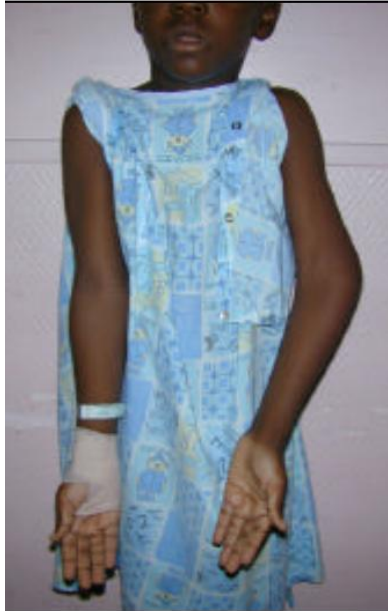

Figure 21: Reduction defect with rotating malfunction triggering an axial defect; cubitus varus

(2)

Rigidity of the limb is one the latest complication to arise; however this occurs less frequently in children (3,(17).

Epiphyseal growth plate arrest corresponds to the premature closing of the growth plate by a bony bridge. It can occur if the fracture line is going through the growth plate, according to the Salter-Harris classification.

It can result, conferring to its localization to a length inequality of a limb. However this does not concern supracondylar fractures since they are extra-articular fractures (2).

4. TREATMENT

After clinical assessment and diagnosis, the elbow should be splinted in a position of comfort (approximately 20°–30° of flexion) to provisionally stabilize the limb (15). Splinting in full elbow extension is contraindicated because it stretches the neurovascular bundle over the fracture site in displaced or unstable fractures (18). The application of a comfortable, well padded, and appropriately applied splint is a critical part of the initial management of these injuries, regardless of their definitive treatment.

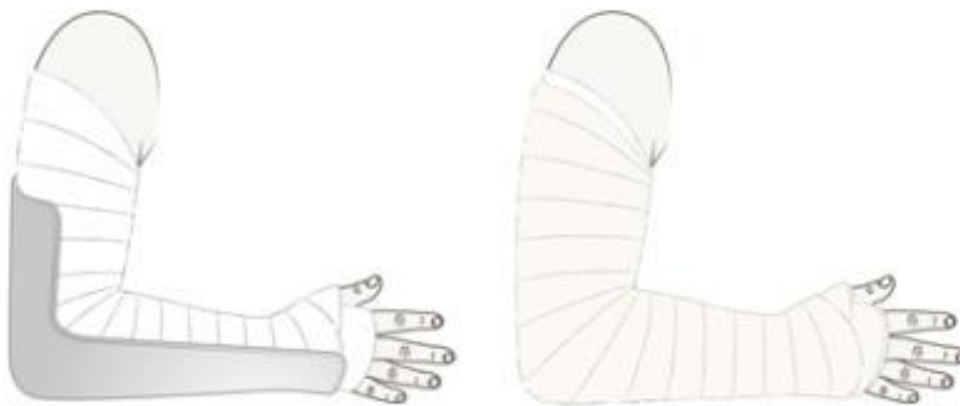

Figure 22: Above the elbow padded splint

The younger is the child the more padding should be added, the skin of children is so delicate and thin, especially in infants, it can quickly create a skin abrasion or lesion. Non-displaced (Type I) or minimally displaced fractures in young children can potentially be treated with an above-elbow cast at 90° of flexion for 4-6 weeks. While it is often easiest to visualize displacement or angulation on the lateral radiograph, the Baumann angle on the AP radiograph can be a useful tool to identify and measure varus impaction(19). When there is varus angulation at the fracture site, strong consideration should be made for closed reduction and percutaneous pinning. More than 10° of varus misalignment (compared to the contralateral arm) is an indication for operative reduction and pinning. As a general principle, larger diameter pins convey better stability and are more effective at maintaining fracture reduction and alignment.

Angulated fractures that maintain an intact posterior cortex, but have an anterior humeral line that passes anterior to the capitellum on the lateral radiograph (Type II) require reduction.

These may become stable after closed reduction and casting at 90° of flexion. If more than 90° of flexion is needed to maintain reduction, then an operative reduction of the fracture with percutaneous pinning should be performed to minimize risks of complications associated with the increased elbow flexion required to maintain reduction in these injuries (15).

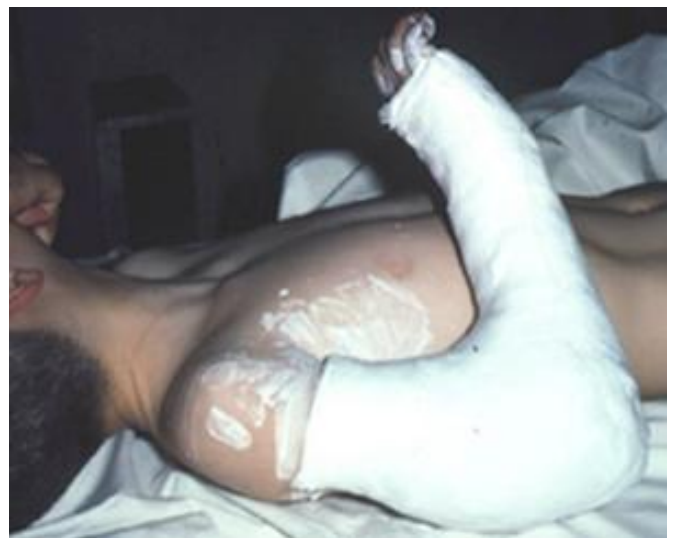
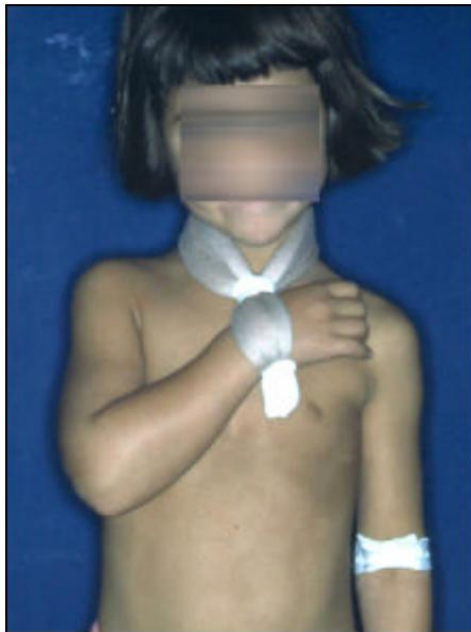
Figure 23: Hyper-flexion immobilization for type 2 supracondylar fracture and 90 degrees plaster cast of Paris

Fractures that create significant displacement of the distal humerus (Type III) are particularly prone to neurovascular compromise. Closed reduction and percutaneous pinning is the preferred treatment for displaced fractures (Fig. 25C and D).

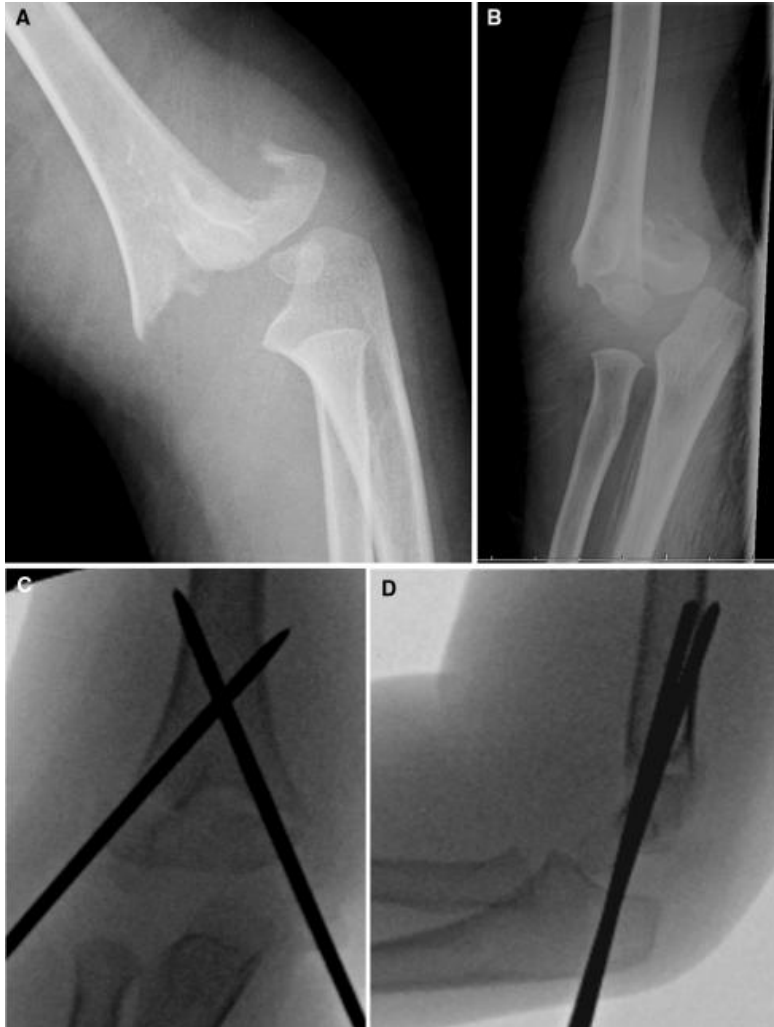

Figure 24: (a) Antero-posterior and (b) lateral radiographs show complete displacement in this type III supracondylar fracture. (c) Intraoperative antero-posterior radiograph demonstrating fracture reduction and cross pinning. (d) Lateral view showing restoration of a normal anterior humeral line

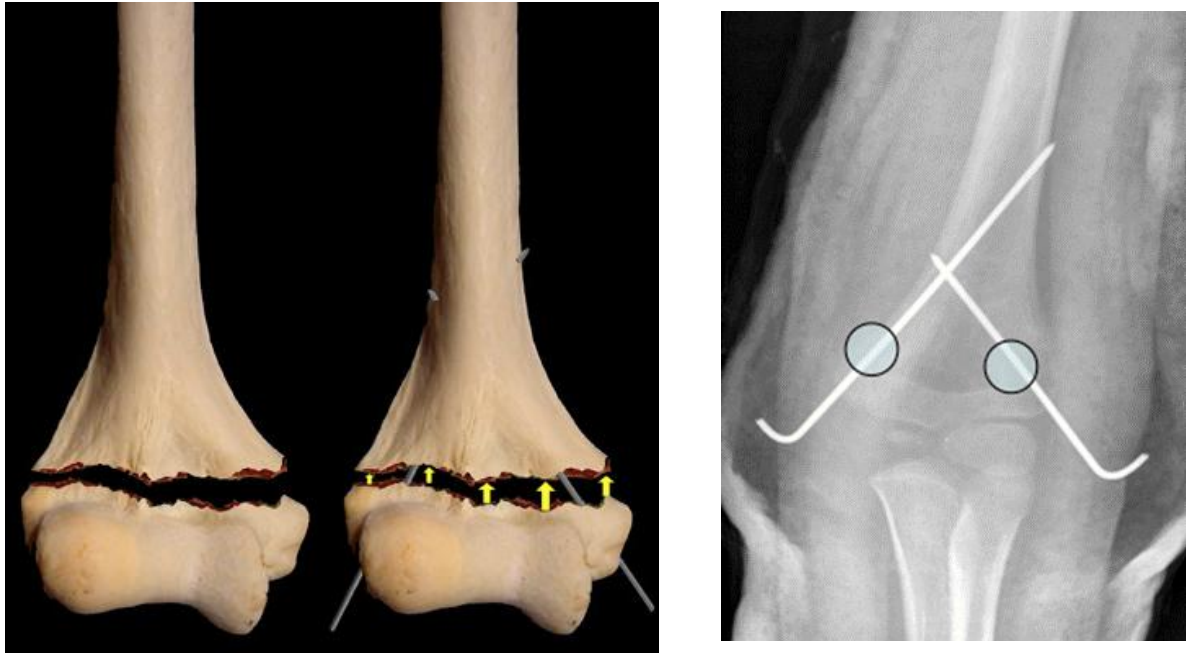


Figure 25: Cross-pin configuration. A typical pin pattern is seen on the right, but with the fracture a bit apart for clarity. The fracture would actually be together when pinned.

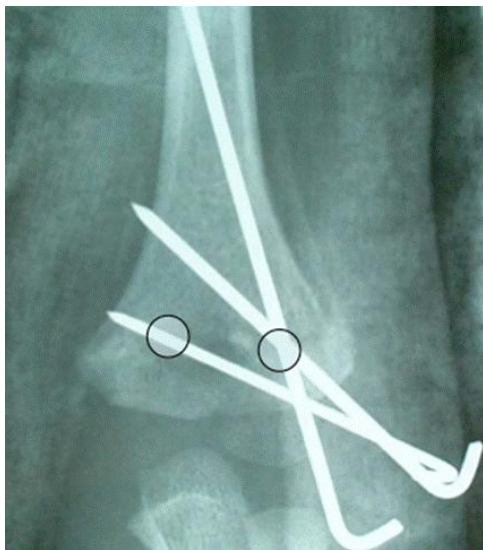

Figure 26: Lateral pin fixation.

Fractures with displacement treated by closed reduction and casting have a higher incidence of residual deformity than those managed with operative reduction and pinning (20). After a careful clinical evaluation that finds no neurovascular injury, an operative fracture may be splinted and managed safely in a delayed fashion (within 24 h) while awaiting operative fracture reduction (15).

Recent studies have shown that delayed surgical intervention does not increase complication rates (21-23) or the quality of the reduction (24).

However, according to the recent American Academy of Orthopaedic Surgeon guidelines, the optimal management of a displaced fracture seems to consist of an operative reduction and percutaneous pinning in an urgent manner and at least within 24 hours (25). Certainly, a child with an operative fracture should be admitted for close observation of the neurovascular status while waiting for operative treatment. An open reduction is indicated in cases where the fracture is irreducible by closed methods or if the brachial artery has been compromised and requires exploration (15). Preoperative arterial insufficiency may be improved by operative reduction and pinning, in that a kinked brachial artery, draped over the distal end of the proximal fragment, may become patent after manipulative reduction of the fracture. Lastly, all open supracondylar fractures warrant a surgical debridement of the fracture followed by stabilization with external fixators, which fortunately is a rare situation.

While postoperative protocols vary from surgeon to surgeon, a typical regimen calls for a long arm, ulnar gutter-type splint or a split long arm cast to control elbow motion and forearm rotation for 3 weeks, followed by pin removal and early range of motion or continued splinting for additional 1–2 weeks (15, 26).

If a stable closed reduction and an experienced paediatric orthopaedic surgeon achieves pinning of the fracture, follow-up may safely be delayed until the day of pin removal (26).

Nevertheless, if there is any uncertainty about fracture reduction or stability after pinning, the first follow-up visit should be within 7 days of surgery. This early follow-up for unstable fractures allows for a repeat closed manipulation and pinning if there has been a loss of reduction (15).

Treatment of complications should also be taken into account.

The median nerve, specifically the anterior interosseous nerve, (52%) and radial nerve (32%) are most frequently injured in the course of the injury (27).

Most deficits that occur at the time of fracture are neurapraxias (a stretch or contusion of the nerve) and spontaneously recover function in 2–3 months (28). If there has been no recovery of function after 4–6 months, then exploration is indicated.

Neurolysis and/or repair have favourable results in children (29).

Iatrogenic nerve deficits often affect the ulnar nerve and result from a pin impinging on the nerve. Management of this complication varies from pin removal and observation to surgical exploration (15).

Vascular insufficiency resulting from supracondylar fractures has been reported to range from 5% to 12% (30). Prompt reduction of the fracture often restores the interrupted arterial flow (30, 31). After reduction, careful observation and clinical exam are necessary to differentiate between a hand that is well perfused with absent pulse from one that is cold, pale, and truly ischemic (15).

Management of a well-perfused hand with an absent pulse varies. In this scenario, many surgeons opt to carefully monitor the child with frequent vascular exams. An arteriogram is often of little use diagnostically as the location of the lesion is often apparent. True vascular insufficiency after reduction calls for surgical exploration.

Cubitus varus, or 'gun-stock deformity', is the most common late complication of this type of fracture. This deformity is the result of fracture malunion and occasionally the partial growth arrest of the medial condylar physis (32). Proper anatomic reduction and fixation during initial management prevents malunion. Minor varus angulation is generally considered a cosmetic, rather than functional, deformity. A corrective osteotomy may be performed to improve clinically significant malunions.

5. PHYSIOTHERAPY

A fractured elbow can be a painful injury to recover from due to the limited movement available. Not being able to move the elbow can cause the joints to become stiff causing a loss in the range of motion possible when bending the arm. Performing some rehabilitation exercises can help improve the elbow's abilities

Evaluation of the fracture with follow up X-rays is important to ensure the fracture is healing in an ideal position, as detailed later in the follow up paragraph.

Once healing is confirmed and the plaster cast has been removed, rehabilitation can generally begin as guided by the treating physiotherapist.

One of the most important components of rehabilitation following a supracondylar fracture is that the patient rests sufficiently from any activity that increases their pain. Activities, which place large amounts of stress through the humerus should also be avoided, particularly lifting, weight bearing or pushing activities. To rest from aggravating activities allows the healing process to take place in the absence of further damage. Once the patient can perform these activities pain free, a gradual return to these activities is indicated provided there is no increase in symptoms. This should take place over a period of weeks to months with direction from the treating physiotherapist.

Ignoring symptoms or adopting a 'no pain, no gain' attitude is likely to cause further damage and may slow healing or prevent healing of the fracture altogether.

Patients with a supracondylar fracture should perform pain-free flexibility and strengthening exercises as part of their rehabilitation to ensure an optimal outcome. This is particularly important, as soft tissue flexibility and strength are quickly lost with immobilization. The treating physiotherapist can advise which exercises are most appropriate for the patient and when they should be commenced.

The prognosis of a supracondylar fracture can vary widely according to the type of fracture in the Gartland classification, depending on the presence of complications or on the quality of the treatment given.

Patients with a supracondylar fracture usually make a full recovery with appropriate management (whether surgical or conservative). Return to activity or sport can usually take place in weeks to months and should be guided by the treating physiotherapist and specialist.

In patients with severe injuries involving damage to other bones, soft tissue, nerves or blood vessels, recovery time may be significantly prolonged.

Physiotherapy treatment can be vital in some patients with a supracondylar fracture to hasten healing and ensure an optimal outcome. Treatment may comprise:

- Soft tissue massage
- Joint mobilization
- Electrotherapy (e.g. ultrasound)
- Taping or bracing
- Exercises to improve strength and flexibility
- Education
- Activity modification
- A graduated return to activity plan

Other intervention for a supracondylar fracture can be realised in addition of the physiotherapy or concomitantly if physiotherapy only was not enough.

Despite appropriate physiotherapy management, some patients with this condition do not improve adequately and may require other intervention.

The treating physiotherapist or doctor can advise on the best course of management when this is the case.

This may include further investigations such as X-rays, CT scan, MRI or bone scan, extended periods of plaster cast immobilization or referral to appropriate medical authorities who can advise on any intervention that may be appropriate to improve the condition. Occasionally, patients who are initially managed conservatively may require surgery to stabilize the fracture and a bone graft to aid fracture healing.

Different physiotherapy exercises should be achieved throughout the course of rehabilitation for a supracondylar fracture.

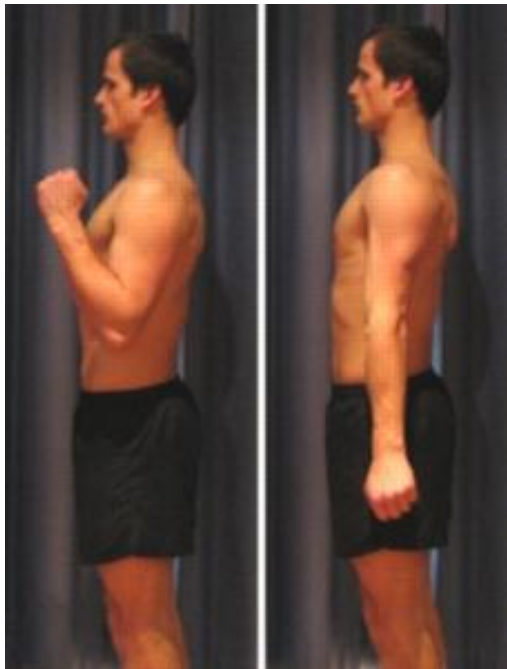The under mentioned exercises are commonly prescribed to patients with a supracondylar fracture following confirmation that the fracture has healed, and that the orthopaedic specialist has indicated it is safe to begin mobilization.

Discussion of the suitability of these exercises with a physiotherapist prior to beginning them is highly advised.

Generally, they should be performed 3 times daily and only provided if they do not cause or increase symptoms:

- Elbow Bend to Straighten

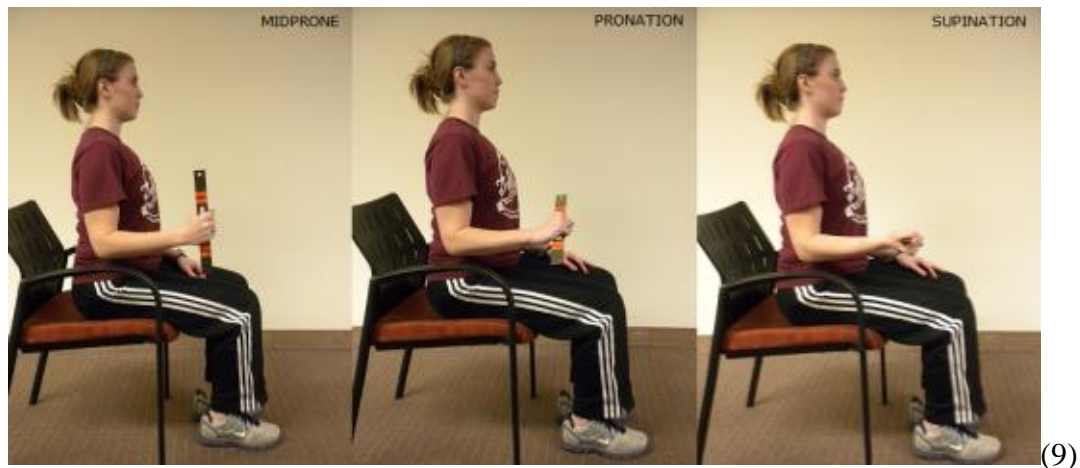The elbow is bent and straightens as far as possible pain free. It is aimed for no more than a mild to moderate stretch. And repeated 10 times provided there is no increase in symptoms (33).



(33)

- Forearm Rotations

This exercise should begin with the elbow at the side and bent to 90 degrees. Slowly, a rotation of palm in supination and then pronation, as far as possible, pain free, should be realised. It is aimed for no more than a mild to moderate stretch and repeated 10 times given there is no increase in symptoms.



- Tennis Ball Squeeze

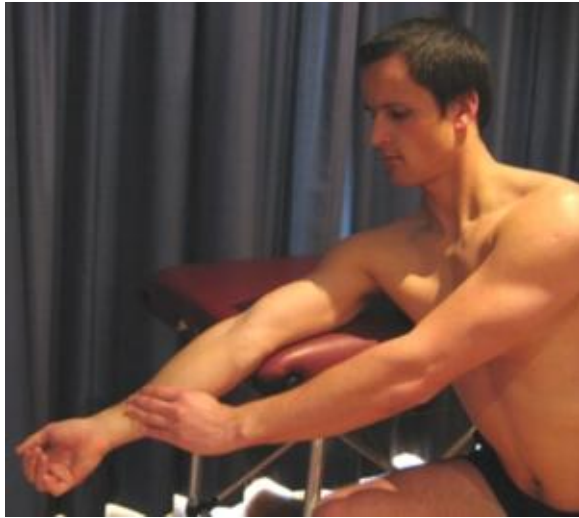This exercise begins with holding a tennis ball; it should be squeezed as hard as possible and comfortably without pain. The exercise is hold for 5 seconds and is repeated 10 times.



The following elbow stretches are designed to restore movement to the elbow and improve flexibility of muscles crossing the elbow. Generally, they should be performed 3 times daily supplied they do not cause or increase pain.

Elbow Extension

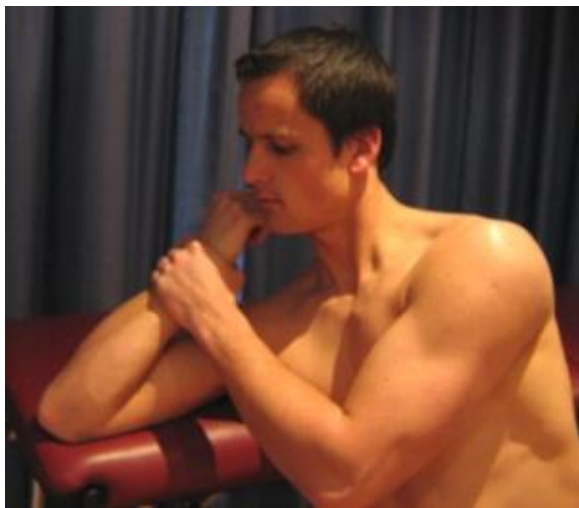The elbow should be placed on the edge of a bench or a table in order to straighten it using the other hand as far as it can go without pain and provided it feels no more than a mild to moderate stretch. It is repeated 10 - 20 times implied the exercise is pain free (33).



(33)

Elbow Flexion

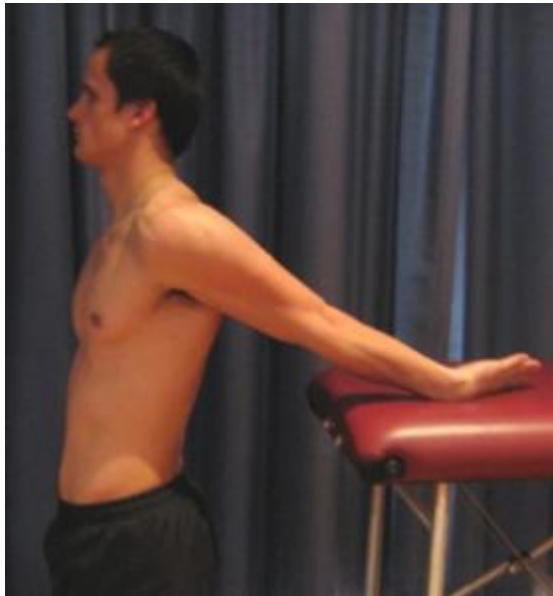The same disposition is needed as in the previous exercises, the elbow should be bent with the other hand as far as it can go without pain and provided it feels no more than a mild to moderate stretch. It is repeated 10 - 20 times given the exercise is pain free.



(33)

Biceps Stretch

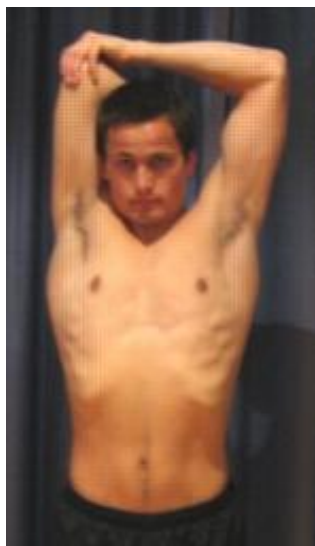This should begin with the back and neck straight and the arm supported behind on a bench or on a table. Gently the body is lowered, allowing the arm to move further behind until it feels a mild to moderate stretch pain-free. It is hold for 15 seconds and repeated 4 times.



(33)

Triceps Stretch

This begins standing tall with the back and neck straight. One hand is placed behind the lower neck and the other hand on the elbow. A gentle push of the elbow is applied backward so the hand moves further down the spine until it feels a mild to moderate stretch pain-free. It is hold for 15 seconds and repeated 4 times.



(33)

The physical therapy management in the paediatric population is very controversial, both its effect and its necessity.

While some studies showed that young age patients could benefit from post-fracture physiotherapy since they have elbow stiffness afterward (34), some also showed that these same patients present only a temporary rigidity and that it usually resolved spontaneously. First, there is an initial rapid recovery in elbow motion; this can be expected after a lateral humeral condylar fracture in a child for example, with progressive improvements for up to one year after the injury. However, this recovery is slower if the patient is older, has a longer period of immobilization, and has a more severe injury.

The supracondylar fractures in children may lead to functional disturbance with loss or reduction of range of motion in the elbow joint.

Nevertheless, the indications for physical therapy after these humeral fractures in children are not clear in the literature, even in the presence of an active or passive limitation of elbow joint motion.(9)

Some studies showed that postoperative physiotherapy is unnecessary in children with supracondylar humeral fractures without associated neurovascular injuries (5).

Physical therapy is not unsuccessful or totally contraindicated.

In opposition, one study showed a significant difference in the grade of joint stiffness at the beginning and the end of a physical therapy, including a complex of various therapeutically physical procedures which could improve the range of motion of the elbow joint (35).

However, this study lack in statistical power had a small population included and low level of scientific proof since it was not a randomized control study.

Children who received physical therapy achieved a more rapid return of normal or near normal elbow range of motion in the early follow up weeks (5), yet this difference turned out to be non-significant in among the group receiving the physiotherapy and the group not receiving it at one year follow up.

On the contrary, in some countries, as is it the case for France, physiotherapy in the paediatric population is not advised and even is counter-indicated (2). This is based on the fact that the child will start moving and using its arm by himself since he needs it.

Despite every controversial study, if a physical therapy is started, it should be apply in a certain fashion.

The primary goals of treatment through physical therapy should focus on pain reduction, healing, rapid recovery of mobility, and avoidance of late complications (36). At two weeks post proximal humeral fracture gentle pendulum and passive range of movement exercises should be implemented(9).

For supracondylar and humeral shaft fractures after the cast is removed, passive and active motion, soft tissue stretching techniques, and strengthening exercises should be implemented to maximize functional outcome (5, 9, 10), as described above.

A striking point discovered was that, the time for return of elbow motion after treatment of these injuries is not well documented.

In one study, the elbow range of motion (ROM) was recorded for the injured and uninjured extremities. The results were that the elbow ROM returned to 72% of contralateral elbow motion by 6 weeks after pinning and progressively increased to 86% by 12 weeks, 94% by 26 weeks, and 98% by 52 weeks (37).

After closed reduction and percutaneous pinning of a displaced, uncomplicated, supracondylar humerus fracture, 94% of the child's normal elbow ROM should be expected by 6 months after pinning. Further improvement may occur up to 1 year postoperatively (37).

This information may be helpful in advising parents what to expect after their child's injury.

Despite the popularity of this treatment, there are no well-documented descriptions of the time of the expected return of motion after treatment of a displaced supracondylar fracture of the humerus (37).

In addition and most importantly, patient education should focus on instructing parents on how to monitor the child's neurovascular status, to recognize signs of compartment syndrome and skin care around the cast.

Recovery is slower in children who are older, immobilized longer, and has a more severe injury.

6. FOLLOW UP

The orthopaedic treatment necessitates a surveillance of the coloration, the temperature, especially the warmth of the skin of the injured limb, as well as of the sensitivity that also needs to be evaluated. These can be modified if compression occurs due to an edema or a large hematoma below the plaster cast.

As important, the pain shall be assessed since an intense, persistent pain can be the first sign of a compartment syndrome as explained earlier. If the pain tends to be resistant to adapted analgesics or the tolerance of the pain seems different than usual, the cast shall be cut through and the limb should be re-examined.

There should not be any pressure points, which could be the origin of a cutaneous lesion or pressure ulcer.

The follow up of the evolution of the fracture point is realized by ordering radiography of the limb under the cast regularly; usually, there are done when needed, when a displacement is suspected or when the patient expresses discomfort or pain.

The goal is:

- To track down the occurrence of any early secondary displacement, resulting in another reduction or a surgery,
- To evaluate the consolidation of the fracture up until the end of the treatment

After the end of the immobilization, there might be a temporary articular rigidity. It will disappear with the resumption of functional movements of the injured limb.

According to the type of fracture, the more severe ones being the most concerning, there should be a long term follow up elaborated after the end of the treatment, in order to assess if the process of growth continues properly.

At last but not least, the patient education is a key point in any appropriate medical treatment; in this case the doctor shall educate the child's parents.

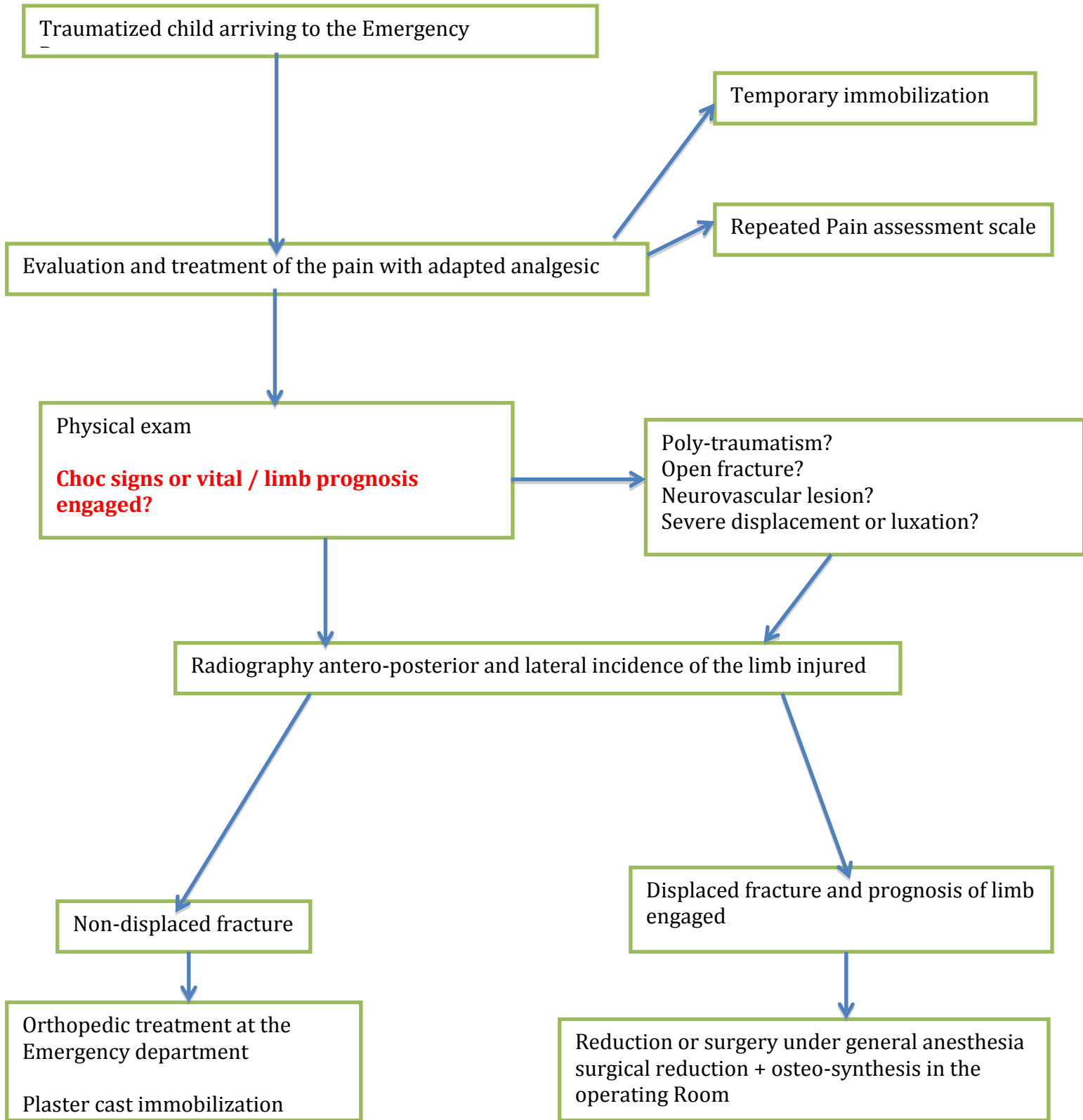


Figure 25: Decision tree for a traumatized child

7. DISCUSSION

Supracondylar fractures of the humerus (SCFH) need a precise treatment in order to obtain a satisfactory result because of the low bone remodelling associated with these injuries(38).

Displaced SCFH are challenging injuries to treat (39-41) and entail technically difficult procedures for orthopaedic surgeons (42).

There remains controversy in the literature with regards to some topics in the definitive management of these types of fractures (43, 44).

The preferred approach on the management of displaced paediatric SCFH is closed reduction and percutaneous pinning, however, this technique requires experience and it is not free of complications or incomplete success (45).

Unless a specific indication for open reduction is present, a closed reduction should always be attempted first. If a satisfactory reduction has not been achieved with closed reduction then an open reduction and pinning technique should be performed as mentioned earlier.

The usage of a lateral external fixator to stabilize SCHF is an interesting and safe alternative in the management of Gartland type III fractures.

An iatrogenic neurological injury rate between 2 and 6% has been reported (46-48) being the ulnar nerve the most frequently nerve affected due to the usage of medial K-wires. This finding has made the cross-pinning configuration a less popular construct among some orthopaedic surgeons.

Among the studies that compared a cross-pin configuration with a two lateral pin construct, there was not a statistically significant difference found (45).

To avoid nerve injury during a medial pin insertion, it is recommended to identify the ulnar nerve through a small incision. With a two lateral pin construct, nerve injury could be explained by a hyperflexion of the elbow during the procedure so physicians should be aware of this to prevent this issue (45).

The effect of timing for surgery of a displaced SCFH in complications is also a controversial topic. Classically, a displaced fracture should be reduced and pinned emergently, but some authors think that it can be treated in a delayed fashion without the risk of increasing complications.

Arguments for early surgical treatment include easiness of fracture reduction, decrease in neurovascular complications, ischemic contracture, angular deformity and elbow stiffness. Disadvantages to reducing fractures emergently include fatigue of the physician during the night, as well as the experience of the surgeon in charge that may be a general orthopaedic surgeon meaning not specialized in paediatric patients.

The treatment of supracondylar fracture of the humerus in the paediatric population is highly specific.

There is little evidence regarding the effect of physical therapy after a closed reduction and pinning of a supracondylar fracture of the humerus in children. Paediatric orthopaedic surgeons tend to remove the pins, most frequently after 3 weeks and begin elbow movement earlier and are not very much concerned about elbow stiffness after supracondylar fracture. They most frequently favour active elbow range of motion exercise. The most contributing factor to restoring the elbow range of motion after a supracondylar fracture in children was the patient's age, followed by the interval between trauma and final fixation, range of motion exercise, and the amount of injury(49). Despite appropriate physiotherapy management, some children with this fracture do not improve adequately and may require other interventions. The treating physiotherapist and pediatric surgeon can advise on the best course of management when this is the case.

8. CONCLUSION

Supracondylar fractures of the humerus are a common paediatric elbow injury that can be associated with neurovascular complications and skeletal deformity.

Since they can present with such acute complications, understanding the anatomy, the radiographic findings, the complications and the management options associated with this fracture is a key to limit the morbidity linked up with these injuries. The most contributing factor to elbow rehabilitation after a supracondylar fracture in children is the patient's age, the interval between trauma and final fixation, range of motion exercise, and the amount of injury.

While the role of post-fractural physiotherapy in this young age patients is still unclear, without any accurate guidelines being elaborated, we can conclude that a child is able to "rehabilitate" himself as soon he resumes doing the functional movements he needs.

At long last, this might not be the case for patients passed the age of puberty; this area could need more research studies in order to offer the best outcomes possible.

Nonetheless, when complicated injuries occur, with difficulties in reduction and/or secondary displacement, the child's elbow might shows rigidity and lack of movement, with this in mind, we can assume that physiotherapy is of great help when complications take place.

9. ACKNOWLEDGMENT

I would like to thank Professor Tomislav Luetic, Department of Pediatrics Surgery, University Hospital Center Rebro, Zagreb, Croatia, for his mentorship and guidance throughout this project.

Additionally, I would like to thank my family, especially my parents and my sister for their unconditional support, my friends for they amazing companionship and the Hospitals of Paris and Rebro which taught me great clinical skills.

10. BIBLIOGRAPHY

1. Allyson S. Howe M. Common Pediatric Fractures. 2014.
2. Vialle R. Fractures chez l'enfant : particularités épidémiologiques, diagnostiques et thérapeutiques.
Question ENC n° 237
. D'après le Polycopié National rédigé par J Cottalorda (Saint-Etienne) BDBB, Chrestian P, editors.
3. Biomechanical differences between adult and child
The Royal Children's Hospital Melbourne: The Royal Children's Hospital Melbourne.
Available from: http://www.rch.org.au/fracture-education/biomechanics/Biomechanical_differences_between_adult_and_child/.
4. Bhatnagar R1 NN, Miller NH. Diagnosis and treatment of common fractures in children: femoral shaft fractures and supracondylar humeral fractures.
. J Surg Orthop Adv 2006 Spring;15(1):1-15. 2006.
5. Keppler P, Salem K, Schwarting B, Kinzl L. The effectiveness of physiotherapy after operative treatment of supracondylar humeral fractures in children. Journal of pediatric orthopedics. 2005;25(3):314-6.
6. Spady DW, Saunders DL, Schopfloch DP, Svenson LW. Patterns of injury in children: a population-based approach. Pediatrics. 2004;113(3 Pt 1):522-9.
7. Cooper C, Dennison EM, Leufkens HG, Bishop N, van Staa TP. Epidemiology of childhood fractures in Britain: a study using the general practice research database. Journal of bone and mineral research : the official journal of the American Society for Bone and Mineral Research. 2004;19(12):1976-81.
8. Erik M Hedström caOS, Ulrica Bergström, and Piotr Michno. Epidemiology of fractures in children and adolescents

Increased incidence over the past decade: a population-based study from northern Sweden. Acta orthopaedica. 2010.
9. Pediatric Humeral Fracture
Texas State University's Evidence-based Practice project space
Doctor of Physical Therapy program at Texas State University - San Marcos.:
Physiopedia. Available from: http://www.physiopedia.com/Pediatric_Humeral_Fracture.
10. Lord B, Sarraf KM. Paediatric supracondylar fractures of the humerus: acute assessment and management. British journal of hospital medicine. 2011;72(1):M8-11.
11. Assistant TR. Elbow-Fracture in Children The radiology Assistant. Available from: <http://www.radiologyassistant.nl/en/p4214416a75d87/elbow-fractures-in-children.html - i4214e87bb3255>.
12. Pediatric Elbow [Internet]. 2011. Available from: <http://fr.slideshare.net/handarmdoc/pediatric-elbow-examination-and-xrays>.
13. Melbourne TRCsH. Supracondylar fracture of the humerus - Emergency Department The Royal Children's Hospital Melbourne web page2014. Available from: http://www.rch.org.au/clinicalguide/guideline_index/fractures/Supracondylar_fracture_of_the_humerus_Emergency_Department/.

14. Gosens T, Bongers KJ. Neurovascular complications and functional outcome in displaced supracondylar fractures of the humerus in children. *Injury*. 2003;34(4):267-73.
15. Brubacher JW, Dodds SD. Pediatric supracondylar fractures of the distal humerus. *Current reviews in musculoskeletal medicine*. 2008;1(3-4):190-6.
16. T Chandraprakasam RAK. Acute compartment syndrome of forearm and hand . *Indian J Plast Surg*. 2011.
17. Thomas AP, Alpar EK. Outcome of supracondylar fractures of the humerus in children. *Journal of the Royal Society of Medicine*. 1987;80(6):347-51.
18. Otsuka NY, Kasser JR. Supracondylar Fractures of the Humerus in Children. *The Journal of the American Academy of Orthopaedic Surgeons*. 1997;5(1):19-26.
19. Madjar-Simic I, Talic-Tanovic A, Hadziahmetovic Z, Sarac-Hadzihalilovic A. Radiographic assessment in the treatment of supracondylar humerus fractures in children. *Acta informatica medica : AIM : journal of the Society for Medical Informatics of Bosnia & Herzegovina : casopis Drustva za medicinsku informatiku BiH*. 2012;20(3):154-9.
20. Pirone AM, Graham HK, Krajcich JI. Management of displaced extension-type supracondylar fractures of the humerus in children. *The Journal of bone and joint surgery American volume*. 1988;70(5):641-50.
21. Iyengar SR, Hoffinger SA, Townsend DR. Early versus delayed reduction and pinning of type III displaced supracondylar fractures of the humerus in children: a comparative study. *Journal of orthopaedic trauma*. 1999;13(1):51-5.
22. Mehlman CT, Strub WM, Roy DR, Wall EJ, Crawford AH. The effect of surgical timing on the perioperative complications of treatment of supracondylar humeral fractures in children. *The Journal of bone and joint surgery American volume*. 2001;83-A(3):323-7.
23. Leet AI, Frisancho J, Ebramzadeh E. Delayed treatment of type 3 supracondylar humerus fractures in children. *Journal of pediatric orthopedics*. 2002;22(2):203-7.
24. Carmichael KD, Joyner K. Quality of reduction versus timing of surgical intervention for pediatric supracondylar humerus fractures. *Orthopedics*. 2006;29(7):628-32.
25. Kishore Mulpuri M, MBBS, MS (Ortho), MHSc (Epi). New pediatric supracondylar humerus fractures CPG. Available from: <http://www.aaos.org/news/aaosnow/nov11/cover1.asp>.
26. Ponce BA, Hedequist DJ, Zurakowski D, Atkinson CC, Waters PM. Complications and timing of follow-up after closed reduction and percutaneous pinning of supracondylar humerus fractures: follow-up after percutaneous pinning of supracondylar humerus fractures. *Journal of pediatric orthopedics*. 2004;24(6):610-4.
27. Campbell CC, Waters PM, Emans JB, Kasser JR, Millis MB. Neurovascular injury and displacement in type III supracondylar humerus fractures. *Journal of pediatric orthopedics*. 1995;15(1):47-52.
28. McGraw JJ, Akbarnia BA, Hanel DP, Keppler L, Burdge RE. Neurological complications resulting from supracondylar fractures of the humerus in children. *Journal of pediatric orthopedics*. 1986;6(6):647-50.
29. Amillo S, Mora G. Surgical management of neural injuries associated with elbow fractures in children. *Journal of pediatric orthopedics*. 1999;19(5):573-7.
30. Shaw BA, Kasser JR, Emans JB, Rand FF. Management of vascular injuries in displaced supracondylar humerus fractures without arteriography. *Journal of orthopaedic trauma*. 1990;4(1):25-9.

31. Matuszewski L. Evaluation and management of pulseless pink/pale hand syndrome coexisting with supracondylar fractures of the humerus in children. *European journal of orthopaedic surgery & traumatology : orthopedie traumatologie*. 2013.
32. Voss FR, Kasser JR, Trepman E, Simmons E, Jr., Hall JE. Uniplanar supracondylar humeral osteotomy with preset Kirschner wires for posttraumatic cubitus varus. *Journal of pediatric orthopedics*. 1994;14(4):471-8.
33. PhysioAdvisor MoAPA. Elbow Stretches – Basic Exercises
Physioadvisor. Available from: <http://www.physioadvisor.com.au/8113013/elbow-flexibility-exercises-elbow-pain-elbow-in.htm>.
34. Bernthal NM, Hoshino CM, Dichter D, Wong M, Silva M. Recovery of elbow motion following pediatric lateral condylar fractures of the humerus. *The Journal of bone and joint surgery American volume*. 2011;93(9):871-7.
35. Jandric S. [Therapeutically effect of the physical procedures on the elbow contractures in children with supracondylar humerus fractures]. *Acta chirurgica Iugoslavica*. 2007;54(2):39-43.
36. Kraus R, Wessel L. The treatment of upper limb fractures in children and adolescents. *Deutsches Arzteblatt international*. 2010;107(51-52):903-10.
37. Zions LE, Woodson CJ, Manjra N, Zalavras C. Time of return of elbow motion after percutaneous pinning of pediatric supracondylar humerus fractures. *Clinical orthopaedics and related research*. 2009;467(8):2007-10.
38. de las Heras JI DD, de la Cerda J, Romanillos O, Martínez-Miranda J, Rodríguez-Merchán EC. Supracondylar fractures of the humerus in children. *Clin Orthop Relat Res*. 2005.
39. Oh CW, Park BC, Kim PT, Park IH, Kyung HS, Ihn JC. Completely displaced supracondylar humerus fractures in children: results of open reduction versus closed reduction. *Journal of orthopaedic science : official journal of the Japanese Orthopaedic Association*. 2003;8(2):137-41.
40. Sadiq MZ, Syed T, Travlos J. Management of grade III supracondylar fracture of the humerus by straight-arm lateral traction. *International orthopaedics*. 2007;31(2):155-8.
41. Pretell Mazzini J, Rodriguez Martin J, Andres Esteban EM. Surgical approaches for open reduction and pinning in severely displaced supracondylar humerus fractures in children: a systematic review. *Journal of children's orthopaedics*. 2010;4(2):143-52.
42. Kazimoglu C, Cetin M, Sener M, Agus H, Kalanderer O. Operative management of type III extension supracondylar fractures in children. *International orthopaedics*. 2009;33(4):1089-94.
43. Mulhall KJ, Abuzakuk T, Curtin W, O'Sullivan M. Displaced supracondylar fractures of the humerus in children. *International orthopaedics*. 2000;24(4):221-3.
44. Sibly TF, Briggs PJ, Gibson MJ. Supracondylar fractures of the humerus in childhood: range of movement following the posterior approach to open reduction. *Injury*. 1991;22(6):456-8.
45. Pretell-Mazzini J, Rodriguez-Martin J, Aunon-Martin I, Zafra-Jimenez JA. Controversial topics in the management of displaced supracondylar humerus fractures in children. *Strategies in trauma and limb reconstruction*. 2011;6(2):43-50.
46. Ramachandran M, Skaggs DL, Crawford HA, Eastwood DM, Lalonde FD, Vitale MG, et al. Delaying treatment of supracondylar fractures in children: has the pendulum swung too far? *The Journal of bone and joint surgery British volume*. 2008;90(9):1228-33.

47. Rasool MN, Naidoo KS. Supracondylar fractures: posterolateral type with brachialis muscle penetration and neurovascular injury. *Journal of pediatric orthopedics*. 1999;19(4):518-22.
48. Birch R, Achan P. Peripheral nerve repairs and their results in children. *Hand clinics*. 2000;16(4):579-95.
49. Sanglim Lee MSP, Chin Youb Chung, Dae Gyu Kwon, Ki Hyuk Sung, Tae Won Kim, In Ho Choi, Tae-Joon Cho, Won Joon Yoo, Kyoung Min Lee, [less]. Consensus and Different Perspectives on Treatment of Supracondylar Fractures of the Humerus in Children. *Clinics in Orthopedic Surgery* 2012.

11. BIOGRAPHY

Charlotte Julie Marion Vigneron was born and raised in a nice suburb around Paris, France, where she graduated from Lycee Theilhard de Chardin with a Scientific Baccalaureat high school diploma.

She attended two years of pre-medical classes at the University Rene Descartes Paris V, which is part of the Premier Cycle d'Etudes Medicales before transferring to the University of Zagreb School of Medicine in 2008.

Throughout the course of her studies Charlotte took the initiative of going abroad for clinical rotations and classes in France at the University Paris V Rene Descartes.

In addition, she added some research experience by realizing a biomedical research internship in Pediatric Kidney transplantation at Californian Pacific Medical Center in San Francisco, California, United States of America.

She entered medical studies in order to become a surgeon; she has yet not changed her mind.

Charlotte has taken the French Medical Residency board, Examen Classant National, in order to apply for a specialisation job and hope to become a surgeon.