

# Echocardiography in the emergency room

---

Jerčinović, Allen Nicholas

Master's thesis / Diplomski rad

2020

Degree Grantor / Ustanova koja je dodijelila akademski / stručni stupanj: **University of Zagreb, School of Medicine / Sveučilište u Zagrebu, Medicinski fakultet**

Permanent link / Trajna poveznica: <https://um.nsk.hr/um:nbn:hr:105:810456>

Rights / Prava: [In copyright](#)/[Zaštićeno autorskim pravom.](#)

Download date / Datum preuzimanja: **2025-03-08**



Repository / Repozitorij:

[Dr Med - University of Zagreb School of Medicine Digital Repository](#)



UNIVERSITY OF ZAGREB  
SCHOOL OF MEDICINE

Allen Nicholas Jerčinović

# **ECHOCARDIOGRAPHY IN THE EMERGENCY ROOM**

GRADUATION THESIS



This graduation paper was made at the Department for Cardiovascular Medicine at Sisters of Mercy University Hospital Center under the supervision of Doc. dr. sc. Nikola Bulj and was submitted for evaluation in the academic year 2019 / 2020.

Mentor: Doc. dr. sc. Nikola Bulj

## LIST OF ABBREVIATIONS

<b>2D</b>	Two Dimensional
<b>3D</b>	Three Dimensional
<b>A-mode</b>	Amplitude Mode
<b>A4C</b>	Apical Four Chamber View
<b>ACLS</b>	Advanced Cardiac Life Support
<b>AoV</b>	Aortic Valve
<b>ASE</b>	American Society of Echocardiography
<b>B-Mode</b>	Brightness Mode
<b>EACVI</b>	European Association of Cardiovascular Imaging
<b>ECG</b>	Electrocardiography
<b>Echo</b>	Echocardiography
<b>ED</b>	Emergency Department
<b>EF</b>	Ejection Fraction
<b>EP</b>	Emergency Physician
<b>FOCUS / FCU</b>	Focused Cardiac Ultrasound
<b>GP</b>	General Practitioner
<b>ICU</b>	Intensive Care Unit
<b>IVC</b>	Inferior Vena Cava
<b>LA</b>	Left Atrium
<b>LLD</b>	Left Lateral Decubitus
<b>LV</b>	Left Ventricle
<b>LVOT</b>	Left Ventricular Outflow Tract
<b>M-Mode</b>	Motion Mode
<b>MV</b>	Mitral Valve
<b>OR</b>	Operating Room

**LIST OF ABBREVIATIONS (CONTINUED)**

<b>PE</b>	Pulmonary Embolism
<b>PEA</b>	Pulseless Electrical Activity
<b>PSLA</b>	Parasternal Long Axis View
<b>RA</b>	Right Atrium
<b>RV</b>	Right Ventricle
<b>SUX</b>	Subxiphoid View
<b>SVC</b>	Superior Vena Cava
<b>TEE</b>	Transesophageal Echocardiogram
<b>TTE</b>	Transthoracic Echocardiogram
<b>US</b>	Ultrasound
<b>WMA</b>	Wall Motion Abnormalities

## TABLE OF CONTENTS

<b>LIST OF ABBREVIATIONS.....</b>	<b>I</b>
<b>SUMMARY.....</b>	<b>IV</b>
<b>SAŽETAK.....</b>	<b>V</b>
<b>1. INTRODUCTION.....</b>	<b>1</b>
<b>2. ECHOCARDIOGRAPHIC TECHNIQUE.....</b>	<b>2</b>
2.1. ANATOMY AND LANDMARKS OF THE HEART.....	2
2.2. ORIENTATION.....	3
2.3. IMAGING MODES.....	3
2.4. VIEWS OF THE HEART.....	6
<b>3. TRANSTHORACIC ECHOCARDIOGRAPHY.....</b>	<b>11</b>
<b>4. TRANSESOPHAGEAL ECHOCARDIOGRAPHY.....</b>	<b>11</b>
<b>5. ECHOCARDIOGRAPHY IN THE EMERGENCY DEPARTMENT.....</b>	<b>12</b>
<b>6. TERMINOLOGY.....</b>	<b>14</b>
6.1. EMERGENCY ECHOCARDIOGRAPHY.....	15
6.2. THE COMPLETE ECHOCARDIOGRAM.....	15
6.3. THE LIMITED ECHOCARDIOGRAM.....	15
6.4. FOCUSED CARDIAC ULTRASOUND.....	16
<b>7. GUIDELINES FOR ECHOCARDIOGRAPHY.....</b>	<b>16</b>
<b>8. EMERGENCY APPLICATIONS OF ECHOCARDIOGRAPHY.....</b>	<b>17</b>
8.1. PERICARDIAL EFFUSION AND CARDIAC TAMPONADE.....	18
8.2. PULMONARY EMBOLISM.....	19
8.3. MYOCARDIAL INFARCTION.....	21
<b>9. CONCLUSION.....</b>	<b>22</b>
<b>REFERENCES.....</b>	<b>23</b>
<b>ACKNOWLEDGEMENTS.....</b>	<b>26</b>
<b>BIOGRAPHY.....</b>	<b>27</b>

## SUMMARY

**Title:** Echocardiography in the Emergency Room

**Author:** Allen Nicholas Jerčinović

Echocardiography, in the hands of a skilled user, has proven to be a highly resourceful and efficient diagnostic tool. It provides real-time, localized, accurate information. Echocardiography can also be used to aid various bedside procedures, complementing them with added accuracy and proficiency.

Today, more than 60 years after its initial conception, echocardiography is established enough to be in a widespread use even outside the cardiology unit. As echocardiography expands into more diverse scenarios, hospitals have begun to develop and adopt protocols that call for the regular use of echocardiography in their emergency departments.

High yield emergency situations where echocardiography has shown great benefit include acute patient complaints due to chest pain, shortness of breath, or circulatory shock. Emergency echocardiography can also provide valuable data about a variety of conditions with cardiac involvement.

While echocardiography has shown great promise, results vary due to a number of factors. To promote the proficient use of echocardiography, numerous organizations have provided recommendations for its safe and efficient use in emergency settings. Echocardiography is often regarded as one of the most challenging ultrasound skills for emergency physicians to become comfortable with. Echocardiography, skillfully performed, is an invaluable method for the evaluation of acute cardiovascular presentations in the emergency department.

**Key Words:** Echocardiography, Emergency, Ultrasound, Cardiology, Emergency Medicine

## SAŽETAK

**Naslov Rada:** Ehokardiografija u Hitnim Stanjima

**Autor:** Allen Nicholas Jerčinović

Ehokardiografija se u rukama iskusnih korisnika pokazala kao vrlo snalažljiv i učinkovit dijagnostički alat. Omogućuje lokalizirane i točne informacije. Ehokardiografija se također može koristiti za pomoć u različitim postupcima uz krevet, nadopunjujući ih s dodatnom točnošću i stručnošću.

Danas, više od 60 godina nakon početka, ehokardiografija je uspostavljena za široku primjenu čak i izvan kardiološke jedinice. Kako se ehokardiografija širi na više različitih scenarija, bolnice su počele razvijati i usvajati protokole koji zahtijevaju redovitu upotrebu ehokardiografije u svojim hitnim odjelima.

Hitne situacije u kojima je ehokardiografija pokazala veliku korist uključuju akutne pritužbe pacijenta zbog boli u prsima, nedostatka daha ili krvožilnog šoka. Hitna ehokardiografija također može pružiti vrijedne podatke o različitim srčanim stanjima.

Iako ehokardiografija pokazuje velike mogućnosti, rezultati se razlikuju zbog niza čimbenika. Da bi promovirali stručno korištenje ehokardiografije, brojne organizacije pružile su preporuke za njenu sigurnu i učinkovitu upotrebu u hitnim situacijama. Često se ehokardiografija smatra jednom od najizazovnijih vještina ultrazvuka za liječnike hitne pomoći. Vješto izvedena ehokardiografija neprocjenjivo je vrijedna metoda za procjenu akutnih kardiovaskularnih stanja na odjelu hitne pomoći.

**Ključne Riječi:** Ehokardiografija, Hitne Službe, Ultrazvuk, Kardiologija, Hitna Medicina



## 1. INTRODUCTION

Since the adoption of clinical ultrasonography in the 1960's, the practice has spread to nearly every aspect of the medical field. Ultrasonography as an imaging procedure differs from other methods in that it can be performed by the treating physician and provide immediate, actionable information.

Ultrasound transmits high frequency sound waves through body tissues, some of which are reflected back and used to compile an image based on qualities of the returning signal. The benign nature these waves makes ultrasound one of the safest imaging modalities available. For these reasons ultrasonography quickly gained interest from emergency physicians and has been adopted and adapted in a wide range of emergency settings. This is increasingly true regarding emergency presentations with implications of cardiac involvement.

Echocardiography is the use of ultrasound to image cardiovascular structures and evaluate blood flow through them. Echocardiography, in the hands of a skilled user, has proven to be a highly resourceful and efficient diagnostic tool in the assessment of cardiovascular disease. Echocardiography is favored for its high patient safety and minimally invasive nature. Machines are relatively inexpensive and highly mobile, making them readily available in most centers. Moreover, echocardiography is able to provide data regarding functional status in real-time. It provides immediate, localized, and precise information. Details such as global ventricular systolic function and size, intravascular volume, and evidence of pericardial effusion can be elaborated through the use of echocardiography. Echocardiography can also be used to aid various bedside procedures such as central venous access or pericardiocentesis, complementing them with added accuracy and proficiency [6;9]. A selection of imaging modes are available which

enhance the visualization and interpretation of data during studies. Echocardiographic techniques including transthoracic and transesophageal and contrast echocardiography all add to the diagnostic capabilities. Due to these reasons many hospital centers have chosen adopt protocols that call for the regular use of echocardiography in emergency settings.

## 2. ECHOCARDIOGRAPHIC TECHNIQUE

### 2.1. ANATOMY AND LANDMARKS OF THE HEART

As the main sonographic landmarks of the heart are structures within the heart itself, an intimate knowledge of and familiarity with the anatomy and possible anatomical variations of the heart are essential. The normal heart sits in the left chest with its base anchored by the great vessels: the aorta, superior vena cava (SVC), and main pulmonary artery. The cardiac apex faces anterior inferior and with an angle of approximately 60 degrees to the left. The heart consists of two thicker walled ventricles, two thinner walled atria and four valves that direct flow between the chambers. The left heart is filled by the four pulmonary veins draining into the Left Atrium (LA). Blood flows between the anterior and posterior leaflets of the mitral valve (MV) into the thick walled left ventricle (LV) and out through the aortic valve/aorta. Blood returns from systemic circulation to the right heart via the superior vena cava (SVC) and inferior vena cava (IVC) which empty into the right atrium. From the right atrium (RA) blood passes to the right ventricle (RV) via the tricuspid valve and finally through pulmonary valve into the pulmonary circulation to repeat the cycle at the LA. By using different windows and views the distinct appearances of various structures are used to orient the user. For example, viewing the SVC and IVC as they drain into the RA can be helpful to gain orientation. Additionally, the cardiac apex provides a distinctive landmark from which to orient the

image. In the parasternal long axis view (PSLA) the apex is on the left side of the screen while in the subxiphoid (SUX) view the apex is on the right side of the screen.

## 2.2. ORIENTATION

A distinction to note when discussing echocardiographic technique by non-cardiologists, is the preferred convention for the orientation of the image. In cardiology an alternative image orientation to that of general ultrasound practices is traditionally used. In this alternate convention, the probe indicator corresponds to the right side of the screen as it is viewed, rather than to the left of the screen (See: Figure 3)[5;9]. Reversing the screen for certain images and/or parts of an exam can be time-consuming and confusing, especially under emergent conditions. For this reason most emergency physicians and labs follow the recommendation by the American Society of Echocardiography (ASE) to not adjust the screen orientation during emergency ultrasound. With this convention, the transducer position is depicted at the top of the screen, with anatomy more distant from the transducer depicted at progressively lower regions of the display, the lateral/left structures to the right, and medial/right structures to the left. (See: Figure 2) [5;9;14].

## 2.3. IMAGING MODES

Ultrasound imaging relies on variations of a signal traveling from the ultrasound transducer and reflected back to it. This signal is in the form of a high frequency sound wave which undergoes characteristic changes as it is attenuated, reflected, refracted, and absorbed. The transducer is able to both transmit and receive the signal due to the piezoelectric effect. The number and arrangement of transducer elements as well as the

pattern in which they fire varies, providing the ability to analyze multiple signals simultaneously. Using characteristics such as the amplitude of the returning signal, then correlating them to other variables an assortment of image types can be compiled each of which hold specific advantages and disadvantages. The following is a brief description of selected imaging modes:

#### *2.3.1. A-MODE*

This is the simplest form of ultrasound imaging. In A-mode, a single transducer element measures the returning signal and plots a graph of signal amplitude versus tissue depth. A-mode may be used to judge the depth of an organ or assess its size. However it is less commonly used today in favor of other imaging modes. A-mode may also be used in the calibration of other modes.

#### *2.3.2. B-MODE*

B-mode is the basis for two dimensional ultrasound imaging. In B-mode the amplitude of the signal is transformed to a grey-scale display. The image is comprised of bright dots correlating to signal amplitude. This mode provides two dimensional information about a cross-section. display of the amplitude vs. depth information from several scan lines in an imaging plane in real time. Some uses of B-mode include to measure the dimensions of cardiac chambers, or to assess valvular structure and function. B-mode is said to provide additional spatial resolution at the expense of temporal resolution.

#### *2.3.3. M-MODE*

M-mode provides a grey-scale display of amplitude from each depth along a scan line over time, with high temporal resolution [9]. It captures returning echoes in only one line of the B-mode image but displays them over time, resulting in a moving image. The

movement of structures positioned in that line can be visualized. Often M-mode and B-mode are displayed together on the ultrasound monitor. Because the focus of the scan is entirely on one line, the machine is capable of a higher rate of sampling. This high sample rate allows for a very high spatial and temporal resolution. For this reason M-mode is useful for tracking the movement of thin or fast moving structures, such as valves or endocardium.

#### *2.3.4. DOPPLER MODE*

Doppler mode utilizes the ‘Doppler shift’ phenomenon. This is characterized by the change of frequency seen in a returning wave, correlating with the velocity and direction of an observed particle. This mode is able to show blood flow or tissue motion in a selected two-dimensional area. Direction and velocity of tissue motion and blood flow are color coded and superimposed on the corresponding B-mode image.

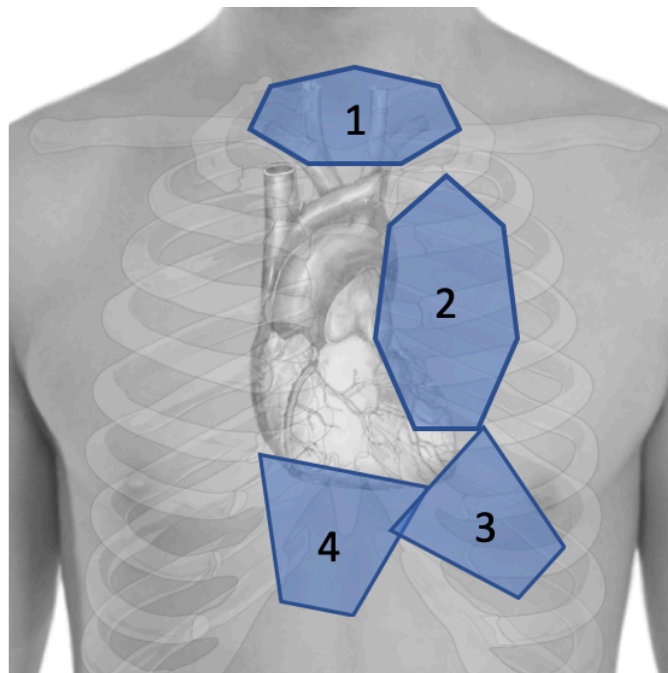
#### *2.3.5. THREE DIMENSIONAL IMAGING (3D):*

In a similar fashion to two dimensional imaging, an image is formed by displaying amplitude vs. depth from several scan lines. In 3D imaging, the imaging planes fill a pyramidal volume giving a larger field of view. The resulting image is a colorized display with a high spatial resolution. This is at the expense of processing time, equating to a reduced temporal resolution. By imaging several sequential cardiac cycles and combining them to produce a final image, this problem can be overcome. This method is not, however, considered to be true real-time.

## 2.4. VIEWS OF THE HEART

To maximize the likelihood of successful imaging and interpretation the heart is viewed from a number of cardiac windows and planes. Both patient habitus and underlying conditions affect the accessibility of the heart to echocardiographic evaluation. By using different positions, angles, and maneuvers one can develop a more complete picture of the structures in and around the heart. Each view of the heart is defined by the transducer position (i.e. parasternal, apical, subcostal, suprasternal) and image plane (i.e. long axis, short axis) [9;14].

Echocardiography is generally performed using one of two approaches: Transthoracic Echocardiography (TTE) and Transesophageal Echocardiography (TEE). Transthoracic Echocardiography is the most commonly employed method in emergency situations. However, TEE offers distinct benefits and may be called for in specific emergent situations depending on a number of factors which will be further discussed in

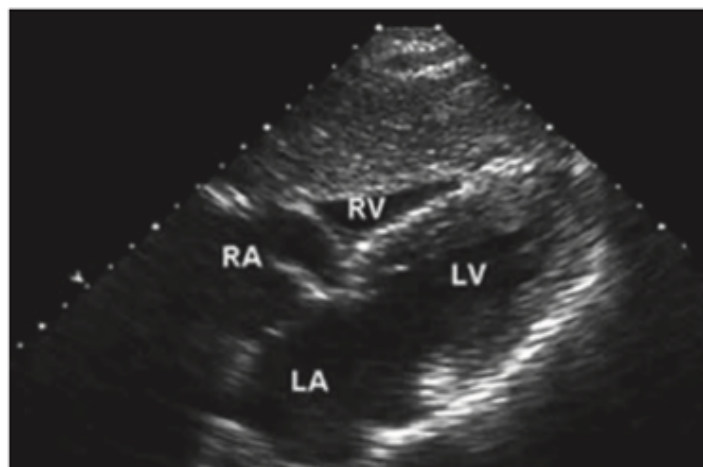

*Figure 1 The four primary echocardiographic windows: Suprasternal (position 1), Parasternal (position 2), Apical (position 3), and Subcostal (position 4)*

later sections. The following is a brief discussion of three of the most commonly used views in TTE: the subxiphoid, parasternal long axis, and apical four chamber views.

#### *2.4.1. SUBCOSTAL VIEW*

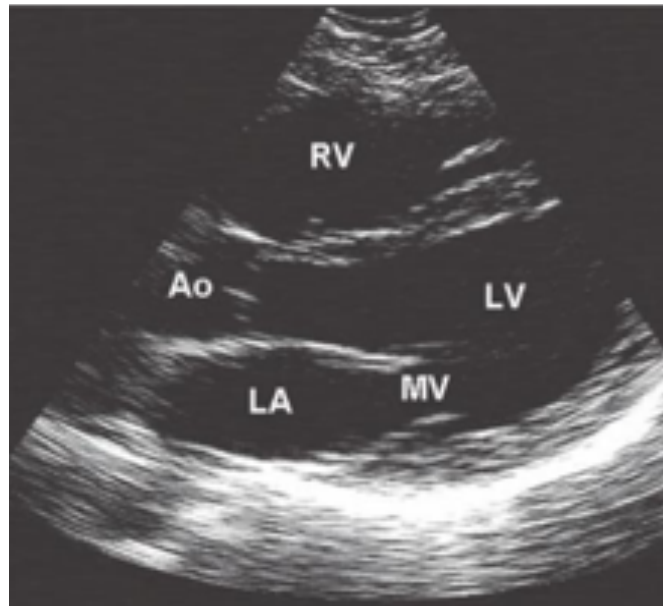
A common approach to image the heart is the subxiphoid or subcostal view. It is of particular benefit in patients with hyperexpanded lungs, in which other windows are poor. Unlike other cardiac views, this view is dependent on the left lobe of the liver as an acoustic window[2]. This view is obtained by placing the transducer on the abdomen facing towards the patients left shoulder (Position 4, Figure 1) [2;9;21]. The subcostal view is considered a good alternative when image quality is poor using the parasternal window[9]. This view is similar to the apical four-chamber view, but the interatrial and interventricular septa lie more perpendicular to the ultrasound beam making them more available for evaluation [9]. In the subxiphoid view, the RA, RV, LA, and LV are available for evaluation[21]. By rotating the transducer, the inferior vena cava can be visualized as it transitions to the right atrium. At this junction measurements can be taken to give a rough estimate of the right atrial pressure [9;21]. Further rotation of the transducer to a fully vertical position gives a long-axis view of the abdominal aorta.



*Figure 2 Subxiphoid View [22]*

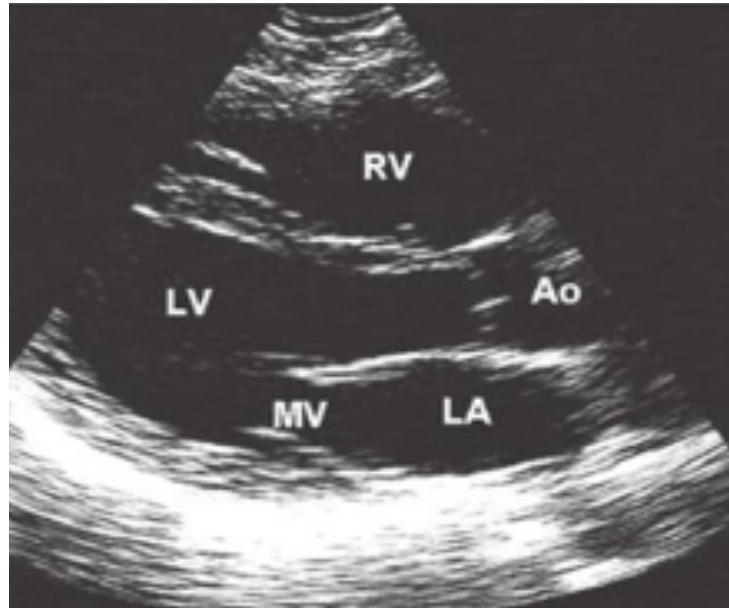
#### 2.4.2. PARASTERNAL LONG AXIS VIEW

The PSLA is a relatively easy to obtain and frequently used view. The long parasternal view is obtained by positioning the transducer on the parasternal area in the third or fourth intercostal space (Position 2, Figure 1) [9;21]. The probe is directed towards the patients right shoulder [21]. This view is often seen as complementary to the subxiphoid view, as well as provides a good alternative to the SUX view in patients with a poor SUX window. These patients generally have conditions causing a heart high in the chest or abdominal distention. This view visualizes the RA, LA, MV, LV, and LVOT. The anterior and posterior leaflets of the mitral valve are usually well visualized, along with the chordae tendinae and papillary muscles. The aortic valve may even be seen to open during systole. In this view pericardial effusions are often located posteriorly [21]. Positioning the patient in a left lateral decubitus position (LLD) may ease in obtaining this view.



*Figure 3 Parasternal Long Axis view with screen in orientation for emergency echocardiography performed by non-cardiologists. [22]*

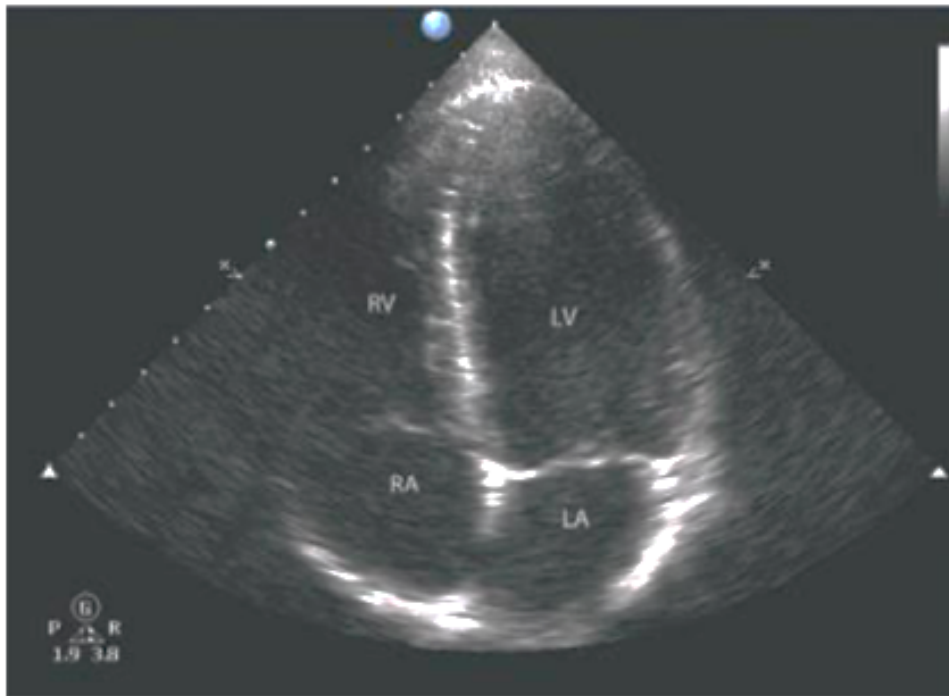



*Figure 4: Parasternal Long Axis view with screen in orientation for echocardiography performed by cardiologists. [22]*

#### 2.4.3. APICAL FOUR CHAMBER VIEW

The apical four chamber view is considered one of the most challenging views to obtain, but if mastered provides abundant information. This view demonstrates all four chambers of the heart. It enables simultaneous examination of all the cardiac cavities, the atrial and ventricular septum, and the atrioventricular junctions. The view is obtained by placing the transducer on the left chest in the region of the apex of the heart (Position 3, Figure 1). This view is useful for LV volume assessments, and the assessment of LV ejection fraction (EF). It is also an excellent option for assessing for pericardial effusion[9;21]. Doppler imaging can be used in this view to observe flow across the tricuspid, mitral, and aortic valves.



*Figure 5 Apical Four Chamber view [22]*

### 3. TRANSTHORACIC ECHOCARDIOGRAPHY

Transthoracic echocardiography is the initial echocardiography modality of choice in acute cardiac care, and indicated in the majority of cardiac emergencies [9]. In transthoracic echocardiography the transducer is positioned at various locations on the thorax while the view is adjusted by angling and rotating the transducer (See: Figure 1). Transthoracic echocardiography is the main method of performing cardiac ultrasound in emergency settings [12]. Thus, in the vast majority of this paper the method of echocardiography can be assumed to be TTE, unless specified otherwise.

### 4. TRANSESOPHAGEAL ECHOCARDIOGRAPHY

Transesophageal Echocardiography, as the name implies, approaches the heart via a transducer inserted down the esophagus. Generally, the probe sits in the esophagus directly posterior to the left atrium [16]. In emergency settings this technique can be used as a first choice method, or after a non-diagnostic TTE [12].

The relative lack of structures obstructing the view of the heart allows for superior imaging especially in situations that make TTE difficult or impossible. Using TEE, a practitioner can diagnose all the pathologies evaluated by TTE, often with added accuracy [13;18]. The transesophageal approach is taken advantage of by cardiac surgeons and anesthesiologists because it makes continuous monitoring possible.

In emergency settings such as the ED or ICU, TEE can be used to monitor resuscitation efforts during ACLS continuously, as opposed to the manner TTE is performed. TEE is also used to image patients on mechanical ventilation or with severe chest trauma or deformity [12;16]. Compared with TTE, TEE better demonstrates valvular pathology and pathology of the aortic arch [16]. TEE is contraindicated in

patients who are hypoxic and/or unable to protect their own airways without prior intubation and ventilation [9]. Practitioners must exclude and or correct any significant coagulopathy before insertion of the TEE probe. If necessary to minimize trauma, patients may be intubated in the esophagus using direct laryngoscopy. During the study, airway and hemodynamics must be managed by an intensivist/anesthetist, independent of the echocardiography practitioner, who can provide the required hemodynamic parameters as requested [9]

## 5. ECHOCARDIOGRAPHY IN THE EMERGENCY DEPARTMENT

As acute cardiac presentations, constitute a considerable portion of complaints seen in the emergency department [9;24], the ability to perform echocardiography has become a highly prized skill in emergency physicians. Further adding to the potential applications in the emergency department are the frequent presentations due to shortness of breath or suspected shock. As symptoms often overlap, and traditional methods may carry added risks, echocardiography provides a low threshold option to level the playing field. The effects of conditions such as ischemic heart disease, pulmonary emboli, congestive heart failure, pulseless electrical activity, and cardiac effusion or tamponade can be visualized with the use of echocardiography. Echocardiography can provide valuable information with high sensitivity in the evaluation of emergency conditions where the etiology is uncertain but are suspected to have cardiac involvement.

A challenge to the effective implementation of echocardiography in the ED is the availability of trained and skilled practitioners. Echocardiography is often regarded as one of the most challenging ultrasound skills for emergency physicians to become comfortable with. As time to diagnosis and therapy are of critical importance in the

emergency department, special consideration must be taken in the decision to perform any diagnostic procedure so as not to cause delay. This decision is generally made in consideration of the timeline of progression, the patient's presentation, as well as risk factors including age, family history, and comorbidities. This decision is further aided by protocols which indicate the appropriate use of urgent echocardiography. Frequently emergency physicians perform cardiac ultrasound as outlined by the guidelines for focused cardiac ultrasound assessments. Cardiac ultrasound is also utilized as a part of the FAST assessment which is commonly part of the curriculum for emergency physicians.

Though there is a relative lack of literature on the outcomes of echocardiography performed in the emergency room, a number of observational studies exist. These studies have shown promising outcomes for the use of echocardiography in the emergency room. In the evaluation of undifferentiated symptomatic and non-traumatic hypotension Jones et al. reported a 94% specificity for septic shock when a hyperdynamic LV was observed [4]. Tayal and Kline investigated the ability of emergency TTE to be used to assist in decision making in patients with pulseless electrical activity (PEA) or near PEA cardiac arrest [20]. This study observed that patients with no cardiac kinetic activity did not respond to advanced cardiac life support (ACLS) measures. The study also reported number of patients observed to have remaining kinetic activity, or even pericardial effusion whom showed a much better survival rate[20].

Echocardiography performed as a focused cardiac ultrasound (FCU) shows great promise in the emergency department when used in conjunction with ACLS. The goal of FCU in the treatment of acute cardiac arrest is to improve outcomes in a number of ways. FCU can be used to identify cardiac contractility and help distinguish among asystole,

PEA, and pseudo-PEA[8]. FCU also aims to determine a cardiac cause of the arrest, and to guide lifesaving bedside procedures [8]. In patients with undifferentiated shock, bedside echocardiography allows for rapid and accurate differentiation between the major shock types: distributive, cardiogenic, hypovolemic, and obstructive. Previous research on the use of cardiac ultrasound in the undifferentiated hypotensive patient presenting to ED showed that despite only taking an average of 6 minutes, its use led clinicians to significantly narrow their differential diagnosis and increase overall diagnostic precision.

## 6. TERMINOLOGY

Though the terminology varies with different conventions, in general echocardiographic exams may be classified as either limited or comprehensive[3;6;19]. Separate conventions recognize and distinguish procedures such as the focused cardiac ultrasound, Focused Assessment with Sonography in Trauma (FAST), or Emergency Cardiac Ultrasound (ECU) as individual procedures distinct from “Emergency Echocardiography”[19]. Echocardiography is also used in the setting of Advanced Cardiac Life Support (ACLS) to monitor changes during pulse checks. In recognition of this wide range of indications and methodologies, establishments such as the Intersocietal accreditation committee (IAC), European Association of Cardiovascular Imaging (EACVI), ASE, and American College of Emergency Physicians (ACEP) have all provided specific definitions and criteria for the use of echocardiography (or cardiac ultrasound) in distinct clinical settings.

### 6.1. EMERGENCY ECHOCARDIOGRAPHY

According to the Imaging EACVI Emergency Echocardiography is a specific term defined as a complete echocardiographic assessment in patients with unstable cardiovascular disease [12]. Emergency echocardiography specifically refers to the assessment of patients with suspected cardiovascular disease requiring immediate diagnosis and treatment. Emergency echocardiography is also distinguished from basic cardiac ultrasound in that it is only performed using a fully equipped echocardiographic machine and interpreted by the performing individual unaided [12]. This distinction has also been accepted in the United States by the ASE and IAC.

### 6.2. THE COMPLETE ECHOCARDIOGRAM

A comprehensive (or complete) echocardiographic imaging study is one which ‘examines all of the cardiac chambers and valves and the great vessels from multiple views, then uses the available information to completely define any recognized abnormalities [3].

### 6.3. THE LIMITED ECHOCARDIOGRAM

A limited study is generally only performed when the patient has recently undergone a complete examination and there is no clinical reason to suspect any changes outside the specific area of interest [3]. A limited study generally examines a single area of the heart or answers a single clinical question.

#### 6.4. FOCUSED CARDIAC ULTRASOUND

In urgent settings it may not be feasible to perform a comprehensive echocardiography examination. Investigations may be targeted to obtain specific information as part of an ongoing clinical examination, while omitting further ultrasonic investigation in favor of saved time. Carried out in this manner examinations fall under the convention of focused cardiac ultrasound. In the literature these studies may be referred to as FOCUS (FOcused Cardiac Ultrasound), or more recently as FCU. Focused echocardiographic studies allow for the rapid evaluation and differential of a number of conditions. These studies vary in their specific goal, but may also vary depending on the availability of equipment and skill level of the user. In contrast to comprehensive echocardiography which measures all parameters, FCU aims to identify the presence or absence of one or several specific findings by using a defined, preestablished image acquisition protocol[19].

### 7. GUIDELINES FOR ECHOCARDIOGRAPHY

This wide range of clinical settings and varying degrees of examination has necessitated the establishment of standards in education and training of practitioners, as well as specific guidelines for the safe and efficient use of emergency echocardiography. These standards are intended to improve confidence in decision making, ensure quality and accurate data, and save precious time. Not every case allows time for a comprehensive echocardiographic exam . Guidelines as to how, when, and who to perform echocardiography in emergency settings vary. A few major authorities on this topic are the European Association of Echocardiography(EAE), the European Association of Cardiovascular Imaging and the American Society of Echocardiography



(ASE). These organizations each provide detailed guidelines and protocols for the use of cardiac imaging. While emergency echocardiography may be performed by non-cardiologists, both the ASE and EACVI recommend a high level of competence in all practitioners performing echocardiographic examinations. Each competence level is based on specific criteria that varies between organizations, but are essentially based on physician abilities as well as specific hours of training and experience. In the United States laboratory accreditation is achieved by fulfilling requirements and standards set by the Intersocial Association of Accreditation. Individual sonographers are accredited by either the Cardiovascular Credentialing International (CCI) or American Registry for Diagnostic Medical Sonography (ARDMS). In the European Union, the European Association of Echocardiography provides accreditation. Each association recognizes the variety of uses of echocardiography, and defines distinct terms to refer to those uses.

## 8. EMERGENCY APPLICATIONS OF ECHOCARDIOGRAPHY

Echocardiography is regularly performed in emergency settings such as the intensive care unit (ICU), emergency department (ED), and the operating room (OR). Frequently, the individual performing the study is outside the specialty of cardiology. Emergency physicians (EPs), anesthesiologists, cardiac surgeons, and even general practitioners (GPs) may choose to utilize echocardiography. High yield situations where echocardiography has shown great benefit include emergency scenarios such as cardiac arrest in victims with non-shockable rhythms, pulmonary embolism, and acute presentations/complications of ischemic heart disease[16]. Echocardiography provides an additional diagnostic option in patients with non-diagnostic lab markers and ECG [9;16]. Patients with chest pain, shortness of breath, new onset murmurs, or suspected

circulatory shock may benefit from the additional diagnostic ability of echocardiography [12]. The scope of applications of echocardiography in emergency settings is vast and often overlap. The following sections will describe a small selection of conditions in which echocardiography can be used to enhance diagnostic capabilities.

### 8.1. PERICARDIAL EFFUSION AND CARDIAC TAMPONADE

Cardiac tamponade is characterized by the accumulation of pericardial fluid under pressure. Pericardial effusion occurs due to fluid or blood entering the pericardial space [7]. Small effusions can lead to cardiac tamponade if the effusion accumulates rapidly [7]. Pericardial effusion leads to stretching and eventual stiffening of the pericardium. Increases in pericardial pressure leads to compression of all cardiac chambers and abnormal hemodynamics of the right and left heart chambers. Cardiac tamponade has a wide variety of potential causes. However, common causes include previous pericarditis, cardiac trauma, or myocardial perforation during intravascular procedures[4]. Patients typically have tachycardia, hypotension, jugular venous distention, and diminished heart sounds. If cardiac tamponade develops sub-acutely, the patient may have peripheral edema, hepatomegaly, and ascites [4]. ECG findings include low limb lead voltage and electrical alternans with large effusions.

Ultrasound can successfully diagnose cardiac tamponade with an overall sensitivity greater than 96% and a specificity of 98% [16]. On TTE, pericardial effusion and signs of hemodynamic compromise can be visualized on ultrasound [16]. Hemodynamic changes can be seen on ultrasound as right atrial systolic collapse or right ventricular diastolic collapse [16]. Further studies using Doppler will reveal increases in tricuspid and pulmonic valve flow velocities during inspiration and lower velocities in

the pulmonic vein, mitral, and aortic valve [7]. These changes occur because Cardiac tamponade makes the four chamber pressures equal and there is greater venous return and RV filling volume [7]. When there is a large amount of pericardial effusion, a swinging motion of the heart can be seen in the pericardial cavity on ultrasound [7].

Ultrasound-guided pericardiocentesis is recognized as a highly successful treatment with a success rate of 90% [16]. Careful evaluation of the ultrasound findings should be done before pericardiocentesis is performed, as pleural effusions and epicardial fat pads can be mistaken for pericardial effusions [16]. Echocardiography is used to provide guidance of the needle and by determining the depth of the pericardial effusion, typically from the subcostal view [7]. It is useful to confirm the position of the needle by imaging with administration of agitated saline [7].

## 8.2. PULMONARY EMBOLISM

Acute Pulmonary embolism (PE) is an important clinical problem with a high mortality. PE is typically due to a deep-vein thrombosis (DVT), where thrombi have broken off and traveled to the pulmonary arterial circulation. DVTs are usually due to thrombus formation in the legs. However, indwelling venous catheters, pacemakers, and internal cardiac defibrillators are associated with upper extremity DVTs. Risk factors for venous thromboembolic disease include cancer, antiphospholipid syndrome, prolonged immobilization, genetics, smoking, surgery, pregnancy, oral contraceptives, and postmenopausal hormone replacement [4].

Patients typically present with cough, chest pain, tachypnea and tachycardia. However, the symptoms and signs of PE are nonspecific and overlap with many other conditions. ECG findings associated with PE (S1Q3T3, atrial tachyarrhythmias,

incomplete right bundle-branch block) are useful in diagnosing PE, but these findings are not always seen. In fact, up to 33% of patients with PE have a normal ECG[23]. While measurement of serum D-dimers and contrast enhanced CT are the main standard diagnostic tools used for PE diagnosis, echocardiography can also play an important role.

Echocardiography is a readily available and versatile tool that can be used to assess RV dysfunction. RV dilation is a common finding seen on echocardiography in a massive PE. Shifting of the interventricular septum may also be seen due to the increased pressure of the pulmonary artery [7].

Furthermore, McConnell's sign (coexistence of RV hypokinesis and preserved apical contractility) is a useful bedside tool for identifying PE. However, studies have reported a low sensitivity of McConnell's sign. Other findings seen in the setting of PE include RV dilation, an increased RV-LV diameter ratio, increased velocity of the jet of tricuspid regurgitation, and decreased tricuspid annulus plane systolic excursion [23].

The ability to detect RV dysfunction with echocardiography also plays an important role in the diagnostic pathway and management of PE patients. A recent study observed a two-fold increase in mortality at 2 weeks and 3 months in patients with RV hypokinesis. TEE is a useful method to visualize the main pulmonary trunk and its bifurcation [7]. TEE is able to identify a large central PE if CT scans with IV contrast are not appropriate, such as in the setting of renal failure or severe contrast allergy. Studies have shown that TEE has a comparable sensitivity (80-97%) and specificity (86-100%) with CT for detecting PE [7].

### 8.3. MYOCARDIAL INFARCTION

Chest pain is a common chief complaint of patients in the emergency room. Rapid evaluation and diagnosis of these patients is critical to determine whether they require hospitalization. This process is a challenge due to large number of patients that have atypical symptoms, nonspecific ECG changes or normal cardiac enzyme levels. Evaluation of a possible myocardial infarction includes the patients history, ECG findings and cardiac biomarkers. If the diagnosis is uncertain due to nonspecific symptoms or ECG findings, ECHO can be used to detect myocardial dysfunction caused by ischemia or necrosis [7]. In the emergency room, it is important to first evaluate ventricular function and the presence of wall motion abnormalities (WMAs), which occur within seconds of coronary artery occlusion. WMAs vary due to the transmural extent of the infarction and limits of the abnormality depend on the coronary artery distribution [7]. Because these changes may occur even before ECG changes or the onset of symptoms, ECHO is useful in the setting of a nondiagnostic ECG or in the situation of ECG findings without chest pain. It is important to note that WMAs may be due to a prior infarction, myocarditis, prior surgery, left bundle branch block, and cardiomyopathy. Therefore, ECHO has a high sensitivity but low specificity for acute coronary syndromes.

RWAs can be assessed on multiple image views. If parasternal and apical views are of poor quality, subcostal views may be used to detect RWAs [1]. Evaluation of wall thickness is also useful to help differentiate between normal and infarcted myocardium [1]. ECHO may also be used to rule out other etiologies of acute chest pain such as pericardial effusion [1].

Invasive measurements of cardiac output and pulmonary capillary wedge pressure is common practice for patients who develop cardiogenic shock or cardiac failure post-

MI [1]. Despite providing useful information to guide treatment, this process carries a risk of increased mortality in patients. Doppler ECHO can be used to non-invasively determine the hemodynamic changes in the patient after infarction and guide patient therapy [1].

## 9. CONCLUSIONS

The procedure for an echocardiographic assessment of the cardiovascular system is continuously being refined according to advances in research and technology. However, the appropriate clinical application of this unique diagnostic technique in the acute setting requires specific education with constant updates and training. (#40)

There are several caveats in regards to the use of echocardiography in emergency settings. The interpretation of data from echocardiograms is highly subjective. Quality of data varies greatly depending on the experience of the physician conducting the study, the clinical setting, and the quality of communication. The scope of applications of echocardiography in emergency settings is vast. Not every case warrants a comprehensive echocardiographic exam. Guidelines as to how, when, and who to perform echocardiography in emergency settings vary. These guidelines are intended to improve confidence in decision making, ensure quality and accurate data, and save precious time.

Echocardiography remains an indispensable tool for the evaluation of acute cardiovascular presentations and complications and shows promise for future added potential. With the growth in the number of trained physicians on the field and technological advances, standards and guidelines will continue to improve and evolve.

## REFERENCES

- [1]. Esmailzadeh M, Parsaee M, Maleki M. The role of echocardiography in coronary artery disease and acute myocardial infarction. *J Tehran Univ Hear Cent.* 2013;8(1):1–13.
- [2]. Hoffmann B, Reardon R, Dean AJ, Bahner DP, Fox JC, Blok BK, et al. SONOGUIDE [Internet]. Sonoguide ultrasound guide for emergency physicians. 2008 [cited 2020 Jun 5]. Available from: <https://www.acep.org/sonoguide/introduction.html>
- [3]. Intersocietal. IAC Standards and Guidelines for Adult Echocardiography Accreditation [Internet]. Intersocietal.org. 2014 [cited 5 June 2020]. Available from: [https://www.intersocietal.org/echo/seeking/echo\\_standards.htm](https://www.intersocietal.org/echo/seeking/echo_standards.htm)
- [4]. Jones AE, Craddock PA, Tayal VS, Kline JA. Diagnostic accuracy of left ventricular function for identifying sepsis among emergency department patients with nontraumatic symptomatic undifferentiated hypotension. *Shock.* 2005;24(6):513–7.
- [5]. Kasper D, Fauci A, Hauser S, Longo D, Jameson J L. Disorders of the Cardiovascular System. In: *Harrison's Principles of Internal Medicine.* 19th ed. McGraw Hill; 2015. p. 1439–660.
- [6]. Kendall JL, Bahner DP, Blaivas M, Budhram G, Dean AJ, Fox JC, et al. Emergency Ultrasound Imaging Criteria Compendium. Vol. 68, *Annals of Emergency Medicine.* 2016. p. e11–48.
- [7]. Kim T-S, Youn H-J. Role of Echocardiography in the Emergency Department. *J Cardiovasc Ultrasound.* 2009;17(2):40–53.
- [8]. Labovitz AJ, Noble VE, Bierig M, Goldstein SA, Jones R, Kort S, et al. Focused cardiac ultrasound in the emergent setting: A consensus statement of the American society of Echocardiography and American College of Emergency Physicians. *J Am Soc Echocardiogr.* 2010;23(12):1225–30.
- [9]. Lancellotti P, Zamorano JL, Habib G, Badano LP, editors. *The EACVI Textbook of Echocardiography.* 2nd ed. Oxford: Oxford University Press; 2017.
- [10]. Mitchell C, Rahko PS, Blauwet LA, Canaday B, Finstuen JA, Foster MC, et al. Guidelines for Performing a Comprehensive Transthoracic Echocardiographic Examination in Adults: Recommendations from the American Society of Echocardiography. *J Am Soc Echocardiogr.* 2019;32(1):1–64.

- [11]. Neskovic AN, Edvardsen T, Galderisi M, Garbi M, Gullace G, Jurcut R, et al. Focus cardiac ultrasound: The European Association of Cardiovascular Imaging viewpoint. *Eur Heart J Cardiovasc Imaging*. 2014;15(9):956–60.
- [12]. Neskovic AN, Hagendorff A, Lancellotti P, Guarracino F, Varga A, Cosyns B, et al. Emergency echocardiography: The European Association of Cardiovascular Imaging recommendations. *Eur Heart J Cardiovasc Imaging*. 2013 Jan;14(1):1–11.
- [13]. O'Rourke MC, Mendenhall BR. Transesophageal Echocardiogram (TEE) [Internet]. StatPearls. 2019 [cited 2020 Jun 5]. Available from: <https://www.ncbi.nlm.nih.gov/books/NBK442026/>
- [14]. Patel AR. Transesophageal echocardiography: Indications, complications, and normal views [Internet]. UpToDate. 2020 [cited 2020 Jun 5]. Available from: [https://www.uptodate.com/contents/transesophageal-echocardiography-indications-complications-and-normal-views?search=transesophageal-echocardiography&source=search\\_result&selectedTitle=1~150&usage\\_type=default&display\\_rank=1#H9](https://www.uptodate.com/contents/transesophageal-echocardiography-indications-complications-and-normal-views?search=transesophageal-echocardiography&source=search_result&selectedTitle=1~150&usage_type=default&display_rank=1#H9)
- [15]. Patel AR. Transthoracic echocardiography: Normal cardiac anatomy and tomographic views [Internet]. UpToDate. 2019 [cited 2020 Jun 6]. Available from: <https://www.uptodate.com/contents/transthoracic-echocardiography-normal-cardiac-anatomy-and-tomographic-views>
- [16]. Prats MI, Martinez CL. New Concepts of US in ED Focused Cardiac US in Cardiac Arrest. *Emergency Medicine Reports*. 2018.
- [17]. Sarti (ed.) A, Lorini (ed.) F. Textbook of echocardiography for intensivists and emergency physicians. 2nd ed. Cham: Springer;.
- [18]. Sengupta PP, Khandheria BK. Transoesophageal echocardiography. *Heart*. 2005;91(4):541–7.
- [19]. Spencer KT, Kimura BJ, Korcarz CE, Pellikka PA, Rahko PS, Siegel RJ. Focused cardiac ultrasound: Recommendations from the american society of echocardiography. *J Am Soc Echocardiogr*. 2013;26(6):567–81.
- [20]. Tayal VS, Kline JA. Emergency Echocardiography to Detect Pericardial Effusion in Patients in PEA and near-PEA States. *Resuscitation*. 2003;59(3):315–8.



- [21]. Taylor RA, Moore CL. Echocardiography. In: Practical Guide to Emergency Ultrasound. 2nd ed. Chicago: Wolters Kluwer Lippincott Williams & Wilkins; 2013. p. 55–71.
- [22]. Taylor RA, Moore CL. Echocardiography. In: Practical Guide to Emergency Ultrasound. 2nd ed. Chicago: Wolters Kluwer Lippincott Williams & Wilkins; 2013. p. 59. Figure 4.6 Primary Bedside echo Windows. The subxyphoid (SX), apical four chamber (A4C), and parasternal long axis (PSLA) views are shown. Note how the subxyphoid is similar to the apical four-chamber, only the apical four-chamber image is rotated slightly counterclockwise. The parasternal long axis is very similar to the subxyphoid, only the parasternal long axis is at a higher level (includes aortic root). The image typically seen in a cardiology parasternal long axis is shown for reference; it is flipped 180 degrees. If desired, this image may be obtained by rotating the probe 180 degrees or flipping the screen orientation. Right ventricle (RV), left ventricle (LV), right atrium (RA), left atrium (LA), mitral valve (MV), aorta (Ao).
- [23]. Torbicki A, Perrier A, Konstantinides S, Agnelli G, Galiè N, Pruszczyk P, et al. Guidelines on the diagnosis and management of acute pulmonary embolism. *Eur Heart J*. 2008;29(18):2276–315.
- [24]. Zavod Za Javno Zdravstvo . Croatian Health Statistics Yearbook 2017 [Internet]. HZJZ.hr. 2018 [cited 26 May 2020]. Available from: <https://www.hzjz.hr/en/statistical-data/croatian-health-statistics-yearbook-2017-tabular-data/>

## ACKNOWLEDGEMENTS

I would like to thank my mentor Doc. dr. sc. Nikola Bulj for his enthusiasm, knowledge, and experience that he kindly shared with me. I would also like to thank the other members of the Department for Cardiovascular Medicine at Sisters of Mercy University Hospital Center, as well as the other members of my graduation thesis committee: Prof. dr. sc. Diana Delić-Brkljačić and Prof. dr. sc. Martina Lovrić Benčić. Thank you all kindly for your time and efforts.

## BIOGRAPHY

Allen Nicholas Jerčinović is a first generation Croatian-American born in the Chicago suburb of Oak Lawn, Illinois in December of 1989. Later, he and his family moved to Joliet, Illinois, where he eventually graduated from Joliet West High School. Following high school, Allen was accepted to Lewis University of Romeoville, Illinois where he completed a four year Bachelor of Science (B.Sc.) degree in biology with a focus on medical sciences. In the years following graduation Allen applied his knowledge to designing and building a number of experimental soil-less farming systems, as well as working as a full-time medical assistant in a pediatrics clinic. In 2014 he sought his true passion and enrolled in the University of Zagreb, School of Medicine.

His hobbies include cooking, hiking, woodworking, and spending time with his friends and family.