

Morphological variation of ulnar dimelia

Schwarz, David Oscar Benjamin

Master's thesis / Diplomski rad

2020

Degree Grantor / Ustanova koja je dodijelila akademski / stručni stupanj: **University of Zagreb, School of Medicine / Sveučilište u Zagrebu, Medicinski fakultet**

Permanent link / Trajna poveznica: <https://um.nsk.hr/um:nbn:hr:105:353195>

Rights / Prava: [In copyright](#)/[Zaštićeno autorskim pravom.](#)

Download date / Datum preuzimanja: **2025-03-10**



Repository / Repozitorij:

[Dr Med - University of Zagreb School of Medicine Digital Repository](#)



**UNIVERSITY OF ZAGREB
SCHOOL OF MEDICINE**

David Schwarz
Morphological variation of ulnar dimelia

GRADUATE THESIS



Zagreb, 2020

This graduate thesis was made at the Department Plastic Surgery, at the University Hospital Center Zagreb, KBC Rebro, mentored by docent, professor, senior lecturer Krešimir Bulić and was submitted for evaluation in the academic year of 2019/2020.

Table of Contents

	Summary	4
	Sažetak	5
1.	Introduction	6
2.	Pathophysiology	8
3.	Morphological variation of ulnar dimelia	10
4.	Variation table extracted from case reports	17
5.	Surgical approaches	21
6.	Anatomical findings after the surgery	27
7.	Discussion	28
8.	Acknowledgements	30
9.	References	31
10.	Biography	34

Summary

Title: Morphological variation of ulnar dimelia

Author: David Schwarz

Ulnar dimelia is a rare congenital disease with a characteristic range morphological of changes. These include duplication of the ulna, absence of the radius and polydactyly, although there is great variation of the changes seen in specific reports. Here I describe the main pathophysiological mechanisms, morphological variations as well as commonly used surgical strategies for this condition. For this purpose, I have screened the major databases to find the relevant literature and created a pooled analysis table for the morphological variations. The parameters used for the summarizing, include number of the upper limb fingers on the affected side, absence/presence of the thumb, type of the ulnar duplication, active and passive movement range, functional capability of the affected hand as well as the preceding events and the gender of the patient. For some of them I have discussed the surgical strategies and the long-term outcomes.

All in all, this condition is characterized by a wide range of morphological variations. Further investigations should be performed to have a complete picture and strong classification algorithm for this extremely rare disease.

Keywords: ulnar dimelia, congenital disease, polydactyly.

Sažetak

Sažetak Naslov: Morfološka varijacija ulnarne dimelije

Autor: David Schwarz

Ulnarna dimelija je rijetka kongenitalna bolest karakterističnog raspona morfoloških promjena. One uključuju dupliciranje ulne, odsutnost radijusa i polidaktiliju, iako postoje velike razlike u promjenama koje su opažene u određenim izvješćima. Ovdje opisujem glavne patofiziološke mehanizme, morfološke varijacije kao i uobičajene kirurške strategije za ovo stanje. U tu svrhu pregledao sam glavne baze podataka da bih pronašao relevantnu literaturu i stvorio zbirnu analiznu tablicu za morfološke varijacije. Parametri korišteni za rezimiranje uključuju broj prstiju gornjih udova na zahvaćenoj strani, odsutnost / prisustvo palca, vrstu ulnarne duplikacije, raspon aktivnog i pasivnog pokreta, funkcionalnu sposobnost zahvaćene ruke kao i prethodne događaje i spol bolesnika. Za neke od njih sam raspravljao o kirurškim strategijama i dugoročnim ishodima.. Sve u svemu, ovo stanje karakterizira širok raspon morfoloških varijacija.

Potrebno je provesti daljnja ispitivanja kako bi se stvorila cjelovita slika i algoritam za klasifikaciju ove izuzetno rijetke bolesti.

Ključne riječi: ulnarna dimelija, urođena bolest, polidaktilija

Introduction

Ulnar dimelia, also called a mirror hand deformity, is a rare congenital anomaly. There is a lack of evidence about the worldwide incidence of this pathological condition and few reports are available. The first extensive report about this phenomenon was published back in 1974 by Kellikian et al., 1974 (1). According to Al-Qattan and Al-Thunanyan (2), there is proposed classification of the minor hand *syndrome* which is based on presence of other congenital anomalies and the quantity of forearm present. According to the classification, the type 1 includes ulnar dimelia, type 2 is characterized by having two ulnae and one radius, type 3 includes one radius and one ulna, type 4 includes cases with associated anomalies (syndromic) and type 5 includes multiple hands on a single limb. Although this classification has somewhat broader scope, the key characteristics of the ulnar dimelia syndrome include:

1. duplication of the ulna (the term ulnar dimelia comes from the fact the forearm contains two ulnae) (3)
2. absence of the radius and thumb
3. polydactyly -supernumerary fingers are formed on the radial side of the fingers of the normal hand.
4. the fingers are arranged symmetrically to the midline (not always)

Although the majority of cases are unilateral, there is an available literature about the bilateral development of ulnar dimelia as well (4).

In figure 1 you can see the typical appearance of mirror hand and its radiographic picture.

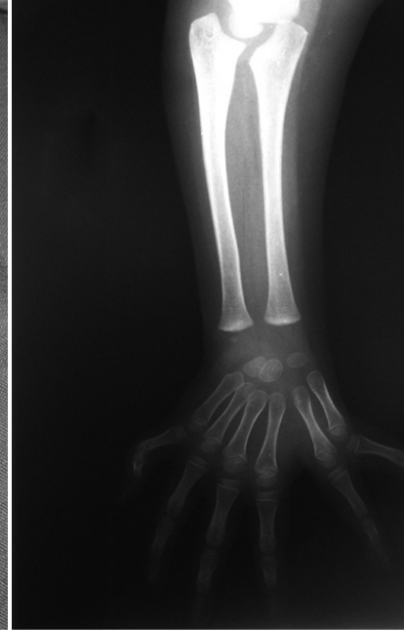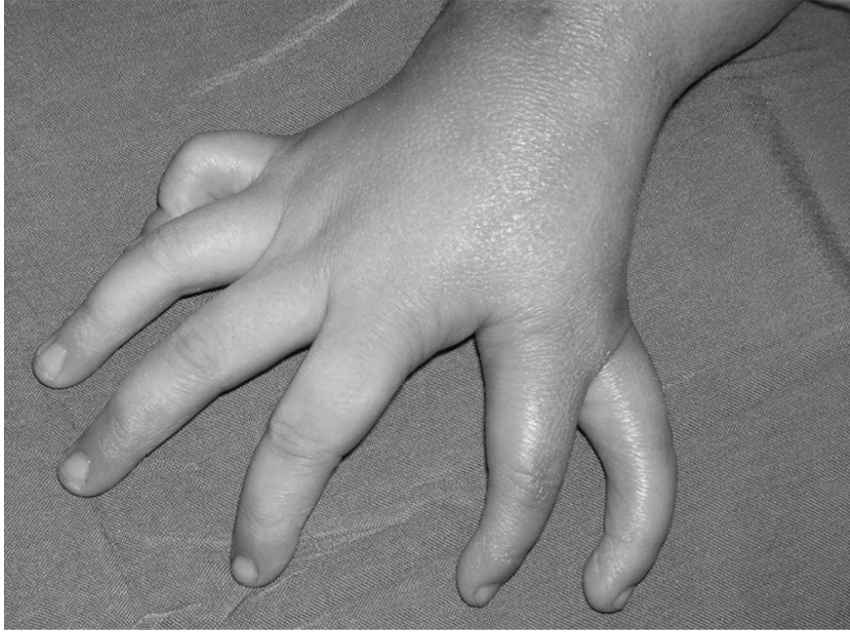


Figure 1 . A. Photograph of the asymmetrical mirror hand showing six digits arranged in two groups.

B. Radiographic picture

Source: *A. Afshar et. al, 2009*

Pathophysiology

The occurrence of ulnar dimelia is based on the hypothesis, that development of the distal parts of the limbs is determined by the more proximal segments. Thus, the occurrence of ulnae determines further development of more distal parts. However, the case report of a lateral forearm bone with the features of a radius in the case described by Richard J. King et al., is in conflict with this hypothesis. There is an alternative hypothesis as well, which states that the development of the limb segments is induced by the cap of ectoderm which is present at the apex of the developing limb bud (5). Early and progressive development of deficiencies in the terminal cap could be the initiation force not only for the presence of two ulnae, but also for various other abnormalities in successive limb segments, such as failure of development of a thumb in cases of absence of the radius as discussed by Harrison et al., 1960 (6). Although, the basis of the deficiencies in the apical cap which are the source for the abnormalities observed in cases of mirror hand is unknown, it is possible that these changes are due to aplasia or degeneration of cells in the center of the cap and it's at least partial division into two parts

(7). It is already known that the group of the mesenchymal cells called the zone of polarizing activity is responsible for the correct development of the radio-ulnar aspect of the of the limb. This group of cells can be referred as the epicenter for the anteroposterior development of the limb, and is located in the posterior side of the limb. The morphology of the tissue is determined by the concentration gradient of the signals generated from the cells. Interestingly, when researchers have tried to isolate the pre-axial and post-axial portions of the limb bud, the development continued on only one side. It can be inferred, that failure of the signals to induce the pre axial side differentiation of the limb will may bring to radial deficiency (12). Furthermore, the duplication can be produced by transplanting the zone of polarizing activity to the radial side of the limb (22). It is possible that the various forms of the anomaly can be due to altered balance of the generated signal across radio-ulnar aspect. In addition, the Fibroblast growth factor type 4 (FGF 4) and sonic hedgehog gene are responsible for limb patterning along it's anteroposterior axis. Either the abnormal positioning of the

zone of polarizing activity and the aberrant signaling of the sonic hedgehog gene can be responsible for the impairment leading to ulnar dimelia. In addition, secondary signaling molecules such as bone morphogenic proteins and certain Hox genes were described to be responsible for the development of mirror image deformities. The changes characteristic for upper limb abnormalities are described in cases when there was observed deletion or rearrangement of genetic material of GLI3 gene (26). GLI3 is the gene responsible for Greig cephalopolysyndactyly syndrome (GCPS), Pallister–Hall syndrome (PHS) and Postaxial polydactyly type-A (PAP-A). The last is autosomal dominant trait, and is characterized by an extra digit in the postaxial and/or preaxial side of the upper and/or lower extremities. In addition, heterozygous mice with mutant GLI3 gene had alternating numbers of extra digits on the preaxial axis in the forelimbs . Occasionally there has been observed a postaxial rudimentary digit, suggesting possible role of GLI3 protein in the development of limb abnormalities (26). The deficiency of extensor muscles seen in the majority of cases can be due to the failure of the development of the mesoderm or its early incorporation into the anterior aspect of the forearm. The underlying genetic causes of this condition need to be investigated, although, Sandrow et al. described a case (8), where both the father and daughter had ulnar dimelia.

Morphological variations of the ulnar dimelia

The key characteristics of ulnar dimelia can be sparse. A case report published by *Javed Jameel et al (9)*., describes a case of ulnar dimelia with multiple fingers arranged symmetrically to the midline, while ulnae were arranged asymmetrical (Figure 2A). The radiographic images showed two ulnae with broadened distal end (Figure 2 B.) Although shoulder passive movements were normal, there was gross restriction of the supination and pronation at forearm. The patient was 2 years old female. There was no family history and the antenatal period was uneventful.

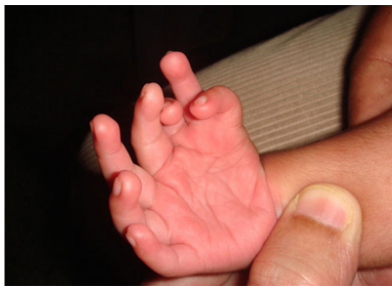
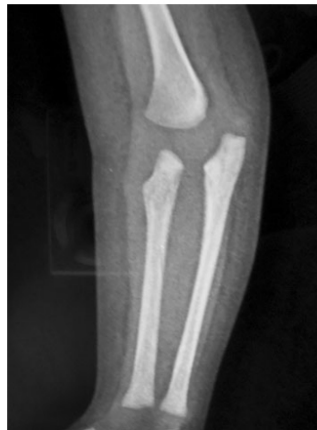
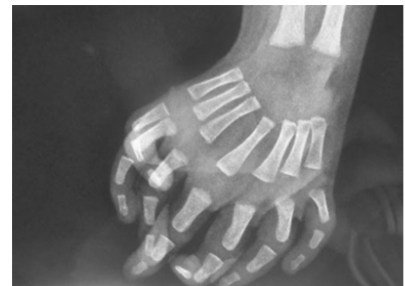Figure 2A. Palmar aspect of hand with seven well-formed digits arranged symmetrically



B. Radiograph of affected limb showing two ulnae with broadened distal end and absent radius



C. Radiograph of hand shows seven triphalangeal digits with seven corresponding metacarpals

Source: *Javed Jameel et al., 2011*

In a case described by *S. Steven Young et al. (10)*, the only morphological change, revealed during the antenatal ultrasonography performed on the 3rd month of gestational period, was polydactyly. As with the other case, the vaginal delivery was without complications and the family history was clear for musculoskeletal abnormalities. Interestingly the polydactyly was accompanied by the absence of ulnar dimelia. This was a rarer subset of hand duplication in which there is a normal radius and ulna (Figure 3B). The boy could hold his head and was able to seat independently.

The functionality of ulnar 4 digits was relatively normal. However, the radial 4 digits were grouped in some opposition to the ulnar 4 fingers with a flexed posture (Figure 3A). They could be actively extended although. The most ulnar of the group of radial digits was biphalangeal, and the most radial 2 digits were syndactylized to the level of the proximal interphalangeal joint (Figure 3A).

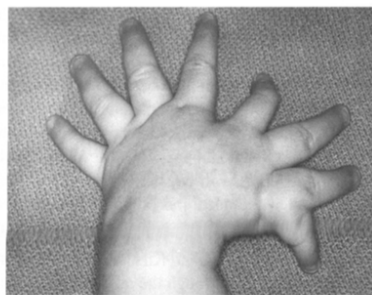
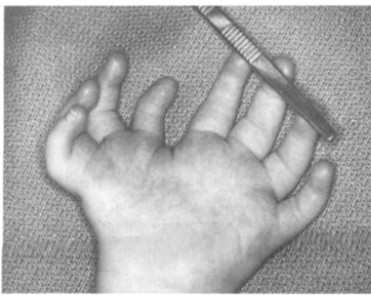
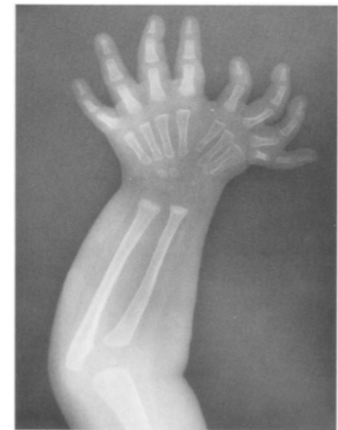

Figure 3 A. Two groups of four digits of the eight-digit hand. The radial four digits assume a flexed posture at rest. The third and fourth digits from the radial border of the hand exhibit incomplete syndactyly.



B. A well-formed radius and ulna on the radiograph

The hand of the patient-reported by *Richard J. King et al. (7)*, had eight fingers and no radius, although the lateral forearm developed number of features resembling the radius. The four fingers on the radial side were similar to those on the ulnar side and resembled the little, ring, middle and index fingers of a separate hand (Figure 4 A,B). Although there was no family history of congenital anomalies, the pregnancy was complicated by hydramnios. The amplitude of the movements at shoulder was normal. The fixed flexion deformity at the elbow was of 30 degrees. The forearm was shorter in comparison with its healthier counterpart. The child was unable to actively extend her wrist. The metacarpophalangeal and interphalangeal joint movement range of movements both passive and active, was with the normal range.

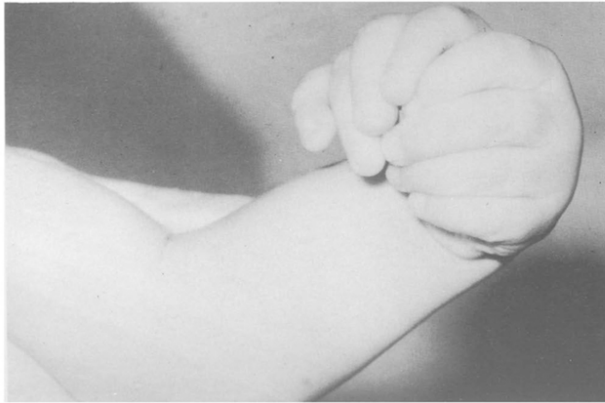
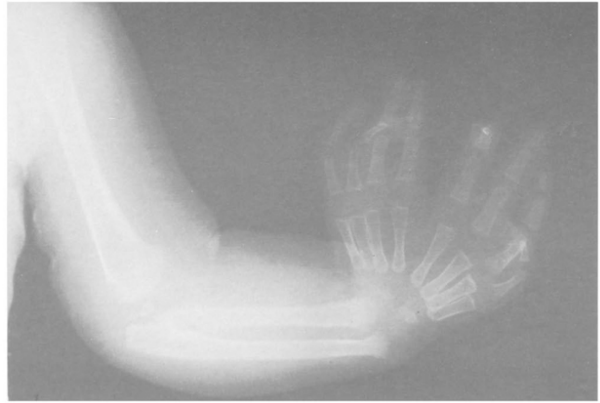


Figure 4 A. The alignment of the deformity



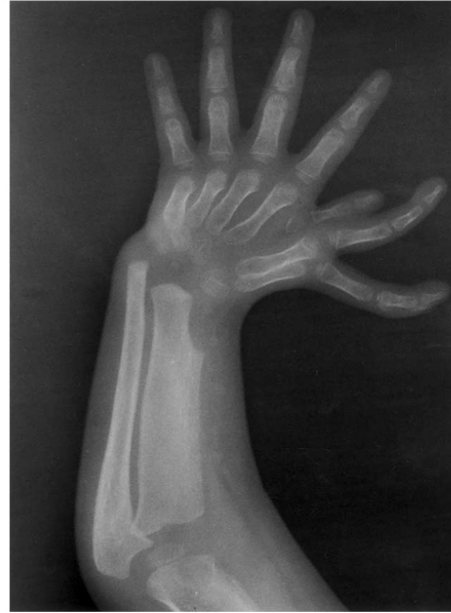B. X-ray of the deformity, with ossification of the hamate and capitate.

Source: *Richard J. King et al.*

A child described by Kumar Bhaskaranand et al. (11) had 7 fingers on the hand, where radial 3 digits were arranged in opposition to the others. Partial duplication was observed on the most radial finger, and the third starting from the radial side was smaller (Figure 5A). Although the arm length was equal on either side, the affected forearm was shorter. Its flexion could reach up to 100 degrees. There was no known exposure to teratogenic factors, the age of the boy was comparable with chronological age. The unique characteristic of this case was revealed after the radiography. There was an abnormal broad and duplicated radius with short but well-formed ulna (Figure 5B).



Figure 5 A. Clinical appearance



B. Radiographic view

Source: *Kumar Bhaskaranand, et al.*

The morphological variations of the ulnar dimelia seem to have a wide range. As we see, the number of fingers, their location, symmetric or asymmetric distribution has a wide range of variation. Interestingly, the human body tries to compensate the reduced functionality of the hand. On the case report, described by J. O. M. Chinegwundoh et al. (12), the wrist of the patient had extra metacarpal bone from the radial side, and, together with the adjacent metacarpal articulated with the same digit (Figure 6A). This part of the wrist served a thumb and excluded the need for pollicization. The wrist was splinted, which was the only intervention performed.

The patient returned at age 15 and had a functioning hand with the preaxial digit acting as a thumb. The distal part of the ulna resembled some features of radius (Figure 6B).

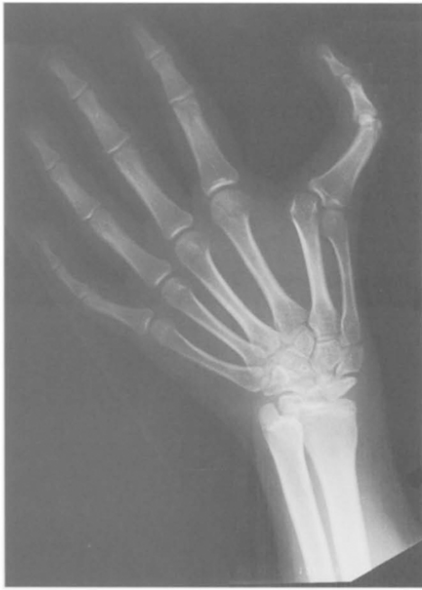
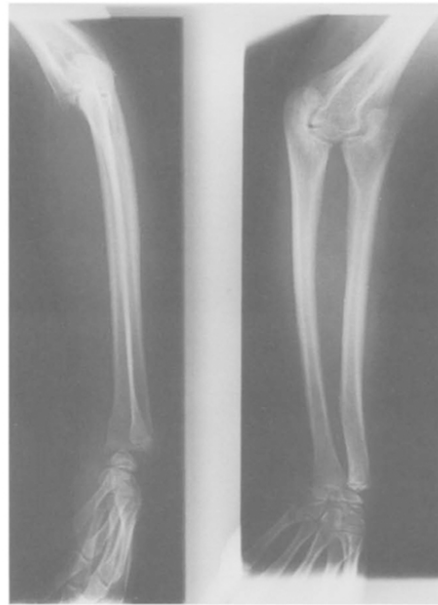
Figure 6 A. Both metacarpal bones on the radial side are connected with the same finger.



B. The distal part of the ulna resembles the radius.

Source: *J. O. M. Chinegwundoh et al*

In the case report described by C. Mathun Ram et al. (13), the child had seven fingers, distributed symmetrically, and two ulnae, facing each other and having different length (Figure 9). The functional capability of the hand was normal.

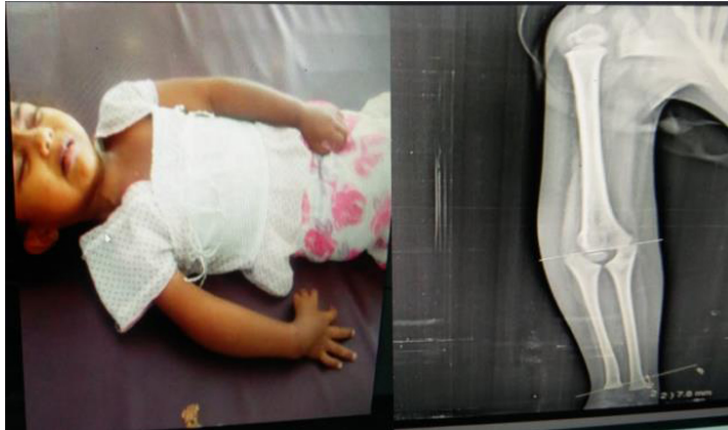

Figure 9. The ulnae facing each other and having different length.

More recent papers describe case reports including arterial tree characterization. Interestingly, the first cadaver dissection in the Warren Anatomical Museum at Harvard University Medical School showed asymmetrical blood supply, and the connection was absent between major supplying arteries. The arterial tree of the 4-year-old girl in the report by A. Afshar et. al (14), who was admitted to the hospital with the diagnosis of ulnar dimelia, was not duplicated on CT angiograms. The ulnar artery was the continuation of the brachial artery and gave rise to the interosseus and attenuated radial arteries. The last terminated at the level of wrist. The deep palmar arch was

absent (Figure 7).

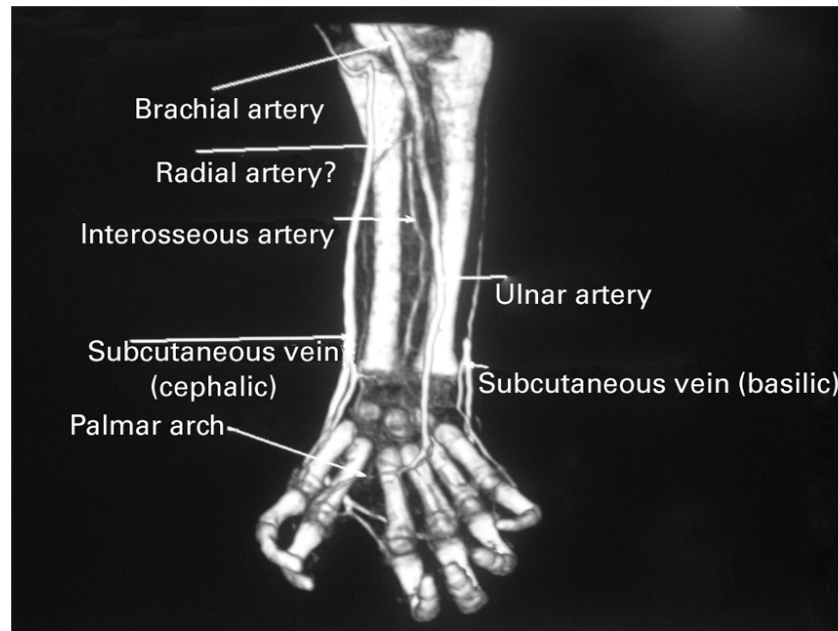


Figure 7 . *Angiography of the limb (Source: Afshar et. al.)*

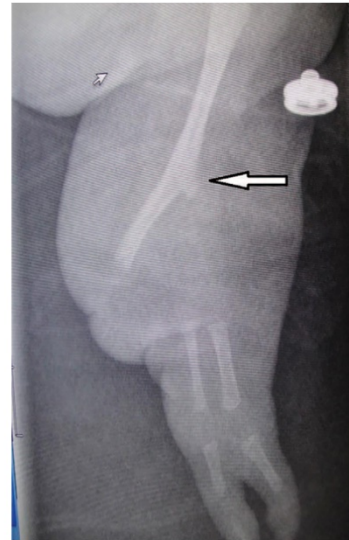
Finally, ulnar ray deficiency can lead to more pronounced defects that will sufficiently diminish the hand functional capability. Mohammad Al-Qattan et al. (15) described a case, when dorsal and ventral dimelia existed in the same patient. Although this is not a case of ulnar dimelia, these two conditions share many pathogenetic aspects needed to be investigated. A 9-month old Saudi female admitted to the hospital having both dorsal and ventral dimelia in the same hand. The upper left limb was short, there was no elbow, the hand had only two digits. The radial hand had dorsal dimelia, and the ulnar hand had ventral dimelia. Radiological examination of the left limb showed severe ulnar ray deficiency (Figure 7A).

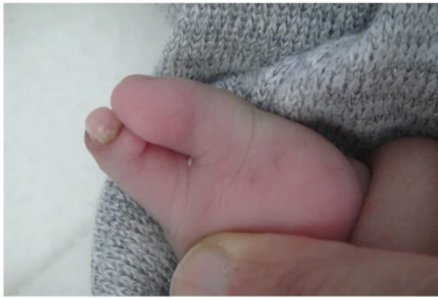
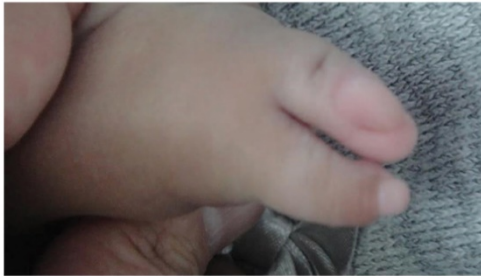
Figure 7A a. The dorsal aspect of the left hand.



7A b. The ventral aspect of the hand



7A c. Radiographic picture

Source: Mohammad Al-Qattan et al.

The variations found in other case reports but not described in the text, can be found at the **Table 1**.

Variation table extracted from the case reports								
Author and date of the publication	Number of fingers, characteristic changes	Relevant information	Gender and age	Shortening of the limb	Fixed flexion of the forearm AND/OR wrist	Supination and pronation	Grasping object between the fingers	Functioning of the opposite limb
Afshar A. et al., 2009 (14)	6 fingers arranged in two groups (asymmetric). separate subgroup of extensor muscles in each group, two ulnae, thenar prominence is absent	No family history, vaginal delivery without complications	4-year-old female	3 cm shorter than the left	Active flexion of the elbow- from 30 to 90 degrees Passive supination range from 0 to 30 degrees	No active supination and pronation	Possible	Normal

Javed Jameel et al., 2011 (9)	7 fingers (symmetric), 2 ulnae (asymmetric) with broadened end	No family history, the antenatal period was uneventful	2 years old female	Yes	Fixed flexion of the elbow 20 degrees, further flexion of 30 degrees	Restricted	Possible	Normal
S. Steven Young et al. (10)	8 fingers (with active flexion and extension of the ulnar part fingers), normal ulna and radius, the most ulnar finger was biphalangal, soft tissue syndactyly of the most radial two digits	Absence of family history	3-month-old boy	No difference	Wrist in a flexed posture. Passive extension of the wrist up to 30 degrees.	No restriction	Yes, used both hands	Normal
Richard J. King et al., 1982 (7)	8 fingers (symmetric), no thumb, the lateral forearm developed number of features resembling the radius	Absence of family history, hidramnios	female	Yes, the forearm was shorter	Fixed flexion of the elbow was 30 degrees	The pronation was full, but the supination amplitude was only the half of the normal range	Possible	Normal
C. Mathun Ram et al., 2018 (13)	7 fingers, symmetrical, two ulnae, medial is longer	First child of the family, delivered normally	4 years old female	Yes	10°, further flexion of 90°	No restriction	Normal functional capacity, lifting a small object was possible	Normal
Kumar Bhaskaranan d et al., 2003 (11)	7 fingers (3 opposed to others), 1 ulna, 2 radii (abnormal, duplicated)	No known teratogenic factors, clean family history	male, 3.5 years old.	Although the length of the entire arms was the same, the forearm was shorter on the affected	Fixed flexion of the elbow- 40°, further flexion of 90° was possible	Not mentioned	Possible	Normal

				side				
Avadis A Muradian et al. ,2007 (25)	7 fingers and no thumb, 2 ulnae, obvious absence of the thenar muscles, no proximal carpal row	Not mentioned	7 years old male	Not mentioned	Active flexion of the elbow- 30 degrees, the forearm rotation limited, the flexion angle of the wrist- 20 degrees	Restricted	Not mentioned	Not mentioned
Chinegwund oh. O. M. et al. (12)	5 fingers and no thumb, 2 ulnae, duplication of the ulnar carpal bones, extra metacarpal on the radial side	No history of infection or drug use during the pregnancy period, vaginal delivery without complications	The case was screened starting from the birth until the child aged 15	Not mentioned	Fixed flexion of the elbow- 40 degrees, further flexion of 50 degrees was possible, fixed palmar flexion angle was 30 degrees.	No supination and pronation	Possible, weak grip	Not mentioned
Mohamadrez a Guity et al. (16)	7 well-formed fingers, no thumb, no syndactyly, thenar prominence was absent 2 ulnae	No remarkable event during the pregnancy	11 months old boy	Not mentioned	The elbow motion ranges from 10 to 80 degrees	Not mentioned	Possible- the more active finger was reconstructed as a thumb	Not mentioned
Christoph Harpf et al. , 1998 (17)	2 clusters of 4 fingers, no thumb, 2 ulnae	The pregnancy lasted without any serious complications	2-month-old boy	The entire arm was hypoplastic	The hyperflexion of the wrist- 100 degrees	Restricted	Not mentioned	Not mentioned
S Rabah et al. (19)	7 fingers and absence of the thumb, 2 ulnae, no radius, the contour of the	First in order birth, perinatal period was uneventful	2-year-old male	The entire arm Was hypoplastic	The flexion of the elbow is up to 40 degrees	Limited	Not mentioned	Not mentioned

	shoulder is hypoplastic, abduction is restricted							
Ryszard Tomaszewski et al., 2015 (20)	8 fingers, no radius, 2 ulnae, one of which showed hypoplasia of the proximal epiphysis	No evidence	2-month-old girl	Not shortened	flexion-extension 90-5 degrees in the ulnar joint, palmar flexion -80 degrees, dorsal flexion-20 degrees	Absence of the supination and pronation	No evidence	Normal

Surgical approaches

Surgical interventions of the ulnar dimelia are intended to return the weak functionality of the wrist in the long run. The important steps include:

- Creation of a functional thumb
- Obtaining a useful elbow flexion
- Correction of forearm rotations.

The key outcomes, although, include maximum functionality of the hand and appropriate flexion of the elbow.

The surgery can be planned to be performed in steps. Before the operation, various types of orthosis are used to correct the deformities. The parents are encouraged to do passive range of movement exercise to reveal the most functional fingers before the operation. After the operation, the physiotherapy can be passively started after 1 -1/2 months.

In the case report described by Javed Jameel et al. (9), radial distraction was used as the first line intervention. This is applicable in all the cases, when there is a radial deviation of the wrist. If there is a flexion abnormality at the proximal side of the elbow, there is a method of excision of a part of the bone followed by the ligament correction. This was performed as the second step in the case report described above. The excision of the extra part was then followed by the reconstruction of the collateral ligament to increase flexion angle of the elbow. To stabilize the elbow in flexion a long arm posterior splint can be used. The most functional fingers based on parent's observation and on-site evaluation are used for classic pollicization. In this case the wrist had seven fingers, and at the third step the most radial two fingers were removed, shortening osteotomy was performed, the metacarpal bone was rotated to make it act as a thumb. The results remain fixed for a nearly month to achieve the best possible outcome. Kirschner wire (K-wire) are used to maintain the alignment.

In the case report described by Steven Young et al. (10) the surgery performed when the child was 7 months old. As he has 8 fingers (Figure 3), the first step was to excise them at the carpometacarpal joint. The general approach was to use the intrinsic

musculature to mimic the thenar muscles. This is crucial for the abduction and the opposition. To enhance opposition, tensioning of the intrinsic musculature was used as well. In addition, to effectively correct the wrist flexion, tenotomy of the palmaris longus and the flexor carpi ulnaris tendons were performed accompanied by capsulotomy. Dorsal venous draining pathway was preserved as much as possible. The results are shown in Figure 8.

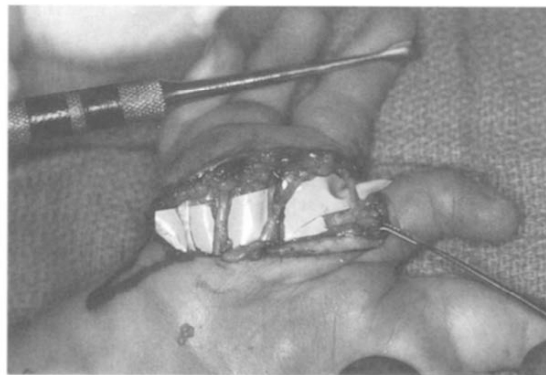
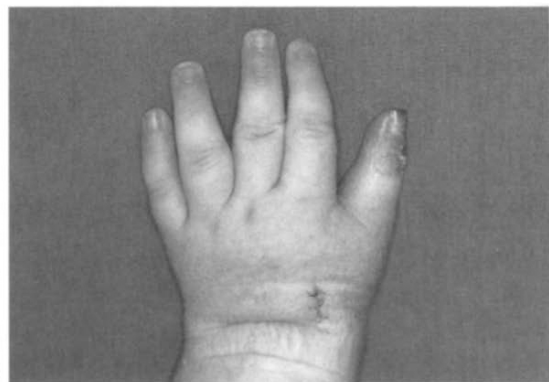
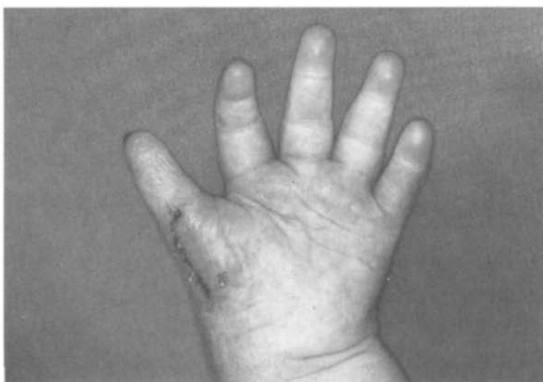
Figure 8 A. The neurovascular bundles of the additional fingers were isolated, the fingers were excised. Opposition of the thumb was created by using the intrinsic muscles.



B. Result after the surgery.

A.Afshar et al. (14) performed excision of the preaxial and pollicization of the other finger (Figure 1). The pollicization is a process, when the digit with its neurovascular pedicle is transposed and rotated. Soft tissue of the excised finger was used for further reconstruction. The interossei muscles were used as the abductor pollicis brevis and transferred to the thenar area. As always, a splint was used to support the wrist. The result can be seen in Figure 10.

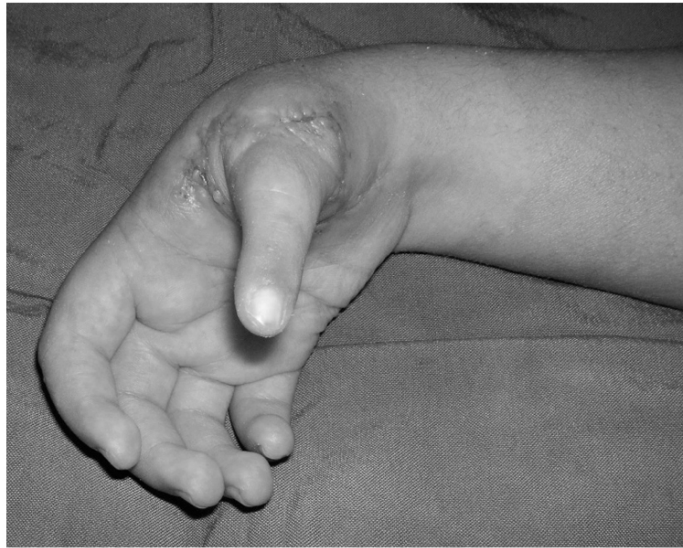

Figure 10. The result of the surgery after 4 weeks.

Source: A. Afshar et al.

More recent findings are using the same techniques described above with slight modifications. In the case report described by Mohamadreza Guity et al. (16) (See table 1), the more active finger is pollicized, the first and third fingers were removed, and the skin was used for further reconstruction. Long arm spica was used to stabilize the changes. The results are shown in Figure 11.

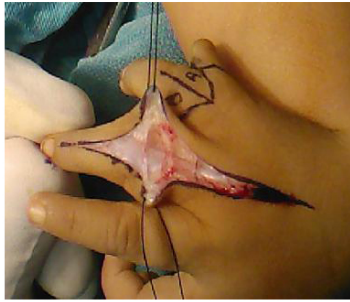
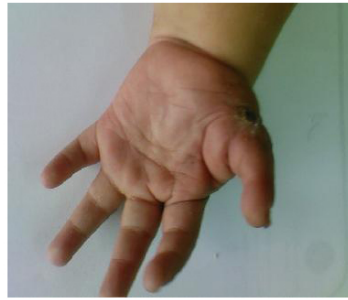

Figure 11. After the surgery



After 8 months



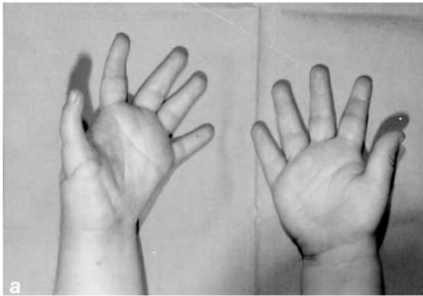
After 20 months

Source: Mohamadreza Guity et al.

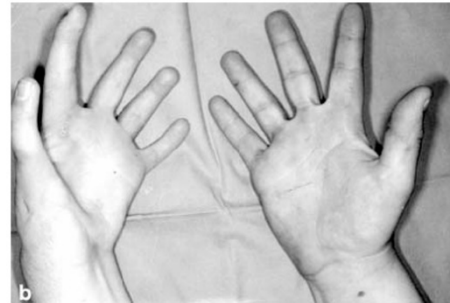
Although, the effects of surgery are satisfying, the long-term effects need to be evaluated. In the case report described by Christoph Harpf et al. (17), a 17-year postoperative follow up was performed. The initial operative steps, creation of the thumb, transfer of the remaining muscles to serve as an abductor were similar with the other reports. Interestingly, electromyographic investigations were performed to analyze the nerve supply pattern of the hand. This information was used for further reconstruction of the muscles in order to achieve the best innervation pattern. As the forearm was hypoplastic, the active range of movement remained between 0-20 degrees. This was due to the fact, that the flexion of the elbow joint was performed only by the forearm flexor muscles. Secondary correction was performed after 17 years in order to improve the active wrist extension. The results are shown in Figure 12.

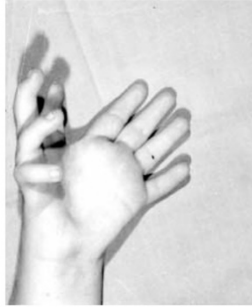

Figure 12 A .Preoperative view



B. Postoperative view at 3 years old



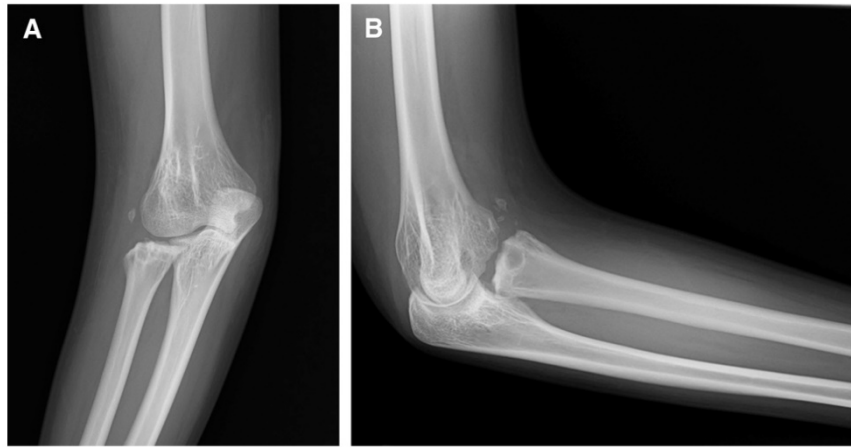
C. Postoperative view after 17 years

Source: Christoph Harpf et al.

Although the results are satisfying, elbow and forearm problems remain after the excision of the additional fingers. In specific cases, surgeons are going further to improve the daily activity of the patient. In the case report described by Takehiko Takagi et al. (18), although the patient has been undergone the above-mentioned surgical steps, the elbow flexion and forearm rotation were significantly limited. The surgeons performed the “second” step of the procedure, where, they focused on the proximal part of the forearm. This biphasic approach resulted in elbow flexion/extension 0/110 degrees, and forearm supination/pronation 90/-10 degrees. The results are shown in Figure 13.

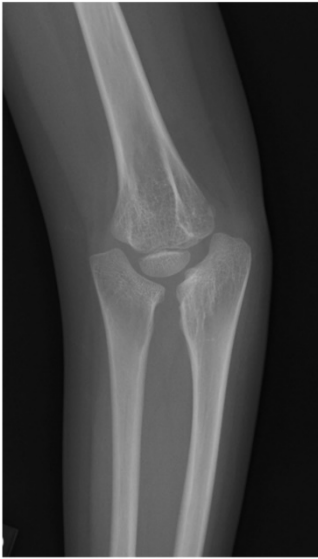

Figure 13 A. Before the surgery.



B. Postoperative anteroposterior (A) and lateral views (B) of the proximal part of the forearm.

Source: Takehiko Takagi et al.

Anatomical findings after the surgery

Unpredicted anatomical variations should be considered before the operation to achieve the best possible outcome. For the majority of cases the pre-axial digits had a well-developed flexor tendon and bilateral interossei. Intraoperative findings in a case report described by A. Afshar et al. (14) include hypoplastic extensor tendons, although the extensor mechanism of the metacarpophalangeal joint was normal. In another case report (7) the anatomy of fibrous flexor sheaths, the insertion of the tendons to the distal phalanges, were normally developed. Bipennate interosseous muscles were also well developed.

Concerning arterial architecture, Gropper described a case, when after the pollicization the vessels were normally developed (21). On the same article tendon anomaly was seen on the flexor pathway. On the other hand, number of pathological changes of the arterial tree were observed in the case report described by Barton et al (22).

However, the analysis of the available literature indicates that minor fluctuations seen in post-surgery observations can't explain the pathological basis of this disease.

Discussion

The literature review revealed important considerations about this condition. First of all, lack of evidence and excellent surgical results decreased the importance of the ulnar dimelia to study deeper and implement preventive therapeutic approaches. The morphological characteristics overlap with other pathologic situations and are not completely specific. These include complete duplications of the entire hand. There are also cases when the duplication occurs at any level of the upper extremity. Other cases (23) describe normal radius and discernable ulna with duplicated fingers, which can be classified as an intermediate condition between ulnar dimelia and multiple hand.

Considering the etiologic sources, it is quite possible that different embryologic events are responsible for such a variety. I have discussed some of the aspects that are thought to be responsible for the development of ulnar dimelia, although none of them completely describes the whole pathological variations seen in these cases. The aberrant impulses that come from the zone of the polarizing activity seem to determine the fate of the further variations. Therefore, this condition should be considered as a problem of formation rather than a failure of differentiation.

Regarding the classification, the parameters such as the number of the fingers, the size of the wrist web space, the opposition angle should be considered as a determination parameter.

The majority of the surgeons are not familiar with this condition and the idea remains to use all the arsenal of the surgical advancement to return the wrist functionality.

According to some authors the best age for reconstruction is before the second year (24).

The main steps in the surgical approach are similar regardless of the morphological type of the ulnar dimelia. The results largely depend on the pre-surgical condition, the age of the patient and the experience of the staff. The main outcomes of the surgery meaning restored elbow flexion, forearm rotation and functional thumb should be evaluated in a long-term follow-up to ensure the completeness of the procedure.

The digits that look well developed serve as a basis for planning the surgery steps in terms of having functional hand. The outcome should produce a better-looking hand, a thumb of an appropriate length and a socially acceptable number of fingers. For the

improved elbow flexion, extension, supination and pronation of forearms the widely approved strategy is to excise the radial ulna proximal part. Summarizing the following points should be emphasized:

- Adequate splinting of the elbow should be started on an individual timeframe.
- Unexpected anatomical variations should be taken account before the surgery. This is especially important for tendons and muscles that are needed to be rearranged.
- Steps should be taken to return the ability to extend the wrist.

In conclusion, the morphological variations of the ulnar dimelia raise some important aspects for scientists to study and intervene as this pathology represents the most extreme form of the differentiation error of the zone of polarizing activity.

Acknowledgements

Firstly, I would like to express my gratitude to my mentor, Doc. dr. sc. Krešimir Bulić

from the Department of Plastic Surgery at the University Hospital Center Zagreb, KBC Rebro, for offering me such an interesting topic for my thesis. He provided me with key information and had a leading role throughout the process of writing this thesis.

The University of Zagreb, School of Medicine, provided me the opportunity to follow my dream and receive an exceptional education.

Finally, my special gratitude goes out to my life partner and family, they always support me in all aspects of my life.

References:

1. Kellikian H: Congenital deformities of the hand and the forearm. Philadelphia, 1974, WB Saunders Co, pp 456-63
2. Al-Qattan MM, Al-Thunayan A, Cordier MD, Nandagopal N, Pitkanen J. Classification of the Mirror Hand-Multiple Hand Spectrum. *Journal of Hand Surgery*. 1998;23(4):534–6.
3. Wood VE. Ulnar dimelia (The mirror hand). In: Green DP (Ed.): *Operative hand surgery*, 2nd edn. New York, Churchill Livingstone, 1988, Vol. 1: 485M91,
4. Laurin CA, Favreau JC, Labelle P. Bilateral Absence of the Radius and Tibia with Bilateral Reduplication of the Ulna and Fibula. *The Journal of Bone & Joint Surgery*. 1964;46(1):137–42.
5. Zwilling E. Limb Morphogenesis. *Advances in Morphogenesis*. 1961;:301–30.
6. Harrison RG, Pearson MA, Roaf R. Ulnar Dimelia. *The Journal of Bone and Joint Surgery British volume*. 1960;42-B(3):549–55.
7. King RJ, Hoyes AD. The Mirror Hand Abnormality. *Hand*. 1982;os-14(2):188–93.
8. Sandrow RE, Sullivan PD, Steel HH. Hereditary Ulnar and Fibular Dimelia with Peculiar Facies. *The Journal of Bone & Joint Surgery*. 1970;52(2):367–70.
9. Jameel J, Khan AQ, Ahmad S, Abbas M. Ulnar dimelia variant: a case report. *Journal of Orthopaedics and Traumatology*. 2011;12(3):163–5.
10. Yang SS, Jackson L, Green DW, Weiland AJ. A rare variant of mirror hand: A case report. *The Journal of Hand Surgery*. 1996;21(6):1048–51.

11. Bhaskaranand K, Bhaskaranand N, Bhat AK. A variant of mirror hand: a case report. *The Journal of Hand Surgery*. 2003;28(4):678–80.
12. Chinegwundoh JOM, Gupta M, Scott WA. Ulnar Dimelia. *Journal of Hand Surgery*. 1997;22(1):77–9.
13. Ram, C. Mathun, and G. Chidambaranathan. “Ulnar Dimelia: a Rare Case.” *International Journal of Research in Orthopaedics*, vol. 5, no. 2, 2019, p. 350., doi:10.18203/issn.2455-4510.intjresorthop20190068.
14. Afshar A. Ulnar dimelia without duplicated arterial anatomy. *The Journal of Bone and Joint Surgery British volume*. 2010;92-B(2):293–6.
15. Al-Qattan M, Al-Kahtani FS. Dorsal and Ventral Dimelia in the Same Hand in A Patient with Severe Ulnar Ray Deficiency: A Case Report. *World Journal Of Plastic Surgery*. 2019Jan;8(1):112–5.
16. Mohamadreza G, Kaveh B, Arash S. Excellent result of a mirror hand anomaly treatment. *Iran J Pediatr*. 2013;23(1):118-9.
17. Hussl CHH. A CASE OF MIRROR HAND DEFORMITY WITH A 17-YEAR POSTOPERATIVE FOLLOW UP: Case report. *Scandinavian Journal of Plastic and Reconstructive Surgery and Hand Surgery*. 1999;33(3):329–33.
18. Takagi T, Seki A, Takayama S. Elbow and forearm reconstruction in patients with ulnar dimelia can improve activities of daily living. *Journal of Shoulder and Elbow Surgery*. 2014;23(3).
19. Mirror Hand Deformity - A Rare Congenital Anomaly Of The Upper Limb. *The Internet Journal of Surgery*. 2009;21(1).

20. Tomaszewski R, Bulandra A. Ulnar dimelia-diagnosis and management of a rare congenital anomaly of the upper limb. *Journal of Orthopaedics*. 2015;12.
21. Gropper PT. Ulnar dimelia. *The Journal of Hand Surgery*. 1983;8(4):487–91.
22. Barton N, Buckgramcko D, Evans D. Soft-tissue anatomy of mirror hand. *The Journal of Hand Surgery: Journal of the British Society for Surgery of the Hand*. 1986;11(3):307–19.
23. Barton N, Buckgramcko D, Evans D, Kleinert H, Semple C, Ulson H. Mirror hand treated by true pollicization. *The Journal of Hand Surgery: Journal of the British Society for Surgery of the Hand*. 1986;11(3):320–36.
24. Jafari D, Sharifi B. A variant of mirror hand. *The Journal of Bone and Joint Surgery British volume*. 2005;87-B(1):108–10.
25. Muradian AA. Ulnar Dimelia, A Case Report. *Basrah Journal of Surgery*. 2007;13(2):73–4.
26. Naruse I, Ueta E, Sumino Y, Ogawa M, Ishikiryama S. Birth defects caused by mutations in human GLI3 and mouse Gli3 genes. *Congenit Anom (Kyoto)*. 2010;50(1):1-7.

Biography

David Schwarz was born in 1994 in St Råby, Sweden. After graduating High school and taking a pre-medical course, he decided to pursue his dream and began his studies in University of Zagreb School of Medicine 2014. His interests lie in the fields of plastic and reconstructive surgery.