

# Bilateral juxtapapillary choroidal neovascularization secondary to Birdshot chorioretinopathy—case report

---

Vidas Pauk, Sania; Vukojević, Nenad; Jandroković, Sonja; Kalauz, Miro; Tomić, Martina; Masnec, Sanja; Škegro, Ivan; Mrazovac Zimak, Danijela

Source / Izvornik: **Clinical Case Reports, 2021, 9**

Journal article, Published version

Rad u časopisu, Objavljena verzija rada (izdavačev PDF)

<https://doi.org/10.1002/ccr3.4601>

Permanent link / Trajna poveznica: <https://urn.nsk.hr/urn:nbn:hr:105:877172>

Rights / Prava: [Attribution-NonCommercial 4.0 International/Imenovanje-Nekomercijalno 4.0 međunarodna](#)

Download date / Datum preuzimanja: **2024-07-02**




Repository / Repozitorij:

[Dr Med - University of Zagreb School of Medicine Digital Repository](#)



## CASE REPORT

# Bilateral juxtapapillary choroidal neovascularization secondary to Birdshot chorioretinopathy—case report

Sania Vidas Pauk<sup>1</sup>  | Nenad Vukojević<sup>1,2</sup> | Sonja Jandroković<sup>1,2</sup> | Miro Kalauz<sup>1,2</sup> | Martina Tomić<sup>3</sup> | Sanja Masnec<sup>1,2</sup> | Ivan Škegro<sup>1,2</sup> | Danijela Mrazovac Zimak<sup>1</sup>

<sup>1</sup>Department of Ophthalmology, Zagreb University Hospital Center, Zagreb, Croatia

<sup>2</sup>School of Medicine, University of Zagreb, Zagreb, Croatia

<sup>3</sup>Department of Ophthalmology, Vuk Vrhovac University Clinic for Diabetes, Endocrinology and Metabolic Diseases, Merkur University Hospital, Zagreb, Croatia

## Correspondence

Sania Vidas Pauk, Department of Ophthalmology, Zagreb University Hospital Center, Kišpatičeva 12, 10000 Zagreb, Croatia.  
Email: sania\_vidas@yahoo.com

## Funding information

This work did not receive any specific grant from funding agencies in the public, commercial, or not-for-profit sectors

## Abstract

Central vision loss, photopsia, floaters, and macular edema in a highly myopic patient can easily be misinterpreted as high myopia complications. In atypical cases, detailed examination and a thorough diagnostic workup are required to establish the proper diagnosis, which is often beyond the scope of diagnoses initially considered.

## KEY WORDS

Birdshot chorioretinopathy, choroidal neovascularization, HLA-A29 antigen, immunosuppressive agents, intravitreal injections, macular edema

## 1 | INTRODUCTION

Birdshot chorioretinopathy (BCR) is a rare, chronic, bilateral, posterior inflammatory disease involving the retina and the choroid, responsible for 6% - 8% of cases of posterior uveitis. It is typically seen in the Caucasian population during their fifties and sixties, with slight female predominance (54.1%).<sup>1-3</sup> The condition has a distinct clinical phenotype consisting of moderate vitritis and/or vitreous debris, retinal vasculitis, and multiple characteristic hypopigmented, cream-colored choroidal lesions radiating from the optic disc to the eye equator.<sup>1-3</sup> After subtle early signs, it may take up to eight years for typical birdshot lesions to appear.<sup>4</sup> Initially, they seem to be located in the choroidal stroma, while in later

stages, the lesions develop a more atrophic appearance and enlarge, involving the outer retina, retinal pigment epithelium (RPE), the choroid, and eventually become irreversible.<sup>5</sup> The HLA-A29 haplotype is strongly associated with BCR, observed in over 95% of patients.<sup>6</sup>

Cystoid macular edema (CME), leading to central vision loss, is the main complication affecting about 50% of patients. Epiretinal membranes occur in nearly 10% of patients, and choroidal neovascularization (CNV), as a rare complication, is reported in only 6% of cases. CNV usually develops at the margin of RPE damage, juxtafoveal, subfoveal, or even juxtapapillary. However, peripapillary or peripheral CNV has also been observed. Other complications include central retinal vein occlusion, recurrent vitreous hemorrhage, and optic atrophy.<sup>4-8</sup>

This is an open access article under the terms of the Creative Commons Attribution-NonCommercial License, which permits use, distribution and reproduction in any medium, provided the original work is properly cited and is not used for commercial purposes.

© 2021 The Authors. *Clinical Case Reports* published by John Wiley & Sons Ltd.

Given the subtle and insidious clinical presentation, with the onset of floaters, photopsia, or visual field defects, and with no pain and redness, the disease can easily be missed and remain unrecognized until the development of a notable decline in central and peripheral vision due to CME, choroidal and retinal atrophy and/or other long-term complications.<sup>9,10</sup>

The disease is chronic, often progressive, with a highly unpredictable and recurrent clinical course, and has significant potential for irreversible tissue damage and visual loss. However, its pathogenesis remains unclear, thus contributing to a lack of optimal treatment protocol.<sup>3</sup>

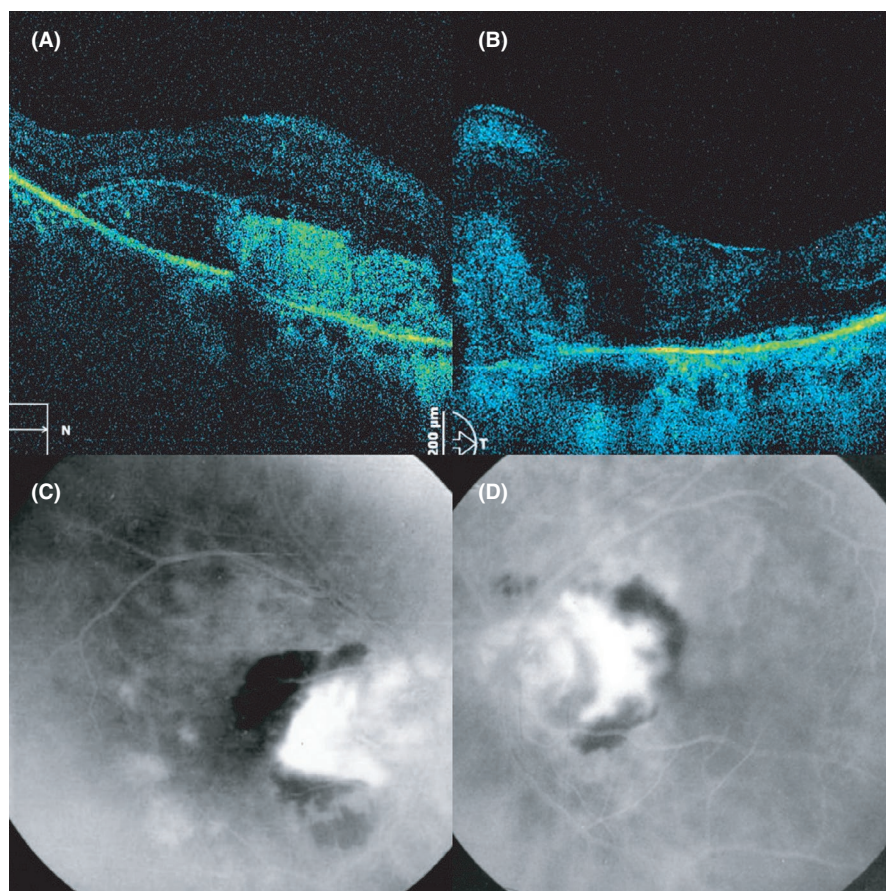
In this paper, the authors present their experience in treating long-standing advanced BCR in a middle-aged woman with profound central vision loss due to bilateral juxtapapillary CNV and CME.

## 2 | CASE PRESENTATION

### 2.1 | Case history, examination, and investigations

In April 2007, a 55-year-old female presented to our department with painless, unspecific central vision loss, complaining of blurry vision, floaters, and photopsia. A year before presentation, she was diagnosed and treated with high

myopia-related CNV. In her long-term medical history, she occasionally noticed photopsia, floaters, and a decline in central vision, which ophthalmologists explained as symptoms related to high myopia. Her medical history was otherwise unremarkable. Upon administration, a complete ophthalmological examination was performed: best-corrected visual acuity (BCVA) testing, slit-lamp examination, spectral-domain optical coherence tomography (SD-OCT), fundus photography, fluorescein angiography (FA), and fundus autofluorescence (AF). Electroretinography (ERG) and electrooculography (EOG) were also performed and rechecked. Her initial log-MAR BCVA was 0.2 (Snellen fraction 20/32, decimal 0.63) on the right eye and 0.5 (Snellen fraction 20/63, decimal 0.32) (eccentric) on the left eye. Spherical refraction was  $-9.50$  and  $-8.50$  diopters, respectively. Anterior-segment findings were within normal range, while posterior segment examination revealed mild anterior vitritis, juxtapapillary CNV with macular edema, and a patterned distribution of choroidal inflammatory lesions radiating from the optic disc. Many of these signs already had an atrophic appearance. Signs of vascular sheathing and vascular attenuation were present in both eyes. SD-OCT obtained by SOCT Copernicus (OPTOPOL Technology Sp. z o.o., Zawiercie, Poland) predominantly showed cystoid macular edema and CNV (Figure 1A and B). FA obtained by fx-500 S (Kowa Electronics and Optics Tokyo, Japan) confirmed the presence and demonstrated



**FIGURE 1** (A) right eye and (B) left eye first visit SD-OCT (SOCT Copernicus, OPTOPOL, Zawiercie, Poland) showed subretinal fluid and intraretinal cysts with a subretinal zone of intermediate reflectivity representing choroidal neovascularization (C) right eye and (D) left eye first visit fluorescein angiography fx-500 S (Kowa Electronics and Optics Tokyo, Japan) confirmed the presence and demonstrate the location of juxtapapillary CNV leakage, hypofluorescent retinal hemorrhage, hyperfluorescent patterned choroidal lesions related to birdshot chorioretinopathy and vascular leakage. Abbreviations: SD-OCT, spectral-domain optical coherence tomography; CNV, choroidal neovascularization

juxtapapillary CNV leakage with retinal hemorrhage, typical BCR inflammatory and atrophic lesions, and vascular changes in both eyes (Figure 1C and D). Electrophysiological testing was first obtained in 2013 using Tomey Primus 2.5 (Tomey GmbH, Erlangen, Germany). Earlier electrophysiological findings were not available to the authors. Neither rod nor combined rod-cone responses were elicited on the ERG in either eye. Single flash cone and 30 Hz flicker cone responses were non-recordable on the right eye, while on the left eye a-wave latency and b-wave implicit times were elongated with reduced amplitude. Arden's index was lower on both eyes; 1.34 on the right and 1.48 on the left eye.

Angiotensin-converting enzyme (ACE), lysozyme, interferon-gamma release assay, tuberculin skin test, chest röntgenography (X-ray), and high-resolution chest computer tomography were within normal range. Additional laboratory tests, including complete blood count, erythrocyte sedimentation rate, C-reactive protein, serum electrolytes, calcium, rapid plasma reagin, syphilis, and Lyme disease serology, came back negative.

Clinical and diagnostic findings led us to perform HLA testing. The HLA-A29-positive haplotype finally helped us to confirm the diagnosis of BCR. In a case like this, the correct diagnosis of BCR may be missed due to subtle anterior segment clinical signs without conjunctival redness, by confusing the signs of mild vitritis, inflammatory CME, and/or CNV with vitreous opacities and myopic CNV-related macular edema, and by failing to recognize the changes in the peripheral retina, especially in earlier stages of the disease.

## 2.2 | Treatment, outcome, and follow-up

After establishing the diagnosis, the patient was treated with multiple intravitreal (IVT) anti-VEGF and corticosteroid therapy courses, combined with oral immunosuppressive therapy (IMT). A total of 25 IVT injections were applied, 21 of 1.25 mg/0.1 ml anti-VEGF (bevacizumab), of which 13 applications in the right and 9 in the left eye, and 4 IVT injections of 8 mg/0.1 ml corticosteroid (triamcinolone acetate; TA), 3 in the right and 1 in the left eye, combined with methotrexate (MTX), in doses between 7.5 and 25 mg weekly orally, with the addition of folic acid 48 hours after MTX administration. Remission of inflammation and vasculitis, CNV attenuation, and resolution of macular edema were achieved one year after initiation of the prescribed therapy.

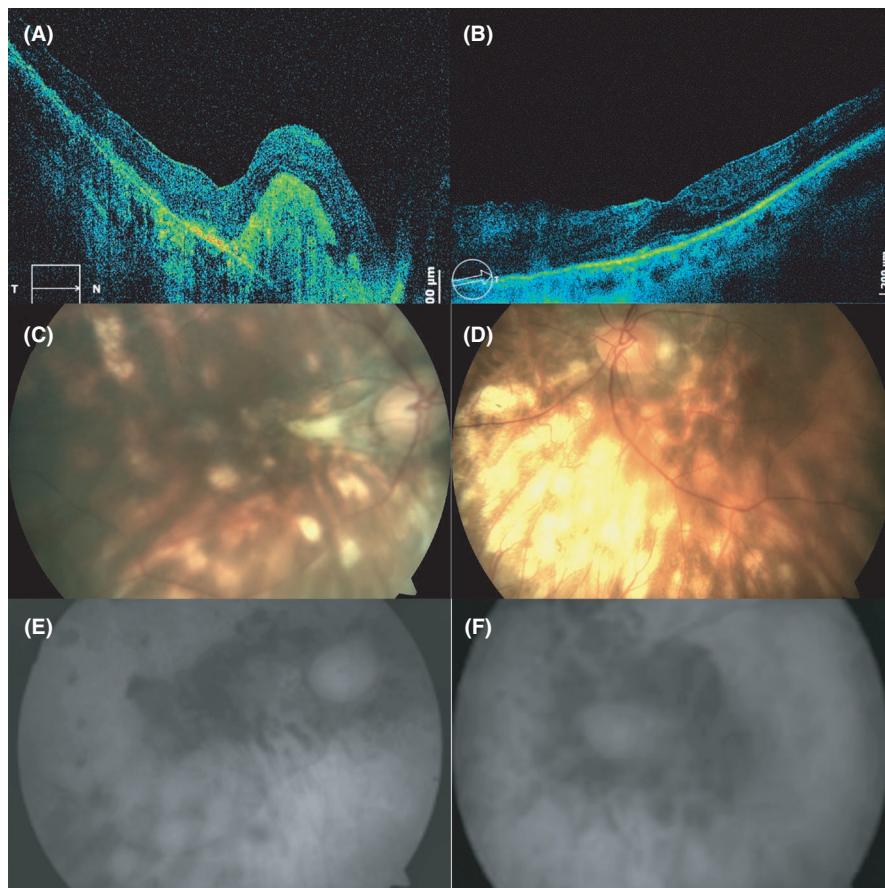
From 2009 to 2011, the patient ceased taking the recommended systemic therapy, which led to the exacerbation of the inflammation and vasculitis, but with no signs of CNV reactivation or newly formed CNV. Again, MTX was given orally, which resulted in stable remission. In 2015, due to stable disease control and the development of mild liver dysfunction, the authors decided to discontinue IMT. Unfortunately, two

years later, in 2017, signs of ocular inflammation reoccurred. Since then, the patient has continuously received cyclosporine A (CSA) therapy in doses between 2.5 and 5 mg/kg/day orally, and to date, the patient is in stable remission. In the meantime, the patient developed a bilateral cataract and underwent cataract surgery without further postoperative complications.

During her last visit in December 2020, logMAR BCVA was 1.0 (Snellen fraction 20/200, decimal 0.1) (eccentric) on the right eye and 0.2 (Snellen fraction 20/32, decimal 0.63) on the left eye, with spherical refraction of  $-0.50$  and  $-1.50$  diopters. Ophthalmoscopy findings revealed no signs of vitritis or vasculitis, only moderate vascular attenuation. No active choroidal lesions were found, only pattern distributed chorioretinal atrophic lesions affecting the right macula with macular fibrosis and visible inactive fibrotic juxtapapillary CNV membranes on both eyes. Left macula findings were within the normal range (Figure 2). ERG showed a slight improvement in the implicit time and amplitude of 30 Hz flicker ERG on the left eye, while other electrophysiological findings remained unchanged.

## 3 | DISCUSSION

A patient suffering from an unusual condition with uncommon complications often presents a diagnostic and therapeutic challenge. Our patient presented with central vision loss in both eyes due to CNV development in severe long-standing BCR. First, she was misdiagnosed with complications due to high myopia that led to years of misguidance before a correct diagnosis was established and adequate treatment was provided. Her ocular findings made us suspicious of a specific form of posterior uveitis. Due to the typical clinical presentation and diagnostic findings, other variants of "white dot" syndromes were excluded. Sarcoidosis was also considered since some reports showed that it might be presented as BCR, and some of them pointed out that sarcoidosis may be one of the potential causes of BCR.<sup>11,12</sup> However, all the diagnostic evaluations undertaken in that manner were within the normal range. Besides, there were no typical findings in the other eye segments, and the patient had no accompanying systemic manifestations typical for sarcoidosis (eg, pulmonary infiltration, bilateral hilar lymphadenopathy, or any lymphadenopathy). Lymph node biopsy was not performed due to a lack of existing lymphadenopathy. Reports suggested that biopsy is a reliable criterion for excluding sarcoidosis.<sup>11,12</sup> After performing a thorough diagnostic workup, with the patient having typical ophthalmoscopy features, and using diagnostic criteria defined at the 2006 University of California, Los Angeles (UCLA) international workshop, the correct diagnosis was finally reached, reinforced by HLA-A29-positive haplotype.<sup>13</sup> All other potential causes of uveitis, infectious, noninfectious, or masquerade were excluded.



**FIGURE 2** (A) right eye last visit SD-OCT (SOCT Copernicus HR, OPTOPOL, Zawiercie, Poland) showed a complete central retinal fluid resolution with a hyper-reflective zone of subretinal fibrosis, loss of retinal pigment epithelium, photoreceptor layer integrity, and loss of integrity of outer retina. (B) left macula SD-OCT showed preserved retinal pigment epithelium, photoreceptor layer integrity, and integrity of outer retina. (C) right eye and (D) left eye last visit fundus photography obtained by Visucam (Carl Zeiss Meditec AG, Jena, Germany) and (E) right eye and (F) left eye fundus autofluorescence showed attenuated juxtapapillary CNV, with inactive fibrotic juxtapapillary membranes, and disseminated retinal fibrosis and atrophic lesions. Abbreviations: SD-OCT, spectral-domain optical coherence tomography; CNV, choroidal neovascularization

BCR typically requires aggressive treatment to prevent vision loss. According to the literature, treatment protocols widely differ, and there are no established therapeutic protocol guidelines. The central components of the treatment are steroid-sparing IMT, for example, MTX, mycophenolate mofetil (MMF), T-cell transduction/calcineurin inhibitors, for example, CSA, intravenous immunoglobulin, and other biologic therapies, each of which may be used alone or in combination with other agents.<sup>3</sup> It is common practice for systemic corticosteroids to be used as initial or adjuvant therapy to manage acute inflammatory manifestations of BCR until systemic IMT becomes effective.<sup>3</sup> Intravitreal (IVT) anti-VEGF and IVT corticosteroid therapy are commonly used as the first-line therapy of CME or CNV.<sup>7,14,15</sup> Some reports presented IVT TA in a dose of 8 mg to be equally safe and effective as systemic corticosteroid therapy in treating posterior uveitis.<sup>15</sup> CSA monotherapy has proven to be effective in the control of BCR. However, its use is limited by side effects, including renal dysfunction and hypertension, which tend to be more significant in the predominantly middle-aged population of BCR patients.<sup>5,16</sup> Despite that, a low-dose CSA monotherapy, between 2.5 and 5 mg/kg/day, is considered safe with a low incidence of side effects.<sup>17</sup> Kiss et al. presented sufficient inflammatory control, stabilization of the chorioretinal changes, and good visual function outcomes when a low dose of CSA was combined

with MTX, azathioprine, MMF, or daclizumab.<sup>14</sup> Nowadays, MMF has become the most frequently prescribed IMT for BCR treatment due to its relatively safe profile and ability to control the disease sufficiently.<sup>18</sup> According to the literature, its efficacy is around 70%. However, combined MMF and systemic corticosteroid or CSA therapy results in an effective treatment.<sup>18,19</sup>

Although nowadays less commonly used than MMF, MTX is also effective in BCR treatment. Rothova et al. conducted a retrospective study on 76 BCR patients divided into three groups according to the treatment approach.<sup>20</sup> Study results showed that MTX treatment had been the most effective in the 5-year follow-up in terms of inflammation and progression control and better visual outcomes, compared to systemic corticosteroid treatments or no systemic treatment at all. It was presumed that MTX reduces inflammation and that it might have a beneficial effect on vasculitis and CME. It is possible that MTX could reduce inflammatory activity and protect the eye from CME, and perhaps, from consequent atrophic changes. Therefore, at that moment, MTX was considered to be the best treatment approach for our patient. In our case, systemic MTX therapy was initially combined with IVT bevacizumab and TA therapy. This therapy led to CNV attenuation and regression of macular edema, followed by suppression of intraocular inflammation and vasculitis, and finally, the achievement of stable remission. Unfortunately,

the patient stopped taking the prescribed therapy on two separate occasions, which resulted in the exacerbation of inflammation and vasculitis. By restarting the MTX treatment after the first exacerbation and CSA treatment after the second exacerbation, stable remission was achieved once more and there was no need for additional systemic corticosteroid or IVT therapy. This case strengthens the results found by Rothova et al.<sup>20</sup> Low-dose MTX and CSA monotherapy, in this case, resulted in control of inflammation in advanced BCR and preservation of central visual function, at least on the left eye, which is supported by electrophysiology findings. Unfortunately, the development of subretinal fibrosis, loss of photoreceptors, and outer retinal layer integrity, due to resistant CME and CNV in the right macula, resulted in severe and irreversible central visual loss. ERG results did not show substantial improvement, probably due to severe damage to the retina and the choroid, which was the result of the duration, advanced stage, and unrecognized state of the disease.

The limitation of this work is the unavailability of MMF since it was not available to the authors in their clinical work at that time of this case. A few months ago, MMF was finally approved in our country by the national health insurance fund as a therapy of choice for resistant cases of posterior uveitis. Additionally, if an IVT dexamethasone implant had been invented and legally approved when our patient needed it, it probably would have been a much better choice than TA. This paper only presented our observations and has no statistical strength. Further investigations are required with additional patients and longer follow-up to resolve ethical dilemmas and to reach a consensus on the best therapy protocol.

## 4 | CONCLUSION

This case report is an overview of a patient presenting long-standing BCR, complicated with resistant CME and juxtapapillary CNV with misdiagnosed high myopia-related complications. Many years went by before the correct diagnosis was reached and proper therapy was introduced. Systemic methotrexate and cyclosporine monotherapy combined with intravitreal bevacizumab and triamcinolone acetonide therapy were efficient in CNV attenuation, CME resolution, preservation of central visual function on the left eye, and intraocular inflammation control in advanced BCR. However, earlier detection of the disease and earlier initiation of therapy probably would have resulted in a better outcome for the patient.

## ACKNOWLEDGMENT

The authors have not received substantial contributions from non-authors.

## CONFLICT OF INTEREST

The authors declare that there was no conflict of interest regarding this work.

## AUTHOR CONTRIBUTIONS

Sania Vidas Pauk conceived and drafted the paper. Nenad Vukojević guided the patient's diagnostic and treatment protocols, and he also reviewed and revised the paper for significant intellectual contributions. Sonja Jandroković revised the paper for significant intellectual contributions. Miro Kalauz consulted the treatment and contributed to drafting. Martina Tomić reviewed and revised the paper for significant intellectual contributions and made the final revision. Sanja Masnec consulted the treatment and contributed to drafting. Ivan Škegro contributed to drafting and revision. Danijela Mrazovac Zimak revised the paper for critical intellectual contributions.

## ETHICAL APPROVAL

The authors made this work following the guidelines of the Declaration of Helsinki.”

## INFORMED PATIENT CONSENT

Written informed consent was obtained from the participant in order to publicize this case report and accompanying images.

## DATA AVAILABILITY STATEMENT

The data that support the findings of this study are available from the corresponding author upon reasonable request.

## ORCID

Sania Vidas Pauk  <https://orcid.org/0000-0002-8229-7826>

## REFERENCES

1. Faia LJ. Gender differences in birdshot chorioretinopathy and the white dot syndromes: Do they exist? *J Ophthalmol.* 2014;2014:146768. <https://doi.org/10.1155/2014/146768>
2. Menezo V, Taylor SR. Birdshot uveitis: current and emerging treatment options. *Clin Ophthalmol.* 2014;8:73-81. <https://doi.org/10.2147/OPHTH.S54832>.
3. Minos E, Barry RJ, Southworth S, et al. Birdshot chorioretinopathy: current knowledge and new concepts in pathophysiology, diagnosis, monitoring and treatment. *Orphanet J Rare Dis.* 2016;11(1):61. <https://doi.org/10.1186/s13023-016-0429-8>
4. Cunningham ET, Levinson RD, Denniston AK, Brézin AP, Zierhut M. Birdshot Chorioretinopathy. *Ocul Immunol Inflamm.* 2017;25(5):589-593. <https://doi.org/10.1080/09273948.2017.1400800>
5. Rothova A, Berendschot TT, Probst K, van Kooij B, Baarsma GS. Birdshot chorioretinopathy: long-term manifestations and visual prognosis. *Ophthalmology.* 2004;111(5):954-959. <https://doi.org/10.1016/j.optha.2003.09.031>
6. Rothova A, Suttorp-van Schulten MS, Frits Treffers W, Kijlstra A. Causes and frequency of blindness in patients with intraocular inflammatory disease. *Br J Ophthalmol.* 1996;80(4):332-336.

7. Oueghlani E, Westcott M, Pavésio CE. Anti-VEGF therapy for choroidal neovascularisation secondary to Birdshot chorioretinopathy. *Klin Monbl Augenheilkd*. 2010;227:340-341.
8. Priem HA, Oosterhuis JA. Birdshot chorioretinopathy: clinical characteristics and evolution. *Br J Ophthalmol*. 1988;72(9):646-659. <https://doi.org/10.1136/bjo.72.9.646>
9. Monnet D, Brézin AP. Birdshot chorioretinopathy. *Curr Opin Ophthalmol*. 2006;17(6):545-550. <https://doi.org/10.1097/ICU.0b013e3280109479>
10. Comander J, Loewenstein J, Sobrin L. Diagnostic testing and disease monitoring in birdshot chorioretinopathy. *Semin Ophthalmol*. 2011;26(4-5):329-336. <https://doi.org/10.3109/08820538.2011.588661>
11. Kuboshiro T, Yoshioka H. Birdshot retinochoroidopathy—a possible relationship to ocular sarcoidosis. *Kurume Med J*. 1988;35(4):193-199. <https://doi.org/10.2739/ikumemedj>
12. Khurana RN, Parikh JG, Rao NA. Sarcoid choroiditis simulating birdshot chorioretinopathy. *Retin Cases Brief Rep*. 2008;2(4):301-303. <https://doi.org/10.1097/ICB.0b013e31809ed9a2>
13. Levinson RD, Brézin A, Rothova A, Accorinti M, Holland GN. Research criteria for the diagnosis of birdshot chorioretinopathy: results of an international consensus conference. *Am J Ophthalmol*. 2006;141(1):185-187.
14. Kiss S, Ahmed M, Letko E, Foster CS. Long-term follow-up of patients with birdshot retinochoroidopathy treated with corticosteroid-sparing systemic immunomodulatory therapy. *Ophthalmology*. 2005;112(6):1066-1071.
15. Ozkiris A. Intravitreal triamcinolone acetonide injection for the treatment of posterior uveitis. *Ocul Immunol Inflamm*. 2006;14(4):233-238. <https://doi.org/10.1080/09273940600826604>
16. Oh KT, Christmas NJ, Folk JC. Birdshot retinochoroiditis: long term follow-up of a chronically progressive disease. *Am J Ophthalmol*. 2002;133:622-629.
17. Vitale AT, Rodriguez A, Foster CS. Low dose cyclosporine therapy in the treatment of birdshot retinochoroidopathy. *Ophthalmology*. 1994;101:822-831.
18. Doycheva D, Zierhut M, Blumenstock G, Stuebiger N, Deuter C. Longterm results of therapy with mycophenolate mofetil in chronic noninfectious uveitis. *Graefes Arch Clin Exp Ophthalmol*. 2011;249(8):1235-1243.
19. Cervantes-Castañeda RA, Gonzalez LA, Cordero-Coma M, Yilmaz T, Foster CS. Combined therapy of cyclosporine A and mycophenolate mofetil for the treatment of birdshot retinochoroidopathy: a 12 month follow up. *Br J Ophthalmol*. 2013;97(5):637-643.
20. Rothova A, Ossewaarde-van Norel A, Los LI, Berendschot TT. Efficacy of low-dose methotrexate treatment in birdshot chorioretinopathy. *Retina*. 2011;31(6):1150-1155. <https://doi.org/10.1097/IAE.0b013e3181ff0d8f>

**How to cite this article:** Vidas Pauk S, Vukojević N, Jandroković S, et al. Bilateral juxtapapillary choroidal neovascularization secondary to Birdshot chorioretinopathy—case report. *Clin Case Rep*. 2021;9:e04601. <https://doi.org/10.1002/ccr3.4601>