

Fatal intracranial hemorrhage in patient with thrombocytopenia and positive HIT antibodies after vaccination with ChAdOx1 nCoV-19 - VITT without thrombosis?

Grgić Medić, Marijana; Tomac, Gordana; Rimac, Vladimira; Zibar Tomšić, Karin; Kraljević, Ivana; Boban, Ana

Source / Izvornik: *Thrombosis Research*, 2022, 215, 55 - 57

Journal article, Published version

Rad u časopisu, Objavljena verzija rada (izdavačev PDF)

<https://doi.org/10.1016/j.thromres.2022.05.006>

Permanent link / Trajna poveznica: <https://urn.nsk.hr/urn:nbn:hr:105:122325>

Rights / Prava: [In copyright](#) / [Zaštićeno autorskim pravom.](#)

Download date / Datum preuzimanja: **2024-06-25**



Repository / Repozitorij:


[Dr Med - University of Zagreb School of Medicine Digital Repository](#)





Since January 2020 Elsevier has created a COVID-19 resource centre with free information in English and Mandarin on the novel coronavirus COVID-19. The COVID-19 resource centre is hosted on Elsevier Connect, the company's public news and information website.

Elsevier hereby grants permission to make all its COVID-19-related research that is available on the COVID-19 resource centre - including this research content - immediately available in PubMed Central and other publicly funded repositories, such as the WHO COVID database with rights for unrestricted research re-use and analyses in any form or by any means with acknowledgement of the original source. These permissions are granted for free by Elsevier for as long as the COVID-19 resource centre remains active.



Letter to the Editors-in-Chief

Fatal intracranial hemorrhage in patient with thrombocytopenia and positive HIT antibodies after vaccination with ChAdOx1 nCoV-19 - VITT without thrombosis?

Vaccination against Coronavirus disease 2019 (COVID-19) has been developed to reduce morbidity and mortality of a novel acute infectious multisystem disease caused by acute respiratory syndrome coronavirus type 2 (SARS-CoV-2) [1]. Four different vaccines against COVID have been approved by European Medicines Agency, two adenoviral vector (ChAdOx1 nCov-19 and Ad26.COV.2.S) and two mRNA based vaccines (BNT162b2, mRNA-1273).

Thrombotic thrombocytopenia following ChAdOx1 nCov-19 vaccination was described for the first time in April 2021 in health care workers in Norway [2]. The patients presented with thrombocytopenia and thrombosis at unusual sites, cerebral sinus vein and splanchnic vein thrombosis, but also life threatening intracranial hemorrhage. Positive antibodies to platelet factor 4-polyanion complexes were described in all patients. This novel entity was named vaccine induced immune thrombotic thrombocytopenia (VITT) [2]. Since then, VITT has been described in number of patients following vaccination with adenoviral vector based vaccines, ChAdOx1 nCov-19 (Astra Zeneca) and Ad26.COV.2.S (Johnson&Johnson).

We present the case of a previously healthy young male patient that developed thrombocytopenia and prothrombotic state following vaccination with ChAdOx1 and died due to massive intracranial hemorrhage.

31-year-old, otherwise healthy man was admitted to the regional hospital for sudden sharp pain in both thoracolumbar regions that occurred during the night's rest after strenuous physical activity.

The patient received the first dose of anti-COVID -19 ChAdOx1 nCov-19 vaccine 10 days earlier and developed fever and flu-like symptoms for 24 h. On the fourth day after vaccination, he developed diarrhea, and on seventh exacerbation of chronic sinusitis, and was treated with azithromycin.

He was admitted to hospital on the tenth day after vaccination, awake and alert with normal vital parameters and no signs of skin or mucosal bleeding. Bilateral adrenal hematomas (44 × 28 mm right, 41 × 25 mm left) were described at MSCT, and laboratory results revealed thrombocytopenia (Plts 77 × 10⁹/L) and increased D - dimers (12.6 mg/L). Furthermore, adrenal hematomas were interpreted as bleeding from efferent adrenal veins, possibly due to venous congestion and thrombosis of the adrenal veins, although no thrombosis was visualized on CT. The patient was transferred to our hospital for further evaluation.

We found persistent thrombocytopenia (Plts 66 × 10⁹/L), elevated fibrinogen (5.2 g/L) and d-dimers (17.62 mg/L), with normal PT and aPTT. Thrombotic thrombocytopenic purpura was excluded (no schistocytes on the peripheral blood smear, normal ADAMTS-13 level, no signs of hemolysis - LDH 216 IU/L, bilirubin 19 μmol/L, free plasma hemoglobin 22 mg/L). Flow cytometer tests were negative for bound and unbound IgG and IgM subclass of platelet-associated autoantibodies, also no evidence of antiphospholipid syndrome was found

(anticardiolipin antibody, beta-2-glycoprotein, and LAC were normal).

It was presumed that elevation of d-dimers could arise from adrenal haematomas. However, as it was suspected that hemorrhage occurred secondary to thrombosis, the patient received low-molecular weight heparin (LMWH), three doses of enoxaparin in total. He was not exposed to heparin in the past. Following introduction of LMWH hemoglobin level and platelet count remained stable.

The next day, patient suddenly became confused and disoriented, and MSCT confirmed intracerebral hematoma in the temporal and occipital lobes (55 × 30 mm in diameter) with suspected thrombosis of sagittal sinus. Despite treatment with rFVIIa and platelet transfusions, intracerebral hematoma progressed, and the patient was transferred to OR for urgent removal of the hematoma. However, a couple of hours later patient become unstable with clinical signs of further progression of intracranial bleeding and died in cardiac arrest. Autopsy revealed diffuse cerebral edema, acute hemorrhage in the left frontotemporo-parietal region and cerebellum, and diffuse subarachnoid hemorrhage. There was no evidence of thrombosis in the cerebral venous sinuses, renal or mesenteric veins. Microscopic analysis revealed no evidence of microangiopathy in the brain or other parenchymal organ.

Immuno-hematological testing to support the diagnosis of VITT was performed 47 days post mortem. Enzyme-linked immunosorbent assays (ELISA) for heparin induced thrombocytopenia (HIT) (PF4 IgG Kit; GTI Diagnostics, Waukesha, Wisconsin, USA) showed positive result: optical density (OD, 450 nm): 1618; threshold for positive test, >0.4). A functional assay was then performed to detect platelet-activating antibodies directed against PF4/heparin using flow cytometer (Fig. 1a, b, c).

Double labelling with monoclonal antibodies against anti-CD41a and anti-CD62P (BD Biosciences, San Jose, California) were used for HIT conformation Figure. Anti-CD41a was used as a platelet specific antibody for the detection of platelet specific glycoprotein IIb/IIIa. The results of functional platelet activation assay from our patient were compared with the results from a patient with typical HIT (positive control). Both sera demonstrated platelet activation and platelet inhibition with addition of a low and high heparin dose, respectively. Unlike the typical HIT positive serum, the serum from our patient demonstrated platelet activation also in the absence of heparin, regardless the addition of AZD1222.

Since the initial description in April 2021, a number of patients have been reported to develop thrombocytopenia and thrombosis after vaccination against COVID with adeno- vector vaccine [3,4]. Although the exact incidence is unknown, it has been estimated to occur in between 1 in 125,000 and 1 in 1 million of vaccinated cases [5]. An online registry has been developed to collect all clinically relevant information on the course, treatment strategies, and outcomes of VITT.

Although the pathogenesis of VITT is not fully understood, this

<https://doi.org/10.1016/j.thromres.2022.05.006>

Received 29 March 2022; Received in revised form 23 April 2022; Accepted 12 May 2022

Available online 18 May 2022

0049-3848/© 2022 Elsevier Ltd. All rights reserved.

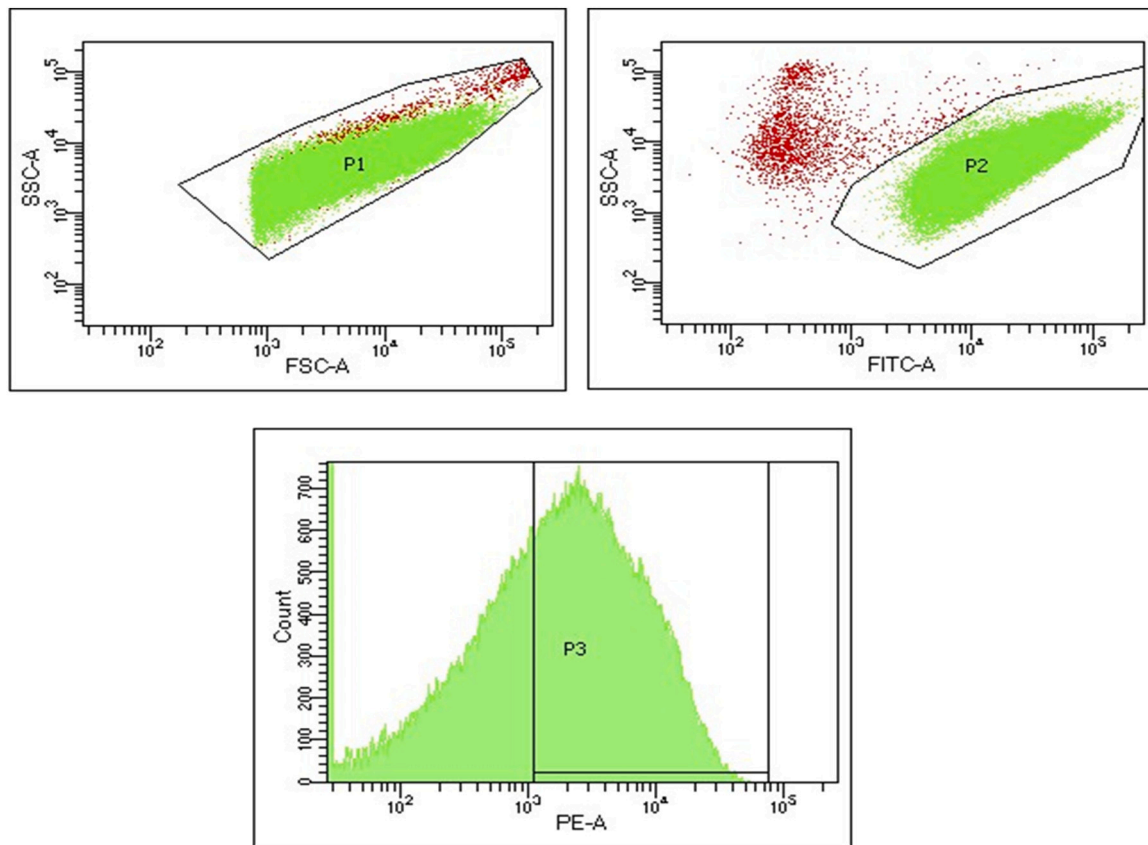


Fig. 1. Result of the functional assay on flow cytometer using donor platelets and patient's plasma sample. Protocol for determining platelets activation was set using SSC/FSC plot (1a) and anti-CD41-FITC antibody for detecting donor platelets (1b), with anti-CD62P-PE antibody for detecting activated donor platelets (positive result of test, 1c).

syndrome resembles autoimmune heparin-induced thrombocytopenia and has some laboratory features that have been observed in patients with severe COVID-19 infection [6]. Strongly positive anti-PF4 antibodies have been found in patients with VITT even when heparin was not administered. These antibodies can induce a procoagulant cellular response by binding to the FcγRII receptor on platelets, but also on monocytes and neutrophils. The risk of thrombosis with VITT, as in HIT, seemingly correlates strongly with levels of circulating anti-PF4 antibodies [7]. High ELISA optical density (OD), which is considered to be a close approximation to the circulating anti-PH4 antibody titer, was also detected in our patient. However, more data are needed to clarify the pathophysiology and risk factors associated with clinical presentation.

Most published cases describe venous thrombosis as the main clinical presentation of VITT, and in a number of patients concomitant intracranial hemorrhage has also been described [6-3, 9-4]. A single case report described a patient with VITT and fatal intracranial hemorrhage with no overt thrombosis, but cerebral thrombosis was revealed later on autopsy [8]. In our patient, no signs of thrombosis were found even on autopsy. To our knowledge, this is the first case of VITT described in the literature that has no proven thrombosis. Intracranial hemorrhage and low platelet counts have been associated with higher mortality in a cohort of patients that developed VITT after vaccination with ChAdOx1 nCoV-19 in UK [4]. On the other hand, thrombocytopenia and intracranial hemorrhage should raise suspicion of immune thrombocytopenia secondary to vaccination against COVID. Vaccine-induced immune thrombocytopenia (VIITP) is another syndrome associated with vaccination against COVID, although it has been dominantly described in patients vaccinated with mRNA vaccines [9]. Clinically, VITTP presents predominantly with a bleeding phenotype, and the anti-PF4 antibodies are mostly found to be negative. However, the differential

diagnosis between VITT and VIITP might be challenging, as the initial presentation can be severe bleeding in both syndromes. Therefore, the clinical suspicion should be immediately followed by the laboratory workup including testing for the anti-PF4 antibodies [6]. In patients that had received COVID-19 vaccination within 20 days, thrombocytopenia, high d-dimers and low fibrinogen should raise the suspicion of VITT, irrespectively on the presence of bleeding or thrombosis. The ELISA assay for PF4/heparin antibodies have been recommended for the conformation of VITT, followed by a functional platelet activation assay [6].

High titer of IgG anti-PF4 antibodies has been described in most cases with VITT in the literature, with very high OD values in ELISA test, in the range of 2.0–3.8 [2]. Our patient had slightly lower OD value, however, the results of functional assay, with the addition of a low and high heparin dose, were in accordance with previously published study [2], confirming the diagnosis of VITT.

As we treated this patient before the recognition of VITT and the publication of the first cases, we could not be aware about efficacy of high doses of intravenous immunoglobulins in this syndrome [10]. We used LMWH based on the procoagulant state and suspicion of thrombosis, together with the supportive treatment, however, we were unable stop rapidly progressive intracranial bleeding leading to death of the patient. Based on current knowledge that VITT behaves like HIT, a total avoidance of heparin could be reasonable.

Severe bleeding phenotype and lack of thrombosis in patient with VITT after vaccination with ChAdOx1 nCoV-19 suggests that this new syndrome may have broad spectrum of clinical presentations. We believe that the lack of overt thrombosis in this patient does not exclude the VITT, but emphasizes the need to distinguish VITT from VIITP, a syndrome with more benign clinical presentation and different

therapeutic management. The results from the large international registry might give us more insight into pathogenesis and management of VITT.

CRedit authorship contribution statement

IK, KZT, AB and MGM treated the patient, GT and VR performed immunohematologic and functional activation tests. All authors contributed to writing and critically assessment of the manuscript.

Declaration of competing interest

The authors declare that they have no known competing financial interests or personal relationships that could have appeared to influence the work reported in this paper.

References

- [1] W.J. Wiersinga, A. Rhodes, A.C. Cheng, S.J. Peacock, H.C. Prescott, Pathophysiology, transmission, diagnosis and treatment of coronavirus disease 2019 (COVID-19): a review, *JAMA* 25 (324(8)) (2020) 782–793.
- [2] N.H. Schultz, I.H. Sørvoll, A.E. Michelsen, L.A. Munthe, F. Lund-Johansen, M. T. Ahlen, M. Wiedmann, A.-H. Aamodt, T.H. Skattør, G.E. Tjønnfjord, P.A. Holme, Thrombosis and thrombocytopenia after ChAdOx1 nCoV-19 vaccination, *N. Engl. J. Med.* 384 (2021) 2124–2130.
- [3] M. Sharifian-Dorche, M. Bahmanyar, A. Sharifian-Dorche, P. Mohammadi, M. Nomovi, A. Mowla, Vaccine-induced immune thrombotic thrombocytopenia and cerebral venous sinus thrombosis post COVID-19 vaccination; a systematic review, *J. Neurol. Sci.* 15 (428) (2021 Sep), 117607.
- [4] S. Phageavord, M. Scully, B.J. Hunt, W. Lester, C. Bagot, B. Craven, A. Rampotas, G. Ambler, M. Makris, Clinical features of vaccine-induced immune thrombocytopenia and thrombosis, *N. Engl. J. Med.* 11 (2021 Aug).
- [5] F.A. Klok, K. Pai, M. Huisman, M. Makris, Vaccine-induced immune thrombotic thrombocytopenia, *Lancet Hematol.* 9 (1) (2021) e73–e80.
- [6] I. Nazy, U.J. Sachs, D.M. Arnold, S.E. McKenzie, P. Choi, K. Althaus, M.T. Ahlen, Grace R.F. Sharma, Recommendations for the clinical and laboratory diagnosis of VITT against COVID-19: communication from the ISTH SSC subcommittee on platelet immunology, *J. Thromb. Haemost.* 19 (6) (2021) 1585–1588.
- [7] G.M. Arepally, T.L. Ortel, Vaccine-induced immune thrombotic thrombocytopenia: what we know and do not know, *Blood* 138 (4) (2021 Jul 29) 293–298.
- [8] T.H. Bjørnstad-Tuveng, A. Rudjord, P. Anker, Fatal cerebral haemorrhage after COVID-19 vaccine, *Tidsskr. Nor. Laegeforen.* 29 (2021 Apr) 141.
- [9] E.J. Lee, D.B. Cines, T. Gernsheimer, C. Kessler, M. Michel, M.D. Tarantino, J. W. Semple, D.M. Arnold, B. Godeau, M.P. Lambert, J.B. Bussel, Thrombocytopenia following Pfizer and Moderna SARS-CoV-2 vaccination, *Am. J. Hematol.* 96 (5) (2021 May 1) 534–537.
- [10] A. Bourguignon, D.M. Arnold, T.E. Warkentin, J.W. Smith, T. Pannu, J.M. Shrum, Z.A.A. Al Maqrashi, A. Shroff, M.C. Lessard, N. Blais, J.G. Kelton, I. Nazy, Adjunct immune globulin for vaccine-induced immune thrombotic thrombocytopenia, *N. Engl. J. Med.* 385 (8) (2021 Aug 19) 720–728.

Marijana Grgić Medić^a, Gordana Tomac^b, Vladimira Rimac^b, Karin Zibar Tomšić^c, Ivana Kraljević^c, Ana Boban^{d,*}

^a Division of Intensive Care Medicine, University Hospital Centre Zagreb, Zagreb, Croatia

^b Clinical Department of Transfusion Medicine and Cellular Therapy, University Hospital Centre Zagreb, Zagreb, Croatia

^c Division of Endocrinology and Diabetes, University Hospital Centre Zagreb, School of Medicine, University of Zagreb, Zagreb, Croatia

^d Division of Hematology, Department of Internal Medicine, University Hospital Centre Zagreb, School of Medicine, University of Zagreb, Zagreb, Croatia

* Corresponding author at: Division of Hematology, Department of Internal Medicine, University Hospital Centre Zagreb, Kispaticeva 12, 10 000 Zagreb, Croatia.

E-mail address: ana.boban@kbc-zagreb.hr (A. Boban).