

Tetralogy of Fallot

Iecho, Eleas

Master's thesis / Diplomski rad

2021

Degree Grantor / Ustanova koja je dodijelila akademski / stručni stupanj: **University of Zagreb, School of Medicine / Sveučilište u Zagrebu, Medicinski fakultet**

Permanent link / Trajna poveznica: <https://um.nsk.hr/um:nbn:hr:105:518861>

Rights / Prava: [In copyright](#)/[Zaštićeno autorskim pravom.](#)

Download date / Datum preuzimanja: **2024-07-22**



Repository / Repozitorij:

[Dr Med - University of Zagreb School of Medicine Digital Repository](#)



**UNIVERSITY OF ZAGREB
SCHOOL OF MEDICINE**

Eleas Iečo

Tetralogy of Fallot

GRADUATION PAPER



Zagreb, 2022

This graduate thesis was made at the Department of Pediatric Cardiology of University Hospital Centre Zagreb, mentored by izv. Prof. dr. sc. Daniel Dilber and was submitted for evaluation in academic year 2021/2022.

Abbreviations

TOF – Tetralogy of Fallot
CHD – Congenital heart defect
VSD – Ventricular septal defect
RVOT – Right ventricular outflow tract
RVOTO – Right ventricular outflow tract obstruction
RVH – Right ventricular hypertrophy
PS – Pulmonary stenosis
RV – Right ventricle
PDA – Patent ductus arteriosus
MAPCAs – Major aortopulmonary collateral arteries
SVR – Systemic vascular resistance
PVR – Pulmonary vascular resistance
LVEDP – Left ventricular end-diastolic pressure
FTT – Failure to thrive
ECG – Electrocardiogram
ECMO – Extracorporeal membrane oxygenation
PGD – Prostaglandin
SPAS – Surgically placed aortopulmonary shunt
CPB – Cardiopulmonary bypass
PR – Pulmonary regurgitation
LCOS – Low cardiac output syndrome
JET – Junctional ectopic tachycardia
SVT – Supraventricular tachycardia
RBBB – Right bundle branch block
LBBB – Left bundle branch block
ICD – Implantable cardioverter defibrillator

Table of content

Summery	1
Sažetaka	1
Introduction	2
Epidemiology	3
Etiology	3
Anatomy	3
Anatomical variants of TOF	5
Pathophysiology	6
Clinical presentation	8
Diagnosis	9
Antenatal diagnosis	10
Postnatal diagnosis	10
Treatment	13
Medical management	13
Surgical management	15
Postoperative management	17
Prognosis	19
Acknowledgments	21
Biography	21
References	22

Summery

Title: Tetralogy of Fallot

Author: Eleas lecho

Tetralogy of Fallot (TOF) is one of the most common cyanotic congenital cardiac malformations and is characterized by four cardinal features: a large VSD; often a dynamic right ventricular outflow tract obstruction (RVOTO); an overriding aorta; and right ventricular hypertrophy (RVH). The severity of the RVOTO, the pressure gradient between the ventricles, and the proportion of the aorta overriding the VSD determine the clinical presentation and the severity of this condition. There are several variants of this condition, that range from mild to very severe, which is distinguished by the degree of the cyanosis. Exaggeration of the condition might occur, which is known as hypercyanotic spells, or tet spells. These spells result in worsening of the right-to-left shunt that leads to a worsening of cyanosis, and if left untreated it will result in death. In the current era, more and more cases are diagnosed antenatally due to better screenings during the pregnancy but also due to improved diagnostic procedures.

The majority of cases are managed by a single-step surgical correction. Due to an improved surgical technique, most cases of TOF could be completely repaired within the first 6 months of life. Although, if the case is severe, a two-step procedure must be done, first-step would be an insertion of a palliative shunt, and after few months the second-step which is a complete correction.

Keywords

Tetralogy of Fallot, congenital heart defect, hypercyanotic spells, tet spells, right ventricular outflow tract obstruction, and nonrestrictive ventricular septal defect.

Sažetaka

Nazlov: Tetralogija Fallot

Autor: Eleas lecho

Tetralogija Fallot (TOF) jedna je od najčešćih cijanotičnih kongenitalnih srčanih malformacija i karakteriziraju je četiri kardinalne značajke: veliki VSD; često dinamička opstrukcija izlaznog trakta desne klijetke (RVOTO); nadmoćna aorta; i

hipertrofija desne klijetke (RVH). Ozbiljnost RVOTO-a, gradijent tlaka između ventrikula i udio aorte koja nadmašuje VSD određuju kliničku sliku i težinu ovog stanja. Postoji nekoliko varijanti ovog stanja, od blage do vrlo teške, koje se razlikuje po stupnju cijanoze. Može doći do preuveličavanja stanja, što je poznato kao hipercijanotične čarolije ili tet čarolije. Ove čarolije rezultiraju pogoršanjem šanta od desne na lijevu stranu što dovodi do pogoršanja cijanoze, a ako se ne liječe, rezultirat će smrću. U današnje vrijeme sve se više slučajeva dijagnosticira antenatalno zbog boljih probira tijekom trudnoće, ali i zbog poboljšanih dijagnostičkih postupaka.

U većini slučajeva upravlja se kirurškom korekcijom u jednom koraku. Zbog poboljšane kirurške tehnike, većina slučajeva TOF-a može se u potpunosti popraviti unutar prvih 6 mjeseci života. Iako, ako je slučaj težak, mora se napraviti zahvat u dva koraka, prvi bi korak bio umetanje palijativnog šanta, a nakon nekoliko mjeseci drugi korak koji je potpuna korekcija.

Introduction

Tetralogy of Fallot is a congenital cardiac malformation, where the etiology is unclear. It's thought that the etiology is multifactorial, it has been associated with maternal factors (age, diabetes, hypertension, smoking etc.), genetic factors, and environmental factors. Two-thirds of all the TOF cases have isolated CHD, without any evidence of chromosomal anomaly or genetic syndrome. The remaining one-third of the cases will be associated with chromosomal anomalies including trisomy 13, 18, and 21, or genetic syndrome such as DiGeorge syndrome (1). The embryologic process that contributes to the development of malformation is still uncertain, however an anterior and cephalad deviation of the infundibular septum has been observed resulting in the misaligned VSD, with an overriding aortic root that causes an RVOTO (2).

This condition occurs in 3 of every 10,000 live births, and accounts for approximately 7-10% of all congenital cardiac malformation, making it the most common cyanotic congenital heart malformation (3).

In this era, around 50% of all cases of TOF are diagnosed during the pregnancy, antenatally, by a fetal echocardiography (2). The malformation could be diagnosed as early as 12th week of gestation (3). After birth the diagnostic procedures includes ECG, chest x-ray, echocardiography, and sometimes also cardiac catheterization.

The definitive diagnosis is made by the echocardiography, which usually provides sufficient amount of information to design a surgical plan (3).

Epidemiology

Tetralogy of Fallot is one of the most common forms of CHD and accounts for approximately 7-10% of all congenital cardiac malformations (4). About 1 in 100 newborns is diagnosed with a CHD, of which 10% are diagnosed with TOF (5). It has an incidence of 1 in 3,500 live births (4). This condition accounts for one-third of all CHD in patients younger than 15, while in adults, TOF has an estimated prevalence of 1 in 3,500 to 1 in 4,300 (6). There doesn't appear to be any significant predisposition toward gender or race (7).

Etiology

The precise etiology of the CHD is unknown and like many other congenital cardiac defects, TOF occurs sporadically. Approximately two-thirds of patients with TOF have isolated CHD, without evidence of chromosomal anomaly or genetic syndrome. (1)

The remaining one-third of infants and children affected with TOF will have chromosomal anomalies, such as Down syndrome (trisomy 21), Edwards syndrome (trisomy 18), and Patau syndrome (trisomy 13) or genetic syndromes such as CATCH-22 (1). CATCH-22 is characterized by cardiac defects, abnormal facial features, thymic hypoplasia, cleft palate, and hypocalcemia. It results from a microdeletion within chromosome 22q11.2 and is associated with DiGeorge syndrome (3,6).

Environmental factors associated with a higher incidence of TOF include alcohol and tobacco use during pregnancy, maternal diabetes, poor prenatal nutrition, maternal age older than 40, and maternal rubella infection (during the first trimester) (8).

Anatomy

This congenital defect results from an abnormal separation of truncus arteriosus into the aorta and pulmonary artery (9) and causes anterior-cephalad displacement of the infundibular septum (10). This results in 4 structural defects (figure 1): a ventricular

septal defect (VSD), an overriding aorta, a right ventricular outflow tract obstruction (RVOTO), and right ventricular hypertrophy (RVH) (9).

Ventricular septal defect

The septal defect is often located in the perimembranous and muscular regions of the ventricular septum, and is usually a large and non-restrictive defect. It allows the shunting of blood freely between the two ventricles (right-to-left shunting) (4).

Overriding aorta

Due to the abnormal separation of truncus arteriosus and malpositioning of the infundibular septum, the aorta is displaced between the right and left ventricles directly above the VSD. As a result, deoxygenated blood from the right ventricle (RV) flows directly into the aorta, instead of the pulmonary artery towards the lungs. (11)

Right ventricular outflow tract obstruction

The obstruction to pulmonary blood flow at the level of the RVOT is a key feature of TOF (4). The greater the RVOTO is, the greater the right-to-left shunting will become, due to the worsening of RVH and non-restrictive VSD (4). The obstruction to the RVOT could be located at the: sub-valvular level (accounts for 50% of all patients), at the pulmonary valve due to pulmonary stenosis (PS) (accounts for approximately 10%), supra-valvular (accounts for approximately 10%), or a mixture (which accounts for approximately 30% of all cases) (4).

Right ventricular hypertrophy

RV hypertrophy develops as a consequence of the increased pressure within the RV. The pressure is caused by the RVOTO and needs to be generated to maintain the pulmonary blood flow. Hypertrophy is a compensatory mechanism to maintain the blood flow, but as a consequence, it alters the size of the RV and the muscle mass (4).

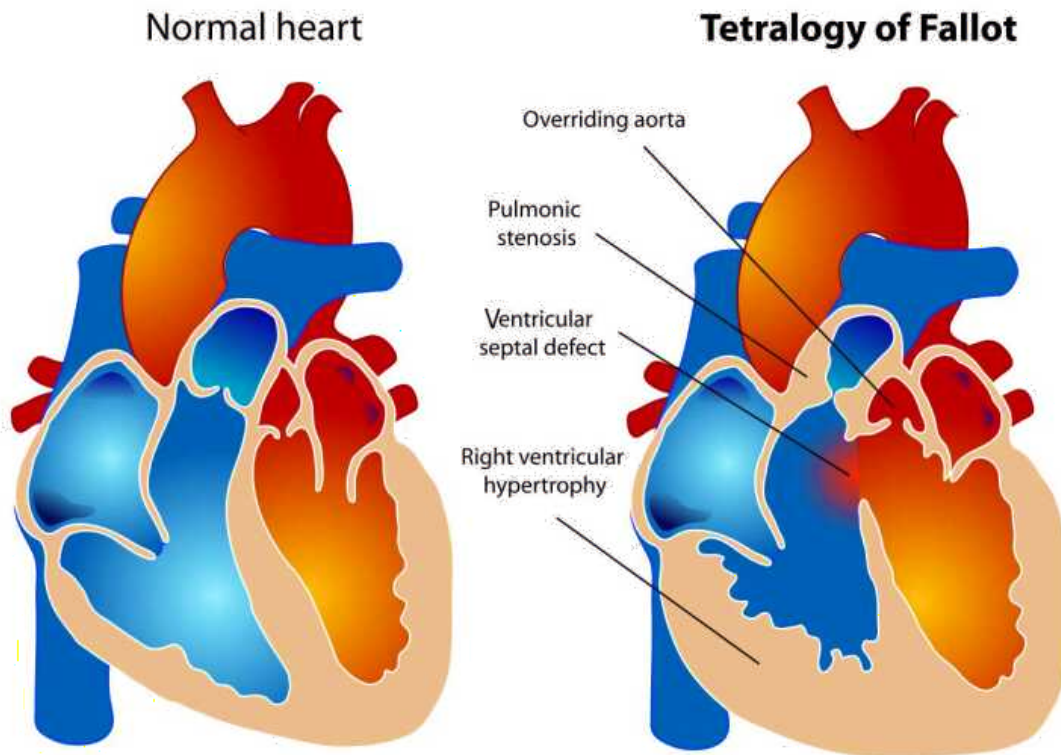


Figure 1. A diagram showing a normal heart compared to one suffering from TOF. Contributed by Wikimedia Commons, LadyofHats (Public Domain)

Anatomical variants of TOF

There are several variants of TOF, largely distinguished by the degree of cyanosis displayed. The following variants are the key important types. (4)

Acyanotic TOF

Is also known as Pink Fallot. The infants and children affected with this variant are acyanotic and have a normal or near-normal oxygen saturation. The degree of RVOTO is minimal with little aortic override. This type behaves like a large unrestricted VSD with a left-to-right shunt. The patient is acyanotic because oxygenated blood from the left side is shunted through the ventricular septum to the right side (4).

Classic TOF

Is also known as Blue Fallot. These children have a degree of RVOTO and aortic override that leads to a degree of right-to-left shunting. This right-to-left shunting results in cyanosis (4).

TOF with pulmonary atresia

This variant of TOF is the most serious one and accounts for approximately 15% of all cases. It's characterized by complete atresia of the pulmonary valve. Due to the complete occlusion of the pulmonary valve, the blood completely bypasses the lungs and therefore flows through the VSD into the LV and then into the aorta. This results in a severe concentration of deoxygenated blood in the arterial circulation. In this variant, intracardiac mixing is essential for survival. All pulmonary blood flow must be supplied from the aorta either by a duct-dependent pulmonary circulation (e.g. PDA) or from major collaterals (major aortopulmonary collateral arteries, MAPCAs) (4). Most neonates with this type are asymptomatic, with enough pulmonary blood flow resulting in acceptable oxygen saturation without signs of congestive heart failure. But over time, stenosis of the MAPCAs may develop, resulting in limitation of the blood flow and cyanosis (12).

Pathophysiology

The misalignment in the TOF allows the mixing of blood between the pulmonary and systemic circulations. The mixing usually occurs at the VSD. The right-to-left shunt through the VSD is determined by the pressure differences between the RV and LV. The amount of pulmonary blood flow (the RV stroke volume) is determined by the severity of the RVOTO. Frequently, the severity of RVOTO has both fixed anatomical and variable physiological components.

There are factors that could either improve or worsen the right-to-left shunting. Some of the factors include:

Systemic vascular resistance

A large reduction of systemic vascular resistance (SVR) in the presence of RVOTO, will exacerbate any right-to-left shunt by reducing the LV end-diastolic pressure

(LVEDP), thus increasing the pressure gradient. For example, a hot bath, infections, or vasodilating drugs reduces the SVR. That's why, in unrepaired TOF, it's important to avoid drugs that reduce the SVR. An increase in SVR has an opposite effect, it reduces the right-to-left shunting. (4)

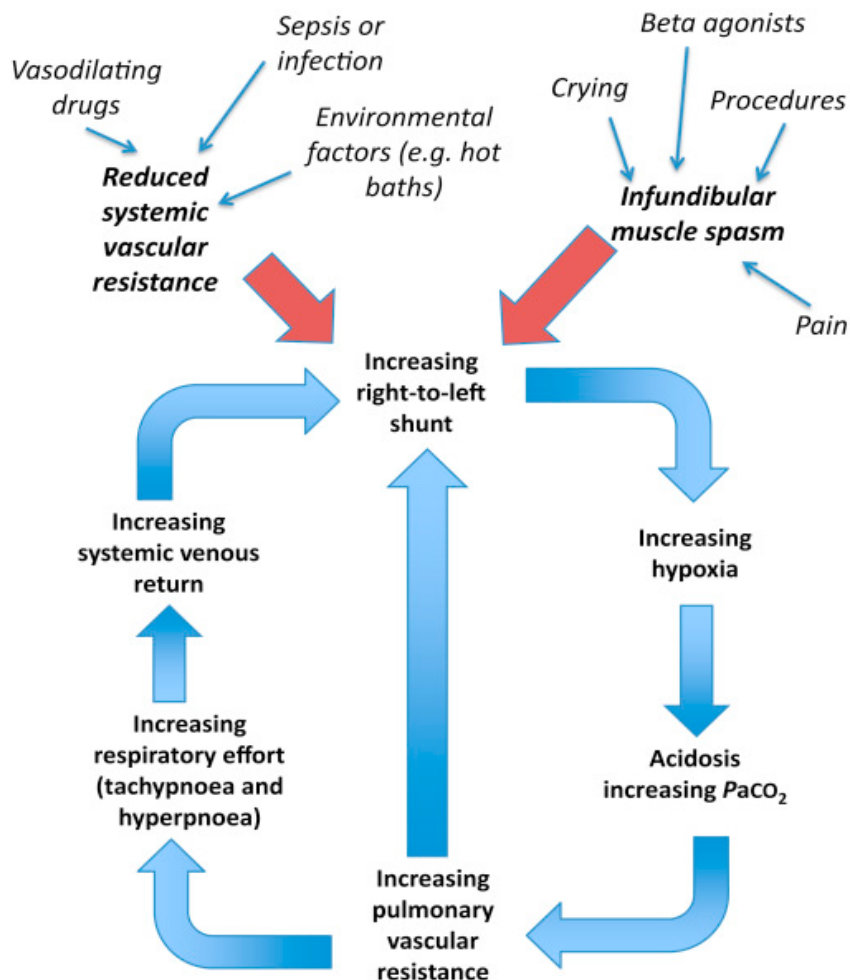


Figure 2 Pathophysiology of TOF. © 2019 British Journal of Anaesthesia. Published by Elsevier Ltd (4).

Infundibular muscle spasm

The infundibular muscle spasm is caused by times of distress, such as crying, pain, and by the use of beta-agonists. Infundibular muscle spasm causes dynamic RVOTO, and when added to any fixed RVOTO, it then exaggerates the right-to-left shunt fraction. Due to the exaggeration of shunting, episodes of profound hypoxemia will occur. These episodes of sudden oxygen desaturation are often referred to as either Tet spells or cyanotic spells. (4)

Pulmonary vascular resistance (PVR)

When the right-to-left shunt increases and worsens, it will contribute to a decrease in arterial PO_2 and at the same time increase in the arterial PCO_2 and a decrease in pH. A decrease in PO_2 and increase in PCO_2 results in an increase in PVR and stimulates the respiratory center, contributing to tachypnea and hyperpnea. Hyperpnea increases the systemic venous return, which causes the right-to-left shunting to worsen, and that will result in worsening cyanosis (4,13).

Clinical presentation

The clinical presentation of TOF varies depending on the severity of the RVOTO. Newborn infants are commonly asymptomatic and often acyanotic (7). But during the neonatal period, most of the patients will develop a mild-to-moderate condition with cyanosis but typically without any respiratory distress. For those patients that are born with a very mild obstruction might be misdiagnosed or undiagnosed at birth and with time the obstruction worsens resulting in newly noticed cyanosis and a louder murmur (3). The oxygen saturation in these patients is usually between 80 and 90% (7).

The majority, if not all, of the patients with TOF have difficulty with feeding, this could lead to failure to thrive (14).

On auscultation, the second heart sound is single and loud, a harsh crescendo-decrescendo systolic ejection murmur can be heard at the upper left sternal border due to blood flow across the narrowed pulmonary valve (7). But when the RVOT is severely obstructed, the murmur will be less prominent (3). In other words, the intensity and duration of the systolic murmur are inversely related to the severity of the RVOTO (13). The VSD is commonly not heard because the defect is large and doesn't block the blood flow.

The presence of a continuous murmur in infants may be a sign of TOF with pulmonary atresia and occur in more than 80% of such patients (15). This murmur is heard over the site of a large MAPCA or PDA. The intensity of the murmur may increase as the PVR decreases (12).

Infants and children with uncorrected TOF are at risk for severe episodes of cyanosis also known as hypercyanotic spells, which are also commonly referred to as “tet spells” or “hypoxic spells”. These types of episodes rarely occur in children younger than 9-12 months of age (7), and the frequency of the episodes decreases after 4-5 years of age (2). They are true emergencies, and are characterized by hyperpnea, worsening cyanosis, the disappearance of heart murmurs, and could result in CNS complications, such as syncope or loss of consciousness, and eventually death. Tet spells are triggered by stressors, such as crying, feeding, dehydration, and anxiety (7,13).

Older children with TOF, often instinctively assume a squatting position to relieve the symptoms, to catch their breath. By squatting, the SVR increases which leads to a decrease in right-to-left shunting and at the same time an increase in pulmonary blood flow (7,16). Tet spells that occur in infants and younger children can be broken by bringing their knees up to their chests. This squatting appearance is known as Fallot’s sign (17).

Infants and children with uncorrected TOF are at high risk for morbidity and mortality due to complications related to severe cyanosis, exercise intolerance, arrhythmias, cerebrovascular complications, or congestive heart failure due to long-standing RVH (12).

Children with unrepaired long-standing cyanotic TOF may develop a condition known as hypertrophic osteoarthropathy (12), which is characterized by clubbing of the digits, periostitis of the long (tubular) bones, and arthritis (18).

Diagnosis

Tetralogy of Fallot can be diagnosed during pregnancy (antenatally) but also soon after birth.

Antenatal diagnosis

During pregnancy, screening tests are made to check for any birth defects, such as TOF. When signs of TOF are seen during a normal ultrasound check-up, the patient is referred to do fetal echocardiography (19). Generally, the reason for patients to be referred to do fetal echocardiography, with suspicion of TOF, includes a severe phenotype, discovery of extra-cardiac malformation, or a known chromosomal abnormality (3).

During a sonographic examination, a finding such as thickened nuchal translucency in the first trimester could be a sign of an increased risk of TOF, especially in a fetus with DiGeorge syndrome (chromosome 22q11 deletion) (20).

Up to 50% of all cases of TOF are diagnosed antenatally by fetal echocardiography (2), and it could be diagnosed as early as 12 weeks of gestation (3).

Fetal echocardiographic findings suggestive of TOF may be: a large aortic root (most common antenatal finding), a small pulmonary artery or a RVOTO, a VSD in the outlet portion of the septum, an overriding aorta, and/or RVH (20).

Finding such as: no blood flow through the pulmonary artery, reversed flow in ductus arteriosus, the collateral blood supply from the aorta to the lungs, and main pulmonary arteries are absent or very small could suggest TOF with pulmonary atresia (20).

A chromosomal analysis should be performed together with an anatomic survey because TOF could be associated with trisomy 18 or 13, but also DiGeorge syndrome (20).

Postnatal diagnosis

Sometimes during the pregnancy, TOF won't be pronounced enough to be detected. When the infant is born some clues could be found during a normal physical examination, such as a murmur, cyanosis, or extra-cardiac malformations that need to be investigated further.

Useful procedures to help us with diagnosing and evaluating TOF after birth include chest X-ray, electrocardiogram (ECG), echocardiography, and sometimes even cardiac catheterization is needed.

Chest x-ray

The hallmark of TOF is a boot-shaped heart (figure 3) with a prominent upturned cardiac apex due to RVH and concavity in the region of the main pulmonary artery (12), but most infants with TOF may not show this finding (21).

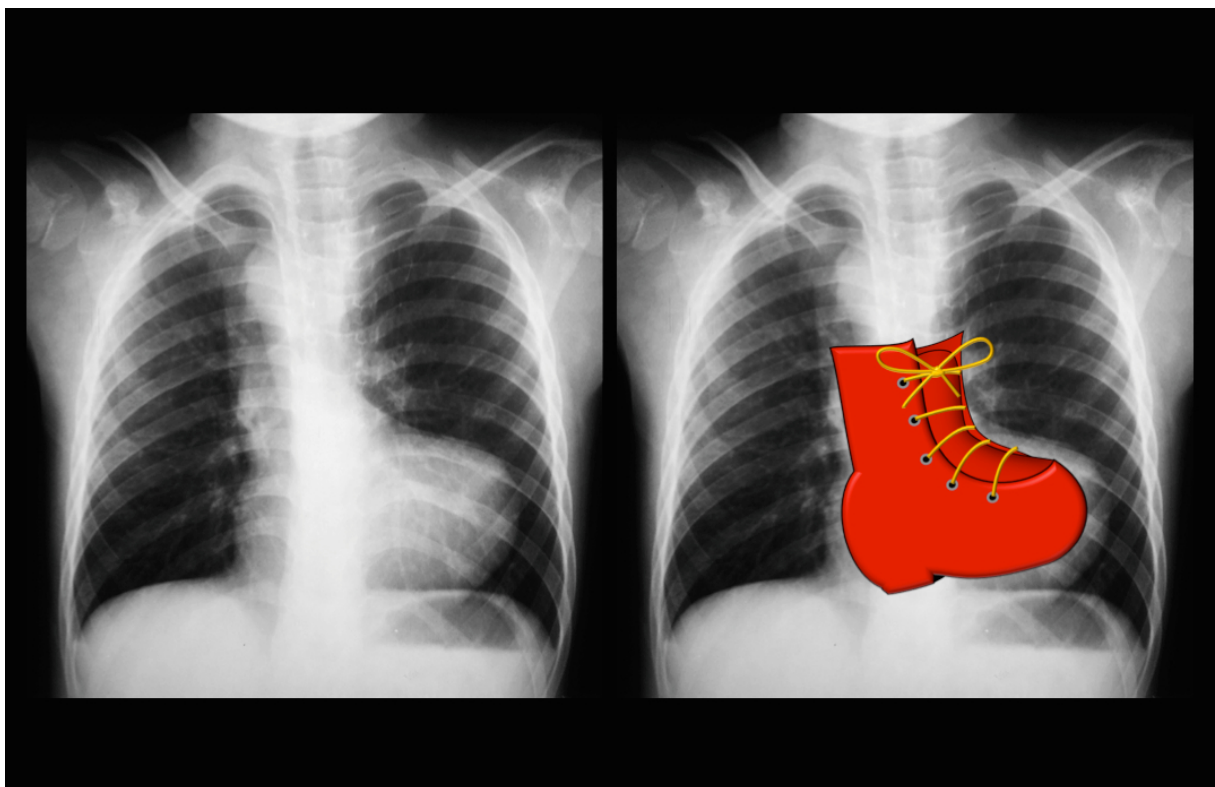


Figure 3 The hallmark of TOF. Case courtesy of Dr. Vincent Tatco, Radiopaedia.org, rID: 43059 (21)

Electrocardiogram

The main finding on an ECG is RVH, which is noted by a tall R-wave in lead V₁ and a deep S-wave in lead V₆ (7). An upright and peaked T-wave in the precordial leads, and right axis deviation could also be seen (12).

Echocardiogram

Echocardiography is the gold standard diagnostic procedure for detecting intracardiac malformations, such as TOF (12). There are 3 basic modes that could be used during imaging of the heart (22):

- Two-dimensional (2D) imaging
- M-mode imaging
- Doppler imaging

The 2D imaging allows the heart structure to be viewed in real-time in a cross-section. This mode is used to detect abnormal anatomy or abnormal movement of structures. The most popular cross-sectional views are (22):

- Parasternal long-axis
- Parasternal short-axis
- Apical view

In the parasternal long-axis view, we could determine the size and check the function of the right and left ventricle, monitoring the degree of the aortic override, and analyzing the VSD.

In the parasternal short-axis view, we could localize the exact location of the VSD, uncover the anatomy of the RVOT, and determine the anatomy of the pulmonary valve.

In apical view, we have a view of all 4 chambers which is used to assess right and left ventricular size and function.

M-mode imaging provides a monodimensional (1D) view and is used for fine measurements (22).

The Doppler imaging technique is used in 3 ways:

- Continuous-wave (CW) doppler
- Pulsed-wave (PW) doppler
- Color-flow mapping (CFM)

CW Doppler is used to assess the severity of valve stenosis or regurgitation, and the flow velocity through the RVOT.

The PW Doppler is used to assess ventricular blood flow patterns, intracardiac shunts, and make exact measures of blood flow at the valve orifices.

The CFM allows us to determine the flow of the blood to a region of interest. In general, the red color indicates that the blood is flowing towards the transducer and the blue color indicates that the blood is flowing away from the transducer. In higher velocities, the colors are shown in lighter shades (22). In patients with TOF with pulmonary atresia, echocardiography with CFM will show the lack of flow between the RV and PA.

Cardiac catheterization and angiography

Due to improvements in 2D and CFM echocardiography, the need for cardiac catheterization has reduced significantly (12). Even though the use has been reduced, these procedures are still been used, especially in severe cases of TOF with pulmonary atresia. These diagnostic procedures determine the anatomical location of MAPCAs and also the coronary arteries, which allows the surgeon to plan for the surgical repair (7,12).

Treatment

The definitive management of TOF is a complete surgical repair (17). The complete surgical repair can safely be performed when the infant reached the age of 4-6 months (7). The majority of neonates and infants born with TOF do not require any active management and instead are managed as an outpatient until they reach the ultimate age and weight for the repair. Some of the patients are born with a more severe form of the condition and need to be treated acutely.

Medical management

Infants born with severe RVOTO are treated pharmaceutically until palliative or complete surgical repair can be performed. These infants need a PDA to supply enough blood flow to the pulmonary system. Generally, an infusion of Prostaglandins (PGD), such as Alprostadil (PGDE₁) or Dinoprostone (PGDE₂), is required to keep the ductus arteriosus open (4).

An infant with a closed PDA and uncorrected TOF may suffer from an acute episode of tet spell, also known as hypercyanotic spell. These spells are very dangerous and

result in acute desaturation and clinical deterioration of the patient (4). What's happening is that, there's a sudden reduction in pulmonary blood flow, due to infundibular spasms, resulting in an increase in right-to-left shunting. As figure 2 shows, the consequences of increased right-to-left shunting, including hypoxia/cyanosis, acidosis, and hyperpnea, will worsen the right-to-left shunting even more. By knowing that, the management of these episodes is to break the cycle. The treatment of these spells must focus on decreasing the PVR and increasing the SVR, hence promoting a left-to-right shunt (3). The treatment of these episodes includes (4,13,23):

- Avoid any triggers, such as crying or exercise
- Knee-to-chest position for infants and squatting toddlers
- High-flow oxygen therapy, which helps with lowering the PVR
- Administration of sedative and analgesia, such as morphine sulfate, fentanyl, and Dexmedetomidine
- IV fluids to improve the RV filling
- Alpha-agonists (phenylephrine noradrenaline) or vasopressin may be administered to increase the SVR, and reduce the right-to-left flow
- Sodium bicarbonate (NaHCO_3) to correct the acidosis
- Beta-blockers (IV Propranolol or Esmolol)
- IF all of the above fails, the patient is connected to extracorporeal membrane oxygenation (ECMO) support and palliative surgery should be considered

According to the recommendation of the American Heart Association guidelines, all patients with an uncorrected cyanotic congenital heart disease should receive antibiotic prophylaxis for subacute bacterial endocarditis before the surgical repair (2). The prophylaxis is indicated until 6 months after the complete surgical repair unless there's a residual VSD. It's then continued until the VSD is corrected (24).

Those patients with a mild RVOTO and a large VSD usually have a left-to-right shunt. This could lead to heart failure. If heart failure develops, inotropic agents, such as Digoxin, and loop diuretics, such as furosemide, should be given (2,4).

Surgical management

Eventually, all patients suffering from TOF will require surgical intervention. The ultimate question is when to do it and whether to first palliate or to perform a complete surgical repair. It's the patient's condition that determines the timing of the intervention (12). Situations where surgical intervention needs to be planned fairly urgently include (23):

- Progressive worsening of infundibular and valvular obstruction resulting in an exaggeration of hypoxemia, with oxygen saturation less than 75-80%
- Severe hypercyanotic spells
- Dependence on PGD from an early neonatal age (commonly seen in TOF with pulmonary atresia)

Cardiac catheter intervention

Is a type of palliative procedure that uses cardiac catheterization to help improve pulmonary blood flow in the neonatal and infant period whilst waiting to the ultimate age for a complete repair. Usually, the procedures are in form of a pulmonary valvotomy or RVOT stenting. The PDA could also be stented, which would reduce the need for use of PGD in those children who are duct-dependent (4).

Palliative intervention

Palliative procedures are now often reserved for infants who are PGD-dependent, are of low birth weight, in those with hypercyanotic spells, or in those patients with significant RVOTO and hypoxemia (1).

Nowadays, patients undergoing a surgically placed aortopulmonary shunt (SPAS) with the goal of having the complete surgical repair within the next 4 to 8 months. There are different types of SPAS, the common ones include the modified Blalock-Taussig (mBT) shunt, which connects the subclavian artery to the ipsilateral branch of the pulmonary artery; and a Central shunt, which connects the ascending aorta with the main pulmonary artery (12).

After the surgery, antiplatelet and anticoagulation therapy varies significantly among institutions (12).

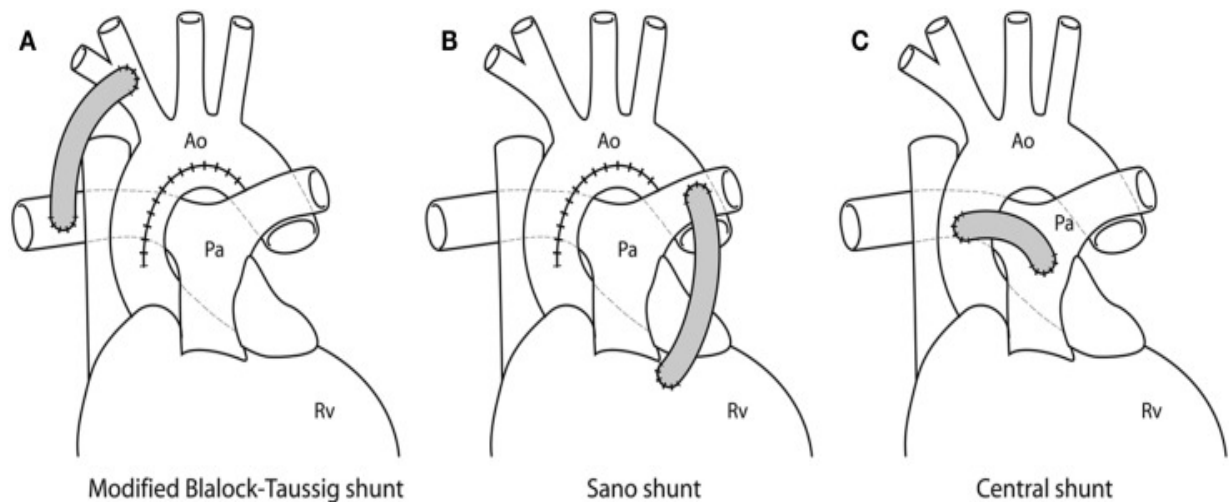


Figure 4. Different palliative shunting options. A) mBT shunt is connected between the right subclavian artery and the ipsilateral branch of the PA. B) Sano shunt is connected between the RV and PA. C) Central shunt is connected between the ascending aorta and the main PA. Copyright © 2013 Biglino, Giardini, Hsia, Figliola, Taylor, Schievano and MOCHA Collaborative Group.(25)

Advantages of shunt placement include (1):

- Constructing a type of PDA that will correct the hypoxemia by establishing a secure source of blood flow to the lungs
- This procedure gives the neonate time to grow and reach the ultimate age for a complete repair
- Doesn't require cardiopulmonary bypass (CPB) (12)

Disadvantages of shunt placement include (1):

- Potential distortion of the branch of the pulmonary artery
- Thrombosis
- It's a 2-stage repair (first shunt placement and then complete surgical repair)

Complete surgical repair

As we mentioned earlier, complete surgical repair of TOF is usually performed around 4 to 6 months of age as an open intracardiac surgery where the patient is required to be performed under CPB. It's performed relatively early in life to reduce the adaptation of the TOF physiology, this shift in timing has led to a reduction in

neonatal mortality by improving the development of the pulmonary system early on, to reduce the RVH development, and subsequent fibrosis (4).

The surgical repair of the TOF involves using a patch to close the VSD, resection of the muscle bundles to reconstruct the RVOT, septate the aorta back to the left ventricle, and reduce the degree of RVOT valvular stenosis (1,4). A transannular patch might be needed to sufficiently enlarge the RVOT, caused by severe stenosis to the pulmonary artery. However, by using a transannular patch it leads to an insufficient pulmonary valve resulting in pulmonary regurgitation (PR) (4,7).

In most cases, a transatrial-transpulmonary approach is used, allowing us to avoid the right ventriculotomy technique and preserve the pulmonary annulus. However, in presence of severe infundibular stenosis, the right ventriculotomy technique might be necessary (23).

Postoperative management

The postoperative course varies depending on multiple factors such as, the age of the child, the duration of the CPB, the type of the TOF repair, and other comorbidities (4).

The majority of patients undergoing a complete surgical repair of TOF have a straightforward course, an uneventful recovery, and are discharged home shortly after the surgery (1). However, in some patients complications may occur, and it's usually in those operations that required resection of muscle bundles and/or right ventriculotomy that often reveals a poor RV diastolic compliance in the early postoperative period (1).

Early postoperative complications

The complications that may develop in the first 12-48h, especially in the neonatal and infant period, include low cardiac output syndrome (LCOS), arrhythmias (23), and pleural effusion (caused by high RV end diastolic pressure) (4).

The LCOS might be caused by (23):

- RV systolic and diastolic dysfunction, which was a consequence of RVH repair. It could also have been a consequence of right ventriculotomy
- Uncontrolled arrhythmias, which is described below
- Residual VSD resulting from either a patched VSD that's significantly leaking or an additional VSD that wasn't recognized prior to and during the surgery.
- Management – all patients are administered Milrinone for 24-72h to support RV.

Arrhythmias – most common arrhythmias affecting the hemodynamics postoperatively are (23):

- Junctional ectopic tachycardia (JET) is the most commonly observed arrhythmia after surgical repair of TOF
- Ectopic arterial tachycardia
- Re-entry supraventricular tachycardia (SVT)
- Right bundle branch block (RBBB)/Left bundle branch block (LBBB) (2)
- Complete AV block is a rare finding, but if present it's mostly transient, and may require temporarily pacing

Risk factors for tachyarrhythmias and sudden cardiac death include patients with old age at time of repair (greater than 3 years), male sex, transient complete heart block after 3rd day of operation, and QRS duration greater than 180ms (2).

Long-term complications

All children and adults that have gone through the surgical repair will be under lifelong follow-up annually with ECG and echocardiography check-ups. Holter monitoring and exercise stress tests are done intermittently and if substantial findings are found, prompt referral for electrophysiological testing is made (7).

The long-term complications seen with postoperative patients include RV volume overload from pulmonary valve regurgitation; RV aneurysm from an outflow patch or ventriculotomy procedure; biventricular dysfunction; and aortic root dilatation and insufficiency (1,2,4).

The three leading causes of mortality in patients with a corrected TOF are (2):

- Arrhythmias
- Heart failure
- Complications from reoperations

Thirty years after the surgical correction, the risk of SCD increases to 6 to 9%. Some of the factors associated with this risk are mentioned in the section above (2).

The commonest indication for reoperation is pulmonary regurgitation (insufficiency), and the criteria for pulmonary valve replacement are based on the severity measured by Cardiac MRI imaging, which has become the gold standard for measuring pulmonary regurgitation and pulmonary volumes (2,23).

Complications during pregnancy

Females who had a complete surgical repair of TOF, have the same outcomes in comparison with the general healthy obstetric population. Pregnancy complications are increased related to the level of the pulmonary hypertension and the severity of the pulmonary insufficiency with biventricular dysfunction. Women with moderate RV hypertension or those who have had a palliative shunt have an increased risk for stillbirth.

Children that are born to a mother with TOF, carry a higher risk of having a CHD in comparison to the general population. The risk is as high as 3-5%, compared to 0.8% of the general population (2). If the DiGeorge syndrome is present, the chance of transmitting the abnormal chromosome is 50%, with a risk of having an associated CHD (2).

Prognosis

The diagnosis and management of TOF is carried out by an interprofessional team that includes a pediatrician, pediatric cardiologist, pediatric cardiac surgeon, and radiologist. The long-term outcome of corrected TOF is good, but after two decades or so a significant number of corrected cases will require pulmonary valve replacement (2). The pulmonary valve replacement is needed due to incompetence of the pulmonary valve that can develop after one to two decades after the total

repair, which would lead to a progressive decrease in RV function with increased dilation. If not treated, it could result in arrhythmias and exercise intolerance. As we mentioned above, the pulmonary valve insufficiency will require a replacement with either a pulmonary valve homograft, conduit, or percutaneous pulmonary valve (4).

These patients still have an increased risk of sudden cardiac death, usually from arrhythmias, hence these patients may need implantable cardioverter defibrillator (ICD) insertion or cardiac catheter ablation (4).

In an uncorrected patient with TOF, the consequence of chronic hypoxia as well as the pathophysiological effect of RVOTO, significantly alters the patient's quality of life, growth, development (including the neurodevelopment), and the educational achievement. If uncorrected, the life expectancy is between the first and fourth decade of life, where death is caused by cardiac failure, arrhythmias, infections (especially respiratory), and thromboembolic disease (4). Approximately 50% of patients may not survive past the first 3 years of life (26), within the first year of life 25% of patients suffering from severe RVOTO die if left untreated, 40% die by the age of 3, 70% by the age of 10, and 95% by the age of 40 (2); compared to those patients that had a corrective surgery where over 90% of the patients reached 25 years of age (27).

After the total surgical correction of TOF, most children remain free of symptoms. It's essential to remember that the repair of TOF is not curative but palliative, and the structural disease continues to progress at a variable rate among the patients (2).

Acknowledgments

First and foremost, I would like to thank my mentor, izv. Prof. dr. sc. Daniel Dilber for the guidelines and support as well as for giving me the opportunity to write this thesis under his guidance. I would also like to thank prof. dr. sc. Marija Jelušić and izv. prof. dr. sc. Ruža Grizelj for being a part of the graduate committee and their time to evaluate this thesis.

Finally, I would like to express my very profound gratitude to my family and friends for providing me with support and continuous encouragement throughout the tough years of medical studies. This accomplishment wouldn't have been possible because, without them, none of this would have been possible.

Biography

I was born on August 7th 1992 in a small town known as Norrköping, Sweden. Two years earlier my parents came to Sweden from Syria, with a goal in their mind to give me and my siblings a better life and opportunities than what they had. I'm the oldest child out of four, and had to mature much faster than most of the kids in my age. Due to the fact that my parents didn't know the culture or the language, I had to help them with daily adult tasks, such as calling the bank, paying the bills, and so on. Because of that, I learned to take care of myself, I learned and understood what my parents did for me, to leave their lovely country to come to Sweden just to give me and my siblings the best of the best.

I went to a private primary school in Norrköping, called Vindruvan (2nd to 9th grade), and after that I went to a high school called Kunskapsgymnasiet, where I studied science and computer program. After I graduated high school, I enrolled into a Premed course in Stockholm for 3 months, and after that enrolled into medical school.

References

1. Sharkey AM, Sharma A. Tetralogy of Fallot: Anatomic variants and their impact on surgical management. Vol. 16, Seminars in Cardiothoracic and Vascular Anesthesia. 2012. p. 88–96.
2. Tetralogy of Fallot - StatPearls - NCBI Bookshelf [Internet]. [cited 2022 Feb 22]. Available from: <https://www.ncbi.nlm.nih.gov/books/NBK513288/>
3. Bailliard F, Anderson RH. Tetralogy of Fallot. Orphanet Journal of Rare Diseases. 2009;4(1).
4. Wilson R, Ross O, Griksaitis MJ. Tetralogy of Fallot. Vol. 19, BJA Education. Elsevier Ltd; 2019. p. 362–9.
5. Tetralogy of Fallot - NORD (National Organization for Rare Disorders) [Internet]. [cited 2022 Feb 17]. Available from: <https://rarediseases.org/rare-diseases/tetralogy-of-fallot/>
6. Tetralogy of Fallot (TOF) in Adults: Practice Essentials, Background, Anatomy [Internet]. [cited 2022 Feb 17]. Available from: <https://emedicine.medscape.com/article/2035949-overview>
7. Ra-id Abdulla. Heart Diseases in Children [Internet]. Abdulla R id, editor. Boston, MA: Springer US; 2011. Available from: <http://link.springer.com/10.1007/978-1-4419-7994-0>
8. Tetralogy of Fallot: MedlinePlus Medical Encyclopedia [Internet]. [cited 2022 Feb 20]. Available from: <https://medlineplus.gov/ency/article/001567.htm>
9. Kumar V, Abbas AK, Aster JC. Robbins Basic Pathology. Robbins Basic Pathology. 2013.
10. Karl TR, Stocker C. Tetralogy of fallot and its variants. Vol. 17, Pediatric Critical Care Medicine. Lippincott Williams and Wilkins; 2016. p. S330–6.
11. Department of Surgery - Tetralogy of Fallot [Internet]. [cited 2022 Feb 22]. Available from: <https://surgery.ucsf.edu/conditions--procedures/tetralogy-of-fallot.aspx>
12. Ricardo A. Munoz, Victor O. Morell, Eduardo M. da Cruz, Carol G. Vetterly, Jose Pedro da Silva. Critical Care of Children with Heart Disease [Internet]. Munoz RA, Morell VO, da Cruz EM, Vetterly CG, da Silva JP, editors. Vol. 2nd

- edition. Cham: Springer International Publishing; 2020. 191–197 p. Available from: <http://link.springer.com/10.1007/978-3-030-21870-6>
13. Park MK (Myung K, Salamat M. Park's pediatric cardiology for practitioners. Vol. 7th edition. 2021. 112–114 p.
 14. Which clinical history findings are characteristic of tetralogy of Fallot (TOF) in infants? [Internet]. [cited 2022 Apr 23]. Available from: <https://www.medscape.com/answers/2035949-167740/which-clinical-history-findings-are-characteristic-of-tetralogy-of-fallot-tof-in-infants>
 15. Perloff JK, Marelli AJ. Perloff's clinical recognition of congenital heart disease. Elsevier/Saunders; 2012. 559 p.
 16. Tetralogy of Fallot: webmed [Internet]. [cited 2022 Feb 22]. Available from: <https://www.webmd.com/heart-disease/tetralogy-fallot>
 17. Ralston Stuart H, Penman I. D, Strachan Mark WJ, Hobson Richard P. Davidson's principles and practice of medicine. 23rd edition. 2018. 536–538 p.
 18. Hypertrophic Osteoarthropathy: Practice Essentials, Background, Pathophysiology [Internet]. [cited 2022 Apr 24]. Available from: <https://emedicine.medscape.com/article/333735-overview>
 19. Congenital Heart Defects - Facts about Tetralogy of Fallot | CDC [Internet]. [cited 2022 Apr 24]. Available from: <https://www.cdc.gov/ncbddd/heartdefects/tetralogyoffallot.html>
 20. Tongsong T, Sittiwangkul R, Chanprapaph P, Sirichotiyakul S. Prenatal sonographic diagnosis of tetralogy of fallot. Journal of Clinical Ultrasound. 2005;33(8):431–427.
 21. Tetralogy of Fallot | Radiology Reference Article | Radiopaedia.org [Internet]. [cited 2022 Feb 23]. Available from: <https://radiopaedia.org/articles/tetralogy-of-fallot?lang=us>
 22. Understanding the echocardiogram - Cardiology Explained - NCBI Bookshelf [Internet]. [cited 2022 Apr 29]. Available from: <https://www.ncbi.nlm.nih.gov/books/NBK2215/>
 23. Munoz RA, Morell VO, da Cruz EM, Vetterly CG, Pedro Da Silva J. Basic Medical and Surgical Concepts Second Edition Critical Care of Children with Heart Disease.
 24. Marc dante KJ, Kliegman RM. Nelson essentials of pediatrics. 2019.

25. Biglino G, Giardini A, Hsia TY, Figliola R, Taylor AM, Schievano S, et al. Modeling single ventricle physiology: Review of engineering tools to study first stage palliation of hypoplastic left heart syndrome. Vol. 1, *Frontiers in Pediatrics*. Frontiers Media S.A.; 2013.
26. Bertranou EG, Blackstone EH, Hazelrig JB, Turner ME, Kirklin JW, Birmingham A. PEDIATRIC CARDIOLOGY Life Expectancy Without Surgery in Tetralogy of Fallot.
27. Park CS, Lee JR, Lim HG, Kim WH, Kim YJ. The long-term result of total repair for tetralogy of Fallot. *European Journal of Cardio-thoracic Surgery*. 2010 Sep;38(3):311–7.

Figures:

Figure 1: Contributed by Wikimedia Commons, LadyofHats (Public Domain)

Figure 2: Copyright © 2019 British Journal of Anaesthesia. Published by Elsevier Ltd.

Figure 3: Case courtesy of Dr. Vincent Tatco, Radiopaedia.org, rID: 43059

Figure 4: Copyright © 2013 Biglino, Giardini, Hsia, Figliola, Taylor, Schievano and MOCHA Collaborative Group.