

Transcatheter aortic valve therapy

Negovetić, Paola

Master's thesis / Diplomski rad

2021

Degree Grantor / Ustanova koja je dodijelila akademski / stručni stupanj: **University of Zagreb, School of Medicine / Sveučilište u Zagrebu, Medicinski fakultet**

Permanent link / Trajna poveznica: <https://um.nsk.hr/um:nbn:hr:105:417136>

Rights / Prava: [In copyright](#) / [Zaštićeno autorskim pravom.](#)

Download date / Datum preuzimanja: **2024-05-10**



Repository / Repozitorij:

[Dr Med - University of Zagreb School of Medicine Digital Repository](#)



**UNIVERSITY OF ZAGREB
SCHOOL OF MEDICINE**

Paola Negovetić

Transcatheter aortic valve therapy

GRADUATE THESIS



Zagreb, 2022.

This graduate thesis was made at the Department of Cardiac and Transplant surgery, University hospital Dubrava in Zagreb under the supervision of Professor Igor Rudež, MD, PhD and was submitted for evaluation in the academic year 2021/2022.

ABBREVIATIONS

| | |
|------------|--|
| AS | aortic stenosis |
| AV | aortic valve |
| ECG | electrocardiogram |
| ECHO | echocardiogram |
| LV | left ventricle |
| TAVI | transcatheter aortic valve implantation |
| ViViV-TAVI | valve-in-valve-in-valve TAVI |

Table of Contents

| | |
|--|-----------|
| 1. INTRODUCTION..... | 1 |
| 1.1. AORTIC VALVE..... | 1 |
| 1.2. AORTIC STENOSIS | 4 |
| 1.2.1. DIAGNOSIS OF AORTIC STENOSIS | 6 |
| 1.2.2. TREATMENT OF AORTIC STENOSIS | 8 |
| 2. TRANSCATHETER AORTIC VALVE IMPLANTATION THERAPY..... | 11 |
| 2.1. HISTORY | 11 |
| 2.2. PROCEDURE | 13 |
| 2.2.1. TRANSFEMORAL VASCULAR ACCESS | 16 |
| 2.2.2. SUBCLAVIAN VASCULAR ACCESS | 17 |
| 2.2.3. TRANSAPICAL VASCULAR ACCESS..... | 19 |
| 2.3. INDICATIONS | 21 |
| 2.4. CONTRAINDICATIONS..... | 23 |
| 2.5. BENEFITS..... | 25 |
| 2.6. COMPLICATIONS | 26 |
| 2.7. FUTURE RESEARCH..... | 31 |
| 3. CONCLUSION..... | 34 |
| 4. ACKNOWLEDGEMENTS..... | 35 |
| 5. REFERENCES..... | 36 |
| 6. BIOGRAPHY | 40 |

SUMMARY

Transcatheter aortic valve therapy

Paola Negovetić

The aortic valve is a component of the heart's outflow tract that is responsible for transporting the newly oxygenated blood from the left ventricle to the aorta and from there to the rest of the body. Aortic stenosis is a pathological condition in which narrowing of the aortic valve opening occurs. The clinical symptoms are not noticeable from the beginning but develop later on once the amount of blood being pumped out of the aorta is significantly decreased. Diagnosis of aortic stenosis is confirmed by an echocardiogram. The treatment of choice for aortic stenosis is determined by the severity of the clinical symptoms and the individual characteristics of the patient. For the patients with a severe clinical picture of aortic stenosis, there is an indication for the surgical aortic valve replacement. In the surgical aortic valve replacement, the stenotic valve is removed and replaced with a new valve. However, some patients presenting with a severe aortic stenosis are deemed inoperable or a high risk for surgery. Transcatheter aortic valve implementation is a less invasive choice of therapy for those patients with severe aortic stenosis who were not approved for the surgical aortic valve replacement. In transcatheter aortic valve replacement, a novel valve is implanted within the native pathological valve. By this valve-in-valve implementation, the stenotic valve is being strengthened and made capable of effectively functioning once more.

Keywords: aortic stenosis, transcatheter aortic valve therapy, valve-in-valve

SAŽETAK

Transkatetersko liječenje aortalnog zaliska

Paola Negovetić

Aortni zalistak je sastavni dio izljevnog trakta srca koji je odgovoran za transport krvi svježe obogaćene kisikom iz lijeve klijetke u aortu, te kasnije u ostatak tijela. Stenoza aorte je patološko stanje u kojem dolazi do progresivnog suženja otvora aornog zaliska. Klinički simptomi često nisu uočljivi od samog početka bolesti, nego se razvijaju tek kasnije kada se količina krvi koja napušta aortu značajno smanji. Dijagnoza aortne stenoze potvrđuje se ultrazvukom srca koji pokazuje patologiju aornog zaliska te protok krvi iz lijeve klijetke u aortu. Izbor liječenja aortne stenoze određuje se putem procjene ozbiljnosti kliničkih simptoma pacijenta te njihovih individualnim karakteristikama. Za bolesnike koji imaju tešku kliničku sliku aortne stenoze postoji indikacija za kiruršku zamjenu patološkog aornog zaliska. Operativna zamjena aornog zaliska provodi se tako da se odstrani bolesni zalistak te se ugradi novi. Međutim, neki pacijenti koji imaju dijagnozu teške aortne stenoze smatraju se visokim rizikom za operaciju ili čak neprikladnim za operaciju. Transkateterska implementacija aornog zaliska manje je invazivan izbor terapije za one pacijente s dijagnozom teške stenoze aorte kojima nije odobrena kirurška zamjena aornog zaliska. Kod transkateterske zamjene aornog zaliska, novi zalistak se implantira unutar originalnog patološkog zaliska. Ovom vrstom implementacije, stenotični zalistak je ojačan i ponovno osposobljen za učinkovito funkcioniranje.

Ključne riječi: aortna stenoza, transkatetersko liječenje aortalnog zaliska, zalistak-u-zalisku

1. INTRODUCTION

1.1. AORTIC VALVE

The aortic valve (AV) is a part of the outflow tract of the heart which transports the oxygenated blood from the left ventricle (LV) to the aorta which then transports it to different tissues in the body. It is positioned between the aorta and its vestibule.

The AV is one of the two semilunar valves of the heart. It is made from three semilunar cusps that are comprised by endocardial folds: the right semilunar cusp, the left semilunar cusp and the posterior cusp. The semilunar cusps have a concave shape when observed from above and they are generally of a smaller size and diameter when compared to the mitral and tricuspid valves, furthermore the force exerted on the semilunar valves is correspondingly half of what is applied on the cusps of the atrioventricular valves. At the site of the attachment of the semilunar cusps is a curved place and the arterial walls are protruded and thin.

Positioned centrally in the thickened margin of the aortic valve is the semilunar cusp nodule, and the rim of all of three cusps is solidified in the location where they come into contact forming the lunule of the semilunar cusp. The aortic sinus is the origin site of the ascending aorta and it is formed by the outward protruding of the aortic wall immediately above the cusps (1). The right and left coronary arteries emerge from the aortic sinuses of the right and the left semilunar cusps, respectively, while no artery emerges from the posterior aortic sinus consequently making it a non-coronary sinus.

When the muscles of the ventricle contract during ventricular systole, the increasing pressure in the upper part of the left ventricle causes the cusps of the aortal valve to project forward into the aorta while the turbulent blood flow stops the semilunar cusps of the valve to adhere completely to the vessel wall which could possibly prevent the

closure of the cusps later on. On the other hand, during the phase of ventricular muscle relaxation, ventricular diastole, the pressure difference causes the elastic recoil of the LV wall which in turn guides the blood flow back into the ventricle. The reversed flow of blood causes the semilunar cusps to instantly close the orifice and prevent further flow of blood from the ventricle into the aorta until another systolic contraction occurs (2).

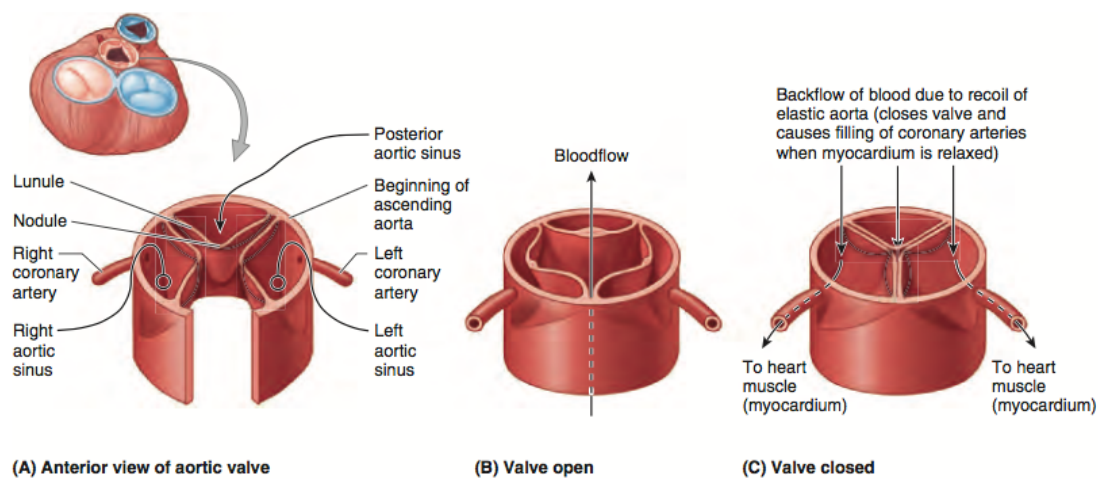


Figure 1. Aortic valve, aortic sinuses, and coronary arteries. A. In the anterior view of the aortic valve, the anatomy is clearly represented with the three semilunar cusps (right, left, posterior). B. Blood ejected from the LV during systole pushes the semilunar cusps apart. C. AV closes during diastole and the nodules and lunules join in the center (2).

If inflammation of the heart valves occurs, it can lead to damaging of the margins of the valves. There are two main outcomes in this scenario: stenosis and insufficiency. Valvular stenosis occurs when the marginal scarring results in narrowing or reducing

the opening of the valve which necessitates that the heart pumps stronger which could lead to extra straining of the heart.

On the other hand, valvular insufficiency occurs when the valve does not close completely resulting in the passive backflow of blood to the LV. The best diagnostic tool for valvular defects is echocardiogram (ECHO), it assesses the gravity of the valvular pathology and aids in choosing the appropriate medical treatment.

1.2. AORTIC STENOSIS

Aortic stenosis (AS), or aortic valve stenosis, is a condition in which the opening of the aortic valve narrows, primarily attributable to the joint effect of gradual fibrosis and matrix calcification. The outcome of this combination is the valvular stiffness that keeps intensifying with subsequent ongoing limitations of the valvular opening which leads to the rise in the work and afterload of the left ventricle. A stenotic aortic valve is depicted in Figure 2. below.

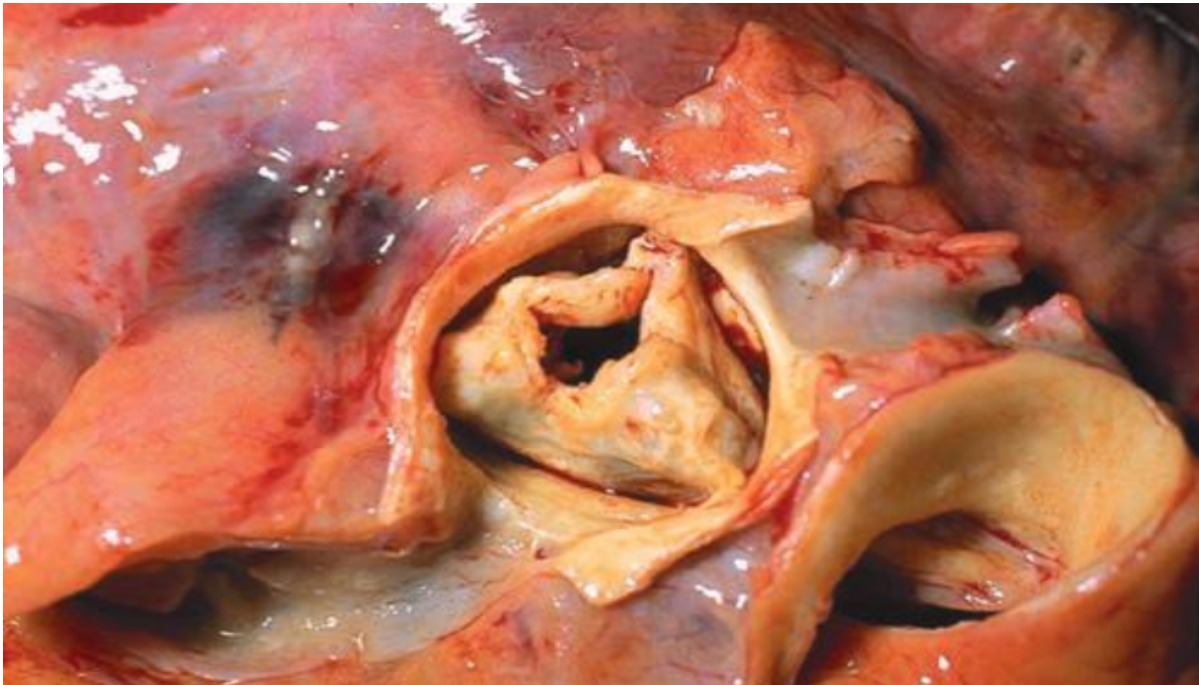


Figure 2. Aortic Stenosis. The aorta was excised to reveal the fused valve leaflets of the aorta that have increased in thickness (3).

This narrowing restricts the outflow of oxygenated blood from the left ventricle to the aorta. Stenosis in most cases occurs during aging because of calcium deposits or damages that resulted in scarring of the aortic valve but it can also occur due to a congenital heart defect termed the bicuspid aortic valve in which the aorta does not

have its usual three semilunar cusps working in harmony but only two cusps which leads to pathological functioning and increased risk for later development of stenosis (3).

In some cases, AS arises as a complication from receiving radiation therapy which can produce inflammation and result in the formation of scar tissue, there is also a possibility of acquiring AS after infection with group A Streptococcus that can lead to development of rheumatic fever that will cause scar formation within the heart. It is one of the most frequent and serious valvular pathologies that affects the patients.

The clinical picture is not apparent right away as many patients do not experience clear symptoms until the amount of the blood flowing out of the aorta to supply the rest of the body is greatly decreased. The extended subclinical interval mentioned above is called aortic sclerosis which is defined as the presence of calcifying changes on the AV but without a transvalvular gradient. When there is an ongoing narrowing of the AV with associated LV hypertrophy it will result in the typical triad of symptoms: angina, syncope in exertion and dyspnea (4).

1.2.1.DIAGNOSIS OF AORTIC STENOSIS

The diagnosis of aortic stenosis begins by taking a comprehensive medical history of the patient followed by a physical examination and the working diagnosis made by the physician is either confirmed or rejected by echocardiogram.

Aortic stenosis is suspected based on the clinical manifestations and the physical examination performed by the physician. As we mentioned above, when the amount of blood flowing from the LV through the aorta is decreased enough it then elicits the classical triad of symptoms (dyspnea, syncope and angina). This manifestation of the disease will lead the patient toward noticing the decline of their health and seeking out medical help. The doctor must perform a thorough medical history which is vital in determining the pathology responsible for deterioration of the health. The physical examination guides us to the underlining pathology.

Besides the clinical symptoms already mentioned, an important finding for AS is the crescendo decrescendo ejection murmur which can be heard on heart auscultation, the sound is most noticeable when placing the stethoscope on the upper left sternal border while the patient is sitting down, and their thorax is slightly bend anteriorly. The murmur in general spreads to the right clavicle and both carotid arteries and it has the characteristics of intensifying with progression of the stenosis level, it can also be intensified on examination by maneuvers that increase the LV volume such as lifting the lower extremities and after the ventricular extrasystole (5).

The electrocardiogram (ECG) characteristically shows hypertrophy of the LV which can be present beside or lacking an ischemic pattern in the ST-wave and the T-wave. In the case of severe AS but without any symptoms, the recommended diagnosis is by performing exercise ECG testing under close supervision in an effort to provoke

symptoms of hypotension, angina or dyspnea. Exercise ECG testing is contraindicated in patients with clinical symptoms. During X-ray of the chest in patients with AS, the findings might contain calcification of the aortic semilunar cusps, the size of the heart can be of a normal physiologic size or slightly enlarged (6).

The gold standard for diagnosing AS is the echocardiogram (ECHO). ECHO is performed to confirm the diagnosis of aortic stenosis after it has been suspected by the clinical picture and the outcome of the physical examination.

The two-dimensional transthoracic ECHO is utilized to recognize an aortic valve that is stenotic and to determine the possible grounds for the valvular pathology, to compute the hypertrophy of the LV and the grade of systolic dysfunction, and to discover any co-occurring valve disorders of the heart such as mitral valve prolapse and or aortic regurgitation and their possible complications such as endocarditis.

On the other hand, Doppler ECHO is employed to measure the degree of the stenosis, which is done by quantifying the jet velocity, the aortic valve area and the transvalvular systolic pressure gradient. By this we can conclude that the severity of the AS is determined by ECHO and is categorized corresponding to the Figure 3. below into Normal, Mild, Moderate, and Severe.

Classification of Aortic Stenosis Severity

| CLASSIFICATION | TRANSAORTIC VELOCITY (M PER SECOND) | MEAN PRESSURE GRADIENT (MM HG) | AORTIC VALVE AREA (CM ²) |
|----------------|-------------------------------------|--------------------------------|--------------------------------------|
| Normal | < 2.0 | < 10 | 3.0 to 4.0 |
| Mild | 2.0 to 2.9 | 10 to 19 | 1.5 to 2.9 |
| Moderate | 3.0 to 3.9 | 20 to 39 | 1.0 to 1.4 |
| Severe | ≥ 4.0 | ≥ 40 | < 1.0 |

Figure 3. Classification of Aortic Stenosis Severity (7).

1.2.2.TREATMENT OF AORTIC STENOSIS

The choice of treatment for AS depends on the clinical picture and the gravity of the disease. In the case of no symptoms or mild ones, the doctor can decide that the best approach is to monitor the condition with regular checkups and propose some lifestyle changes in the form of physical exercise and a balanced diet. This approach is known as watchful waiting.

If the disease has progressed so far as to cause clinical symptoms, then there is an indication that a replacement of the valve is needed. Aortic valve replacement, either with surgical or percutaneous approach, is the only absolute treatment for AS. In the procedure, the damaged valve is removed and replaced with a substitute valve which could be mechanical or biological if it comes from pigs, cows or people. Both mechanical and biological valve substitutes have their benefits and their weaknesses. Mechanical valves in general have a longer usage period and do not need to be replaced as often, but the downside is that the patient must be on blood-thinning treatment for the remainder of their lives in order to prevent blood clots. On the other hand, biological valves do not require the addition of blood-thinning medication, but they do not last as long and need to be exchanged after ten to fifteen years (8). Management of the patient with severe AS can be seen on Figure 4. presented on the next page.

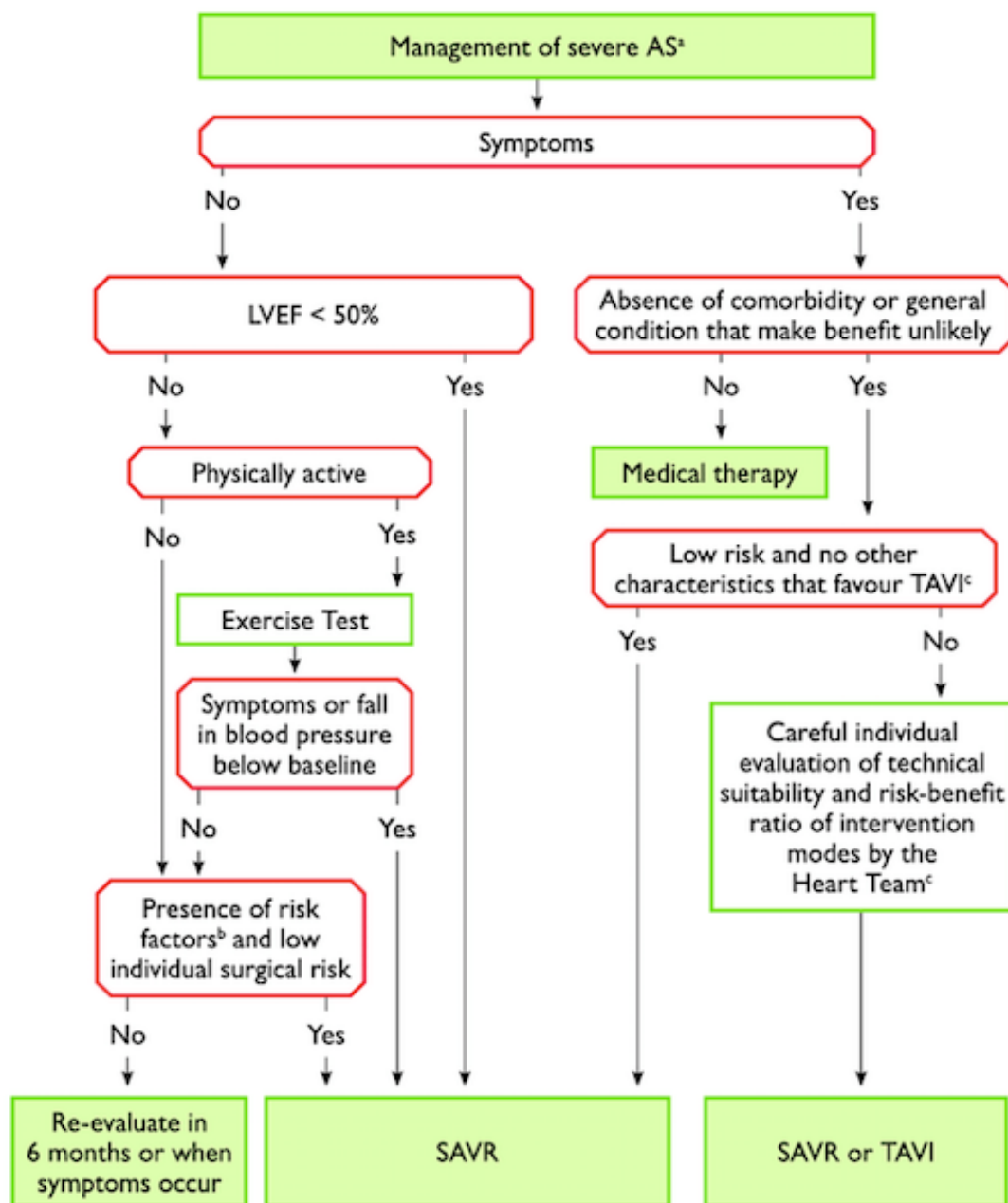


Figure 4. Management guidelines for severe AS (9).

Balloon aortic valvuloplasty is the treatment of choice in the case of congenital aortic stenosis where calcification of the valve has not yet occurred. In contrast, every other type of AS goes together with major calcification and this treatment option is not curative. This procedure is also used for patients who are contraindicated for

undergoing aortic valve replacement due to their comorbid conditions and the valvuloplasty serves as a palliative treatment but not as a cure for their condition.

Besides being used as a palliative treatment, it can also serve as a link to surgical replacement of the aortic valve or the transcatheter aortic valve implantation therapy in patients who are unstable and have a great surgical risk. The procedure increases the survival of the patient but the effect is temporary, the hemodynamic benefit lasts for approximately six months (10). The transient effect is caused by the failure to alter the pathology of the leaflet fundamentally, early recoil and the restenosis of the valve. Within the last twenty years, a less invasive treatment option has emerged that is a preferred choice for patients with great risk from complications during the surgical replacement of the aortic valve (11). The procedure is transcatheter aortic valve implantation therapy (TAVI) and will be discussed in detail on the following pages.

2. TRANSCATHETER AORTIC VALVE IMPLANTATION THERAPY

2.1. HISTORY

The idea for TAVI began in the early 1990s, it originated from doctors who saw room for improvement in the long-term unsatisfying clinical outcomes of the aortic balloon valvuloplasty for the treatment of aortic stenosis. Hence, Cribier and Anderson created the balloon-expandable and self-expandable systems used in TAVI procedures (12). The progress of the innovation was slowed down and ultimately delayed due to the skeptical outlooks of their colleagues and the medical industry until 2002, when Alain Cribier carried out the first TAVI and provided confirmation of the success of their model (13).

Following the first stage of compassionate implantation, big, randomized trials permitted TAVI to insert itself in the American and European recommendations for patients who are inoperable or have a high surgical risk (14). As of 2005, the management of patients who were not at the highest risk with the use of less bulky devices in the clinical trials might validate that the treatment choice of TAVI was comparable to the classical replacement of aortic valve in a surgical setting (15).

On Figure 5. is the depiction of Cribier's concept and the cadaver experiment.

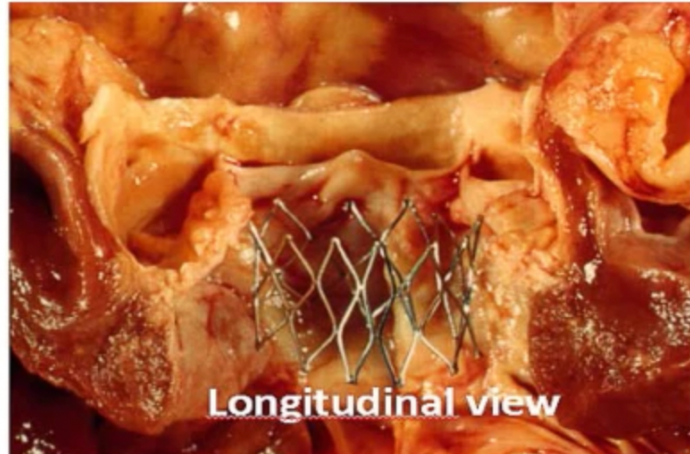
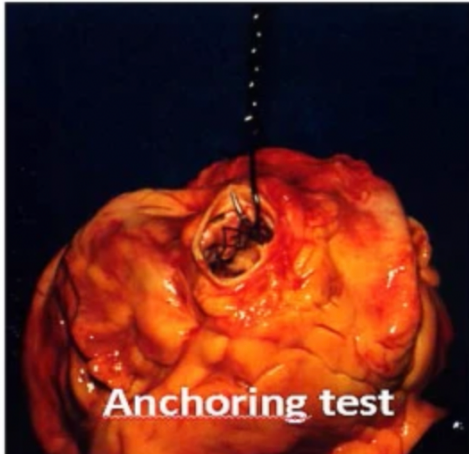
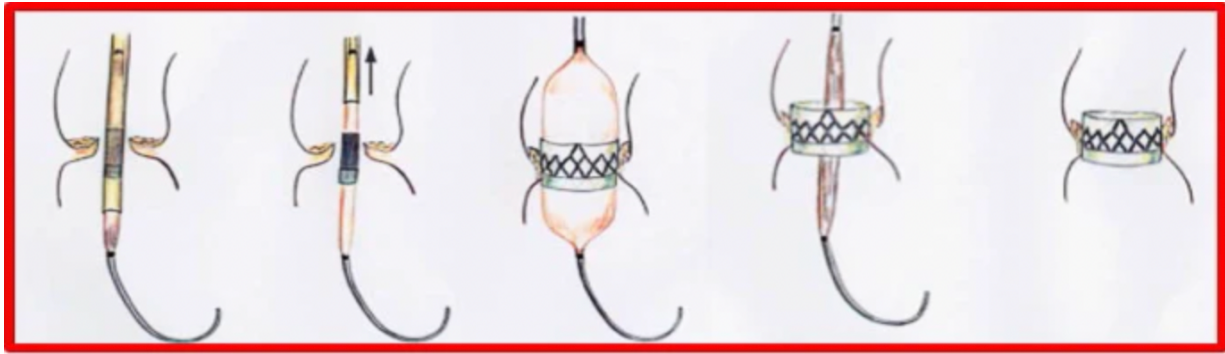


Figure 5. Cribier's TAVI concept and the experiment on the cadaver. The Anchoring test was performed to evaluate the valve stability which was positioned by balloon enlargement within the annulus of the aorta (15).

2.2. PROCEDURE

In Transcatheter Aortic Valve Implantation (TAVI), a new valve is implanted without removal of the original injured aortic valve. Instead of removal, during the procedure, the new valve is positioned within the pathological valve to make it stronger and capable of satisfactory functioning once again.

The valves used in TAVI are not the same as the ones conventionally used in AV replacement surgery. The design of the currently available TAVI valves usually comprises of a bioprosthetic tissue valve which is commonly made from the bovine pericardium and is set on a compressible stent composed of metal. The bioprosthetic valves are susceptible to degeneration and calcification that can possibly restrict their long-term permanency. Most frequently used valves in the procedure are the Edwards SAPIEN device and the CoreValve system.

The Edwards SAPIEN device is made from a bovine pericardial valve housed in a balloon inflatable stent made from a stainless-steel frame with a fabric sealed cuff. It is a trileaflet transcatheter valve made from the bovine pericardium and sewn to the frame of the stent which is 14 millimeters tall. The stent is fashioned to be positioned in a sub coronary location. In order to limit paravalvular leaks there is a polymer skirt peripherally fixed to the stainless-steel stent.

On the other hand, the CoreValve device is the third generation of a porcine pericardial valve with three leaflets housed by a self-expandable Nitinol stent, which depending on the size of the native valve, is 53- or 55- millimeters long (16). The frame of the valve is separated into three different regions of hoop strength or radial force, the lower positioned zone contains a great radial fore in order to expand and rule out the leaflets that are calcified and also to reduce the recoil. The middle zone has a great hoop

strength and conveys the valve. The highest zone has a small radial force and is broadening away from the frame in order to achieve contact with the ascending aorta. The stent of this valve is longer and is designed to be situated in the LV outflow tract that extends to the aortic root (17). Thus, we can deduce that although the CoreValve device implants intra-annularly, its function is superior to the annulus of the aorta.

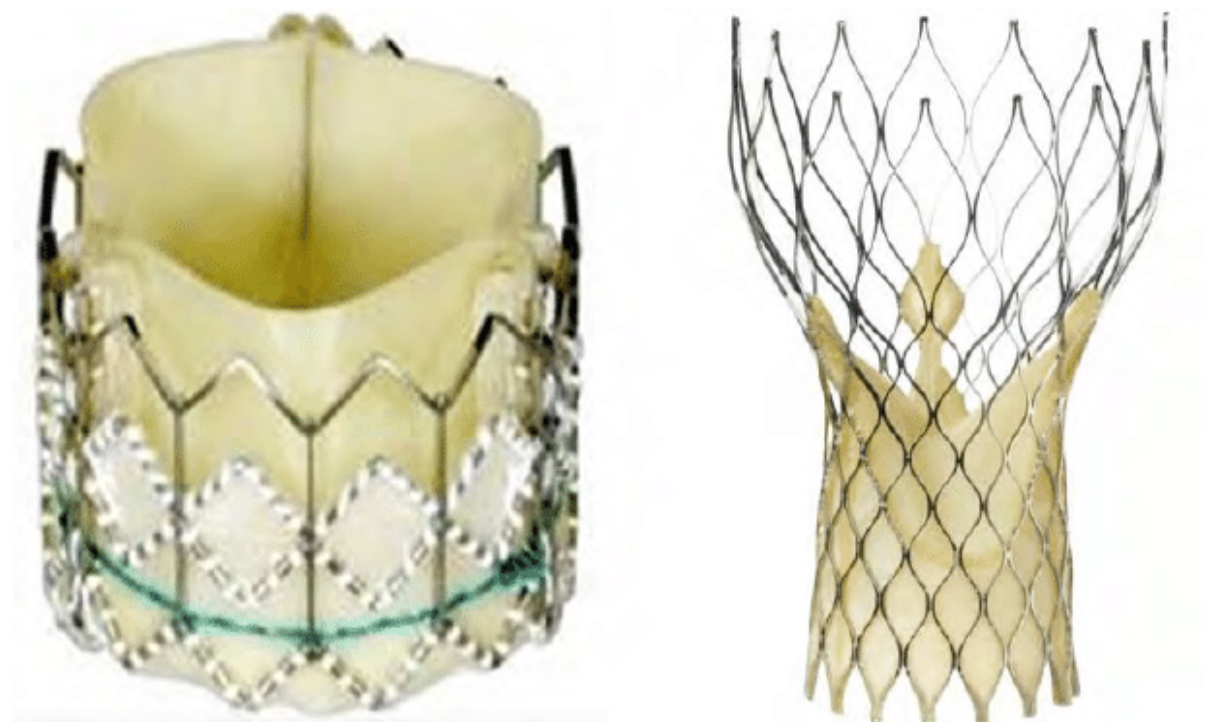


Figure 6. Transcatheter aortic valves. On the left is the SAPIEN device and on the right is the CoreValve system (18).

As we mentioned above, in TAVI the new valve is implanted inside the damaged native AV which is a big difference to the AV replacement surgery wherein the diseased valve is completely removed. Another difference is that TAVI is performed without the cardiopulmonary bypass. For the optimal performance, fluoroscopy and ECHO are used throughout the procedure. There are different approaches for gaining vascular

access for the implantation of the transcatheter bioprosthetic valve: the transfemoral, the subclavian and the transapical (19).

2.2.1. TRANSFEMORAL VASCULAR ACCESS

The predominant access route used for the implantation of the transcatheter valves, for both the Edwards SAPIEN and the CoreValve device, is the femoral artery route. Percutaneous transfemoral route of access is recognized as a less invasive approach when compared to alternative options but problems can occur in patients suffering from peripheral vascular diseases. The inclination towards this option arises from the rapidity of the procedure, the experience of the surgeons, and the success of the closure apparatus. For each diameter value of the femoral artery, there is an approved size of the delivery system. Meaning, that with an increase in the calcification or the level of vessel tortuosity, there will be a need for a larger vessel to be used in the procedure.

During the transfemoral access TAVI, the device travels from the femoral artery retrograde upwards the aorta to reach the AV and is there positioned between the semilunar cusps of the damaged AV, pushing them apart. In the case of pathology within the femoral artery and/or the aorta, then the device is alternatively used in an antegrade approach by means of a minimally invasive surgical procedure known as the transapical implantation. When the device is positioned at the AV it calls for self-expansion or balloon dilatation, this action shifts the native AV to the side where it is aligned with the aortic root (20). In the case of an iliofemoral vascular disease that does not allow the transfemoral access, which occurs in 10-15% of the patients undergoing TAVI, then there is an array of other options for the access route to choose from.

2.2.2.SUBCLAVIAN VASCULAR ACCESS

In the patients who are not approved for the transfemoral vascular access for TAVI procedure, the subclavian artery is viewed as a sustainable substitution. Additionally, as there is less of a distance between the aortic valve and the access site, the short distance from the annulus and the delivery catheter could be seen as a technical advantage (21). The procedure is done by a retrograde TAVI approach with direct transport by the subclavian artery in the selected patients. The access to the subclavian artery can be gained percutaneously or by an anterior subclavicular incision. The choice of the approach can be assisted with the use of a preoperative computed tomography which will detect the depth of the subclavian artery. In the case of a deeper subclavian artery, the angle for the device delivery will be more acute. It is also necessary to examine the angle of origin of the artery (22).

For the ideal subclavian access, the angle of origin is inclined in the direction of the thoracic outlet. If the angle is steeper than 90 degrees from the aortic arch, it might be problematic to navigate. In general, the left subclavian artery exhibits a preferable angulation for access to the aortic valve and the deployment of the device, it is therefore typically favored to the right subclavian artery (23). The right subclavian artery can be favored in the situation where there is a reliance of the myocardial perfusion on a bypass graft of the left internal mammary artery.

During rapid ventricular pacing, the native valve is dilated with the use of a balloon valvuloplasty. The bioprosthetic valve is consequently introduced, with the guidance of echocardiographic and angiographic imaging to achieve the correct positioning. After the new valve is installed, the results are again verified with the imaging techniques. Subsequent to a successful implantation, the apparatus is taken out and

the subclavian artery is reconstructed according to its original anatomy. The incision in the subclavian access is well accepted as it grants the patients to be mobile soon after the procedure. Healing of this area of access is linked to pleasing esthetic results (24).

2.2.3. TRANSAPICAL VASCULAR ACCESS

Another access option for the patients who are not approved for the transfemoral access is the transapical access. Patients suffering from systemically obstructing atherosclerosis are eligible for this vascular access when undergoing TAVI. Most of the patients are able to undergo a minor anterior thoracotomy. The contraindications for this access route are frailty and having a very reduced pulmonary function (25). This option is the only one with the antegrade approach thus providing great controllability and makes it easier for the operator to manipulate the apparatus. On the other hand, when compared to the other alternatives it comes with a considerably worse post-procedure outcome. Due to this, the frequency of using this access is on the decline (26).

The patient is in a supine position. Prior to the incision, the apex of the heart needs to be located with the use of computed tomography or echocardiography to determine the exact position of the access point and to assure that the septum runs parallel to the axis for the valve delivery. Confirmation of the apex position is obtained with the use of fluoroscopy before the incision. An anterolateral thoracotomy is done with a diameter of 4 to 6 cm. After the pericardium is open, stay sutures are used to aid in exposing the cardiac apex. By palpating, on the true apex there can be a dimple, or an indentation felt. The optimal apex site is marked with a sterile pen, while staying away from the coronary vessels. The left ventricle is accessed with a guard wire and a needle with the help of a transesophageal echocardiogram, passing the wire along the path of the septum all the way to the aortic valve. By this manner, the accurate route for the apparatus is verified whilst preventing injury to the ventricle or the surrounding tissue. Once proper preparations have been made, the transcatheter

valve is introduced into the predetermined position. After successful implantation, the apparatus is removed from the patient and the thoracotomy is closed.

2.3. INDICATIONS

TAVI or transcatheter aortic valve replacement (TAVR) therapy is a less invasive procedure option for severe symptomatic AS when compared to conventional aortic valve replacement surgery. Comparisons between TAVI and the classical AV replacement have been made in several clinical trials which have reached a consensus that TAVI is not an inferior procedure when compared to AV replacement when talking about the short-term morbidity and mortality and overall “success” of the technique.

TAVI is indicated in patients diagnosed with a symptomatic severe aortic valve stenosis who are inoperable or have a high risk regarding surgical treatment. With advancing imaging, newer transcatheter valves, streamlining the procedure and the increasing experience and hence skill of the surgeons, there have been improvements in the safety of the procedure and in the performance of the transcatheter valves. Due to this upgrade, TAVI is being investigated for other indications. TAVI has in recent years gained the approval from the Food and Drug Administration for intermediate risk patients. In 2019, there were a couple of randomized trials that assessed the use of TAVI in patients diagnosed with severe symptomatic AS with low operative risk. The findings of the studies revealed that in younger, and low-risk patients, there was an early advantage in using TAVI instead of the surgical replacement of the aortic valve and was linked to a lower duration of the hospital stay, faster recovery and even reduced rates of repeated hospitalizations (27).

Factors that favor the selection of TAVI over the surgical replacement of the aortic valve are age above 75 years, a presence of a severe comorbidity, frailty, previous cardiac surgery, decreased mobility and conditions that could influence the course of

rehabilitation after the procedure, porcelain aorta, a favorable access for transfemoral TAVI, sequelae seen on chest radiation, severe scoliosis or chest deformation, expected mismatch between the patient and the prosthesis, a presence of an intact coronary bypass graft at risk when sternotomy is performed (28).

2.4. CONTRAINDICATIONS

The contraindications for the use of TAVI are classified into absolute and relative contraindications. The group of absolute contraindications is further divided into anatomical causes responsible for not being eligible for the procedure and clinical causes. Absolute contraindication for TAVI is absence of a heart team and absence of a cardiac surgery department on the location, another would be that the suitability of TAVI was not verified by a cardiac team. Clinical absolute contraindications include life expectancy that is evaluated at less than twelve months, if the enhancement of life quality is not likely due to the comorbidities, serious primary disease associated with diseases of other valves that provide a major contribution to the clinical symptoms of the patient and can be managed only by means of surgery. Anatomical absolute contraindications consist of active endocarditis, a thrombus in the left ventricle of the heart, a plaque containing mobile thrombi in the ascending aorta or the aortic arch, an inadequate size of the annulus which comprises less than 18 millimeters or greater than 29 millimeters, an elevated risk of obstruction of the coronary ostium due to a small aortic sinus or asymmetric calcification of the valve or a short distance between the coronary ostium and the annulus. Additionally, for transfemoral or subclavian approach, the inadequate vascular access due to the size of the vessel or the calcification or its tortuosity fall under the category of anatomical absolute contraindications (29).

The relative contraindications for TAVI include a hemodynamic instability, a left ventricular ejection fraction less than 20%, an untreated coronary artery disease that requires revascularization, bicuspid or non-calcified valves. A relative contraindication

regarding the transapical approach encompasses a severe pulmonary disease and unapproachable apex of the left ventricle (30).

2.5. BENEFITS

This less invasive method is beneficial as it broadens the prospect for effective mechanical treatment to a large range of patients who would be otherwise untreatable due to their contraindications or high risk for replacement surgery (31). By estimation, there is approximately 30% of cases with severe aortic stenosis that are not eligible for surgery (11).

A big, multicenter clinical trial was conducted with patients who were seen as inoperable or a very high surgical risk. In those patients who were formerly considered to be inoperable, TAVI noticeably reduced the symptoms of the patients, decreased the death rate altogether from any cause, reduced the frequency of recurrent hospitalization at year one after the treatment when compared to the surgical valve replacement and correspondingly reduced the length of the hospitalization altogether. There were findings of a substantially reduced symptoms and increased functional ability when compared to the patients who are exclusively on pharmaceutical therapy (3).

With the evolution of TAVI from its experimental stages to a widely used procedure it has made a number of upgrades such as improved technology that ensure an easier implantation, more accurate imaging with the use of a multi-detector computed tomography leading to decreasing rates of major complications following the procedure. These upgrades have given rise to a more accessible transfemoral route for implantation, a decreased need for pacemakers, decreased rates of stroke, decreased vascular events and decreased rates of paravalvular leaks (32). The hemodynamic functioning has shown constant superiority in TAVI compared to the surgical management of AS (33).

2.6. COMPLICATIONS

In the multicenter clinical studies mentioned above, the findings revealed that the rates of neurological events, specifically stroke, and major vascular events were higher in the TAVI group when compared to the patients receiving the surgical aortic valve replacement. One of the highly destructive and severe side effects of the procedure is development of a stroke that leads to both increased mortality and to a greatly decreased life quality and increase in disability of the patient. Cerebral protection devices, used to capture debris, are being utilized to decrease the frequency of stroke development (34).

A frequent complication after TAVI, with the use of first generation transcatheter valves, compared to the surgical aortic valve replacement were paravalvular leaks that occur as the transcatheter prostheses are not sutured properly on the native valve and crush it with the radial force of the stent. The incidence of paravalvular leaks has been significantly reduced with the continuously improving technology. The predictors of significant paravalvular leaks demonstrated on a multi-imaging analysis were under sizing of the valve, incomplete valve contact with the native annulus of the aorta, often occurring due to an extensive calcification, and the malposition of the device itself (35). Complications arising from the transfemoral access are vascular complications and they occur in 6% of the patients with the devices of the present generation of devices (36). This includes femoral or iliac artery dissection or rupture, peripheral embolization of atherosclerotic fragments, or life-threatening stenosis of the femoral artery generated by the arteriotomy closure.

A rare complication of the procedure, seen in 0.2% of the cases, is the injury of the aortic wall. This injury can present in different manifestations such as type A or B aortic

dissection or development of an aortic hematoma. Aortic hematoma, characterized by leakage of blood between the layers of the aortic wall, is a menacing complication of the procedure when it first appears but then again it is usually able to be managed safely with the use of a percutaneous technique. Conversely, type A aortic dissection, characterized by a tear in the innermost layer of the ascending part of the aorta, is the manifestation that typically endangers the survival rate of the patients. Since it is one of the most alarming complications, the selection of the patients for TAVI needs to take this complication into account especially when considering elderly patients with a medical history of grave comorbid conditions. The main mechanism for the type A aortic dissection is trauma caused by the wire or the catheter and insertion of the vascular sheath. Since the scope of the dissection, and furthermore the intricacy of the surgical revision, can seldom be assessed solely from the medical imaging, in majority of the cases, an immediate thoracotomy with surgical revision is required (37). To prevent the dissection in TAVI, steps need to be taken in the preoperative, intraoperative and postoperative segment of the procedure. During the preoperative stage, imaging techniques are used to foresee the risk of a vascular complication both at the site of access as well as along the complete aorta. During the intraoperative stage, the catheter can easily injure the vascular system. For this reason, during the insertion and retraction of the catheter, the surgeon needs to maintain the sheath position constant and station the guidewire in the correct location with the aid of fluoroscopy. Lastly, in the postoperative stage, transesophageal echocardiography is advised to expose any complications (38).

One of the highly difficult and taxing steps of the TAVI procedure is achieving the correct valve positioning with the prothesis device. Although this implantation is done

in a controlled and a systematic fashion, valve mispositioning still happens. In rare cases, the malposition of the valve can endanger the patient's hemodynamic status. The location of the prosthesis in relation to the annulus of the aortic valve is visualized with the use of 20 milliliters of contrast media and the expected location of the prosthesis is 4 to 8 millimeters inferior to the annulus of the aortic valve. If this distance is more than 12 millimeters from the annulus, then it is defined as a "too low" implantation. This low implantation can cause aortic regurgitation. In order to ensure the proper position, transesophageal echocardiography or contrast angiography are used during the procedure.

Calcifications of the native valve may lead to an asymmetric dilation of the transcatheter valve which will result in the valve not being completely circular in shape. This change in the shape of the valve could possibly influence the long-term endurance of the prosthesis. Studies related to this issue are underway and the data from further research will be needed to see the correlation between the calcifications and the durability of the prosthesis (39).

The durability of the transcatheter valves is a large issue since they provide great five-year results, but very little information exists on their long-term durability. Due to the composition of the valves, which is the bioprosthetic material, they are susceptible to deteriorating with time (40). They are classified as structural valve deterioration and non-structural valve deterioration. The non-structural valve deterioration refers to processes such as infective endocarditis, patient prosthesis mismatch and valve thrombosis. Alternatively, structural valve deterioration represents the intrinsic pathology of the stent structure or the leaflets with processes such as leaflet tear, stent creep, stent fracture and leaflet calcification. There are similarities between the

degeneration of the TAVI valves and the bioprosthetic surgical aortic valves. In contrast, the mechanisms that are involved solely in the TAVI degeneration are balloon expansion, valve crimpling, valve thrombosis and stent under-expansion (41). There is an issue with declaring an estimate of the valve durability since there is an absence of a universally acknowledged definition of structural valve deterioration. Durability of the valve is especially crucial for younger patients who are expected to outlast their bioprosthetic valve. Hence, while the utilization of TAVI is safe and effective for the elderly patients, there remains an open question regarding the benefits and costs of its use on the younger population. With increasing knowledge gained through research, and subsequent iterative improvements in the production and implantation techniques of TAVI valves, long-term outcomes and durability of the valves might improve (42).

Frequent complications of TAVI were disturbances in the heart conduction and consequent implantation of permanent pacemakers. When considering the close proximity of the aortic valve to the conduction system of the heart, it is not shocking that disturbances in the conduction system are recognized complications of the TAVI procedure, arising even without the surgical removal of the annulus tissue or the valve. These abnormalities are the AV block and the bundle branch block. This occurs due to the pressure exerted by the transcatheter valves on the surrounding tissue, transient periprocedural inflammation, edema, and underlying pre-existing conduction comorbidities, leading to an increased rate of rhythm disorders that ultimately need a permanent pacemaker to be implanted. The incidence of permanent pacemaker implantation depends greatly according to the type of the valve used during the procedure, the history of the right bundle branch block, the depth of the implantation,

the level of calcification of the aortic annulus, but it is estimated to be required in up to 20% of the patients (43). With the intention of decreasing or even preventing conduction disturbances from arising, before the implantation process, the abnormalities in the conduction system of the heart need to be documented with the help of a 12-lead ECG which will detect any preexisting bundle branch block or AV block. During the procedure as well as five days after it, a three-lead rhythm strip is performed to watch out for the late development of a complete heart block following the TAVI procedure (44).

It can be concluded that the complications arising from the TAVI procedure, as in all other fields in medicine, can only be eliminated or at least reduced with further cumulating our knowledge and continuing to conduct future studies aimed at improving the existing state of affairs. The responsibility of the medical professionals continues to be to warrant a safe and efficient treatment for the patient.

2.7. FUTURE RESEARCH

TAVI underwent great development in the innovation and the research since being introduced back in 2002. Since its introduction, it has solidified itself as the favored treatment for symptomatic AS with patients who were considered to be inoperable or to possess a high risk of undergoing surgery. Twenty years of device modification, fine-tuning of the procedural technique, increasing experience of surgeons, and adjustments to the selection criteria for the patients, have considerably decreased complications arising from the procedure and the relating clinical outcomes.

Other key points to investigate are the benefits versus the shortcomings of TAVI compared to the surgical aortic valve replacement, the possibility of lessening the incidence of permanent pacemaker implantation and stroke complications, oral anticoagulation therapy use after TAVI procedure, and the durability subject of a long-term transcatheter heart valve (45).

Even though there was a rapid adoption of TAVI in the medical community, there is still limited information from studies on the need for aortic reintervention following a TAVI procedure. More and more younger patients are becoming eligible for the procedure and are undergoing TAVI. Meanwhile, the durability of the bioprosthetic valve is currently not a permanent, long-term solution for them, so the need for aortic reinterventions is expected to increase in the future (46). In a study conducted at the University of Michigan between 2011 and 2019, there were 1489 patients who underwent TAVI procedure. Out of these patients, 24 needed to undergo an aortic valve reintervention. In addition, 4 more patients who received the TAVI procedure at a different institution, came to the University of Michigan for an aortic valve reintervention. These 28 patients were retrospectively reviewed. The incidence of the

aortic reintervention at 8 years post procedure was 4.6%. 71% of the patients were considered to be unsuitable for another TAVI procedure due to the concurrent cardiac procedures, endocarditis, or unfavorable anatomy. Concurrent cardiac procedures were associated with a need for TAVI-explant. They concluded that conducting a repeat TAVI procedure was often not possible due to the need for concurrent cardiac procedures or the presence of an unfavorable anatomy (47). There is a lack of research on the topic of TAVI failure and aortic reintervention. This scarcity may be due to the infrequency of the TAVI failure and the subsequent aortic reintervention, TAVI recipients not outliving the bioprosthetic valve lasts, shortage of long-term follow-up of TAVI recipients, under-reporting of these events or a mixture of these elements. The option of conducting a repeat TAVI procedure seems limited and mostly continues to be a theoretical approach with no data to support it. As it was already stated above, with the expansion of the pool of patients eligible for TAVI, mainly the younger population, there is a noticeable increase of TAVI-explant estimated in the next decade according to the study. Therefore, more careful clinical judgement and selection of candidates for the TAVI procedure is vital and the TAVI team should keep in mind the lifetime management during the planning for the initial procedure on the aortic valve. A procedure which will be seen more and more in the upcoming years is valve-in-valve technique. In a published clinical report, a case of TAVI failure with a previous history of a surgical aortic valve replacement resulted in the necessity for the developing valve-in-valve-in-valve TAVI (ViViV-TAVI). The acute failure of the valve reported in this case commonly ends in a pulmonary oedema hastily evolving into a cardiogenic shock (48). The emergency procedure was needed to prevent death and resulted in a speedy hemodynamic and general recovery, demonstrating that valve-

in-valve-in-valve TAVI can be used beneficially as a rescue method for acute valve-in-valve TAVI failure. Additionally, another case was reported of an elderly woman who initially underwent surgical aortic valve replacement, followed by a TAVI procedure 10 years after the initial treatment, and finally became symptomatic again 6 years later and valve-in-valve-in-valve TAVI was performed successfully on the patient (49). Procedures of ViViV-TAVI have been reported, most of them related to immediate complications of aortic insufficiency, perivalvular leak, or valve recoil. With the steadfast increase in the utilization of TAVI, it can be expected that progressively more TAVI failures will occur, necessitating a rescue method such as the ViViV-TAVI. Valve-in-valve-in-valve technique is a novel method and requires further research to see its full potential but also to reveal the long-term outcomes and possible shortcomings.

To conclude, there are still important tasks to additionally modernize the procedure, improve the outcomes for the patients, and decrease the expenses. Specifically, researching the use of TAVI in patients of a younger age and belonging to a lower risk group for undergoing surgery, is of high yield as time goes on.

3. CONCLUSION

Two decades ago, TAVI was launched as a pioneer procedure for patients suffering with severe aortic stenosis and considered not operable or having a high risk of undergoing surgical aortic valve replacement. Today, TAVI is no longer an experimental option but a mainstay, standard-of-care, therapy for more and more patients falling under the diagnosis of AS, and in the future will probably be indicated as a therapy for more pathological conditions. With the improvement of the technology, the procedure itself, the experience and skill set of the operators performing it, TAVI is on an upward curve. There are, of course, more regions in which there is room for improvement and refinement to ensure the best possible outcome for the patient and also a desire to decrease the frequency of common complications arising from TAVI such as stroke, major vascular events and placement of a permanent pacemaker. Taken as a whole, it can be expected that TAVI will continue to grow and refine, becoming the staple therapy choice for the treatment of most aortic stenosis patients.

4. ACKNOWLEDGEMENTS

I would like to thank my mentor, Professor Igor Rudež, MD, PhD, on his patience and help throughout the process of writing this graduate thesis.

Thank you to my family and friends for their unyielding support during the course of my education.

5. REFERENCES

1. Kuhnel W FH. Color Atlas of Human Anatomy Vol. 2, Internal Organs. In: 6th ed. Stutthart: Thieme; 2015. p. 16–23.
2. Moore KL, Dalley AF, Agur A. Clinically oriented anatomy. In: 8th ed. Philadelphia: Lippincott Williams and Wilkins; 2017. p. 137–54.
3. Brunicardi F., Andersen K. Dana. Schwartz's Principles of Surgery. In: 10th ed. New York: McGraw-Hill Education; 2015. p. 757–62.
4. Carabello BA. Introduction to aortic stenosis. *Circ Res*. 2013 Jul 5;113(2):179–85.
5. Joseph J, Naqvi SY, Giri J, Goldberg S. Aortic Stenosis: Pathophysiology, Diagnosis, and Therapy. *Am J Med*. 2017 Mar;130(3):253–63.
6. Zheng KH, Tzolos E, Dweck MR. Pathophysiology of Aortic Stenosis and Future Perspectives for Medical Therapy. *Cardiol Clin*. 2020 Feb;38(1):1–12.
7. Aronow WS. Aortic stenosis. *Compr Ther*. 2007;33(4):174–83.
8. Grimard BH, Safford RE, Burns EL. Aortic Stenosis: Diagnosis and Treatment. *Am Fam Physician*. 2016 Mar 1;93(5):371–8.
9. Baumgartner H, Falk V, Bax J, De Bonis M, Hamm C, Holm P, et al. 2017 ESC/EACTS Guidelines for the management of valvular heart disease. *Eur Heart J*. 2017 Aug 26;38.
10. Ben-Dor I, Maluenda G, Dvir D, Barbash IM, Okubagzi P, Torguson R, et al. Balloon aortic valvuloplasty for severe aortic stenosis as a bridge to transcatheter/surgical aortic valve replacement. *Catheter Cardiovasc Interv Off J Soc Card Angiogr Interv*. 2013 Oct 1;82(4):632–7.
11. Avvedimento M, Tang GHL. Transcatheter aortic valve replacement (TAVR): Recent updates. *Prog Cardiovasc Dis*. 2021 Dec;69:73–83.
12. Figulla HR, Franz M, Lauten A. The History of Transcatheter Aortic Valve Implantation (TAVI)-A Personal View Over 25 Years of development. *Cardiovasc Revascularization Med Mol Interv*. 2020 Mar;21(3):398–403.
13. Akodad M, Lefèvre T. TAVI: Simplification Is the Ultimate Sophistication. *Front Cardiovasc Med*. 2018;5:96.
14. Sokoloff A, Eltchaninoff H. [TAVI: History and perspectives]. *Presse Medicale Paris Fr* 1983. 2017 Aug;46(7-8 Pt 1):772–6.
15. de Jaegere P, de Ronde M, den Heijer P, Weger A, Baan J. The history of transcatheter aortic valve implantation: The role and contribution of an early

- believer and adopter, the Netherlands. *Neth Heart J Mon J Neth Soc Cardiol Neth Heart Found*. 2020 Aug;28(Suppl 1):128–35.
16. Grube E, Schuler G, Buellesfeld L, Gerckens U, Linke A, Wenaweser P, et al. Percutaneous aortic valve replacement for severe aortic stenosis in high-risk patients using the second- and current third-generation self-expanding CoreValve prosthesis: device success and 30-day clinical outcome. *J Am Coll Cardiol*. 2007 Jul 3;50(1):69–76.
 17. Lawrence H. Cohn, David H. Adams. *Cardiac Surgery in the Adult*. In: 5th ed. McGraw-Hill Education; 2017. p. 134–6.
 18. Figure 1. SAPIEN, SAPIEN XT, SAPIEN 3 valves (Edwards Lifesciences, A)... [Internet]. ResearchGate. [cited 2022 Mar 18]. Available from: https://www.researchgate.net/figure/SAPIEN-SAPIEN-XT-SAPIEN-3-valves-Edwards-Lifesciences-A-and-Corevalve-Evolut-R_fig1_323162696
 19. Biasco L, Ferrari E, Pedrazzini G, Faletra F, Moccetti T, Petracca F, et al. Access Sites for TAVI: Patient Selection Criteria, Technical Aspects, and Outcomes. *Front Cardiovasc Med*. 2018;5:88.
 20. Howard C, Jullian L, Joshi M, Noshirwani A, Bashir M, Harky A. TAVI and the future of aortic valve replacement. *J Card Surg*. 2019 Dec;34(12):1577–90.
 21. Petronio AS, De Carlo M, Bedogni F, Marzocchi A, Klugmann S, Maisano F, et al. Safety and Efficacy of the Subclavian Approach for Transcatheter Aortic Valve Implantation With the CoreValve Revalving System. *Circ Cardiovasc Interv*. 2010 Aug;3(4):359–66.
 22. Schofer N, Deuschl F, Conradi L, Lubos E, Schirmer J, Reichenspurner H, et al. Preferential short cut or alternative route: the transaxillary access for transcatheter aortic valve implantation. *J Thorac Dis*. 2015 Sep;7(9):1543–7.
 23. Toušek P, Kočka V, Bednář F, Dvořáček M, Vlček L, Bulvas M, et al. Right subclavian approach in transcatheter aortic valve implantation using the CoreValve prosthesis. *Cor Vasa*. 2012 Sep 1;54(5):e326–8.
 24. Watson DR, Yakubov SJ, Lyons JM, Soto CES, Kander NH, Chapekis AT, et al. Trans-subclavian approach for transcatheter aortic valve replacement. *Ann Cardiothorac Surg*. 2017 Sep;6(5):565–7.
 25. Nakatsuka D, Tabata M. Transapical approach for transcatheter aortic valve implantation. *Ann Cardiothorac Surg*. 2017 Sep;6(5):553–4.
 26. Chamandi C, Abi-Akar R, Rodés-Cabau J, Blanchard D, Dumont E, Spaulding C, et al. Transcarotid Compared With Other Alternative Access Routes for Transcatheter Aortic Valve Replacement. *Circ Cardiovasc Interv*. 2018 Nov;11(11):e006388.

27. Rahhab Z, El Faquir N, Tchetché D, Delgado V, Kodali S, Mara Vollema E, et al. Expanding the indications for transcatheter aortic valve implantation. *Nat Rev Cardiol*. 2020 Feb;17(2):75–84.
28. Thonghong T, Backer OD, Søndergaard L. Comprehensive update on the new indications for transcatheter aortic valve replacement in the latest 2017 European guidelines for the management of valvular heart disease. *Open Heart*. 2018 Feb 1;5(1):e000753.
29. Popelova, Jana & Brtko. Summary of the ESC guidelines on the management of valvular heart disease. *Czech Soc Cardiol Rev Artic*. 2013;
30. Mahmaljy H, Tawney A, Young M. Transcatheter Aortic Valve Replacement. In: StatPearls [Internet]. Treasure Island (FL): StatPearls Publishing; 2022 [cited 2022 Apr 27]. Available from: <http://www.ncbi.nlm.nih.gov/books/NBK431075/>
31. Arai T, Lefèvre T. Who is the right patient for TAVI? *J Cardiol*. 2014 Mar;63(3):178–81.
32. Terré JA, George I, Smith CR. Pros and cons of transcatheter aortic valve implantation (TAVI). *Ann Cardiothorac Surg*. 2017 Sep;6(5):444–52.
33. Reardon MJ, Van Mieghem NM, Popma JJ, Kleiman NS, Søndergaard L, Mumtaz M, et al. Surgical or Transcatheter Aortic-Valve Replacement in Intermediate-Risk Patients. *N Engl J Med*. 2017 Apr 6;376(14):1321–31.
34. Haussig S, Mangner N, Dwyer MG, Lehmkuhl L, Lücke C, Woitek F, et al. Effect of a Cerebral Protection Device on Brain Lesions Following Transcatheter Aortic Valve Implantation in Patients With Severe Aortic Stenosis: The CLEAN-TAVI Randomized Clinical Trial. *JAMA*. 2016 Aug 9;316(6):592–601.
35. Haensig M, Lehmkuhl L, Rastan AJ, Kempfert J, Mukherjee C, Gutberlet M, et al. Aortic valve calcium scoring is a predictor of significant paravalvular aortic insufficiency in transapical-aortic valve implantation. *Eur J Cardio-Thorac Surg Off J Eur Assoc Cardio-Thorac Surg*. 2012 Jun;41(6):1234–40; discussion 1240-1241.
36. Thourani VH, Kodali S, Makkar RR, Herrmann HC, Williams M, Babaliaros V, et al. Transcatheter aortic valve replacement versus surgical valve replacement in intermediate-risk patients: a propensity score analysis. *Lancet Lond Engl*. 2016 May 28;387(10034):2218–25.
37. Geile J, Doberentz E, Madea B. Rapid development of an iatrogenic aortic dissection following transcatheter aortic valve implantation. *Forensic Sci Med Pathol*. 2020 Jun 1;16(2):335–9.
38. Rujirachun P, Junyavoraluk A, Jakrapanichakul D, Wongpraparut N, Chunhamaneewat N, Maneesai A, et al. Immediate aortic dissection after transcatheter aortic valve replacement: A case report and review of the literature. *Clin Case Rep*. 2021 Jul 6;9(7):e04412.

39. Buzzatti N, Sala A, Alfieri O. Comparing traditional aortic valve surgery and transapical approach to transcatheter aortic valve implant. *Eur Heart J Suppl.* 2020 Jun 1;22(Supplement_E):E7–12.
40. Fauvel C, Capoulade R, Durand E, Béziau DM, Schott JJ, Le Tourneau T, et al. Durability of transcatheter aortic valve implantation: A translational review. *Arch Cardiovasc Dis.* 2020 Mar 1;113(3):209–21.
41. Kataruka A, Otto CM. Valve durability after transcatheter aortic valve implantation. *J Thorac Dis.* 2018 Nov;10(Suppl 30):S3629–36.
42. Marengo G, Elia E, Bruno F, Franchin L, Piroli F, De Filippo O, et al. Durability of transcatheter aortic valves, current evidence and future prospective. *Vessel Plus.* 2021 Mar 12;5:12.
43. Guetta V, Goldenberg G, Segev A, Dvir D, Kornowski R, Finckelstein A, et al. Predictors and course of high-degree atrioventricular block after transcatheter aortic valve implantation using the CoreValve Revalving System. *Am J Cardiol.* 2011 Dec 1;108(11):1600–5.
44. Young Lee M, Chilakamarri Yeshwant S, Chava S, Lawrence Lustgarten D. Mechanisms of Heart Block after Transcatheter Aortic Valve Replacement – Cardiac Anatomy, Clinical Predictors and Mechanical Factors that Contribute to Permanent Pacemaker Implantation. *Arrhythmia Electrophysiol Rev.* 2015 Aug;4(2):81–5.
45. Tiyerili V, Sötemann D, Grothusen C, Eckel C, Becher MU, Blumenstein J, et al. Latest Advances in Transcatheter Aortic Valve Implantation (2022). *Surg Technol Int.* 2022 Jan 11;40:sti40/1478.
46. Lam KY, Koene B, Timmermans N, Soliman-Hamad M, van Straten A. Reintervention After Aortic Valve Replacement: Comparison of 3 Aortic Bioprostheses. *Ann Thorac Surg.* 2020 Aug;110(2):615–21.
47. Fukuhara S, Nguyen CTN, Kim KM, Yang B, Ailawadi G, Patel HJ, et al. Aortic valve reintervention after transcatheter aortic valve replacement. *J Thorac Cardiovasc Surg.* 2021 Jul 20;S0022-5223(21)01112-0.
48. Malik IS, Jabbour RJ, Ruparelia N, Sen S, Hadjizoulou N, Rana B, et al. Rescue Valve-in-Valve-in-Valve TAVR for Acute Transvalvular Aortic Regurgitation. *Cardiovasc Revasc Med.* 2020 Nov 1;21(11, Supplement):11–3.
49. Grondahl BJ, Dhar G. Valve in Valve in Valve. *JACC Case Rep.* 2019 Dec 1;1(4):468–70.

6. BIOGRAPHY

I was born in Zagreb on the 30th of January 1997. I finished my high school education at XV. Gymnasium International Baccalaureate (IB) Program in 2015. In the academic year 2015/2016 I enrolled in the University of Zagreb, School of Medicine, Medical Studies in English.

During the course of my studies, I attended various science congresses and was an active member of the student section for Dermatovenerology.