

# Neurogena upala moždanih ovojnica i bol u području glave i vrata

---

**Filipović, Boris**

**Doctoral thesis / Disertacija**

**2016**

*Degree Grantor / Ustanova koja je dodijelila akademski / stručni stupanj:* **University of Zagreb, School of Medicine / Sveučilište u Zagrebu, Medicinski fakultet**

*Permanent link / Trajna poveznica:* <https://urn.nsk.hr/urn:nbn:hr:105:400981>

*Rights / Prava:* [In copyright](#)/[Zaštićeno autorskim pravom.](#)

*Download date / Datum preuzimanja:* **2025-02-18**



*Repository / Repozitorij:*

[Dr Med - University of Zagreb School of Medicine Digital Repository](#)



**SVEUČILIŠTE U ZAGREBU  
MEDICINSKI FAKULTET**

**Boris Filipović**

**Neurogena upala moždanih ovojnica  
i bol u području glave i vrata**

**DISERTACIJA**

Zagreb, 2016.

*Pokusi za ovu disertaciju izvedeni su na Zavodu za farmakologiju Medicinskog fakulteta Sveučilišta u Zagrebu.*

*Voditelj rada: prof. dr. sc. Zdravko Lacković, dr. med.*

*Disertacija je pisana kao skup objavljenih znanstvenih radova popraćen kritičkim preglednim poglavljem (tzv. skandinavski tip), na temelju članka 35. **Pravilnika o doktorskim studijima** (Medicinski fakultet u Zagrebu, 2014.) te članka 14. **Pravilnika o doktorskim studijima na Sveučilištu u Zagrebu** (2010.).*

*Disertacija je usuglašena sa standardima **ORPHEUS** (Standards for PhD Education in Biomedicine and Health Science in Europe, ORPHEUS/AMSE/WFME Task Force, Aarhus University Press, Denmark 2012).*

*Zahvaljujem svojem mentoru, prof. dr. sc. Zdravku Lackoviću na savjetovanju, vođenju i strpljenju tijekom mogega znanstvenog odrastanja, usađenoj želji za stjecanjem novih znanja te neprocjenjivom prijateljskom odnosu.*

*Zahvaljujem izv. prof. dr. sc. Lidiji Bach-Rojecky na dugogodišnjoj pomoći od samih početaka rada u laboratoriju i odluci da se znanošću počnem aktivno baviti.*

*Zahvaljujem dr. sc. Ivici Mataku na suradnji i nebrojenim korisnim savjetima pri izvođenju pokusa i pisanju znanstvenih radova.*

*Zahvaljujem tehničkoj suradnici, gđi Božici Hržan na pomoći pri izvođenju pokusa i svim djelatnicama Zavoda za farmakologiju Medicinskog fakulteta Sveučilišta u Zagrebu na pruženoj podršci tijekom izrade ove disertacije.*

*Zahvaljujem svojoj obitelji na razumijevanju i podršci, zbog vas ovo ima smisla i drago mi je da smo zajedno kroz to prošli.*

# SADRŽAJ

## Kratice

<b>1. UVOD</b>	1
<b>1.1. Anatomija i fiziologija boli</b>	1
1.1.1. Prijenos boli	1
1.1.2. Podjela boli	2
1.1.3. Periferna i centralna senzitivizacija	6
<b>1.2. Bol u području glave i vrata</b>	10
1.2.1. Senzorna inervacija glave i vrata	10
1.2.2. Glavobolje	14
1.2.2.1. Definicija i klasifikacija glavobolja	14
1.2.2.2. Teorija konvergencije za primarne glavobolje	15
1.2.2.3. Povezanost migrene s drugim bolnim stanjima u području glave i vrata: postoje li ekstrakranijalni generatori migrene?	18
<b>1.3. Neurogena upala moždanih ovojnica</b>	19
1.3.1. Moždane ovojnice	
1.3.1.1. Anatomija i histologija	19
1.3.1.2. Inervacija moždanih ovojnica	20
1.3.1.3. Proupalne stanice moždanih ovojnica	22
1.3.1.4. Upala moždanih ovojnica – meningitis	22
1.3.2. Neurogena upala	23
1.3.3. Trigeminovaskularna teorija migrene	25
1.3.4. Eksperimentalni modeli aktivacije trigeminovaskularnog sustava	25
1.3.5. Farmakologija neurogene upale moždanih ovojnica	28
<b>1.4. Antinociceptivni učinak botulinum toksina tipa A</b>	29
<b>2. HIPOTEZA</b>	32
<b>3. CILJEVI RADA</b>	33

<b>4. MATERIJAL I METODE</b>	34
<b>4.1. Životinje</b>	34
<b>4.2. Ispitivane supstancije</b>	34
4.2.1. Botulinum toksin tipa A	34
4.2.2. Triptani	35
4.2.3. Morfin	35
4.2.4. Lidokain	36
<b>4.3 Korištene kemikalije i reagensi</b>	36
<b>4.4. Bihevioralni testovi za mjerenje nocicepcije</b>	36
4.4.1. Von Freyevi filament	36
4.4.2. Metoda pritiska šape po Randallu i Salittu	37
<b>4.5. Odrađivanje neurogene upale moždanih i spinalnih ovojnica</b>	38
4.5.1. Mjerenje ekstravazacije proteina plazme	38
4.5.2. Histološka bojenja moždanih i spinalnih ovojnica	39
4.5.3. Mjerenje porasta apsolutnog broja stanica u moždanim i spinalnim ovojnicama	39
<b>4.6. Inhibicija aksonalnog transporta kroz trigeminalni ganglij</b>	39
<b>4.7. Eksperimentalni modeli boli</b>	40
4.7.1. Formalinski test	40
4.7.2. Model upale temporomandibularnog zgloba uzrokovane CFA	41
4.7.3. Model parcijalnog presijecanja mišića gastroknemijusa	42
4.7.4. Model podvezivanja infraorbitalnog živca	42
4.7.5. Model podvezivanja velikog okcipitalnog živca	43
4.7.6. Model podvezivanja ishijadičnog živca	44
4.7.7. Model parcijalnog presijecanja ishijadičnog živca	45
<b>4.8. Statistička obrada rezultata</b>	45
<b>5. REZULTATI</b>	
<b>5.1. Djelovanje različitih vrsta boli u inervacijskom području trigeminalnog živca na razvoj neurogene upale kranijalnih moždanih ovojnica</b>	46
5.1.1. Upalna bol	46
5.1.1.1. <i>Formalinski test</i>	46

5.1.1.2. <i>Upalna bol temporomandibularnog zgloba uzrokovana CFA</i>	49
5.1.2. Neuropatska bol	52
5.1.2.1. <i>Podvezivanje infraorbitalnog živca</i>	52
<b>5.2. Neurogena upala kao specifična reakcija kranijalne dure na bolni podražaj iz područja glave i vrata</b>	55
5.2.1. Neuropatska bol podrijetlom iz vrata	55
5.2.1.1. <i>Podvezivanje velikog okcipitalnog živca</i>	55
5.2.2. Neuropatska bol podrijetlom iz stražnje šape	56
5.2.2.1. <i>Parcijalno presijecanje ishijadičnog živca</i>	56
5.2.2.2. <i>Podvezivanje ishijadičnog živca</i>	57
<b>5.3. Je li bol iz inervacijskog područja ishijadičnog živca povezana s neurogenom upalom lumbalnih ovojnica?</b>	58
5.3.1. <i>Parcijalno presijecanje ishijadičnog živca</i>	58
5.3.2. <i>Podvezivanje ishijadičnog živca</i>	59
<b>5.4. Farmakološka karakterizacija neurogene upale kranijalnih moždanih ovojnica</b>	61
5.4.1. Botulinum toksin tipa A	61
5.4.1.1. <i>Formalinski test</i>	61
5.4.1.2. <i>Model parcijalnog presijecanja mišića gastroknemijusa</i>	62
5.4.1.3. <i>Model bolnosti temporomandibularnog zgloba uzrokovane CFA</i>	63
5.4.1.4. <i>Podvezivanje infraorbitalnog živca</i>	66
5.4.2. Karakterizacija djelovanja različitih analgetika na bol i neurogenu upalu	71
<b>6. RASPRAVA</b>	75
<b>6.1. Neurogena upala moždanih ovojnica kao posljedica boli u trigeminalnom području</b>	75
6.1.1. Periferna ozljeda u području trigeminusa povezana je s neurogenom upalom u moždanim ovojnicama (duri mater)	75
6.1.2. Unilateralni periferni bolni podražaj uzrokuje bilateralnu alodiniju i neurogenu upalu dure	76

6.1.3. Pojavnost i intenzitet neurogene upale dure ovise o intenzitetu i trajanju perifernog bolnog podražaja	76
6.1.4. Neurogena upala dure ovisi o prijenosu bolnog podražaja s periferije	78
6.1.5. Periferna bol uzrokuje nastanak dviju komponenti neurogene upale dure	78
6.1.6. Stanična komponenta neurogene upale dure uključuje više vrsta proupalnih stanica	79
6.1.7. Neurogena upala dure u upalnoj i neuropatskoj boli i procesi periferne i centralne senzitivacije	80
6.1.8. Neurogena upala dure u neuropatskoj boli sudjeluje u konačnoj percepciji boli	80
<b>6.2. Neurogena upala kao specifična reakcija kranijalne dure na periferni bolni podražaj iz područja glave i vrata</b>	<b>82</b>
<b>6.3. Lumbalna dura nema sposobnost razvoja neurogene upale nakon perifernog bolnog podražaja</b>	<b>83</b>
<b>6.4. Antinociceptivni učinak BoNT/A u migreni</b>	<b>84</b>
<b>7. ZAKLJUČAK</b>	<b>90</b>
<b>8. SAŽETAK</b>	<b>91</b>
<b>9. SUMMARY</b>	<b>92</b>
<b>10. LITERATURA</b>	<b>94</b>
<b>11. ŽIVOTOPIS</b>	<b>112</b>
<b>12. OBJAVLJENI RADOVI</b>	<b>113</b>

*Prilozi - Objavljeni znanstveni radovi vezani uz problematiku disertacije*

- I. Filipović B, Bach-Rojecky L, Lacković Z. Lasting reduction of postsurgical hyperalgesia after single injection of botulinum toxin type A in rat. *Fundam Clin Pharmacol* 2010;24:43-5.
- II. Filipović B, Gjurić M, Hat J, Glunčić I. High mega jugular bulb presenting with facial nerve palsy and severe headache. *Skull Base* 2010;20:465-8.
- III. Filipović B, Matak I, Bach-Rojecky L, Lacković Z. Central action of peripherally applied botulinum toxin type A on pain and dural protein extravasation in rat model of trigeminal neuropathy. *PLoS One*. 2012;7:e29803.
- IV. Filipović B, Matak I, Lacković Z. Dural neurogenic inflammation induced by neuropathic pain is specific to cranial region. *J Neural Transm* 2014;121:555-63.
- V. Lacković Z, Filipović B, Matak I, Helyes Z. Activity of botulinum toxin type A in cranial dura: implications for treatment of migraine and other headaches. *Br J Pharmacol*. 2016; 173:279-91.



## Kratice

<b>BoNT/A</b>	- botulinum toksin tipa A (engl. <i>botulinum toxin type A</i> )
<b>CGRP</b>	- polipeptid kalcitoninskog gena (engl. <i>calcitonin gene related paptide</i> )
<b>SP</b>	- supstancija P (engl. <i>substance P</i> )
<b>TRPV</b>	- kapsaicinom aktivirani neselektivni ionski kanal (engl. <i>transient receptor potential cation channel subfamily V member 1</i> )
<b>ASIC</b>	- na kiselinu osjetljivi ionski kanali (engl. <i>acid sensing ion channels</i> )
<b>AMPA</b>	- $\alpha$ -amino-3-hidroksi-5-metil-4-izoksazolpropionska kiselina (engl. <i><math>\alpha</math>-amino-3-hydroxy-5-methyl-4-izoxazolepropionic acide</i> )
<b>NK</b>	- neurokinin
<b>ATP</b>	- adenzin trifosfat (engl. <i>adenosine triphosphate</i> )
<b>NMDA</b>	- N-metil-D-aspartat (engl. <i>N-methyl-D-aspartate</i> )
<b>GABA</b>	- gama-aminomaslačna kiselina (engl. <i>gamma-amino butyric acid</i> )
<b>TNF-<math>\alpha</math></b>	- faktor nekroze tumora (engl. <i>tumor necrosis factor alpha</i> )
<b>MAPKs</b>	- porodica kinaza aktiviranih mitogenom (engl. <i>mitogen-activated protein kinases</i> )
<b>PKA</b>	- protein kinaza A (engl. <i>protein kinase A</i> )
<b>PKC</b>	- protein kinaza C (engl. <i>protein kinase C</i> )
<b>cGMP</b>	- ciklički gvanozin monofosfat (engl. <i>cyclic guanosine monophosphate</i> )
<b>ASCI</b>	- na kiselinu osjetljivi ionski kanali (engl. <i>acid sensing ion channel</i> )
<b>COX-2</b>	- cikloksigenaza-2 (engl. <i>cyclooxygenase 2</i> )
<b>i.m.</b>	- intramuskularno
<b>s.c.</b>	- subkutano
<b>i.g.</b>	- intraganglijski
<b>SŽS</b>	- središnji živčani sustav
<b>SNAP-25</b>	- engl. <i>synaptosomal associated protein 25 kDa</i>
<b>SNARE</b>	- engl. <i>soluble N-ethylmaleimid fusion protein attachment protein</i>

# 1. UVOD

## 1.1. ANATOMIJA I FIZIOLOGIJA BOLI

Prema definiciji Svjetske organizacije za istraživanje boli, IASP (engl. *International Association for Study of Pain*), bol je definirana kao neugodno senzorno i emocionalno iskustvo povezano sa stvarnom ili mogućom ozljedom tkiva. Fiziološka uloga boli je zaštita organizma od ozljede koja je nastala ili će nastati i poticanje organizma na obranu i/ili zalječenje. Patološka, kronična bol gubi funkciju zaštite organizma i šteti njegovu funkcioniranju te dovodi cjelokupni opstanak u pitanje.

Bol pripada u skupinu somatosenzornih osjeta s: mehaničkim (dodir, tlak, vibracije) i toplinskim osjetom (toplo, hladno); propiocepcijom (položaj tijela i zglobnih pokreta); osjetom visceralnog istezanja.<sup>1</sup> Svi somatosenzorni osjeti, osim boli, imaju svojstvo adaptacije odnosno slabe nakon ponavljanja podražaja. S druge strane, ako se bolni podražaj ne ukloni, bol postaje sve intenzivnija, što se naziva senzitivizacija.

### 1.1.1. Prijenos boli

Bol registriraju receptori (nociceptori), koji su goli živčani završetci osjetnih neurona prisutni u većini tkiva kao što su: koža, mišići, unutarnji organi, krvne žile i kosti.<sup>2</sup> Važno je istaknuti da mozak nema nociceptore, već da se oni nalaze u moždanim ovojnica koje ga okružuju.

Živčani impulsi nastali aktivacijom nociceptora prenose se prema središnjem živčanom sustavu (SŽS) perifernim okončinama primarnih aferentnih neurona čija se tijela nalaze u perifernim osjetnim ganglijima. Centralne okončine tih neurona aktiviraju sekundarne neurone osjetnog puta, koji su lokalizirani ovisno o anatomskom području: glava i vrat – u moždanom deblu i produženoj moždini; ostali dio tijela – u stražnjem rogu kralježničke moždine. Aksoni centralnih neurona odlaze prema višim supraspinalnim centrima SŽS-a, od kojih je prvi talamus, a zatim u područja koja su odgovorna za obradu pojedinih komponenti boli (primarna, kognitivna, afektivna): somatosenzorni korteks, prefrontalni korteks, središnje jezgre amigdala i ventralne medijalne jezgre hipokampusu.<sup>3</sup>

Prijenos boli prema supraspinalnim centrima može se modulirati na više načina:

a) podražaj mehanoreceptora koji ne sudjeluju u prijenosu bolnog podražaja (senzorna vlakna tipa A $\alpha$  i A $\beta$ ) aktivira inhibicijske interneurone na razini moždanog debla/kralježničke moždine, koji izlučuju inhibicijske neurotransmitore poput endorfina i  $\gamma$ -aminomaslačne kiseline (GABA). To se naziva teorijom kontrolnih vrata boli, engl. "*Gate theory*".<sup>4</sup>

b) aktivacijom periakveduktalne sive tvari mezencefalona, odnosno njegovih serotninergičnih jezgri (raphe magnus) čiji aksoni na razini produžene/kralježničke moždine mogu inhibirati ekscitacijske i/ili ekscitirati inhibicijske interneurone.<sup>5</sup>

### **1.1.2 Podjela boli**

Bol se može podijeliti prema: podrijetlu – kutana, mišićna i visceralna bol; trajanju – akutna i kronična; etiologiji – nociceptivna, upalna i neuropatska; intenzitetu – slaba i jaka.

#### **Podjela boli prema podrijetlu**

*Kutana bol nastaje* stimulacijom kožnih nociceptora, a bolni podražaj prenose dvije vrste aferentnih vlakana:

- mehanički nociceptor je goli završetak primarnog aferentnog A $\delta$  senzornog vlakna (mijelinizirana, imaju veliku brzinu provođenja akcijskog potencijala; 12 – 36 m/s) kojega aktiviraju podražaji jakog intenziteta (npr. gnječenje ili ubod kože), što uzrokuje osjet oštre, štipajuće boli
- polimodalni nociceptor je goli završetak primarnog aferentnog C senzornog vlakna (nemijelinizirana, imaju malu brzinu provođenja akcijskog potencijala, 0,5 – 1,2 m/s) kojega aktiviraju mehanički, kemijski ili toplinski podražaji srednjeg intenziteta

Obje vrste receptora odnosno aferentnih vlakana se nalaze u dermisu oko pripadajućih krvnih žila. Njihovom aktivacijom se doživljavaju dvije faze kutane boli. Prva faza je posljedica aktivacije mijeliniziranih A $\delta$ -vlakana i nastupa brzo, traje kratko, intenzivna je (oštra) i dobro lokalizirana. Druga faza je posljedica aktivacije nemijeliniziranih C-vlakana i nastupa sporije, traje dulje, slabijeg je intenziteta (tupa) i lokalizacije.<sup>2</sup>

*Mišićna bol* rezultat je aktivacije mišićnih nociceptora koji se slično kao kutani nociceptori dijele u dvije skupine:

- mala mijelinizirana vlakna grupe III (odgovaraju kutanim A $\delta$ -vlaknima) odgovaraju na rastezanje i kontrakciju mišića
- nemijelinizirana vlakna grupe IV (odgovaraju kutanim C-vlaknima) reagiraju na termalni podražaj, ishemiju/hipoksiju i pritisak na mišić

Mišićna bol je, neovisno o trajanju, karakterizirana kao tupa i grčevita.<sup>6</sup>

*Visceralna bol.* Nociceptori unutarnjih organa imaju veći prag aktivacije i aktiviraju se tek posredovanjem upalnih medijatora, kada postaju osjetljivi na mehaničke podražaje. Visceralna bol je karakterizirana kao difuzna i tupa, slabo lokalizirana.<sup>7</sup>

### **Podjela boli prema etiologiji**

Najvažnija podjela boli je prema etiologiji – na nociceptivnu, upalnu i neuropatsku bol, koje se razlikuju prema mehanizmima nastanka, patofiziološkim karakteristikama i trajanju.<sup>8</sup>

#### **1) Nociceptivna bol**

Nociceptivna bol se javlja u fiziološkim uvjetima i traje kratko (sekunde), a ima ulogu upozorenja organizma na potencijalnu ozljedu. Nastaje nakon što podražaj jakog intenziteta aktivira nociceptore na C i A $\delta$  vlaknima. Nociceptori mogu biti različiti tipovi ionskih kanala: TRPV-1 (kapsaicinom aktivirani neselektivni ionski kanal, engl. *transient receptor potential cation channel subfamily V member 1*), ASIC (na kiselinu osjetljivi ionski kanali, engl. *acid sensing ion channels*) i drugi. Vežanjem specifičnih liganda za navedene receptore odnosno ionske kanale oni postaju propusni (neselektivno) za različite ione, što uzrokuje depolarizaciju membrane perifernih okončina aferentnih neurona i izlučivanje glavnog ekscitacijskog neurotransmitora, glutamata. Tako izlučeni glutamat se veže na specifične ionotropne AMPA (AMPA:  $\alpha$ -amino-3-hidroksi-5-metil-4-izoksazolpropionska kiselina) receptore na tim istim perifernim okončinama i uzrokuje stvaranje akcijskog potencijala, odnosno živčanog impulsa. Retrogradnim prijenosom impulsa na centralnim okončinama perifernih aferentnih neurona dolazi do izlučivanja glutamata, što rezultira aktivacijom centralnih osjetnih neurona (brza sinaptička neurotransmisija). Dodatno se iz centralnih okončina izlučuju neuromodulatori, koji sudjeluju u sporoj neurotransmisiji tipa supstancije P, SP (engl. *substance P*), koja djeluje preko specifičnih neurokininskih receptora NK<sub>1</sub> i pojačava aktivnost centralnih neurona.<sup>3</sup>

#### **2) Upalna bol**

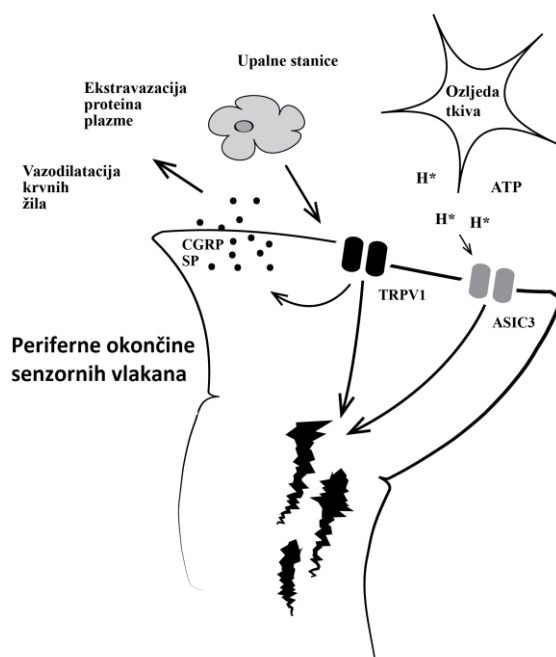
Upalna bol se javlja nakon upale ili ozljede tkiva (koža, mišić, zglob i dr.), a rezultat je djelovanja medijatora upale (prostagladini, histamin, bradikinin, ATP, H<sup>+</sup>, citokini i dr.) izlučenih iz oštećenih stanica tkiva (npr. fibroblasta) ili proupalnih stanica (mastociti, leukociti i dr.) (slika 1). Neki od medijatora upale (serotonin, H<sup>+</sup>) izravno stimuliraju nociceptore, dok drugi na periferne senzorne okončine djeluju posredno (smanjuju prag receptorskog potencijala i povećavaju podražljivost membrane) u procesu koji se naziva

periferna senzitivacija. Kao rezultat stvaranja akcijskog potencijala na perifernim okončinama dodatno dolazi do izlučivanja neuropeptida kao što su SP i polipeptid kalcitoninskog gena, CGRP (engl. *calcitonin gene related peptide*). U perifernim tkivima SP uzrokuje vazodilataciju krvnih žila, a CGRP povećava kapilarnu permeabilnost. To rezultira povećanjem broja upalnih stanica te medijatora upale na mjestu ozljede, što se naziva neurogena upala, a čime se zatvara pozitivna povratna sprega (periferna senzitivacija).<sup>9</sup> Neuropeptidi se također izlučuju iz aksonskih kolaterala perifernih okončina koje nisu izravno stimulirane, čime se lokalno područje zahvaćeno upalnom boli širi na regionalno područje, što se naziva aksonski refleksi. Dodatno se SP i CGRP luče iz susjednih nepodraženih perifernih neurona, što je posljedica međusobne aktivacije tijela neurona na razini ganglija.<sup>10</sup>

U upali se aktiviraju tzv. tihi nociceptori (engl. *silent nociceptors*), koji se ne aktiviraju bolnim podražajima u fiziološkim uvjetima (čine 10 – 20% C-vlakana u koži).<sup>8</sup> Također moguće su radikalnije promjene fenotipa pojedinih A-vlakana (A $\beta$ ), koja nakon pojačanog djelovanja neuromodulatora (SP, CGRP) poprimaju odlike C-vlakana te sudjeluju u prijenosu bolnih podražaja.<sup>8</sup>

U tijelima neurona događaju se promjene u transkripciji gena koji sudjeluju u neurotransmiji boli. Proces je posredovan faktorima rasta živaca, NGF (engl. *nerve growth factor*), izlučenima iz upalnih stanica, fibroblasta i dr. te njihovim retrogradnim transportom do tijela neurona u perifernim ganglijima. Transkripcijom gena se povećava translacija brojnih neuromodulatora (SP, CGRP), receptora (NK<sub>1</sub>, AMPA, CGRP) i ionskih kanala (TRPV-1, Na<sup>+</sup>, K<sup>+</sup>).<sup>9, 11</sup>

Sve ove promjene upućuju na plastičnost perifernog živčanog sustava te mogućnost povećanja osjetljivosti na bolne (hiperalgezija) i/ili nebolne podražaje (alodinija).<sup>8</sup>



**Slika 1. Mehanizam nastanka upalne boli na periferiji (prema ref. Zhang i Bao, 2006)<sup>9</sup>**

U perifernim tkivima, u uvjetima upale ili ozljede (koža, mišić, zglob i dr.), dolazi do izlučivanja medijatora upale (prostagladini, histamin, bradikinin, ATP,  $H^+$ , citokini i dr.) iz oštećenih stanica tkiva (npr. fibroblasta) ili upalnih stanica (mastociti, leukociti i dr.). Neki od medijatora upale (ATP,  $H^+$ ) izravno stimuliraju nociceptore, što uzrokuje stvaranje akcijskog potencijala koji se dalje prenosi kao bolni signal prema SŽS-u. Dodatno, kao rezultat stvaranja akcijskog potencijala na perifernim okončinama, dolazi do izlučivanja neuropeptida kao što su SP i CGRP. U perifernim tkivima SP uzrokuje vazodilataciju krvnih žila, a CGRP povećava kapilarnu permeabilnost, što rezultira povećanjem broja upalnih stanica.

### **3) Neuropatska bol**

Neuropatska bol nastaje nakon ozljede perifernih i/ili centralnih neurona, a javlja se u stanjima kao što su dijabetes, kronični alkoholizam, traumatske ozljede perifernih živaca i kralježničke moždine, te kao posljedica primjene određenih citostatika (primjerice, vinka alkaloidi i taksani).<sup>12</sup> Patofiziološki mehanizmi neuropatske boli su složeni i karakteriziraju ih procesi periferne i centralne senzitivacije.

Na perifernim okončinama neurona događaju se znatne promjene u podražljivosti i prijenosu impulsa, što je posljedica promjena u sastavu ionskih kanala (kanalopatije tipa  $Na^+$ ,  $K^+$ , TRPV-1). Također dolazi do promjena u funkcionalnosti receptora gdje glutamat više ne djeluje samo preko receptora AMPA, već i preko NMDA (NMDA: N-metil-D-aspartat) i kainatnih receptora.

Na mjestu ozljede živca nastaje regenerativni, ali često nekontrolirani rast aksona (klicanje živaca ili engl. *nerve sprouting*), koji se naziva neurinom. Elektrofiziološkim mjerenjima dokazana je njihova povećana spontana aktivnost, abnormalna ekscitabilnost i osjetljivost.<sup>13</sup> Također je pokazano da povećanu ekscitabilnost neurona uzrokuje i prijelaz napona s mjesta demijelinizacije oštećenog neurona na neozlijeđeni susjedni neuron.<sup>8</sup>

U neuropatskoj boli promjene se događaju i na razini centralnih neurona kralježničke/produžene moždine te je zabilježena njihova povećana podražljivost, što je posljedica, kao u perifernim neuronima, promjena u sastavu ionskih kanala (kanalopatije tipa  $\text{Na}^+$ ,  $\text{K}^+$ , TRPV-1,  $\text{Ca}^{2+}$  i dr.). Za neuropatsku bol su karakteristični procesi plastičnosti odnosno reorganizacije neuronskih krugova s uspostavom novih sinapsi između nociceptivnih neurona i neurona koji u fiziološkim uvjetima ne sudjeluju u prijenosu boli (npr. inervacija lamine II stražnjeg roga kralježničke moždine A $\beta$ -vlaknima). Modulacija nocicepcije odnosno centralna dezinhibicija je dodatno poremećena u neuropatskoj boli, gdje dolazi do gubitka inhibicijskih interneurona te smanjene sinteze inhibicijskih neurotransmitora, npr. GABA.<sup>8</sup>

Važnu ulogu u neuropatskoj nocicepciji imaju glija-stanice u perifernim ganglijima i na razini produžene/kralježničke moždine. Njihova aktivnost je potaknuta djelovanjem glutamata, SP-a, dušikovog oksida (NO) i drugih molekula. Aktivirane glija-stanice izlučuju proupalne citokine kao što su TNF- $\alpha$  i IL-1, ATP, NO, koji zatim djeluju na tijela neurona ekscitacijski, povećavajući sinaptičku snagu, što rezultira održavanjem visokog stupnja centralne senzitivacije.<sup>14</sup>

### **1.1.3. Periferna i centralna senzitivacija**

Senzitivacija je fenomen u kojem opetovani bolni podražaji uzrokuju pojačan osjet boli. Ovisno o razini koju zahvaća, senzitivacija se dijeli na dva tipa, perifernu i centralnu, a svi patofiziološki mehanizmi koji ih prate nisu poznati do kraja.<sup>15</sup> Oba fenomena su karakteristična za dvije vrste boli, upalnu i neuropatsku.

**Periferna senzitivacija** je fenomen povećane podražljivosti prvog neurona osjetnog puta. Razlikuje se od centralne senzitivacije jer predstavlja oblik nociceptorske boli gdje je za njezino održavanje potreban trajan periferni izvor bolnog podražaja. Bihevioralni fenomen koji se javlja je primarna hiperalgezija, definirana kao povećana osjetljivost na bolni podražaj.<sup>16</sup>

Mehanizam nastanka periferne senzitivacije povezan je s djelovanjem raznih medijatora upale (bradikinin, prostagladin, ATP, serotonin) na specifične metabotropne receptore spregnute s G proteinima na staničnim membranama nociceptora. Njihovom aktivacijom pokreću se unutarstanični signalni putovi praćeni fosforilacijom porodice protein kinaza. Poznato je 518 raznih tipova protein kinaza, a danas je razvoj specifičnih inhibitora protein kinaza jedna od strategija razvoja novih lijekova za liječenje kronične boli.<sup>17</sup> Posebno je istraživana porodica kinaza aktiviranih mitogenom, MAPKs (engl. *mitogen-activated protein*

*kinases*), koja uzrokuje fosforilaciju ionskih kanala i receptora ( $\text{Na}^+$ ,  $\text{K}^+$ , ASIC, NMDA), što rezultira povećanom podražljivošću nociceptora. Osim na periferiji, MAPKs je aktiviran i na razini tijela neurona, gdje uzrokuje pojačanu transkripciju i translaciju medijatora koji sudjeluju u procesu senzitivacije.

Nociceptori su razni tipovi ionskih kanala koji sudjeluju u detekciji bolnog podražaja, prijenosu akcijskog potencijala prema SŽS-u, oslobađanju neurotransmitora.<sup>18</sup> Njihova povećana zastupljenost i funkcionalnost u procesu periferne senzitivacije (posljedica posttranslacijskih promjena, odnosno fosforilacije) na membranama nociceptora uzrokuje njihovu povećanu ekscitabilnost na mjestu ozljede/upale.

Smatra se da je porodica TRP kationskih kanala najvažnija u nocicepciji jer sudjeluje u patofiziološkim promjenama kod svih triju vrsta boli. Posebno je do sada istražena njihova podvrsta TRPV-1, koja se aktivira toplinom ("termoTRP"), ali se može direktno stimulirati i kapsaicinom, alkaloidom iz čili paprike. U ljudi je pokazana uloga receptora TRPV-1 u upalnoj i neuropatskoj boli.<sup>19,20</sup> Njihova važnost u nocicepciji je pokazana istraživanjima na transgeničnim miševima. U miševa bez receptora TRPV-1 (TRPV-1  $-/-$ ) pokazana je neosjetljivost na toplinski podražaj ( $> 43\text{ }^\circ\text{C}$ ), dok je u miševa s gubitkom receptora TRPV-4 pokazana neosjetljivost na mehanički podražaj.<sup>21,22</sup>

Receptori TRPV-1 sudjeluju i u patogenezi neurogene upale jer se njihovom aktivacijom izlučuje CGRP iz stimuliranih nociceptora.<sup>23</sup> Do sada su u kliničkim ispitivanjima testirani različiti antagonisti receptora TRPV-1 i TRPV-3 u terapiji različitih vrsta boli.<sup>24</sup> Ostali ionski kanali također sudjeluju u perifernoj senzitivaciji, a navedeni su u tablici 1.



**Tablica 1.** Vrste i podvrste ionskih kanala čiji poremećaj funkcije uzrokuje nastanak različitih vrsta boli (prema ref. Cregg i sur., 2010)<sup>18</sup>

	Vrste ionskih kanala	Podvrste koje sudjeluju u patofiziologiji bolnih stanja	Poremećaj funkcije - kanalopatije
Sudjeluju u detekciji bolnog podražaja	Kapsaicinom aktivirani neselektivni ionski kanal (TRP)	TRPV-1, TRPV-3, TRPV-4	- upalna bol - visceralna bol - neuropatska bol
	Kanali osjetljivi na ATP	P2X3	- neuropatska bol
	Kanali osjetljivi na kiselinu (ASIC)	ASIC-3	- upalna alodinija i hiperalgezija
Sudjeluju u prijenosu bolnog signala	Natrijski (Na <sup>+</sup> )	Na <sub>v</sub> 1.1-1.9	- upalna i neuropatska bol - migrena - sindrom bolnih ruku i nogu
	Kalijski (K <sup>+</sup> )	K <sub>v</sub> 1; TREK-1	- upalna i neuropatska bol
Sudjeluju u izlučivanju neurotransmitora	Kalcijski (Ca <sup>2+</sup> )	Ca <sub>v</sub> 2.1, 2.2, 3.1, 3.2	- upalna i neuropatska bol

### Centralna senzitivizacija

Centralna senzitivizacija u užem smislu je fenomen povećane podražljivosti drugog neurona osjetnog puta. Međutim, ona osim produžene i kraljezničke moždine,<sup>25,26</sup> u širem smislu zahvaća i subkortikalne i kortikalne strukture: talamus, amigdalnu, hipotalamus, parabrahijalne jezgre, periakveduktalnu sivu tvar, superiorne kolikule, prednji cingulatni korteks, prefrontalni korteks.<sup>27,28,29,30,31</sup>

Centralna senzitivizacija predstavlja abnormalno stanje središnjeg dijela nociceptivnog sustava, u kojem je bol posljedica promjena sustava, a ne rezultat djelovanja stvarnog perifernog bolnog podražaja. Nakon nastanka centralne senzitivizacije bol više ne ovisi o prisutnosti, intenzitetu i trajanju perifernog podražaja.

Neuroni mijenjaju fenotip, što znači da reagiraju na razne bezbolne podražaje niskog intenziteta s tendencijom progresivnog povećavanja stvaranja živčanih impulsa (engl. *temporal windup*). To rezultira bihevioralnim fenomenima kao što su: alodinija, odnosno bolna preosjetljivost na bezbolni mehanički podražaj; osjećaj boli dugo nakon prestanka

podražaja (engl. *after pain*); sekundarna hiperalgezija ili bolna preosjetljivost koja se javlja na drugom dijelu tijela od mjesta bolnog podražaja.<sup>32</sup>

Nastanak centralne senzitivacije može potaknuti samo bolni podražaj dovoljnog intenziteta i trajanja koji stimulira aferentna C-vlakna, kao što su: opetovani toplinski podražaj (> 49 °C),<sup>25</sup> električna stimulacija (1 Hz, od 10 do 20 s),<sup>33</sup> kemijski podražaj koji djeluje preko receptora TRPV-1, primjerice podražaj nociceptora formalinom,<sup>34</sup> alil izotiocijanatom (ulje gorušice, engl. *mustard oil*)<sup>35</sup> i kapsaicinom.<sup>36</sup> Također je pokazano da aktivacija mišićnih i zglobnih nociceptora uzrokuje centralnu senzitivaciju mnogo jačeg intenziteta i trajanja od aktivacije kožnih nociceptora.<sup>33</sup>

Centralna senzitivacija se dijeli na:

a) Brzu: posljedica je izlučivanja glutamata, SP-a, CGRP-a i aktivacije unutarstaničnih signalnih putova

Centralnu senzitivaciju karakterizira vezanje glutamata na receptore NMDA. U fiziološkim uvjetima receptor NMDA je blokiran (ovisno o naponu membrane) magnezijevim ionom ( $Mg^{2+}$ ) koji sjedi na receptorskoj pori. U uvjetima pojačane transmisije glutamata, SP-a i CGPR-a, koji uzrokuju dovoljno jaku depolarizaciju membrane,  $Mg^{2+}$  je istisnut iz pore. Na tako slobodan receptor sada se mogu vezati glutamat i glicin (koaktivacija s dva liganda), što uzrokuje povećano stvaranje akcijskog potencijala i rezultira povećanom staničnom ekscitabilnošću i sinaptičkom efikasnošću. Također aktivacija receptora NMDA dovodi do povišene koncentracije unutarstaničnog  $Ca^{2+}$  koja aktivacijom enzima NO sintetaze uzrokuje povećano stvaranje NO i aktivacije unutarstaničnih signalnih putova preko cikličkog gvanozin monofosfata (cGMP). Također NO difundira u presinaptičku pukotinu te anterogradno prelazi u centralne okončine perifernih neurona, gdje aktivira cGMP, što rezultira pojačanim izlučivanjem glutamata i SP-a.<sup>37</sup>

Pokazano je da na centralnu senzitivaciju na razini produžene/kralježničke moždine utječe zastupljenost SP pozitivnih neurona.<sup>38</sup> CGPR u procesu centralne senzitivacije potencira učinak SP-a i glutamata te djelujući preko receptora CGRP-1 uzrokuje aktivaciju protein kinaze A (PKA) i protein kinaze C (PKC).<sup>39,40</sup>

Signalni unutarstanični putovi koji sudjeluju u centralnoj senzitivaciji jesu: put preko protein kinaza A i C (PKA, PKC), mitogenom aktivirane protein kinaze (MAPK), CREB (engl. *cAMP response element binding protein*), izvanstanične regulacijske signalne kinaze (ERK 1 i 2). Aktivacija protein kinaza uzrokuje fosforilaciju receptora AMPA i NMDA te više ionskih kanala, čime se dodatno mijenja njihova aktivnost.<sup>41,42</sup>

Također protein kinaze utječu na translokaciju receptora i ionskih kanala (od stanične membrane ili prema njoj), čime se mijenja njihova zastupljenost na staničnoj membrani.<sup>43</sup> Pod djelovanjem ERK i PKC dolazi do smanjene aktivnosti inhibicijskih neurona (GABA), odnosno dezinhibicije.<sup>44</sup>

Opisani procesi nazivaju se posttranslacijske modifikacijske promjene (mijenjaju osnovnu aktivnost neurona) i premda rezultiraju znatnim bihevioralnim fenomenima (alodinija i slično), one su u pravilu ovisne o bolnom podražaju i reverzibilne su.<sup>45,46</sup>

#### b) Odgođenu: posljedica je transkripcijskih promjena

Ako opisane promjene dovoljno dugo potraju i centralna senzitivizacija prijeđe u odgođenu ili kroničnu fazu, pod djelovanjem ERK i CREB-a, ali i drugih kinaza i transkripcijskih faktora (faktor nekroze tumora - TNF, drugih citokina) dolazi do transkripcijskih promjena koje rezultiraju pojačanom ekspresijom gena, poput c-fos i cikloksigenaza-2 (Cox-2).<sup>47</sup> To rezultira translacijom novih receptora, ionskih kanala, protein kinaza i slično, s razvojem dodatne pojačane spontane aktivnosti neurona, koja sve manje ovisi o perifernom bolnom podražaju.

## **1.2. BOL U PODRUČJU GLAVE I VRATA**

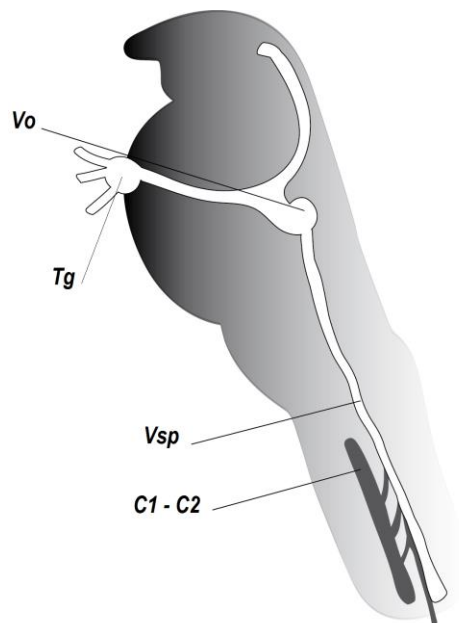
### **1.2.1. Senzorna inervacija glave i vrata**

Trigeminalni živac, V (lat. *nervus trigeminus*) je peti po redu i najveći kranijalni živac koji prenosi somatosenzorni osjet iz područja lica i glave. Sastoji se od perifernih i centralnih vlakna primarnih pseudounipolarnih trigeminalnih neurona čija tijela se nalaze u trigeminalnom gangliju (lat. *ganglion trigeminale*), na području Meckelove šupljine na bazi lubanje.

Centralne trigeminalne senzorne jezgre se nalaze u moždanom deblu i prate se kaudalno u produljenu moždinu te se nazivaju kompleks trigeminalnih jezgara (engl. *trigeminal brain stem nuclear complex*) (slika 2), koji se dijeli na:

a) osnovne senzorne jezgre, Vo (engl. *principal sensory nucleus*) na kojima završavaju primarna nenociceptivna senzorna vlakna trigeminusa (mijelinizirana, velikog promjera, A $\alpha$  i A $\beta$ );

b) spinalne trigeminalne jezgre, Vsp (engl. *spinal trigeminal nucleus*) na kojima završavaju primarna nociceptivna vlakna trigeminusa (vlakna tipa A $\delta$  i C). Vsp je dodatno podijeljen na tri skupine: rostralne, srednje i kaudalne trigeminalne jezgre.<sup>48</sup>



**Slika 2. Centralne trigeminalne senzorne jezgre na razini moždanog debla i produžene moždine s cervikalnim spinalnim jezgrama C1 i C2 (prema ref. Schuenke i sur., 2007)<sup>48</sup>**

*Vo - osnovne trigeminalne senzorne jezgre; Vsp - spinalne trigeminalne jezgre; Tg - trigeminalni ganglij; C1-C2 - cervikalne spinalne jezgre C1 i C2.*

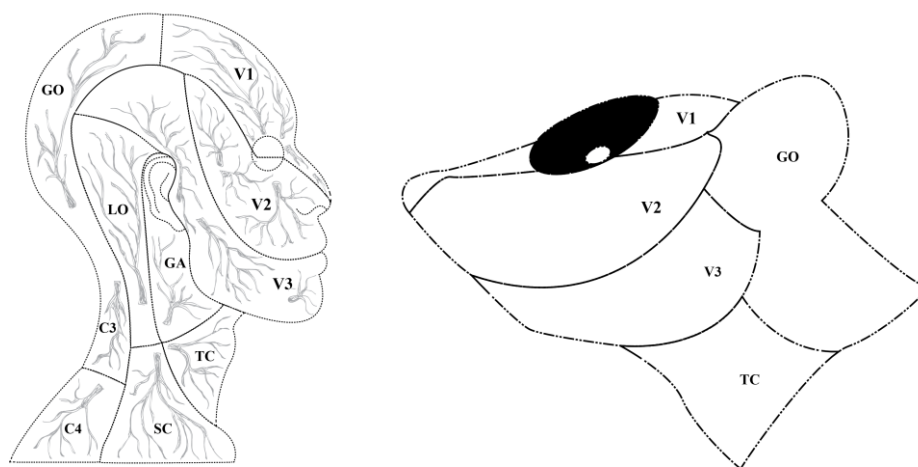
Kaudalne trigeminalne jezgre imaju sličnu histološku i anatomsku organizaciju te fiziološku ulogu u nocicepciji kao dorzalni rog kralježničke moždine. Izolirana lezija kaudalnih jezgri trigemina rezultira parcijalnim do potpunim gubitkom osjeta boli i temperature iz područja lica i glave.<sup>49</sup> Također je pokazano da centralne okončine perifernih trigeminalnih nociceptivnih neurona koje završavaju u kaudalnim i dijelom srednjim Vsp, jesu vlakna koja predominantno sadržavaju neuropeptide SP i CGRP.<sup>50</sup>

TG napuštaju tri senzorne grane trigeminalnog živca koje sadržavaju primarna aferentna vlakna koja inerviraju ekstrakranijalne (dubinske i površinske strukture glave) i intrakranijalne (moždane ovojnice) strukture (tablica 2): oftalmička grana, V1 (lat. *nervus ophthalmicus*); maksilarna grana, V2 (lat. *nervus maxillaris*); mandibularna grana, V3 (lat. *nervus mandibularis*).

**Tablica 2.** *Grane trigeminalnog živca s pripadajućom osjetnom inervacijom ekstrakranijskih struktura (prema ref. Schuenke i sur., 2007)<sup>48</sup>*

GRANE TRIGEMINALNOG ŽIVCA (V)	OSJETNA INERVACIJA EKSTRAKRANIJSKIH STRUKTURA NA GLAVI
V1 - oftalmička	orbita, konjunktiva i kornea oka, korijena i vrha nosa, dio sluznica nosa i frontalnog sinusa, koža gornjeg kapka i frontalnog i parijetalnog dijela glave
V2 - maksilarna	dio sluznice nosa te maksilarnog, etmoidnog i sfenoidnog sinusa, gornja čeljust i zubi, koža donjeg kapka i baze nosa te gornje usne i srednjeg dijela lica
V3 - mandibularna	donja čeljust i zubi, sluznica jezika i usne šupljine, koža donje usne, dijela vrata i prednjeg dijela uške

Područja kutane senzorne (dermatomi) inervacije područja glave i vrata inervirane pojedinim granama trigeminusa (i ostalih senzornih živaca) dobro su ograničena, za razliku od ostalih dijelova tijela (slika 3).



**Slika 3.** *Područja kutane senzorne inervacije (dermatomi) u čovjeka i štakora na glavi i vratu (modificirano prema <http://www.youmedicine.arduanet.it/index.php/en/youmedicine-flash/899-peripheral-nerve-fields>)*

V1 - oftalmička grana trigeminusa; V2 - maksilarna grana trigeminusa; V3 - mandibularna grana trigeminusa; GO - veliki okcipitalni živac; LO - mali okcipitalni živac; TC - transverzalni cervikalni živac; GA - veliki aurikularni živac; SC - supraklavikularni živac

Stražnji dio glave i vrata prima senzornu inervaciju preko stražnjih grana prvih triju cervikalnih spinalnih živaca (C1-C3); subokcipitalni živac, C1 (lat. *nervus suboccipitalis*); veliki okcipitalni živac, C2 (lat. *nervus occipitalis major*); treći okcipitalni živac, C3 (engl. *third occipital nerve*) (slika 3, tablica 3). Tijela primarnih senzornih cervikalnih

pseudounipolarnih neurona se nalaze u ganglijima stražnjih korjenova (engl. *dorsal root ganglion*). Centralne okončine tih neurona čine stražnje spinalne korjenove koji završavaju na centralnim spinalnim jezgrama koje se za C1 i C2 nalaze u produljenoj moždini i kranijalno se nastavljaju na kaudalne spinalne jezgre trigeminusa i čine trigemino-cervikalni kompleks jezgri (engl. *trigemincervical complex*). Kaudalno se centralne spinalne jezgre C1 i C2 nastavljaju na stražnji rog kralježničke moždine, gdje završavaju ostale centralne okončine cervikalnih živaca (C3 - C8).<sup>48</sup>

Prednji dio vrata i dio uške primaju senzornu inervaciju od cervikalnog plexusa (lat. *plexus cervicalis*), koji čine prednje grane prvih četiriju cervikalnih spinalnih živaca (C1 - C4). Najveća grana cervikalnog plexusa je veliki aurikularni živac (C2 i C3) (lat. *nervus auricularis magnus*) (slika 3, tablica 3).

**Tablica 3.** Cervikalni osjetni živci s pripadajućom osjetnom inervacijom ekstrakranijalnih struktura na glavi i vratu (prema ref. Schuenke i sur., 2007)<sup>48</sup>

		Osjetna inervacija kože i dubokih struktura
<b>Stražnje grane cervikalnih živaca</b>	Subokcipitalni živac, C1	stražnjeg parijetalnog i okcipitalnog dijela glave
	Veliki okcipitalni živac, C2	
	Treći okcipitalni živac, C3	stražnjeg dijela vrata

		Osjetna inervacija kože i dubokih struktura
<b>Cervikalni plexus, prednje grane cervikalnih živaca C1-C4</b>	Veliki aurikularni živac, C2-C3	uške i zvukovoda
	Transverzalni cervikalni živac, C2-C3	prednje regije vrata
	Mali okcipitalni živac, C2-C3	stražnjeg dijela uške i dijela oglavka
	Supraklavikularni živac, C3-C4	supraklavikularna regija vrata

## 1.2.2. Glavobolje

### 1.2.2.1. Definicija i klasifikacija glavobolja

Glavobolja je definirana kao svaka bol u području glave i vrata koja nastaje aktivacijom nociceptora ekstrakranijalnih (koža, mišići, živci, arterije i vene, konjuktiva, sluznice, periost) i/ili intrakranijalnih (moždane ovojnice, živci, arterije i vene) struktura.<sup>51</sup>

Glavobolje su heterogena skupina neuroloških poremećaja. U skladu s time Međunarodno društvo za glavobolje, IHS (engl. *International Headache Society*), sastavilo je klasifikaciju glavobolja, strukturiranu kao hijerarhijski sustav gdje su glavobolje podijeljene u tri velike grupe.<sup>52</sup> Svaka grupa glavobolja je prema strogim dijagnostičkim kriterijima podijeljena u tipove, podtipove i forme (tablica 4).

Tri glavne grupe glavobolja su primarne, sekundarne i kranijalne neuralgije.

**Tablica 4.** Internacionalna klasifikacija glavobolja 3-beta s glavnim grupama i tipovima glavobolja (prema ref. *Headache Classification Committee, 2013*)<sup>52</sup>

Internacionalna klasifikacija glavobolja 3-beta

Glavne grupe glavobolja (ICHD 3-Beta)	Dijagnostički kriterij	Glavni tipovi glavobolja
Primarne glavobolje	svaki tip glavobolje ima specifičnu simptomatologiju	1 Migrena 1.1 Migrena s austom 1.2 Kronična migrena 1.3 Komplikacije migrene 1.4 Vjerojatna migrena 1.5 Sindromi povezani sa migrenom
	nepoznati etiološki čimbenici koji su ih uzrokovali	2 Tenzijska glavobolja 3 Klaster glavobolja i Trigeminalne autonomne glavobolje 4 Druge primarne glavobolje
Sekundarne glavobolje (uzrokovane*)	zasnivaju se prema specifičnom uzroku koji je doveo do glavobolje	5 *tumorima glave i vrata 6 *vaskularnih poremećajima glave i vrata 7 *nevaskularnim intrakranijalnim poremećajima 8 *substancijama ili odvikavanjem 9 *infekcijama 10 *poremećajima homeostaze
	simptomi mogu odgovarati bilo kojem tipu primarnih glavobolja	11 *poremećajima glave, vrata, očiju, nosa, sinusa, zubiju, usta ili drugih struktura na glavi i vratu 12 *psihijatrijskim poremećajima
Kranijalne neuralgije i druge gl.	nastaju zbog stimulacije (kompresija, upala i slično) kranijalnih i cervikalnih specifičnu simptomatologiju	13 Kranijalne neuralgije i centralni uzroci bolova u licu
	glavobolje koje ispunjavaju sve kriterije osim jednog glavobolje se ne mogu svrstati niti u jednu grupu	14 Druge glavobolje, kranijalne neuralgije, centralni ili primarni uzroci boli u licu

Primarne glavobolje su: migrena, tenzijska glavobolja, klaster glavobolja te miješana skupina pod nazivom ostale primarne glavobolje. Svaka od primarnih glavobolja ima specifičnu simptomatologiju i detaljne dijagnostičke kriterije koji moraju biti zadovoljeni. U primarnih glavobolja nepoznati su etiološki čimbenici koji su ih uzrokovali, premda su poznati pojedini prateći patofiziološki mehanizmi.<sup>52</sup>

S druge strane, sekundarne glavobolje su klasificirane prema etiologiji, a ne prema simptomatologiji. Nazivaju se prema specifičnom uzroku koji je prouzročio glavobolju, npr. glavobolja uzrokovana intrakranijalnim tumorom, gdje je uzrok glavobolje intrakranijalni tumor. Za dijagnozu je bitno da se potencijalni uzrok javio u istom razdoblju kao i glavobolja te da su se simptomi glavobolje smanjili ili potpuno nestali u određenom periodu nakon što se taj uzrok uklonio.<sup>52</sup>

Treća velika grupa glavobolja su kranijalne neuralgije, koje nastaju zbog stimulacije (kompresija, upala i slično) kranijalnih i cervikalnih živaca te imaju strogo definiranu simptomatologiju. Nazivaju se atipične ili primarne ako je uzrok stimulacije živca nepoznat, odnosno sekundarne ako je uzrok poznat (npr. infekcija herpes zoster virusom).<sup>52</sup>

#### **1.2.2.2. Teorija konvergencije za primarne glavobolje**

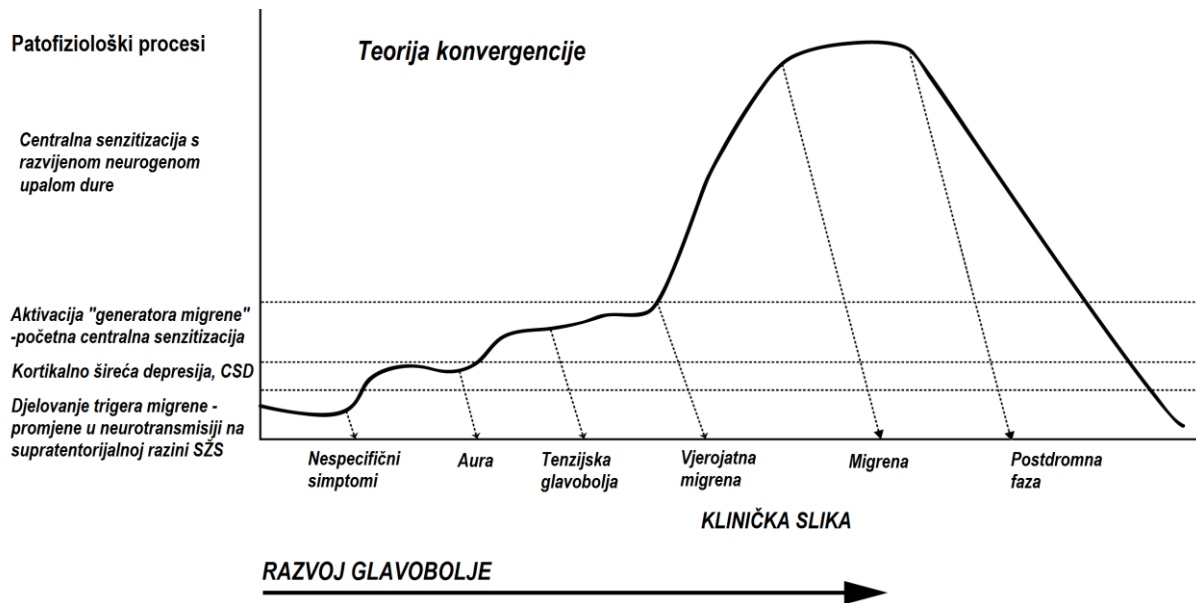
Uz klasifikaciju glavobolja (ICHD III) koja jasno definira razlike između pojedinih tipova primarnih glavobolja,<sup>52</sup> postavlja se pitanje predstavlja li svaka od njih zaseban neurološki poremećaj sa specifičnom patofiziologijom ili je riječ o različitim kliničkim oblicima istih patofizioloških procesa, promatranih u različitoj fazi nastanka.

Ponajprije se govori o dva najčešća tipa primarnih glavobolja, migreni i tenzijskoj glavobolji, koje je u akutnim fazama teško razlikovati i klasificirati prema ICHD III.<sup>53</sup> Vanjski faktori (okidači, „trigeri“) za koje je poznato da mogu uzrokovati napadaj migrene (stres, promjene u režimu spavanja, određene vrste hrane, mirisi, alkohol, menstrualni ciklus), mogu uzrokovati tenzijsku glavobolju.<sup>54</sup> Također postoji sličnost u njihovu odgovoru na specifičnu farmakoterapiju. Cady i suradnici, 2000. godine, su pokazali da je sumatriptan (klasični antimigrenozni lijek) jednako učinkovit u smanjenju boli kod migrene i tenzijske glavobolje.<sup>55</sup> Slična opažanja su potvrđena u kasnijim studijama, gdje je sumatriptan bio učinkovitiji ako su glavobolje bile liječene u ranijoj fazi s razvijenom slabom do srednje jakom boli.<sup>56</sup>

Na temelju navedenih epidemioloških, kliničkih i farmakoloških sličnosti između primarnih glavobolja, Cady i suradnici, 2002. godine, su iznijeli hipotezu zajedničke patofiziologije za primarne glavobolje, nazivajući je teorijom konvergencije za primarne glavobolje (engl. *convergence hypothesis for primary headaches*).<sup>57</sup>



Glavobolju su podijelili u faze: početnu, auru, srednje tešku glavobolju (tenzijska glavobolja i vjerojatna migrena), tešku glavobolju (migrenu) te postdromnu fazu. Svaka faza ima karakterističnu kliničku prezentaciju i patofiziologiju (slika 4).



Slika 4. Teorija konvergencije s patofiziološkim procesima po fazama razvoja glavobolje (prema ref. Cady i sur., 2002)<sup>57</sup>

U početnoj fazi primarnih glavobolja patofiziološki proces je započet djelovanjem vanjskih faktora na SŽS. Smatra se da SŽS pacijenta s predispozicijom za razvoj primarne glavobolje nema razvijene kompenzacijske mehanizme kojima bi se adaptirao na novo stanje nastalo djelovanjem vanjskih faktora. Rezultat su promjene u neurotransmisiji na supratentorijalnoj razini SŽS-a koje se klinički manifestiraju kao promjene u apetitu, promjene raspoloženja, koncentracije i slično. Istraživanja provedena pomoću funkcijskih metoda oslikavanja mozga su pokazala promjene u funkcionalnoj aktivnosti regija mozga pacijenata s migrenom koje uključuju periakveduktalnu sivu tvar, diencefalon, hipotalamus, cerebelum i korteks.<sup>58,59,60</sup> Osim funkcijskih promjena otkrivene su i strukturalne promjene tih regija mozga (smanjenje sive tvari mozga).<sup>61</sup>

Promjene u neurotransmisiji u okcipitalnom korteksu su obilježene kao kortikalne šireće depresije, CSD (engl. *cortical spreading depression*). CSD je val depresije u neuralnoj funkciji mozga koji započinje u okcipitalnom režnju i širi se prema frontalnom režnju mozga, a prethodi mu kratki period neuronalne ekscitacije vrlo sličan epileptičkom napadu.<sup>62</sup> Rezultat

je promjena u membranskoj provodljivosti neurona, a do sada je identificirano nekoliko mutacija ionskih kanala koje uzrokuju nastanak CSD-a u pacijenata s hereditarnom hemiplegičnom migrenom.<sup>63</sup> Klinički CSD-a predstavlja fazu aure koja se očituje kao promjene u vidnom polju (vidni skotomi) i u pravilu prethode fazi boli u glavobolji.

Pretpostavlja se da opisane promjene u kortikalnoj neurotransmisiji rezultiraju promjenama u centralnim silaznim sustavima kontrole boli. Na taj se način aktiviraju različiti dijelovi produžene moždine kao što su spinalne trigeminalne i cervikalne jezgre, periakveduktalna siva tvar, koji se nazivaju generatorima migrene (engl. "*deep brain generator*").<sup>64</sup> Pokrenuti patofiziološki procesi centralne senzitivacije se na toj razini klinički prezentiraju kao blaga do srednje jaka bol, praćena povećanom bolnom osjetljivošću (hiperalgezija) ekstrakranijalnih područja inerviranih trigeminalnim živcem (V1-V3) i cervikalnim živcima (C2-C3). To bi stanje odgovaralo srednje jakoj migreni, odnosno potpuno razvijenoj tenzijskoj glavobolji.<sup>57</sup> Ako se centralna senzitivacija trigeminalnog sustava ne prekine na toj razini (npr. ranijom upotrebom triptana), aktiviraju se duralni nociceptori koji luče neuropeptide CGRP i SP, što uzrokuju neurogenu upalu dure (vidi u tekstu pod: Trigeminovaskularna teorija migrene).<sup>65</sup> To stanje se smatra klinički pravom neurovaskularnom migrenom, s razvijenim srednje jakim do jakim bolovima i razlikuje migrenu od ostalih tipova glavobolje. Pokazano je da neurogena upala dure uzrokuje i podržava daljnju centralnu senzitivaciju na razini centralnih jezgri trigeminusa. Klinički je za tu fazu karakterističan fenomen alodinije, a zbog aktivacije autonomnog živčanog sustava mogu se javiti i simptomi mučnine i povraćanja.<sup>66</sup>

Pretpostavlja se da genetički faktori imaju ulogu i određuju individualnu sposobnost kontrole opisanih procesa centralne senzitivacije. Na taj je način definirano u kojem obliku će se razviti primarna glavobolja, odnosno migrena i tenzijska glavobolja (slika 4). Važno je istaknuti da se bez obzira na tip glavobolje opisani patofiziološki procesi mogu zaustaviti u svakoj od faza te na taj način prevenirati teži oblici kliničke slike.<sup>57,67</sup>

Zanimljivo je također da se migrena i tenzijska glavobolja u određenom postotku "transformiraju", odnosno prelaze u kronični oblik (bol jakog intenziteta koja traje više od 15 dana u mjesecu), kada ih je u pravilu nemoguće razlikovati prema ICHD III jer nestaju ostali popratni simptomi (aura, povraćanje i dr.). Ta vrsta glavobolje još se naziva kronična dnevna glavobolja.<sup>51</sup> Točni patofiziološki procesi koji su prate nisu dovoljno poznati.

### 1.2.2.3. Povezanost migrene s drugim bolnim stanjima u području glave i vrata: postoje li ekstrakranijalni generatori migrene?

Postavlja se pitanje mogu li promjene u ekstrakranijalnim strukturama, npr. ozljede živca, temporomandibularnog zgloba i slično, uzrokovati primarnu senzitivaciju trigeminovaskularnog sustava koja bi rezultirala neurogenom upalom dure (vidi u tekstu pod: Trigeminovaskularna teorija migrene), odnosno postoje li ekstrakranijalni *generatori migrene*. Sekundarne glavobolje, prema ICHD III, mogu biti uzrokovane raznim poremećajima glave i vrata (tablica 4), dok njihova klinička slika može odgovarati bilo kojem tipu primarnih glavobolja, uključujući migrenu. S tim u skladu kao komplikacije kirurških zahvata na glavi i vratu mogu se razviti teži oblici sekundarnih glavobolja.<sup>68</sup> Frakture glave, od kojih frakture sinusa čine 12%, prati razvoj kroničnih oblika glavobolja tipa migrene i tenzijske glavobolje.<sup>69</sup>

Migrenu se od svih primarnih glavobolja u kliničkoj praksi najviše povezuje s bolestima nosa i paranazalnih sinusa (devijacije nosnog septuma, rinosinusitis).<sup>70</sup> Rezultati multicentričnog istraživanja na 2991 pacijentu sa "samoproglášenom" dijagnozom *sinusne glavobolje* pokazali su da više od 80% tih pacijenta ima kriterije za primarnu migrenu (s aurom i bez nje), a dodatnih 8% vjerojatnu migrenu.<sup>71</sup> O povezanosti migrene s bolestima nosa i sinusa govore podaci da kirurško liječenje deformacija nosnog septuma i paranazalnih sinusa može smanjiti intenzitet boli ili dovesti do potpunog gubitka boli u migreni.<sup>72,73,74,75</sup> Smatra se da je patofiziološki početni moment nastanka boli podrijetlom iz nosa i sinusa kontakt nosnih sluznica (devijacija nosnog septuma s lateralnim nosnim zidom), koji uzrokuje nastanak perifernog podražaja u trigeminalnom sustavu. Pretpostavlja se da takav neprekinuti podražaj u dužem periodu može izazvati perifernu i centralnu senzitivaciju trigeminalnog sustava prisutnu u glavobolji.<sup>76</sup> Edem nosne sluznice u upalnim ili alergijskim stanjima, osim što uzrokuje dodatni kontakt sluznice, izvor je imunoloških faktora (IL-1, IL-6), medijatora upale (bradikina, prostaglandina) i neuropeptida (SP, CGRP, VIP), koji mogu dodatno pridonijeti senzitivaciji trigeminalnog sustava te postati rizični faktori za razvoj kronične glavobolje.<sup>77</sup> S tim u skladu su klinička opažanja pogoršanja migrene u vrijeme sezone alergija.<sup>78</sup>

Poremećaji temporomandibularnog zgloba uzrokuju kroničnu bol.<sup>79</sup> Pokazano je da najteži oblici tih poremećaja imaju visok postotak komorbiditeta (do 86% pacijenata) s primarnim glavoboljama, od kojih se posebno ističe migrena.<sup>80</sup> Dodatno se smatra da ti poremećaji mogu biti uzrok kronifikacije migrene.<sup>81</sup> U pretkliničkim istraživanjima je pokazano da upala temporomandibularnog zgloba uzrokuje trigeminalnu senzitivaciju, zbog čega se dovodi u vezu s migrenom.<sup>82</sup> Zanimljivo je da takav oblik upalne boli podrijetlom iz dubokih struktura,

u odnosu na kutanu upalnu bol, rezultira mnogo jačom centralnom senzitivacijom na razini spinalnih jezgri trigeminusa.<sup>83</sup>

U prilog postojanju ekstrakranijalnih generatora migrene govore rezultati kliničkih slučajeva i kontrolirane kliničke studije na 75 pacijenata koji pokazuju da kirurška dekompresija ogranaka trigeminalnog živca i cervikalnih živaca uzrokuje smanjenje boli u migreni.<sup>84,85</sup> Autori smatraju da kod dijela pacijenata s kroničnom migrenom konstrikcija tih perifernih živaca može biti ekstrakranijalni uzrok senzitivacije trigeminovaskularnog sustava.<sup>86</sup>

### **1.3. NEUROGENA UPALA MOŽDANIH OVOJNICA**

#### **1.3.1. Moždane ovojnice**

##### **1.3.1.1. Anatomija i histologija**

Moždane ovojnice (lat. *meninges cerebri*) su anatomske strukture koje obavijaju mozak, a čine ih ukupno tri membrane: meka ovojnica (lat. *pia mater*), paučinasta ovojnica (lat. *arahnioidea mater*), tvrda ovojnica (lat. *dura mater*). Ovojnice štite SŽS (zajedno s cerebrospinalnom tekućinom i kostima lubanje) i stvaraju potporu krvnim žilama mozga te tvore venske sinuse i šupljine ispunjene cerebrospinalnom tekućinom. Kaudalno od foramina magna se nastavljaju na ovojnice kralježničke moždine ili spinalne ovojnice (lat. *meninges medullae spinalis*), koje imaju sličnu ulogu kao i moždane ovojnice, ali se od njih znatno razlikuju (anatomski, histološki, inervacijski).<sup>48</sup>

Pia mater ili meka moždana ovojnica pranja uz i prati konture mozga i kralježničke moždine. Sastoji se od tankog sloja fibroznog tkiva s površinskim slojem masnih stanica, što je čini izrazito tankom i hidrofobnom membranom. Ona oblaže cerebralne krvne žile i formira pialni omotač odnosno perivaskularni prostor, a i sama je dobro vaskularizirana mrežom kapilara. Anatomski se iznad meke ovojnice nalazi subarahnoidni prostor (lat. *spatium subarahnioideum*), koji je odjeljuje od paučinaste ovojnice i u kojem se nalazi cerebrospinalna tekućina. Subarahnoidni prostor se kaudalno nastavlja na kralježnički kanal (lat. *canalis vertebralis*).<sup>87</sup>

Arahnioidea mater ili paučinasta moždana ovojnica se razvija od istog sloja mezenhima kao i pia mater, koji okružuje mozak u embrionalnom razvoju, zbog čega se te dvije ovojnice nazivaju leptomeninge. Paučinasta ovojnica se sastoji od fibrocita i kolagenih vlakana, a za

razliku od meke ovojnice većinom je avaskularizirana. Ona nije čvrsto vezana struktura, već je na svojim dijelovima odnosno filamentima koji se nazivaju arahnoidni trabekuli, spojena s mekom ovojnicom.<sup>87,88</sup>

Dura mater ili tvrda moždana ovojnica još se naziva pahimeningea (grč. *pachymeninx*: *pachy* – debeo, *menix* – membrana). Sastoji se od kolagenih vlakana i fibrocita, proupalnih stanica (tkivni mastociti) (vidi kasnije u tekstu: Proupalne stanice moždanih ovojnica), krvnih žila i perifernih okončina senzornih živaca (vidi kasnije u tekstu: Inervacija moždanih ovojnica). Krvna opskrba dure većinom se odvija preko srednje meningealne arterije (lat. *a. meningea media*). Dura mater se dijeli na dvije topografske cjeline s granicom na foramen magnumu: kranijalnu (lat. *dura mater cranialis*) i kralježničku ili spinalnu duru (lat. *dura mater spinalis*). Anatomski se kranijalna dura sastoji od dva sloja, periostealnog (čvrsto srastao uz lubanjske kosti) i meningealnog (obavija paučinastu ovojnicu), dok se spinalna dura sastoji samo od meningealnog sloja. Dva sloja dure su srasla, osim na dijelovima gdje tvore duralne venske sinuse u koje se dreniraju venska krv iz mozga i cerebrospinalna tekućina. Također meningealni sloj dure se odvaja od periostealnog sloja i tvori podvostručenja koja odjeljuju kranijalnu šupljinu i čine pregrade između dijelova mozga, ujedno pružajući potporu i stabilnost mozgu. Postoje četiri podvostručenja kranijalne dure, orijentirane sagitalno (lat. *falx cerebri* i *falx cerebelli*) i transverzalno (lat. *tentorium cerebelli* i *diaphragma sellae*).<sup>48</sup>

### **1.3.1.2. Inervacija moždanih ovojnica**

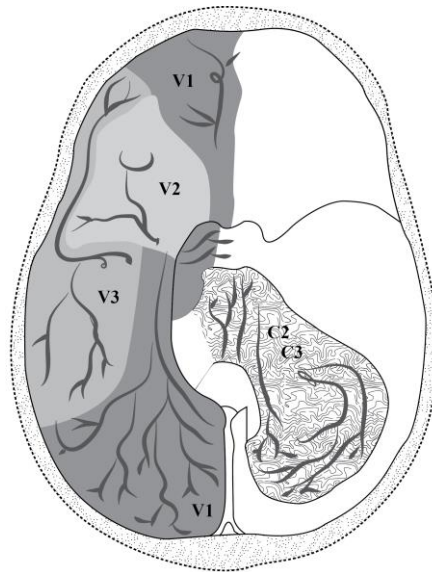
Za patofiziologiju nekih tipova glavobolja, a posebno migrenu, važna je osjetna inervacija moždanih ovojnica, posebno dure, koja je bogato inervirana aferentnim živčanim vlaknima, najvećim dijelom iz trigeminalnog ganglija te manjim iz spinalnih cervikalnih ganglija (C2-C3).<sup>87</sup>

Sve tri grane trigeminalnog živca (V1-V3) nakon odvajanja od TG-a daju intrakranijalne (meningealne) ogranke koji senzorno inerviraju duru. Koristeći se metodom retrogradnog obilježavanja živčanih vlakana, Mayber i suradnici su 1984. godine, uspjeli dokazati da duru prednje lubanjske jame (engl. *anterior cranial fossa*) i svoda lubanje (supratentorijalna dura) inerviraju većinom meningealni ogranaci V1 (meningealni ogranaci etmoidalnih živaca, lat. *nervus ethmoidales*), dok su ogranaci V2 i V3 manjim dijelom zastupljeni.<sup>89</sup> Područje srednje lubanjske jame (engl. *middle cranial fossa*) je senzorno inervirano meningealnim ogranacima V2 i V3, koji su većinom organizirani kao periarterijski pleksusi koji prate srednju

meningealnu arteriju. Tentorium cerebri i stražnji dio falx cerebri (hrv. srpolika mozgovna pregrada) inervira tentorijalni živac, meningealni V1 ogranak.<sup>90</sup> Dura stražnje lubanjske jame (engl. *posterior cranial fossa*) je inervirana senzornim vlaknima koja potječu od spinalnih cervikalnih ganglija C2 i C3, a prenose ih intrakranijalni ogranaci cervikalnih živaca C2 i C3. Također je pokazano da dio tih senzornih vlakana dure (C2 i C3) putuje zajedno s X. i XII. kranijalnim živcima (lat. *nervus vagus* - X; *nervus hypoglossus* - XII) (slika 5).<sup>91</sup>

Simpatička inervacija dure potječe od gornjih cervikalnih simpatičkih ganglija (C2 i C3), čija vlakna putuju zajedno s cervikalnim (C2 i C3) i kranijalnim živcima (X). Simpatička vlakna intrakranijalno formiraju simpatičke pleksuse oko srednje meningealne arterije i njezinih ogranaka te sagitalnog i transverzalnog sinusa ili se nalaze kao slobodni završetci unutar dure. Zanimljivo je da se simpatička vlakna vizualiziraju i oko nakupina duralnih mastocita.<sup>92</sup>

Parasimpatička inervacija je većinom zastupljena u mekoj ovojnici oko intracerebralnih krvnih žila i potječe od otičkog i sfenopalatinalnog parasimpatičnog ganglija, dok u duri nije posebno izražena.<sup>93</sup>



**Slika 5. Senzorna inervacija moždanih ovojnica (prema ref. Schuenke i sur., 2007)<sup>48</sup>**

V1 - oftalmička grana trigeminusa; V2 - maksilarna grana trigeminusa; V3 - mandibularna grana trigeminusa; intrakranijalni ogranaci cervikalnih živaca C2 i C3 grana.

U duralnim senzornim vlaknima (V1-3, C2-3) u najvećem se postotku nalazi neuropeptid CGRP-a, a SP je također visoko zastupljen te ga u pravilu prati. Imunohistokemijski je dokazana bogata mreža CGRP vlakana, posebice oko duralnih krvnih žila (pleksusi), ali i u nevaskularnim prostorima dure (slobodni živčani završetci).<sup>93,94</sup> Danas se smatra da je upravo

CGRP glavni neurotransmiter u procesu meningealne nocicepcije. S druge strane, simpatička vlakna u najvećem postotku sadržavaju neuropeptid Y, dok je u parasimpatičkim vlaknima visoko zastupljen vazoaktivni intestinalni polipeptid, VIP (engl. *vasoactive intestinal polypeptide*).<sup>93,94</sup>

Razni oblici stimulacije dure uzrokuju izlučivanje neuropeptida, što rezultira razvojem neurogene upale dure: električna stimulacija dure;<sup>95</sup> direktna kemijska stimulacija dure (hipertonična otopina, kapsaicin);<sup>96</sup> medijatori upale (npr. interleukini 1 i 6, TNF- $\alpha$ ).<sup>97,98</sup> Također je pokazano da u duri postoje specifični mehanoreceptori (aktiviraju se rastezanjem dure) i termoreceptori. Na temelju prikupljenih dokaza smatra se da polimodalna svojstva duralnih nociceptora čine osnovu patofiziologije raznih tipova glavobolja.<sup>99,100</sup>

### **1.3.1.3. Proupalne stanice moždanih ovojnica**

Mastociti su vrsta stanica imunološkog sustava koje se u fiziološkim uvjetima stvaraju u koštanoj srži te su krvlju transportirane (kao još nezrele stanice) do ciljnih vezivnih tkiva. Pod djelovanjem specifičnih mikrouvjeta u tim tkivima, nezreli mastociti se diferenciraju u "tkivne ili zrele" mastocite. Oni sadržavaju granule s medijatorima upale kao što su histamin, serotonin i prostagladin E te sudjeluju u imunološkim reakcijama.<sup>101</sup> U moždanim ovojnicama se tkivni mastociti nalaze u duri oko krvnih žila, senzornih i autonomnih živčanih završetaka.<sup>92,102,103</sup> Njihova aktivacija (povećanje broja i degranulacija) u štakora rezultat je stimulacije C aferentnih vlakana različitim vrstama podražaja: električna stimulacija trigeminalnog ganglija, kronični stres, odstranjenje gornjih simpatičkih ganglija.<sup>104,105,106,107</sup> Stimulacija degranulacije mastocita ili direktno apliciranje medijatora iz mastocita na duru (histamin, serotonin i dr.) uzrokuje prolongiranu ekscitaciju meningealnih nociceptora te aktivaciju spinalnih jezgri trigeminusa mjerenu kroz c-fos ekspresiju.<sup>108,109</sup> Na membranama duralnih mastocita su pokazani receptori za CGRP,<sup>110</sup> međutim njihova aktivacija ovisi i o prisutnosti receptora NK-1.<sup>111</sup> Stoga se smatra da više različitih vrsta neuropeptida posreduje u aktivaciji mastocita (CGRP, SP, VIP, pituarni adenil ciklaza aktivirajući peptid-38).<sup>112,113,114</sup> U skladu sa svim nalazima danas se smatra da tkivni mastociti sudjeluju u procesima meningealne nocicepcije i neurogene upale dure, odnosno u patogenezi migrene.<sup>101,106,112,115</sup>

### **1.3.1.4. Upala moždanih ovojnica – meningitis**

Meningitis je infektivna upala moždanih ovojnica praćena simptomima glavobolje, ukočenosti vratne muskulature i povraćanjem te promjenama svijesti. Neprepoznat i neliječen meningitis može dovesti do smrtnog ishoda ili komplikacija kao što su gluhoća, sljepoća,

epilepsija, smanjena kognitivna sposobnost. U tablici 5. su navedene najčešće vrste meningitisa (prema uzroku) sa specifičnim nalazom lumbalne punkcije odnosno analize cerebrospinalnog likvora.<sup>116</sup>

**Tablica 5.** Najčešće vrste meningitisa s nalazom analize cerebrospinalnog likvora (prema ref. Bamberger, 2010)<sup>116</sup>

Analiza cerebrospinalnog likvora				
Vrsta (uzrok) meningitisa	Razina glukoze	Razina bjelančevina (mg/dL)	Pleocitoza (broj upalnih stanica po $\mu\text{L}$ )	Postotak neutrofila (%)
Bakterijski	Niska	> 100	> 500	> 80
Virusni	Normalna	< 200	10 – 1000	Rana faza > 50 Kasna faza < 20
Gljivični	Niska	varijabilne	50 – 500	< 30
Tuberkuloza	Niska	> 100	50 – 500	< 30

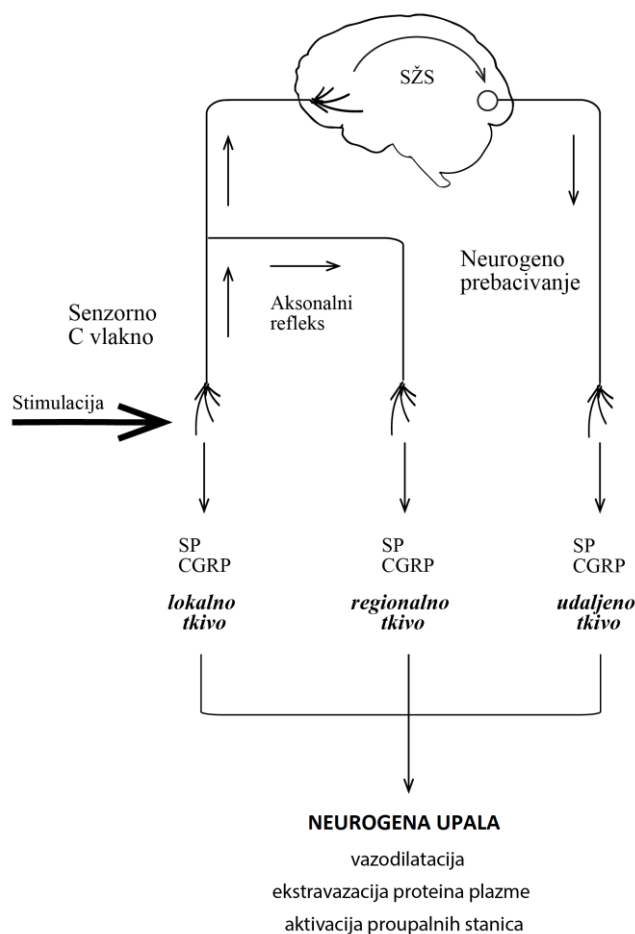
### 1.3.2. Neurogena upala

Neurogena upala je sterilna upala koja se razvija djelovanjem neuropeptida (SP, CGRP, neurokinini A) izlučenih iz perifernih okončina senzornih C-vlakana. Oni se vežu na receptore (NK-1 i CGRP-1) na epitelu krvnih žila (u tkivima kao što su koža, mišići, sluznice, ovojnice) i uzrokuju njihovu povećanu permeabilnost i vazodilataciju, što rezultira ekstravazacijom proteina plazme i upalnih stanica u tkivo, a klinički se manifestira kao lokalna upala.<sup>117,118,119</sup> Smatra se da neurogena upala sudjeluje u patogenezi bolesti kao što su astma, psorijaza, fibromialgija, migrena i druge, međutim uzroci koji dovode do razvoja neurogene upale u tim stanjima nisu dovoljno poznati.<sup>120,121,122</sup>

Primarnu stimulaciju aferentnog C-vlakna uzrokuju razni tipovi podražaja: kemijski iritansi (kapsicin, formaldehid, alkohol, eter, ksilen i dr.), električni podražaj, ozljede neurona itd. Upalne stanice u razvijenoj neurogenoj upali tkiva izlučuju medijatore upale (histamin, serotonin, bradikinin), koji uzrokuju dodatnu stimulaciju perifernih okončina C-vlakana, čime se ostvaruje pozitivna povratna sprega, a sam proces periferne senzitivacije pojačava. Intenzitet neurogene upale ovisi o više parametara, kao što su gustoća C-vlakana u tkivu zahvaćenom upalom; vrsta i koncentracija neuropeptida u C-vlaknima, broju receptora za neuropeptide u tkivu; koncentracija specifičnih enzimskih neuropeptidaza u tkivu.<sup>118</sup>



Neurogena upala može nastati lokalno na mjestu djelovanja podražaja, ali i na udaljenom regionalnom mjestu, što je posljedica širenja živčanog impulsa na aksonske kolaterale podraženog C-vlakna, i naziva se aksonalni refleks (engl. *axonal reflex*).<sup>77</sup> Također, neurogena upala može nastati u udaljenoj regiji tijela, a rezultat je retrogradnog širenja živčanog impulsa prema SŽS-u. On uzrokuje aktivaciju različitih neurona (npr. na glavi su to periferne i/ili centralne jezgre trigeminusa) koja dovodi do posljedičnog anterogradnog širenja impulsa u druga udaljena tkiva, gdje uzrokuje nastanak neurogene upale, što se naziva neurogeno prebacivanje (engl. *neurogenic switching*) (slika 6). Na taj način se objašnjava povezanost stanja kao što su astma ili alergije s migrenom. Također primjer neurogenog prebacivanja je gustatorni rinitis, koji je posljedica aktivacije autonomnog živčanog sustava (simpatikusa i parasimpatikusa) nakon periferne stimulacije C-vlakana. Ta vrsta rinitisa (obilježena simptomima rinoreje, nosne kongestije i znojenja) se javlja nakon uzimanja začinjene hrane, odnosno djelovanja kapsaicina na trigeminalni i autonomni živčani sustav.<sup>123</sup>



**Slika 6. Mehanizam nastanka neurogene upale u lokalnom i regionalnom tkivu te udaljenom dijelu tijela nakon perifernog bolnog podražaja (prema ref. Meggs, 1995)<sup>77</sup>**

### **1.3.3. Trigemiovaskularna teorija migrene**

Migrena je neurološki poremećaj SŽS-a sa simptomima glavobolje koju prati mučnina, povraćanje, vrtoglavica te pojačana osjetljivost na svjetlost, zvukove i mirise.<sup>124</sup> Svjetska zdravstvena organizacija, WHO (engl. *World Health Organisation*), svrstala je migrenu zajedno s demencijom i psihozom u skupinu teških i onesposobljavajućih zdravstvenih poremećaja.<sup>125</sup>

Usprkos intenzivnim istraživanjima migrene unatrag 30 godina njezini patofiziološki mehanizmi nisu do kraja poznati.<sup>126,127,128,129</sup> Migrena je velik dio 20. stoljeća bila definirana kao vaskularna bolest kranijalnih i cerebralnih krvnih žila. U 80-im godinama počinje se istraživati trigeminovaskularni sustav te uloga upale moždanih ovojnica u patofiziologiji migrene. To je rezultiralo nastankom trigeminovaskularne teorije migrene prema kojoj je bol rezultat djelovanja vaskularnih i neuralnih mehanizama, za što danas ima najviše dokaza.<sup>126</sup> Bol nastaje u perifernom dijelu trigeminovaskularnog sustava, odnosno aktivacijom perifernih okončina živaca koji se nalaze oko duralnih krvnih žila. Posljedica aktivacije živaca je izlučivanje neuropeptida (SP, CGRP) s razvojem neurogene upale moždanih ovojnica (dura mater), koja se smatra glavnim i specifičnim patofiziološkim mehanizmom nastanka boli u migreni. Neurogena upala dure karakterizirana je promjenama na duralnim krvnim žilama (vazodilatacija i vazokonstrikcija) koje nastaju djelovanjem CGRP-a, ekstravazacijom proteina plazme predominantno kao posljedica djelovanja SP-a te aktivacijom upalnih stanica u duri pod djelovanjem više vrsta neuropeptida (CGRP, SP, VIP).<sup>130,131</sup>

Razvijena neurogena upala dio je lančane reakcije u kojoj razvijena upala podržava daljnju perifernu (aktivacija primarnih jezgri V u trigeminalnom gangliju) i centralnu (aktivacija centralnih spinalnih jezgri V) senzitivaciju koje se mogu pratiti kroz aktivaciju c-fos gena. Takva pojačana senzitivacija trigeminalnog sustava se klinički očituje kao potpuno razvijeni oblik migrene (vidi u tekstu pod: Teorija konvergencije za primarne glavobolje) u kojemu prevladava bol jačeg intenziteta s razvijenom hiperalgezijom i alodinijom.<sup>132,133</sup>

### **1.3.4. Eksperimentalni modeli aktivacije trigeminovaskularnog sustava**

Pojedine komponente neurogene upale dure i posljedična aktivacija centralnih jezgri trigeminusa su istraživane na eksperimentalnim modelima. U posljednjih 20-ak godina ti modeli, koji se nazivaju i eksperimentalni modeli "migrene" (iako migrena ne postoji u eksperimentalnih životinja), koriste se u pretkliničkim farmakološkim istraživanjima potencijalnih novih antimigrenoznih lijekova.

#### a) Model električne stimulacije trigeminalnog ganglija

Jedno od prvih istraživanja trigeminovaskularne teorije migrene je provedeno na modelu električne stimulacije trigeminalnog ganglija u štakora.<sup>134</sup> Električna stimulacija TG (0,6 mA, 5 m/s, 5 Hz, 5 min) aktivira duralna C-vlakna koja predominantno sadržavaju CGRP i SP, s posljedičnim razvojem neurogene upale dure. Upala je mjerena kao ekstravazacija proteina plazme u tkivu dure pomoću radioaktivno označenog serumskog albumina (<sup>125</sup>I serumski albumin goveda) ili Evansovog modrila.

Ovim modelom promatrana je samo jedna komponenta neurogene upale (ekstravazacija proteina plazme), koja je u pretkliničkim testiranjima služila kao pokazatelj efikasnosti potencijalnih antimigrenoznih lijekova.<sup>135</sup> Međutim, efikasnost u pretkliničkim ispitivanjima ne mora uvijek pretkazati uspjeh u kliničkim ispitivanjima. Naime, pokazano je da specifični blokatori ekstravazacije proteina plazme (antagonisti receptora NK<sub>1</sub>) koji su bili učinkoviti u eksperimentalnom modelu, nisu pokazali očekivanu efikasnost u kliničkim ispitivanjima kao antimigrenozni lijekovi.<sup>136</sup> Time je uloga ekstravazacije proteina plazme kao patofiziološkog mehanizma nastanka boli u migreni dovedena u pitanje, odnosno uloga neurotransmisije preko SP-a, a daljnja istraživanja su se usmjerila na druge komponente upale, odnosno na druge neurotransmitske sustave (CGRP).

#### b) Model električne stimulacije dure

Uloga vazodilatacije duralnih krvnih žila u patogenezi boli u migreni istraživana je na modelu električne stimulacije dure. Pokazano je da taj oblik stimulacije (50 – 300 μA) aktivira duralna Aδ vlakna koja sadržavaju predominantno CGRP, a rezultira razvojem izolirane komponente neurogene upale, duralnom vazodilatacijom. Promjene duralnih krvnih žila su mjerene intravitalnim mikroskopom kroz uski kranijalni prozor.<sup>137</sup>

#### c) Model električne stimulacije sagitalnog sinusa

Ova vrsta stimulacije uzrokuje aktivaciju spinalnih jezgri trigeminusa koja se prati kroz porast električne aktivnosti (metoda mjerenja električnog potencijala pomoću mikroelektroda) te ekspresiju c-fos (metodama imunohistokemije).<sup>138,139</sup> Na modelu je dokazano da triptani (zolmitriptan, naratriptan), dihidroergotamin te antagonisti receptora NK-1 smanjuju aktivnost spinalnih jezgri trigeminusa.<sup>138,140,141,142</sup>

Triptani osim učinka na periferni dio trigeminovaskularnog sustava (vazodilatacija i ekstravazacija) imaju i izravni učinak na spinalne jezgre trigeminusa. Smatra se da ga

ostvaruju djelujući na receptore 5HT<sub>1B/1D</sub> na centralnim okončinama perifernih trigeminalnih živaca.<sup>143</sup> Za razliku od ostalih triptana, sumatriptan ne mijenja aktivnost spinalnih jezgri trigeminusa, što se objasnilo njegovom slabijom penetracijom u SŽS.<sup>139</sup> S druge strane, izostanak učinka na spinalne jezgre trigeminusa moguće je objasniti njegovim slabijim potencijalom kao agonistom receptora 5-HT<sub>1B/1D</sub> u odnosu na zolmitriptan i eletriptan.<sup>144</sup>

#### e) Model intracisternalnog injiciranja kapsaicina

Injiciranje kapsaicina (0,1 ml; 15,25 µg/ml) intracisternalno uzrokuje aktivaciju spinalnih jezgri trigeminusa mjereno kroz c-fos ekspresiju. Na tom modelu je istraživana potencijalna mehanizam djelovanja valproične kiseline u migreni. Pokazano je da valproat smanjuje aktivaciju c-fos u trigeminalnim jezgrama preko receptora GABA-A.<sup>145</sup>

#### f) Model primjene medijatora upale na eksponiranu duru

Apliciranje medijatora upale (histamina, serotonina, bradikinina, prostaglandina E) na eksponiranu duru u štakora uzrokuje aktivaciju spinalnih jezgri trigeminusa. Na tom modelu je dokazano da aktivacija duralnih nociceptora uzrokuje povećanu osjetljivost spinalnih jezgri trigeminusa (klinički se očituje kao hiperalgezija i alodinija) na periferni mehanički podražaj u području lica u štakora.<sup>96</sup>

Na tom modelu je pokazano da sumatriptan ima učinak na više aspekata centralne senzitivacije spinalnih jezgri trigeminusa (na primjer, širinu duralnih receptivnih polja, stopu i veličinu spontanog okidanja akcijskog potencijala i slično) kada je primijenjen u isto vrijeme (rani tretman) kao i medijatori upale na duru. S druge strane sumatriptan nema učinka na centralnu senzitivaciju primijenjen 2 h (kasni tretman) nakon apliciranja medijatora upale. Kao zaključak nameće se da je sumatriptan učinkovitiji u blokiranju indukcije centralne senzitivacije, dok mu je učinak smanjen u uvjetima potpuno razvijene centralne senzitivacije.<sup>146</sup>

Koristeći se ovim modelom, Levy i suradnici, 2004. godine su pokazali da i sumatriptan, kao i ostali triptani, ima centralni učinak (u ranom tretmanu) na spinalne jezgre trigeminusa koji ostvaruje preko presinaptičkih receptora 5HT<sub>1B/1D</sub>, smanjujući neurotransmisiju (CGRP-a, SP-a ili glutamata) između centralnih okončina perifernih trigeminalnih neurona i spinalnih trigeminalnih jezgri.<sup>147</sup>

### 1.3.5. Farmakologija neurogene upale moždanih ovojnica

Korištenjem prije navedenih modela trigeminovaskularne aktivacije otkriveno je da je izlučivanje SP-a predominantno odgovorno za nastanak duralne ekstravazacije, dok CGRP uzrokuje, uz duralnu ekstravazaciju, i vazodilataciju duralnih krvnih žila. Pojedine farmakološke supstancije djeluju na izlučivanje neuropeptida i/ili na njihove posljedice te na taj način blokiraju nastanak neurogene upale moždanih ovojnica.

#### *a) Triptani*

Shepherd i suradnici, 1995. godine, su pokazali da triptani blokiraju duralnu ekstravazaciju djelovanjem na receptore 5-HT<sub>1D</sub> (na okončinama trigeminalnih živaca), što je povezano sa smanjenjem izlučivanja SP-a.<sup>139</sup> S druge strane, blokiranje duralne vazodilatacije se odvija preko aktivnosti na receptore 5HT<sub>1B</sub> i povezano je sa smanjenjem izlučivanja CGRP-a.<sup>148</sup>

#### *b) Ergotamin i dihidroergotamin*

U prvoj farmakološkoj studiji na modelu električne stimulacije trigeminalnog ganglija pokazano je da ergotamin i dihidroergotamin blokiraju ekstravazaciju proteina plazme. Smatra se da ostvaruju mehanizam djelovanja preko presinaptičkog blokiranja izlučivanja vazoaktivnih neuropeptida (SP i NK-1) iz okončina perivaskularnih živaca.<sup>149</sup>

#### *c) Nesteroidni protuupalni lijekovi*

Na modelu električne stimulacije trigeminalnog ganglija pokazano je da indometacin u dozi od 1 mg/kg i acetilsalicilna kiselina (50 mg/kg) smanjuju duralnu ekstravazaciju posredovanu djelovanjem SP-a. Predloženo je da oba lijeka djeluju na promjene u vaskularnoj permeabilnosti i/ili kontraktilnosti glatkih mišića uzrokovanih djelovanjem neuropeptida.<sup>150</sup>

#### *d) Valproat*

Lee i suradnici, 1995. godine, su pokazali da valproat djeluje na duralnu ekstravazaciju blokirajući učinak SP-a, a odvija se preko djelovanja na GABA-A receptore u moždanim ovojnicama. Učinak valproata na duralnu ekstravazaciju je blokiran GABA-A antagonistom, bikukulinom.<sup>151</sup>

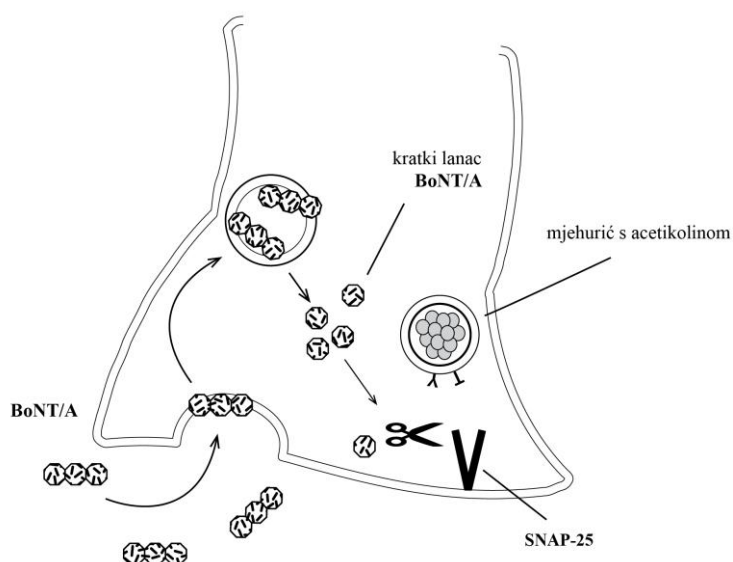
#### e) Morfin

Morfin, selektivni agonist receptora  $\mu$ - $\delta$ ,<sup>152</sup> u eksperimentalnim modelima migrene blokira duralnu ekstravazaciju.<sup>153</sup> Morfin također smanjuje duralnu vazodilataciju presinaptičkim blokiranjem izlučivanja CGRP-a preko  $\mu$  receptora na perifernim trigeminalnim okončinama.<sup>154</sup>

### 1.4. ANTINOCICEPTIVNI UČINAK BOTULINUM TOKSINA TIPA A

Botulinum toksin tipa A (BoNT-A) jedan je od najpotentnijih otrova u prirodi, a rabi se za liječenje mišićne hiperkontraktilnosti.<sup>155</sup> Aktivni toksični dio molekule od 150 kDa prate proteini koji ga štite od proteolitičkog djelovanja i čine kompleks stabilnim.<sup>156</sup> Aktivni dio molekule se sastoji od dva lanca: duži lanac (100 kDa) se veže za transmembranske akceptore i sudjeluje u endocitozi toksina u stanicu; kraći lanac (50 kDa) je cink proteaza koja cijepa sinaptosomalni protein od 25 kilodaltona, SNAP-25 (engl. *synaptosomal associated protein 25 kDa*), koji je dio proteinskog kompleksa SNARE (engl. *soluble N-ethylmaleimid fusion protein attachment protein*) odgovornog za egzocitozu neurotransmitora (slika 7).<sup>155,157</sup>

Uz djelovanje na živčano-mišićnu spojnicu gdje blokira egzocitozu acetilkolina, pokazalo se da BoNT-A na isti način blokira egzocitozu neurotransmitora iz senzornih neurona, zbog čega djeluje na bol. Antinociceptivni učinak pokazan je u eksperimentalnim modelima boli, kao što su upalna bol uzrokovana karagenanom, kapsaicinom, formalinom, dijabetička neuropatija, neuropatija trigeminusa, neuropatija uzrokovana paklitakselom.<sup>158,159,160,161,162</sup> U ljudi je do sada pokazan antinociceptivni učinak BoNT/A u bolnim stanjima kao što su različiti tipovi glavobolja, intersticijski cistitis, kronični artritis, fantomska bol, postoperativna bol, bolne distonije.<sup>163,164,165,166</sup>



**Slika 7. Mehanizam djelovanja botulinum toksina tipa A (prema ref. Turton i sur., 2002)<sup>157</sup>**

*Nakon vezanja za specifične akceptore na membranama neurona, za što je vjerojatno odgovoran dugi lanac, slijedi internalizacija i translokacija biološki aktivnog kratkog lanca BoNT/A u citosol, koji cijepa SNAP-25 protein i tako sprječava egzocitozu acetilkolina.*

O mjestu i mehanizmu antinociceptivnog djelovanja BoNT/A postoje proturječna mišljenja. Prema perifernoj hipotezi, nakon lokalnog injiciranja BoNT/A djeluje na okončine perifernih senzornih živaca: a) blokirajući izlučivanje neurotransmitora i neuropeptida (SP, CGRP) i/ili b) mijenjajući zastupljenost ionskih kanala (TRPV1) na njihovim membranama.<sup>167,168</sup> Posljedica takvog perifernog djelovanja bila bi smanjena transmisija u SŽS.

Središnja teorija pretpostavlja da toksin s mjesta primjene retrogradno putuje u SŽS, gdje smanjuje oslobađanje neurotransmitora iz središnjih grana perifernog aferentnog neurona. U prilog centralnom mjestu djelovanja BoNT/A govore brojni rezultati iz pretkliničkih istraživanja, primjerice bilateralni učinak nakon jednokratne jednostrane primjene u modelima bilateralne boli; primijenjen u spinalni kanal djeluje brže i u nekoliko puta nižim dozama u usporedbi s perifernom subkutanom primjenom; primijenjen periferno BoNT/A putuje retrogradnim aksonalnim transportom u SŽS, gdje cijepa SNAP-25.<sup>169,170,171,172,173</sup>

Primjena BoNT/A u liječenju migrene odobrena je 2010. godine.<sup>174,175</sup> BoNT/A se pokazao učinkovit i kod drugih tipova glavobolja, npr. u tenzijskoj glavobolji, trigeminalnoj neuropatiji, kroničnoj dnevnoj glavobolji.<sup>176,177,178,179</sup> Međutim mehanizam i mjesto djelovanja BoNT/A u tim oblicima glavobolja do sada je nepoznat. Premda postoje brojna istraživanja antinociceptivnog djelovanja u ljudi (s različitim tipovima glavobolja), djelovanje BoNT/A u eksperimentalnim modelima trigeminovaskularne aktivacije do sada nije istraživano. Postoje proturječna mišljenja o mehanizmu i mjestu djelovanja BoNT/A u

migreni, a uključuju perifernu i centralnu hipotezu, kao što je prethodno opisano.<sup>159,180</sup> Nedavnim istraživanjem pokazano je da BoNT/A smanjuje razinu CGRP-a u krvi pacijenata s migrenom, na temelju čega se pretpostavlja da je mehanizam djelovanja u migreni povezan s neurotransmisijom tog neuropeptida.<sup>181</sup>



## **2. HIPOTEZA**

**Na temelju naših preliminarnih pokusa pretpostavljamo da nije samo migrena, već da su i druge boli različitog podrijetla u području inervacije n. trigeminusa praćene neurogenom upalom dure. Pretpostavljamo da će neurogenu upalu smanjiti blokatori izlučivanja neurotransmitora (BoNT/A) i/ili agonisti 5-HT receptora (triptani).**

### **3. CILJEVI RADA**

#### **Opći:**

- rabiti poznate i razviti nove eksperimentalne modele boli u području glave i vrata te istražiti jesu li praćeni neurogenom upalom moždanih ovojnica
- provjeriti sudjelovanje periferne senzitivacije ekstrakranijalnih živaca u centralnoj senzitivaciji neurona, koja se može pratiti preko neurogene upale moždanih ovojnica

#### **Specifični:**

- istražiti je li neurogena upala specifično vezana za određenu vrstu boli, tipa migrene
- razviti eksperimentalni model za ispitivanje učinkovitosti novih antimigrenoznih lijekova u kojem bismo mjerili dva ključna parametra: bol i neurogenu upalu
- ispitati učinkovitost BoNT/A, kao i triptana, u modelima boli u području glave i vrata
- istražiti uključuje li mehanizam djelovanja BoNT/A smanjenje neurogene upale

## 4. MATERIJAL I METODE

### 4.1. ŽIVOTINJE

Korišteni su mužjaci štakora soja Wistar, stari 2 – 3 mjeseca, uzgajani na Zavodu za farmakologiju Medicinskog fakulteta Sveučilišta u Zagrebu. U radu sa životinjama slijedio se Zakon o dobrobiti životinja (Narodne novine 19/1999) te smjernice Internacionalne asocijacije za ispitivanje boli (International Association for Study of Pain, IASP). Za obavljanje pokusa na projektima čijih je ova disertacija dio, dobivena je dozvola Etičkog povjerenstva Medicinskog fakulteta Sveučilišta u Zagrebu (br. 07-76/2005-439) i Ministarstva poljoprivrede Republike Hrvatske (br. 72.3-13, HR 191/02/P). U svakom dijelu pokusa vodilo se računa o dobrobiti životinja. U dijelu eksperimenta koji se odnosi na kirurški zahvat i injiciranje pojedinih ispitivanih supstancija, životinje su bile duboko anestezirane kloralhidratom (u dozi od 300 mg/kg; i.p). Žrtvovanje životinja za potrebe uzimanja uzoraka tkiva obavljalo se letalnom dozom kloralhidrata.

### 4.2. ISPITIVANE SUPSTANCIJE

#### 4.2.1. Botulinum toksin tipa A

U pokusima je korišten botulinum toksin tipa A (BoNT-A) (Botox<sup>®</sup>, Allergan, USA; bočica sadržava 100 internacionalnih jedinica (i.j.) pročišćenog *Clostridium botulinum toxina* tip A; 1i.j. odgovara količini toksina koja nakon i.p. primjene uzrokuje smrt 50% miševa (LD<sub>50</sub> odgovara 0,048 ng). BoNT/A je otopljen u fiziološkoj otopini kako bi se dobile potrebne doze koje su, ovisno o pokusu, bile između 1 i 7 i.j./kg.

U pokusima BoNT/A je primijenjen injiciranjem u:

#### a) Područje brkova štakora

Nakon što je namješten u odgovarajući položaj, u područje brkova (lijeve ili desne strane) štakora s.c. je inicirano (Tuberculin syringe 27G, Becton Dickinson, SAD) 20 µl otopine BoNT/A u dozi od 3,5 i.j./kg. Ispravnost injiciranja provjerena je opipavanjem injiciranog mjesta (mjehurić na mjestu injiciranja).

#### b) Područje temporomandibularnog zgloba štakora

Anesteziranim životinjama je plasirana igla (*Tuberculin syringe* 27G, Becton Dickinson, SAD) kroz kožu ispod donje granice zigomatičnog luka, a iznad gornje granice kondila

mandibule dok nije probila kapsulu TMZ.<sup>82</sup> Ukupno je injicirana otopina 20 µl BoNT/A u dozi od 5 i.j./kg u lijevi TMZ. U pretpokusu se radi provjere lokalizacije u nekoliko životinja injiciralo Evansovo modrilo u zglob. Životinje su žrtvovane supraterepijskom dozom kloralhidrata, a područje zgloba pregledano (boja je bila vidljiva u području TMZ-a).

#### c) Područje plantarne strane šape štakora

Nakon što je namješten u odgovarajući položaj, u plantarnu površinu stražnje desne šape štakora s.c. je injicirano (Tuberculin syringe 27<sub>G</sub>, Becton Dickinson, SAD) 20 µl BoNT/A u dozi od 1, 3,5 i 7 i.j./kg. Ispravnost injiciranja provjerena je opipavanjem injiciranog mjesta (mjehurić na mjestu injiciranja).

#### d) Područje trigeminalnog ganglija štakora

Anesteziranim životinjama je plasirana igla (Hamilton Microliter #701, Hamilton, Bonaduz, Switzerland) kroz kožu u području infraorbitalnog otvora te dalje kroz infraorbitalni kanal sve do foramena rotundum i područja Meckelove šupljine na bazi lubanje gdje se nalazi TG.<sup>182</sup> Ukupno je injicirano 2 µl otopine BoNT/A u dozi od 2 i.j./kg. U pretpokusu je radi točne lokalizacije i.g. injiciranja nekoliko životinja injicirano Evansovim modrilom u ganglij. Životinje su žrtvovane supraterepijskom dozom kloralhidrata, transkardijalno perfundirane fiziološkom otopinom (5 nM) u volumenu od 500 ml. Učinjena je široka kraniotomija s odstranjenjem mozga te vizualizirano modrilo u području trigeminalnog ganglija.

### **4.2.2. Triptani**

U pokusima su korišteni sumatriptan (Imigran<sup>®</sup>, GlaxoSmithKline Pharmaceuticals, Velika Britanija, 50 mg) i zolmitriptan (Zomig<sup>®</sup>, AstraZeneca, Velika Britanija, 2,5 mg), koji su otopljeni u fiziološkoj otopini kako bi se dobila korištena doza od 175 µg/kg koja je aplicirana peroralno, sondiranjem. Korištena doza lijeka je dobivena preračunavanjem na bazi prije upotrebljivanih intravenoznih doza (50 µg/kg), uračunavajući oralnu raspoloživost lijeka (25–30 %) u štakora.<sup>183,184</sup>

### **4.2.3. Morfin**

U pokusima je korišten morfin (Morfinklorid, Alkaloid, Makedonija, 4 mg/ml) koji je injiciran s.c. u područje abdomena štakora u dozi od 8 mg/kg. Korištena doza je uzeta na bazi prijašnjih podataka o analgetskom učinku lijeka, a bez popratnih lokomotornih

nuspojava.<sup>185,186</sup> Za procjenu općeg antinociceptivnog učinka doze lijeka korištena je metoda procjene podizanja repa (engl. *tail-flick*).<sup>187</sup>

#### **4.2.4. Lidokain**

U pokusima je korišten lidokain 2% (Lidokainklorid, Belupo, Hrvatska, 20 mg/ml), koji je injiciran s.c. u područje lijeve strane brkova štakora u volumenu od 20 µl, što odgovara dozi koja je uzeta na bazi ranije korištenih doza lijeka s lokalnim analgetskim učinkom.<sup>188</sup>

### **4.3. KORIŠTENE KEMIKALIJE I REAGENSI**

Za pripremu otopina u pokusima korištene su sljedeće **krute supstancije**: kloralhidrat (Chloral hydrate, Merck KGaA, Njemačka), Evansovo modriilo (Evan's blue, Merck KGaA, Njemačka), kolhicin (Colchicine, Sigma, SAD). Sve supstancije su otopljene u odgovarajućem volumenu fiziološke otopine kako bi se dobile odgovarajuće doze. Od **tekućih supstancija** korišteni su: kompletni Freundov adjuvans (CFA) (Complete Freund's adjuvant cell suspension, Sigma, St. Louis, SAD), formaldehid 35% (Kemika, Hrvatska), etanol 100% i 96% (Kemika, Hrvatska), formamid (Kemika, Hrvatska), eter (Dietil eter, T.T.T, Hrvatska), destilirana otopina.

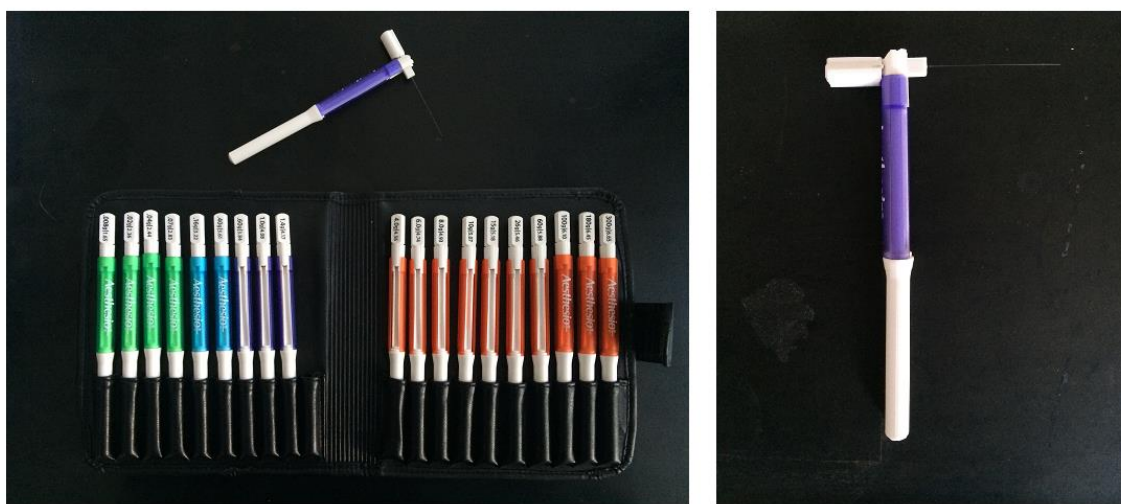Korišteni su sljedeći reagensi u histološkim bojenjima tkiva: hemalaun eozin (HE): hematoksin boja u prahu (Hematoksilini, Natural Blac 1, BSC certificirana, Biognost, Hrvatska), eozin Y boja u prahu (Eozin žučkasti, Acid Red 87, Eosin WS, BSC certificirana, Biognost, Hrvatska); Giemsa: giemsa boja u prahu (Giemsa, BSC certificirana; Biognost, Hrvatska).

### **4.4. BIHEVIORALNI TESTOVI ZA MJERENJE NOCICEPCIJE**

#### **4.4.1. Von Freyevi filament**

Alodinija (bolna osjetljivost na inače bezbolan mehanički podražaj) je ispitivana Von Freyevim filamentima. Životinja je stavljena u prozirni plastični kavez na 10 minuta da se prilagodi eksperimentalnim uvjetima i zauzme normalan položaj (bez njuškanja i kretanja). Dio njuške štakora se stimulirao filamentima različite debljine (različite sile) u rastućem slijedu od 0,16, 0,4, 0,6, 1, 2, 4, 6, 10 do 15 g (slika 8). Mjerila se sila u gramima koja je potrebna da u životinje izazove bolnu reakciju koja je registrirana kao trljanje dijela njuške

životinje i/ili nagli pomaci glave u suprotnu stranu s trzanjem glave. Alodinija u životinja je definirana u slučaju opisane bolne reakcije na pritisak manji od 4 g. Životinje su reagirale na pritisak od 15 g odmakom glave u suprotnu stranu, zbog čega je ta vrijednost uzeta kao maksimalna. Mjerenja su se izvodila na obje strane lica, po tri puta u intervalima od 10 minuta, od čega je za konačnu vrijednost izračunata njihova srednja vrijednost.



Slika 8. Fotografija Von Freyevih filamenata

#### 4.4.2. Metoda pritiska šape po Randallu i Salittu

Hiperalgzija (povećana bolna osjetljivost na bolni podražaj) se mjerila standardnim testom po Randallu i Salittu – metoda pritiska šape (engl. *paw-pressure test*).<sup>189</sup> Aparat za mjerenje načinjen je u našem laboratoriju (prema komercijalnom aparatu Paw-pressure Analgesia Instrument, Ugo Basile, Italija). Nakon što je životinja primljena u odgovarajući položaj, desna stražnja šapa je stavljena na podložak, nakon čega je s njezine dorzalne strane vršen pritisak rastućeg intenziteta. Mjerena je sila kojom klizni uteg pritišće površinu šape od oko 6 mm<sup>2</sup>, koja je radi lakšeg razumijevanja rezultata (a u skladu sa znanstvenom literaturom na engl. jeziku, "*withdrawal threshold*") izražena kao masa u gramima koja je potrebna da izazove bolnost. Odmak šape štakora s podloška registriran je kao bolnost, odnosno izmjerena masa predstavljala je prag bolnog podražaja. Smatralo se da su životinje čiji je prag podražaja bio manji za 35% u odnosu na kontrolu razvile hiperalgziju. Na svakom štakoru mjerenje se izvodilo tri puta u intervalima od 10 minuta, od čega je za konačnu vrijednost izračunata

njihova srednja vrijednost. Mjerenje je prekinuto kod mase od 250 grama kako bi se izbjeglo oštećenje tkiva.

#### **4.5. ODRADIVANJE NEUROGENE UPALE MOŽDANIH I SPINALNIH OVOJNICA**

Neurogena upala je patofiziološki fenomen karakteriziran ekstravazacijom proteina plazme, vazodilatacijom krvnih žila i aktivacijom upalnih stanica u zahvaćenom tkivu.<sup>117</sup>

##### **4.5.1. Mjerenje ekstravazacije proteina plazme**

Izlaženje proteina krvne plazme kroz propusne krvne žile u tkivo (ekstravazacija) rezultira edemom. Jedan od načina mjerenja ekstravazacije je pomoću boje (Evansovo modrilo) koja se veže za albumine u krvi i nakon ekstravazacije se određuje u tkivu. U eksperimentalnim modelima boli u ovoj doktorskoj disertaciji ispitivana je pojavnost neurogene upale moždanih i spinalnih ovojnica.

U anestetiziranih životinja (inhalacijskom anestezijom eterom, u digestoru) je injicirana otopina Evansovog modrila (50 mg/kg, u volumenu od 1 mL) u repnu venu. Nakon 30 minuta od injiciranja životinje su anestetizirane kloralhidratom, torakotomirane i transkardijalno perfundirane fiziološkom otopinom (500 ml). Za prikupljanje moždanih ovojnica perfundirane životinje su kraniotomirane te im je pažljivo odstranjen mozak, čuvajući pritom moždane ovojnice. Prikupljeno je tkivo moždanih ovojnica koje pripada području supratentorijalne dure i dure prednje lubanjske jame. Za prikupljanje spinalnih ovojnica perfundiranim životinjama je eksponirana kralježnica u cijeloj duljini te su odstranjeni dorzalni dijelovi kralježaka. Pažljivo je odstranjena kralježnička moždina, a spinalna dura regija L1 - L5 je prikupljena za analizu.

Duralno tkivo je izvagano (prosječna masa tkiva: kranijalna dura 15 mg; spinalna dura 8 mg) i pohranjeno u 2 mL otopine formamida na 48 h i na temperaturu od 37 °C. U tom periodu i uvjetima Evansovo modrilo se ekstrahira iz tkiva u otopinu formamida. Kolorimetrijska absorbancija ekstrahiranog Evansovog modrila je detektirana spektrofotometrom (Iskra, Ljubljana, Slovenija) na 620 nm. Svakom mjerenju ekstravazacije proteina plazme prethodila je izrada baždarne krivulje absorbancije Evansovog modrila, iz koje se nakon izračunate absorbancije iskazivala masa Evansovog modrila (ng) po masi prikupljenog tkiva dure (mg).

#### 4.5.2. Histološka bojenja moždanih i spinalnih ovojnica

Korištena su klasična histološka bojenja tkiva hemalaun eozinom i Giemsom prema postupcima koji su navedeni u tablici 6.

**Tablica 6.** *Histološki postupak bojenja tkiva hemalaun eozinom i Giemsom*

<b>BOJENJE HEMALAUN EOZINOM</b>	<b>BOJENJE GIEMSOM</b>
Bojenje hematoksilinom - 90 s	Bojenje Giemsom - u 2,5 ml Giemse dodati 47,5 ml destilirane vode pH 7,2
Ispiranje destiliranom vodom	Ispiranje destiliranom vodom
Ispiranje destiliranom vodom	Diferenciranje
Bojenje eozinom 1x	• uroniti stakla kratko u kiselu vodu (par kapi konc. octene kis. u 100 mL dH <sub>2</sub> O)
Ispiranje destiliranom vodom	• 95%-tni alkohol; nekoliko urona
95% etanol - 5x	• 2-propanol; nekoliko urona
Supstitucija za ksilen	• 2-propanol 5'
Ksilen 2'	Bistrenje
Postavljanje pokrovnog stakalca	• ksilen; nekoliko urona
	• ksilen 2'
	Postavljanje pokrovnog stakalca

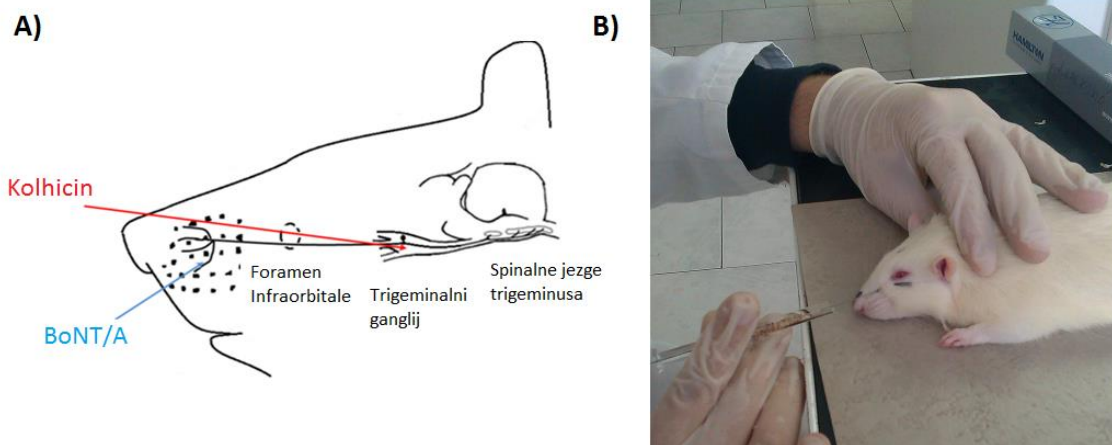
#### 4.5.3. Mjerenje porasta apsolutnog broja stanica u moždanim i spinalnim ovojnicama

Histološki obrađeno (hemalaun eozin ili Giemsa) tkivo moždanih i spinalnih ovojnica je fotografirano te su automatski izbrojeni svi stanični profili zastupljeni u tkivu korištenjem računalnog programa (engl. *CellSens Dimension programme*, Olympus, Japan). Zasebno su analizirana 4 nepreklapajuća vizualna polja po duralnom uzorku, a njihova središnja vrijednost je izračunata za svaku životinju. U skupinama su bile po 4 životinje.

#### 4.6. INHIBICIJA AKSONALNOG TRANSPORTA KROZ TRIGEMINALNI GANGLIJ

U živčanom tkivu kolhicin u malim dozama uzrokuje depolarizaciju tubulina i time sprječava aksonalni transport.<sup>190</sup> Otopina kolhicina u fiziološkoj otopini (5 mM), u volumenu od 2  $\mu$ L, injicirana je u područje lijevog TG-a u postupku istovjetnom onome za injiciranje BoNT/A u ganglij. Kolhicin je injiciran 24 h prije s.c. injiciranja BoNT/A u područje brkova štakora (slika 9). Kontrolna skupina životinja je injicirana fiziološkom otopinom (2  $\mu$ L) u TG.





Slika 9. Shematski (A) i fotografski (B) prikaz injiciranja otopine kolhicina kroz infraorbitalni otvor u trigeminalni ganglij. BoNT/A je injiciran subkutano u područje brkova štakora 24 sata nakon injiciranja kolhicina.

#### 4.7. EKSPERIMENTALNI MODELI BOLI

Za ispitivanje pojavnosti neurogene upale moždanih i spinalnih ovojnica te djelovanje ispitivanih supstancija na nju korišteni su eksperimentalni modeli upalne i neuropatske boli (tablica 7).

Tablica 7. Eksperimentalni modeli upalne i neuropatske boli

Vrsta boli	Eksperimentalni model boli
Upalna bol	Formalinski test CFA upala temporomandibularnog zgloba Parcijalno presijecanje mišića gastroknemijusa
Neuropatska bol	Podvezivanje infraorbitalnog živca (IoNP) Podvezivanje velikog okcipitalnog živca (GoNP) Podvezivanje ishijadičnog živca (INP) Parcijalno presijecanje ishijadičnog živca (INPP)

##### 4.7.1. Formalinski test

Za potrebe pokusa korišten je 35%-tni formaldehid razrijeđen fiziološkom otopinom kako bi se dobile potrebne otopine formalina. Formalin (ovisno o pokusu u koncentraciji od 1%, 2,5%, 5%) je injiciran u volumenu od 50  $\mu$ l, s.c. (Tuberculin syringe 27G, Becton Dickinson, SAD) u područje njuške štakora s lijeve strane. Injiciranje formalina rezultira boli koja je obilježena dvjema fazama. Prva faza testa, koja traje 15 minuta, a posljedica je izravne

stimulacije nociceptora formalinom, predstavlja nociceptivnu bol. Druga faza testa traje između 15 i 60 minuta, u njoj se oslobađaju upalni medijatori i ona predstavlja upalnu bol.<sup>191</sup> Kao pokazatelj boli mjereno je vrijeme trljanja formalinom injiciranog područja brkova.

Formalinskim testom ispitivana je:

a) pojavnost neurogene upale moždanih ovojnica nakon injiciranja otopine formalina 2,5%-tne koncentracije (mjerena kao ekstravazacija proteina plazme); intenzitet neurogene upale (ovisno o različitim koncentracijama otopine formalina - 1%, 2,5%, 5%); duljina trajanja neurogene upale nakon injiciranja otopine formalina u koncentraciji od 2,5% (u vremenu 1/2 sata, 4 sata, 24 sata).

b) antinociceptivni učinak BoNT/A na drugu fazu testa i neurogenu upalu moždanih ovojnica. BoNT/A (20 µL) je injiciran s.c. u dozi od 3,5 i.j./kg u područje lijeve strane njuške tri dana prije injiciranja formalina (2,5%). U pokus je bila uključena i kontrolna skupina životinja, kojoj je umjesto BoNT/A injicirana fiziološka otopina.

#### **4.7.2. Model upale temporomandibularnog zgloba uzrokovane CFA**

Anesteziranim životinjama (kloralhidrat 300 mg/kg) injicirana je otopina CFA (50 µL) i.a. u lijevi TMZ (identičan postupak i.a. iniciranju BoNT/A u zglob). Kontrolne životinje su injicirane i.a. fiziološkom otopinom (0,9%) u zglob. Nakon što su od injiciranja CFA prošla 24 sata, razvila se obostrana alodinija koja je mjerena Von Freyevim filamentima. Do sada je na istom modelu bila pokazana jednostrana alodinija.<sup>82</sup> Nastanak obostrane alodinije u našem pokusu je moguće objasniti intenzitetom razvijene alodinije koja je iznosila približno 90% smanjenja praga boli za razliku od prijašnjih studija (50%-tno smanjenje).

U modelu je ispitivana:

a) pojavnost neurogene upale moždanih ovojnica mjerena kao: ekstravazacija proteina plazme; porast apsolutnog broja proupalnih stanica u duri; karakterizacija specifičnih tipova stanica u duri. U skupinama je bilo 5 – 9 životinja.

b) antinociceptivni učinak BoNT/A te njegovo djelovanje na neurogenu upalu moždanih ovojnica. Sedamdeset dva sata prije i.a. injiciranja CFA u zglob BoNT/A je injiciran: a) i.g. u područje lijevog trigeminalnog ganglija; ili b) i.a. u područje lijevog TMZ-a (kao što je prije opisano u određenim dozama i volumenu).

Kako bi se objasnilo mjesto i mehanizam djelovanja BoNT/A, u dodatnom pokusu injicirana je otopina kolhicina (2  $\mu$ L) 24 h prije BoNT/A u trigeminalni ganglij, a mjerena je učinkovitost BoNT/A na obostranu alodiniju. U skupinama je bilo 5 – 9 životinja.

#### **4.7.3. Model parcijalnog presijecanja mišića gastroknemijusa**

Anesteziranim životinjama je zarezana koža stražnje strane desne natkoljenice u duljini od 3 cm te je učinjena longitudinalna incizija mišića gastroknemijusa (paralelna s mišićnim vlaknima).<sup>192</sup> Koža je zašivena najlonskim koncem (4-0). Kontrolna skupina u ovom modelu bile su netretirane životinje.

U modelu se bol pojavila 24 sata nakon presijecanja mišića (traje do 14 dana). Bol je upalnog karaktera i posljedica je oslobađanja medijatora upale na mjestu ozljede te se koristi kao eksperimentalni model postkirurške boli. Mehaničku hiperalgezu (prag mehaničkog podražaja niži za barem 20% u odnosu na srednju vrijednost kontrole) mjerenu metodom pritiska šape 24 sata nakon ozljede razvilo je 60% životinja, koje su uključene u daljnje ispitivanje.

Na modelu je ispitivan antinociceptivni učinak različitih doza BoNT/A (1 i.j./kg, 3,5 i.j./kg, 7 i.j./kg) na postkiruršku bol (metodom pritiska šape) 6 dana nakon injiciranja u plantarnu stranu stražnje šape životinja. Dodatno je ispitivan učinak BoNT/A u dozi od 3,5 i.j./kg (injiciran u plantarnu stranu stražnje šape) na postkiruršku bol nakon 1, 6, 10 i 14 dana od injiciranja.

U skupinama je bilo 7 – 8 životinja.

#### **4.7.4. Model podvezivanja infraorbitalnog živca**

Anesteziranim životinjama (kloralhidratom 300 mg/kg) je injicirana fiziološka otopina (1 ml) u lijevi medijalni očni kut radi podizanja orbitalnog sadržaja odnosno bolje vizualizacije infraorbitalnog živca. Učinjen je rez kože frontalno u medijalnoj liniji do sredine nosnih kostiju. Zatim je slijedila tupa eksploracija medijalnog dijela orbite kako bi se izolirao intraorbitalni dio infraorbitalnog živca, modificiranom kirurškom tehnikom po Greggu.<sup>193</sup> Živac je podvezan s dvije svilene ligature (debljine 5-0) međusobno razmaknute 2 mm, pazeći pritom da se ne poremeti epineuralna cirkulacija.<sup>194</sup> U kontrolnoj skupini životinja infraorbitalni živac je vizualiziran bez podvezivanja. Orbitalni sadržaj je nježno reponiran, a koža zašivena najlonskim koncem (debljine 4-0).

Podvezivanje infraorbitalnog živca (IoNP) uzrokuje bol u životinja, koja ima dvije faze. U prvih 14 dana nakon podvezivanja živca prisutna je upalna bol (postkirurška bol), koja je

posljedica ozljede tkiva i otpuštanja medijatora upale. U drugoj fazi pokusa (14 dana od podvezivanja) u životinja se razvila neuropatska bol, praćena bilateralnom alodinijom koja je posljedica ozljede živca te se može pratiti u idućih 45 dana.<sup>195</sup> Početna mjerenja Von Freyevim filamentima su učinjena 24 h prije podvezivanja živaca te nakon 14 dana, koliko je potrebno za potpuni razvoj neuropatske boli odnosno alodinije. Životinje koje su razvile bilateralnu alodiniju (definirano kao obostrana bolnost od 0,16 – 4 g, što je iznosilo oko 70% operiranih životinja), uključene su u daljnja ispitivanja.

U modelu je mjerena:

a) neurogena upala moždanih ovojnica (14 dana nakon podvezivanja živaca) kao: ekstravazacija proteina plazme, porast apsolutnog broja proupalnih stanica u duri, a dodatno je određen specifični tip stanica u duri. U skupinama je bilo 5 – 8 životinja.

b) antinociceptivni učinak BoNT/A: BoNT/A je injiciran 14 dana nakon podvezivanja živaca s.c. (20 µL) u dozi od 3,5. i.j./kg u područje brkova ipsilateralno ili kontralateralno u odnosu na ozljedu živca. Ispitivao se učinak BoNT/A na obostranu alodiniju (mjereno: 3., 6., 20., 30. dan nakon injiciranja BoNT/A) i neurogenu upalu moždanih ovojnica (3 dana nakon injiciranja BoNT/A).

U drugom pokusu je zbog istraživanja potencijalnog mjesta i mehanizma djelovanja BoNT/A, kolhicin injiciran (2 µL) 24 h prije BoNT/A u područje TG-a, a mjereno je učinak na obostranu alodiniju i neurogenu upalu. Kontrolna skupina životinja je injicirana fiziološkom otopinom (20 µL) u trigeminalni ganglij. U skupinama je bilo 5 – 8 životinja.

c) učinak raznih tipova analgetika (triptana, morfina, lidokaina, kao što je prije opisano u određenim dozama i volumenu) na alodiniju i neurogenu upalu moždanih ovojnica. U skupinama je bilo 5 – 8 životinja.

#### **4.7.5. Model podvezivanja velikog okcipitalnog živca**

Model podvezivanja velikog okcipitalnog živca, GoNP, je razvijen u našem laboratoriju za potrebe istraživanja ove doktorske disertacije. Anesteziranim životinjama (kloralhidratom 300 mg/kg) je zarezana koža retroaurikularno lijevo s produžetkom na stražnju stranu vrata te je odignuta koža i potkožje. Nakon eksploracije okcipitalne regije vizualiziran je i izoliran veliki okcipitalni živac te su na njega postavljene dvije svilene ligature (debljine 5-0) na 2 mm razmaka, uzimajući pritom u obzir da se ne poremeti perineuralna cirkulacija, kao što je bilo opisano u literaturi.<sup>194</sup> Kožna incizija je zašivena najlonskim koncem (debljine 4-0). U kontrolnoj skupini životinja okcipitalni živac je vizualiziran bez podvezivanja. U prvih 14

dana nakon podvezivanja živca prisutna je upalna bol, nakog čega se razvila neuropatska bol praćena bilateralnom alodinijom. Početna bihevioralna mjerenja Von Freyevim filamentima u području brkova štakora učinjena su 24 h prije podvezivanja i 14 dana nakon podvezivanja živca. Životinje koje su razvile bilateralnu alodiniju (definirano kao obostrana bolnost od 0,16 g do 4 g; iznosilo je oko 70% operiranih životinja), bile su uključene u daljnje ispitivanje. Ispitivanja na modelu su uključivala mjerenje pojavnosti neurogene upale moždanih ovojnica (ekstravazacija proteina plazme u duri metodom Evansovog modrila). U skupinama je bilo 5 – 8 životinja.

#### **4.7.6. Model podvezivanja ishijadičnog živca**

Anesteziranim životinjama (kloralhidratom 300 mg/kg) je zarezana koža stražnje strane desne natkoljenice, a nakon eksploracije regije izoliran je desni ishijadični živac, kao što su u modelu podvezivanja ishijadičnog živca (INP) prvotno opisali Bennett i Xie, 1988. godine.<sup>194</sup> Na živac su postavljene dvije svilene ligature (5-0) na 2 mm razmaka, uzimajući pritom u obzir da se ne poremeti perineuralna cirkulacija. Kožna incizija je zašivena najlonskim koncem (debljine 4-0). Kontrolnoj skupini životinja nakon izoliranja živca nije postavljena ligatura.

Početna mjerenja nocicepcije (metoda pritiska šape po Randallu i Salittu) učinjena su 24 h prije podvezivanja živca te nakon 14 dana, koliko je potrebno za potpuni razvoj neuropatske boli. Mjerenja su obavljana obostrano. Životinje koje su 14 dana nakon podvezivanja živca razvile hiperalgeziju (prag mehaničkog podražaja niži za barem 20% u odnosu na srednju vrijednost kontrole s "lažnim zahvatom", što je iznosilo oko 70% operiranih životinja), uključene su u daljnje ispitivanje.

U modelu je ispitivana:

- a) pojavnost neurogene upale moždanih ovojnica u drugoj fazi pokusa (neuropatska bol), mjerena kao povećana ekstravazacija proteina plazme. U skupinama je bilo 5 – 8 životinja.
- b) pojavnost neurogene upale spinalnih ovojnica mjerena kao ekstravazacija proteina plazme i porast apsolutnog broja proupalnih stanica u spinalnoj duri. U skupinama je bilo 5 – 8 životinja.

#### **4.7.7. Model parcijalnog presijecanja ishijadičnog živca**

Anesteziranim životinjama (kloralhidratom 300 mg/kg) je zarezana koža stražnje strane desne natkoljenice te je nakon eksploracije regije izoliran desni ishijadični živac. Kroz njegovu sredinu je postavljena igla kako bi se točno odredila, a zatim zarezala polovica živca. U kontrolnoj skupini životinja učinjen je "lažni zahvat", nakon izoliranja živac nije zarezan. Kožna incizija je zatvorena najlonskim koncem (debljine 4-0).

Početna mjerenja nocicepcije (metoda pritiska šape po Randallu i Salittu) provedena su 24 h prije ozljede živaca te nakon 14 dana, koliko je potrebno za potpuni razvoj neuropatske boli. Životinje koje su razvile hiperalgeziju (prag mehaničkog podražaja niži za barem 20% u odnosu na srednju vrijednost kontrole s "lažnim zahvatom", što je iznosilo oko 70% operiranih životinja), bile su uključene u daljnje ispitivanje.

U modelu parcijalnog presijecanja ishijadičnog živca (INPP) ispitivana je pojavnost neurogene upale moždanih i spinalnih ovojnica mjerena kao povećana ekstravazacija proteina plazme u duri. U skupinama je bilo 5 – 8 životinja.

#### **4.8. STATISTIČKA OBRADA REZULTATA**

Rezultati pokusa na eksperimentalnim modelima boli na životinjama izraženi su kao aritmetička sredina  $\pm$  standardna srednja pogreška. Nakon analize varijance, razlike između skupina analizirane su Newman-Keulsovim ili Tukeyovim post hoc testom. Kada je bilo primjenjivo, rezultati su analizirani dvosmjernim t-testom (*two-tailed t-test*). Značajne su sve p vrijednosti manje od 0,05 ( $p < 0,05$ ), osim u slučaju višekratnih mjerenja gdje je, uz faktor korekcije, granica značajnosti pomaknuta s uobičajenih 0,05 na 0,01 ( $p < 0,01$ ) ili 0,001 ( $p < 0,001$ ).

## **5. REZULTATI**

### **5.1. DJELOVANJE RAZLIČITIH VRSTA BOLI U INERVACIJSKOM PODRUČJU TRIGEMINALNOG ŽIVCA NA RAZVOJ NEUROGENE UPALE KRANIJALNIH MOŽDANIH OVOJNICA**

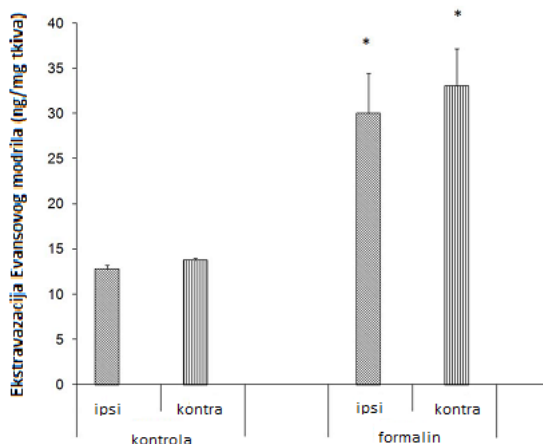
Do sada se neurogena upala dure povezivala s patofiziologijom nastanka boli u migreni. Cilj ovih pokusa je istražiti pojavnost neurogene upale dure nakon različitih vrsta ozljeda na periferiji primarno inerviranoj granama trigeminalnog živca. U tu svrhu koristili smo se različitim eksperimentalnim modelima boli u štakora: upalna (akutna – formalinski test, kronična – injiciranje CFA u temporomandibularni zglob); neuropatska (podvezivanje infraorbitalnog živca). Neurogenu upalu dure smo mjerili kao: povećanu duralnu ekstravazaciju proteina plazme metodom Evansovog modrila; infiltraciju proupalnih stanica u duri metodama bojenja tkiva hemalaun eozinom i Giemsa (s dodatnom karakterizacijom tipova stanica).

#### **5.1.1. UPALNA BOL**

##### **5.1.1.1. Formalinski test**

Formalinskim testom se ispitivao utjecaj upalne boli (druga faza testa, 15 – 60 minuta) uzrokovane injiciranjem formalina (2,5%, 50 µl) u područje brkova lijeve strane lica štakora na razvoj neurogene upale kranijalnih moždanih ovojnica, ipsilateralno i kontralateralno u odnosu na injiciranje formalina.

Za određivanje neurogene upale u kranijalnoj duri koristila se metoda mjerenja ekstravazacije proteina plazme Evansovim modrilom. Pokazano je da je upalna bol u formalinskom testu praćena razvojem obostrane neurogene upale kranijalnih moždanih ovojnica (ipsi i kontra) (slika 10).

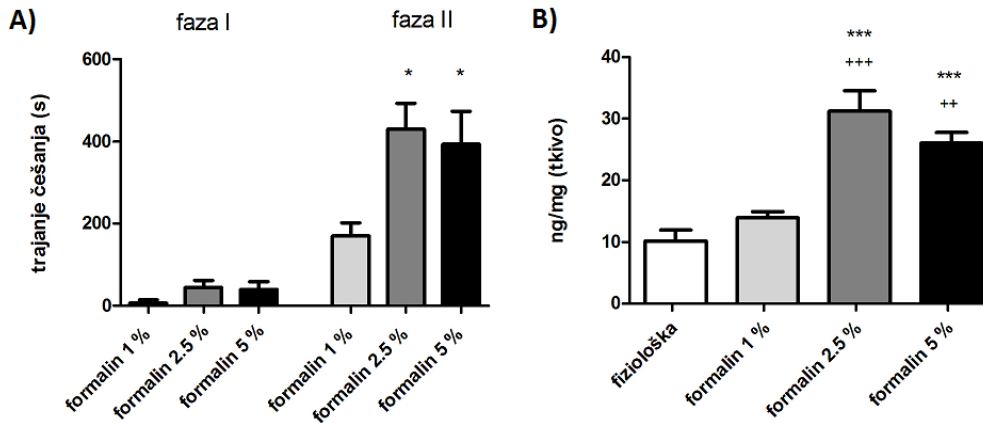


**Slika 10. Upalna bol uzrokovana unilateralnim injiciranjem formalina u područje brkova štakora praćena je bilateralnom neurogenom upalom kranijalnih moždanih ovojnica (prema ref. Filipović i sur., 2012)<sup>227</sup>**

Neurogena upala dure je uzrokovana injiciranjem formalina u područje brkova štakora (2,5%-tni formalin, 50  $\mu$ L), a mjerena je količina Evansovog modrila u duralnom tkivu, koje je podijeljeno na ipsilateralnu i kontralateralnu stranu u odnosu na stranu injiciranja formalina u lice štakora. Analizirani uzorak se sastojao od spojenih duralnih uzoraka tkiva četiriju životinja. Ipsi - duralno tkivo ipsilateralno u odnosu na injiciranje formalina; kontra - duralno tkivo kontralateralno u odnosu na iniciranje formalina; formalin - životinje injicirane formalinom; kontrola - životinje injicirane fiziološkom otopinom. Rezultati su prikazani kao aritmetička sredina Evansovog modrila mjenenog u ng po mg duralnog tkiva  $\pm$  standardna srednja pogreška;  $n = 4$  ( $n$  - broj uzorka po skupini); \* $p < 0,05$  u usporedbi s kontrolom (Newman-Keulsov post hoc test).

U formalinskom testu se ispitivao utjecaj različitih koncentracija otopine formalina (1%, 2,5%, 5%) na razvoj neurogene upale moždanih ovojnica (mjerena ekstravazacija Evansovog modrila u duri). Pokazano je da se upalna bol u drugoj fazi formalinskog testa javlja pri koncentraciji formalina od 2,5% i 5% (uzrokuje bolno češanje injiciranog područja mjereno u sekundama) (slika 11). Koncentracija formalina od 1% nije rezultirala razvojem neurogene upale, dok je najveći intenzitet neurogene upale moždanih ovojnica dobiven koncentracijom formalina od 2,5%.

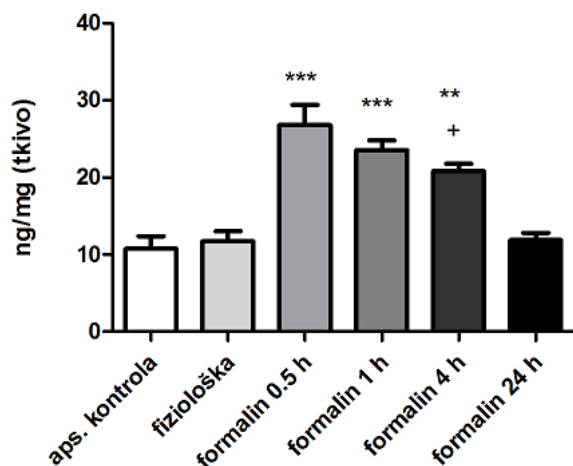




**Slika 11. Utjecaj različitih koncentracija formalina na razvoj boli i neurogene upale moždanih ovojnica**

A) Injiciranje otopine formalina u područje brkova štakora u koncentraciji od 2,5% i 5% (50  $\mu$ L) uzrokuje bolno češanje (u sekundama) injiciranog područja u drugoj fazi formalinskog testa. B) Koncentracija formalina od 1% (50  $\mu$ L) nije rezultirala razvojem neurogene upale dure. Najveći intenzitet neurogene upale je uzrokovan injiciranjem otopine formalina od 2,5% (50  $\mu$ L) (mjerena je ekstravazacija Evansovog modrila u duralnom tkivu). Legenda: Fiziološka: skupina životinja u kojih je injicirana fiziološka otopina (50  $\mu$ L) u područje brkova. Formalin 1%: skupina životinja u kojih je injicirana otopina formalina (50  $\mu$ L) u koncentraciji od 1% u područje brkova. Formalin 2,5%: skupina životinja u kojih je injicirana otopina formalina (50  $\mu$ L) u koncentraciji od 2,5% u područje brkova. Formalin 5%: skupina životinja u kojih je injicirana otopina formalina (50  $\mu$ L) u koncentraciji od 5% u područje brkova. A) Mjereno je trajanje češanja (u sekundama) područja brkova nakon injiciranja formalina u koncentraciji od 1%, 2,5%, 5% (50  $\mu$ L) u područje brkova. B) Mjerena je količina Evansovog modrila izdvojenog iz duralnog tkiva (ng po mg duralnog tkiva). Rezultati su prikazani kao aritmetička sredina  $\pm$  standardna srednja pogreška; n = 6 (n - broj uzorka po skupini); \*p < 0,05 u usporedbi s formalinom 1%; \*\*\*p < 0,001 u usporedbi s fiziološkom; ++p < 0,01 u usporedbi s formalinom 1%; +++p < 0,001 u usporedbi s formalinom 1% (one way ANOVA, Newman-Keulsov post hoc test).

Također se u formalinskom testu ispitivala duljina trajanja neurogene upale moždanih ovojnica nakon injicirana otopine formalina 2,5% (50  $\mu$ L) u područje brkova. Koristila se metoda mjerenja ekstravazacije Evansovog modrila u duri nakon 1/2 h, 1 h, 4 h i 24 h. Najveći intenzitet neurogene upale dobiven je 1/2 h i 1 h od injiciranja formalina, a nakon 4 sata neurogena upala je dalje bila mjerljiva. Dvadeset četiri sata nakon injiciranja neurogena upala više nije bila prisutna u tkivu dure (slika 12).



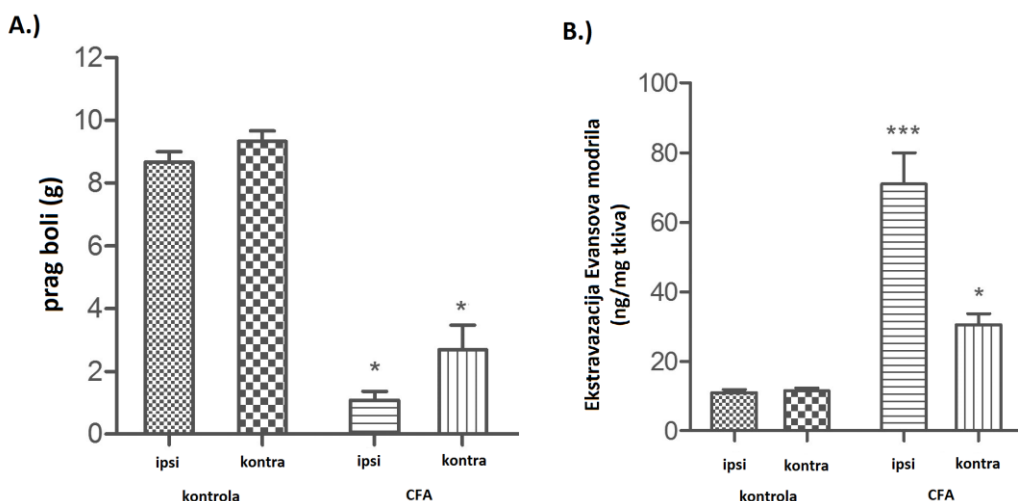
**Slika 12. Duljina trajanja neurogene upale moždanih ovojnica nakon injiciranja otopine formalina u područje brkova**

Otopina formalina koncentracije 2,5% (50  $\mu$ L) injicirana je u područje brkova, a neurogena upala moždanih ovojnica je mjerena nakon 1/2 h, 1 h, 4 h i 24 h (mjerena je ekstravazacija Evansovog modrila u duralnom tkivu). Legenda: Aps. kontrola: skupina životinja koja nije bila tretirana. Fiziološka: skupina životinja u kojih je injicirana fiziološka otopina (50  $\mu$ L) u područje brkova. Formalin 1/2 h: skupina životinja u kojih je injicirana otopina formalina (50  $\mu$ L) u koncentraciji od 2,5% u područje brkova, a mjerena je neurogena upala nakon 1/2 h. Formalin 1 h: skupina životinja u kojih je injicirana otopina formalina (50  $\mu$ L) u koncentraciji od 2,5% u područje brkova, a mjerena je neurogena upala nakon 1 h. Formalin 4 h: skupina životinja u kojih je injicirana otopina formalina (50  $\mu$ L) u koncentraciji od 2,5% u područje brkova, a mjerena je neurogena upala nakon 4 h. Formalin 24 h: skupina životinja u kojih je injicirana otopina formalina (50  $\mu$ L) u koncentraciji od 2,5% u područje brkova, a mjerena je neurogena upala nakon 24 h. Mjerena je količina Evansovog modrila izdvojenog iz duralnog tkiva (ng po mg duralnog tkiva). Rezultati su prikazani kao aritmetička sredina  $\pm$  standardna srednja pogreška;  $n = 6$  ( $n$  - broj uzorka po skupini); \*\*\* $p < 0,001$  u usporedbi s fiziološkom; \*\* $p < 0,01$  u usporedbi s fiziološkom; + $p < 0,001$  u usporedbi s formalinom 1/2 h (one way ANOVA, Newman-Keulsov post hoc test).

### 5.1.1.2. Upalna bol temporomandibularnog zgloba uzrokovana CFA

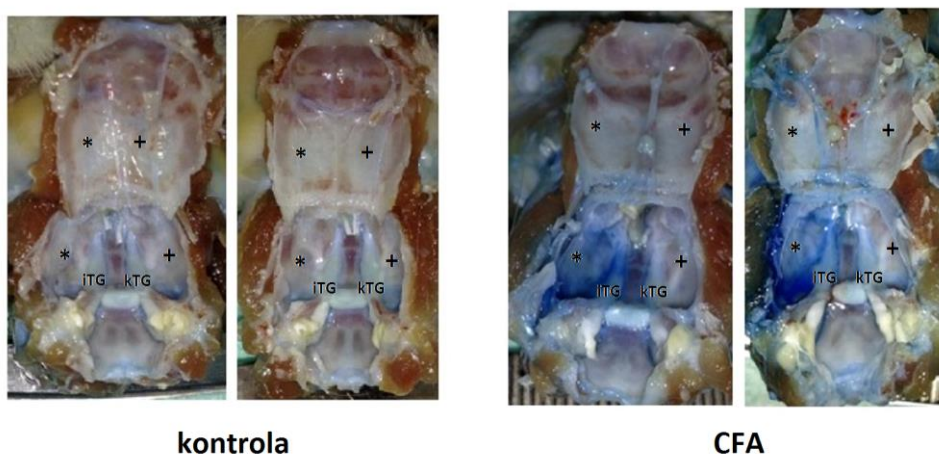
U modelu se ispitivao utjecaj jednostrane upalne boli zgloba (24 sata nakon injiciranja CFA u lijevi TMZ) na razvoj neurogene upale kranijalnih moždanih ovojnica. Neurogena upala u kranijalnoj duri utvrđena je mjerenjem ekstravazacije proteina plazme Evansovim modrilom te histološkim bojenjem tkiva dure (Giemsa) s ciljem određivanja ukupnog broja stanica.

Jednostrano injiciranje CFA u TMZ štakora dovodi do razvoja obostrane mehaničke alodinije (mjereno Von Freyevim filamentima) u području brkova štakora (slika 13 A), ali i do razvoja neurogene upale kranijalnih moždanih ovojnica s obje strane (slika 13 B, slika 14). Primijećen je porast ekstravazacije proteina plazme u kranijalnoj duri, koji je dvostruko veći s ispilateralne (strana injiciranja CFA) u odnosu na kontralateralnu stranu (slika 13 B).



**Slika 13. Upalna bol uzrokovana injiciranjem CFA u područje lijevog temporomandibularnog zgloba praćena je razvojem obostrane alodinije i neurogene upale kranijalnih moždanih ovojnica (prema ref. Lacković i sur., 2015)<sup>205</sup>**

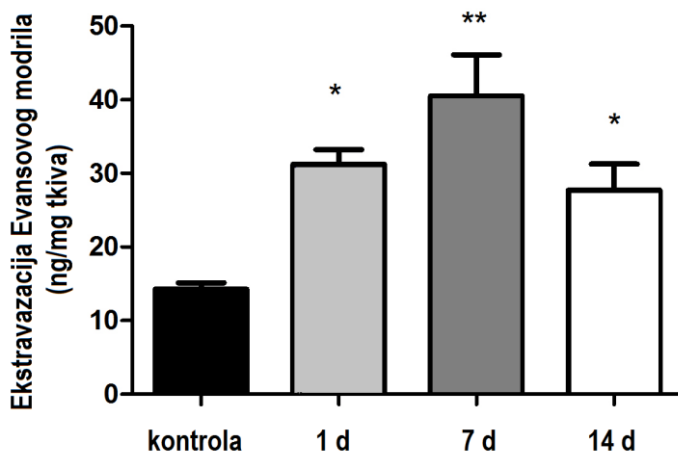
Upalna bol u zglobu je uzrokovana injiciranjem CFA (50  $\mu$ L) u područje lijevog TMZ-a. Dvadeset četiri sata nakon injiciranja CFA A) Mjerena je sila u gramima, koja je dovela do trljanja lica štakora tj. odgovora na mehanički podražaj uzrokovan Von Freyevim filamentima. B) Mjerena je količina Evansovog modrila izdvojenog iz duralnog tkiva (ng po mg duralnog tkiva) koje je podijeljeno na ipsilateralnu i kontralateralnu stranu u odnosu na upalu zgloba (CFA injiciranje). Legenda: A; ipsi - ipsilateralna strana lica u odnosu na injiciranje CFA; kontra - kontralateralna strana lica u odnosu na injiciranje CFA. B; ipsi - duralno tkivo ipsilateralno u odnosu na injiciranje CFA; kontra - duralno tkivo kontralateralno u odnosu na injiciranje CFA; CFA - životinje injicirane CFA u lijevi TMZ; kontrola - životinje injicirane fiziološkom otopinom u lijevi TMZ. Rezultati su prikazani kao aritmetička sredina  $\pm$  standardna srednja pogreška; n = 5 - 9 (n - broj životinja po skupini); \*p < 0,001, \*\*\*p < 0,05 u usporedbi s kontrolom (one-way ANOVA, Newman-Keulsov post hoc test).



**Slika 14. Neurogena upala kranijalnih moždanih ovojnica kao posljedica upale temporomandibularnog zgloba uzrokovane jednostranim injiciranjem CFA (prema ref. Lacković i sur., 2015)<sup>205</sup>**

Fotografije su učinjene nakon perfuzije fiziološkom otopinom te odstranjenja moždanog tkiva. Legenda: CFA - životinje injicirane CFA u lijevi TMZ; kontrola - životinje injicirane fiziološkom otopinom u lijevi TMZ; \* dura - ipsilateralno u odnosu na injiciranje CFA; + dura - kontralateralno u odnosu na injiciranje CFA; iTG - trigeminalni ganglij ipsilateralno u odnosu na injiciranje CFA; kTG - trigeminalni ganglij kontralateralno u odnosu na injiciranje CFA.

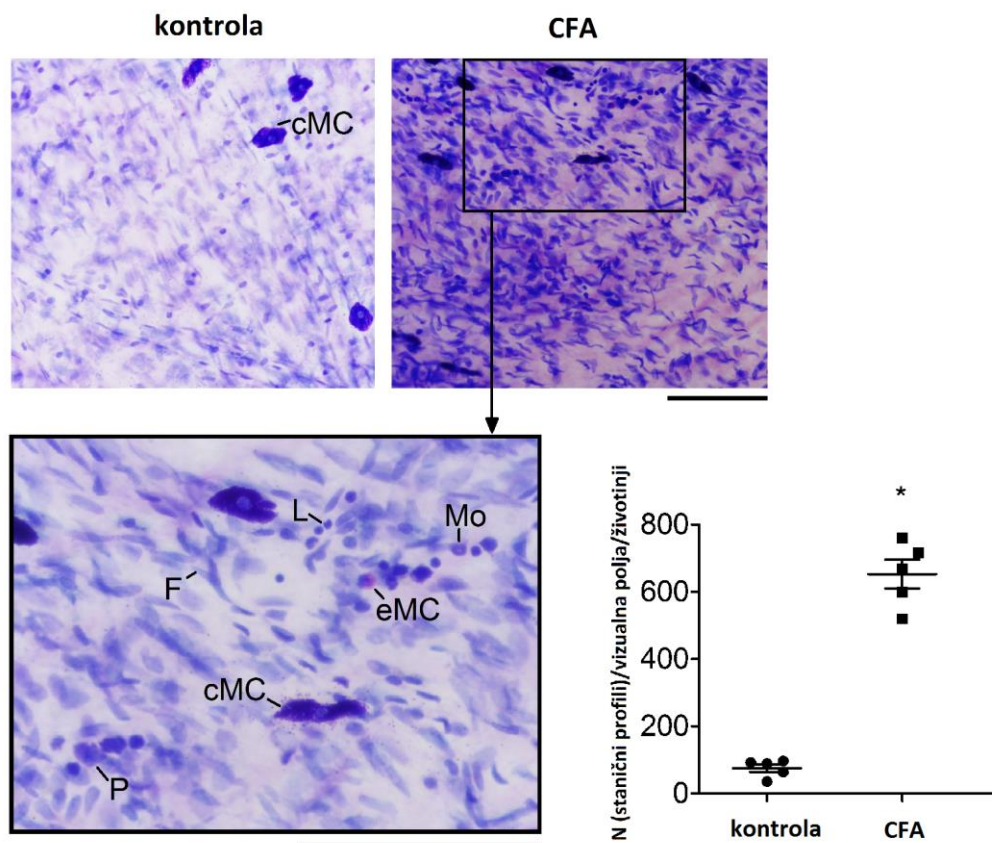
U dodatnom pokusu ispitivala se duljina trajanja neurogene upale moždanih ovojnica nakon injiciranja otopine CFA (50  $\mu$ L) u područje lijevog TMZ-a. Koristila se metoda mjerenja ekstravazacije Evansovog modrila u duri nakon 1, 7 i 14 dana. Najveći intenzitet neurogene upale dobiven je 7 dana od injiciranja CFA. Četrnaest dana nakon injiciranja neurogena upala je i dalje bila prisutna (slika 15).



**Slika 15. Duljina trajanja neurogene upale moždanih ovojnica nakon injiciranja otopine CFA u područje temporomandibularnog zgloba**

Otopina CFA (50  $\mu$ L) injicirana je u područje lijevog TMZ-a, a neurogena upala moždanih ovojnica je mjerena nakon 1, 7 i 14 dana (mjerena je ekstravazacija Evansovog modrila u duralnom tkivu). Legenda: kontrola: skupina životinja u kojih je injicirana fiziološka otopina (50  $\mu$ L) u područje TMZ-a; 1 d: skupina životinja u kojih je injicirana otopina CFA u područje TMZ-a, a neurogena upala je mjerena nakon 1 dan. 7 d: skupina životinja u kojih je injicirana otopina CFA u područje TMZ-a, a neurogena upala je mjerena nakon 7 dana; 14 d: Formalin 4 h: skupina životinja u kojih je injicirana otopina CFA u područje TMZ-a, a neurogena upala je mjerena nakon 14 dana. Mjerena je količina Evansovog modrila izdvojenog iz duralnog tkiva (ng po mg duralnog tkiva). Rezultati su prikazani kao aritmetička sredina +/- standardna srednja pogreška; n = 6 (n - broj uzorka po skupini); \*\*p < 0,001 u usporedbi s fiziološkom; \*p < 0,01 u usporedbi s fiziološkom (one way ANOVA, Newman-Keulsov post hoc test).

Histološkim bojenjem tkiva po Giemsi u kranijalnoj duri uočene su specifične upalne stanice, karakterizirane kao limfociti, monociti, plazma stanice, makrofazi (slika 16). Pokazan je također porast ukupnog broja stanica unutar moždanih ovojnica (broj staničnih profila je automatski izračunat korištenjem vizualizacijskog programa CellSens Dimension) u odnosu na kontrolne životinje (slika 16).



**Slika 16. Infiltracija proupalnih stanica u moždane ovojnice nakon uzrokovanja upalne boli temporomandibularnog zgloba injiciranjem CFA (prema ref. Lacković i sur., 2015)<sup>205</sup>**

Upalna bol u zglobu je uzrokovana injiciranjem CFA (50  $\mu$ L) u područje lijevog TMZ-a. Dvadeset četiri sata nakon injiciranja CFA životinje su perfundirane fiziološkom otopinom, a duralno tkivo prikupljeno za histološko bojenje po Giemsi. Broj Giemsa pozitivno obojenih staničnih profila je automatski izračunat korištenjem vizualizacijskog programa CellSens Dimension (Olympus).

Legenda: L - limfociti; Mo - monociti; P - plazma stanice; cMC - tkivni makrofazi; eMC - makrofazi iz krvi; F - fibroblasti. Scale bars = 100  $\mu$ m. Rezultati su prikazani kao aritmetička sredina broja stanica u 4 do 5 vizualnih polja u jednoj životinji. Scatter plot predstavlja pojedinačne vrijednosti svake životinje, dok horizontalne linije predstavljaju aritmetičke sredine  $\pm$  standardna srednja pogreška; n = 5; \*p < 0,001, u usporedbi s kontrolom (one-way ANOVA, Newman-Keulsov post hoc test).

## 5.1.2. NEUROPATSKA BOL

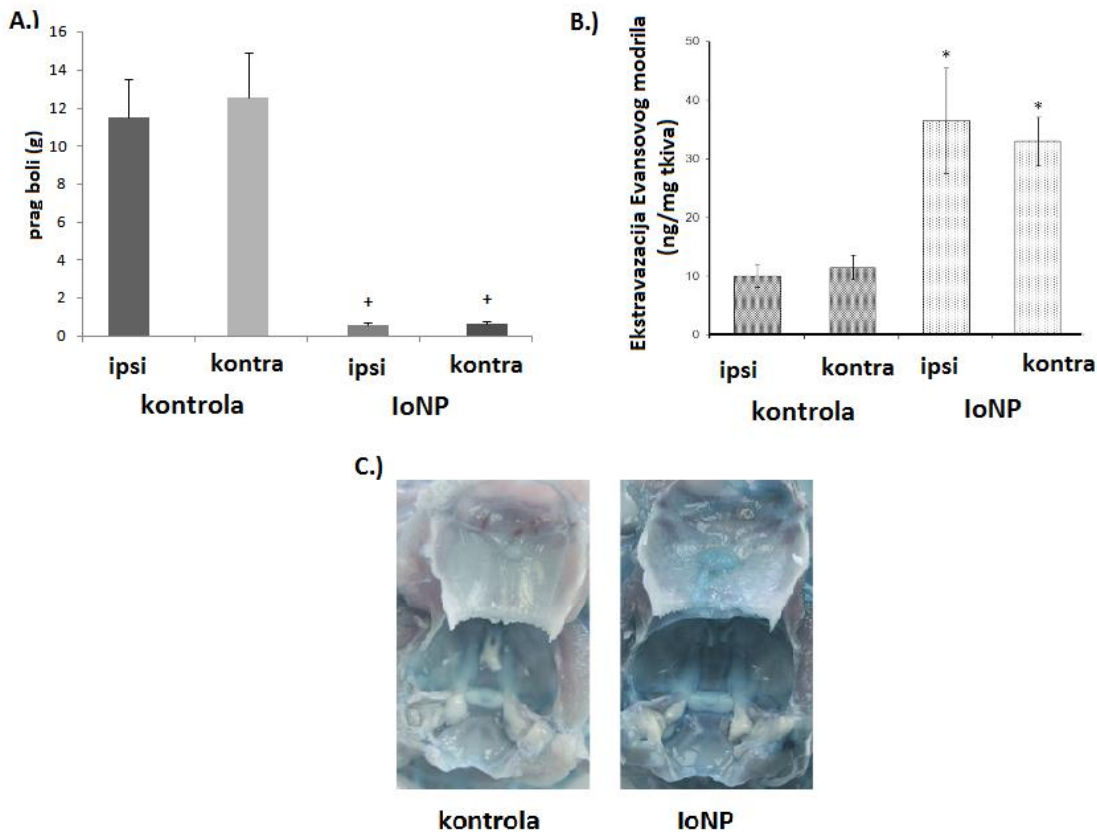
### 5.1.2.1. Podvezivanje infraorbitalnog živca

U eksperimentalnom modelu neuropatske boli uzrokovane podvezivanjem infraorbitalnog živca ispitivao se utjecaj boli (14 dana nakon podvezivanja) na razvoj neurogene upale kranijalnih moždanih ovojnica.

Pokazano je IoNP rezultira povećanom obostranom bolnom osjetljivošću, odnosno mehaničkom alodinijom (mjereno Von Freyevim filamentima) u području brkova štakora (slika 17 A), koja se javila u otprilike 70% životinja. Dodatno je uočeno da je jednostrana



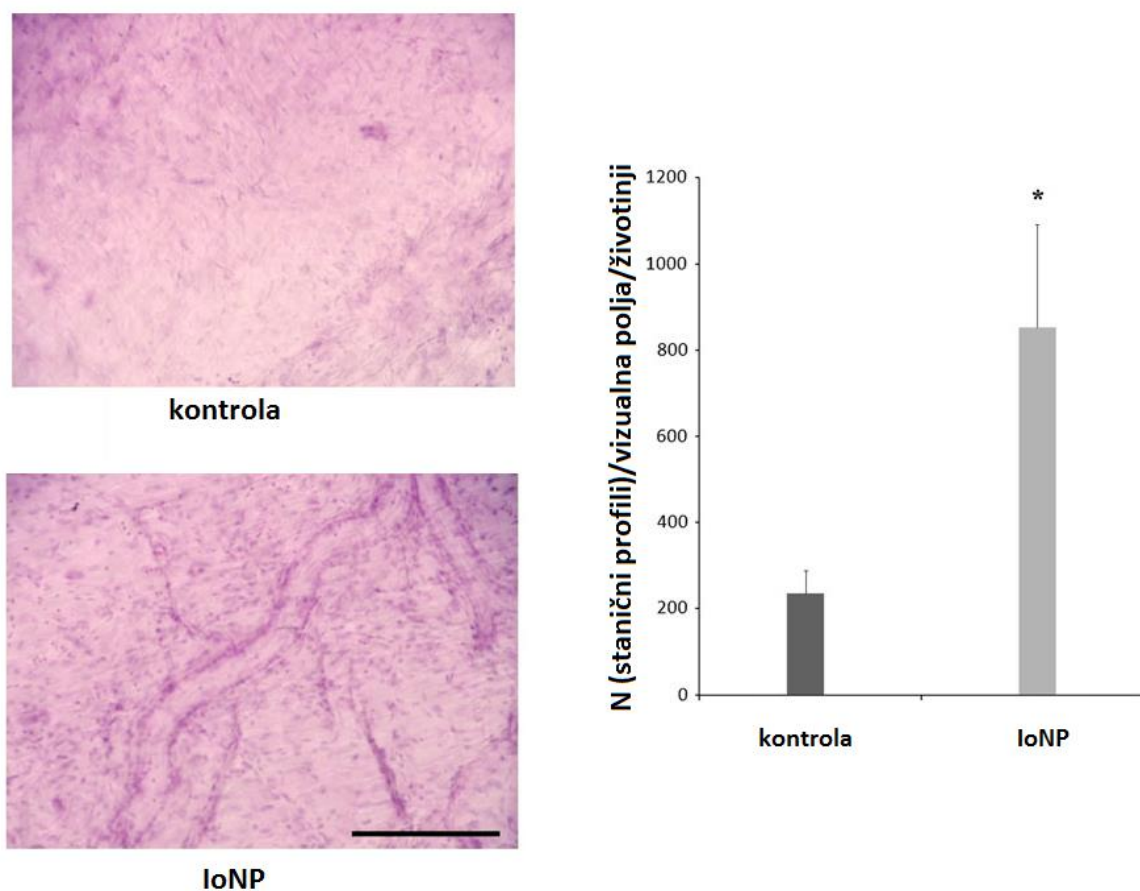
neuropatska bol praćena razvojem obostrane neurogene upale kranijalnih moždanih ovojnica (slika 17 B, slika 17 C), mjereno kao porast ekstravazacije plazmatskih proteina u kranijalnoj duri (slika 17 B).



**Slika 17. Neuropatska bol uzrokovana podvezivanjem infraorbitalnog živca praćena je razvojem obostrane aloidinije i neurogene upale kranijalnih moždanih ovojnica (prema ref. Filipović i sur., 2012)<sup>227</sup>**

Neuropatska bol se razvila 14 dana nakon podvezivanja lijevog infraorbitalnog živca. A) Mjerena je sila u gramima koja uzrokuje bolni odgovor nakon primjene Von Freyevih filamenata na područje brkova štakora. B) Mjerena je količina Evansovog modrila izdvojenog iz duralnog tkiva (ng po mg duralnog tkiva) koje je podijeljeno na ipsilateralnu i kontralateralnu stranu u odnosu na ozljedu živca. C) Fotografije dure nakon perfuzije fiziološkom otopinom te odstranjenja moždanog tkiva. Legenda: A; ipsi - ipsilateralna strana lica u odnosu na ozljedu živca; kontra - kontralateralna strana lica u odnosu na ozljedu živca. B; ipsi - duralno tkivo ipsilateralno u odnosu na ozljedu živca; kontra - duralno tkivo kontralateralno u odnosu na ozljedu živca; IoNP - životinje s podvezanim lijevom infraorbitalnim živcem; kontrola - operirane životinje kojima nije podvezan infraorbitalni živac. Rezultati su prikazani kao aritmetička sredina +/- standardna srednja pogreška; n = 5 – 9; <sup>+</sup>p < 0,001, <sup>\*</sup>p < 0,01 u usporedbi s kontrolom (Newman-Keulsov post hoc test).

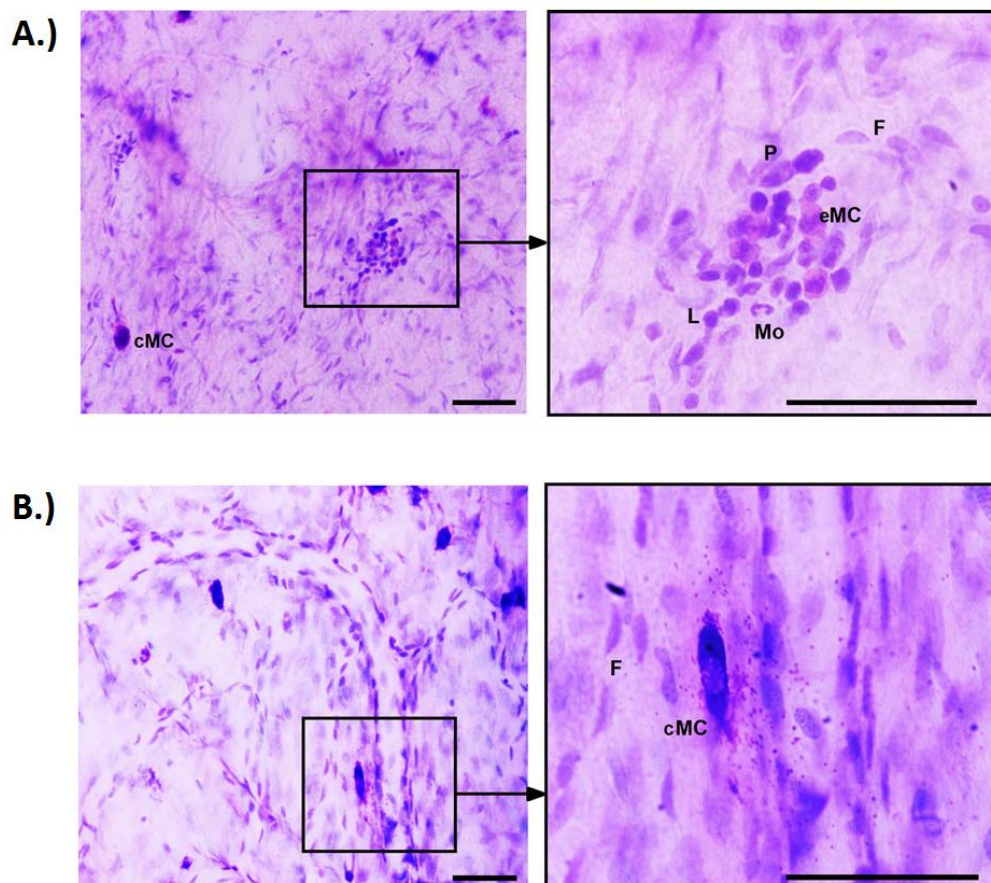
Histološkim bojenjem tkiva hemalaun eozinom pokazan je porast ukupnog broja stanica unutar moždanih ovojnica (broj staničnih profila je automatski izračunat korištenjem vizualizacijskog programa CellSens Dimension) u odnosu na kontrolne životinje (slika 18).



**Slika 18. Neuropatska bol uzrokovana podvezivanjem lijevog infraorbitalnog živca praćena je infiltracijom proupalnih stanica u moždane ovojnice (prema ref. Filipović i sur., 2014)<sup>215</sup>**

Neuropatska bol se razvila 14 dana nakon podvezivanja lijevog infraorbitalnog živca te su životinje perfundirane fiziološkom otopinom, a duralno tkivo prikupljeno za histološko bojenje hemalaun eozinom. Broj hemalaun eozin pozitivno obojenih staničnih profila je automatski izračunat koristeći se vizualizacijskim programom CellSens Dimension (Olympus). Rezultati su prikazani kao aritmetička sredina broja stanica u 4 do 5 vizualnih polja u jednoj životinji, dok horizontalne linije predstavljaju +/- standardnu srednju pogrešku;  $n = 3 - 4$ ; skala vrijednosti predstavlja 100  $\mu\text{m}$ ; \* $p < 0,01$ , u usporedbi s kontrolom (two-tailed t test).

Histološkim bojenjem tkiva po Giemsi u kranijalnoj duri uočene su specifične upalne stanice, karakterizirane kao limfociti, monociti, plazma stanice, makrofazi (slika 19).



**Slika 19. Neuropatska bol uzrokovana podvezivanjem lijevog infraorbitalnog živca praćena je infiltracijom specifićnih proupalnih stanica u moždane ovojnice (prema ref. Filipović i sur., 2014)<sup>215</sup>**

Neuropatska bol se razvila 14 dana nakon podvezivanja lijevog infraorbitalnog živca te su životinje perfundirane fiziološkom otopinom, a duralno tkivo prikupljeno za histološko bojenje po Giemsi. Legenda: L - limfociti; Mo - monociti; P - plasma stanice; cMC - tkivni makrofazi; eMC - makrofazi iz krvi; F - fibroblasti. Skala vrijednosti predstavlja 50  $\mu$ m.

## **5.2. NEUROGENA UPALA KAO SPECIFIĆNA REAKCIJA KRANIJALNE DURE NA BOLNI PODRAŽAJ IZ PODRUĆJA GLAVE I VRATA**

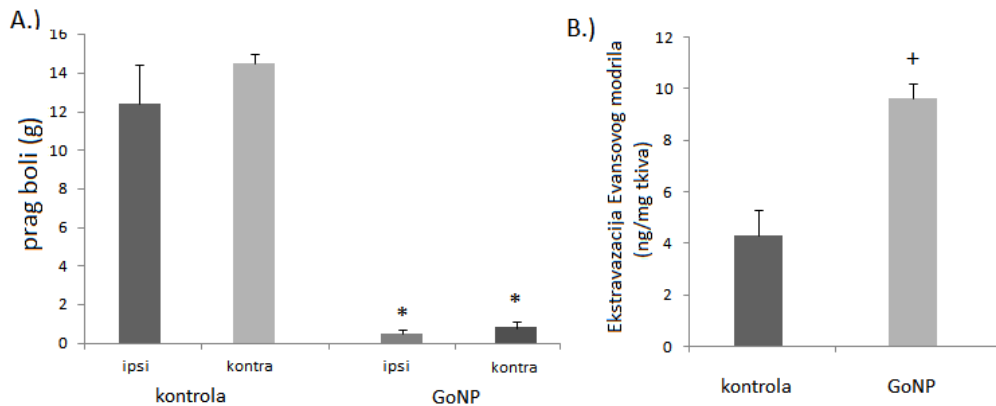
### **5.2.1. Neuropatska bol podrijetlom iz vrata**

#### **5.2.1.1. Podvezivanje velikog okcipitalnog živca**

U eksperimentalnom modelu neuropatske boli uzrokovane podvezivanjem velikog okcipitalnog živca (GoNP) ispitivao se utjecaj ozljede živca (14 dana nakon podvezivanja) na razvoj alodinije u inervacijskom području trigeminusa te na razvoj neurogene upale kranijalnih moždanih ovojnica.



Pokazano je da neuropatska bol uzrokovana ozljedom okcipitalnog živca rezultira obostrano povećanom bolnom osjetljivošću, odnosno mehaničkom alodinijom (mjereno Von Freyevim filamentima) u području brkova štakora, što pripada inervacijskom području trigeminusa (slika 20 A). Dodatno je uočeno da neuropatska bol kao posljedica ozljede okcipitalnog živca rezultira razvojem obostrane neurogene upale kranijalnih moždanih ovojnica, koje su primarno inervirane ograncima trigeminusa (slika 20 B).



**Slika 20. Neuropatska bol uzrokovana podvezivanjem velikog okcipitalnog živca povezana je s razvojem neurogene upale kranijalnih moždanih ovojnica (prema ref. Filipović i sur., 2014)<sup>215</sup>**

Neuropatska bol se razvila 14 dana nakon podvezivanja lijevog velikog okcipitalnog živca. A) Mjerena je sila u gramima koja uzrokuje bolni odgovor nakon primjene Von Freyevih filamenata na područje brkova štakora; B) Mjerena je količina Evansovog modrila izdvojenog iz duralnog tkiva (ng po mg duralnog tkiva), koje je podijeljeno na ipsilateralnu i kontralateralnu stranu u odnosu na ozljedu živca. Legenda: A; ipsi - ipsilateralna strana lica u odnosu na ozljedu živca; kontra - kontralateralna strana lica u odnosu na ozljedu živca. GoNP - životinje s podvezanim lijevim velikim okcipitalnim živcem; kontrola - operirane životinje kojima nije podvezan veliki okcipitalni živac. Rezultati su prikazani kao aritmetička sredina +/- standardna srednja pogreška; n = 5 - 9; +p < 0,05, \*p < 0,001 u usporedbi s kontrolom (two-tailed t test).

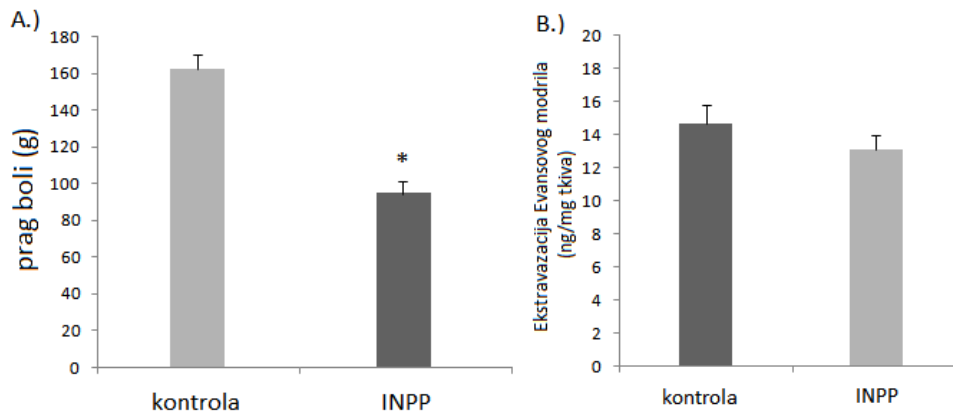
## 5.2.2. Neuropatska bol podrijetlom iz stražnje šape

### 5.2.2.1. Parcijalno presijecanje ishijadičnog živca

U eksperimentalnom modelu neuropatske boli uzrokovane parcijalnim presijecanjem ishijadičnog živca (INPP) ispitivao se utjecaj boli (14 dana nakon presijecanja) podrijetlom iz perifernih dijelova tijela na razvoj neurogene upale kranijalnih moždanih ovojnica.

Pokazano je da neuropatska bol uzrokovana ozljedom ishijadičnog živca rezultira jednostranom bolnom osjetljivošću, odnosno mehaničkom hiperalgezijom (mjereno metodom pritiska šape) u području šape štakora (slika 21 A). Takva ozljeda u inervacijskom području ishijadičnog živca, što je izvan inervacijskog područja glave, nije rezultirala razvojem

neurogene upale kranijalnih moždanih ovojnica, koje su primarno inervirane ograncima trigeminalnog živca (slika 21 B).



**Slika 21. Neuropatska bol uzrokovana parcijalnim presijecanjem ishijadičnog živca nije povezana s razvojem neurogene upale kranijalnih moždanih ovojnica (prema ref. Filipović i sur., 2014)<sup>215</sup>**

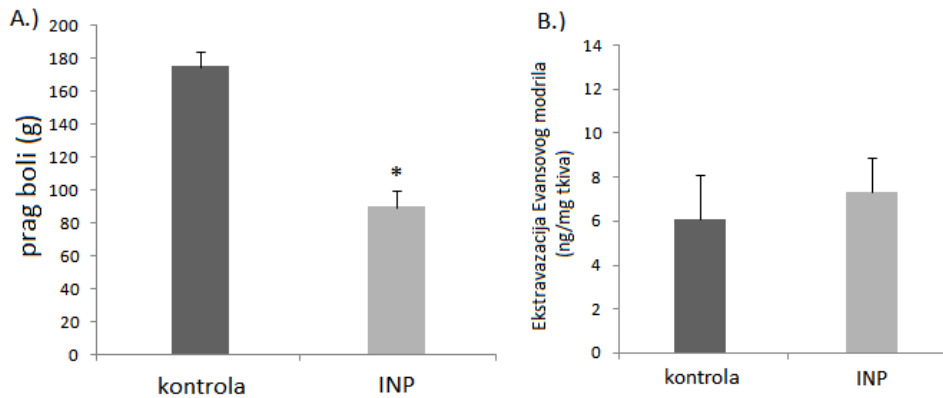
Neuropatska bol se razvila 14 dana nakon parcijalnog presijecanja desnog ishijadičnog živca u štakora. A) Mjerena je sila kojom uteg pritišće površinu šape od oko 6 mm<sup>2</sup>, a koja dovede do pomaka šape, tj. bolnog odgovora. Ta vrijednost predstavlja prag boli, a radi jednostavnosti prikazana je kao masa u gramima. B) Mjerena je količina Evansovog modrila izdvojenog iz duralnog tkiva (ng po mg duralnog tkiva). Legenda: INPP - životinje s parcijalno presječenim ishijadičnim živcem; kontrola - operirane životinje kojima nije parcijalno presječen ishijadični živac. Rezultati su prikazani kao aritmetička sredina +/- standardna srednja pogreška; n = 5 – 8; \*p < 0,001 u usporedbi s kontrolom (two-tailed t test).

### 5.2.2.2. Podvezivanje ishijadičnog živca

Model podvezivanja ishijadičnog živca (INP) smo dodatno koristili (uz model parcijalnog presijecanja ishijadičnog živca) radi što točnije usporedbe s modelom neuropatske boli iz trigeminalne regije – podvezivanje infraorbitalnog živca.

U eksperimentalnom modelu neuropatske boli uzrokovane podvezivanjem ishijadičnog živca ispitivao se utjecaj boli (14 dana nakon podvezivanja) iz perifernih dijelova tijela na razvoj neurogene upale kranijalnih moždanih ovojnica.

Pokazano je da neuropatska bol uzrokovana ozljedom ishijadičnog živca rezultira jednostranom mehaničkom hiperalgezijom (mjereno metodom pritiska šape) u području šape štakora (slika 22 A), dok je, kao i u prethodnom modelu, razvoj neurogene upale kranijalnih moždanih ovojnica koje su primarno inervirane ograncima trigeminalnog živca izostao (slika 22 B).



**Slika 22. Neuropatska bol uzrokovana podvezivanjem ishijadičnog živca nije povezana s razvojem neurogene upale kranijalnih moždanih ovojnica (prema ref. Filipović i sur., 2014)<sup>215</sup>**

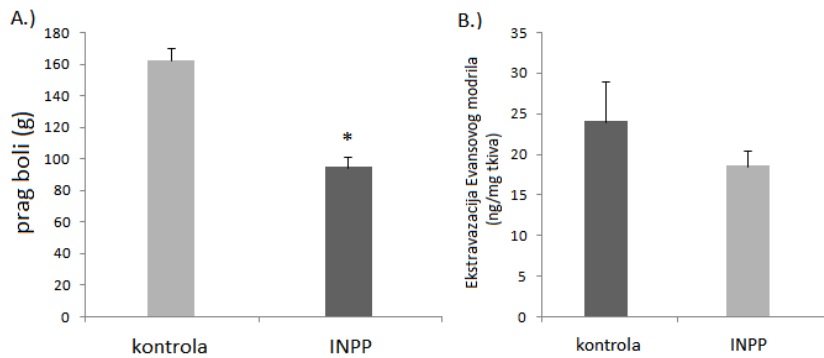
Neuropatska bol se razvila 14 dana nakon podvezivanja desnog ishijadičnog živca u štakora. A) Mjerena je sila kojom uteg pritišće površinu šape od oko 6 mm<sup>2</sup>, a koja dovede do pomaka šape, tj. bolnog odgovora. Ta vrijednost predstavlja prag boli, a radi jednostavnosti prikazana je kao masa u gramima. B) Mjerena je količina Evansovog modrila izdvojenog iz duralnog tkiva (ng po mg duralnog tkiva). INP - životinje s podvezanim ishijadičnim živcem; kontrola - operirane životinje kojima nije podvezan ishijadični živac. Rezultati su prikazani kao aritmetička sredina +/- standardna srednja pogreška; n = 5 – 8 (n - broj životinja po skupini); A)\*p < 0,001 u usporedbi s kontrolom (two-tailed t test). B) p < 0,05 u usporedbi s kontrolom (two-tailed t test).

### **5.3. JE LI BOL IZ INERVACIJSKOG PODRUČJA ISHIJADIČNOG ŽIVCA POVEZANA S NEUROGENOM UPALOM LUMBALNIH OVOJNICA?**

#### **5.3.1. Parcijalno presijecanje ishijadičnog živca**

U eksperimentalnom modelu neuropatske boli uzrokovane parcijalnim presijecanjem ishijadičnog živca (INPP) ispitivao se utjecaj boli (14 dana nakon presijecanja) na razvoj neurogene upale lumbalnih ovojnica.

Pokazano je da neuropatska bol uzrokovana ozljedom ishijadičnog živca rezultira jednostranom mehaničkom hiperalgezijom (mjereno metodom pritiska šape) (slika 23 A). Međutim, povećana bolnost u ovom modelu nije praćena ekstravazacijom proteina plazme u lumbalnim ovojnicama (mjereno metodom Evansova modrila) (slika 23 B).



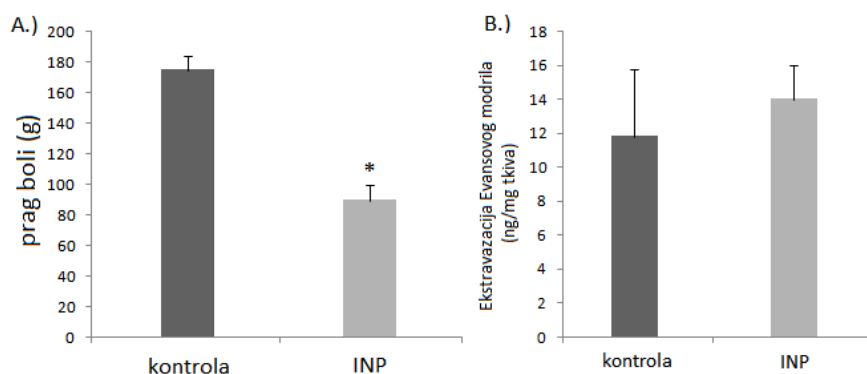
**Slika 23. Neuropatska bol uzrokovana parcijalnim presijecanjem ishijadičnog živca nije povezana s razvojem neurogene upale lumbalnih ovojnica (prema ref. Filipović i sur., 2014)<sup>215</sup>**

Neuropatska bol se razvila 14 dana nakon parcijalnog presijecanja desnog ishijadičnog živca u štakora. A) Mjerena je sila kojom uteg pritišće površinu šape od oko 6 mm<sup>2</sup>, a koja dovede do pomaka šape, tj. bolnog odgovora. Ta vrijednost predstavlja prag boli, a radi jednostavnosti prikazana je kao masa u gramima. B) Mjerena je količina Evansovog modrila izdvojenog iz lumbalnog duralnog tkiva (ng po mg duralnog tkiva). Legenda: INPP - životinje s parcijalno presječenim ishijadičnim živcem; kontrola - operirane životinje kojima nije parcijalno presječen ishijadični živac. Rezultati su prikazani kao aritmetička sredina +/- standardna srednja pogreška; n = 5 – 8; A) \*p < 0,001 u usporedbi s kontrolom (two-tailed t test); B) p < 0,05 u usporedbi s kontrolom (two-tailed t test).

### 5.3.2. Podvezivanje ishijadičnog živca

U eksperimentalnom modelu neuropatske boli uzrokovane podvezivanjem ishijadičnog živca (INP) ispitivao se utjecaj boli (14 dana nakon podvezivanja) na razvoj neurogene upale lumbalnih ovojnica.

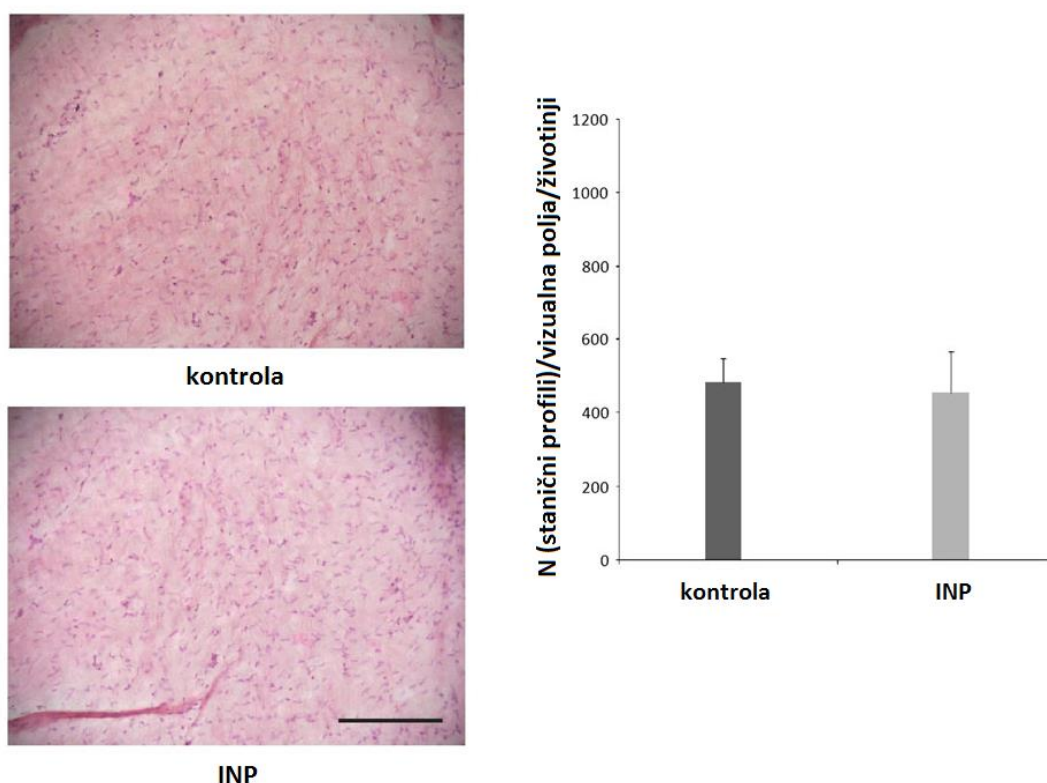
Pokazano je da neuropatska bol uzrokovana ozljedom ishijadičnog živca rezultira jednostranom mehaničkom hiperalgezijom (mjereno metodom pritiska šape) u području šape štakora (slika 24 A). Kao i u prethodnom modelu, povećana bolnost nakon podvezivanja živca nije praćena ekstravazacijom proteina plazme u lumbalnim ovojnicama mjereno metodom Evansova modrila (slika 24 B).



**Slika 24. Neuropatska bol uzrokovana podvezivanjem ishijadičnog živca nije povezana s razvojem neurogene upale lumbalnih spinalnih ovojnica (prema ref. Filipović i sur., 2014)<sup>215</sup>**

Neuropatska bol se razvila 14 dana nakon podvezivanja ishijadičnog živca u štakora. A) Mjerena je sila kojom uteg pritišće površinu šape od oko 6 mm<sup>2</sup>, a koja dovede do pomaka šape, tj. bolnog odgovora. Ta vrijednost predstavlja prag boli, a radi jednostavnosti prikazana je kao masa u gramima. B) Mjerena je količina Evansovog modrila izdvojenog iz lumbalnog duralnog tkiva (ng po mg duralnog tkiva). Legenda: INP - životinje s podvezanim ishijadičnim živcem; kontrola - operirane životinje kojima nije podvezan ishijadični živac. Rezultati su prikazani kao aritmetička sredina +/- standardna srednja pogreška; n = 5 – 8; A)\*p < 0,001 u usporedbi s kontrolom (two-tailed t test); B) p < 0,05 u usporedbi s kontrolom (two-tailed t test).

Dodatno, histološkim bojenjem tkiva HE nije uočen porast ukupnog broja stanica unutar lumbalnih ovojnica (broj staničnih profila je automatski izračunat pomoću vizualizacijskog programa CellSens Dimension) u odnosu na kontrolne životinje (slika 25).



**Slika 25. Neuropatska bol uzrokovana podvezivanjem ishijadičnog živca nije praćena infiltracijom proupalnih stanica u lumbalnim ovojnica (prema ref. Filipović i sur., 2014)<sup>215</sup>**

Neuropatska bol se razvila 14 dana nakon podvezivanja ishijadičnog živca u štakora. Životinje su perfundirane fiziološkom otopinom, a lumbalno duralno tkivo prikupljeno za histološko bojenje hemalaun eozinom. Broj hemalaun eozin pozitivno obojenih staničnih profila je automatski izračunat pomoću vizualizacijskog programa CellSens Dimension (Olympus). Rezultati su prikazani kao aritmetička sredina broja stanica u 4 do 5 vizualnih polja u jednoj životinji, dok horizontalne linije predstavljaju +/- standardna srednja pogreška; n = 3 – 4; skala vrijednosti predstavlja 100  $\mu$ m; \*p < 0,01, u usporedbi s kontrolom (two-tailed t test).

## **5.4. FARMAKOLOŠKA KARAKTERIZACIJA NEUROGENE UPALE KRANIJALNIH MOŽDANIH OVOJNICA**

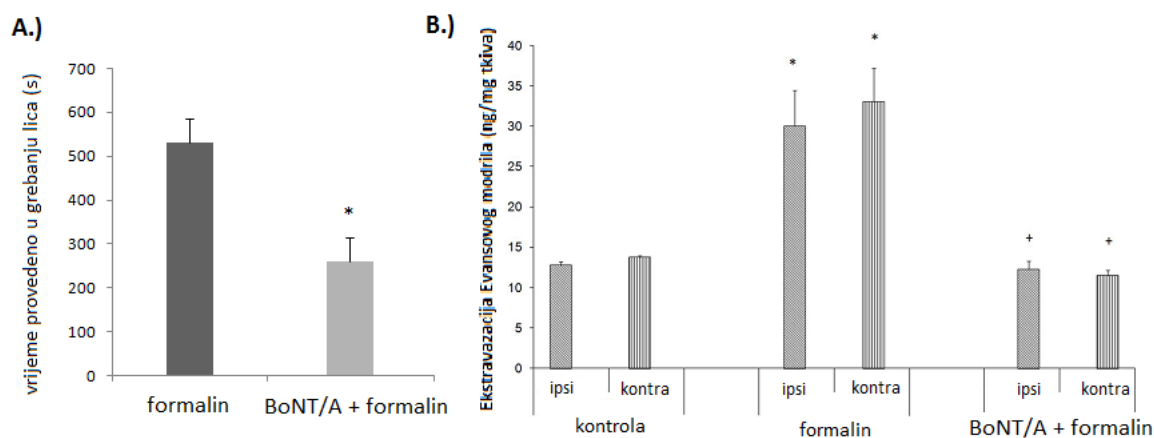
### **5.4.1. Botulinum toksin tipa A**

#### **5.4.1.1. Formalinski test**

Formalinskim testom se ispitivao učinak BoNT/A na upalnu bol (druga faza testa, 15 – 60 min), pri čemu je mjereno vrijeme tijekom kojeg životinja grebe/trlja područje brkova u koje je neposredno prije injicirana 2,5%-tna otopina formalina (50  $\mu$ l). Osim analgetskog, ispitivan je učinak BoNT/A i na neurogenu upalu moždanih ovojnica mjerenjem ekstravazacije proteina plazme u tkivo dure (metoda pomoću Evansovog modrila).

BoNT/A je primijenjen jednokratno u dozi od 3,5 i.j./kg, s.c. u lijevu stranu brkova štakora 3 dana prije injiciranja formalina. BoNT/A nakon perifernog injiciranja statistički značajno

manjuje bolnu osjetljivost uzrokovanu formalinom (slika 26 A), kao i neurogenu upalu moždanih ovojnica s ipsilateralne, ali i kontralateralne strane (slika 26 B).



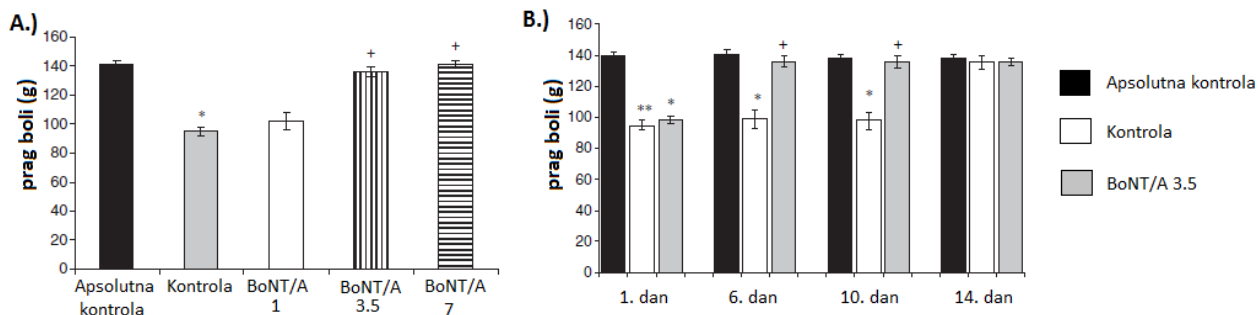
**Slika 26. Jednokratna periferna primjena BoNT/A (3,5 i.j./kg, s.c.) smanjuje bol, kao i bilateralnu neurogenu upalu kranijalnih moždanih ovojnica (prema ref. Filipović i sur., 2012)<sup>227</sup>**

Bolna preosjetljivost (hiperalgezija) i neurogena upala kranijalne moždane dure su uzrokovani injiciranjem formalina u područje brkova štakora (2,5%-tni formalin, 50  $\mu$ L). BoNT/A (3,5 i.j./kg) je injiciran s.c. u područje lijeve strane brkova štakora 3 dana prije injiciranja formalina. A) Mjereno je vrijeme (sekunde) tijekom kojeg životinja grebe/trlja područje brkova u drugoj fazi formalinskog testa (period od 15 - 60 min). B) Neurogena upala je mjerena kao povećana ekstravazacija proteina plazme u kranijalnim moždanim ovojnicama (količina Evansovog modrila u ng po mg duralnog tkiva), koje su podijeljene na ipsilateralnu i kontralateralnu stranu u odnosu na injiciranje formalina. Analizirani uzorak se sastojao od spojenih duralnih uzoraka tkiva četiriju životinja. Legenda: Ipsi - duralno tkivo ipsilateralno u odnosu na injiciranje formalina; kontra - duralno tkivo kontralateralno u odnosu na iniciranje formalina; formalin - životinje injicirane formalinom; kontrolna - životinje injicirane fiziološkom otopinom; BoNT/A + formalin - životinje injicirane BoNT/A (3,5 i.j./kg) 3 dana prije injiciranja formalina. Rezultati su prikazani kao aritmetička sredina +/- standardna srednja pogreška; A) n = 5 - 8 ; B) n = 4 (broj uzoraka po skupini). \*p < 0,05 u usporedbi s kontrolom; +p < 0,05 u usporedbi s formalinom (Newman-Keulsov post hoc test).

#### 5.4.1.2. Model parcijalnog presijecanja mišića gastroknemijusa

U modelu se ispitivao učinak jednokratne primjene BoNT/A u različitim dozama (1 i.j./kg, 3,5 i.j./kg, 7 i.j./kg) s.c. na postkiruršku bol (mjerenu metodom pritiska šape) 6 dana nakon injiciranja u plantarnu stranu stražnje šape životinja. Dodatno je ispitivan učinak BoNT/A u dozi od 3,5 i.j./kg (injiciran u plantarnu stranu stražnje šape) na postkiruršku bol, nakon 1, 6, 10 i 14 dana od injiciranja.

BoNT/A je primijenjen jednokratno u dozi od 3,5 i 7 i.j./kg, s.c., 6 dana nakon injiciranja statistički značajno smanjuje bolnu osjetljivost (mjerenu metodom pritiska šape), dok u dozi od 1 i.j./kg nije imao učinka na bolnost (slika 27 A). BoNT/A je u dozi od 3,5 i.j./kg, s.c., statistički značajno smanjuje bolnu osjetljivost 6, 10 i 14 dana od perifernog injiciranja, dok 1 dan nakon injiciranja nije imao učinak na bolnost (slika 27 B).



**Slika 27. Jednokratna primjena BoNT/A u plantarnu stranu šape (3,5 i 7 i.j./kg s.c.) smanjuje bolnu osjetljivost do ukupno 14 dana nakon injiciranja u modelu postkirurške boli (prema ref. Filipović i sur., 2010)<sup>223</sup>**

Postkirurška bol se razvila 1 dan nakon parcijalnog presjecanja mišića gastroknemijusa u štakora. Mjerena je sila kojom uteg pritišće površinu šape od oko 6 mm<sup>2</sup>, a koja dovede do pomaka šape, tj. bolnog odgovora. Ta vrijednost predstavlja prag boli, a radi jednostavnosti prikazana je kao masa u gramima. A) Mjerenje je izvedeno 6 dana nakon injiciranja BoNT/A. B) Mjerenje je izvedeno 1, 6, 10 i 14 dana nakon injiciranja BoNT/A. Legenda: Apsolutna kontrola - životinje koje nisu tretirane; Kontrola - životinje s parcijalno presječenim mišićem gastroknemijusom; BoNT/A 1 - životinje s parcijalno presječenim mišićem gastroknemijusom kojima je injiciran BoNT/A u dozi od 1 i.j./kg; BoNT/A 3,5 - životinje s parcijalno presječenim mišićem gastroknemijusom kojima je injiciran BoNT/A u dozi od 3,5 i.j./kg; BoNT/A 7 - životinje s parcijalno presječenim mišićem gastroknemijusom kojima je injiciran BoNT/A u dozi od 7 i.j./kg; Rezultati su prikazani kao aritmetička sredina +/- standardna srednja pogreška; n = 7–8; \*p < 0,01 u usporedbi s apsolutnom kontrolom, \*\*p < 0,001 u usporedbi s apsolutnom kontrolom, + p < 0,01 u usporedbi s kontrolom (one-way ANOVA, Newman-Keulsov post hoc test).

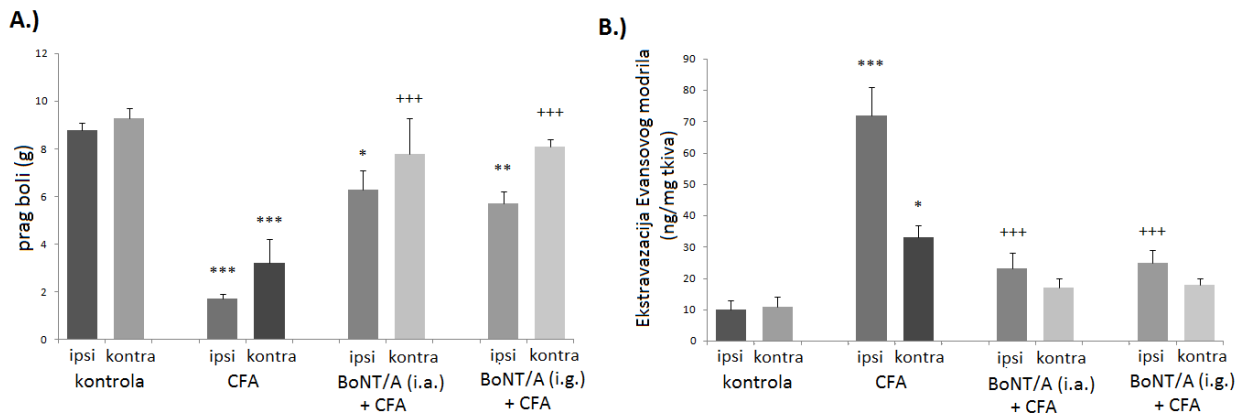
### 5.4.1.3. Model bolnosti temporomandibularnog zgloba uzrokovane CFA

U modelu se ispitivao učinak jednokratne primjene BoNT/A u područje lijevog TMZ-a (5 i.j./kg, i.a.) ili u lijevi trigeminalni ganglij (2 i.j./kg) na obostranu mehaničku preosjetljivost (mjereno Von Freyevim filamentima u području brkova štakora) i prateću neurogenu upalu moždanih ovojnica (mjereno kao ekstravazacija proteina plazme).

BoNT/A je primijenjen 3 dana prije injiciranja otopine CFA (50 µL) u lijevi TMZ, a reakcija na bolne podražaje mjerena je 24 h nakon injiciranja CFA. Učinak BoNT/A (5 i.j./kg i.a. u lijevi TMZ ili 2 i.j./kg trigeminalni ganglij) na razvoj neurogene upale kranijalnih moždanih ovojnica mjereno je pomoću Evansovog modrila te histološkim bojenjem tkiva po Giemsi i određivanjem ukupnog broja stanica u moždanim ovojnicama (vizualizacijskim programom CellSens Dimension).

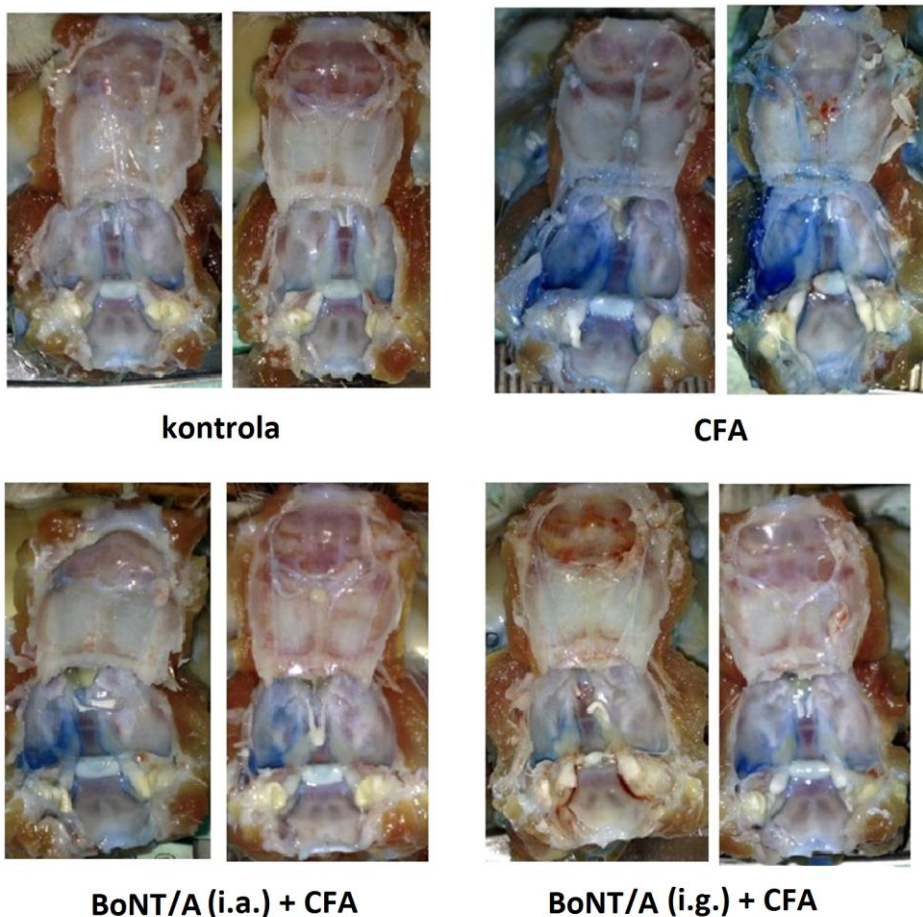


Jednostrano primijenjen BoNT/A (i.a. u područje TMZ-a ili direktno u trigeminalni ganglij) 3 dana prije uzrokovanja boli u području zgloba je statistički spriječio nastanak obostrane mehaničke alodinije (slika 28 A) te razvoj prateće neurogene upale kranijalnih moždanih ovojnica mjerene kao ekstravazacija Evansovog modrila (slika 28 B, slika 29).



**Slika 28. Jednokratna primjena BoNT/A u zglob ili trigeminalni ganglij (5 i.j./kg i.a. ili 2 i.j./kg i.g.) smanjuje obostranu alodiniju i neurogenu upalu moždanih ovojnica u modelu upalne boli zgloba uzrokovane CFA (prema ref. Lacković i sur., 2015)<sup>205</sup>**

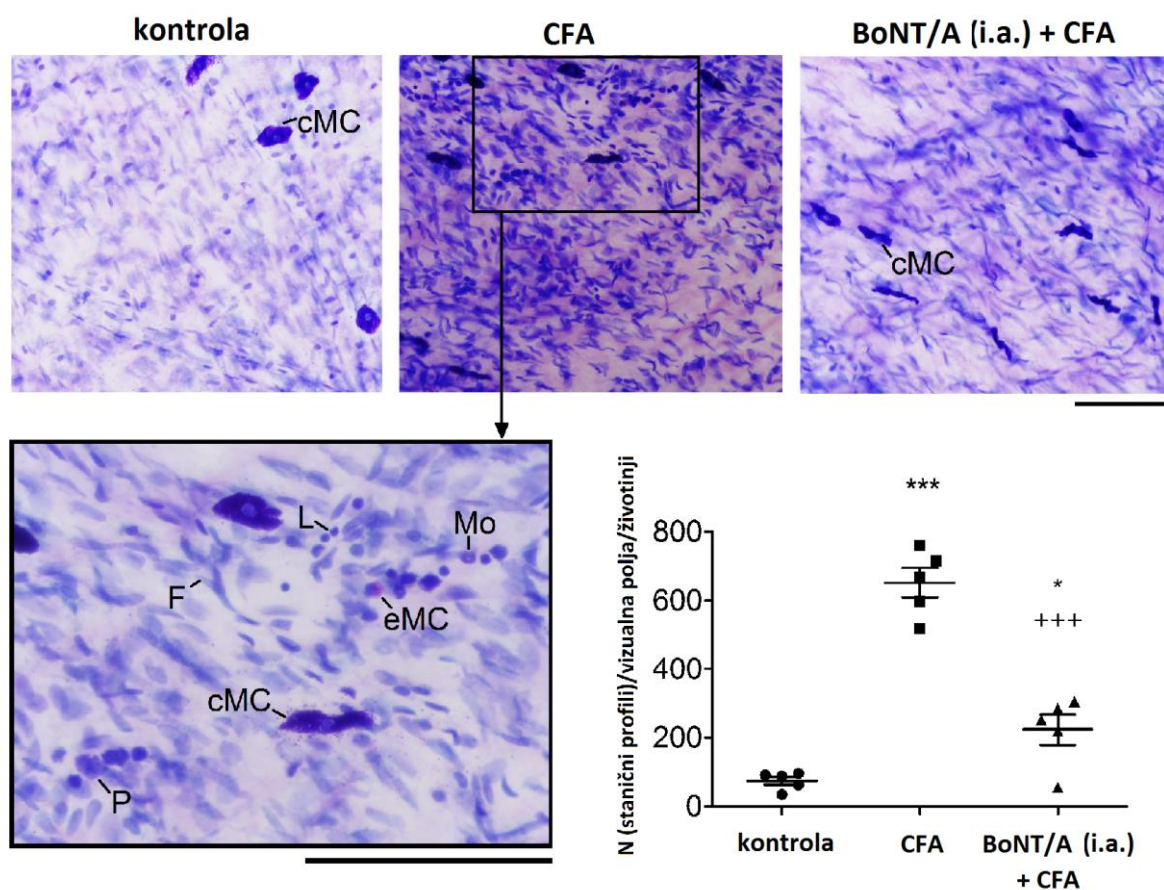
BoNT/A je bio primijenjen u lijevi TMZ (5 i.j./kg) ili lijevi trigeminalni ganglij (2 i.j./kg) 3 dana prije injiciranja otopine CFA (50  $\mu$ L) u lijevi TMZ. A) Mehanička alodinija je mjerena Von Freyevim filamentima 24 sata nakon injiciranja CFA. Mjerena je sila u gramima koja je uzrokovala bolni odgovor nakon primjene Von Freyevih filamenata na područje brkova štakora. B) Neurogena upala je mjerena kao povećana ekstravazacija proteina plazme u kranijalnim moždanim ovojnicama (količina Evansovog modrila u ng po mg duralnog tkiva), koje su podijeljene na ipsilateralnu i kontralateralnu stranu u odnosu na injiciranje CFA u TMZ. Legenda: Ipsi - ipsilateralna strana lica u odnosu na injiciranje CFA; kontra - kontralateralna strana lica u odnosu na injiciranje CFA. CFA - životinje kojima je injiciran CFA u lijevi TMZ; kontrola - životinje injicirane fiziološkom otopinom u lijevi TMZ. BoNT/A (i.a.) + CFA: životinje kojima je injiciran BoNT/A (5 i.j./kg) u lijevi TMZ 3 dana prije injiciranja CFA u lijevi TMZ; BoNT/A (i.g.) + CFA: životinje kojima je injiciran BoNT/A (2 i.j./kg) u lijevi TG 3 dana prije injiciranja CFA u lijevi TMZ. Rezultati su prikazani kao aritmetička sredina  $\pm$  standardna srednja pogreška;  $n = 5 - 9$ ; \* $p < 0,05$ , \*\* $p < 0,01$ , \*\*\* $p < 0,001$  u usporedbi s kontrolom; +++ $p < 0,001$  u usporedbi s CFA (one-way ANOVA, Newman-Keulsov post hoc test).



**Slika 29. Jednokratna jednostrana primjena BoNT/A u zglob ili trigeminalni ganglij (5 i.j./kg i.a. ili 2 i.j./kg i.g.) smanjuje neurogenu upalu kranijalnih moždanih ovojnica u modelu upalne boli zgloba uzrokovane CFA (prema ref. Lacković i sur., 2015)<sup>205</sup>**

Fotografije su učinjene nakon perfuzije fiziološkom otopinom te odstranjenja moždanog tkiva. Legenda: CFA - životinje kojima je injiciran CFA u lijevi TMZ; kontrola - životinje injicirane fiziološkom otopinom u lijevi TMZ; BoNT/A (i.a.) + CFA: životinje kojima je injiciran BoNT/A (5 i.j./kg) u lijevi TMZ 3 dana prije injiciranja CFA u lijevi TMZ.; BoNT/A (i.g.) + CFA: životinje kojima je injiciran BoNT/A (2 i.j./kg) u lijevi TG, 3 dana prije injiciranja CFA u lijevi TMZ.

Jednostrano primijenjen BoNT/A (i.a. u područje TMZ-a) 3 dana prije uzrokovanja boli u području zgloba smanjuje infiltraciju proupalnih stanica u moždanim ovojnicama (slika 30).



**Slika 30. Jednokratna primjena BoNT/A (5 i.j./kg i.a) smanjuje infiltraciju proupalnih stanica u moždane ovojnice u modelu upalne boli zgloba uzrokovane CFA (prema ref. Lacković i sur., 2015)<sup>205</sup>**

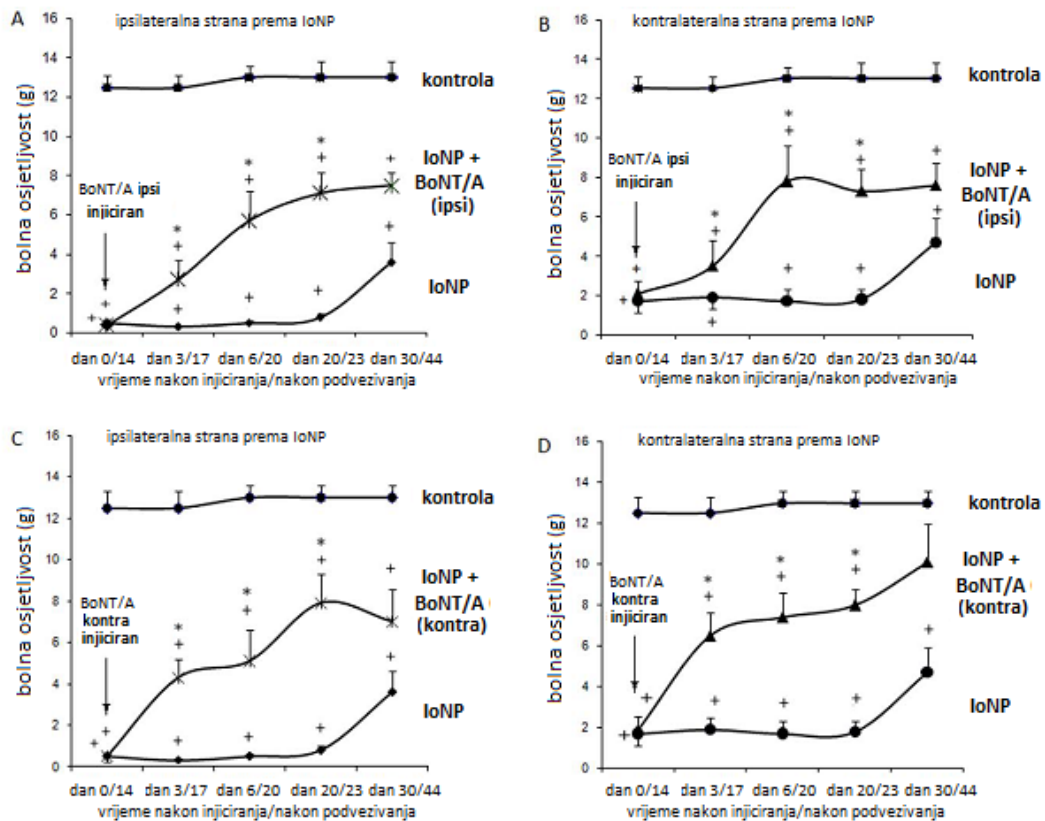
BoNT/A je bio primijenjen u lijevi TMZ (5 i.j./kg) 3 dana prije injiciranja otopine CFA (50  $\mu$ L) u lijevi TMZ. Dvadeset četiri sata nakon injiciranja CFA, životinje su perfundirane fiziološkom otopinom, a duralno tkivo prikupljeno za histološko bojenje po Giemsi. Broj Giemsa pozitivno obojenih staničnih profila je automatski izračunat pomoću vizualizacijskog programa CellSens Dimension (Olympus). Legenda: L - limfociti; Mo - moniciti; P - plasma stanice; cMC - tkivni makrofazi; eMC - makrofazi iz krvi; F - fibroblasti. Skala vrijednosti predstavlja 100  $\mu$ m. Rezultati su prikazani kao aritmetička sredina broja stanica u 4 do 5 vizualnih polja u jednoj životinji. Scatter plot predstavlja pojedinačne vrijednosti svake životinje, dok horizontalne linije predstavljaju aritmetičku sredinu +/- standardna srednja pogreška; n = 5; \*p < 0,05 u usporedbi s kontrolom; \*\*\*p < 0,001 u usporedbi s kontrolom; +++p < 0,001 u usporedbi s CFA (p < 0,05 je smatran statistički značajnim (one-way ANOVA, Newman-Keulsov post hoc test).

#### 5.4.1.4. Podvezivanje infraorbitalnog živca

U modelu neuropatske boli uzrokovane podvezivanjem infraorbitalnog živca, IoNP, ispitivan je učinak periferno primijenjenog BoNT/A u područje brkova štakora (3,5 i.j./kg, s.c.) na obostranu mehaničku alodiniju i neurogenu upalu kranijalnih moždanih ovojnica.

Dva tjedna nakon podvezivanja infraorbitalnog živca životinjama koje su razvile obostranu mehaničku alodiniju (reakcija na podražaj < 2 g nakon stimulacije područja brkova štakora Von Freyevim filamentima) injiciran je jednokratno BoNT/A ipsilateralno ili kontralateralno u odnosu na ozljedu živca te su provedena mjerenja 3, 6, 20 i 30 dana nakon injiciranja BoNT/A.

Toksin je nakon jednokratne periferne primjene, neovisno o strani injiciranja, statistički značajno smanjio bilateralnu mehaničku alodiniju 3, 6 i 20 dana nakon primjene (slika 31), dok se 30 dana od injiciranja BoNT/A učinak toksina nije mogao detektirati budući da mehanička alodinija više nije bila prisutna (slika 31).

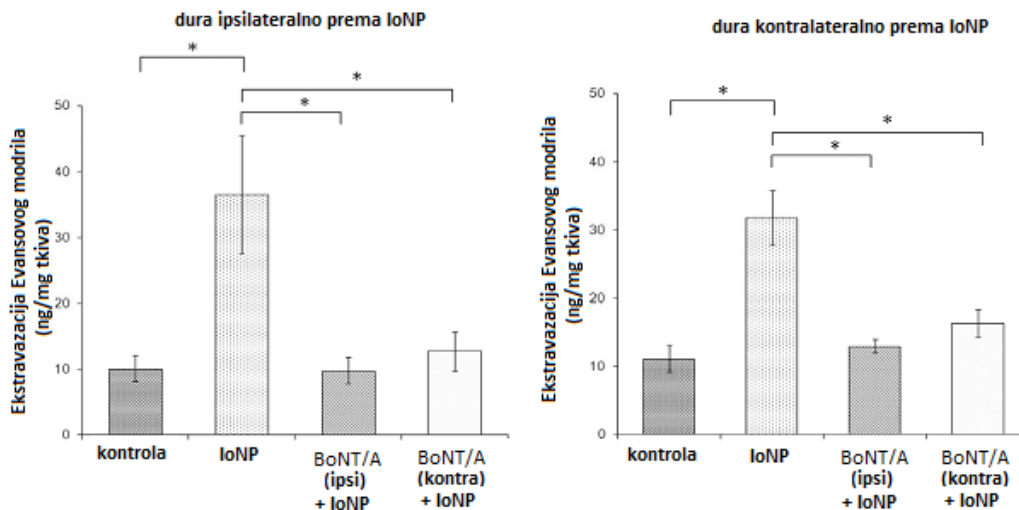


**Slika 31. Jednokratna primjene BoNT/A (3,5 i.j./kg, s.c.), neovisno o strani primjene, smanjuje obostranu alodiniju u modelu neuropatske boli uzrokovane podvezivanjem infraorbitalnog živca (prema ref. Filipović i sur., 2012)<sup>227</sup>**

BoNT/A (3,5 i.j./kg) je primijenjen (14 dana nakon IoNP) u područje brkova štakora ipsilateralno (A i B) ili kontralateralno (C i D) u odnosu na ozljedu živca. Mehanička alodinija je mjerena Von Freyevim filamentima 0, 3, 6, 20 i 30 dana nakon injiciranja BoNT/A ipsilateralno (A i C) i kontralateralno (B i D) u odnosu na ozljedu živca. Mjerena je sila u gramima koja je uzrokovala bolni odgovor nakon stimulacije područja brkova štakora Von Freyevim filamentima. Legenda: Ipsi - ipsilateralna strana lica u odnosu na ozljedu živca; kontra - kontralateralna strana lica u odnosu na ozljedu živca. IoNP - životinje s podvezanim lijevim infraorbitalnim živcem; kontrola - životinje koje su operirane, ali im nije podvezan infraorbitalni živac; IoNP + BoNT/A (ipsi) - životinje s podvezanim lijevim infraorbitalnim živcem koje su primile BoNT/A (3,5 i.j./kg) u ipsilateralnu stranu brkova u odnosu na ozljedu živca; IoNP + BoNT/A (kontra) - životinje s podvezanim lijevim infraorbitalnim živcem koje su primile BoNT/A (3,5 i.j./kg) u kontralateralnu stranu brkova u odnosu na ozljedu živca. Rezultati su prikazani kao aritmetička sredina +/- standardna srednja pogreška; n = 5 – 8; \*p < 0,01, BoNT/A injicirane u usporedbi s kontrolom; +p < 0,001 BoNT/A injicirane ili IoNP životinje u usporedbi s kontrolom (one-way ANOVA, Newman-Keulsov post hoc test).

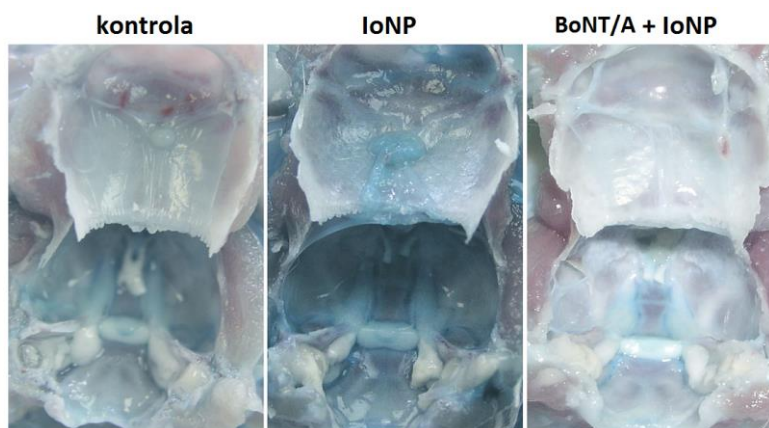


Osim mjerenja mehaničke hiperosjetljivosti, ispitan je i učinak BoNT/A na neurogenu upalu moždanih ovojnica (mjerena je ekstravazacija proteina plazme u tkivu dure 3 dana nakon injiciranja BoNT/A s.c.). BoNT/A je neovisno o strani primjene (ipsilateralno ili kontralateralno) statistički značajno smanjio i obostranu ekstravazaciju proteina plazme u kranijalnim moždanim ovojnicama (slika 32, slika 33).



**Slika 32. Jednokratna primjena BoNT/A (3,5 i.j./kg, s.c.), neovisno o strani primjene, smanjuje obostranu neurogenu upalu kranijalnih moždanih ovojnica u modelu neuropatske boli uzrokovane podvezivanjem infraorbitalnog živca (prema ref. Filipović i sur., 2012)<sup>227</sup>**

BoNT/A (3,5 i.j./kg) je primijenjen s.c. (14 dana nakon podvezivanja infraorbitalnog živca, IoNP) u područje brkova štakora, ipsilateralno ili kontralateralno u odnosu na ozljedu živca. Neurogena upala moždanih ovojnica je mjerena kao količina Evansovog modrila izdvojenog iz duralnog tkiva (ng po mg tkiva), posebno za ipsilateralnu odnosno kontralateralnu stranu u odnosu na IoNP. Analizirani uzorak se sastojao od spojenih duralnih uzoraka tkiva četiriju životinja. Legenda: kontrola - životinje koje su operirane i kojima nije podvezan infraorbitalni živac; IoNP - životinje s podvezanim lijevim infraorbitalnim živcem; IoNP + BoNT/A (ipsi) - životinje s podvezanim lijevim infraorbitalnim živcem koje su primile BoNT/A (3,5 i.j./kg) u ipsilateralnu stranu brkova u odnosu na ozljedu živca; IoNP + BoNT/A (kontra) - životinje s podvezanim lijevim infraorbitalnim živcem koje su primile BoNT/A (3,5 i.j./kg) u kontralateralnu stranu brkova u odnosu na ozljedu živca. Rezultati su prikazani kao aritmetička sredina +/- standardna srednja pogreška; n = 5, \*p < 0,01 (Newman-Keulsov post hoc test).

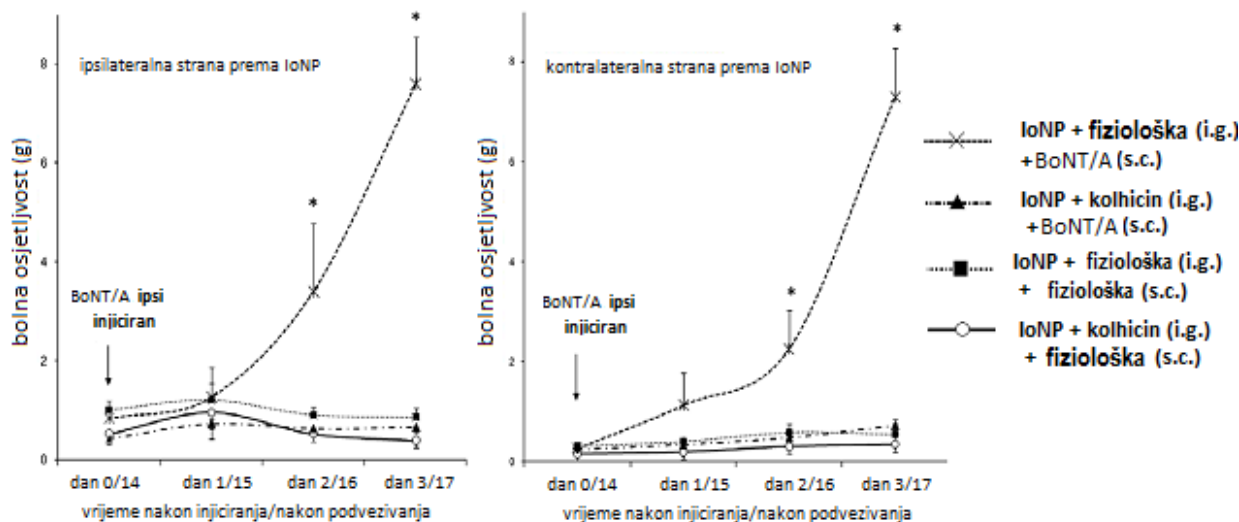


**Slika 33. Jednokratna primjena BoNT/A (3,5 i.j./kg, s.c.) smanjuje neurogenu upalu kranijalnih moždanih ovojnica u modelu neuropatske boli uzrokovane IoNP**

Fotografije su učinjene nakon perfuzije fiziološkom otopinom i odstranjenja moždanog tkiva. Legenda: IoNP - životinje s podvezanim lijevim infraorbitalnim živcem; kontrola - životinje koje su operirane, ali im nije podvezan infraorbitalni živac; IoNP + BoNT/A - životinje s podvezanim lijevim infraorbitalnim živcem koje su primile BoNT/A (3,5 i.j./kg) u ipsilateralnu stranu brkova u odnosu na ozljedu živca.

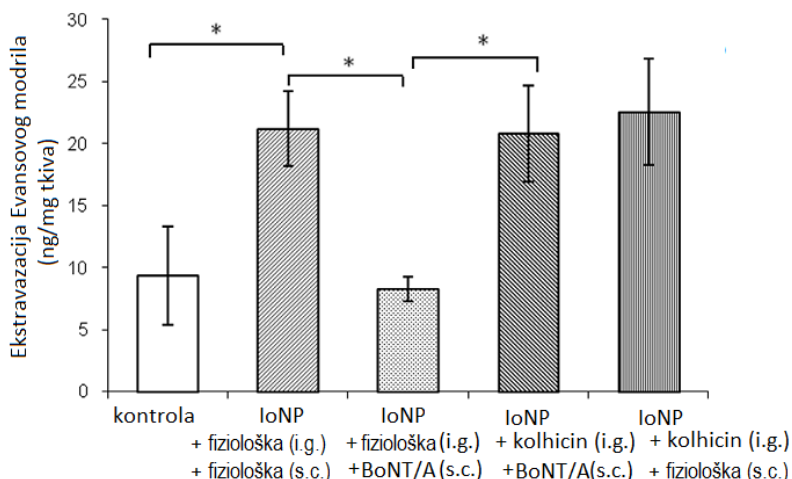
U dodatnom pokusu na modelu IoNP ispitivala se ovisnost učinka BoNT/A o aksonalnom transportu. Dva tjedna nakon podvezivanja infraorbitalnog živca životinje koje su razvile obostranu mehaničku alodiniju u području brkova štakora primile su otopinu kolhicina (2  $\mu$ L) u područje lijevog trigeminalnog ganglija. Nakon 24 sata istim je životinjama injicirano 20  $\mu$ L BoNT/A (3,5 i.j./kg) ili fiziološka otopina u područje brkova ipsilateralno ili kontralateralno u odnosu na ozljedu živca.

Mjerenje mehaničke osjetljivosti Von Freyevim filamentima provedeno je, kako je prethodno opisano, 1, 2 i 3 dana nakon injiciranja BoNT/A. Sam toksin je nakon jednokratne periferne primjene (neovisno o strani injiciranja) u dozi od 3,5 i.j./kg u područje brkova smanjio mehaničku alodiniju nakon 2 i 3 dana, kao i ekstravazaciju proteina plazme u moždane ovojnice u odnosu na skupinu životinja koja je u područje brkova primila fiziološku otopinu (slika 34). Primjena blokatora aksonalnog transporta u trigeminalni ganglij prije injiciranja BoNT/A potpuno je spriječila djelovanje BoNT/A na mehaničku alodiniju (slika 34) te na neurogenu upalu (slika 35).



**Slika 34. BoNT/A (3,5 i.j./kg, s.c.) obostrano smanjuje mehaničku alodiniju u modelu neuropatske boli, što se može spriječiti blokadom aksonalnog transporta (prema ref. Filipović i sur., 2012)<sup>227</sup>**

Životinje su injicirane u lijevi trigeminalni ganglij otopinom kolhicina (2  $\mu$ L), 24 h prije nego što je BoNT/A (3,5 i.j./kg) primijenjen s.c. (14 dana nakon podvezivanja lijevog infraorbitalnog živca, IoNP) u područje brkova štakora ipsilateralno u odnosu na ozljedu živca. Mehanička alodinija je mjerena Von Freyevim filamentima 0, 1, 2, 3 dana nakon injiciranja BoNT/A. Mjerena je sila u gramima koja je uzrokovala bolni odgovor nakon stimulacije područja brkova štakora Von Freyevim filamentima. Legenda: Kontrola: životinje koje su operirane, ali im nije podvezan infraorbitalni živac; IoNP + fizioška (i.g.) + fizioška (s.c.) - životinje s podvezanim lijevim infraorbitalnim živcem koje su primile fiziološku otopinu u lijevi trigeminalni ganglij i područje lijevih brkova; IoNP + fizioška (i.g.) + BoNT/A (s.c.) - životinje s podvezanim lijevim infraorbitalnim živcem koje su primile fiziološku otopinu u lijevi TG i BoNT/A (3,5 i.j./kg) u ipsilateralnu stranu brkova u odnosu na ozljedu živca; IoNP + kolhicin (i.g.) + fizioška (s.c.) - životinje s podvezanim lijevim infraorbitalnim živcem koje su primile kolhicin u lijevi TG i fiziološku otopinu u ipsilateralnu stranu brkova u odnosu na ozljedu živca; IoNP + kolhicin (i.g.) + BoNT/A (s.c.) - životinje s podvezanim lijevim infraorbitalnim živcem koje su primile kolhicin u lijevi TG i BoNT/A u ipsilateralnu stranu brkova u odnosu na ozljedu živca. Rezultati su prikazani kao aritmetička sredina  $\pm$  standardna srednja pogreška;  $n = 6$ . Vrijednosti kontrolne skupine nisu prikazane (iznosile su 12,5  $\pm$  0,5g). \* $p < 0,01$ , u usporedbi s IoNP + f.o. (i.g.) + f.o. (s.c.); IoNP + kolhicin (i.g.) + f.o. (s.c.); IoNP + kolhicin (i.g.) + BoNT/A (s.c.) (Tukeyov post hoc test).



**Slika 35. BoNT/A (3,5 i.j./kg, s.c.) obostrano smanjuje neurogenu upalu moždanih ovojnica u modelu neuropatske boli, što se može spriječiti blokadom aksonalnog transporta (prema ref. Filipović i sur., 2012)<sup>227</sup>**

Životinje su injicirane u lijevi trigeminalni ganglij otopinom kolhicina (2  $\mu$ L) 24 h prije nego što je BoNT/A (3,5 i.j./kg) primijenjen s.c. (14 dana nakon podvezivanja lijevog infraorbitalnog živca, IoNP) u područje brkova štakora ipsilateralno u odnosu na ozljedu živca. Neurogena upala moždanih ovojnica je mjerena kao količina Evansovog modrila izdvojenog iz duralnog tkiva (ng po mg tkiva). Analizirani uzorak se sastojao od spojenih duralnih uzoraka tkiva četiriju životinja. Legenda: Kontrola: životinje koje su operirane, ali im nije podvezan infraorbitalni živac; IoNP + fiziološka (i.g.) + fiziološka (s.c.) - životinje s podvezanim lijevim infraorbitalnim živcem koje su primile fiziološku otopinu u lijevi trigeminalni ganglij i područje lijevih brkova štakora; IoNP + fiziološka (i.g.) + BoNT/A (s.c.) - životinje s podvezanim lijevim infraorbitalnim živcem koje su primile fiziološku otopinu u lijevi TG i BoNT/A (3,5 i.j./kg) u ipsilateralnu stranu brkova u odnosu na ozljedu živca; IoNP + kolhicin (i.g.) + fiziološka (s.c.) - životinje s podvezanim lijevim infraorbitalnim živcem koje su primile kolhicin u lijevi TG i fiziološku otopinu u ipsilateralnu stranu brkova u odnosu na ozljedu živca; IoNP + kolhicin (i.g.) + BoNT/A (s.c.) - životinje s podvezanim lijevim infraorbitalnim živcem koje su primile kolhicin u lijevi TG i BoNT/A u ipsilateralnu stranu brkova u odnosu na ozljedu živca; i.g. intraganglijsko injiciranje; s.c. subkutano injiciranje. Rezultati su prikazani kao aritmetička sredina +/- standardna srednja pogreška; n = 6; \*p < 0,01 (Newman-Keulsov post hoc test).

#### 5.4.2. Karakterizacija djelovanja različitih analgetika na bol i neurogenu upalu

U modelu neuropatske boli uzrokovane podvezivanjem infraorbitalnog živca, IoNP, ispitivao se učinak na obostranu mehaničku alodiniju i neurogenu upalu kranijalnih moždanih ovojnica sljedećih supstancija: sumatriptana i zolmitriptana (175 mg/kg p.o.), opioidnog analgetika morfina (8 mg/kg, s.c), neopioidnog analgetika acetilsalicilne kiseline (200 mg/kg, p.o.) i lokalnog anestetika lidokaina (2%, 20  $\mu$ L, s.c.). Osjetljivost na mehanički podražaj mjerena je Von Freyevim filamentima, kako je prethodno opisano, a neurogena upala, izražena kao ekstravazacija proteina plazme u moždane ovojnice, mjerena je pomoću Evansovog modrila.



## A) TRIPTANI

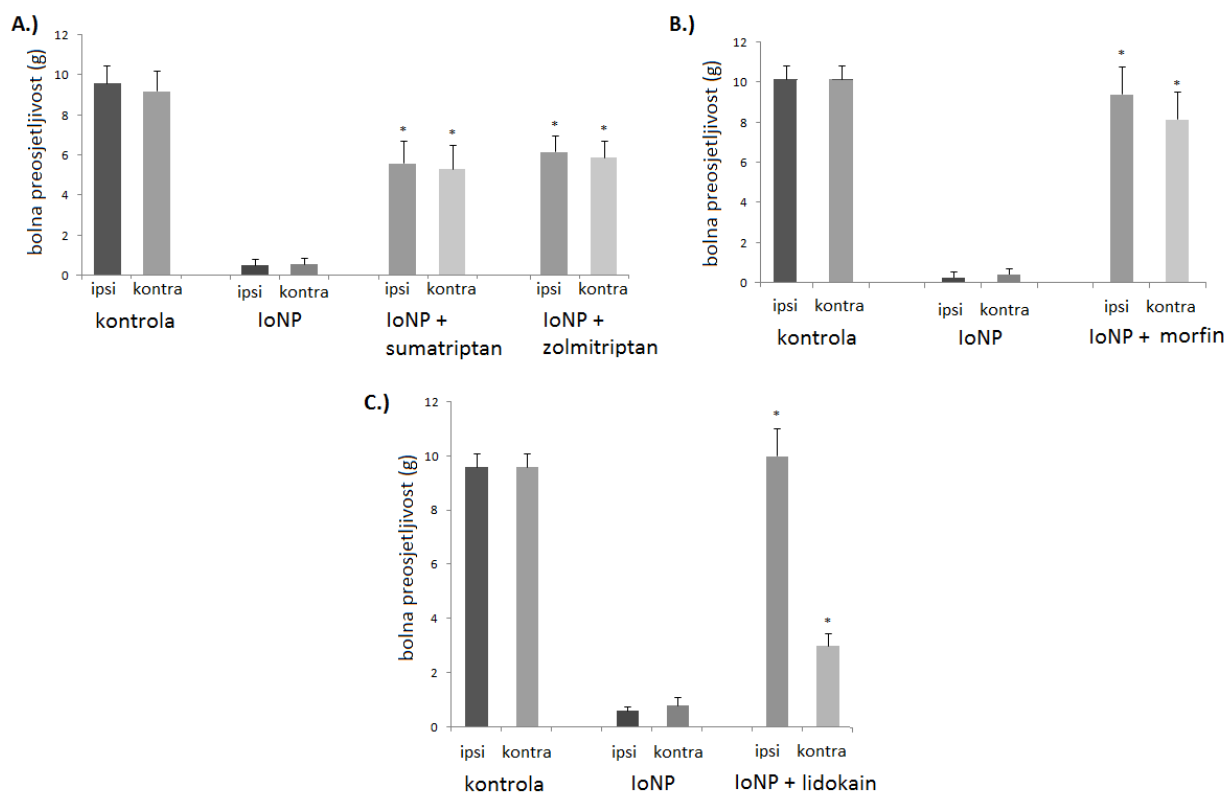
Osjetljivost na bolni mehanički podražaj u području brkova štakora mjerena je 2 sata nakon primjene sumatriptana (175 mg/kg p.o) i zolmitriptana (175 mg/kg p.o). Sumatriptan i zolmitriptan su statistički značajno smanjili mehaničku alodiniju obostrano (slika 36 A), kao i neurogenu upalu moždanih ovojnica u odnosu na skupinu životinja s neuropatskom boli (IoNP) (slika 37 A).

## B) MORFIN

Morfin (8 mg/kg, s.c.) je 1 sat nakon primjene gotovo potpuno poništio mehaničku hiperosjetljivost (slika 36 B) te neurogenu upalu moždanih ovojnica u odnosu na skupinu životinja s neuropatskom boli (IoNP) (slika 37 B).

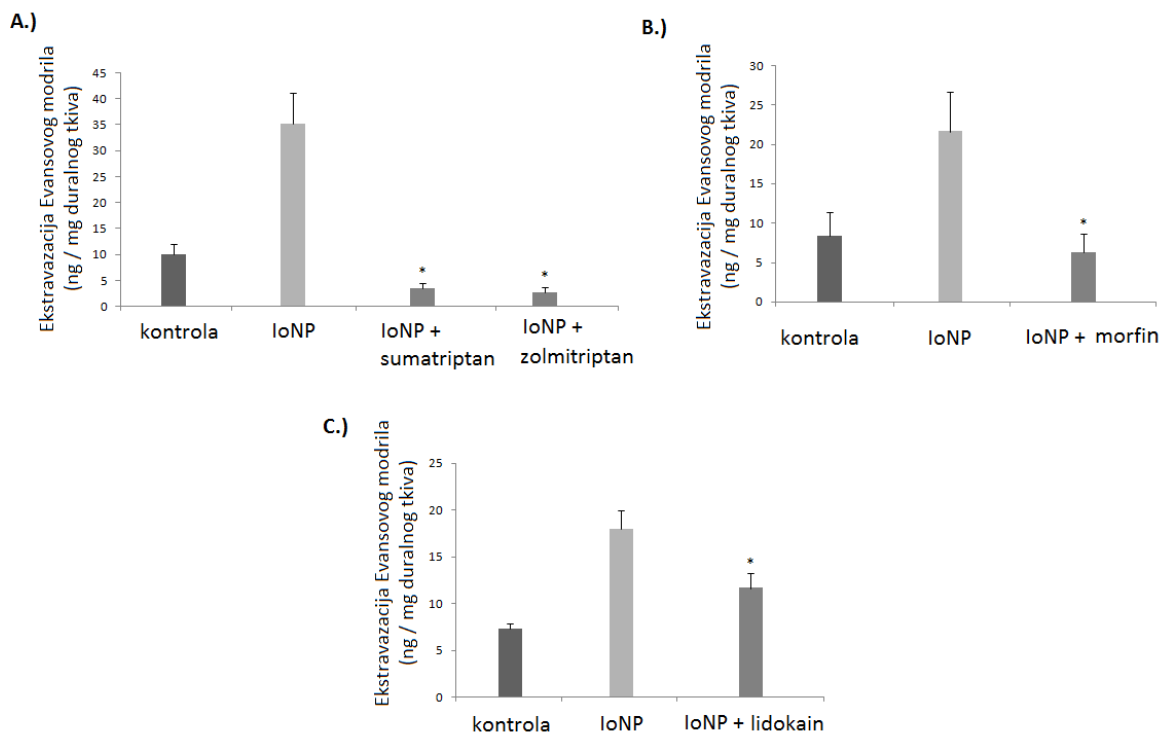
## C) LIDOKAIN

Lidokain (2%, 20 µl), primijenjen subkutano, jednokratno u područje brkova lijeve strane lica (ipsilateralna strana u odnosu na ozljedu živca) je 1 h nakon primjene statistički značajno smanjio mehaničku alodiniju obostrano (slika 36 C), kao i neurogenu upalu moždanih ovojnica u odnosu na skupinu životinja s neuropatskom boli (IoNP) (slika 37 C).



**Slika 36. Učinak različitih analgetika na obostranu mehaničku alodiniju u modelu neuropatske boli uzorkovane IoNP**

Mjeren je učinak različitih analgetika u životinja koje su 14 dana nakon podvezivanja lijevog infraorbitalnog živca (70% životinja) razvile obostranu mehaničku alodiniju (< 2 grama). Mjerena je sila u gramima koja je uzrokovala bolni odgovor nakon stimulacije područja brkova štakora Von Freyevim filamentima. A) Sumatriptan i zolmitriptan su primijenjeni peroralno u dozi od 175 mg/kg, a mehanička alodinija je mjerena 2 sata nakon primjene. B) Morfin je primijenjen subkutano u dozi od 8 mg/kg, a mehanička alodinija je mjerena 1 sat nakon primjene morfina. C) Lidokain je primijenjen jednokratno subkutano (2%, 20  $\mu$ l), a mehanička alodinija je mjerena 1 h nakon primjene lidokaina. Legenda: Ipsi - ipsilateralna strana lica u odnosu na ozljedu živca; kontra - kontralateralna strana lica u odnosu na ozljedu živca; - životinje s podvezanim lijevom infraorbitalnim živcem i razvijenom bolnom osjetljivošću; kontrola - životinje koje su operirane bez podvezivanja infraorbitalnog živca; IoNP + sumatriptan: životinje koje su primile sumatriptan peroralno u dozi od 175 mg/kg 14 dana nakon podvezivanja lijevog infraorbitalnog živca i s razvijenom bolnom osjetljivošću; IoNP + zolmitriptan: životinje koje su primile zolmitriptan peroralno u dozi od 175 mg/kg, 14 dana nakon podvezivanja lijevog infraorbitalnog živca i s razvijenom bolnom osjetljivošću; IoNP + morfin: životinje koje su primile morfin (8 mg/kg s.c.) 14 dana nakon podvezivanja lijevog infraorbitalnog živca i s razvijenom bolnom osjetljivošću; IoNP + lidokain: životinje koje su primile lidokain (2%, 20  $\mu$ . s.c.) u područje lijeve strane brkova 14 dana nakon podvezivanja lijevog infraorbitalnog živca i s razvijenom bolnom osjetljivošću. Rezultati su prikazani kao aritmetička sredina  $\pm$  standardna srednja pogreška; n = 6; \*p < 0,05, u usporedbi s IoNP (Newman-Keulsov post hoc test).



**Slika 37. Učinak različitih analgetika na neurogenu upalu moždanih ovojnica u modelu neuropatske boli uzorkovane IoNP**

Mjeren je učinak različitih analgetika u životinja koje su 14 dana nakon podvezivanja lijevog infraorbitalnog živca (70% životinja) razvile obostranu mehaničku alodiniju (< 2 grama). Neurogena upala moždanih ovojnica je mjerena kao količina Evansovog modrila izdvojenog iz duralnog tkiva (ng po mg tkiva). A) Sumatriptan i zolmitriptan su primijenjeni peroralno u dozi od 175 mg/kg, a neurogena upala moždanih ovojnica je mjerena 2 sata nakon primjene. B) Morfij je primijenjen subkutano u dozi od 8 mg/kg, a neurogena upala moždanih ovojnica je mjerena 1 sat nakon primjene morfina. C) Lidokain je primijenjen jednokratno subkutano (2%, 20  $\mu$ l), a neurogena upala moždanih ovojnica je mjerena 1 h nakon primjene lidokaina. Legenda: IoNP - životinje s podvezanim lijevim infraorbitalnim živcem i razvijenom bolnom osjetljivošću; kontrola - životinje koje su operirane bez podvezivanja infraorbitalnog živca; IoNP + sumatriptan: životinje koje su primile sumatriptan peroralno u dozi od 175 mg/kg 14 dana nakon podvezivanja lijevog infraorbitalnog živca i s razvijenom bolnom osjetljivošću; IoNP + zolmitriptan: životinje koje su primile zolmitriptan peroralno u dozi od 175 mg/kg 14 dana nakon podvezivanja lijevog infraorbitalnog živca i s razvijenom bolnom osjetljivošću; IoNP + morfin: životinje koje su primile morfin (8 mg/kg s.c.) 14 dana nakon podvezivanja lijevog infraorbitalnog živca i s razvijenom bolnom osjetljivošću; IoNP + lidokain: životinje koje su primile lidokain (2%, 20  $\mu$ . s.c.) u područje lijeve strane brkova 14 dana nakon podvezivanja lijevog infraorbitalnog živca i s razvijenom bolnom osjetljivošću. Rezultati su prikazani kao aritmetička sredina  $\pm$  standardna srednja pogreška; n = 6; \*p < 0,05, u usporedbi s IoNP (Newman-Keulsov post hoc test).

## 6. RASPRAVA

### 6.1. Neurogena upala moždanih ovojnica kao posljedica boli u trigeminalnom području

Različiti bolni podražaji na periferiji stimuliraju aferentna C-vlakna na izlučivanje neuropeptida, SP i CGRP, koji posljedično uzrokuju neurogenu upalu u tkivu koja se sastoji od tri komponente: vazodilatacije krvnih žila, ekstravazacije plazmatskih proteina i aktivacije proupalnih stanica.<sup>118</sup> Neurogena upala moždanih ovojnica (dure mater) je do sada istraživana u patofiziologiji boli u migreni.<sup>131</sup> U eksperimentalnim modelima migrene električna i kemijska stimulacija dijelova trigeminovaskularnog sustava (dure, trigeminalnog ganglija i dr.) uzrokuje nastanak svih triju komponenti neurogene upale dure.<sup>96,107,134,137</sup>

#### 6.1.1. Periferna ozljeda u području trigeminusa povezana je s neurogenom upalom u moždanim ovojnicama (duri mater)

Rezultati ove doktorske disertacije pokazuju da različite vrste ozljeda (upalna i ozljeda živaca) kraniofacijalnih struktura u trigeminalnoj regiji uzrokuju nastanak neurogene upale dure (slika 10, 13, 14, 17). Smatra se da je fenomen nastanka neurogene upale u tkivu udaljenom od mjesta ozljede rezultat transporta živčanog impulsa prema SŽS-u te zatim njegova preusmjerenja i anterogradnog širenja u drugo tkivo. Fenomen tako nastale neurogene upale još se naziva neurogeno prebacivanje, a alternativni je naziv preskakanje (engl. *neurogenic switching*) i do sada nije istraživano u moždanim ovojnicama nakon periferne ozljede.<sup>77</sup>

Sve tri grane trigeminalnog živca (V): n. ophtalmicus (V1), n. maxillaris (V2), n. mandibularis (V3), senzorno inerviraju duru i kraniofacijalne strukture. Međutim, riječ je o anatomski udaljenim i odvojenim, ekstrakranijalnim odnosno intrakranijalnim dijelovima V živca, primjerice: dura prednje lubanjske jame (engl. *anterior cranial fossa*) i svoda lubanje (supratentorijalna dura) je inervirana intrakranijalnim meningealnim ograncima V1 (meningealna grana nn. ethmoidales); ekstrakranijalna grana V1 izlazi iz baze lubanje na razini gornje orbitalne fisure i donosi senzornu inervaciju iz orbite, konjunktive oka, kože gornjeg kapka, dijela nosa i sinusa te kože frontalnog i parijentalnog dijela glave.<sup>89,196</sup> Podražaj kraniofacijalnih struktura stimulira periferne okončine primarnih trigeminalnih neurona, a retrogradnim širenjem živčanog impulsa aktiviraju se: 1) tijela primarnih neurona odnosno periferne jezgre trigeminusa unutar trigeminalnog ganglija; 2) a daljnjim širenjem impulsa kroz centralne okončine trigeminalnih primarnih neurona aktiviraju se sekundarni

trigeminalni neuroni odnosno centralne trigeminalne jezgre na razini moždanog debla i produžene moždine.<sup>197</sup>

Nastanak neurogene upale u udaljenom tkivu dure nakon perifernog bolnog podražaja može se objasniti međusobnom aktivacijom trigeminalnih neurona koji inerviraju kraniofacijalne strukture i duru na razini: 1) perifernih jezgri trigeminusa (trigeminalnog ganglija); 2) centralnih jezgri trigeminusa; 3) ili obje razine. Međusobna (unakrsna) aktivacija neurona (engl. *cross excitation*) je prije dokazana u trigeminalnom gangliju i gangliju stražnjih korjenova.<sup>198,199</sup> U modelu kemijskog podraživanja dure (apliciranjem na duru medijatora upale tipa: histamina, serotonin, bradikinin i dr.) nastanak neurogene upale dure te posljedično alodinije kraniofacijalnog područja se pripisuje međusobnoj aktivaciji neurona na razini centralnih jezgri trigeminusa.<sup>96,200</sup>

### ***6.1.2. Unilateralni periferni bolni podražaj uzrokuje bilateralnu alodiniju i neurogenu upalu dure***

U našim pokusima unilateralno injiciranje CFA u TMZ i podvezivanje infraorbitalnog živca uzrokovalo je nastanak bilateralne alodinije i neurogene upale dure (slika 13, slika 17). Premda mehanizam nastanka bilateralne alodinije nije dovoljno istražen, Samsam i suradnici su pokazali da unilateralna električna stimulacija trigeminalnog ganglija uzrokuje bilateralno smanjenje razine neuropeptida (SP, CGPR, neurokinin A) u centralnim jezgrama trigeminusa.<sup>201</sup> Jacquin i suradnici, 1990. godine, su dodatno pokazali da jedan dio centralnih okončina primarnih trigeminalnih neurona prelazi središnju liniju i završava u kontralateralnim stražnjim rogovima na centralnim jezgrama trigeminusa.<sup>202</sup> U skladu s navedenim rezultatima možemo pretpostaviti da su bilateralna alodinija i neurogena upala dure rezultat retrogradnog širenja bolnog impulsa s periferije prema SŽS-u, koji aktivira ipsilateralne, ali i kontralateralne centralne jezgre trigeminusa, od kojih polazi senzorna inervacija kraniofacijalnih struktura, kao i dure.

### ***6.1.3. Pojavnost i intenzitet neurogene upale dure ovise o intenzitetu i trajanju perifernog bolnog podražaja***

Pojavnost i intenzitet neurogene upale u nekom tkivu ovise o više faktora: intenzitetu i trajanju bolnog podražaja; zastupljenosti senzornih C-vlakana u tkivu; koncentraciji neuropeptida (SP i CGRP) u vlaknima; zastupljenosti receptora za neuropeptide u tkivu; koncentraciji tkivnih neuropeptidaza.<sup>118</sup>

Naši rezultati potvrđuju da pojavnost neurogene upale dure ovisi o intenzitetu perifernog bolnog podražaja (slika 11). Bolni podražaj slabijeg intenziteta (primjerice injiciranje 1%-tnog formalina u područje brkova štakora) nije uzrokovao nastanak neurogene upale dure za razliku od podražaja jačeg intenziteta uzrokovanog primjenom 2,5%-tnog i 5%-tnog formalina. Calavelou i suradnici, 1995. godine, su pokazali da tek primjena 1,5%-tne i 2,5%-tne otopine formalina u orofacijalnom testu u štakora uzrokuje bol u drugoj fazi (15 – 45 minuta nakon injiciranja formalina) koja je, pretpostavlja se, posljedica aktivacije centralnih jezgri trigeminusa i centralne senzitivizacije.<sup>203</sup> Razvijanje neurogene upale ovisno o koncentraciji primijenjenog formalina u našem pokusu potvrđuje da je za nastanak neurogene upale dure potreban periferni bolni podražaj određenog intenziteta koji može uzrokovati aktivaciju centralnih jezgri trigeminusa i procese centralne senzitivizacije.

Potrebno je dodatno istaknuti da viša koncentracija formalina (5% u odnosu na 2,5%), odnosno jači kemijski podražaj, nije uzrokovala povećanje bolnog odgovora u drugoj fazi formalinskog testa ni intenzivniju upalu u duri (slika 11). To može značiti da se pri takvoj vrsti i mjestu perifernog podražaja (formalin, područje brkova štakora), a pri koncentraciji formalina od 2,5% postiže maksimalna stimulacija duralnih C-vlakana i plato u izlučivanju neuropeptida u duri, što posljedično rezultira i maksimalnim intenzitetom neurogene upale.

U našim pokusima pojavnost i intenzitet neurogene upale dure ovise o vremenu koje je prošlo nakon kemijske indukcije bolnog podražaja (slika 12, slika 15). U pokusu s formalinskim testom najveći intenzitet neurogene upale dure (mjerena kao ekstravazacija plazmatskih proteina) je postignut između 30 i 60 minuta od injiciranja 2,5%-tnog formalina. Nakon 4 sata upala se blago smanjila, a 24 h od kemijskog podražaja je nestala. Možemo zaključiti da izlučivanje neuropeptida u duri u akutnoj boli ovisi o bolnom podražaju s periferije. Slabljenje intenziteta perifernog bolnog podražaja s vremenom prati smanjenje i nestanak neurogene upale dure. Međutim, što je logično, neurogena upala dure prisutna je duže u tkivu u odnosu na trajanje bolnog podražaja u formalinskom testu.

U pokusu s kroničnom boli, upalnom boli temporomandibularnog zgloba nakon injiciranja otopine CFA, najveći intenzitet neurogene upale je dobiven 7 dana od injiciranja CFA (slika 15). Nakon 14 dana neurogena upala dure ima intenciju smanjenja te se može zaključiti da pad intenziteta upale prati smanjenje intenziteta kronične boli.

#### **6.1.4. Neurogena upala dure ovisi o prijenosu bolnog podražaja s periferije**

Prethodno je pokazano da kronična bol s razvijenom središnjom senzitivacijom (pojava hiperalgezije i alodinije) nije ovisna o stimulaciji nociceptora na periferiji.<sup>25,26</sup> Stoga smo željeli ispitati je li pojavnost neurogene upale dure ovisna o prijenosu bolnog podražaja s periferije u modelima kronične boli.

U tu svrhu smo injicirali lokalni anestetik (lidokain) u područje brkova štakora s razvijenom neuropatskom boli, 14 dana nakon ozljede infraorbitalnog živca. Lokalni anestetici ostvaruju antinociceptivni učinak blokiranjem ionskih Na<sup>+</sup> kanala na perifernim okončinama nociceptora, smanjujući pritom stvaranje živčanog impulsa i prienos bolnog signala prema SŽS-u.<sup>204</sup> U našem pokusu lidokain je smanjio neurogenu upalu dure (slika 36, slika 37), na temelju čega možemo zaključiti da izlučivanje neuropeptida u duri, koji održavaju neurogenu upalu dure pri kroničnoj boli (uz razvijenu centralnu senzitivaciju), također ovisi o prijenosu bolnog podražaja s periferije.

#### **6.1.5. Periferna bol uzrokuje nastanak dviju komponenti neurogene upale dure**

Neurogenu upalu dure u migreni karakteriziraju tri komponente: vazodilatacija duralnih krvnih žila, ekstravazacija plazmatskih proteina i aktivacija proupalnih stanica u duri.<sup>131</sup> U eksperimentalnim modelima migrene pojedine se komponente neurogene upale dure pojavljuju nakon stimulacije određenih senzornih vlakana (C, A $\delta$ ) i izlučivanja specifičnih neuropeptida (CGRP, SP).<sup>96,107,134,137</sup> Tako je pokazano da se stimulacijom duralnih C aferentnih vlakana luči SP, koji preko receptora NK<sub>1</sub> na duralnim krvnim žilama uzrokuje ekstravazaciju proteina plazme.<sup>134</sup> Stimulacijom duralnih C i A $\delta$  vlakana izlučuje se CGRP, koji djelovanjem na receptore CGRP<sub>1</sub> na duralnim krvnim žilama uzrokuje vazodilataciju, te preko receptora na membranama mastocita njihovu aktivaciju.<sup>104,110,137</sup> Aktivacija mastocita također ovisi o ekspresiji receptora NK<sub>1</sub>, a osim CGRP-a mogu je uzrokovati i druge vrste neuropeptida (SP, VIP, pituarni adenil ciklaza aktivirajući peptid-38).<sup>111,112,113,114</sup> Na temelju rezultata tih studija možemo raspravljati o potencijalnim mehanizmima nastanka neurogene upale dure nakon uzrokovanja boli na periferiji. Naši rezultati jasno pokazuju da se neurogena upala dure sastoji od ekstravazacije plazmatskih proteina i infiltracije proupalnih stanica u duri (slika 10, slika 13, slika 14, slika 16, slika 17, slika 18, slika 19).

Premda nismo izravno mjerili duralnu vazodilataciju, pokazali smo da periferna bol uzrokovana injiciranjem CFA u TMZ uzrokuje povišenje vrijednosti koncentracije CGRP-a u duri.<sup>205</sup> Budući da je duralna vazodilatacija u duri posredovana izlučivanjem CGRP-a te da se SP i CGRP nalaze kolokalizirani u istim duralnim neuronima,<sup>206</sup> možemo pretpostaviti da

pojavnost duralne ektravazacije i proupalnih stanica u duri nije moguća ako ih ne prati i duralna vazodilatacija.

Prema našim rezultatima čini se da upalna i neuropatska bol iz trigeminalne regije uzrokuju dominantnu stimulaciju duralnih C aferentnih vlakana i izlučivanje neuropeptida SP i CGRP u duri, što se povezuje s nastankom neurogene upale. Suprotno tome, ne možemo sa sigurnošću tvrditi da periferna bol uzokuje i stimulaciju duralnih A $\delta$  vlakana budući da se njihovom aktivacijom isključivo luči CGRP.<sup>137</sup> Premda su izmjerene povišene vrijednosti toga neuropeptida u duri,<sup>205</sup> one mogu biti posljedica pojačane neuronalne ekspresije peptida zbog aktivacije senzornih C-vlakana.

#### ***6.1.6. Stanična komponenta neurogene upale dure uključuje više vrsta proupalnih stanica***

Do sada je bilo poznato da se stanična komponenta neurogene upale dure u modelima migrene sastoji od aktiviranih mastocita i trombocita, dok druge vrste proupalnih stanica nisu bile opisane.<sup>105,106,107</sup> U našim pokusima pokazan je porast apsolutnog broja stanica u supratentorijalnoj duri nakon uzrokovanja upalne i neuropatske boli (slika 16, slika 18). Dodatnom karakterizacijom identificirani su specifični tipovi upalnih stanica u duri: mononuklearni leukociti (limfociti), nezreli mastociti, plazma stanice i monociti uz tkivne mastocite koji su jedini bili vizualizirani i u kontrolnim uzorcima tkiva dure (slika 16, slika 19). U duri nisu identificirani polimorfonuklearni leukociti (neutrofil), čime je isključena mogućnost da je upala uzrokovana infekcijom.

Stimulacija degranulacije mastocita ili direktno apliciranje sastojaka njihovih granula na duru (histamin, serotonin i dr.) uzokuje prolongiranu ekscitaciju meningealnih nociceptora te rezultira aktivacijom spinalnih jezgri trigeminusa mjerenu c-fos ekspresijom.<sup>108,109</sup> U skladu s tim nalazima pretpostavlja se da duralni mastociti doprinose procesu neurogene upale dure te sudjeluju u perifernoj i centralnoj senzitivaciji trigeminalnog sustava u migreni.<sup>112,115</sup>

Možemo pretpostaviti da u našim modelima neuropatske boli (14 dana), akutne (24 sata) i kronične upalne boli (14 dana) započeti i neprekinuti procesi senzitivacije uzrokuju daljnje izlučivanje neuropeptida i proupalnih medijatora, što rezultira dodatnom regrutacijom proupalnih stanica. S druge strane, nepojavljivanje dodatnih proupalnih stanica nakon antidromne električne stimulacije ganglija (5 minuta),<sup>134</sup> može biti rezultat primjene podražaja kratkog trajanja.



### **6.1.7. Neurogena upala dure u upalnoj i neuropatskoj boli i procesi periferne i centralne senzitivacije**

Za patogenezu upalne i neuropatske boli posebno su važni procesi periferne i centralne senzitivacije koji uključuju: aktivaciju tzv. tihih nociceptora; promjenu aktivnosti receptora (NMDA, CGRP-1 i dr.); disregulaciju ionskih kanala (Nav, K, TRPV1, i dr.); aktivaciju signalnih unutarstaničnih putova ovisnih o Ca<sup>2+</sup> (PKA, CREB i dr.); transkripciju gena i stvaranje novih neuromodulatora (SP, CGRP) i receptora (NMDA, CGRP).<sup>15,19,39,40,207</sup> Također, u procesima periferne senzitivacije kod upalne i neuropatske boli sudjeluje i neurogena upala u lokalnom tkivu.<sup>118</sup> U eksperimentalnim modelima migrene (primjerice, direktna električna stimulacija dure ili kemijska stimulacija apliciranjem medijatora upale) nastala neurogena upala dure uzrokuje ekscitaciju duralnih nociceptora i aktivaciju primarnih i sekundarnih trigeminalnih jezgri (mjerenu kroz c-fos ekspresiju), čime sudjeluje u procesima periferne, ali i centralne senzitivacije.<sup>96,108,138,139</sup>

Na temelju naših rezultata, u kojima je pokazano da različite vrste perifernih ozljeda (akutna i kronična upala, ozljeda živca) rezultiraju nastankom neurogene upale dure, možemo pretpostaviti (nismo direktno mjerili, primjerice, c-fos ekspresiju) da neurogena upala dure ima ulogu u održavanju periferne i centralne senzitivacije trigeminalnog sustava ne samo u migrenoznoj boli, već i u upalnoj i neuropatskoj boli, što do sada nije bilo pokazano, međutim zahtijeva dodatna ispitivanja.

### **6.1.8. Neurogena upala dure u neuropatskoj boli sudjeluje u konačnoj percepciji boli**

Prethodno je pokazano da su analgetici s različitim mehanizmima djelovanja efikasni u blokiranju neurogene upale dure u eksperimentalnim modelima migrene.<sup>149,150,208,209</sup> Također, oni smanjuju bolni odgovor *in vivo* (češanje područja brkova) nastao električnom stimulacijom dure u budnih štakora.<sup>210</sup> S tim u skladu smatra se da je blokiranje neurogene upale dure jedan od mehanizama smanjenja migrenozne boli.

U našim istraživanjima željeli smo ispitati je li neurogena upala dure u neuropatskoj boli samo reakcija na bolni podražaj s periferije ili njezina pojavnost utječe i na percepciju boli. U tu svrhu koristili smo se analgeticima (triptani, morfij) s perifernim i/ili centralnim mehanizmom djelovanja koji blokiraju neurogenu upalu dure u eksperimentalnim modelima migrene.

#### a) Triptani (sumatriptan i zolmitriptan)

Triptani (agonisti serotoninergičnih receptora) su jedni od učinkovitijih lijekova u terapiji migrenozne boli, koji postižu učinak djelujući na periferne (krvne žile i okončine duralnih trigeminalnih neurona) i centralne dijelove trigeminovaskularnog sustava (trigeminalne jezgre).<sup>211</sup> Triptani direktno blokiraju duralnu ekstravazaciju presinaptičkim blokiranjem izlučivanja SP-a preko receptora 5-HT<sub>1D</sub> na okončinama duralnih C-vlakana.<sup>137</sup> Blokiranje duralne vazodilatacije triptani ostvaruju presinaptičkim blokiranjem izlučivanja CGRP-a preko receptora 5-HT<sub>1B</sub> na okončinama duralnih A $\delta$  i C-vlakana.<sup>137</sup> Učinak na centralne jezgre triptani ostvaruju preko receptora 5-HT<sub>1B/1D</sub> na centralnim okončinama perifernih trigeminalnih neurona, presinaptičkim blokiranjem izlučivanja CGRP-a.<sup>143,147</sup> Zanimljivo je istaknuti da triptani djeluju na aktivnost centralnih trigeminalnih jezgri kada se primjenjuju prije nego što su se procesi centralne senzitivacije potpuno razvili, odnosno smatra se da su učinkoviti jedino u fazi njihove indukcije.<sup>146</sup>

U našim pokusima sumatriptan i zolmitriptan su nakon per os primjene blokirali ekstravazaciju proteina plazme u kranijalnoj duri u modelu neuropatske boli, IoNP, što je rezultiralo smanjenim bilateralnim bolnim odgovorom (alodinija) u štakora (slika 36, slika 37). S obzirom na to da aktivnost centralnih jezgri trigeminusa u našim pokusima nismo mjerili, možemo pretpostaviti da su triptani blokirali nastanak duralne ekstravazacije presinaptičkim blokiranjem: a) izlučivanja SP-a aktivacijom receptora 5-HT<sub>1D</sub> na perifernim okončinama duralnih C-vlakana; b) izlučivanja CGRP-a aktivacijom receptora 5-HT<sub>1B/1D</sub> na centralnim okončinama perifernih trigeminalnih neurona. Međutim ne možemo sa sigurnošću tvrditi da je blokiranje neurogene upale dure direktno rezultiralo smanjenjem obostrane alodinije.

Također je zanimljivo da su oba triptana bila učinkovita u smanjenju obaju fenomena (alodinije i neurogene upale), usprkos tome što su bili primijenjeni u kroničnoj fazi (14 dana nakon podvezivanja živca) s već razvijenom centralnom senzitivacijom. Ti su rezultati suprotni rezultatima Bursteina i suradnika, iz 2004. godine, koji su pokazali da su triptani učinkoviti jedino kada su primijenjeni u fazi indukcije centralne senzitivacije.<sup>146</sup>

#### b) Opioidni analgetici (morfin)

Opioidni analgetici su agonisti opioidnih receptora ( $\mu$ ,  $\delta$ ,  $\kappa$ ) čija je kolokalizacija pokazana u neuronima trigeminalnog ganglija koji sadržavaju CGRP.<sup>212</sup> Opioidi se koriste u liječenju težih oblika migrenozne boli, a smatra se da je mehanizam njihova djelovanja u migreni sličan agonistima receptora 5-HT<sub>1B/1D</sub>: 1) periferni – inhibicija izlučivanja neuropeptida iz okončina

duralnih trigeminalnih neurona; 2) centralni – inhibicija aktivnosti centralnih trigeminalnih jezgri.<sup>213</sup> Morfin, selektivni agonist  $\mu$ - $\delta$  receptora,<sup>152</sup> u eksperimentalnim modelima migrene blokira duralnu ekstravazaciju<sup>153</sup> i aktivaciju trigeminalnih jezgri.<sup>154,214</sup> Morfin također smanjuje duralnu vazodilataciju presinaptičkim blokiranjem izlučivanja CGRP-a preko  $\mu$  receptora na perifernim trigeminalnim okončinama.<sup>154</sup>

U našim pokusima morfin primijenjen u dozi od 8 mg/kg s.c. u područje abdomena je blokirao duralnu ekstravazaciju u modelu neuropatske boli te obostrano smanjio bolni odgovor (alodiniju) u štakora (slika 36, slika 37). Međutim, kao i u pokusu s triptanima, aktivnost centralnih jezgri trigeminusa nismo mjerili, stoga možemo samo pretpostaviti da je njegov učinak na neurogenu upalu dure posredovan perifernim i/ili centralnim mehanizmima. Također, ne možemo sa sigurnošću tvrditi da je blokiranje neurogene upale dure direktno rezultiralo smanjenjem obostrane alodinije u našim pokusima.

## **6.2. Neurogena upala kao specifična reakcija kranijalne dure na periferni bolni podražaj iz područja glave i vrata**

Jedan od naših ciljeva bio je istražiti je li neurogena upala kranijalne dure specifična reakcija na bolni podražaj iz trigeminalne regije ili se javlja kao generalni odgovor na bolni podražaj iz različitih područja glave i vrata, odnosno tijela općenito. Naši rezultati pokazuju da je neurogena upala kranijalne dure specifična reakcija na bolni podražaj podrijetlom iz područja glave i vrata koje je najvećim dijelom senzorno inervirano trigeminalnim i okcipitalnim živcem.<sup>196</sup>

Naši dosadašnji rezultati su pokazali da se intenzivna neurogena upala dure javlja nakon uzrokovanja boli u području trigeminalne inervacije, odnosno nakon injiciranja formalina u orofacijalnom testu, nakon ozljede infraorbitalnog živca i injiciranja CFA u TMZ (slika 10, slika 13, slika 17), što se može objasniti senzornom inervacijom kranijalne dure koja se većinom odvija preko trigeminalnog živca i uključuje senzorna C-vlakna.<sup>89,118,196</sup>

Manja, ali statistički značajna razina neurogene upale kranijalne dure je uzrokovana i neuropatskom boli iz okcipitalne regije (GoNP) (slika 20).<sup>215</sup> Model podvezivanja velikog okcipitalnog živca, GoNP, prvi je put razvijen u našem laboratoriju za potrebe istraživanja na ovoj doktorskoj disertaciji. Dodatna zanimljivost modela je u tome što podvezivanje okcipitalnog živca (senzorna inervacija područja stražnjeg dijela glave i vrata u štakora) uzrokuje bilateralnu mehaničku alodiniju područja njuške/brkova štakora koja je inervirana trigeminalnim živcem (slika 20). Patofiziologija obaju fenomena, alodinije i neurogene upale

kranijalne dure, može se objasniti međusobnom aktivacijom trigeminalnih i okcipitalnih neurona na različitim razinama:

1) blizinom i preklapanjem perifernih (kutanih) inervacijskih područja okcipitalnog i trigeminalnog živca u štakora.<sup>196</sup>

2) dura stražnje lubanjske jame je direktno senzorno inervirana osjetnim spinalnim živcima C2 i C3 (veliki okcipitalni živac je grana spinalnog živca C2).<sup>91</sup> Međutim u svim našim ispitivanjima testirali smo neurogenu upalu supratentorialne dure i prednje lubanjske jame koje su senzorno inervirane trigeminusom (V1-V3).<sup>89,196</sup> Hipotetski, alodinija i neurogena upala mogu biti posljedica blizine i međusobne aktivacije spinalnih (C2 i C3) i trigeminalnih (V1-V3) duralnih okončina živaca.

3) pokazano je da se konvergencija i međusobna aktivacija trigeminalnih i okcipitalnih neurona događa na razini njihovih sekundarnih jezgri u produženoj moždini, u takozvanom trigeminalno-cervikalnom kompleksu.<sup>216,217</sup> Na taj se način objašnjava nastanak cervikogenih glavobolja, kada podražaji podrijetlom iz stražnjeg dijela glave i vrata uzrokuju ili pogoršavaju razne tipove glavobolja, uključujući migrenu, glavobolje lokalizirane u frontalnoj i temporalnoj regiji.<sup>218</sup>

Bol podrijetlom iz drugih dijelova tijela (šapa štakora) nakon ozljede senzornih živaca u modelima podvezivanja i parcijalnog presijecanja ishijadičnog živca (INPP i INP) nije uzrokovala neurogenu upalu dure kranijalnog područja (slika 21, slika 22). Time smo dokazali da se neurogena upala dure kranijalne regije ne javlja kao dio generalnog odgovora na bolni podražaj iz različitih dijelova tijela, već je vezana uz periferni bolni podražaj iz područja glave i vrata.

### **6.3. Lumbalna dura nema sposobnost razvoja neurogene upale nakon perifernog bolnog podražaja**

S obzirom na opaženi fenomen kranijalne neurogene upale nakon uzrokovanja boli u području glave i vrata (u području trigeminalne i okcipitalne inervacije), željeli smo dodatno istražiti moguću pojavu neurogene upale lumbalne dure nakon perifernog bolnog podražaja. Neuropatska bol uzrokovana oštećenjem perifernog živca ishijadikusa u dva eksperimentalna modela (INPP i INP), nije uzrokovala neurogenu upalu lumbalne dure, odnosno nije uzrokovala ekstrasvazaciju proteina plazme ni aktivaciju proupalnih stanica (slika 23, slika 24, slika 25).

Jedno od mogućih objašnjenja takvih rezultata može biti što lumbalna dura u štakora ima općenito manju gustoću senzornih CGRP pozitivnih vlakana i populaciju proupalnih stanica,<sup>219</sup> a postoje i velike razlike u anatomiji i senzornoj inervaciji u odnosu na kranijalnu duru.<sup>220</sup> Međutim Xanthos i suradnici, 2011. godine, su pokazali porast broja mastocita lumbalne dure u modelima upalne boli (uzrokovane kapsaicinom i karagenanom) bez drugih znakova neurogene upale dure poput ekstavazacije proteina plazme.<sup>221</sup> Također je pokazano da laminektomija u štakora uzrokuje porast duralnih lumbalnih vlakana koja sadržavaju neuropeptide SP i CGRP, na temelju čega su autori zaključili da bi porast u razini tih neuropeptida mogao biti važan patofiziološki mehanizam nastanak bolova u donjem dijelu leđa pacijenata nakon operacije lumbalne kralježnice.<sup>222</sup>

Rezultati ove disertacije nisu u skladu s rezultatima nekih istraživanja i pokazuju da se neurogena upala lumbalne dure ne razvija nakon perifernog bolnog podražaja u štakora. Međutim treba spomenuti razlike između vrsta životinja koje se koriste u istraživanjima. Primjerice, lumbalna dura u kunića za razliku od štakora ima veliku distribuciju senzornih vlakana koja luče neuropeptide SP i CGRP.<sup>219</sup> S obzirom na kontradiktorne rezultate istraživanja, pri čemu izbor vrste životinja, bolnog podražaja, ali i način mjerenja, odnosno kvantificiranja neurogene upale lumbalne dure u velikoj mjeri utječe na rezultate, ne možemo sa sigurnošću zaključiti događa li se neurogena upala lumbalne dure zbog ozljeda na periferiji.

#### **6.4. Antinociceptivni učinak BoNT/A u migreni**

Do sada je pokazan učinak BoNT/A u bolnim poremećajima kao što su kronične dnevne glavobolje, intersticijski cistitis, kronični artritis, postkirurška bol, fantomska bol, bolne distonije i drugi.<sup>163,164,165</sup> Primjena BoNT/A u liječenju migrene odobrena je 2010. godine.<sup>174,175</sup> Antinociceptivni učinak pokazan je i u eksperimentalnim modelima boli kao što su upalna bol uzrokovana karagenanom, kapsaicinom, formalinom, dijabetička neuropatija i neuropatija trigeminusa.<sup>158,159,160,161</sup> Rezultati ove disertacije također pokazuju učinak BoNT/A u modelu postkirurške boli, koji ovisi o primijenjenoj dozi toksina i dugotrajan je nakon jednokratno primijenjene doze (slika 27).<sup>223</sup>

O mjestu i mehanizmu antinociceptivnog djelovanja BoNT/A postoje proturječna mišljenja. Prema perifernoj hipotezi, nakon lokalnog injiciranja BoNT/A djeluje na okončine perifernih senzornih živaca: a) blokirajući izlučivanje neurotransmitora i neuropeptida (SP, CGRP);<sup>167</sup> i/ili b) mijenjajući zastupljenost ionskih kanala (TRPV1) na njihovim membranama.<sup>168</sup>

U prilog centralnom mjestu djelovanja BoNT/A govore rezultati više od 10 godina istraživanja iz našeg laboratorija. Koristeći se različitim eksperimentalnim modelima boli pokazali smo da nakon periferne primjene BoNT/A putuje retrogradnim aksonalnim transportom u SŽS, gdje cijepa SNAP-25, protein važan za neuroegzocitozu. U modelima bilateralne boli unilateralno injiciran BoNT/A je smanjio obostranu hiperosjetljivost na mehaničke podražaje, a primijenjen u spinalni kanal djeluje brže i u nekoliko puta nižim dozama u usporedbi s perifernom subkutanom primjenom.<sup>169,170,171,172,173</sup> Pokazali smo također da mehanizam antinociceptivnog djelovanja BoNT/A u trigeminalnoj regiji ovisi o neuronima osjetljivima na kapsaicin pri čemu je pokazana kolokalizacija enzimske aktivnosti BoNT/A (pocijepani SNAP-25) s receptorima TRPV-1 na centralnim okončinama perifernih trigeminalnih neurona u moždanom deblu.<sup>173</sup> Autori smatraju da BoNT/A nakon perifernog injiciranja u područje brkova štakora aksonalnim transportom putuje do centralnih okončina perifernih neurona i ondje sudjeluje u: a) izlučivanju glutamata i drugih neurotransmitora; i/ili b) translokaciji ionskih receptora TRPV-1, koja je ovisna o SNAP-25.<sup>224</sup> Naša nedavna istraživanja pokazuju da je mehanizam centralnog djelovanja BoNT/A povezan s endogenim sustavima kontrole boli, opioidnim i GABA-ergičkim.<sup>225,226</sup>

BoNT/A je registrirani lijek za kroničnu migrenu, a prema terapijskom protokolu se primjenjuje lokalno, injiciranjem u više mjesta na glavi i vratu.<sup>175</sup> Međutim potencijalni mehanizam i mjesto djelovanja BoNT/A do sada nisu istraživani na eksperimentalnim modelima migrene. Patofiziologija migrenozne boli uključuje disfunkciju SŽS-a koja rezultira aktivacijom trigeminovaskularnog sustava i neurogenom upalom dure.<sup>131,134</sup> Također, specifični (primjerice triptani, dihidroergotami, antagonisti receptora CGRP) i nespecifični anagletici (primjerice nesteriodni antireumatici, morfin) koji se koriste u liječenju migrene djeluju na neurogenu upalu dure u eksperimentalnim modelima migrene.<sup>149,150,208,209</sup> Duralni neuroni koji sudjeluju u migrenoznoj nocicepciji i ekstrakranijalni neuroni koji inerviraju mjesta perifernog injiciranja BoNT/A u migreni su anatomski udaljeni i odvojeni dijelovi trigeminalnog živca.<sup>89</sup> S obzirom na to učinak BoNT/A na migrenoznu bol je teško objasniti isključivo njegovim perifernim djelovanjem na mjestu injiciranja.

Učinak BoNT/A na trigeminovaskularnu aktivaciju, odnosno neurogenu upalu dure, do sada nije bio istraživani. U našim smo se pokusima za aktivaciju trigeminovaskularnog sustava koristili različitim vrstama periferne boli u trigeminalnom području, poput orofacijalnog formalinskog testa,<sup>215</sup> modela neuropatske boli nakon ozljede infraorbitalnog živca<sup>227</sup> i modela kronične upalne boli TMZ.<sup>205</sup> Dodatna prednost ovih modela u odnosu na npr. model

električne stimulacije trigeminalnog ganglija je mogućnost istodobnog praćenja dvaju fenomena: neurogene upale dure i nocicepcije.<sup>134</sup>

BoNT/A je u bihevioralnim testovima smanjio hiperalgeziju u modelu upalne boli kratkog trajanja (druga faza formalinskog testa) i alodiniju u modelima kronične upale i neuropatske boli (slika 26, slika 28, slika 31). Sljedeći bihevioralni nalazi govore u prilog centralnom mjestu i mehanizmu antinociceptivnog djelovanja BoNT/A:

1) učinak na bilateralnu alodiniju i to nakon: a) unilateralnog injiciranja (slika 26, slika 28, slika 31); b) injiciranja u kontralateralnu stranu od mjesta bolnog podražaja (slika 31); c) intraganglijskog injiciranja (slika 28)

2) učinak na bilateralnu alodiniju je potpuno poništen blokadom aksonalnog transporta BoNT/A kroz trigeminalni ganglij (prethodnim injiciranjem otopine kolhicina u ganglij) (slika 34).

Protokol apliciranja BoNT/A u kroničnoj migreni sastoji se od ukupno 31 injekcijskog mjesta na glavi i vratu.<sup>175</sup> Sličan protokol je teško primijeniti u štakora zbog malih kranijalnih dimezija. Iz toga razloga injicirali smo BoNT/A (s.c.) bilateralno u područje čela (inervirano oftalmičkom-V1 granom) i brkova štakora (inervirano maksilarnom-V2 granom). Tako primijenjen BoNT/A u četiri mjesta na glavi štakora je spriječio bol uzrokovanu CFA i neurogenu upalu dure slično kao i BoNT/A injiciran u jednoj dozi u temporomandibularni zglob.<sup>205</sup> Na taj način smo pokazali da učinak BoNT/A na alodiniju i duralnu upalu nije posredovan njegovim izravnim perifernim učinkom na neurone stimulirane CFA.

Prije je navedeno da specifični neuropeptidi u duri sudjeluju u nastanku pojedinih komponenti neurogene upale: SP u ekstravazaciji proteina plazme;<sup>134</sup> CGRP u vazodilataciji;<sup>110,137</sup> a CGRP, SP, VIP i dr. u aktivaciji proupalnih stanica.<sup>112,113,114</sup> Do sada je in vitro studijama pokazano da BoNT/A smanjuje izlučivanje CGRP-a u kulturi stanica trigeminalnog ganglija, a smanjio je i izlučivanje SP-a iz pupilarnog sfinktera u kunića.<sup>180,228,229,230</sup> BoNT/A je u našim pokusima neovisno o mjestu injiciranja (njuška, TMZ, trigeminalni ganglij) blokirao duralnu ekstravazaciju i infiltraciju proupalnih stanica u duri (slika 26, slika 28, slika 30, slika 32). Učinak je poništen blokadom aksonalnog transporta BoNT/A kroz trigeminalni ganglij (slika 35). Smatra se da glavnu ulogu u migrenoznoj nocicepciji ima signalizacija CGRP-a.<sup>122,131</sup> S tim u skladu pokazali smo da periferno injiciran BoNT/A blokira porast CGRP-a u kranijalnoj duri u modelu kronične upalne boli TMZ-a.<sup>205</sup> S obzirom na to da CGRP u duri uzrokuje vazodilataciju,<sup>137</sup> možemo zaključiti da bi BoNT/A mogao blokirati nastanak svih triju komponenti neurogene upale dure. Zanimljivo je da su izmjerene povišene vrijednosti

CGRP-a u plazmi pacijenata s kroničnom migrenom koji su pozitivno reagirali na BoNT/A.<sup>231</sup> Vrijednosti CGRP-a u plazmi su normalizirane nakon terapije s BoNT/A.<sup>181</sup>

S obzirom na to da je učinak BoNT/A u migreni teško objasniti njegovim lokalnim djelovanjem na periferne, ekstrakranijalne senzorne živčane okončine predloženo je da BoNT/A ostvaruje učinak na bol u migreni nakon transporta u duralne trigeminalne završetke.<sup>232,233</sup> Tome u prilog govore naši nalazi da učinak BoNT/A na neurogenu upalu dure ovisi o aksonalnom transportu toksina (slika 35). Štoviše, Lacković i suradnici, 2015. godine, su nakon perifernog injiciranja BoNT/A vizualizirali njegovu enzimatsku aktivnost (pocijepani SNAP 25) u kranijalnoj duri i kolokalizirali je s CGRP pozitivnim duralnim okončinama.<sup>205</sup>

Nedavnim je istraživanjem pokazano da BoNT/A smanjuje mehaničku senzitivnost ekstrakranijalnih projekcija duralnih aferentnih završetaka koje izlaze kroz kranijalne koštane suture u štakora.<sup>234</sup> Međutim mi smo pokazali da je učinak BoNT/A na duru prisutan i ako je toksin injiciran dalje od kranijalnih koštanih sutura (TMZ, brkovi). Dodatno smo pokazali da blokada aksonalnog transporta toksina (injiciranjem kolhicina u trigeminalni ganglij) sprječava vizualizaciju pocijepanog SNAP-25 u duri kao i učinak BoNT/A na neurogenu upalu dure (slika 35).<sup>205</sup> Učinak kolhicina je ograničen na mjesto injiciranja,<sup>235</sup> stoga mogući aksonalni transport BoNT/A u duru kroz ekstrakranijalne projekcije duralnih aferentnih završetaka ne bi trebao biti blokiran injiciranjem kolhicina u ganglij. Možemo zaključiti da naši rezultati ne pokazuju da je učinak BoNT/A u migreni povezan s njegovim direktnim lokalnim djelovanjem na ekstrakranijalne projekcije duralnih aferentnih završetaka.<sup>234</sup>

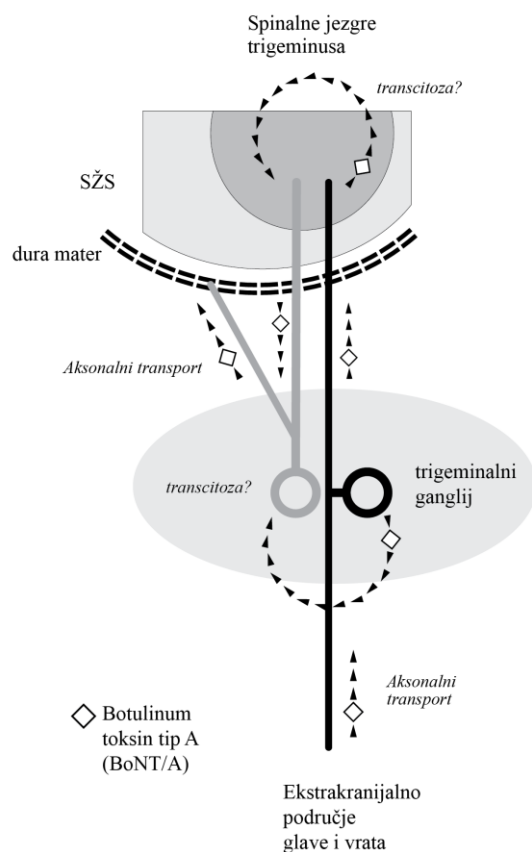
Na temelju prikazanih rezultata učinak BoNT/A na migrenu je moguće objasniti na sljedeći način:

- 1) periferno injiciran BoNT/A aksonalnim transportom putuje do duralnih senzornih okončina gdje blokira izlučivanje neuropeptida CGRP-a i SP-a ovisno o SNAP-25, što rezultira direktnim perifernim smanjenjem neurogene upale dure i meningealne nocicepcije;
- 2) periferno injiciran BoNT/A aksonalnim transportom putuje do centralnih okončina trigeminalnih neurona i ondje sudjeluje u: a) izlučivanju glutamata i drugih neurotransmitora; i/ili b) translokaciji ionskih TRPV1 kanala, koja je ovisna o SNAP-25;<sup>224</sup> te centralno djeluje na meningealnu nocicepciju.

Međutim, ne možemo isključiti mogućnost da je centralni mehanizam djelovanja BoNT/A na migrenu dijelom povezan i s endogenim sustavima kontrole boli, posebice s opioidnim i GABA-ergičkim.



Na temelju rezultata istraživanja u ovom radu ostaje nam odgovoriti na pitanje gdje i na koji način BoNT/A prelazi iz ekstrakranijalnih u duralne trigeminalne neurone. Jedno od logičnih objašnjenja je transcitoza BoNT/A, koja je do sada bila direktno pokazana između različitih neurona u retini i mozgu.<sup>236,237</sup> U trigeminalnoj regiji Kitamura i suradnici, 2009. godine, su pretpostavili postojanje transcitoze BoNT/A unutar trigeminalnog ganglija nakon perifernog injiciranja toksina.<sup>161</sup> Autori su istraživali učinak BoNT/A na izlučivanje neurotransmitora iz trigeminalnih neurona izoliranih iz štakora s neuropatijom uzrokovanom ozljedom infraorbitalnog živca. Periferno injiciran BoNT/A u lice štakora smanjio je izlučivanje neurotransmitora iz svih izoliranih neurona u gangliju štakora, a ponuđeno objašnjenje tako širokog učinka BoNT/A je transcitoza toksina u sve neurone ganglija.<sup>161</sup> Dodatno su Shimizu i suradnici, 2012. godine, pokazali da periferno injiciran BoNT/A u lice štakora smanjuje ekspresiju receptora TRPV-1 u neuronima koji inerviraju duru. Autori su pretpostavili da je učinak BoNT/A posredovan transcitozom toksina unutar trigeminalnog ganglija iz ekstrakranijalnih neurona u neurone koji inerviraju duru.<sup>224</sup> Možemo pretpostaviti da se transcitoza BoNT/A događa unutar trigeminalnog ganglija s još nepoznatim mehanizmom. Međutim, ne možemo isključiti ni mogućnost transcitoze BoNT/A na razini centralnih trigeminalnih jezgri (slika 38).<sup>232,233</sup>



**Slika 38. Moguća mjesta djelovanja aksonalno transportiranog BoNT/A u migreni i drugim glavoboljama (modificirano prema referenci: Lacković i sur., 2015)<sup>205</sup>**

Nakon injiciranja BoNT/A u ekstrakranijalno područje glave i vrata, toksin putuje retrogradno aksonalnim transportom kroz ekstrakranijalna aferentna vlakna senzornih trigeminalnih neurona (na slici crne boje) do trigeminalnog ganglija. BoNT/A zatim transcitozom prelazi u intrakranijalna - meningealna aferentna vlakna (na slici sive boje) i anterogradnim transportom putuje do dure mater gdje inhibira izlučivanje neuropeptida. Alternativno, transcitoza toksina se događa unutar spinalnih jezgi trigeminusa.

## 7. ZAKLJUČAK

1. Različite vrste periferne boli (akutna, kronična, upalna, neuropatska) u području glave i vrata (inervacija trigeminalnog i okcipitalnog živca) praćene su neurogenom upalom kranijalne dure, što se očituje ekstravazacijom proteina plazme u tkivo dure te infiltracijom tkiva s više vrsta proupalnih stanica. Upala kranijalne dure nakon unilateralnog perifernog bolnog podražaja često je bilateralna. Njezina pojavnost i intenzitet ovise o trajanju i intenzitetu perifernog bolnog podražaja te se može blokirati lijekovima koji istodobno priječe bol. Rezultati upućuju na to da neurogena upala kranijalne dure sudjeluje u patofiziologiji različitih tipova glavobolja.
2. Nasuprot perifernoj boli u području glave i vrata, neuropatska bol iz područja noge odnosno podrijetla inervacije n. ishiadiakusa ne uzrokuje nastanak neurogene upale kranijalnih ni spinalnih moždanih ovojnica. Prema tome se čini da neurogena upala spinalnih ovojnica ne sudjeluje u patofiziologiji boli donjeg dijela leđa.
3. Antimigrenozni lijek BoNT/A ostvaruje učinak blokiranjem neurogene upale kranijalne dure nakon periferne primjene. Utvrdili smo da je učinak na bilateralnu alodiniju u modelu neuropatske boli na licu prisutan: a) nakon injiciranja u kontralateralnu stranu lica; b) nakon injiciranja u trigeminalni ganglij. Učinak na bilateralnu alodiniju je potpuno poništen blokadom aksonalnog transporta BoNT/A kroz trigeminalni ganglij, što dodatno upućuje na središnji mehanizam antinociceptivnog djelovanja BoNT/A.

## 8. SAŽETAK

**Uvod:** Neurogena upala moždanih ovojnica do sada se povezivala s patofiziologijom migrene. Najvažniji nalaz ove disertacije je da bol različitog podrijetla u području glave i vrata uzrokuje nastanak neurogene upale moždanih ovojnica. To bi moglo biti povezano s izlučivanjem polipeptida iz ogranaka senzornih duralnih neurona, što bi trebali spriječiti triptani te botulinum toksin tipa A (BoNT/A).

**Materijal i metode:** Ispitivanja su se provodila na mužjacima štakora soja Wistar. Pojavnost neurogene upale moždanih ovojnica (ekstravazacija plazmatskih proteina i proupalne stanice u duri) ispitivana je na modelima akutne i kronične upalne i neuropatske boli inervacijskog područja n. trigeminusa te neuropatske boli inervacijskog područja n. okcipitalisa major i n. ishijadikusa. Također je ispitivana neurogena upala spinalnih ovojnica nakon neuropatske boli iz inervacije n. ishijadikusa. Ispitivan je učinak pojedinih analgetika (triptani, opioidi, lokalni anestetici) u modelu neuropatske boli podvezivanja infraorbitalnog živaca, na alodiniju i neurogenu upalu dure. Ispitivan je i učinak BoNT/A (s.c. područje brkova, 3,5 i.j/kg; i.a. temporomandibularni zglob, 5 i.j/kg; i.g. trigeminalni ganglij, 2 i.j/kg) na alodiniju i neurogenu upalu u modelima akutne i kronične upalne i neuropatske boli trigeminalne regije. Ispitivan je utjecaj inhibicije aksonalnog transporta kolhicinom na učinak BoNT/A.

**Rezultati:** Neurogene upale moždanih ovojnica se pojavljuju u upalnoj i neuropatskoj boli u području glave i vrata koje je inervirano trigeminalnim i okcipitalnim živcem. Nasuprot tome neuropatska bol (ishijadični živac) nije praćena razvojem neurogene upale spinalnih ovojnica u području kralježničke moždine, a ni upalom kranijalne dure. Triptani (sumatriptan i zolmitriptan), morfin i lokalni anestetici su smanjili alodiniju i neurogenu upalu dure u modelu neuropatske boli. BoNT/A je smanjio alodiniju i neurogenu upalu dure u modelima akutne i kronične upalne i neuropatske boli. Učinak je poništen blokatorom aksonalnog transporta kolhicinom kroz trigeminalni ganglij.

**Zaključak:** Rezultati ove disertacije pokazuju da je različita vrsta boli u trigeminalnoj, a dijelom i u okcipitalnoj regiji (područje glave i vrata) praćena razvojem neurogene upale moždanih ovojnica. Pojedini analgetici i antimigrenozni lijekovi smanjuju bol blokirajući neurogenu upalu dure.

Ključne riječi: neurogena upala, moždane ovojnice, bol, analgetici, botulinum toksin tipa A

## 9. SUMMARY

**Introduction:** Up to now, neurogenic inflammation of dura mater was associated to pathophysiology of migraine pain. The main finding of this doctoral thesis is that pain in the head and neck region elicits dural neurogenic inflammation as well. This phenomenon is caused by the neuropeptides release from the dural sensory neurons and could be prevented by triptans and/or botulinum toxin type A (BoNT/A).

**Material and methods:** Male Wistar rats were used in all experiments. Neurogenic inflammation of cranial dura mater was measured (as plasma protein extravasation and proinflammatory cell infiltration) in models of acute and chronic inflammatory and neuropathic pain in the trigeminal innervation area, and neuropathic pain in the innervation area of major occipital and ischiadic nerve. Additionally, occurrence of neurogenic inflammation of spinal dura was measured in the models of neuropathic pain in the innervation area of ischiadic nerve. The effect of different analgesic drugs (triptans, morphine, local anesthetic) on allodynia and dural neurogenic inflammation was measured in the neuropathic pain model (constriction of the infraorbital nerve). Furthermore we investigated the effect of BoNT/A (s.c. in the whisker pad, 3.5 IJ/kg; i.a. in the temporomandibular joint, 5 IJ/kg; i.g. in the trigeminal ganglion, 2 IJ/kg) on allodynia and dural neurogenic inflammation in the models of acute and chronic inflammatory and neuropathic pain in the trigeminal innervation area. Additionally, we used colchicine (axonal transport inhibitor) to investigate the mechanism of the BoNT/A.

**Results:** Neurogenic inflammation of cranial dura was elicited by inflammatory and neuropathic pain from trigeminal and occipital innervation area. However, neuropathic pain from the innervation area of ischiadic nerve did not result in neurogenic inflammation of cranial and spinal dura mater. Triptans (sumatriptan and zolmitriptan), morphine and local anesthetic decreased both allodynia and dural neurogenic inflammation in the model of trigeminal neuropathic pain. BoNT/A abolished allodynia and dural neurogenic inflammation in the models of acute and chronic inflammatory and neuropathic pain. The effect of BoNT/A was abolished by blocking the axonal transport through trigeminal ganglion.

**Conclusion:** Results of this doctoral thesis indicates that different pain in trigeminal and also occipital area (head and neck region) results in neurogenic inflammation of cranial dura.

Antinociceptive mechanism of action of several analgesic and anti-migraine drugs is associated with reduction of dural neurogenic inflammation.

Key words: neurogenic inflammation, dura mater, pain, analgesic drug, botulinum toxin type A

## 10. LITERATURA

1. Hendry SHC, Hsiao SS, Bushnell MC. Somatic sensation. U: *Fundamental Neuroscience.*, 2. izd. San Diego Academic Press: Squire LR, Roberts JI, Spitzer NC, Zigmond MJ, McConnell SK, Bloom FE; 2003, str. 677-99.
2. Julius D, Basbaum AI. Molecular mechanisms of nociception. *Nature* 2001;413:203-10.
3. Brooks J, Tracey I. From nociception to pain perception: imaging the spinal and supraspinal pathways. *J Anat* 2005;207:19-33.
4. Melzack R, Wall P. Pain mechanisms: a new theory. *Science* 1965;150:971-99.
5. Vanegas H, Schaible HG. Descending control of persistent pain: inhibitory or facilitatory? *Brain Res Rev* 2004;46:295-309.
6. Mense S. Nociception from skeletal muscle in relation to clinical muscle pain. *Pain* 1993;54:241-89.
7. Cervero F. Sensory innervation of the viscera: peripheral basis of visceral pain. *Physiol Rev* 1994;74:95-138.
8. Millan MJ. The induction of pain: an integrative review. *Prog Neurobiol* 1999;57:1-164.
9. Zhang X, Bao L. The development and modulation of nociceptive circuitry. *Curr Opin Neurobiol* 2006;16:460-6.
10. Sann H, Pierau FK. Efferent functions of C-fiber nociceptors. *Z Rheumatol* 1998;57:8-13.
11. Mannion RJ, Costigan M, Decosterd I, et al. Neurotrophins: peripherally and centrally acting modulators of tactile stimulus-induced inflammatory pain hypersensitivity. *Proc Natl Acad Sci U S A.* 1999;96:9385-90.
12. Vaillancourt PD, Langevin HM. Painful peripheral neuropathies. *Med Clin North Am.* 1999;83:627-42.
13. Amir R, Kocsis JD, Devor M. Multiple interacting sites of ectopic spike electrogenesis in primary sensory neurons. *J. Neurosci* 2005;25:2576-85.
14. Wieseler-Frank J, Maier SF, Watkins LR. Central proinflammatory cytokines and pain enhancement. *Neurosignals* 2005;14:166-74.
15. Schaible HG. Peripheral and central mechanisms of pain generation. *Handb Exp Pharmacol* 2007;3-28.

16. Hucho T, Levine JD. Signaling pathways in sensitization: Toward a nociceptor cell biology. *Neuron* 2007;55:365-76.
17. Ji RR, Kawasaki Y, Zhuang ZY, Wen YR, Zhang YQ. Protein kinases as potential targets for the treatment of pathological pain. *Handb Exp Pharmacol* 2007;359-89.
18. Cregg R, Momin A, Rugiero F, Wood JN, Zhao J. Pain channelopathies. *J Physiol* 2010;588:1897-904.
19. Bevan S, Andersson DA. TRP channel antagonists for pain - opportunities beyond TRPV1. *Curr Opin Investig Drugs* 2009;10:655-63.
20. Cortright DN, Szallasi A. TRP channels and pain. *Curr Pharm Des* 2009;15:1736-49.
21. Caterina MJ, Leffler A, Malmberg AB, et al. Impaired nociception and pain sensation in mice lacking the capsaicin receptor. *Science* 2000;288:306-13.
22. Suzuki M, Mizuno A, Kodaira K, Imai M. Impaired pressure sensation in mice lacking TRPV4. *J Biol Chem* 2003;278:22664-8.
23. Fischer MJ, Reeh PW. Sensitization to heat through G-protein-coupled receptor pathways in the isolated sciatic mouse nerve. *Eur J Neurosci* 2007;25:3570-5.
24. Brederson JD, Kym PR, Szallasi A. Targeting TRP channels for pain relief. *Eur J Pharmacol* 2013;716:61-76.
25. Woolf CJ. Evidence for a central component of post-injury pain hypersensitivity. *Nature* 1983;306:686-8.
26. Cook AJ, Woolf CJ, Wall PD. Prolonged C-fibre mediated facilitation of the flexion reflex in the rat is not due to changes in afferent terminal or motoneurone excitability. *Neurosci Lett* 1986;70:91-6.
27. Dostrovsky JO, Guilbaud G. Nociceptive responses in medial thalamus of the normal and arthritic rat. *Pain* 1990;40:93-104.
28. Neugebauer V, Li W. Differential sensitization of amygdala neurons to afferent inputs in a model of arthritic pain. *J Neurophysiol* 2003;89:716-27.
29. Wei F, Zhuo M. Potentiation of sensory responses in the anterior cingulate cortex following digit amputation in the anaesthetised rat. *J Physiol* 2001;532:823-33.
30. Mohr C, Leyendecker S, Mangels I, Machner B, Sander T, Helmchen C. Central representation of cold-evoked pain relief in capsaicin induced pain: An event-related fMRI study. *Pain* 2008;139:416-30.
31. Peyron R, Laurent B, Garcia-Larrea L. Functional imaging of brain responses to pain: A review and meta-analysis (2000). *Neurophysiol Clin* 2000;30:263-88.



32. Latremoliere A, Woolf CJ. Central sensitization: a generator of pain hypersensitivity by central neural plasticity. *J Pain* 2009;10:895-926.
33. Wall PD, Woolf CJ. Muscle but not cutaneous C-afferent input produces prolonged increases in the excitability of the flexion reflex in the rat. *J Physiol* 1984;356:443-58.
34. McNamara CR, Mandel-Brehm J, Bautista DM, et al. TRPA1 mediates formalin-induced pain. *Proc Natl Acad Sci U S A* 2007;104:13525-30.
35. Jordt SE, Bautista DM, Chuang HH, et al. Mustard oils and cannabinoids excite sensory nerve fibres through the TRP channel ANKTM1. *Nature* 2004;427:260–265.
36. LaMotte RH, Shain CN, Simone DA, Tsai EF. Neurogenic hyperalgesia: psychophysical studies of underlying mechanisms. *J Neurophysiol* 1991;66:190-211.
37. Davis KL, Martin E, Turko IV, Murad F. Novel effects of nitric oxide. *Annu Rev Pharmacol Toxicol* 2001;41:203-36.
38. Khasabov SG, Rogers SD, Ghilardi JR, Peters CM, Mantyh PW, Simone DA. Spinal neurons that possess the substance P receptor are required for the development of central sensitization. *J Neurosci* 2002;22:9086-98.
39. Sun RQ, Lawand NB, Willis WD. The role of calcitonin gene-related peptide (CGRP) in the generation and maintenance of mechanical allodynia and hyperalgesia in rats after intradermal injection of capsaicin. *Pain* 2003;104:201-8.
40. Sun RQ, Tu YJ, Lawand NB, Yan JY, Lin Q, Willis WD. Calcitonin gene-related peptide receptor activation produces PKA- and PKC-dependent mechanical hyperalgesia and central sensitization. *J Neurophysiol* 2004;92:2859-66.
41. Carvalho AL, Duarte CB, Carvalho AP. Regulation of AMPA receptors by phosphorylation. *Neurochem Res* 2000;25:1245-55.
42. Chen BS, Roche KW. Regulation of NMDA receptors by phosphorylation. *Neuropharmacology* 2007;53:362-8.
43. Lau CG, Zukin RS. NMDA receptor trafficking in synaptic plasticity and neuropsychiatric disorders. *Nat Rev Neurosci* 2007;8:413-26.
44. Torsney C, MacDermott AB. Disinhibition opens the gate to pathological pain signaling in superficial neurokinin 1 receptor-expressing neurons in rat spinal cord. *J Neurosci* 2006;26:1833-43.
45. Maeda T, Hamabe W, Gao Y, et al. Morphine has an antinociceptive effect through activation of the okadaic-acid-sensitive Ser/Thr protein phosphatases PP 2 A and PP5 estimated by tail-pinch test in mice. *Brain Res* 2005;1056:191-9.

46. Zhang X, Wu J, Fang L, Willis WD. The effects of protein phosphatase inhibitors on the duration of central sensitization of rat dorsal horn neurons following injection of capsaicin. *Mol Pain* 2006;2:23.
47. Ji RR, Baba H, Brenner GJ, Woolf CJ. Nociceptive-specific activation of ERK in spinal neurons contributes to pain hypersensitivity. *Nat Neurosci* 1999;2:1114-9.
48. Schuenke M, Schulte E, Schumacher U. Atlas of Anatomy, Head and Neuroanatomy, Thieme, Stuttgart-New York, 2007, str. 241-8.
49. Lisney SJ. Some current topics of interest in the physiology of trigeminal pain: a review. *J R Soc Med* 1983;76:292-96.
50. Pearson JC, Jemmes L. Localization of serotonin and substance P like immunofluorescence in the caudal spinal trigeminal nucleus of rat. *Neurosci Lett* 1988;88:151-56.
51. Olesen J, Peer Tfelt-Hansen K, Welch A, Goadsby PJ, Ramadan NM. The Headaches Third Edition. Lippincott Williams and Wilkins. 2006. Philadelphia, USA, str. 18-22.
52. Headache Classification Committee: The International Classification of Headache Disorders, 3rd edition (beta version). *Cephalalgia* 2013;33:629-808.
53. Marcus DA. Migraine and tension-type headaches: the questionable validity of current classification systems. *Clin J Pain* 1992;8:28-36.
54. Ulrich V, Russell MB, Jensen R, Olesen J. A comparison of tension-type headache in migraineurs and in non-migraineurs: a population-based study. *Pain* 1996;67:501-6.
55. Cady RK, Gutterman D, Saiers JA, Beach ME. Responsiveness of non-IHS migraine and tension-type headache to sumatriptan. *Cephalalgia* 1997;17:588-90.
56. Cady RK, Sheftell F, Lipton RB, et al. Effect of early intervention with sumatriptan on migraine pain: retrospective analyses of data from three clinical trials. *Clin Ther* 2000;22:1035-48.
57. Cady R, Schreiber C, Farmer K, Sheftell F. Primary headaches: a convergence hypothesis. *Headache* 2002;42:204-16.
58. Mainero C, Boshyan J, Hadjikhani N. Altered functional magnetic resonance imaging resting-state connectivity in periaqueductal gray networks in migraine. *Ann Neurol* 2011;70:838-45.
59. Moulton EA, Becerra L, Johnson A, Burstein R, Borsook D. Altered hypothalamic functional connectivity with autonomic circuits and the locus coeruleus in migraine. *PLoS One*. 2014;9:e95508. doi: 10.1371/journal.pone.0095508.

60. Akerman S, Holland PR, Goadsby PJ. Diencephalic and brainstem mechanisms in migraine. *Nat Rev Neurosci* 2011;12:570-84.
61. Coppola G, Di Renzo A, Tinelli E, i sur. Evidence for brain morphometric changes during the migraine cycle: A magnetic resonance-based morphometry study. *Cephalalgia* 2015;35:783-91.
62. Charles AC, Baca SM. Cortical spreading depression and migraine. *Nat Rev Neurol* 2013;9:637-44.
63. Gasparini CF, Sutherland HG, Griffiths LR. Studies on the pathophysiology and genetic basis of migraine. *Curr Genomics* 2013;14:300-15.
64. Bigal ME, Lipton RB. Concepts and mechanisms of migraine chronification. *Headache* 2008;48:7-15.
65. Moskowitz MA. The neurobiology of vascular head pain. *Ann Neurol* 1984;16:157-68.
66. Gupta R, Bhatia MS. A report of cranial autonomic symptoms in migraineurs. *Cephalalgia* 2007;27:22-8.
67. Cady RK. The convergence hypothesis. *Headache*. 2007;47:44-51.
68. Khan OA, Majumdar S, Jones NS. Facial pain following sinonasal surgery or facial trauma. *Clin Otolaryngol Allied Sci* 2002;27:171-4.
69. Sivori LA 2nd, de Leeuw R, Morgan I, Cunningham LL Jr. Complications of frontal sinus fractures with emphasis on chronic craniofacial pain and its treatment: a review of 43 cases. *J Oral Maxillofac Surg* 2010;68:2041-6.
70. Cady RK, Schreiber CP. Sinus problems as a cause of headache refractoriness and migraine chronification. *Curr Pain Headache Rep* 2009;13:319-25.
71. Schreiber CP, Hutchinson S, Webster CJ, i sur. Prevalence of migraine among patients with a history of self-reported or physician-diagnosed "sinus" headache. *Arch Intern Med* 2004;164:1769-72.
72. Levine HL. Functional endoscopic sinus surgery: evaluation, surgery and follow-up of 250 patients. *Laryngoscope* 1990;100:79-84.
73. Novak VJ, Makek M. Pathogenesis and surgical treatment of migraine and neurovascular headaches with rhinogenic trigger. *Head Neck* 1992;14:467-72.
74. Novak VJ. Pathogenesis and surgical treatment of neurovascular primary headaches. *Ital J Neurol Sci* 1995;16:49-55.

75. Behin F, Behin B, Bigal ME, Lipton RB. Surgical treatment of patients with refractory migraine headaches and intranasal contact points. *Cephalalgia* 2005;25:439-43.
76. Wolff HG: Wolff's Headache and Other Head Pain, 3. izd. New York: Oxford University Press; 1972.
77. Meggs WJ. Neurogenic switching: a hypothesis for a mechanism for shifting the site of inflammation in allergy and chemical sensitivity. *Environ Health Perspect* 1995;103:54-6.
78. Lipton RB, Buse DC, Serrano D, i sur. Differences in rates of common comorbid medical and psychiatric conditions in chronic and episodic migraine individuals. Presented at the 22nd Annual Practicing Physician's Approach to the Difficult Patient. Scottsdale, AZ; February 9-13, 2009.
79. De Rossi SS, Greenberg MS, Liu F, Steinkeler A. Temporomandibular disorders: evaluation and management. *Med Clin North Am* 2014;98:1353-84.
80. Franco AL, Gonçalves DA, Castanharo SM, Speciali JG, Bigal ME, Camparis CM. Migraine is the most prevalent primary headache in individuals with temporomandibular disorders. *J Orofac Pain* 2010;24:287-92.
81. Bevilaqua Grossi D, Lipton RB, Bigal ME. Temporomandibular disorders and migraine chronification. *Curr Pain Headache Rep* 2009;13:314-8.
82. Villa G, Ceruti S, Zanardelli M, i sur. Temporomandibular joint inflammation activates glial and immune cells in both the trigeminal ganglia and in the spinal trigeminal nucleus. *Mol Pain* 2010;6:89.
83. Imbe H, Iwata K, Zhou QQ, Zou S, Dubner R, Ren K. Orofacial deep and cutaneous tissue inflammation and trigeminal neuronal activation. Implications for persistent temporomandibular pain. *Cells Tissues Organs* 2001;169:238-47.
84. Guyuron B, Reed D, Kriegler JS, Davis J, Pashmini N, Amini S. A placebo-controlled surgical trial of the treatment of migraine headaches. *Plast Reconstr Surg* 2009;124:461-8.
85. Guyuron B, Tucker T, Davis J. Surgical treatment of migraine headaches. *Plast Reconstr Surg* 2002;109:2183-9.
86. Guyuron B, Yohannes E, Miller R, Chim H, Reed D, Chance MR. Electron microscopic and proteomic comparison of terminal branches of the trigeminal nerve in patients with and without migraine headaches. *Plast Reconstr Surg* 2014;134:796-805.

87. Kahle W, Leonhardt H, Platzer W. Živčani sustav i osjetila, Medicinska naklada, Zagreb,1996, str. 134-8.
88. Moore KL, Dalley AF, Agur AMR. Clinically oriented anatomy. Lippincott Williams & Wilkins, 2013, str. 238-9.
89. Mayberg MR, Zervas NT, Moskowitz MA. Trigeminal projections to supratentorial pial and dural blood vessels in cats demonstrated by horseradish peroxidase histochemistry J Comp Neurol 1984;223:46-56.
90. Steiger HJ, Meakin CJ. The meningeal representation in the trigeminal ganglion-an experimental study in the cat. Headache 1984;24:305-9.
91. Keller JT, Saunders MC, Beduk A, Jollis JG. Innervation of the posterior fossa dura of the cat. Brain Res Bull 1985;14:97-102.
92. Keller JT, Marfurt CF, Dimlich RV, Tierney BE. Sympathetic innervation of the supratentorial dura mater of the rat. J Comp Neurol 1989;290:310-21.
93. Uddman R, Grunditz T, Kato J, Sundler F. Distribution and origin of nerve fibers in the rat temporomandibular joint capsule. Anat Embryol (Berl) 1998;197:273-82.
94. Messlinger K, Hanesch U, Baumgärtel M, Trost B, Schmidt RF. Innervation of the dura mater encephali of cat and rat: ultrastructure and calcitonin gene-related peptide-like and substance P-like immunoreactivity. Anat Embryol (Berl) 1993;188:219-37.
95. Levy D, Strassman AM. Mechanical response properties of A and C primary afferent neurons innervating the rat intracranial dura. J Neurophysiol 2002;88:3021-31.
96. Burstein R, Yamamura H, Malick A, Strassman AM. Chemical stimulation of intracranial dura induces enhanced responses to facial stimulation in brainstem trigeminal neurons. J Neurophysiol 1998;79:964-82.
97. Zhang X, Burstein R, Levy D. Local action of the proinflammatory cytokines IL-1 $\beta$  and IL-6 on intracranial meningeal nociceptors. Cephalalgia 2012;32:66-72.
98. Zhang XC, Kainz V, Burstein R, Levy D. Tumor necrosis factor- $\alpha$  induces sensitization of meningeal nociceptors mediated via local COX and p38 MAP kinase actions. Pain 2011;152:140-9.
99. Strassman AM, Raymond SA, Burstein R. Sensitization of meningeal sensory neurons and the origin of headaches. Nature 1996;384:560-4.
100. Messlinger K, Ellrich J. Meningeal nociception: electrophysiological studies related to headache and referred pain. Microsc Res Tech 2001;53:129-37.

101. Rozniecki JJ, Dimitriadou V, Lambracht-Hall M, Pang X, Theoharides TC. Morphological and functional demonstration of rat dura mater mast cell-neuron interactions in vitro and in vivo. *Brain Res* 1999;849:1-15.
102. Dimlich RV, Keller JT, Strauss TA, Fritts MJ. Linear arrays of homogeneous mast cells in the dura mater of the rat. *J Neurocytol* 1991;20:485-503.
103. Michaloudi H, Batzios C, Chiotelli M, Papadopoulos GC. Developmental changes of mast cell populations in the cerebral meninges of the rat. *J Anat* 2007;211:556-66.
104. Dimitriadou V, Buzzi MG, Theoharides TC, Moskowitz MA. Ultrastructural evidence for neurogenically mediated changes in blood vessels of the rat dura mater and tongue following antidromic trigeminal stimulation. *Neuroscience* 1992;48:187-203.
105. Buzzi MG, Dimitriadou V, Theoharides TC, Moskowitz MA. 5-Hydroxytryptamine receptor agonists for the abortive treatment of vascular headaches block mast cell, endothelial and platelet activation within the rat dura mater after trigeminal stimulation *Brain Res* 1992;583:137-49.
106. Buzzi MG, Bonamini M, Moskowitz MA. Neurogenic model of migraine. *Cephalalgia* 1995;15:277-80.
107. Bergerot A, Reynier-Rebuffel AM, Callebert J, Aubineau P. Long-term superior cervical sympathectomy induces mast cell hyperplasia and increases histamine and serotonin content in the rat dura mater. *Neuroscience* 2000;96:205-13.
108. Levy D, Burstein R, Kainz V, Jakubowski M, Strassman AM. Mast cell degranulation activates a pain pathway underlying migraine headache. *Pain* 2007;130:166-76.
109. Zhang XC, Strassman AM, Burstein R, Levy D. Sensitization and activation of intracranial meningeal nociceptors by mast cell mediators. *J Pharmacol Exp Ther* 2007;322:806-12.
110. Eftekhari S, Warfvinge K, Blixt FW, Edvinsson L. Differentiation of nerve fibers storing CGRP and CGRP receptors in the peripheral trigeminovascular system. *J Pain* 2013;14:1289-303.
111. Kandere-Grzybowska K, Gheorghe D, Priller J, et al. Stress-induced dura vascular permeability does not develop in mast cell-deficient and neurokinin-1 receptor knockout mice. *Brain Res* 2003;980:213-20.
112. Theoharides TC, Donelan J, Kandere-Grzybowska K, Konstantinidou A. The role of mast cells in migraine pathophysiology. *Brain Res Brain Res Rev* 2005;49:65-76.

113. Baun M, Pedersen MH, Olesen J, Jansen-Olesen I. Dural mast cell degranulation is a putative mechanism for headache induced by PACAP-38. *Cephalalgia* 2012;32:337-45.
114. Kilinc E, Firat T, Tore F, Kiyani A, Kukner A, Tunçel N. Vasoactive Intestinal peptide modulates c-Fos activity in the trigeminal nucleus and dura mater mast cells in sympathectomized rats. *J Neurosci Res* 2015;93:644-50.
115. Levy D. Migraine pain, meningeal inflammation, and mast cells. *Curr Pain Headache Rep* 2009;13:237-40.
116. Bamberger DM. Diagnosis, initial management, and prevention of meningitis. *Am Fam Physician* 2010;82:1491-8.
117. Barnes PJ, Belvisi MG, Rogers DF. Modulation of neurogenic inflammation: novel approaches to inflammatory disease. *Pharmacol Sci Trends* 1990;11:185-9.
118. Bascom R, Meggs WJ, Frampton M, et al. Neurogenic inflammation: with additional discussion of central and perceptual integration of non neurogenic inflammation. *Environ Health Perspect* 1997;105:531-7.
119. Holzer P. Neurogenic vasodilatation and plasma leakage in the skin. *Gen Pharmacol* 1998;30:5-11.
120. Butler CA, Heaney LG. Neurogenic inflammation and asthma. *Inflamm Allergy Drug Targets* 2007;6:127-32.
121. Raychaudhuri SP, Raychaudhuri SK. Role of NGF and neurogenic inflammation in the pathogenesis of psoriasis. *Prog Brain Res* 2004;146:433-7.
122. Peroutka SJ. Neurogenic inflammation and migraine: implications for the therapeutics. *Mol Interv* 2005;5:304-11.
123. Raphael GD, Baraniuk JN, Kaliner MA. How and why the nose runs. *J Allergy Clin Immunol* 1991;87:457-67.
124. Goadsby PJ, Lipton RB, Ferrari MD. Migraine - current understanding and treatment. *New Engl J Med* 2002;346:257-70.
125. Shapiro R, Goadsby P. The long drought: the dearth of public funding for headache research. *Cephalalgia* 2007;27:991-4.
126. Moskowitz MA. Neurogenic inflammation in the pathophysiology and treatment of migraine. *Neurology* 1993;43:16-20.
127. Cutrer FM. Pathophysiology of migraine. *Semin Neurol* 2010;30:120-30.

128. Nosedá R, Burstein R. Migraine pathophysiology: anatomy of the trigeminovascular pathway and associated neurological symptoms, cortical spreading depression, sensitization, and modulation of pain. *Pain* 2013;154:44-53.
129. Bhaskar S, Saeidi K, Borhani P, Amiri H. Recent progress in migraine pathophysiology: role of cortical spreading depression and magnetic resonance imaging. *Eur J Neurosci* 2013;38:3540-51.
130. Bigal ME, Walter S, Rapoport AM. Calcitonin gene-related peptide (CGRP) and migraine current understanding and state of development. *Headache* 2013;53:1230-44.
131. Williamson DJ, Hargreaves RJ. Neurogenic inflammation in the context of migraine. *Microsc Res Tech*. 2001;53:167-78.
132. Burstein R, Cutrer MF, Yarnitsky D. The development of cutaneous allodynia during a migraine attack clinical evidence for the sequential recruitment of spinal and supraspinal nociceptive neurons in migraine. *Brain* 2000;123:1703-9.
133. Landy S, Rice K, Lobo B. Central sensitisation and cutaneous allodynia in migraine: implications for treatment. *CNS Drugs* 2004;18:337-42.
134. Markowitz S, Saito K, Moskowitz MA. Neurogenically mediated leakage of plasma protein occurs from blood vessels in dura mater but not brain. *J Neurosci* 1987;7:4129-36.
135. Nelson DL, Phebus LA, Johnson KW, et al. Preclinical pharmacological profile of the selective 5-HT<sub>1F</sub> receptor agonist lasmiditan. *Cephalalgia* 2010;30:1159-6.
136. Goldstein DJ, Wang O, Saper JR, Stoltz R, Silberstein SD, Mathew NT. Ineffectiveness of neurokinin-1 antagonist in acute migraine: a crossover study. *Cephalalgia* 1997;17:785-90.
137. Shepherd SL, Williamson DJ, Beer MS, Hill RG, Hargreaves RJ. Differential effects of 5-HT<sub>1B/1D</sub> receptor agonists on neurogenic dural plasma extravasation and vasodilation in anaesthetized rats. *Neuropharmacology* 1997;36:525-33.
138. Hoskin KL, Kaube H, Goadsby PJ. Central activation of the trigeminovascular pathway in the cat is inhibited by dihydroergotamine. A c-Fos and electrophysiological study. *Brain* 1996;119:249-56.
139. Shepherd SL, Williamson DJ, Williams J, Hill RG, Hargreaves RJ. Comparison of the effects of sumatriptan and the NK1 antagonist CP-99,994 on plasma extravasation in dura mater and c-fos mRNA expression in trigeminal nucleus caudalis of rats. *Neuropharmacology* 1995;34:255-61.



140. Goadsby PJ, Hoskin KL. Inhibition of trigeminal neurons by intravenous administration of the serotonin (5HT)1B/D receptor agonist zolmitriptan (311C90): are brain stem sites therapeutic target in migraine? *Pain* 1996;67:355-9.
141. Goadsby PJ, Boes CJ. Zolmitriptan: differences from sumatriptan. *Curr Med Res Opin* 2001;1:46-50.
142. Donaldson C, Boers PM, Hoskin KL, Zagami AS, Lambert GA. The role of 5-HT1B and 5-HT1D receptors in the selective inhibitory effect of naratriptan on trigeminovascular neurons. *Neuropharmacology* 2002;42:374-85.
143. Goadsby PJ, Knight Y. Inhibition of trigeminal neurones after intravenous administration of naratriptan through an action at 5-hydroxy-tryptamine (5-HT(1B/1D)) receptors. *Br J Pharmacol* 1997;122:918-22.
144. Johnson DE, Rollema H, Schmidt AW, McHarg AD. Serotonergic effects and extracellular brain levels of eletriptan, zolmitriptan and sumatriptan in rat brain. *Eur J Pharmacol* 2001;425:203-10.
145. Cutrer FM, Limmroth V, Ayata G, Moskowitz MA. Attenuation by valproate of c-fos immunoreactivity in trigeminal nucleus caudalis induced by intracisternal capsaicin. *Br J Pharmacol* 1995;116:3199-204.
146. Burstein R, Jakubowski M. Analgesic triptan action in an animal model of intracranial pain: a race against the development of central sensitization. *Ann Neurol* 2004;55:27-36.
147. Levy D, Jakubowski M, Burstein R. Disruption of communication between peripheral and central trigeminovascular neurons mediates the antimigraine action of 5HT 1B/1D receptor agonists. *Proc Natl Acad Sci U S A* 2004;101:4274-9.
148. Williamson DJ, Hargreaves RJ, Hill RG, Shephard SL. Sumatriptan inhibits neurogenic vasodilation of dural blood vessels in the anaesthetized rat--intravital microscope studies *Cephalalgia* 1997;17:525-31.
149. Saito K, Markowitz S, Moskowitz MA. Ergot alkaloids block neurogenic extravasation in dura mater: proposed action in vascular headaches. *Ann Neurol* 1988;24:732-7.
150. Buzzi MG, Sakas DE, Moskowitz MA. Indomethacin and acetylsalicylic acid block neurogenic plasma protein extravasation in rat dura mater. *Eur J Pharmacol* 1989;165:251-8.

151. Lee WS, Limmroth V, Ayata C, i sur. Peripheral GABAA receptor-mediated effects of sodium valproate on dural plasma protein extravasation to substance P and trigeminal stimulation. *Br J Pharmacol* 1995;116:1661-67.
152. Yekkiralala AS, Kalyuzhny AE, Portoghese PS. Standard Opioid Agonists Activate Heteromeric Opioid Receptors: Evidence for Morphine and [d-Ala<sup>2</sup>-MePhe<sup>4</sup>-Glyol<sup>5</sup>]Enkephalin as Selective  $\mu$ - $\delta$  Agonists. *ACS Chemical Neuroscience* 2010;1:146-54.
153. Moskowitz MA, Macfarlane R. Neurovascular and molecular mechanisms in migraine headaches. *Cerebrovasc. Brain Metab Rev* 1993;5:159-77.
154. Williamson DJ, Shepherd SL, Cook DA, Hargreaves RJ, Hill RG, Cumberbatch MJ. Role of opioid receptors in neurogenic dural vasodilation and sensitization of trigeminal neurones in anaesthetized rats. *Br J Pharmacol* 2001;133:807-14.
155. Bach-Rojecky L, Relja M, Filipović B, Lacković Z. Botulinum toksin tipa A i kolinergični sustav. *Lijec Vjesn* 2007;129:407-14.
156. Chen F, Kuzmienko GM, Stevens RC. Biophysical characterisation of the stability of the 150-kilodalton botulinum toxin, the nontoxic component, and the 900-kilodalton botulinum toxin complex species. *Infection Immunity* 1998;66:2420-5.
157. Turton K, Chaddock JA, Acharya KR. Botulinum and tetanus neurotoxins: structure, function and therapeutic utility. *Trend Biochem Sci* 2002;27:552-8.
158. Bach-Rojecky L, Lacković Z. Antinociceptive effect of botulinum toxin type A in rat model of carrageenan and capsaicin induced pain. *Croat Med J* 2005;46:201-8.
159. Cui M, Khanijou S, Rubino J, Aoki KR. Subcutaneous administration of botulinum toxin A reduces formalin-induced pain. *Pain* 2004;107:125-33.
160. Bach-Rojecky L, Relja M, Lacković Z. Botulinum toxin type A in experimental neuropathic pain. *J. Neural. Transm* 2005;112:215-9.
161. Kitamura Y, Matsuka Y, Spigelman I, i sur. Botulinum toxin type A (150 kDa) decreases exaggerated neurotransmitter release from trigeminal ganglion neurons and relieves neuropathy behaviors induced by infraorbital nerve constriction. *Neuroscience* 2009;59:1422-29.
162. Favre-Guilmond C, Auguet M., Chabrier PE. Different antinociceptive effects of botulinum toxin type A in inflammatory and peripheral polyneuropathic rat models. *Eur J Pharmacol* 2009;617:48-53.
163. Mahant N, Clouston PD, Lorent IT. The current use of botulinum toxin. *J Clin Neurosci* 2000;7:389-394.

164. Wittekindt C, Liu WC, Klussmann JP, Guntinas-Lichius O. Botulinum toxin type A for the treatment of chronic neck pain after neck dissection. *Head Neck* 2004; 26:39-45.
165. Smith CP, Radziszewski P, Borkowski A, Somogyi GT, Boone TB, Chancellor MB. Botulinum toxin a has antinociceptive effects in treating interstitial cystitis. *Urology* 2004;64:871-5.
166. Luvisetto S, Gazerani P, Cianchetti C, Pavone F. Botulinum Toxin Type A as a Therapeutic Agent against Headache and Related Disorders. *Toxins (Basel)* 2015;7:3818-44.
167. Aoki KR. Review of a proposed mechanism for the antinociceptive action of botulinum toxin type A. *Neurotoxicology* 2005;26:785-93.
168. Aoki KR, Francis J. Updates on the antinociceptive mechanism hypothesis of botulinum toxin A. *Parkinsonism Relat Disord* 2011;17:28-33.
169. Bach-Rojecky L, Lacković Z. Central origin of the antinociceptive action of botulinum toxin type A. *Pharmacol Biochem Behav* 2009;94:234-8.
170. Bach-Rojecky L, Salković-Petrisić M, Lacković Z. Botulinum toxin type A reduces pain supersensitivity in experimental diabetic neuropathy: bilateral effect after unilateral injection. *Eur J Pharmacol* 2010;633:10-4.
171. Matak I, Bach-Rojecky L, Filipović B, Lacković Z. Behavioral and immunohistochemical evidence for central antinociceptive activity of botulinum toxin A. *Neuroscience* 2011;186:201-7.
172. Matak I, Riederer P, Lacković Z. Botulinum toxin's axonal transport from periphery to the spinal cord. *Neurochem Int* 2012;61:236-9.
173. Matak I, Rossetto O, Lacković Z. Botulinum toxin type A selectivity for certain types of pain is associated with capsaicin-sensitive neurons. *Pain* 2014;155:1516-26.
174. Aurora SK, Dodick DW, Turkel CC, i sur. PREEMPT 1 Chronic Migraine Study Group. Onabotulinum toxin A for treatment of chronic migraine: results from the double-blind, randomized, placebo-controlled phase of the PREEMPT 1 trial. *Cephalalgia* 2010;30:793-803.
175. Diener HC, Dodick DW, Aurora SK, i sur; PREEMPT 2 Chronic Migraine Study Group. OnabotulinumtoxinA for treatment of chronic migraine: results from the double-blind, randomized, placebo-controlled phase of the PREEMPT 2 trial. *Cephalalgia*. 2010;30:804-14.

176. Blumenfeld A. Botulinum toxin type A as an effective prophylactic treatment in primary headache disorders. *Headache* 2003;43:853-60.
177. Freitag F. Managing and treating tension-type headache. *Med Clin North Am* 2013;97:281-92.
178. Jackson JL, Kuriyama A, Hayashino Y. Botulinum toxin A for prophylactic treatment of migraine and tension headaches in adults: a meta-analysis. *JAMA* 2012;307:1736-45.
179. Xia JH, He CH, Zhang HF, i sur. Botulinum toxin A in the treatment of trigeminal neuralgia. *Int J Neurosci* 2015;1-6.
180. Durham PL, Cady R. Regulation of calcitonin gene-related peptide secretion from trigeminal nerve cells by botulinum toxin type A: implications for migraine therapy. *Headache* 2004;44:35-43.
181. Cernuda-Morollon E, Ramon C, Martinez-Cambor P, Serrano-Pertierra E, Larrosa D, Pascual J. OnabotulinumtoxinA decreases interictal CGRP plasma levels in chronic migraine patients. *Pain* 2015;156:820-4.
182. Neubert JK, Mannes AJ, Keller J, i sur. Peripheral targeting of the trigeminal ganglion via the infraorbital foramen as a therapeutic strategy. *Brain Res Brain Res Protoc* 2005;15:119-26.
183. Dallas FA, Dixon CM, McCulloch RJ, Saynor DA. The kinetics of <sup>14</sup>C-GR43175 in rat and dog. *Cephalalgia* 1989;9:53-6.
184. Schuh-Hofer, Boehnke C, Reuter U, i sur. A fluorescence-based method to assess plasma protein extravasation in rat dura mater using confocal laser scanning microscopy. *Brain Res Brain Res Protoc* 2003;12:77-82.
185. Jóhannesson T, Becker BA. Morphine analgesia in rats at various ages. *Acta Pharmacol Toxicol (Copenh)* 1973;33:429-41.
186. Babbini M, Davis WM. Time-dose relationships for locomotor activity effects of morphine after acute or repeated treatment. *Br J Pharmacol* 1972;46:213-24.
187. D'Amour F. E. and Smith D. L. A method for determining loss of pain sensation. *J. Pharmac exp. Ther* 1941;72:74-9.
188. Becker DE, Reed KL. Essentials of local anaesthetic pharmacology. *Anesthesia Progress* 2006;53:98-109.
189. Randall LO, Selitto JJ. A method for measurement of analgesic activity of infammed tissue. *Ach Int Pharmacodyn* 1957;61:409-19.

190. James KA, Bray JJ, Morgan IG, Austin L. The effect of colchicine on the transport of axonal protein in the chicken. *Biochem J* 1970;117:767-71.
191. Raboisson P, Dallel R. The orofacial formalin test. *Neurosci Biobehav Rev* 2004;28:219-26.
192. Pogatzki EM, Niemeir JS, Brennan TJ. Persistent secondary hyperalgesia after gastrocnemius incision in rat. *Eur. J. Pain* 2002;6:295-305.
193. Gregg JM. A surgical approach to the ophthalmic-maxillary nerve trunks in the rat. *J Dent Res* 1973;52:392.
194. Bennett GJ, Xie YK. A peripheral mononeuropathy in rat that produces disorders like those seen in men. *Pain* 1988;33:87-107.
195. Vos BP, Strassman AM, Maciewicz RJ. Behavioral evidence of trigeminal neuropathic pain following chronic constriction injury to the rat's infraorbital nerve. *J Neurosci* 1994;74:2708-23.
196. Larrier D, Lee A. Anatomy of headache and facial pain. *Otolaryngol Clin North Am* 2003;36:1041-53.
197. Sessle BJ. Neural mechanisms and pathways in craniofacial pain. *Can J Neurol Sci* 1999;26:7-11.
198. Amir R, Devor M. Functional cross-excitation between afferent A- and C- neurons in dorsal root ganglia. *Neuroscience* 2000;95:189-95.
199. Thalakoti S, Patil VV, Damodaram S, i sur. Neuron–glia signaling in trigeminal ganglion: implications for migraine pathology. *Headache* 2007;47:1008-23.
200. Yamamura H, Malick A, Nancy L, Chamberlin NL, Burstein R. Reduction of the threshold of cardiovascular and neuronal responses to facial and intracranial stimulation reflects central sensitization and cutaneous allodynia in a rat model of migraine. *J Neurophysiol* 1999;81:479-93.
201. Samsam M, Coveñas R, Csillik B, i sur. Depletion of substance P, neurokinin A and calcitonin gene-related peptide from the contralateral and ipsilateral caudal trigeminal nucleus following unilateral electrical stimulation of the trigeminal ganglion; a possible neurophysiological and neuroanatomical link to generalized head pain. *J Chem Neuroanat* 2001;21:161-9.
202. Jacquin MF, Chiaia NL, Rhoades RW. Trigeminal projections to contralateral dorsal horn: central extent, peripheral origins, and plasticity. *Somatosens Mot Res* 1990;7:153-83.

203. Clavelou P, Dallel R, Orliaguet T, Woda A, Raboisson P. The orofacial formalin test in rats: effects of different formalin concentrations. *Pain*. 1995;62:295-301.
204. Fozzard HA, Lee PJ, Lipkind GM. Mechanism of local anesthetic drug action on voltage-gated sodium channels. *Curr Pharm Des* 2005;11:2671-86.
205. Lacković Z, Filipović B, Matak I, Helyes Z. Botulinum toxin type A activity in cranial dura: implications for treatment of migraine and other headaches. *Br J Pharmacol*. 2016; 173:279-91.
206. Ma QP, Hill R, Sirinathsinghji D. Colocalization of CGRP with 5-HT1B/1D receptors and substance P in trigeminal ganglion neurons in rats. *Eur J Neurosci* 2001;13:2099-104.
207. Spofford CM, Brennan TJ. Gene expression in skin, muscle, and dorsal root ganglion after plantar incision in the rat. *Anesthesiology* 2012;117:161-72.
208. Buzzi MG, Moskowitz MA. The antimigraine drug, sumatriptan (GR43175), selectively blocks neurogenic plasma extravasation from blood vessels in dura mater. *Br J Pharmacol* 1990;99:202-6.
209. Hargreaves RJ, Lines CR, Rapoport AM, Ho TW, Sheftell FD. Ten years of rizatriptan: from development to clinical science and future directions. *Headache* 2009;49:3-20.
210. Dong Z, Jiang L, Wang X, Wang X, Yu S. Nociceptive behaviours were induced by electrical stimulation of the dura mater surrounding the superior sagittal sinus in conscious adult rats and reduced by morphine and rizatriptan benzoate. *Brain Res* 2011;1368:151-8.
211. Tepper SJ, Rapoport AM, Sheftell FD. Mechanisms of action of the 5-HT1B/1D receptor agonists. *Arch Neurol* 2002;59:1084-8.
212. Li JL, Ding YQ, Li YQ, et al. Immunocytochemical localization of mu-opioid receptor in primary afferent neurons containing substance P or calcitonin gene-related peptide. A light and electron microscope study in the rat. *Brain Res* 1998;794:347-52.
213. Goadsby PJ. Diagnosis and optimum treatment of migraine. *CNS Drugs* 1994;1:245-53.
214. Nozaki K, Moskowitz MA, Boccacini P. CP-93, 129, sumatriptan, dihydroergotamine block c-fos expression within rat trigeminal nucleus caudalis caused by chemical stimulation of the meninges. *Br. J. Pharmacol* 1992;106:409-15.

215. Filipović B, Matak I, Lacković Z. Dural neurogenic inflammation induced by neuropathic pain is specific to cranial region. *J Neural Transm* 2014;121:555-63.
216. Bartsch T, Goadsby PJ. Increased responses in trigeminocervical nociceptive neurons to cervical input after stimulation of the dura mater. *Brain* 2003;126:1801-13.
217. Le Doaré K, Akerman S, Holland PR, i sur. Occipital afferent activation of second order neurons in the trigeminocervical complex in rat. *Neurosci Lett* 2006;403:73-7.
218. Vincent MB. Headache and neck. *Curr Pain Headache Rep* 2011;15:324-31.
219. Kumar R, Berger RJ, Dunsker SB, Keller JT. Innervation of the spinal dura. Myth or reality? *Spine (Phila Pa 1976)* 1996;21:18-26.
220. Fricke B, Andres KH, Von Düring M. Nerve fibers innervating the cranial and spinal meninges: morphology of nerve fiber terminals and their structural integration. *Microsc Res Tech* 2001;53:96-105.
221. Xanthos DN, Gaderer S, Drdla R, Nuro E, Abramova A, Ellmeier W, Sandkuhler J. Central nervous system mast cells in peripheral inflammatory nociception. *Mol Pain* 2011;7:42.
222. Saxler G, Brankamp J, von Knoch M, Lör F, Hilken G, Hanesch U. The density of nociceptive SP- and CGRP-immunopositive nerve fibers in the dura mater lumbalis of rats is enhanced after laminectomy, even after application of autologous fat grafts. *Eur Spine J* 2008;17:1362-72.
223. Filipović B, Bach-Rojecky L, Lacković Z. Lasting reduction of postsurgical hyperalgesia after single injection of botulinum toxin type A in rat. *Fundam Clin Pharmacol* 2010;24:43-5.
224. Shimizu T, Shibata M, Toriumi H, i sur. Reduction of TRPV1 expression in the trigeminal system by botulinum neurotoxin type-A. *Neurobiol Dis* 2012;48:367-78.
225. Drinovac V, Bach-Rojecky L, Lacković Z. Association of antinociceptive action of botulinum toxin type A with GABA-A receptor. *J Neural Transm.* 2014;121:665-9.
226. Drinovac V, Bach-Rojecky L, Matak I, Lacković Z. Involvement of  $\mu$ -opioid receptors in antinociceptive action of botulinum toxin type A. *Neuropharmacology.* 2013;70:331-7.
227. Filipović B, Matak I, Bach-Rojecky L, Lacković Z. Central action of peripherally applied botulinum toxin type A on pain and dural protein extravasation in rat model of trigeminal neuropathy. *PLoS One* 2012;7(1):e29803. doi: 10.1371/journal.pone.0029803.

228. Meng J, Ovsepian SV, Wang J, i sur. Activation of TRPV 1 mediates calcitonin gene-related peptide release, which excites trigeminal sensory neurons and is attenuated by a retargeted botulinum toxin with anti-nociceptive potential. *J Neurosci* 2009;29:4981-92.
229. Meng J, Wang J, Lawrence G, Dolly O. Synaptobrevin I mediates exocytosis of CGRP from sensory neurons and inhibition by botulinum toxins reflects their anti-nociceptive potential. *J Cell Sci* 2007;120:2864-74.
230. Ishikawa H, Mitsui Y, Yoshitomi T, i sur. Presynaptic effects of botulinum toxin type A on the neuronally evoked response of albino and pigmented rabbit iris sphincter and dilator muscles. *Jpn J Ophthalmol* 2000;44:106-9.
231. Cernuda-Morollon E, Martinez-Camblor P, Ramon C, Larrosa D, Serrano-Pertierra E, Pascual J. CGRP and VIP levels as predictors of efficacy of Onabotulinumtoxin type A in chronic migraine. *Headache* 2014;54:987-95.
232. Matak I, Lacković Z. Botulinum toxin A, brain and pain. *Prog Neurobiol* 2014;119-120:39-59.
233. Ramachandran R, Yaksh TL. Therapeutic use of botulinum toxin in migraine: mechanisms of action. *Br J Pharmacol* 2014;171:4177-92.
234. Burstein R, Zhang X, Levy D, Aoki KR, Brin MF. Selective inhibition of meningeal nociceptors by botulinum neurotoxin type A: Therapeutic implications for migraine and other pains. *Cephalalgia* 2014;34:853-69.
235. Cangiano A, Fried JA. The production of denervation-like changes in rat muscle by colchicine, without interference with axonal transport or muscle activity. *J Physiol* 1977;265: 63-84.
236. Restani L, Antonucci F, Gianfranceschi L, Rossi C, Rossetto O, Caleo M. Evidence for anterograde transport and transcytosis of botulinum neurotoxin A (BoNT/A). *J Neurosci* 2011;31:15650-9.
237. Restani L, Novelli E, Bottari D, i sur. Botulinum neurotoxin A impairs neurotransmission following retrograde transynaptic transport. *Traffic* 2012;13:1083-9.



## 11. ŽIVOTOPIS

### **Boris Filipović, dr.med**



Boris Filipović rođen je 02. siječnja 1984. godine u Virovitici. Završio je 2. Opću gimnaziju u Zagrebu 2002. godine. Dodiplomski studij medicine upisao je na Medicinskom fakultetu Sveučilišta u Zagrebu 2002. godine, a završio u 5% najboljih studenata u generaciji 2008. godine. Od 2008. do 2009. godine odrađivao je pripravnički staž u Kliničkoj bolnici Dubrava. Pohađao je od 2009. do 2010. godine Poslijediplomski specijalistički studij "Strateško poduzetništvo" na Ekonomskom fakultetu Sveučilišta u Zagrebu. 2011. godine upisuje Poslijediplomski doktorski studij "Biomedicina i zdravstvo" na Medicinskom fakultetu Sveučilišta u Zagrebu, koji je završio 2016. godine. Od 2005. godine radi kao mladi istraživač u Laboratoriju za neurofarmakologiju, Zavoda za farmakologiju Medicinskog fakulteta Sveučilišta u Zagrebu, pod vodstvom prof. dr. sc. Zdravka Lackovića. Specijalizaciju iz otorinolaringologije i kirurgije glave i vrata je započeo 2011. godine u Kliničkoj bolnici Sveti Duh. U sklopu specijalizacije usavršavao se u klinikama u Hrvatskoj, Njemačkoj i SAD-u, a specijalistički ispit iz otorinolaringologije položio je 2016. godine. Te iste godine započeo je subspecijalističko usavršavanje u sklopu EAFPS (*engl.* The European Academy of Facial Plastic Surgery) u Nizozemskoj, pod vodstvom dr. sc. Peter JFM Lohuisa. Ukupno do sada je sudjelovao na preko 20 kongresa, 15 tečajeva te je objavio 8 radova u međunarodnim publikacijama.

## 12. Objavljeni radovi

### Objavljeni radovi uključeni u disertaciju:

1. Lacković Z, Filipović B, Matak I, Helyes Z. **Activity of botulinum toxin type A in cranial dura: implications for treatment of migraine and other headaches.** Br J Pharmacol. 2016;173:279-91.
2. Filipović B, Matak I, Lacković Z. **Dural neurogenic inflammation induced by neuropathic pain is specific to cranial region.** J Neural Transm. 2014;121:555-63.
3. Filipović B, Matak I, Bach-Rojecky L, Lacković Z. **Central action of peripherally applied botulinum toxin type A on pain and dural protein extravasation in rat model of trigeminal neuropathy.** PLoS One. 2012;7:e29803.
4. Filipović B, Gjurić M, Hat J, Glunčić I. **High mega jugular bulb presenting with facial nerve palsy and severe headache.** Skull Base 2010;20:465-8.
5. Filipović B, Bach-Rojecky L, Lacković Z. **Lasting reduction of postsurgical hyperalgesia after single injection of botulinum toxin type A in rat.** Fundam Clin Pharmacol. 2010;24:43-5.

### Objavljeni radovi vezani uz temu koji nisu uključeni u disertaciju:

1. Matak I, Bach-Rojecky L, Filipović B, Lacković Z. **Behavioral and immunohistochemical evidence for central antinociceptive activity of botulinum toxin A.** Neuroscience. 2011; 186:201-7.
2. Bach-Rojecky L, Relja M, Filipović B, Lacković Z. **Botulinum toxin type A and cholinergic system.** Liječnički vjesnik. 2007;12;407-14.

*Prilozi - Objavljeni znanstveni radovi vezani uz problematiku disertacije*

- I. Filipović B, Bach-Rojecky L, Lacković Z. Lasting reduction of postsurgical hyperalgesia after single injection of botulinum toxin type A in rat. *Fundam Clin Pharmacol* 2010;24:43-5.

**SHORT  
COMMUNICATION**

# Lasting reduction of postsurgical hyperalgesia after single injection of botulinum toxin type A in rat

Boris Filipović<sup>a</sup>, Lidija Bach-Rojecky<sup>b</sup>, Zdravko Lacković<sup>a\*</sup><sup>a</sup>Laboratory of Molecular Neuropharmacology, Department of Pharmacology and Croatian Brain Research Institute, University of Zagreb School of Medicine, Zagreb, Croatia<sup>b</sup>Department of Pharmacology, University of Zagreb School of Pharmacy and Biochemistry, Zagreb, Croatia**Keywords**botulinum toxin type A,  
pain,  
surgery**ABSTRACT**

A single injection of low doses of botulinum toxin type A (3.5 U/kg) completely abolished secondary mechanical hyperalgesia throughout its duration in a model of post surgical pain after gastrocnemius incision in rat.

Received 9 February 2009;  
revised 21 May 2009;  
accepted 6 July 2009

\*Correspondence and reprints:  
lac@mef.hr

**INTRODUCTION**

Nearly 50% of surgical patients suffer from intense post surgical pain [1]. Opioids and non-opioid drugs are used to alleviate this problem, but it persists to be an issue.

The most common experimental approach to the study of postsurgical hyperalgesia is the incisional model of pain [2]. Diverse drugs reduce incision-induced mechanical hyperalgesia in rats, but only morphine has been proven to be 100% effective, with results lasting only for a few hours [3].

There is a continually rising number of reports suggesting long-lasting antinociceptive effect of botulinum toxin type A (BTX-A) in both humans and animals [4,5]. It is generally assumed that the mechanism of BTX-A-induced antinociception might be the prevention of neurotransmitter release from the primary sensory neurons [6]. Here, we report that single injection of BTX-A completely abolished secondary hyperalgesia after gastrocnemius incision in rats.

**MATERIALS AND METHODS**

A total number of 50 male Wistar rats (300–350 g) were included in the study. The Principles of Laboratory

Animal Care (NIH Publication 86-23, 1985) were followed, and approval was granted by the Ethical Committee, University of Zagreb School of Medicine.

**Drugs**

Botulinum toxin type A (BOTOX; Allergan, Irvine, CA, USA); chloral hydrate and ethanol (Sigma, St Louis, MO, USA).

Forty-five animals were anaesthetized by a single intraperitoneal injection of chloral hydrate (300 mg/kg). A 3-cm longitudinal incision was made through the skin of the midportion of the posterior hind limb starting 1–1.5 cm from the edge of the heel and extending to the popliteal region [2]. Longitudinal incision of gastrocnemius muscle (parallel with muscular fibers) was done. After hemostasis, the skin was sutured. Sutures were removed 3 days after the procedure.

Five unoperated rats served as control. Sensitivity to mechanical stimuli was measured in terms of paw withdrawal after painful pressure as described by Randall and Selitto [7]. The measurements were performed three times in 10-min intervals. The experimenter was unaware of the treatment groups. Animals which developed secondary hyperalgesia (27 out of 45)

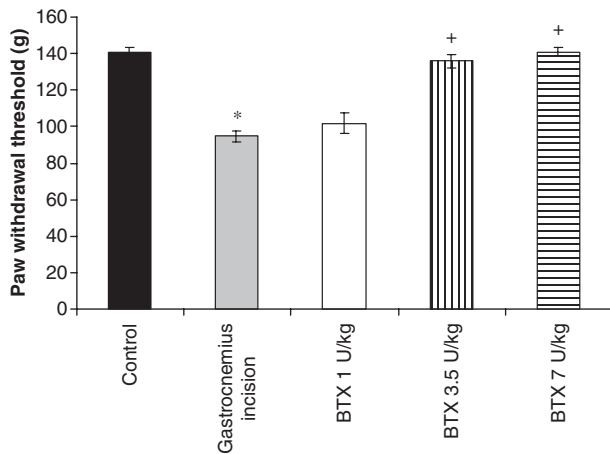
after 24 h (paw-withdrawal threshold reduced for at least 35% compared to the unoperated controls) were injected subcutaneously either with saline or BTX-A (1, 3.5 and 7 U/kg) into the plantar surface of the hindpaw pad (in a volume 20  $\mu$ L). In the time-course experiment, mechanical sensitivity was measured on day 1, 6, 10 and 14 following the BTX-A injection.

Results are presented as mean  $\pm$  SE. Statistical analysis was performed using ANOVA and Newman–Keuls post hoc test. In the time-course experiment, two-way ANOVA for repeated measurements followed by Tukey's test was applied.  $P < 0.05$  was considered significant.

## RESULTS AND DISCUSSION

BTX-A (3.5 and 7 U/kg) produced a complete reversal of mechanical hyperalgesia measured on day 6 after the toxin application (Figure 1). Since paw withdrawal was measured, results might be influenced by decreased muscular strength which, in turn, could be induced by BTX-A. However, it was previously shown by Cui *et al.* [8] (and in our laboratory: unpublished) that BTX-A in a dose of 7 U/kg did not affect motor performance in the rotarod test.

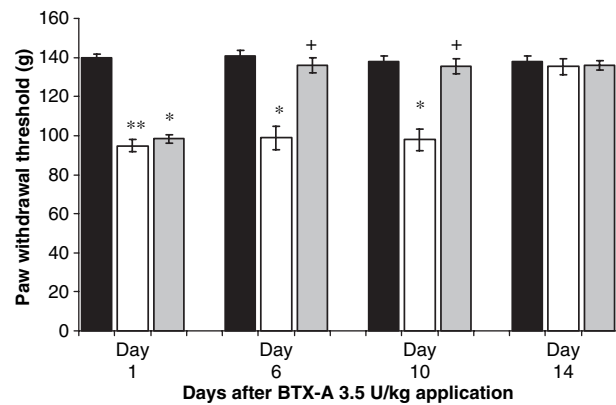
BTX-A (3.5 U/kg) did not influence mechanical pain threshold on day 1 after its application. However, on



**Figure 1** Dose-dependent antinociceptive effect of BTX-A on mechanical hyperalgesia in experimental model of postsurgical pain. Measurements were done on day 6 after BTX-A subcutaneous application into the rat hindpaw. Control, saline-treated unoperated animals ( $n = 5$ ); gastrocnemius incision, saline-treated group after gastrocnemius incision ( $n = 6$ ); BTX 1 U/kg ( $n = 7$ ), BTX 3.5 U/kg ( $n = 8$ ) and BTX 7 U/kg ( $n = 6$ )—BTX-A-treated groups after gastrocnemius incision. Mean  $\pm$  SE, \* $P < 0.001$  compared to control; + $P < 0.001$  compared to gastrocnemius incision (ANOVA and Newman–Keuls post hoc test).

days 6 and 10, BTX-A completely abolished the secondary mechanical hyperalgesia (Figure 2). This is in line with our previous report on experimental neuropathy where BTX-A reduced hyperalgesia starting from day 5 and lasting for 10 more days [5]. On day 14 following the gastrocnemius incision, there was no difference between the tested groups (Figure 2), indicating that post surgical hyperalgesia ceased. Our results are in line with three open label clinical trials. Dohin *et al.* found that intramuscular BTX-A pretreatment decreases the duration of postoperative pain and improves the comfort in 9 children with cerebral palsy after limb surgery [9]. Wittekindt *et al.* [10] report reduced chronic and shooting pain lasting 4 weeks after subcutaneous injection of BTX-A in 16 patients after neck dissection. They also report similar results, pain reduction after a single subcutaneous injection of BTX-A in 13 patients after neck dissection, in their more recent dose-finding study [11].

Keeping in mind the number of patients suffering from postsurgical pain and inadequate treatments, our finding that single BTX-A injection completely abolished hyperalgesia for at least 10 days in the experimental model of postsurgical pain seems to be of major importance. Together with three before-mentioned clinical trials, our findings emphasize the need for further controlled clinical trials.



**Figure 2** Time-course of the antinociceptive effect of BTX-A (3.5 U/kg) on mechanical hypersensitivity in experimental model of post surgical pain. Black bars, saline-treated unoperated controls ( $n = 5$ ); White bars, saline-treated group after gastrocnemius incision ( $n = 6$ ); Gray bars, BTX-A treated group after gastrocnemius incision ( $n = 8$ ). Mean  $\pm$  SE, \* $P < 0.01$ , \*\* $P < 0.001$  compared to saline-treated unoperated controls; + $P < 0.01$  compared to saline-treated group after gastrocnemius incision (ANOVA for repeated measurements followed by Tukey HSD test).

## ACKNOWLEDGEMENTS

We acknowledge Bozica Hržan for technical assistance. Supported by the Croatian Ministry of Science, Education and Sports (Project No. 108-1080003-0001 to Z. Lacković) and Deutscher Akademischer Austausch Dienst (DAAD).

## REFERENCES

- 1 Chavuin M. Relieving postoperative pain. *Presse Med.* (1999) **28** 203–211.
- 2 Pogatzki E.M., Niemeir J.S., Brennan T.J. Persistent secondary hyperalgesia after gastrocnemius incision in rat. *Eur. J. Pain* (2002) **6** 295–305.
- 3 Whiteside G.T., Harrison J., Boulet J., et al. Pharmacological characterization of a rat model of incisional pain. *Br. J. Pharmacol.* (2004) **141** 85–91.
- 4 Jabbari B. Botulinum neurotoxins in the treatment of refractory pain. *Nat. Clin. Pract. Neurol.* (2008) **4** 676–685.
- 5 Bach-Rojecky L., Relja M., Lackovic Z. Botulinum toxin type A in experimental neuropathic pain. *J. Neural Transm.* (2005) **112** 215–219.
- 6 Aoki K.R. Review of a proposed mechanism for the antinociceptive action of botulinum toxin type A. *Neurotoxicology* (2005) **26** 785–793.
- 7 Randall L.O., Selitto J.J. A method for measurement for analgesic activity of inflamed tissue. *Arch. Int. Pharmacodyn. Ther.* (1957) **111** 409–419.
- 8 Cui M., Khanijou S., Rubino J., Aoki K.R. Subcutaneous administration of botulinum toxin A reduces formalin-induced pain. *Pain* (2004) **107** 25–133.
- 9 Dohin B., Garin C., Vanhems P., Kohler R. Botulinum toxin for postoperative care after limb surgery in cerebral palsy children. *Rev. Chir. Orthop. Reparatrice. Appar. Mot.* (2007) **93** 674–681.
- 10 Wittekindt C., Liu W.C., Klussmann J.P., Guntinas-Lichius O. Botulinum toxin type A for the treatment of chronic neck pain after neck dissection. *Head Neck* (2004) **26** 39–45.
- 11 Wittekindt C., Liu W.C., Preuss S.F., Guntinas-Lichius O. Botulinum toxin for neuropathic pain after neck dissection: a dose-finding study. *Laryngoscope* (2006) **116** 1168–1171.

- II. Filipović B, Gjurić M, Hat J, Glunčić I. High mega jugular bulb presenting with facial nerve palsy and severe headache. *Skull Base* 2010;20:465-8.



# High Mega Jugular Bulb Presenting with Facial Nerve Palsy and Severe Headache

Boris Filipović, M.D.,<sup>1</sup> Mislav Gjurić, M.D., Ph.D.,<sup>1</sup> Josip Hat, M.D., Ph.D.,<sup>2</sup> and Ivo Glunčić, M.D., Ph.D.<sup>3</sup>

## ABSTRACT

We present a rare case of a 50-year-old female patient with symptomatic high mega jugular bulb requiring surgery. We review her medical file, preoperative and postoperative imaging, audiograms, and surgical report. High jugular bulb was diagnosed with computed tomography and magnetic resonance imaging. Symptoms of facial nerve palsy and headache were abolished after surgical procedure. Headache and facial nerve palsy can be caused by high mega jugular bulb. Surgery is indicated in such symptomatic cases and leads to relief of signs and symptoms of disease.

**KEYWORDS:** High jugular bulb, facial nerve palsy, headache, surgery, jugular foramen

High mega jugular bulb is a vascular abnormality of the internal jugular vein (IJV) at the jugular foramen. The position and size of the jugular bulb are extremely variable. High jugular bulb (HJB) is diagnosed if the cranial margin of the jugular bulb extends over the inferior surface of the bony annulus, protruding into the middle ear or over the basal turn of the cochlea. In one histological study, HJB was found in 3.5% of 815 temporal bone samples.<sup>1</sup> If the jugular bulb is large in cross-diameter, it is called *mega jugular bulb*, regardless of its position. In two-thirds of the population, the jugular bulb and the jugular vein on the right side are significantly larger than the ones on the left side.<sup>2</sup> A jugular bulb diverticulum is a localized expansion of the jugular bulb wall, with a potential of causing pressure to the surrounding structures that leads to various symptoms.<sup>3</sup>

In most cases, HJB remains asymptomatic, but sometimes symptoms of ear disease are present.<sup>4</sup> The symptoms related to a jugular bulb diverticulum depend on its localization. A lateral protrusion toward the tympanic cavity leads to symptoms of conductive hearing

loss and pulsatile tinnitus, whereas a medial localization toward the petrous apex can cause vertigo, sensorineural hearing loss, and tinnitus.<sup>5</sup> HJB can even mimic Ménière's disease with severe acute vertiginous attacks, as reported in a case study of six patients.<sup>6</sup> So far, three patients were described in the literature who had various forms of facial nerve involvement ranging from facial twitching and recurrent facial paralysis to episodic hemifacial spasm.<sup>7-9</sup> In regard to this rare clinical entity, we add a fourth case and evaluate the presentation and management considerations.

## CASE REPORT

In this report, we present a 50-year-old female patient, who was referred with persisting headache lasting for 28 months despite various medical treatments. Her main symptom was an incapacitating headache starting behind the right ear and extending to the right side of the face. The headache was present in a laying or bending position, usually for a period of several hours.

<sup>1</sup>Health center "Sinteza"; <sup>2</sup>Department of Radiology, Clinical Hospital "Sestre milosrdnice," School of Medicine, University of Zagreb, Zagreb, Croatia; <sup>3</sup>Department of Otorhinolaryngology, Clinical Hospital Center Split, School of Medicine, University of Split, Split, Croatia.

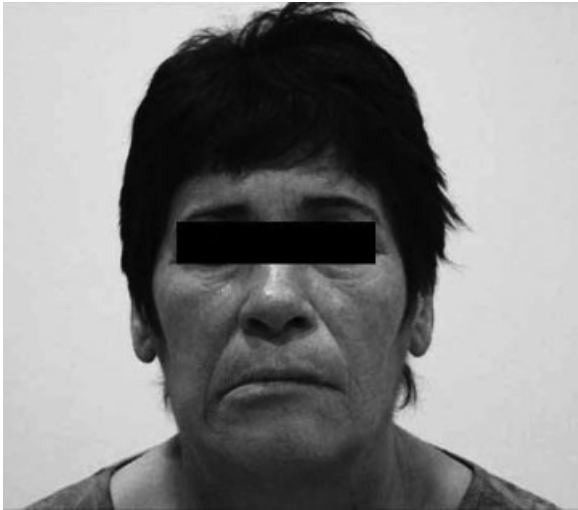
Address for correspondence and reprint requests: Mislav Gjurić, M.D., Ph.D., Health Center "Sinteza," Zagreb, Croatia (e-mail: mg@poliklinika-sinteza.hr).

Skull Base 2010;20:465-468. Copyright © 2010 by Thieme Medical Publishers, Inc., 333 Seventh Avenue, New York, NY 10001, USA. Tel: +1 (212) 584-4662.

Received: March 29, 2010. Accepted: April 19, 2010. Published online: June 11, 2010.

DOI: <http://dx.doi.org/10.1055/s-0030-1261259>.

ISSN 1531-5010.

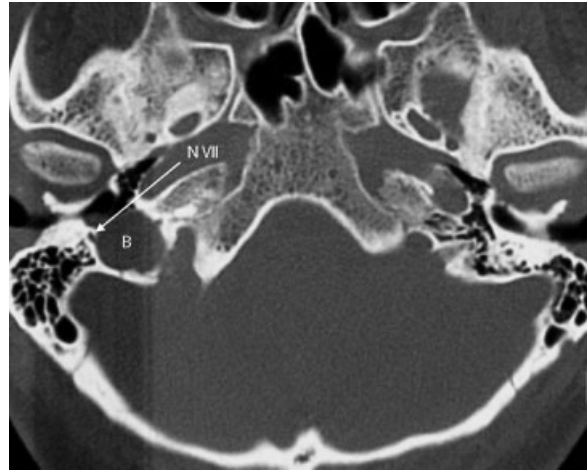


**Figure 1** Patient presenting with right-sided facial nerve palsy limited to the corner of the mouth (with patient approval).

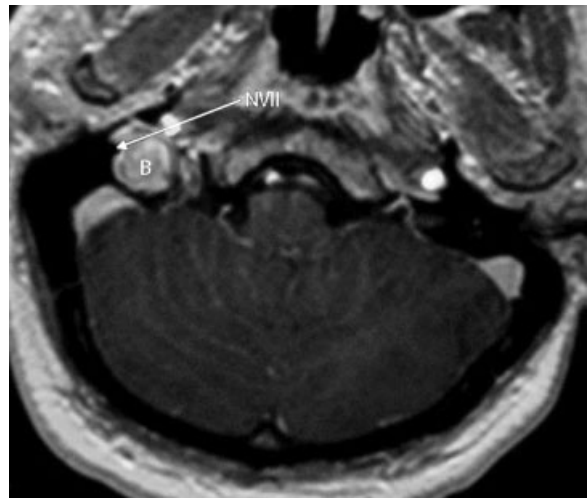
With each attack, the headache was becoming more intense. Soon it was so severe that the patient was neither able to perform her daily activities nor do her job and was constantly on narcotic analgesics. One month after the headache started, she developed an ipsilateral lower facial asymmetry on resting and smiling. Two months later, she reported right-sided hearing loss and tinnitus.

Head and neck examination revealed right peripheral facial nerve palsy limited to the corner of the mouth (Fig. 1). Audiological testing demonstrated tympanometry and stapedial reflexes within the normal range and a mild right sensorineural hearing loss of 34 dB. Needle electromyoneurography of the musculus zygomaticus and musculus orbicularis oris showed signs of chronic neural lesion, registered as a significantly reduced motor conduction velocity and reduced amplitude of the compound muscle action potential in the right facial nerve, as compared with the opposite side. The patient underwent high-resolution computed tomography (CT) scan with the standard radiological protocol for the inner ear (Fig. 2), magnetic resonance imaging (MRI) scan (Figs. 3 and 4), and 3-D angiography and postcontrast venography (Fig. 5). Imaging demonstrated a high-positioned mega jugular bulb on the right side with a diverticulum at its cranial curvature reaching the vestibular aqueduct (Fig. 5). Additionally, intimate contact of the HJB with the mastoid segment of the facial nerve was shown (Fig. 4).

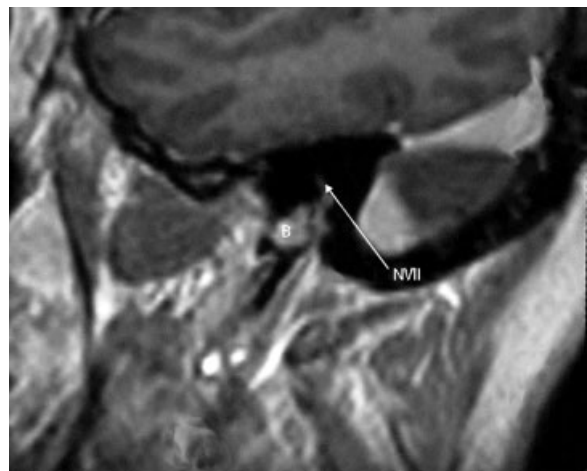
The patient was advised to undergo a surgical exploration of the jugular foramen area with exposure of the facial nerve and removal of the jugular bulb anomaly. A retroauricular skin incision with extension to the neck was used to expose the mastoid and the IJV in the neck. Complete mastoidectomy was performed, exposing the sigmoid sinus and the facial nerve in the mastoid and the



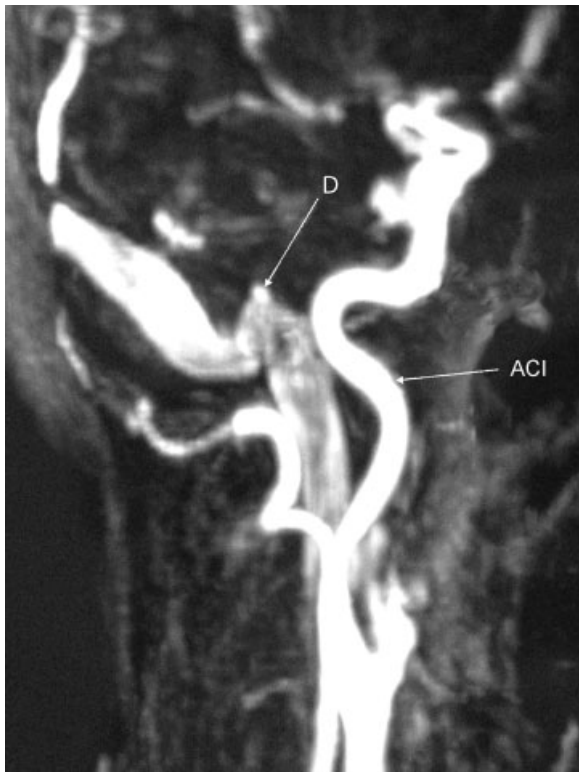
**Figure 2** CT axial scan: high jugular bulb (B) protruding into tympanic cavity, with close contact to the mastoid segment of facial nerve (N VII).



**Figure 3** MRI T1 axial scan (equivalent plain): contrast-enhanced, HJB (B) protruding into tympanic cavity, mastoid segment of facial nerve (N VII).



**Figure 4** MRI T1 3-D contrast-enhanced, oblique reconstruction image: mastoid part of the facial nerve (N VII) in contact with the HJB (B).



**Figure 5** Dynamic contrast-enhanced angiography: arterial and venous phase, right internal carotid artery (ACI), HJB diverticulum (D).

stylomastoid foramen. The sigmoid sinus was extraluminally packed with Surgicel (Ethicon, Neuchatel, China) and the IVJ ligated in the neck. The bony canal of the facial nerve was found eroded by the pressure of the HJB in a short segment inferior to the posterior semicircular canal toward the level of the digastric ridge. The denuded facial nerve was separated from the HJB, which was then resected, keeping its medial wall preserved. Patching of the bone defect and multilayer wound closure concluded the procedure.

Immediately after surgery, there was a dramatic drop in the intensity of the headache. Right facial nerve palsy, which developed in the early postoperative period, resolved completely after 2 months. The hearing loss remained unchanged and the tinnitus diminished shortly after the operation. One year after surgery, the patient is well and working again. From time to time, she experiences some pain, which is different in character and due to vertebral discopathy (C3–C7). The patient is at present undergoing physical therapy for this problem.

## DISCUSSION

Anatomic variations and anomalies of the IJV at the jugular foramen are common but mainly asymptomatic. If present, symptoms are related to the jugular foramen mass and lead to unilateral hearing loss, aural fullness, tinnitus, and vestibular symptoms. Otalgia and mi-

grainlike headache are possible in patients with different vascular anomalies, whereas symptoms of cranial nerve involvement are extremely rare.<sup>10</sup> Jahrsdoerfer et al, in the review of literature on jugular bulb diverticula, mentioned one patient with facial twitching.<sup>8</sup> Pappas et al reported a case of a young woman with a history of recurrent facial paralysis since age 16 years and episodic hemifacial spasm between episodes of paralysis.<sup>9</sup> Like our patient, she also suffered from frequent parietal headaches, and the facial paralysis was also limited to the lower face. The patient did not undergo surgery. Gal et al presented a 33-year-old woman with jugular diverticulum and facial paralysis who underwent transmastoid surgery with posterior tympanotomy.<sup>7</sup> Facial nerve decompression led to recovery of its function.

In a patient with clinical symptoms of jugular foramen mass, it is mandatory to rule out the presence of an expanding tumor (cholesteatoma, neurilemmoma, meningioma, or paraganglioma) and the existence of vascular anomalies (enlarged jugular bulb or aberrant internal carotid artery). The correct diagnosis is made from an imaging study including high-resolution CT scan and MRI scan. Vascular pathology is evaluated with CT, magnetic resonance angiography, and digital subtraction angiography. In our patient, CT scan demonstrated a wide HJB that protruded into the tympanic cavity and reached the external auditory canal, which was dehiscent. There were no signs of osteolysis or destruction of surrounding pneumatic cells. Contrast enhancement of the lesion was homogenic; MRI scan showed hypointense signal in the T1 and T2 sequences (flow signal void), and postcontrast enhancement of the lesion was homogenic, consistent with the CT scan. The HJB was in close contact with and compressed the mastoid part of the facial nerve canal. There was no contrast enhancement of surrounding structures that would suggest additional anomaly or tumor. 3-D time-of-flight magnetic resonance angiography showed a normal aspect of internal carotid artery and other arteries. Postcontrast venography showed the characteristic pattern of HJB.

Management of high mega jugular bulb must be individualized. Asymptomatic cases are discovered while evaluating unrelated pathology and do not require treatment. The appreciation of the existence of HJB is of extreme importance if surgical procedures are planned in the ear. Rare cases of symptomatic cranial nerve involvement merit surgical consideration. A high index of suspicion and a reasonable degree of plausibility of symptoms possibly explained by the existence of HJB or jugular diverticulum must be present. Competency of the contralateral venous drainage must be established prior to surgery. Surgery itself is a standard lateral skull base procedure with minimal morbidity and high chances of success in properly evaluated cases.

## CONCLUSION

The presence of HJB can cause severe headache and facial palsy. Diagnosis is confirmed with CT, MRI, and vascular imaging studies. In such symptomatic cases, surgical management is reasonable and has high chances of success in alleviating the symptoms and problems.

## REFERENCES

1. Subotić R. The high position of the jugular bulb. *Acta Otolaryngol* 1979;87:340–344
2. Swartz JD, Harnsberger HR. *Imaging of the Temporal Bone*. 3rd ed. New York: Thieme; 1998:193–195
3. Wadin K, Wilbrand H. The jugular bulb diverticulum. A radioanatomic investigation. *Acta Radiol Diagn (Stockh)* 1986;27:395–401
4. Wadin K, Thomander L, Wilbrand H. Effects of a high jugular fossa and jugular bulb diverticulum on the inner ear. A clinical and radiologic investigation. *Acta Radiol Diagn (Stockh)* 1986;27:629–636
5. Presutti L, Laudadio P. Jugular bulb diverticula. *ORL J Otorhinolaryngol Relat Spec* 1991;53:57–60
6. Sterkers O, Bozorg Grayeli A, Julien N, Bouccara D, Rihane S, Chaigne P. [Jugular bulb diverticulum mimicking Menière's disease. Surgical treatment] [in French]. *Ann Otolaryngol Chir Cervicofac* 1993;110:363–371
7. Gal M, Darrouzet V, Pescio P, Vincey P, Bébéar JP. [Jugular bulb diverticular and facial paralysis] [in French]. *Rev Laryngol Otol Rhinol (Bord)* 1999;120:43–46
8. Jahrsdoerfer RA, Cail WS, Cantrell RW. Endolymphatic duct obstruction from a jugular bulb diverticulum. *Ann Otol Rhinol Laryngol* 1981;90(6 Pt 1):619–623
9. Pappas DG Jr, Hoffman RA, Cohen NL, Holliday RA, Pappas DG Sr. Petrous jugular malposition (diverticulum). *Otolaryngol Head Neck Surg* 1993;109:847–852
10. Adelman JU. Headaches and papilledema secondary to dural arteriovenous malformation. *Headache* 1998;38:621–623

- III. Filipović B, Matak I, Bach-Rojecky L, Lacković Z. Central action of peripherally applied botulinum toxin type A on pain and dural protein extravasation in rat model of trigeminal neuropathy. PLoS One 2012;7:e29803.



# Central Action of Peripherally Applied Botulinum Toxin Type A on Pain and Dural Protein Extravasation in Rat Model of Trigeminal Neuropathy

Boris Filipović<sup>1,3</sup>, Ivica Matak<sup>1</sup>, Lidija Bach-Rojecky<sup>2</sup>, Zdravko Lacković<sup>1\*</sup>

**1** Laboratory of Molecular Neuropharmacology, Department of Pharmacology and Croatian Brain Research Institute, University of Zagreb School of Medicine, Zagreb, Croatia, **2** Department of Pharmacology, University of Zagreb School of Pharmacy and Biochemistry, Zagreb, Croatia, **3** Department of Otorhinolaryngology-Head and Neck Surgery, University Hospital Sveti Duh, Zagreb, Croatia

## Abstract

**Background:** Infraorbital nerve constriction (IoNC) is an experimental model of trigeminal neuropathy. We investigated if IoNC is accompanied by dural extravasation and if botulinum toxin type A (BoNT/A) can reduce pain and dural extravasation in this model.

**Methodology/Principal Findings:** Rats which developed mechanical allodynia 14 days after the IoNC were injected with BoNT/A (3.5 U/kg) into vibrissal pad. Allodynia was tested by von Frey filaments and dural extravasation was measured as colorimetric absorbance of Evans blue - plasma protein complexes. Presence of dural extravasation was also examined in orofacial formalin-induced pain. Unilateral IoNC, as well as formalin injection, produced bilateral dural extravasation. Single unilateral BoNT/A injection bilaterally reduced IoNC induced dural extravasation, as well as allodynia (lasting more than 2 weeks). Similarly, BoNT/A reduced formalin-induced pain and dural extravasation. Effects of BoNT/A on pain and dural extravasation in IoNC model were dependent on axonal transport through sensory neurons, as evidenced by colchicine injections (5 mM, 2  $\mu$ l) into the trigeminal ganglion completely preventing BoNT/A effects.

**Conclusions/Significance:** Two different types of pain, IoNC and formalin, are accompanied by dural extravasation. The lasting effect of a unilateral injection of BoNT/A in experimental animals suggests that BoNT/A might have a long-term beneficial effect in craniofacial pain associated with dural neurogenic inflammation. Bilateral effects of BoNT/A and dependence on retrograde axonal transport suggest a central site of its action.

**Citation:** Filipović B, Matak I, Bach-Rojecky L, Lacković Z (2012) Central Action of Peripherally Applied Botulinum Toxin Type A on Pain and Dural Protein Extravasation in Rat Model of Trigeminal Neuropathy. PLoS ONE 7(1): e29803. doi:10.1371/journal.pone.0029803

**Editor:** Louis S. Premkumar, Southern Illinois University School of Medicine, United States of America

**Received:** June 21, 2011; **Accepted:** December 5, 2011; **Published:** January 4, 2012

**Copyright:** © 2012 Filipović et al. This is an open-access article distributed under the terms of the Creative Commons Attribution License, which permits unrestricted use, distribution, and reproduction in any medium, provided the original author and source are credited.

**Funding:** This study was supported by the Croatian Ministry of Science, Education and Sport (Project No. 108-1080003-0001) and Deutscher Akademischer Austausch Dienst (DAAD) project awarded to Professors Peter Riederer, Jürgen Deckert and Zdravko Lacković. The funders had no role in study design, data collection and analysis, decision to publish, or preparation of the manuscript.

**Competing Interests:** The authors have declared that no competing interests exist.

\* E-mail: lac@mef.hr

## Introduction

In animals, long-lasting antinociception of peripherally applied botulinum toxin type A (BoNT/A) was reported in inflammatory pain induced by formalin [1], carrageenan and capsaicin [2], [3], peripheral neuropathic pain [4]–[8], postsurgical pain [9], experimental cystitis [10] and prostatitis [11]. Bilateral effect of unilaterally applied BoNT/A was demonstrated in different models [12]–[14]. Retrograde transport in sensory neurons and central site of BoNT/A action were suggested [12], [13] to explain this bilateral effect.

Infraorbital nerve constriction injury (IoNC) accompanied by hyperalgesia and allodynia is used as a model of trigeminal neuropathy in rats [15]. Standard antimigraine drugs, like 5-HT<sub>1B/1D</sub> receptor agonists and some antiepileptics reduce mechanical allodynia and hyperalgesia after the IoNC [16], [17]. BoNT/A pretreatment prevented the development of IoNC-induced trigeminal neuropathy [7], [8].

In the present study we found that: (1.) two types of pain in trigeminal region, IoNC and formalin injection, are, apart from mechanical allodynia, accompanied by dural protein extravasation; (2.) BoNT/A, besides bilateral reduction of pain, also bilaterally reduces dural extravasation in IoNC model; (3.) BoNT/A effects on pain and dural neurogenic inflammation are dependent on axonal transport in trigeminal sensory neurons.

## Materials and Methods

### Animals and Ethics statement

A total number of 200 male Wistar rats (300–350 g), bred in our animal facility (University of Zagreb School of Medicine, Croatia), were included in the study. Animals were kept under a constant 12 h/12 h light/dark cycle with unlimited access to food and water. The experiments were conducted according to the National Institute of Health Guide for the Care and Use of Laboratory Animals (Publication No. 85-23, revised 1996) and

approved by the Ethical Committee of the University of Zagreb, School of Medicine (permit No. 07-76/2005-43).

## Drugs

The following drugs were used: botulinum toxin type A (Botox<sup>®</sup>, Allergan, Inc., Irvine, CA, USA); chloral hydrate, colchicine and formamide (Sigma, St. Louis, MO, USA); Evans blue (Merck KGaA, Darmstadt, Germany); formalin (Kemika, Zagreb, Croatia). Colchicine was reconstituted in 0.9% saline to obtain the 5 mM concentration. Each vial of Botox<sup>®</sup> contains 100 U of purified *Clostridium botulinum* type A neurotoxin complex. One unit of Botox<sup>®</sup> contains approximately 48 pg of whole molecular complex of BoNT/A, with molecular weight of 900 kDa. In order to obtain the dose needed, BoNT/A was reconstituted in adequate volume of 0.9% saline. Evans blue was reconstituted in 0.9% saline to obtain the required dose (40 mg/kg). Formalin was diluted to 2.5% concentration with saline.

BoNT/A was injected subcutaneously (s.c.) in a volume of 20  $\mu$ l with a 27  $\frac{1}{2}$  gauge syringe into the ipsilateral or contralateral vibrissal pad of conscious, restrained rats. Control animals were injected with saline. BoNT/A dose of 3.5 U/kg was chosen on the basis of previous experiments [1], [13], [18]. Colchicine (2  $\mu$ l) was injected into the trigeminal ganglion (i.g.) of anesthetized rat as described by Neubert et al. [19]. Hamilton syringe needle (Hamilton Microliter #701, Hamilton, Bonaduz, Switzerland) was inserted through the skin into the infraorbital foramen, and advanced through the infraorbital canal and foramen rotundum into the trigeminal ganglion. Formalin was injected subcutaneously (s.c.) into the vibrissal pad of conscious, restrained rats in a volume of 50  $\mu$ l with a 27  $\frac{1}{2}$  gauge syringe.

## Surgery

Animals were anesthetized by a single intraperitoneal injection of chloral hydrate (300 mg/kg). Chronic constriction injury to the left infraorbital nerve was performed as described previously [15]. The skin on the left side of the forehead and nose of the rat was shaved. 1 ml of saline was injected into the medial portion of the orbit to elevate the eye in order to gain a better access to the infraorbital nerve. A mid-line scalp incision was made, exposing skull and nasal bone. Electrocauterization was used to prevent bleeding. The intraorbital part of infraorbital nerve was exposed using a modified surgical procedure [20]. Medial edge of the orbit was dissected free and orbital contents were gently elevated using small cotton balls. The infraorbital nerve was dissected and two silk ligatures (5-0) were placed around the nerve spaced 2 mm apart. The ligatures reduced the diameter of the nerve by just a noticeable amount and they did not interrupt the epineurial circulation, as previously described [21]. Orbital content was then gently moved back to orbit. Skin and underlying fascia were sutured in layers with nylon sutures (4-0). Sham operation was performed by exposing infraorbital nerve without placing silk ligatures.

## Mechanical allodynia testing

Von Frey monofilaments (Stoelting Co., Wood Dale, IL, USA) were used for mechanical stimulation. The filaments produced a bending force of 0.16, 0.4, 0.6, 1, 2, 4, 6, 8, 10 and 15 g. Testing was performed as previously described in detail by Kayser et al. [17]. The rats were placed in a small transparent plastic cage for ten minutes to accommodate to the experimental environment until they assumed their normal sniffing/no locomotion position. For each session, series of von Frey filaments were applied on the tested side of the face in ascending order, starting at 0.16 g, until a defined behavioral response was elicited. Each time, the measurement started on the side contralateral to IoNC injury. A positive reaction

to the stimulation within the IoN territory, at the center of the vibrissal pad area, consisted of a rapid withdrawal of the head and/or attack/escape reaction [15]. If no response was observed, we assigned 15 g as the withdrawal threshold, since the pressure exerted by thickest (15 g) filament was enough to push the head of sham-operated rats. Measurements were performed three times for each filament on both sides of the face in 10 min intervals. Baseline measurements were performed one day prior to the IoNC injury. Pain sensitivity was retested fourteen days following the IoNC injury (day 0). Time between the surgery and testing was chosen based on the time required for full development of mechanical sensitivity in IoNC model [15], [17] and aimed to exclude the possible influence of postsurgical hyperalgesia on pain testing [9]. Only animals which developed bilateral mechanical allodynia (we defined it as responsiveness to 0.16–2 g on both sides) were included in the further study (approximately 70% of the IoNC operated animals).

## Dural extravasation

Evans blue (dye which complexes with plasma proteins) technique is routinely used to investigate the effects of nociceptive afferents on vascular function [3], [22]. Animals were injected with 1 ml Evans blue solution (40 mg/kg) into the tail vein. After stimulation of the vibrissal pad area with von Frey filament (2 g) for a period of 10 minutes, animals were deeply anesthetized by chloral hydrate (300 mg/kg, i.p), the thorax was opened and the right atrium incised for drainage. Saline (500 ml) was perfused via left ventricle at a constant rate. The brain was carefully removed and the cranial cavity rinsed with saline to remove residual blood and cerebrospinal fluid prior to dissection of the dura. The dura covering supratentorial region of the brain, primarily innervated by trigeminal nerve [23], was harvested from left and right side separately. To assess bilateral dural extravasation, dural tissue from 4 animals was pooled in one sample (left and right side separately) and weighted. Average weight was 10–18 mg. Collected tissue was incubated in 2 ml of formamide at 37°C for 48 h. Colorimetric absorbance measurements of Evans blue formamide extracts were carried out with a spectrophotometer (Iskra, Ljubljana, Slovenia) at 620 nm.

## Experimental design

**Time course of bilateral mechanical allodynia.** Animals which developed mechanical allodynia on day 14 after IoNC were divided in 4 groups (5–8 animals): 1. Sham operated; 2. IoNC+Saline; 3. IoNC+BoNT/A (ipsi.) (BoNT/A injected ipsilateral to the IoNC injury); 4. IoNC+BoNT/A (contra.) (BoNT/A injected contralateral to the IoNC injury). Measurements of mechanical sensitivity were further repeated on day 3, 6, 20 and 30 following BoNT/A single injection (day 0).

**Bilateral assessment of dural neurogenic inflammation.** Plasma dural extravasation was investigated in additional 4 groups of animals (20 animals per group): 1. Sham operated; 2. IoNC+Saline; 3. IoNC+BoNT/A (ipsi.); 4. IoNC+BoNT/A (contra.) Fourteen days after the IoNC injury, neuropathic animals were selected similarly to that described above, and injected with BoNT/A or saline. Three days after the injection, allodynia was retested and Evans blue technique was employed to test dural plasma protein extravasation.

**Characterization of axonal transport of BoNT/A.** To test the role of axonal transport of BoNT/A in sensory neurons for its effects on bilateral neuropathic pain and dural extravasation, an axonal transport blocker colchicine was injected into the trigeminal ganglion.

After 24 hrs, animals pre-treated with colchicine were injected s.c. into the vibrissal pad with BoNT/A or saline into the side ipsilateral to the IoNC injury and colchicine injection.

Animals were divided in 5 groups: Sham; IoNC+saline (i.g.)+saline (s.c.); IoNC+saline (i.g.)+BoNT/A (s.c.); IoNC+colchicine (i.g.)+saline (s.c.); IoNC+colchicine (i.g.)+BoNT/A (s.c.).

Experimental procedure for bilateral measurements of mechanical allodynia and dural extravasation was similar to that described above, except that the dural samples were not divided into left and right sides and were not pooled, because we observed no significant difference between dural extravasation on opposite sides.

**Orofacial formalin test.** Animals pretreated with saline or BoNT/A (3.5 U/kg into the vibrissal pad) 3 days prior to testing were injected with Evans blue. Immediately following Evans Blue administration the animals were injected unilaterally with 2.5% formalin (50 µl) into the BoNT/A treated vibrissal pad and placed in transparent cages for 45 min of observation. Behavioral testing was performed as previously described [18], [24]. In brief, facial rubbing time (in seconds) was measured in 3 minute intervals for a period of 45 min.

Following behavioral testing, animals were immediately anesthetized and perfused with saline. Left and right sides of dural tissue were excised and pooled from two animals.

Animals were divided in 3 groups (8 animals per group): 1. control: saline (s.c.); 2. saline (s.c.)+formalin (s.c.); 3. BoNT/A (s.c.)+formalin (s.c.).

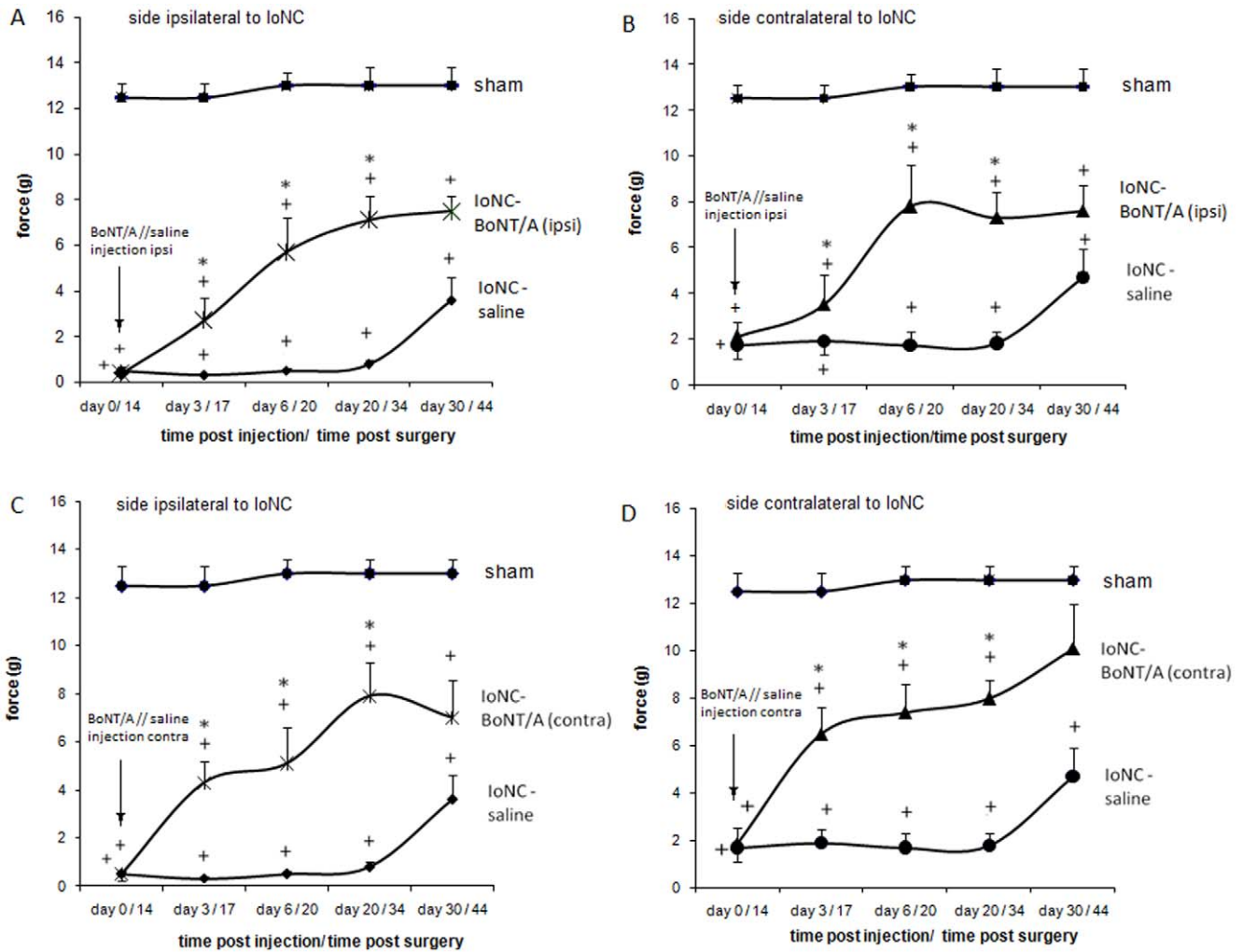
**Statistical analysis**

The results were presented as mean ± S.E.M and analyzed by ANOVA followed by the Newman-Keuls post hoc test for between-group differences. In the time-course experiment ANOVA was employed for repeated measurements followed by Tukey’s test. P<0.05 was considered significant.

**Results**

**Effects of BoNT/A on allodynia induced by IoNC injury**

BoNT/A (3.5 U/kg) injected s.c. into the vibrissal pad (ipsilaterally to the nerve injury) of animals which developed



**Figure 1. Botulinum toxin A (3.5 U/kg) decreases mechanical allodynia induced by IoNC- injury in rats.** BoNT/A was injected into the vibrissal pad ipsilaterally (A and B) or contralaterally (C and D) to the side of the nerve injury. Measurements were performed on the ipsilateral (A and C) and contralateral (B and D) side to the nerve injury. Legend: ■ – sham-operated control; ◆ - saline-injected IoNC operated animals when measured on the ipsilateral side; ● - saline-injected IoNC operated animals when measured on the contralateral side; \* - BoNT/A-injected IoNC operated animals when measured on the ipsilateral side; ▲ – BoNT/A-injected IoNC operated animals when measured on the contralateral side. Mean ± S.E.M; n = 5–8 (n- indicates the number of animals per group). \*P<0.01 - BoNT/A-injected compared to saline-injected animals; +P<0.001 - BoNT/A-injected or saline-injected animals compared to sham-operated control. doi:10.1371/journal.pone.0029803.g001



bilateral allodynia 14 days after the IoNC significantly reduced mechanical allodynia on that side, as well as on the contralateral side (Figure 1A and 1B). When BoNT/A was injected contralaterally to the nerve injury, it still reduced mechanical allodynia on both sides of the face (Figure 1C and 1D). The effect on both sides was evident on our first measurement 3 days post BoNT/A injection, and persisted for at least 17 more days. On day 44 following the IoNC injury (day 30 post-BoNT/A application), mechanical allodynia started to disappear (Figure 1 A, B, C, D). To exclude the possibility of BoNT/A passive diffusion away from the site of injection, methylene blue (20 µl) was injected into the vibrissal pad. The colour only resided near the place of injection and did not spread away from the site of injection (data not shown). Moreover, animals injected into the vibrissal pad with 3.5 U/kg of BoNT/A or even higher doses (15 U/kg) did not exhibit impaired rotarod performance which excludes possible systemic effect (results not shown).

**Effects of BoNT/A on dural extravasation after IoNC injury**

In the IoNC operated saline treated rats with bilateral mechanical allodynia, dural extravasation (measured as ng of Evans blue per mg of dural tissue) was measured three days after BoNT/A injection into the vibrissal pad, i.e. 17-days post-IoNC injury. BoNT/A (3.5 U/kg) abolished bilateral dural extravasation in the IoNC injured rats (Figure 2). Botulinum toxin exerted the effect on dural extravasation when injected both ipsilaterally or contralaterally to the site of nerve injury (Figure 2).

**Effect of BoNT/A on mechanical allodynia and dural extravasation after IoNC injury is axonal transport dependent**

Mechanical bilateral allodynia and dural extravasation were significantly reduced 2 and 3 days following the BoNT/A injection into the vibrissal pad. When axonal transport blocker colchicine was injected ipsilateral to BoNT/A injection into the trigeminal ganglion, BoNT/A failed to reduce bilateral mechanical allodynia (Figure 3) and dural neurogenic extravasation (Figure 4). Colchicine itself did not alter either mechanical allodynia (Figure 3) or dural neurogenic inflammation induced by IoNC (Figure 4), although it was previously shown that it affects thermal hyperalgesia in experimental animals [25].

**Orofacial formalin test**

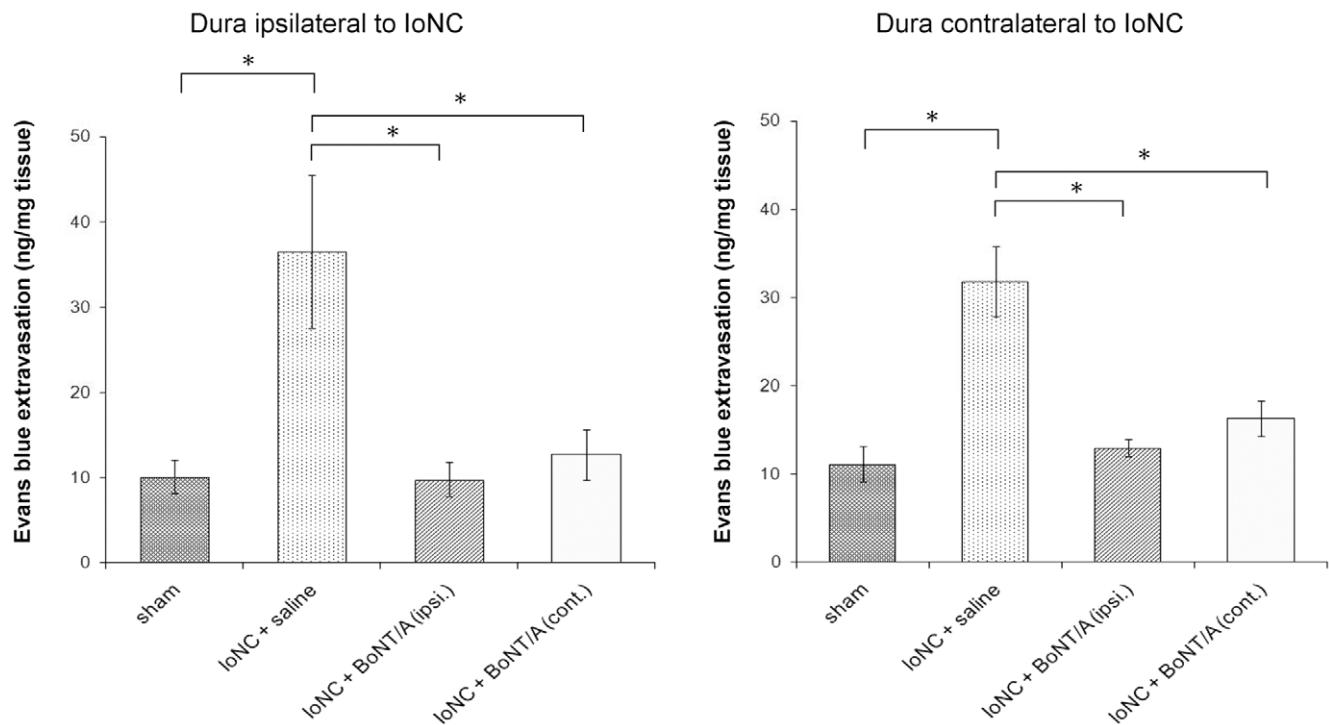
BoNT/A (3.5 U/kg) reduced formalin-induced painful behaviour, measured as time of facial rubbing, during phase II of formalin test (results not shown), which is in line with our previous findings [18].

Formalin-induced orofacial pain also resulted in bilateral dural extravasation (measured as amount of Evans-blue extravasated dye), similarly to IoNC. Unilaterally applied BoNT/A reduced dural extravasation on both sides, as well (Figure 5).

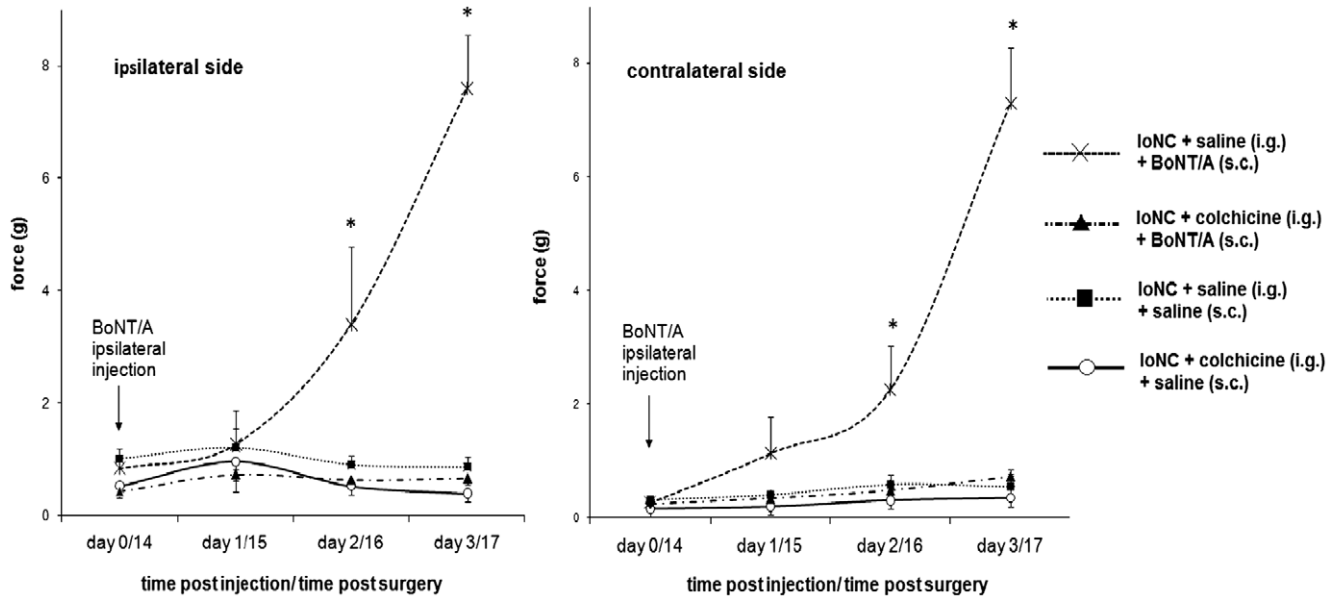
**Discussion**

**Trigeminal pain-evoked dural protein extravasation**

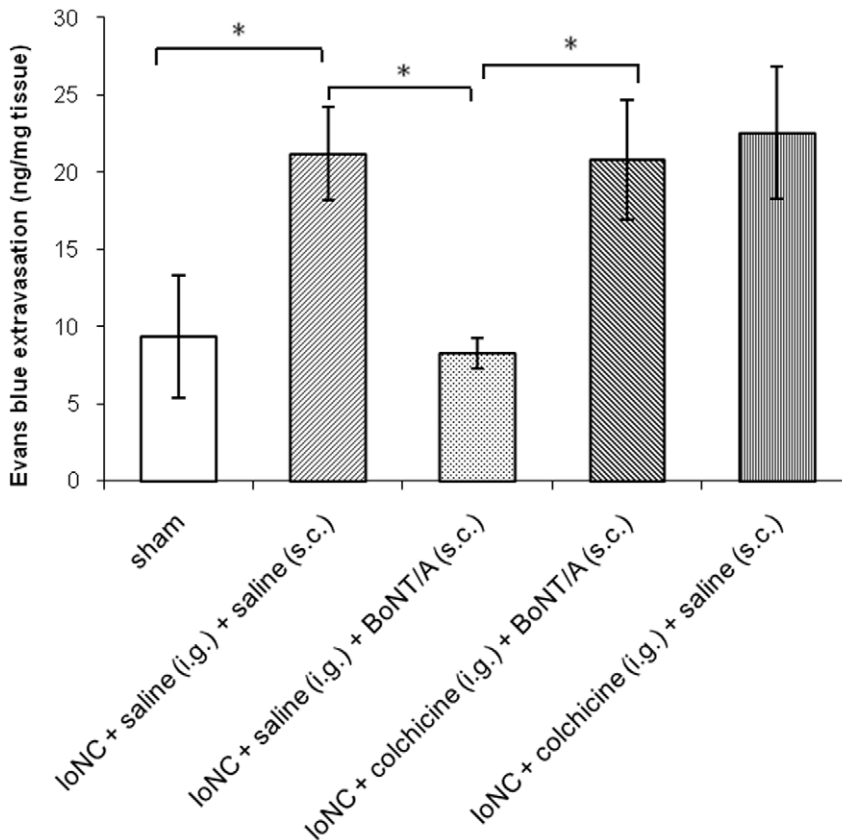
Dural neurogenic inflammation is a phenomenon which is only superficially investigated. There is sparse evidence for its existence



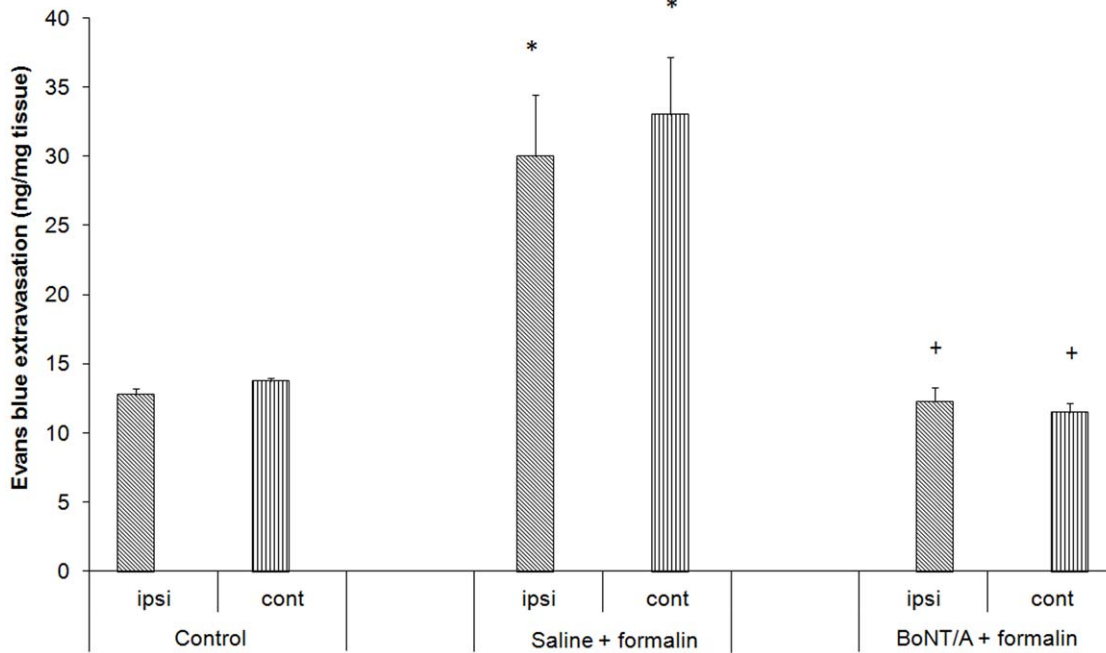
**Figure 2. Botulinum toxin A (3.5 U/kg) decreases dural extravasation in IoNC injured rats.** BoNT/A was injected into the vibrissal pad 14 days after infraorbital constriction ipsilaterally or contralaterally to the side of nerve injury. Absorbances of Evans blue extracted from dural tissue after incubation in formamide were measured. Each sample consists of combined dural tissue of 4 animals. Corresponding amounts of Evans blue were calculated from calibration curve, and divided by the wet mass of corresponding dural samples. Legend: Sham-operated animals; *IoNC+saline* – saline injected animals after IoNC injury; *IoNC+BoNT/A (ipsi.)* – BoNT/A injected ipsilaterally in IoNC operated animals; *IoNC+BoNT/A (contra.)* – BoNT/A injected contralaterally in IoNC operated animals. Mean ± S.E.M., n=5 (n-indicates the number of samples per group). \*P<0.01 (Newman Keuls post-hoc). doi:10.1371/journal.pone.0029803.g002



**Figure 3. BoNT/A (3.5 U/kg) decreases IoNC-induced mechanical allodynia which is prevented by intraganglionic colchicine pretreatment.** Animals were injected into the trigeminal ganglion with colchicine 24 hrs prior to s.c. BoNT/A or saline injection into the vibrissal pad (both injections given into the ipsilateral side to the IoN injury). Animals were divided in 5 groups: Sham operated; IoNC+saline (i.g.)+saline (s.c.); IoNC+saline (i.g.)+BoNT/A; IoNC+colchicine (i.g.)+saline (s.c.); IoNC+colchicine (i.g.)+BoNT/A (s.c.). Measurements were performed on the ipsilateral and contralateral side to the nerve injury. Sham operated values (around 12.5±0.5 g) were not shown. Mean ± S.E.M., n=6 (n-indicates the number of animals per group). \*P<0.01 compared to IoNC+saline (i.g.)+saline (s.c.); IoNC+colchicine (i.g.)+saline (s.c.); IoNC+colchicine (i.g.)+BoNT/A (s.c.) (Tukey's test). doi:10.1371/journal.pone.0029803.g003



**Figure 4. BoNT/A (3.5 U/kg) decreases dural extravasation in IoNC-injured rats which is prevented by intraganglionic colchicine.** Animals were injected into the trigeminal ganglion with colchicine 24 hrs prior to s.c. BoNT/A or saline injection into the vibrissal pad (both injections given into the ipsilateral side to the IoN injury). Absorbances of Evans blue extracted from dural tissue after incubation in formamide were measured. Legend: i.g. - intraganglionic; s.c. - subcutaneous injection. Data are represented as mean ± S.E.M., n=6 (n-indicates the number of samples per group). \*P<0.01 (Newman Keuls post-hoc). doi:10.1371/journal.pone.0029803.g004



**Figure 5. BoNT/A (3.5 U/kg) decreases orofacial formalin-induced dural extravasation.** Dural extravasation was induced by formalin injection into the vibrissal pad (2.5% formalin, 50  $\mu$ l). Ipsilateral vibrissal pad was injected with saline of BoNT/A 3 days prior to formalin injection. Amount of Evans blue extracted from dural tissue after incubation in formamide was measured. Ipsi: dural tissue ipsilateral to injections; Cont: dural tissue contralateral to injections. Control: saline -injected animals; saline+formalin: animals injected with saline and formalin; BoNT/A+formalin: animals injected with BoNT/A and formalin. Data are represented as mean  $\pm$ SEM.  $n=4$  ( $n$  -number of samples/group), \*,  $P<0.05$  compared to control; +  $P<0.05$  compared to saline+formalin (Newman-Keuls post hoc). doi:10.1371/journal.pone.0029803.g005

in humans [26] and it was primarily investigated in relation to migraine in an animal model [27]–[31]. According to trigemino-vascular theory, migraine is associated with activation of trigeminal nerve afferents which innervate dura, leading to release of neuropeptides like calcitonin gene related peptide (CGRP) and substance P (SP) [32]. It can be evoked by electrical stimulation of trigeminal ganglion and systemic chemical or immunological stimulation [33]. Classical antimigraine agents (like ergot alkaloids, triptans), decrease dural plasma protein extravasation after electrical stimulation of trigeminal ganglion [27]–[31].

As a new finding of this study we have shown that dural extravasation can be induced by two different types of trigeminal pain (neuropathic and inflammatory).

Nerves which innervate the dura (middle meningeal nerve) and area innervated by infraorbital nerve (affected by IoNC and formalin) belong to the maxillary trigeminal branch, but they are distinct and physically separated [23]. Possible explanations for dural extravasation after IoNC and formalin could be: (1) interactions between neurons innervating the injured infraorbital nerve area with adjacent neurons in trigeminal ganglion innervating dural vessels, and/or (2) central cross-excitation inside spinal trigeminal nucleus in the brainstem. Mutual activation between the adjacent neurons of the same ganglion has been described in trigeminal and dorsal root ganglia [34], [35]. Based on the animal model of chemical stimulation of dura, it was proposed that the coexistence of dural extravasation and allodynia is modulated by excitation of nociceptive neurons in trigeminal nucleus caudalis, a convergent point of sensory inputs from dura and facial skin [36], [37].

Allodynia and dural extravasation on the side contralateral to nerve injury might be associated with spreading of excitation to contralateral nuclei, via unknown neural pathways. It is shown

that unilateral electrical stimulation of trigeminal ganglion results in bilateral decrease of neuropeptides, suggesting the activation of contralateral trigeminal pathway [38]. Using unilateral injection of retrograde tracers, Jacquin et al. [39] found that some primary trigeminal afferents cross the midline and terminate in contralateral dorsal horn, which might explain our observation.

#### Bilateral effect of BoNT/A on allodynia and dural extravasation

It was recently demonstrated that BoNT/A counteracts the development of unilateral neuropathy which follows IoNC [7], [8]. Previously mentioned studies used a different experimental setup: contralateral side was sham-operated, and BoNT/A was administered before the development of neuropathy. In our present study, sham operation was done on a separate group of animals and, additionally, we administered BoNT/A following the full development of neuropathic pain. Using this approach, we have observed BoNT/A bilateral effects on allodynia, lasting over a period of one month. This effect was seen even when BoNT/A was applied to the uninjured side (Figure 1).

Bilateral pain reduction after unilateral peripheral BoNT/A injection has recently been demonstrated in models of paclitaxel-induced polyneuropathy [14], diabetic neuropathy [13] and acidic saline-induced mechanical hyperalgesia in rats [12]. Bach-Rojecky and Lacković [12] demonstrated that BoNT/A effects are CNS mediated and dependent on axonal transport. Apart from bilateral pain reduction in IoNC, effect of BoNT/A was bilateral in both IoNC and formalin-evoked dural extravasation. Contralateral effect of BoNT/A might ensue via contralaterally terminating afferent sensory fibers [39] or by transcytosis within central neurons, as suggested by some authors [7], [40].

The mechanism of BoNT/A action on pain and dural extravasation is unclear. It might be connected with BoNT/A effects on CGRP/SP release. In several *in vitro* studies on cultured trigeminal ganglion neurons or brainstem slices, BoNT/A reduced stimulated CGRP release [41]–[43]. In addition, BoNT/A reduces Substance P release in rabbit iris sphincter [44]. Since an increased level of CGRP might be important in vasodilatation and transmission of pain in migraine, some authors propose that BoNT/A effectiveness in migraine is associated with reduced CGRP release from trigeminal neurons [41], [45], [46].

### Axonal transport of BoNT/A in sensory trigeminal neurons

Axonal transport of BoNT/A has recently been demonstrated in motoneurons [40] and sensory neurons [18]. Truncated SNAP-25 was immunohistochemically demonstrated in medullary dorsal horn after BoNT/A (3.5 U/kg) injection into the rat vibrissal pad [18]. Apparently, BoNT/A enters peripheral trigeminal nerve endings and is axonally transported through the trigeminal ganglion to the spinal trigeminal nucleus.

Since axonal transport to CNS was shown to be necessary for antinociceptive activity of BoNT/A [12], [18], we hypothesized that bilateral reduction of allodynia and dural extravasation are dependent on BoNT/A axonal transport in sensory neurons. In line with this hypothesis is our present finding that BoNT/A effectively reduced pain and dural extravasation even when applied to uninjured side of neuropathic animals.

Colchicine, prevented both effects of peripherally applied BoNT/A, most probably by blocking axonal transport of

BoNT/A in trigeminal sensory neurons. These results additionally exclude bilateral effect due to possible peripheral spreading to uninjected side of the face. Importantly, this experiment also shows that trigeminal sensory system is the primary site of BoNT/A action and excludes possible involvement of extracranial autonomous nerves.

### Conclusion

Present results demonstrate for the first time that bilateral dural neurogenic inflammation can be evoked by experimental pain in trigeminal region. Both pain and dural neurogenic inflammation can be prevented by single BoNT/A peripheral injection, provided by axonal transport in sensory neurons. Although the central site of BoNT/A action seems the only logical explanation, the precise mechanism requires further elucidation. The possibility that dural extravasation occurs in other types of extracranial pain and its importance for trigeminal pain pathophysiology should be further investigated.

### Acknowledgments

We are grateful to Božica Hržan for her excellent technical assistance.

### Author Contributions

Conceived and designed the experiments: BF ZL. Performed the experiments: BF IM. Analyzed the data: BF IM LB. Contributed reagents/materials/analysis tools: ZL. Wrote the paper: BF IM LB ZL.

### References

- Cui M, Khanjoui S, Rubino J, Aoki KR (2004) Subcutaneous administration of botulinum toxin A reduces formalin-induced pain. *Pain* 107: 125–133.
- Bach-Rojecky L, Lacković Z (2005) Antinociceptive effect of botulinum toxin type A in rat model of the carrageenan and capsaicin induced pain. *Croat Med J* 46: 201–208.
- Bach-Rojecky L, Dominis M, Lacković Z (2008) Lack of anti-inflammatory effects of botulinum toxin A in experimental models of inflammation. *Fundam Clin Pharmacol* 22: 503–509.
- Bach-Rojecky L, Relja M, Lacković Z (2005) Botulinum toxin type A in experimental neuropathic pain. *J Neural Transm* 112: 215–219.
- Park HJ, Lee Y, Lee J, Park C, Moon DE (2006) The effects of botulinum toxin A on mechanical and cold allodynia in a rat model of neuropathic pain. *Can J Anaesth* 53: 470–477.
- Luisetto S, Marinelli S, Cobiainchi S, Pavone F (2007) Antiallodymic efficacy of botulinum neurotoxin A in a model of neuropathic pain. *Neuroscience* 145: 1–4.
- Kitamura Y, Matsuka Y, Spigelman I, Ishihara Y, Yamamoto Y, et al. (2009) Botulinum toxin type A (150 kDa) decreases exaggerated neurotransmitter release from trigeminal ganglion neurons and relieves neuropathy behaviors induced by infraorbital nerve constriction. *Neuroscience* 59: 1422–1429.
- Kumada A, Matsuka Y, Spigelman I, Maruhama K, Yamamoto Y, et al. (2011) Intradermal injection of Botulinum toxin type A alleviates infraorbital nerve constriction-induced thermal hyperalgesia in an operant assay. *J Oral Rehabil* doi: 10.1111/j.1365-2842.2011.02236.x.
- Filipović B, Bach-Rojecky L, Lacković Z (2010) Lasting reduction of postsurgical hyperalgesia after single injection of botulinum toxin type A in rat. *Fundam Clin Pharmacol* 24: 43–45.
- Smith CP, Radziszewski P, Borkowski A, Somogyi GT, Boone TB, et al. (2004) Botulinum toxin A has antinociceptive effect in treating interstitial cystitis. *Urology* 64: 871–875.
- Chuang YC, Yoshimura N, Huang CC, Wu M, Chiang PH, et al. (2008) Intraprostatic botulinum toxin A injection inhibits cyclooxygenase-2 expression and suppresses prostatic pain on capsaicin induced prostatitis model in rat. *J Urol* 180: 742–748.
- Bach-Rojecky L, Lacković Z (2009) Central origin of the antinociceptive action of botulinum toxin type A. *Pharmacol Biochem Behav* 94: 234–238.
- Bach-Rojecky L, Šalković-Petrišić M, Lacković Z (2010) Botulinum toxin type A reduces pain supersensitivity in experimental diabetic neuropathy: bilateral effects after unilateral injection. *Eur J Pharmacol* 633: 10–14.
- Favre-Guilhard C, Auguet M, Chabrier PE (2009) Different antinociceptive effects of botulinum toxin type A in inflammatory and peripheral polyneuropathic rat models. *Eur J Pharmacol* 617: 48–53.
- Vos BP, Strassman AM, Maciewicz RJ (1994) Behavioral evidence of trigeminal neuropathic pain following chronic constriction injury to the rat's infraorbital nerve. *J Neurosci* 74: 2708–2723.
- Christensen D, Gautron M, Guilbaud G, Kayser V (2001) Effect of gabapentin and lamotrigine on mechanical allodynia-like behaviour in a rat model of trigeminal neuropathic pain. *Pain* 93: 147–153.
- Kayser V, Aube B, Hamon M, Bourgoin S (2002) The antimigraine 5-HT<sub>1B/1D</sub> receptor agonists, sumatriptan, zolmitriptan and dihydroergotamine, attenuate pain-related behaviour in a rat model of trigeminal neuropathic pain. *Br J Pharmacol* 137: 1287–1297.
- Matak I, Bach-Rojecky L, Filipović B, Lacković Z (2011) Behavioral and immunohistochemical evidence for central antinociceptive activity of botulinum toxin A. *Neuroscience* 86: 201–207.
- Neubert JK, Mannes AJ, Keller J, Wexel M, Iadarola MJ, et al. (2005) Peripheral targeting of the trigeminal ganglion via the infraorbital foramen as a therapeutic strategy. *Brain Res Brain Res Protoc* 15: 119–126.
- Gregg JM (1973) A surgical approach to the ophthalmic-maxillary nerve trunks in the rat. *J Dent Res* 52: 392.
- Bennett GJ, Xie YK (1998) A peripheral mononeuropathy in rat that produces disorders like those seen in men. *Pain* 33: 87–107.
- Kolston J, Lisney SJ (1993) A study of vasodilator responses evoked by antidromic stimulation of A delta afferent nerve fibers supplying normal and reinnervated rat skin. *Microvasc Res* 46: 143–157.
- Larrier D, Lee A (2003) Anatomy of headache and facial pain. *Otolaryngol Clin North Am* 36: 1041–1053.
- Raboison P, Dalle R (2004) The orofacial formalin test. *Neurosci Biobehav Rev* 28: 219–226.
- Yamamoto T, Yaksh TL (1993) Effects of colchicine applied to the peripheral nerve on the thermal hyperalgesia evoked with chronic nerve constriction. *Pain* 55: 227–233.
- Knotkova H, Pappagallo M (2007) Imaging intracranial plasma extravasation in a migraine patient: a case report. *Pain Med* 8: 383–387.
- Saito K, Markowitz S, Moskowitz MA (1988) Ergot alkaloids block neurogenic extravasation in dura mater: proposed action in vascular headaches. *Ann Neurol* 24: 732–737.
- Buzzi MG, Sakas DE, Moskowitz MA (1989) Indomethacin and acetylsalicylic acid block neurogenic plasma protein extravasation in rat dura mater. *Eur J Pharmacol* 165: 251–258.
- Buzzi MG, Moskowitz MA (1991) Evidence for 5-HT<sub>1B/1D</sub> receptors mediating the antimigraine effect of sumatriptan and dihydroergotamine. *Cephalalgia* 11: 165–168.

30. Lee WS, Limmroth V, Ayata C, Cutrer FM, Waerber C, et al. (1995) Peripheral GABAA receptor-mediated effects of sodium valproate on dural plasma protein extravasation to substance P and trigeminal stimulation. *Br J Pharmacol* 116: 1661–1667.
31. Nelson DL, Phebus LA, Johnson KW, Waincott DB, Cohen ML, et al. (2010) Preclinical pharmacological profile of the selective 5-HT<sub>1F</sub> receptor agonist lasmiditan. *Cephalalgia* 30: 1159–1169.
32. Moskowitz MA (1990) Basic mechanisms in vascular headache. *Neurol Clin* 8: 801–815.
33. Markowitz S, Saito K, Moskowitz MA (1987) Neurogenically mediated leakage of plasma protein occurs from blood vessels in dura mater but not brain. *J Neurosci* 7: 4129–4136.
34. Amir R, Devor M (2000) Functional cross-excitation between afferent A- and C-neurons in dorsal root ganglia. *Neuroscience* 95: 189–195.
35. Thalakoti S, Patil VV, Damodaram S, Vause CV, Langford LE, et al. (2007) Neuron–glia signaling in trigeminal ganglion: implications for migraine pathology. *Headache* 47: 1008–1023.
36. Burstein R, Yamamura H, Malick A, Strassman AM (1998) Chemical stimulation of intracranial dura induces enhanced responses to facial stimulation in brainstem trigeminal neurons. *J Neurophysiol* 79: 964–982.
37. Yamamura H, Malick A, Nancy L, Chamberlin NL, Burstein R (1999) Reduction of the threshold of cardiovascular and neuronal responses to facial and intracranial stimulation reflects central sensitization and cutaneous allodynia in a rat model of migraine. *J Neurophysiol* 81: 479–493.
38. Samsam M, Coveñas R, Csilik B, Ahangari R, Yajeya J, et al. (2001) Depletion of substance P, neurokinin A and calcitonin gene-related peptide from the contralateral and ipsilateral caudal trigeminal nucleus following unilateral electrical stimulation of the trigeminal ganglion; a possible neurophysiological and neuroanatomical link to generalized head pain. *J Chem Neuroanat* 21: 161–169.
39. Jacquin FM, Nicolas L, Rhoades WR (1990) Trigeminal projections to contralateral dorsal horn: central extent, peripheral origins, and plasticity. *Somatosens Mot Res* 7: 153–183.
40. Antonucci F, Rossi C, Gianfranceschi L, Rossetto O, Caleo M (2008) Long distance retrograde effects of botulinum neurotoxin A. *J Neurosci* 28: 3689–3696.
41. Durham PL, Cady R (2004) Regulation of calcitonin gene-related peptide secretion from trigeminal nerve cells by botulinum toxin type A: implications for migraine therapy. *Headache* 44: 35–43.
42. Meng J, Wang J, Lawrence G, Dolly O (2007) Synaptobrevin I mediates exocytosis of CGRP from sensory neurons and inhibition by botulinum toxins reflects their anti-nociceptive potential. *J Cell Sci* 120: 2864–2874.
43. Meng J, Ovsepian SV, Wang J, Pickering M, Saase A, et al. (2009) Activation of TRPV 1 mediates calcitonin gene-related peptide release, which excites trigeminal sensory neurons and is attenuated by a retargeted botulinum toxin with anti-nociceptive potential. *J Neurosci* 29: 4981–4992.
44. Ishikawa H, Mitsui Y, Yoshitomi T, Mashimo K, Aoki S, et al. (2000) Presynaptic effects of botulinum toxin type A on the neuronally evoked response of albino and pigmented rabbit iris sphincter and dilator muscles. *Jpn J Ophthalmol* 44: 106–109.
45. Doods H, Arndt K, Rudolf K, Just S (2007) CGRP antagonists: unraveling the role of CGRP in migraine. *Trends Pharmacol Sci* 28: 580–587.
46. Villalón CM, Olesen J (2009) The role of CGRP in the pathophysiology of migraine and efficacy of CGRP receptor antagonists as acute antimigraine drugs. *Pharmacol Ther* 124: 309–323.

IV. Filipović B, Matak I, Lacković Z. Dural neurogenic inflammation induced by neuropathic pain is specific to cranial region. *J Neural Transm* 2014;121:555-63.

# Dural neurogenic inflammation induced by neuropathic pain is specific to cranial region

B. Filipović · I. Matak · Z. Lacković

Received: 29 July 2013 / Accepted: 15 December 2013  
© Springer-Verlag Wien 2013

**Abstract** Up to now, dural neurogenic inflammation (DNI) has been studied primarily as a part of migraine pain pathophysiology. A recent study from our laboratory demonstrated the occurrence of DNI in response to peripheral trigeminal nerve injury. In this report, we characterize the occurrence of DNI after different peripheral nerve injuries in and outside of the trigeminal region. We have used the infraorbital nerve constriction injury model (IoNC) as a model of trigeminal neuropathic pain. Greater occipital nerve constriction injury (GoNC), partial transection of the sciatic nerve (ScNT) and sciatic nerve constriction injury (SCI) were employed to characterize the occurrence of DNI in response to nerve injury outside of the trigeminal region. DNI was measured as colorimetric absorbance of Evans blue plasma protein complexes. In addition, cellular inflammatory response in dural tissue was histologically examined in IoNC and SCI models. In comparison to the strong DNI evoked by IoNC, a smaller but significant DNI has been observed following the GoNC. However, DNI has not been observed either in cranial or in lumbar dura following ScNT and SCI. Histological evidence has demonstrated a dural proinflammatory cell infiltration in the IoNC model, which is in contrast to the SCI model. Inflammatory cell types (lymphocytes, plasma cells, and monocytes) have indicated the presence of sterile cellular inflammatory response in the

IoNC model. To our knowledge, this is the first observation that the DNI evoked by peripheral neuropathic pain is specific to the trigeminal area and the adjacent occipital area. DNI after peripheral nerve injury consists of both plasma protein extravasation and proinflammatory cell infiltration.

**Keywords** Dural neurogenic inflammation · Trigeminal region · Nerve injury · Dural extravasation · Cellular inflammatory response

## Abbreviations

DNI	Dural neurogenic inflammation
IoNC	Infraorbital nerve constriction injury
GoNC	Greater occipital nerve constriction injury
ScNT	Partial transection of sciatic nerve
SCI	Sciatic nerve constriction injury

## Background

Neurogenic inflammation is a sterile tissue inflammation found in different diseases including psoriasis, asthma, migraine, etc. (Raychaudhuri and Raychaudhuri 2004; Groneberg et al. 2004; Peroutka 2005). It is evoked by the release of inflammatory neuropeptides such as calcitonin gene related peptide (CGRP) and substance P (SP) from the afferent nerve endings in the affected tissue, resulting in all classical signs of inflammation (Marianna et al. 2008).

Neurogenic inflammation in dura mater (DNI) was studied primarily as a part of migraine pathophysiology (Moskowitz 1990; Peroutka 2005). In the early 1990s, trigeminovascular theory of migraine was formulated based on the series of experiments in which electrical stimulation trigeminal ganglion in experimental animals induces dural

---

B. Filipović · I. Matak · Z. Lacković (✉)  
Laboratory of Molecular Neuropharmacology, Department  
of Pharmacology and Croatian Brain Research Institute,  
University of Zagreb School of Medicine, Šalata 11,  
10000 Zagreb, Croatia  
e-mail: lac@mef.hr

B. Filipović  
Department of Otorhinolaryngology-Head and Neck Surgery,  
University Hospital Sveti Duh, Zagreb, Croatia

extravasation of plasma proteins (Markowitz et al. 1987). Accordingly, it is proposed that trigeminal activation leads to dural neurogenic vasodilatation and plasma protein extravasation during a migraine attack. This, in turn, activates the peripheral nerve endings in the dura mater. Drugs active in migraine are effective in reducing DNI after electrical stimulation of the trigeminal ganglion (Saito et al. 1988; Buzzi et al. 1989; Buzzi and Moskowitz 1991) and this model is regularly used in potential antimigraine drug screening (Nelson et al. 2010). In contrast to numerous animal studies, the evidence for dural neurogenic extravasation in humans during a migraine attack is scarce. In a case report of Knotkova and Pappagallo (2007), dural extravasation of intravenously injected radiolabelled serum albumin was found in a patient during migraine attack. DNI was located ipsilaterally to the reported pain origin.

Recently, we reported that DNI can be evoked by trigeminal pain induced by extracranial stimuli i.e. infraorbital nerve constriction injury (IoNC) or injection of formalin in rats. This effect can be prevented with single peripheral injection of botulinum toxin type A, a recently approved migraine drug (Filipović et al. 2012). This suggests that various peripheral painful stimuli in the trigeminal region cause dural neurogenic inflammation. However, it is not known whether the DNI is linked only to pain in the trigeminal innervation area or it exists as a general phenomenon in the whole body. Here we have found that DNI is selectively present in the cranial dura [IoNC and greater occipital nerve constriction (GoNC) models], but not in the lumbar dura mater [sciatic nerve constriction (SCI) and sciatic nerve transection (ScNT) models]. In addition, we have found that DNI consists of both plasma protein extravasation and sterile cellular inflammatory response.

## Methods

### Animals and ethics statement

A total number of 90 male Wistar rats (300–350 g) bred in our animal facility (University of Zagreb School of Medicine, Croatia) were included in the study. Animals were kept under a constant 12 h/12 h light/dark cycle with unlimited access to food and water. The experiments were conducted according to the National Institutes of Health Guide for the Care and Use of Laboratory Animals (Publication No. 85-23, revised 1996) and approved by the Ethical Committee of the University of Zagreb, School of Medicine (permit No. 07-76/2005-43).

### Drugs

The following drugs were used: formamide (Sigma, St. Louis, MO, USA); Evans blue (Merck KGaA, Darmstadt,

Germany). Evans blue was reconstituted in 0.9 % saline to obtain the required dose (40 mg/kg).

### Surgery

Animals were anesthetized by a single intraperitoneal injection of chloral hydrate (300 mg/kg).

### Infraorbital nerve constriction injury model (IoNC)

Chronic constriction injury to the left infraorbital nerve was performed as described previously in detail (Gregg 1973; Vos et al. 1994; Filipović et al. 2012). In brief, a mid-line scalp incision was made, exposing the skull and the nasal bone. Intraorbital part of the infraorbital nerve was exposed and two silk ligatures (5-0) were placed around the nerve with 2 mm spacing in between. The ligatures slightly reduced the diameter of the nerve without interrupting the epineurial circulation, as previously described (Bennett and Xie 1988). Skin and the underlying fascia were sutured in layers with nylon sutures (4-0). Sham operation was performed by exposing the infraorbital nerve without placing the silk ligatures.

### Greater occipital nerve constriction injury model (GoNC)

A retroauricular incision of the rat skin was performed to identify the distal part of the greater occipital nerve just before entering the posterior surface of the left auricle. The injury was induced by placing two silk ligatures (5-0) around the nerve with 2 mm spacing between them. The incision was sutured with nylon sutures (4-0). A sham operation was performed by exposing the nerve without the constriction injury.

### Partial transection of sciatic nerve model (ScNT)

A partial transection of the sciatic nerve was performed as previously described (Lindenlaub and Sommer 2000; Bach-Rojecky et al. 2005). An incision in the left groin of the rat was made exposing the sciatic nerve. The nerve was cut at least 50 % in diameter and the skin and muscle were sutured with nylon sutures (4-0). A sham operation was performed by exposing the sciatic nerve without injuring it.

### Sciatic nerve constriction injury model (SCI)

Chronic constriction injury to the left sciatic nerve was performed as described previously in detail (Bennett and Xie 1988). In brief, the incision in the left groin of the rat was made exposing the sciatic nerve and two silk ligatures (5-0) were placed around the nerve with 2 mm spacing in between. The ligatures slightly reduced the diameter of the



nerve without interrupting the epineural circulation. Skin and muscle were sutured with nylon sutures (4-0). A sham operation was performed by exposing the sciatic nerve without constriction injury.

#### Behavioral testing

In all the nerve injury models, behavioral testing was performed at 0 and 14 days following the peripheral nerve injury, based on the time required for full development of mechanical sensitivity in IoNC model (Vos et al. 1994) and to exclude the possible influence of postsurgical hyperalgesia on pain testing (Filipović et al. 2010). Von Frey monofilaments (Stoelting Co., Wood Dale, IL, USA) were used for testing the mechanical allodynia in the IoNC, GoNC and SCI models. The filaments produced a calibrated bending force of 0.16, 0.4, 0.6, 1, 2, 4, 6, 8, 10 and 15 g. Testing was performed as described previously in detail by Kayser et al. (2002) and Filipović et al. (2012). Animals which developed bilateral mechanical allodynia were included in further study (around 70 % of the IoNC/GoNC/SCI-operated animals). In the ScNT and SCI models, mechanical hyperalgesia was tested using a standard paw pressure test (Randall and Selitto 1957). Animals which developed unilateral mechanical hyperalgesia (measured as the reduction in paw withdrawal threshold of at least 20 % in comparison to sham-operated controls) were included in further experiment (Bach-Rojecky et al. 2005).

#### Dural extravasation

Intravenous administration of the Evans blue dye, which complexes with plasma proteins, is routinely used to investigate the neurogenic inflammation in experimental animal models. As previously described in detail by Filipović et al. (2012), animals were perfused with saline (500 ml) after the injection of 1 ml Evans blue solution (40 mg/kg) and stimulation of vibrissal pad/paw area (10 min) with the von Frey filament (2 g). Dura covering the supratentorial region of the brain primarily innervated by the trigeminal nerve (Larrier and Lee 2003) was harvested and weighed. In addition, in the ScNT and SCI models the spinal cord was removed and the spinal canal was rinsed with saline. Lumbar dura was harvested and weighed. Collected tissue was incubated in 2 ml of formamide at 37 °C for 48 h. Colorimetric absorbance measurements of Evans blue formamide extracts were performed with a spectrophotometer (Iskra, Ljubljana, Slovenia) at 620 nm.

#### Histological study

Histological examination of the cranial dural tissue was performed in the IoNC model and lumbar dural tissue

in SCI model using classical hematoxylin and eosin (HE) staining. HE-positive cell profiles on dural images were counted automatically using cellSens Dimension programme (Olympus, Japan). Four non-overlapping visual fields were analyzed and mean value was calculated for each animal. In addition, to characterize the specific cell types present in dural inflammation, we performed Giemsa staining of the cranial dura mater after IoNC.

#### Statistical analysis

The results were presented as mean  $\pm$  SEM and analyzed by two-tailed *t* test. *P* < 0.05 was considered significant.

## Results

Dural neurogenic inflammation occurs in neuropathic pain originating from trigeminal (IoNC) and adjacent occipital (GoNC) innervation region

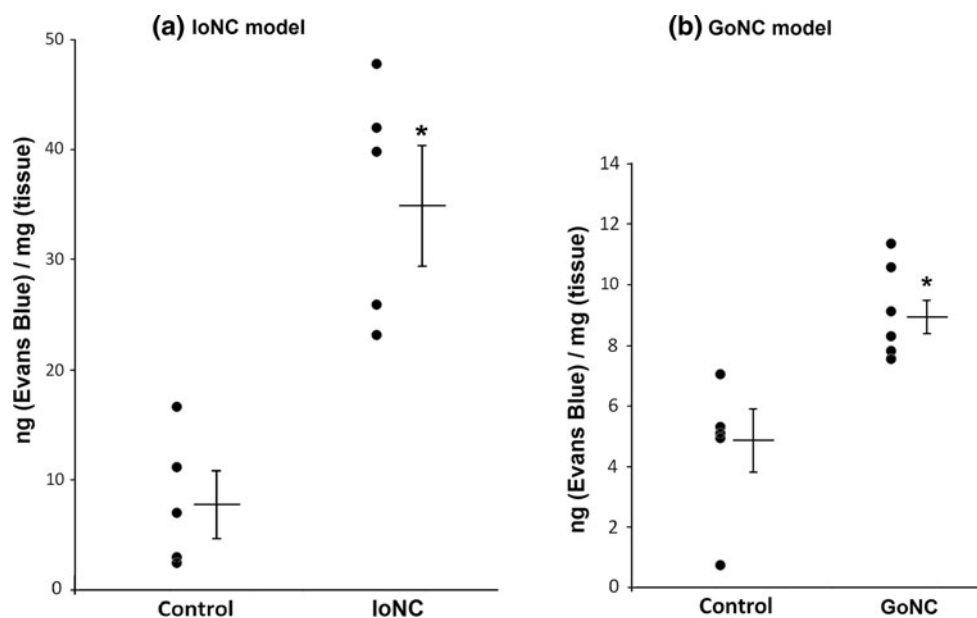
#### Behavioral testing

Mechanical allodynia was present in around 70 % of the animals in IoNC and GoNC models 14 days after the nerve injury. Mechanical allodynia developed bilaterally in both IoNC (von Frey filaments; ipsilateral side neuropathy/sham operated  $0.34 \pm 0.18$  g/13  $\pm$  2.7 g, contralateral side neuropathy/sham operated  $0.3 \pm 0.13$  g/14  $\pm$  2.3 g) and GoNC (von Frey filaments; ipsilateral side neuropathy/sham operated  $0.47 \pm 0.19$ /14  $\pm$  2.3 g, contralateral side neuropathy/sham operated  $0.52 \pm 0.1$  g/15  $\pm$  0 g) (in all comparisons *P* < 0.001).

#### Neurogenic inflammation of cranial dura

We examined whether the occurrence of cranial DNI is connected only to trigeminal nerve injury, or if it may be also evoked by nerve injury in the adjacent innervation areas. Therefore, we assessed the plasma protein extravasation evoked by injured nerve branches from trigeminal (IoNC) and extra-trigeminal nerve regions (GoNC). Dural plasma protein extravasation (measured as amount of Evans blue extravasated dye) was found to be significantly increased in both IoNC and GoNC models compared to sham values. IoNC-evoked dural extravasation was elevated 4.5 times in comparison to sham-operated controls (Fig. 1a), while GoNC-evoked dural extravasation was elevated only two times in comparison to sham-operated controls (Fig. 1b).

**Fig. 1** Protein extravasation of cranial dural tissue is present in neuropathic pain originating from trigeminal and adjacent occipital region. Dural extravasation was tested 14 days following infraorbital nerve constriction injury (a, IoNC) and greater occipital nerve constriction injury (b, GoNC). Graph represents scatter plot of data. Each dot represents the amount (ng/mg tissue) of Evans blue extracted from dura of single animal. Control sham-operated animals, IoNC infraorbital nerve constriction injury animals, GoNC greater occipital nerve constriction injury animals. Cross represents mean  $\pm$  SEM,  $P < 0.05$  compared to control (two-tailed  $t$  test)



Dural neurogenic inflammation does not occur in neuropathic pain originating from sciatic nerve (ScNT and SCI)

#### Behavioral testing

Mechanical hyperalgesia/allodynia was present in around 70 % of the animals in ScNT and SCI models 14 days after the nerve injury. In contrast to bilateral allodynia after injury of cranial nerves (IoNC and GoNC), mechanical hyperalgesia in the operated animals appeared only on the ipsilateral side of the peripheral nerve injury in both ScNT (paw pressure  $94.9 \pm 6.6$  g in neuropathic vs.  $162.0 \pm 7.6$  g in sham operated.  $P < 0.001$ ) and SCI (paw pressure  $89.3 \pm 10.2$  g in neuropathic vs.  $174.4 \pm 9.5$  g in sham operated.  $P < 0.001$ ). Similarly, we observed mechanical allodynia only ipsilaterally to the nerve injury (von Frey filaments; ipsilateral side neuropathy/sham operated  $5.9 \pm 0.9$  g/ $24 \pm 1.2$  g.  $P < 0.001$ ) in the SCI model.

#### Neurogenic inflammation of cranial dura

To exclude the possibility that cranial DNI may be evoked by peripheral nerve injuries in distant non-cranial regions, we assessed the cranial dura plasma protein extravasation in sciatic nerve injury (ScNT and SCI) models. In both neuropathic pain models, plasma protein extravasation (measured as amount of Evans blue extravasated dye) was not significantly altered (Fig. 2a, b).

#### Neurogenic inflammation of lumbar dura

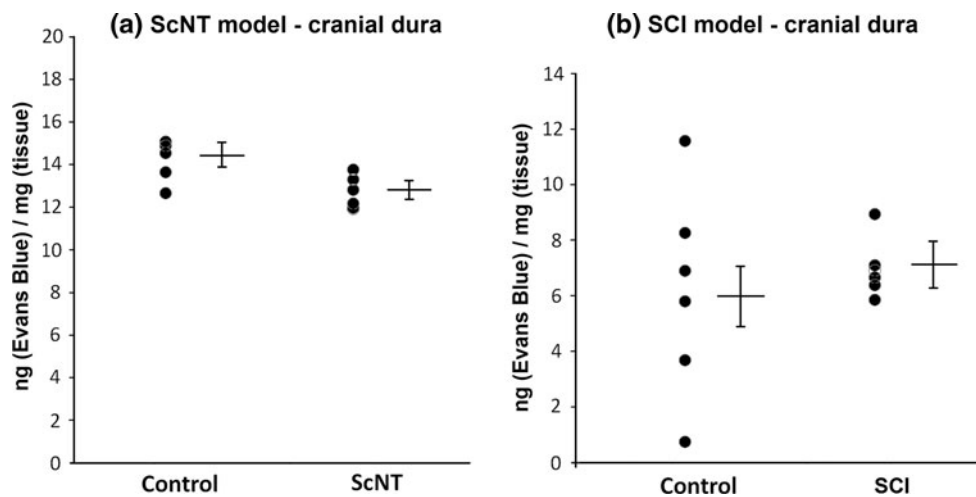
To examine possible existence of DNI in lumbar dura, we assessed the neurogenic inflammation of lumbar dura in the ScNT and SCI models. Plasma protein extravasation was not significantly altered in lumbar dura (Fig. 3a, b) in both ScNT and SCI models.

Dural neurogenic inflammation in IoNC model is accompanied by proinflammatory cell tissue infiltration

Apart from the plasma protein extravasation, we examined if the dural neurogenic inflammation might be accompanied by cellular inflammatory response. Hematoxylin–Eosin staining of cranial dural tissue in IoNC animals showed an increased number of cells dispersed throughout the dural tissue. Inflammatory cells were also visible in the proximity of dural vessels (Fig. 4a). When quantified automatically, this resulted in an elevated count of HE-positive cell nuclei (Fig. 4b).

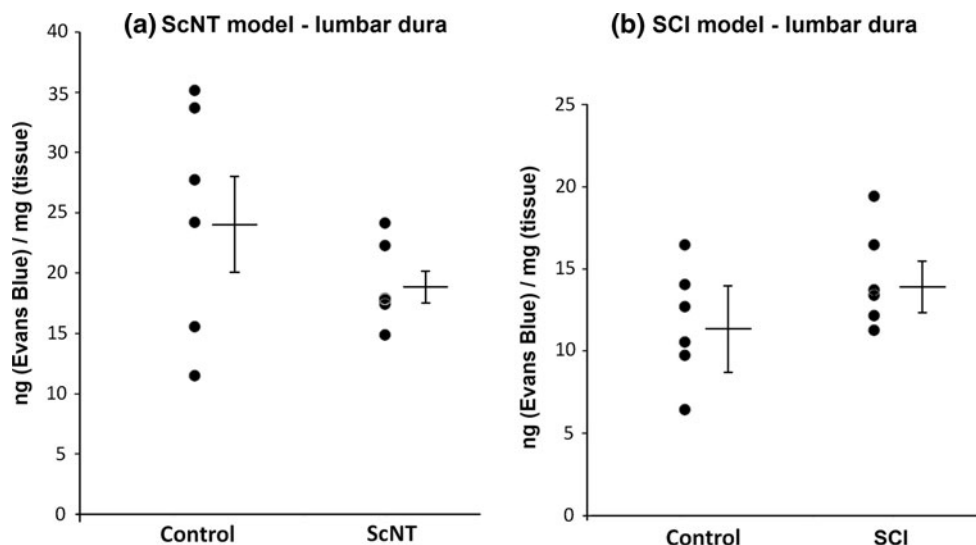
We employed Giemsa staining to further characterize the proinflammatory cell types present in dura mater of IoNC-operated animals. Grouped mononuclear leukocytes (lymphocytes), “early staged” mast cells, plasma cell, and monocytes were visible in IoNC animals (Fig. 5a). These categories of inflammatory cell types were not observed in control animals (Fig. 5b).

In line with the lack of occurrence of plasma protein extravasation after sciatic nerve injuries (Fig. 3a, b), we observed no changes in proinflammatory cell count of lumbar dural tissue in SCI-operated animals (Fig. 4a, b, right panels).



**Fig. 2** Protein extravasation of cranial dura tissue is not present in neuropathic pain originating from peripheral region. Dural extravasation was tested 14 days following partial transection of the sciatic nerve (**a**, ScNT) and sciatic nerve constriction (**b**, SCI). Graph represents scatter plot of data. Each dot represents the amount (ng/mg

tissue) of Evans blue extracted from dura of single animal. Control sham-operated animals, ScNT partial transection of sciatic nerve animals, SCI sciatic nerve constriction injury animals. Cross represents mean  $\pm$  SEM,  $P < 0.05$  compared to control (two-tailed  $t$  test)



**Fig. 3** Protein extravasation of lumbar dura tissue is not present in neuropathic pain originating from peripheral region. Dural extravasation was tested 14 days following a partial transection of sciatic nerve (**a**, ScNT) and sciatic nerve constriction (**b**, SCI). Graph represents scatter plot of data. Each dot represents the amount (ng/mg

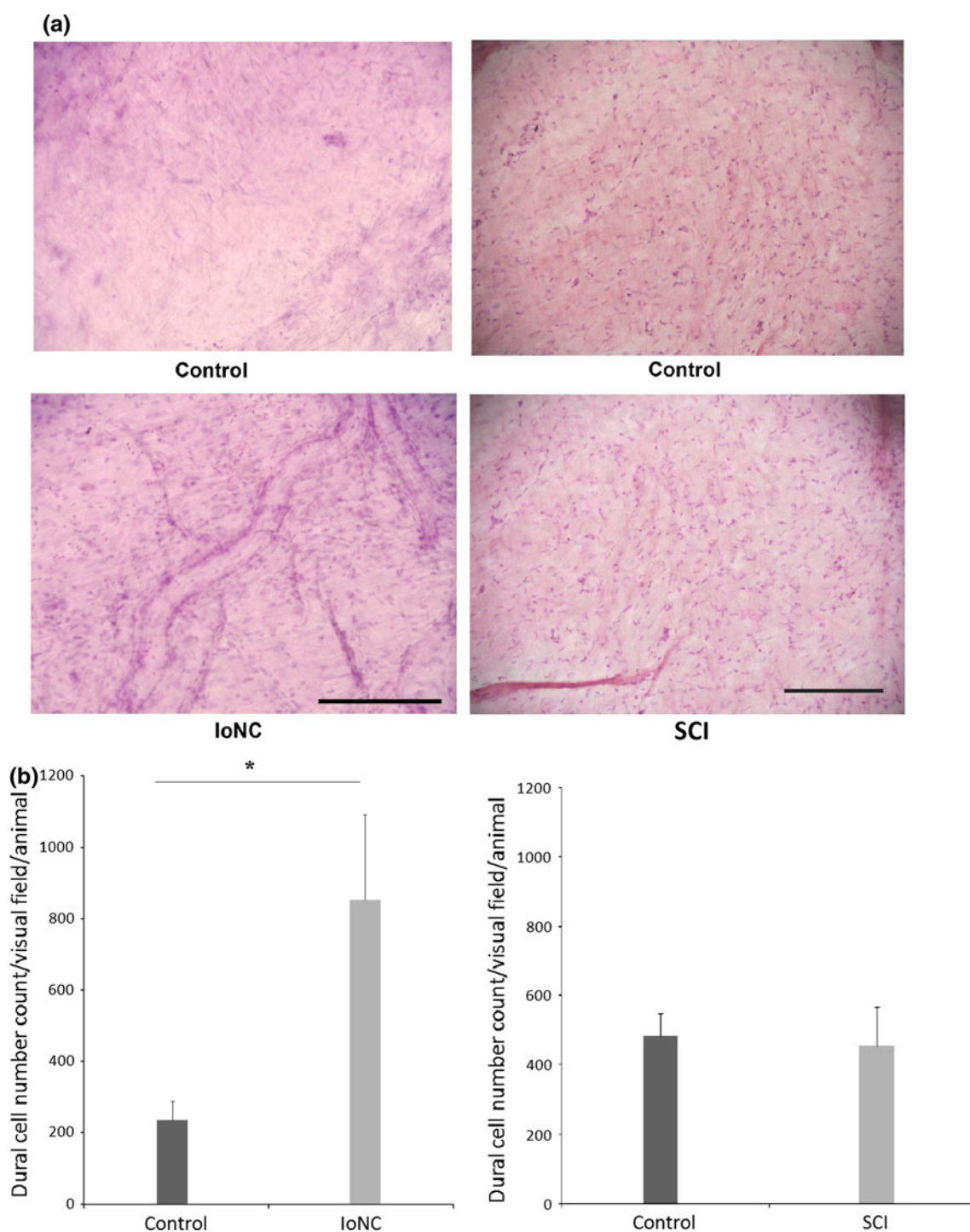
tissue) of Evans blue extracted from dura of single animal. Control sham-operated animals, ScNT partial transection of sciatic nerve animals, SCI sciatic nerve constriction injury animals. Cross represents mean  $\pm$  SEM.  $n = 6$ ,  $P < 0.05$  compared to control (two-tailed  $t$  test)

## Discussion

Pain-evoked dural neurogenic inflammation is specific to cranial region

The connection between DNI and craniofacial pain was, up to now, studied only in the context of migraine pain. Moreover, some authors consider DNI to be “the origin of pain” in migraine (Williamson and Hargreaves 2001;

Buzzi and Moskowitz 2005). The main event leading to DNI is activation of the trigeminal system at the level of trigeminal ganglion and/or secondary trigeminal spinal nuclei. DNI was experimentally studied using the model of electrical stimulation of the trigeminal ganglion, resulting in plasma protein leakage in dura mater (Markowitz et al. 1987). As a result, different drugs which target DNI have been preclinically tested (Saito et al. 1988; Buzzi et al. 1989; Buzzi and Moskowitz 1991) and some of them are



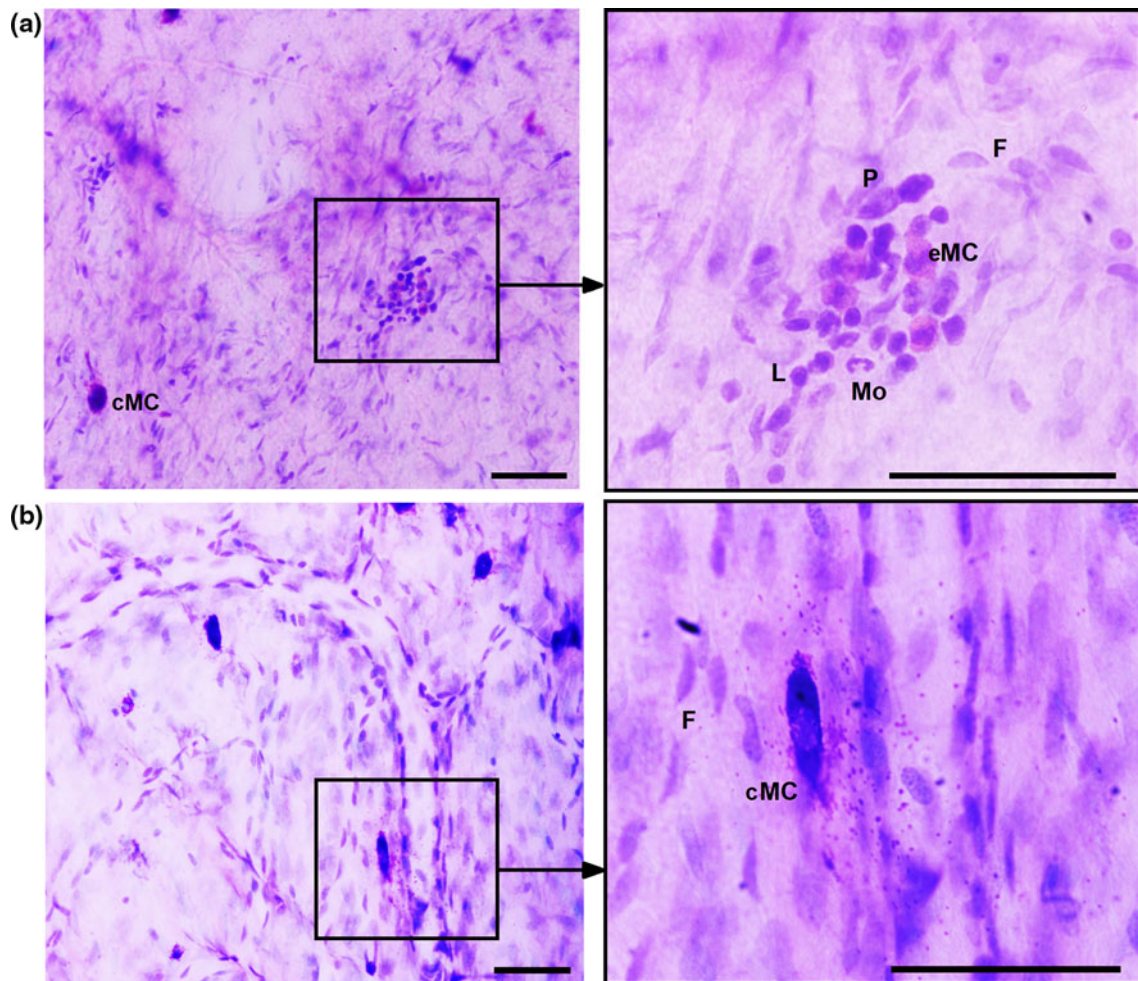
**Fig. 4** Elevated count of proinflammatory cell infiltration of dura mater is present only in the IoNC-induced trigeminal neuropathy animals in contrast to SCI-induced peripheral neuropathy animals. *Control* sham-operated animals, *IoNC* infraorbital nerve constriction injury animals, *SCI* sciatic nerve constriction injury animals. Histological examination of cranial (IoNC) and lumbar (SCI) dural tissue

performed using hematoxylin–eosin (HE) staining. *Scale bar* represents 100  $\mu\text{m}$ . Mean number of HE-positive cell nuclei in one visual field per animal. Mean value for each animal was calculated from four non-overlapping visual fields. Mean  $\pm$  SEM;  $n = 3\text{--}4$  (animals/group);  $*P < 0.01$  (two-tailed  $t$  test)

used in the treatment of migraine (Goldstein et al. 2001; Hargreaves et al. 2009). We previously reported that the extracranial pain in the trigeminal region evoked by IoNC

or orofacial formalin test leads to DNI (Filipović et al. 2012). As an underlying mechanism of pain-induced DNI, we suggested a possible cross-activation between sensory





**Fig. 5** Cell types found in cranial dural tissue of IoNC-induced trigeminal neuropathy animals indicate a sterile inflammation. Histological examination of cranial (IoNC) dural tissue performed using Giemsa staining. Scale bar represents 50  $\mu$ m. **a** IoNC

infraorbital nerve constriction injury animals, **b** Control sham-operated animals. *eMC* early stage mast cell, *cMC* constitutional tissue mast cell, *Mo* monocyte, *P* plasma cell, *L* lymphocyte, *F* fibrocyte

facial and dural afferents, either at the level of trigeminal ganglion, or within the spinal trigeminal nucleus in the brainstem, or both. Previous studies demonstrated cross-activation of neurons on the levels of trigeminal ganglion and spinal trigeminal nucleus (Burstein et al. 1998; Thalakoti et al. 2007).

In the present study, we have used different peripheral nerve injuries to examine whether the pain-evoked DNI is specific primarily to trigeminal nerve, or DNI a general phenomenon associated with nerve injury in different body regions. Our results clearly demonstrate that DNI is linked to the cranial region only. The highest level of DNI was evoked after the trigeminal nerve injury (Fig. 1a) which is consistent with innervation of supratentorial dura by the trigeminal nerve (Larrier and Lee 2003). Much lower but significant DNI of supratentorial dura was evoked by the occipital nerve injury (GoNC) (Fig. 1b). This phenomenon might be associated with the proximity of peripheral

(cutaneous) innervation areas of occipital vs. trigeminal nerve in rat, or a convergence and cross-excitation of trigeminal and occipital neurons at the level of secondary neurons in C2 trigeminocervical complex (Bartsch and Goadsby 2003; Le Doaré et al. 2006). Nerve injury in more distant body regions (ScNT and SCI) did not evoke any measurable neurogenic inflammation of supratentorial cranial dura (Fig. 2a, b), demonstrating that the cranial DNI cannot be evoked by neuropathic pain in a distant part of the body. In contrast to the cranial region (IoNC and GoNC), we did not observe the DNI in lumbar dura mater measured either as plasma protein extravasation (Fig. 3a, b) or histologically as proinflammatory cell infiltration (Fig. 4a, b) in the peripheral region (ScNT and SCI).

Rat spinal dura mater has a lower density of afferent CGRP fibers and mast cell population (Kumar et al. 1996). Therefore, it is possible that spinal dura anatomically and physiologically has fewer prerequisites to develop DNI and

neurogenic inflammation when compared to cranial dura (Fricke et al. 2001). Recently, Xanthos et al. (2011) observed an increase in lumbar dura mast cell degranulation density in peripheral inflammatory pain models (capsaicin and carrageenan), but no other evidence of DNI. In contrast to rat, an immunohistochemical study of lumbar dura of rabbits showed extensive distribution of SP, CGRP nerve fibers, and possible role in low back pain was suggested (Kallakuri et al. 1998). Sensory innervation of lower lumbar dura in rat originates from upper lumbar sensory ganglia (Konnai et al. 2000). Laminectomy increased the density of SP and CGRP containing nerve fibers. Association with low back pain after lumbar surgery in patients was suggested (Saxler et al. 2008).

Dural neurogenic inflammation evoked by trigeminal nerve injury consists of dural plasma protein leakage and sterile proinflammatory cell infiltration

Neurogenic inflammation is a phenomenon consisting of blood vessel dilation, plasma protein extravasation and mast cell degranulation (Williamson and Hargreaves 2001). Mast cells are normally expressed in dural tissue in close proximity to blood vessels and nerve fibers (Michaloudi et al. 2007). These “constitutional tissue mast cells” are visible in both IoNC and sham-operated animals (Fig. 5a, b). Mast cells derive from blood marrow and enter dural tissue as immature cells which, under specific micro-environmental conditions, differentiate to “constitutional tissue mast cell” (Rozniecki et al. 1999). It was shown that they can be activated by trigeminal electrical stimulation and stress (Buzzi et al. 1992, 1995). In line with these findings it is believed that mast cells are involved in dural neurogenic inflammation and migraine (Buzzi et al. 1995; Rozniecki et al. 1999; Theoharides et al. 2005).

Here we can report that, aside from dural plasma protein extravasation, there is a cellular inflammatory response following the IoNC-induced trigeminal neuropathy (Fig. 4a, b). By measuring total count of HE-positive cell nuclei, we have found an increased number of cell bodies in cranial dura from IoNC-operated neuropathic animals. Contrary to that, we did not observe plasma extravasation or an increase in the total count of HE-positive cell nuclei in lumbar dura after SCI.

We have further characterized the types of inflammatory cells using Giemsa nuclear staining in the IoNC model. We have found several groups of inflammatory cells dispersed throughout the cranial dura next to “constitutional tissue dural mast cells”, in the cranial tissue of neuropathic animals. They were identified as mononuclear leukocytes (lymphocytes), “early staged mast cells”, plasma cells, and monocytes (Fig. 5a). Polymorphonuclear leukocytes (neutrophils) were not observed, indicating that the dural tissue

inflammation evoked by nerve injury was sterile, i.e. the inflammatory response was not evoked by infection. Since the inflammatory response was sterile, we can assume that it may have a role in the pathophysiology of the IoNC-induced trigeminal neuropathic pain, and possibly trigeminal neuropathic pain in general.

Dural mast cell and platelet activation was observed in models of DNI (mainly electrical stimulation of trigeminal ganglion) investigated by other authors (Buzzi et al. 1992, 1995), but other cellular inflammatory response was not reported. It is possible that the length of antidromic electrical stimulation was too short in electrical stimulation model (5 min) in comparison to the IoNC-evoked long-lasting nociceptive stimulation. Activation of mast cells and platelets occurs in the early stages of inflammation and leads to the release of proinflammatory mediators, such as histamine, serotonin, prostaglandin I<sub>2</sub>, etc. (Theoharides et al. 2005; Levy et al. 2006; Levy 2009). The release of proinflammatory mediators in dura in the later stage of inflammation could evoke the observed inflammatory response.

## Conclusion

Peripheral nerve injury-evoked DNI and sterile cellular inflammatory response are regionally specific to the cranial area, suggesting that DNI is important in the pathophysiology of different neuropathic disorders in trigeminal and possibly adjacent (occipital) cranial regions.

**Acknowledgments** We are grateful to Professor Marija Dominis for contribution in characterization of inflammatory cells. We are also grateful to Božica Hržan for her excellent technical assistance and Ingeborg Remich for the manuscript language revision.

**Conflict of interest** The author(s) declare that they have no competing interests.

## References

- Bach-Rojecky L, Relja M, Lacković Z (2005) Botulinum toxin type A in experimental neuropathic pain. *J Neural Transm* 112:215–219
- Bartsch T, Goadsby PJ (2003) Increased responses in trigeminocervical nociceptive neurons to cervical input after stimulation of the dura mater. *Brain* 126:1801–1813
- Bennett GJ, Xie YK (1988) A peripheral mononeuropathy in rat that produces disorders like those seen in men. *Pain* 33:87–107
- Burstein R, Yamamura H, Malick A, Strassman AM (1998) Chemical stimulation of intracranial dura induces enhanced responses to facial stimulation in brainstem trigeminal neurons. *J Neurophysiol* 79:964–982
- Buzzi MG, Moskowitz MA (1991) Evidence for 5-HT<sub>1B/1D</sub> receptors mediating the antimigraine effect of sumatriptan and dihydroergotamine. *Cephalalgia* 11:165–168
- Buzzi MG, Moskowitz MA (2005) The pathophysiology of migraine: year 2005. *J Headache Pain* 6:105–111

- Buzzi MG, Sakas DE, Moskowitz MA (1989) Indomethacin and acetylsalicylic acid block neurogenic plasma protein extravasation in rat dura mater. *Eur J Pharmacol* 165:251–258
- Buzzi MG, Dimitriadou V, Theoharides TC, Moskowitz MA (1992) 5-Hydroxytryptamine receptor agonists for the abortive treatment of vascular headaches block mast cell, endothelial and platelet activation within the rat dura mater after trigeminal stimulation. *Brain Res* 583:137–149
- Buzzi MG, Bonamini M, Moskowitz MA (1995) Neurogenic model of migraine. *Cephalalgia* 15:277–280
- Filipović B, Bach-Rojecky L, Lacković Z (2010) Lasting reduction of postsurgical hyperalgesia after single injection of botulinum toxin type A in rat. *Fundam Clin Pharmacol* 24:43–45
- Filipović B, Matak I, Bach-Rojecky L, Lacković Z (2012) Central action of peripherally applied botulinum toxin type A on pain and dural protein extravasation in rat model of trigeminal neuropathy. *PLoS ONE* 7:e29803. doi:10.1371/journal.pone.0029803
- Fricke B, Andres KH, Von Düring M (2001) Nerve fibers innervating the cranial and spinal meninges: morphology of nerve fiber terminals and their structural integration. *Microsc Res Tech* 53:96–105
- Goldstein DJ, Offen WW, Klein EG, Phebus LA, Hipskind P, Johnson KW, Ryan RE Jr (2001) Lanepitant, an NK-1 antagonist, in migraine prevention. *Cephalalgia* 21:102–106
- Gregg JM (1973) A surgical approach to the ophthalmic-maxillary nerve trunks in the rat. *J Dent Res* 52:392
- Groneberg DA, Quarcio D, Frossard N, Fischer A (2004) Neurogenic mechanisms in bronchial inflammatory diseases. *Allergy* 59:1139–1152
- Hargreaves RJ, Lines CR, Rapoport AM, Ho TW, Sheffell FD (2009) Ten years of rizatriptan: from development to clinical science and future directions. *Headache* 1:3–20. doi:10.1111/j.1526-4610.2008.01335.x
- Kallakuri S, Cavanaugh JM, Blagoev DC (1998) An immunohistochemical study of innervation of lumbar spinal dura and longitudinal ligaments. *Spine (Phila Pa 1976)* 23:403–411
- Kayser V, Aubel B, Hamon M, Bourgoin S (2002) The antimigraine 5-HT<sub>1B/1D</sub> receptor agonists, sumatriptan, zolmitriptan and dihydroergotamine, attenuate pain-related behaviour in a rat model of trigeminal neuropathic pain. *British J Pharmacol* 137:1287–1297
- Knotkova H, Pappagallo M (2007) Imaging intracranial plasma extravasation in a migraine patient: a case report. *Pain Med* 8:383–387
- Konnai Y, Honda T, Sekiguchi Y, Kikuchi S, Sugira T (2000) Sensory innervation of the lumbar dura mater passing through the sympathetic trunk in rats. *Spine (Phila Pa 1976)* 25:776–782
- Kumar R, Berger RJ, Dunsker SB, Keller JT (1996) Innervation of the spinal dura. Myth or reality? *Spine (Phila Pa 1976)* 21:18–26
- Larrier D, Lee A (2003) Anatomy of headache and facial pain. *Otolaryngol Clin North Am* 36:1041–1053
- Le Doaré K, Akerman S, Holland PR, Lasalandra MP, Bergerot A, Classey JD, Knight YE, Goadsby PJ (2006) Occipital afferent activation of second order neurons in the trigeminocervical complex in rat. *Neurosci Lett* 403:73–77
- Levy D (2009) Migraine pain, meningeal inflammation, and mast cells. *Curr Pain Headache Rep* 13:237–240
- Levy D, Burstein R, Strassman AM (2006) Mast cell involvement in the pathophysiology of migraine headache: a hypothesis. *Headache* 1:13–18
- Lindenlaub T, Sommer C (2000) Partial sciatic nerve transection as a model of neuropathic pain: a qualitative and quantitative neuropathological study. *Pain* 15:97–106
- Marianna K, Cecilia HS, Brian PT, Leslie CG, Robert PS (2008) Neuropeptides activate human mast cell degranulation and chemokine production. *Immunology* 123:398–410
- Markowitz S, Saito K, Moskowitz MA (1987) Neurogenically mediated leakage of plasma protein occurs from blood vessels in dura mater but not brain. *J Neurosci* 7:4129–4136
- Michaloudi H, Batzios C, Chiotelli M, Papadopoulos GC (2007) Development changes of mast cell population in the cerebral meninges of the rat. *J Anat* 211:556–566
- Moskowitz MA (1990) Basic mechanisms in vascular headache. *Neurol Clin* 8:801–815
- Nelson DL, Phebus LA, Johnson KW, Waincott DB, Cohen ML, Calligaro DO, Xu YC (2010) Preclinical pharmacological profile of the selective 5-HT<sub>1F</sub> receptor lasmiditan. *Cephalalgia* 30:1159–1169
- Peroutka SJ (2005) Neurogenic inflammation and migraine: implications for the therapeutics. *Mol Interv* 5:304–311
- Randall LO, Selitto JJ (1957) A method for measurement of analgesic activity of inflamed tissue. *Arch Int Pharmacodyn* 61:409–419
- Raychaudhuri SP, Raychaudhuri SK (2004) Role of NGF and neurogenic inflammation in the pathogenesis of psoriasis. *Prog Brain Res* 46:433–437
- Rozniecki JJ, Dimitriadou V, Lambracht-Hall M, Pang X, Theoharides TC (1999) Morphological and functional demonstration of rat dura mater mast cell-neuron interactions in vitro and in vivo. *Brain Res* 849:1–15
- Saito K, Markowitz S, Moskowitz MA (1988) Ergot alkaloids block neurogenic extravasation in dura mater: proposed action in vascular headaches. *Ann Neurol* 24:732–737
- Saxler G, Brankamp J, von Knoch M, Loer F, Hilken G, Hanesch U (2008) The density of nociceptive SP- and CGRP-immunopositive nerve fibers in the dura mater lumbalis of rats is enhanced after laminectomy, even after application of autologous fat grafts. *Eur Spine J* 17:1362–1372. doi:10.1007/s00586-008-0741-7
- Thalakoti S, Patil VV, Damodaram S, Vause CV, Langford LE, Freeman SE, Durham PL (2007) Neuron–glia signaling in trigeminal ganglion: implications for migraine pathology. *Headache* 47:1008–1023
- Theoharides TC, Donelan J, Kandere-Grzybowska K, Konstantinidou A (2005) The role of mast cells in migraine pathophysiology. *Brain Res Brain Res Rev* 49:65–76
- Vos BP, Strassman AM, Maciewicz RJ (1994) Behavioral evidence of trigeminal neuropathic pain following chronic constriction injury to the rat's infraorbital nerve. *J Neurosci* 14:2708–2723
- Williamson DJ, Hargreaves RJ (2001) Neurogenic inflammation in the context of migraine. *Microsc Res Tech* 53:167–178
- Xanthos DN, Gaderer S, Drdla R, Nuro E, Abramova A, Ellmeier W, Sandkühler J (2011) Central nervous system mast cells in peripheral inflammatory nociception. *Mol Pain* 7:42. doi:10.1186/1744-8069-7-42

- V. Lacković Z, Filipović B, Matak I, Helyes Z. Activity of botulinum toxin type A in cranial dura: implications for treatment of migraine and other headaches. *Br J Pharmacol.* 2016; 173:279-91.



## RESEARCH PAPER

# Activity of botulinum toxin type A in cranial dura: implications for treatment of migraine and other headaches

Zdravko Lacković<sup>1</sup>, Boris Filipović<sup>1,2</sup>, Ivica Matak<sup>1</sup> and Zsuzsanna Helyes<sup>3,4</sup>

<sup>1</sup>Laboratory of Molecular Neuropharmacology, Department of Pharmacology, University of Zagreb School of Medicine, Šalata 11, 10000 Zagreb, Croatia, <sup>2</sup>Department of Otorhinolaryngology-Head and Neck Surgery, University Hospital Sveti Duh, Sveti Duh 64, 10000 Zagreb, Croatia,

<sup>3</sup>Department of Pharmacology and Pharmacotherapy, University of Pécs School of Medicine, Szigeti u. 12, H-7624 Pécs, Hungary, and <sup>4</sup>János Szentágothai Research Center, 3MTA-PTE NAP B Pain Research Group, University of Pécs School of Medicine, Ifjúság útja 20, H-7624 Pécs, Hungary

### Correspondence

Zdravko Lacković, Laboratory of Molecular Neuropharmacology, Department of Pharmacology, University of Zagreb School of Medicine, Šalata 11, 10000 Zagreb, Croatia.

E-mail: lac@mef.hr;

lackoviczdravko@gmail.com

### Received

14 May 2015

### Revised

30 July 2015

### Accepted

1 October 2015

## BACKGROUND AND PURPOSE

Although botulinum toxin type A (BoNT/A) is approved for chronic migraine treatment, its mechanism of action is still unknown. Dural neurogenic inflammation (DNI) commonly used to investigate migraine pathophysiology can be evoked by trigeminal pain. Here, we investigated the reactivity of cranial dura to trigeminal pain and the mechanism of BoNT/A action on DNI.

## EXPERIMENTAL APPROACH

Because temporomandibular disorders are highly comorbid with migraine, we employed a rat model of inflammation induced by complete Freund's adjuvant, followed by treatment with BoNT/A injections or sumatriptan p.o. DNI was assessed by Evans blue-plasma protein extravasation, cell histology and RIA for CGRP. BoNT/A enzymatic activity in dura was assessed by immunohistochemistry for cleaved synaptosomal-associated protein 25 (SNAP-25).

## KEY RESULTS

BoNT/A and sumatriptan reduced the mechanical allodynia and DNI, evoked by complete Freund's adjuvant. BoNT/A prevented inflammatory cell infiltration and inhibited the increase of CGRP levels in dura. After peripheral application, BoNT/A-cleaved SNAP-25 colocalized with CGRP in intracranial dural nerve endings. Injection of the axonal transport blocker colchicine into the trigeminal ganglion prevented the formation of cleaved SNAP-25 in dura.

## CONCLUSIONS AND IMPLICATIONS

Pericranially injected BoNT/A was taken up by local sensory nerve endings, axonally transported to the trigeminal ganglion and transcytosed to dural afferents. Colocalization of cleaved SNAP-25 and the migraine mediator CGRP in dura suggests that BoNT/A may prevent DNI by suppressing transmission by CGRP. This might explain the effects of BoNT/A in temporomandibular joint inflammation and in migraine and some other headaches.

## Abbreviations

BoNT/A, botulinum toxin type A; CFA, complete Freund's adjuvant; DNI, dural neurogenic inflammation; i.a., intra-articular; i.g., intraganglionic; SNAP-25, synaptosomal-associated protein 25; TMJ, temporomandibular joint

## Tables of Links

TARGETS
<b>GPCRs</b>
CGRP receptor

LIGANDS
CGRP
Colchicine
Sumatriptan

These Tables list key protein targets and ligands in this article which are hyperlinked to corresponding entries in <http://www.guidetopharmacology.org>, the common portal for data from the IUPHAR/BPS Guide to PHARMACOLOGY (Pawson *et al.*, 2014) and are permanently archived in the Concise Guide to PHARMACOLOGY 2013/14 (Alexander *et al.*, 2013).

## Introduction

Botulinum toxin type A (BoNT/A) blocks the vesicular release of neurotransmitters by proteolytic cleavage of a synaptic protein, synaptosomal-associated protein 25 (SNAP-25). SNAP-25 is a part of the synaptic protein complex which is involved in Ca<sup>2+</sup>-dependent exocytosis (Kalandakanond and Coffield, 2001; Blasi *et al.*, 1993). This effect of BoNT/A at peripheral nerve endings is the basis of its therapeutic use in a range of neuromuscular (blepharospasm, focal dystonia and spasticity) and autonomic disorders (hyperhidrosis and bladder dysfunction) associated with neuronal over-activity (Dressler, 2013). Based on large clinical studies, pericranially injected BoNT/A has also been approved for the treatment of chronic migraine (Diener *et al.*, 2010). It is widely accepted that migraine headaches involve activation of trigeminal afferents innervating the meningeal blood vessels and dural neurogenic inflammation (DNI) (Moskowitz, 1990; Geppetti *et al.*, 2012; Ramachandran and Yaksh, 2014). We have recently found that the activation of dural afferents, measured as plasma protein extravasation, can be evoked by extracranial pain in the trigeminal region (orofacial formalin-evoked pain and infraorbital nerve constriction-induced trigeminal neuropathy) (Filipović *et al.*, 2012, 2014). The plasma protein extravasation induced by different types of pain was prevented by peripherally injected BoNT/A. The effect of BoNT/A in the cranial dura was associated with axonal transport of the toxin, because its effects were prevented by injection of colchicine directly into the trigeminal ganglion (Filipović *et al.*, 2012).

In the present study, we investigated the effects of BoNT/A in a model of trigeminal pain induced by complete Freund's adjuvant (CFA) injection into the temporomandibular joint (TMJ), a common model of temporomandibular disorders (Harper *et al.*, 2001; Villa *et al.*, 2010). Temporomandibular disorders involve dysfunction of both the TMJ and masticatory muscles, leading to chronic pain (De Rossi *et al.*, 2014). BoNT/A injections into masticatory muscles have been reported to reduce the tenderness and pain in patients suffering from temporomandibular disorders (Sunil Dutt *et al.*, 2015). Severe forms of temporomandibular disorders are highly comorbid with primary headaches – up to 86% of patients suffer from migraine or other primary headaches (Bevilaqua Grossi *et al.*, 2009; Franco *et al.*, 2010). The underlying mechanism of the comorbidity is proposed to be related to extensive innervation of cranial dura by

mandibular branch of trigeminal nerve (Schueler *et al.*, 2013). So far, inflammation of the TMJ has been used pre-clinically to study the trigeminal sensitization associated with migraine (Villa *et al.*, 2010; Thalakoti *et al.*, 2007). CFA injection into the TMJ induces pain and inflammation leading to peripheral and central sensitization of trigeminal system (Villa *et al.*, 2010). Similarly, by stimulating the TMJ with capsaicin, Thalakoti *et al.* (2007) found widespread peripheral sensitization in trigeminal ganglion cells. Accordingly, we hypothesized that TMJ pain might provide a suitable model to study trigeminal activation leading to DNI, as well as the mechanism of BoNT/A action in the trigeminovascular system, assumed to be involved in migraine and other headaches. In the TMJ inflammation model, apart from neurogenic plasma protein extravasation, we studied the effect of BoNT/A on CGRP, a neuropeptide considered the main mediator of trigeminal sensitization in migraine (Bigal *et al.*, 2013).

Here, we have found that CFA-evoked TMJ inflammation was accompanied by inflammatory changes in the cranial dura (plasma protein extravasation and inflammatory cell infiltration) and increased levels of CGRP. Additionally, following peripheral toxin injection, cleaved SNAP-25, the product of BoNT/A enzymic activity, was colocalized with CGRP-expressing dural afferents. BoNT/A prevented the CFA-evoked dural inflammation and CGRP peptide increase in cranial dura.

## Methods

### *Animal welfare and ethical statement*

All animal care and experimental procedures were in accordance with the 2010/63/EU Directive on the protection of animals used for scientific purposes and the recommendations of International Association for the Study of Pain (Zimmerman, 1983) and were approved by the Ethical Committee of University of Zagreb School of Medicine (permit no. 07-76/2005-43). The experimental procedures used in the work described in this article were as humane as possible. All animal studies are described in compliance with the ARRIVE guidelines for reporting experiments involving animals (Kilkenny *et al.*, 2010).

One hundred and five male Wistar rats (average weight 300–350 g; 3–3.5 months old; University of Zagreb School

of Medicine, Croatia) were used in these experiments. Rats were kept under a constant 12 h/12 h light/dark cycle with free access to food and water. The animals were randomly allocated to different experimental treatments. The experimenter conducting the behavioural testing was unaware of the treatments given to the animals.

### *CFA-induced inflammatory pain in the TMJ*

Animals were anesthetized with chloral hydrate (300 mg kg<sup>-1</sup> i.p.). Injection into the TMJ was performed by inserting a 27 gauge needle medially through the skin below the inferior border of the zygomatic arch and superior to the mandibular condyl until it entered the joint capsule (Villa *et al.*, 2010). Inflammation of the TMJ was elicited by injection of 50 µL of CFA into the left joint capsule. Control rats were injected intra-articularly (i.a.) with saline (0.9% NaCl). Methylene blue was injected into a few animals, and the site of injection was examined in a preliminary experiment to confirm successful targeting of the TMJ.

### *Behavioural testing*

The next day (24 h) following CFA injection, behavioural assessment of mechanical allodynia was performed using the von Frey monofilaments (Stoelting Co., Wood Dale, IL, USA) as previously described in detail (Filipović *et al.*, 2012). Filaments produced a calibrated bending force of 0.16, 0.4, 0.6, 1, 2, 4, 6, 8 and 10. The rats were placed in a transparent plastic cage for 10 min to accommodate to the experimental environment until they assumed their normal sniffing/no locomotion position. For each session, a series of von Frey filaments were applied on the tested side of the face in ascending order, starting at 0.16 g, with three attempts until a defined behavioural response was elicited. Each time, the measurement started on the side contralateral to the CFA injection. A positive reaction was interpreted as defensive forepaw movement and/or escape/attack reaction after stimulation of whisker pad area with filaments. In total, the measurements were performed in three sessions in 10 min intervals. If no response was observed, we assigned 10 g as the withdrawal threshold, because the force exerted by thicker filaments (>10 g) was large enough to push the head of animals.

### *Pharmacological treatments*

#### *BoNT/A injections*

The rats were anesthetized with chloral hydrate (300 mg kg<sup>-1</sup> i.p.) (first anaesthetic) for different BoNT/A treatments, 3 days prior to the CFA (50 µL) injection in the left TMJ (performed under the second anaesthetic). For intra-articular injections, BoNT/A in a dose of 5 U kg<sup>-1</sup> and 20 µL volume was injected into the left TMJ capsule of anesthetized rats, as described earlier. For intraganglionic injections, rats were injected with BoNT/A in a dose of 2 U kg<sup>-1</sup> (2 µL volume) into the left trigeminal ganglion of anesthetized rats, as described previously (Matak *et al.*, 2011; Filipović *et al.*, 2012). In brief, a Hamilton syringe needle (Hamilton Microliter #701; Hamilton, Bonaduz, Switzerland) was inserted through the skin into the infraorbital foramen and advanced through the infraorbital canal and foramen rotundum into the trigeminal ganglion.

The multiple facial injections we made as follows: anesthetized rats were injected with BoNT/A at four sites: (i) bilaterally into the rat forehead above the orbital arch and (ii) bilaterally into the whisker pad. Five microlitre injections (5 µL per site) were administered using a Hamilton syringe. A total dose of 5 U kg<sup>-1</sup> was employed and divided in four equal doses (1.25 U kg<sup>-1</sup> per site).

#### *Sumatriptan*

A group of animals were given sumatriptan, p.o., 24 h after CFA injection into the TMJ. The p.o. dose of 175 µg kg<sup>-1</sup> was calculated on the basis of previously used i.v. dose (50 µg kg<sup>-1</sup>) corrected for p.o. bioavailability (25–30%) in rats (Dallas *et al.*, 1989; Schuh-Hofer *et al.*, 2003). Mechanical allodynia was measured, as described above, 2 h after the administration of sumatriptan.

#### *Dural neurogenic plasma protein extravasation*

Plasma protein extravasation, as an indicator of neurogenic inflammation, was measured 24 h after CFA injection. This was measured by injecting Evans blue dye which complexes to plasma proteins. Anaesthetized animals were perfused transcatheterially with 500 mL of saline 30 min after injection of 1 mL Evans blue solution (40 mg kg<sup>-1</sup>) into the tail vein. Supratentorial dura was dissected into the left (ipsilateral to CFA treatment) and right sides (contralateral to CFA) and weighed. Evans blue was extracted in formamide, and the absorbance of Evans blue was measured spectrophotometrically. The amounts of extravasated Evans blue were calculated using the standard concentration curve, as previously described in detail (Filipović *et al.*, 2012).

#### *RIA for CGRP*

For the measurement of CGRP immunoreactivity with RIA, animals were injected with BoNT/A into the TMJ, as described above. One day after the induction of TMJ inflammation, animals were deeply anesthetized with chloral hydrate (300 mg kg<sup>-1</sup> i.p.). Approximately 100 µL of CSF was withdrawn from cisterna magna using 27½ gauge syringe needle inserted percutaneously between the occipital bone and atlas. Only transparent CSF samples were taken for further analysis. The sample was rapidly frozen by immersing the sealed Eppendorf tube containing the CSF in liquid nitrogen and kept at –80°C. Immediately following the CSF sampling, anesthetized animals were killed by decapitation. Supratentorial dura, brainstem and trigeminal ganglion were quickly dissected, frozen in liquid nitrogen and kept at –80°C until further use. The frozen brainstem was placed in cryostat-cooled environment (–25°C) for dissection of ipsilateral trigeminal nucleus caudalis without thawing. The nucleus was excised manually using a pre-cooled microtome blade, scalpel and forceps. Dissected tissue was further kept at –80°C until homogenization.

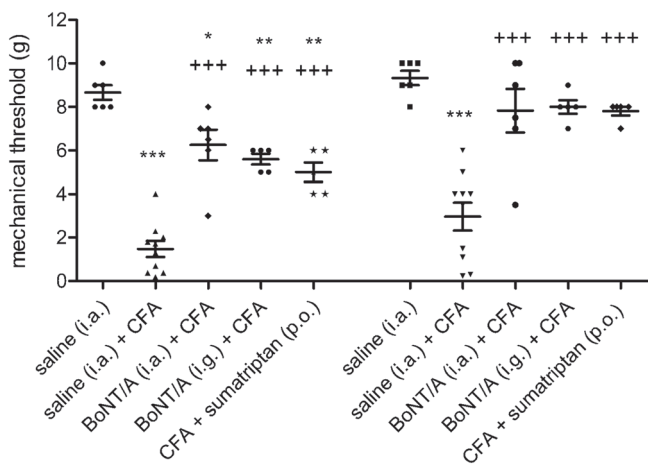
Tissue samples were weighed and immediately homogenized with 1 mL distilled water and 20 µL of aprotinin solution (Trasyolol, Bayer, Germany). Trigeminal ganglia and caudal nucleus samples were manually homogenized in a glass homogeniser, while dura was homogenized using a Polytron mechanical homogenizer. The samples were then centrifuged for 10 min at 8944 g, and the procedure was repeated with the

resulting supernatant. Final supernatants were kept at  $-30^{\circ}\text{C}$  until further analysis. CSF was directly used as a RIA sample without further preparation.

Radioimmunoassay was performed similarly as previously described (Németh *et al.*, 1998; Pozsgai *et al.*, 2012). In brief, samples or CGRP standards (Sigma) were diluted in buffer for RIA containing 1:120 000 anti-CGRP polyclonal antibody (Sigma) and tracer containing radio-iodinated CGRP standard. Diluted samples were incubated at  $4^{\circ}\text{C}$  for 48 h. Antigen-bound and free CGRP peptides were then separated by adding 100  $\mu\text{L}$  of distilled water with 10% activated charcoal, 2% dextran and 0.2% fat-free milk powder. The samples were vortexed and centrifuged at 2010 g for 20 min. Levels of radioactivity of the pellets containing the free peptide and supernatant containing the antibody-bound peptide were determined with a  $\gamma$  counter. Concentrations of CGRP ( $\text{fmol mg}^{-1}$  or  $\text{fmol mL}^{-1}$ ) in samples were calculated based on a standard concentration curve.

### Histology and immunohistochemistry of the dura mater

In order to assess inflammatory cell infiltration in the dura mater by histology, animals were injected with BoNT/A ( $5 \text{ U kg}^{-1}$ ) and CFA into the TMJ as described above. One day after CFA, the anaesthetized animals were perfused with saline and 250 mL of 4% paraformaldehyde in PBS. Ipsilateral and contralateral supratentorial dura were carefully dissected and placed in paraformaldehyde fixative containing 15% sucrose, followed by 30% sucrose in PBS



**Figure 1**

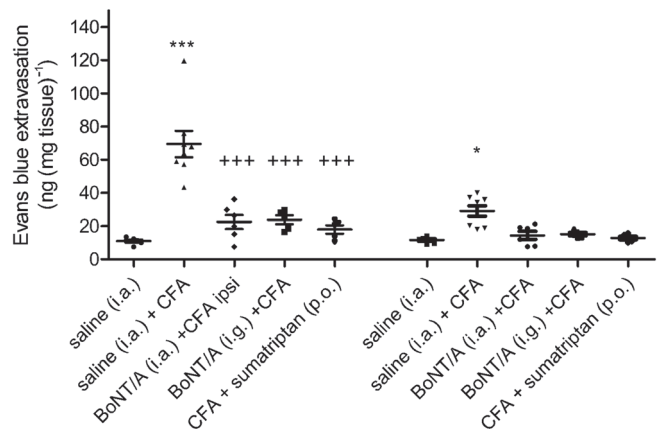
BoNT/A and sumatriptan effects on bilateral allodynia induced by unilateral TMJ inflammation. BoNT/A ( $5 \text{ U kg}^{-1}$ ) was injected into the TMJ ( $5 \text{ U kg}^{-1}$  i.a.) or trigeminal ganglion ( $2 \text{ U kg}^{-1}$  i.g.) 3 days before CFA. Facial allodynia was measured with von Frey filaments 24 h after CFA injection into the TMJ. Sumatriptan ( $175 \text{ mg kg}^{-1}$ ) was administered p.o. 24 h after CFA, and allodynia was measured 2 h after sumatriptan. Scatter plot represents data of individual animals, and horizontal lines and bars indicate mean  $\pm$  SEM.  $n$  (animals per group) = 5–9. \* $P < 0.05$ , \*\* $P < 0.01$ , \*\*\* $P < 0.001$ , significantly different from saline control; +++ $P < 0.001$ , significantly different from saline + CFA; one-way ANOVA followed by Newman–Keuls *post hoc* test.

on the next day. After 48 h, the samples were stored at  $-80^{\circ}\text{C}$  until further use.

Histological study of the cranial dural tissue was performed using standard Giemsa staining. Bright field microphotographs were taken with Olympus BX-51 microscope coupled with DP-70 digital camera (Olympus, Tokyo, Japan) under constant condenser light intensity and camera exposition. The number of Giemsa-stained cell profiles was automatically quantified in four to five non-overlapping visual fields (obtained at  $20\times$  magnification) per single animal, using cellSens Dimension programme (Olympus) as previously described in detail (Filipović *et al.*, 2014). Five animals per group were examined.

To investigate the possible spread of peripherally injected BoNT/A to dural afferents, animals were injected in the TMJ unilaterally with 5 or  $15 \text{ U kg}^{-1}$  BoNT/A, as described above. One group of animals was injected with  $15 \text{ U kg}^{-1}$  BoNT/A into the whisker pad. An additional group of animals was injected unilaterally with a total dose of  $20 \text{ U kg}^{-1}$  BoNT/A ( $7 \text{ U}$  per 350 g rat) divided in four injection sites ( $1.75 \text{ U}/20 \mu\text{L}$  per site) – (i) TMJ, (ii) whisker pad, (iii) medial (forehead) and (iv) lateral (temporal) cranial region. Six days after peripheral injection of BoNT/A, animals were anesthetized and perfused for immunohistochemistry with saline and paraformaldehyde fixative.

Dural samples were stained for cleaved SNAP-25 using the free-floating procedure as previously described (Matak *et al.*, 2014). In brief, dissected dura was washed in PBS, blocked with 10% normal goat serum and incubated overnight at



**Figure 2**

The effect of BoNT/A and sumatriptan on Evans blue/plasma protein extravasation in dura mater after TMJ inflammation. BoNT/A was injected into the TMJ ( $5 \text{ U kg}^{-1}$  i.a.) or trigeminal ganglion ( $2 \text{ U kg}^{-1}$  i.g.) 3 days before CFA. Sumatriptan ( $175 \text{ mg kg}^{-1}$ ) was administered p.o. 24 h after CFA. Four days following BoNT/A or 2 h after sumatriptan rats were injected with Evans blue (i.v.,  $40 \text{ mg kg}^{-1}$ ) and perfused with saline. Dura was collected for formaldehyde extraction and spectrophotometric measurement of Evans blue dye which extravasates in complex with plasma proteins. Scatter plot represents data from individual animals, and horizontal lines and bars indicate mean  $\pm$  SEM.  $n$  (animals per group) = 5–9. \* $P < 0.05$ , \*\*\* $P < 0.001$ , significantly different from saline control; ++ $P < 0.01$ ; +++ $P < 0.001$ , significantly different from saline + CFA; one-way ANOVA followed by Newman–Keuls *post hoc* test.



room temperature with 1:1600 anti-BoNT/A-cleaved SNAP-25 antibody (provided by Ornella Rossetto, University of Padua, Italy) in PBS containing 1% goat serum. The antibody binds specifically to BoNT/A-cleaved SNAP-25 and not the intact SNAP-25 (Matak *et al.*, 2011). Next day, the samples were incubated with Alexa Fluor 555 anti-rabbit secondary antibody. Stained dura was carefully spread on the glass slides and cover-slipped with an anti-fading agent. In animals injected at four different sites or only into the TMJ ( $5 \text{ U kg}^{-1}$ ), additional labelling with rabbit anti-CGRP antibody (1:5000, Sigma) was performed. In order to prevent a possible cross-reactivity of cleaved SNAP-25 with CGRP, a modified primary antibody elution procedure with pre-heated acidic buffer ( $50^\circ\text{C}$ ,  $\text{pH} = 2$ , 25 mM glycine and 1% SDS) was performed, as described previously in detail (Matak *et al.*, 2014). After the elution, the dural samples were stained with anti-CGRP and Alexa Fluor 488 secondary antibody. The appearance of cleaved SNAP-25 Alexa Fluor 555 stained fibre profiles, observed before and after antibody elution, was unchanged. Cross-reactivity controls (omitted CGRP antibody) showed no Alexa Fluor 488 signal in association with cleaved SNAP-25 fibers, as reported previously (Matak *et al.*, 2014).

### *Investigation of the effect of the axonal transport inhibitor, colchicine, on antinociceptive activity and appearance of cleaved SNAP-25 in dura mater following BoNT/A injection*

By blocking the axonal transport within the trigeminal ganglion, we examined the involvement of the axonal traffic via the trigeminal nerve of BoNT/A for its antinociceptive

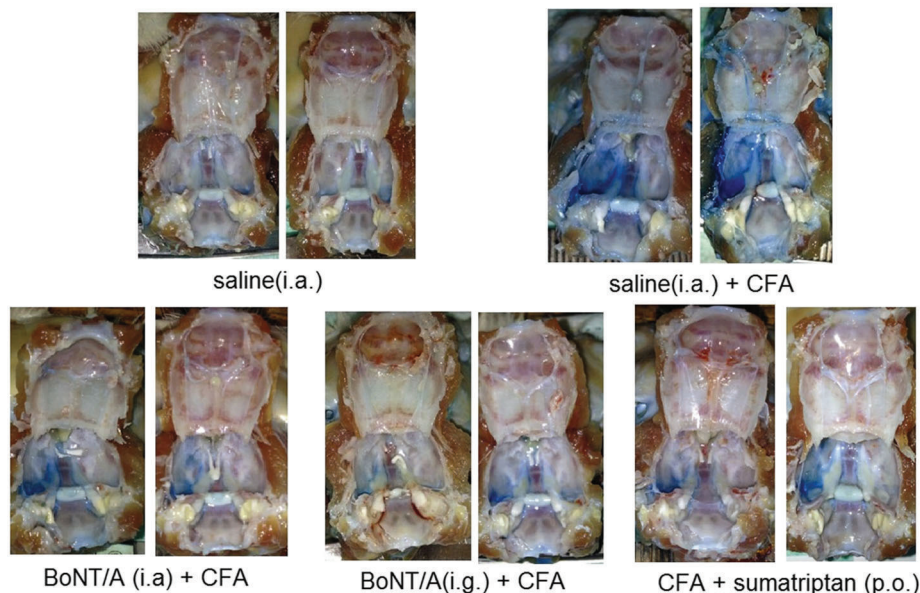
activity and for the presence of cleaved SNAP-25 in the dura mater. Anesthetized animals were injected in the TMJ with saline or BoNT/A ( $5 \text{ U kg}^{-1}$ ). Immediately after TMJ injection, the animals were injected with  $2 \mu\text{L}$  of saline or an equal volume of the axonal transport blocker colchicine (5 mM) into the trigeminal ganglion, percutaneously via the infraorbital canal as previously described (Filipović *et al.*, 2012). Seven days after i.a. and i.g. treatments, the animals were treated with CFA, and the mechanical allodynia was measured after 24 h, as described above. Then, the animals were anaesthetized and perfused with saline and fixative, and the dural tissue was processed and stained for immunohistochemistry of BoNT/A-cleaved SNAP-25 as described above.

### *Data analysis*

Results are presented as means  $\pm$  SEM and analysed by one-way ANOVA followed by the Newman–Keuls *post hoc* test.  $P < 0.05$  was considered significant.

### *Materials*

The suppliers of the reagents used were as follows: Evans blue (Merck KGaA, Darmstadt, Germany) reconstituted in 0.9% saline to obtain the required dose ( $40 \text{ mg kg}^{-1}$ ); CFA cell suspension (Sigma, St. Louis, MO, USA); colchicine (Sigma, St. Louis, MO, USA); sumatriptan (Glaxo Wellcome, Taplow, UK) reconstituted in drinking water; and BoNT/A diluted in 0.9% saline (Botox®; Allergan Inc., Irvine, CA, USA). One unit (1 U) of BoNT/A preparation contains 48 pg of purified *Clostridium botulinum* neurotoxin type A complex.



### **Figure 3**

Neurogenic plasma protein extravasation in dura is reduced by i.a./i.g. BoNT/A and p.o. sumatriptan – photographs of open cranial cavities. Left side: TMJ was injected with CFA 1 day before animal perfusion with saline. BoNT/A was injected into the TMJ ( $5 \text{ U kg}^{-1}$  i.a.) or trigeminal ganglion ( $2 \text{ U kg}^{-1}$  i.g.) 3 days before CFA. Sumatriptan ( $175 \text{ mg kg}^{-1}$ ) was administered p.o. 24 h after CFA. Four days following BoNT/A or 2 h after sumatriptan rats were intravenously injected with Evans blue ( $40 \text{ mg kg}^{-1}$ ) and perfused with saline. Photographs were taken upon the perfusion with saline and the removal of brain tissue.

## Results

### *CFA-evoked bilateral allodynia is reduced by i.a. and i.g. BoNT/A, and oral sumatriptan*

Animals treated with CFA injected into the TMJ developed mechanical allodynia 24 h after the injection. Allodynia appeared bilaterally. Pre-treatment with BoNT/A injected ipsilaterally to the CFA injection [both i.a. ( $5 \text{ U kg}^{-1}$ ) and i.g. ( $2 \text{ U kg}^{-1}$ )] 3 days before CFA, reduced the mechanical allodynia bilaterally ( $P < 0.001$ ). Similarly, 2 h after administration of sumatriptan ( $175 \mu\text{g kg}^{-1}$ , p.o.), the mechanical allodynia was reduced bilaterally ( $P < 0.001$ ). The differences between the BoNT/A and sumatriptan treatments were not significant (Figure 1).

### *BoNT/A and sumatriptan reduce plasma protein extravasation in dura mater*

Dural plasma protein extravasation was significantly increased bilaterally in CFA-injected animals compared with control values (Figures 2–4). Plasma protein extravasation in the ipsilateral dura was double that on the contralateral side ( $P < 0.001$ , *t*-test for dependent samples). BoNT/A injected both i.a. ( $5 \text{ U kg}^{-1}$ ) and i.g. ( $2 \text{ U kg}^{-1}$ ), as well as sumatriptan ( $175 \mu\text{g kg}^{-1}$  p.o.), reduced the ipsilateral dural plasma protein extravasation (Figure 2). In the contralateral side, none of the treatments affected the DNI.

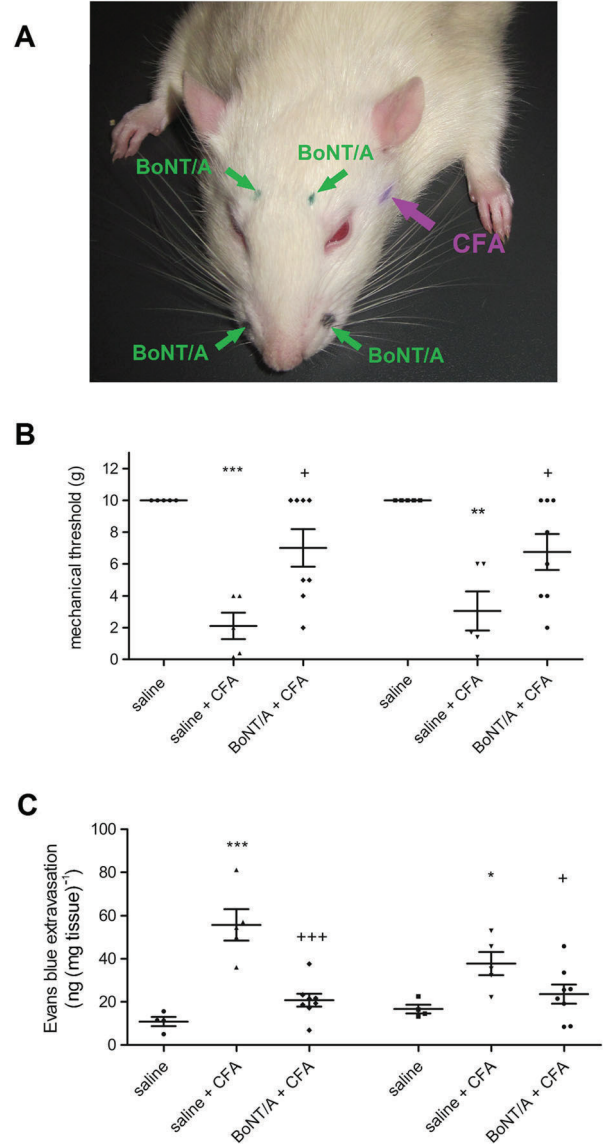
In a separate experiment, we employed four BoNT/A low-dose bilateral injections into the face of the rats (Figure 4). As observed with the single BoNT/A injection into the TMJ, four injections outside of TMJ prevented both bilateral allodynia and the CFA-evoked plasma protein extravasation (Figure 4).

### *TMJ inflammation induces dural tissue infiltration with inflammatory cells, which is prevented by BoNT/A*

Histological staining of the dural tissue of CFA-treated rats demonstrated an elevated number of automatically counted, Giemsa-positive, cell nuclei, compared with those in saline-treated animals ( $P < 0.001$ ), indicating an inflammatory cell infiltration. Inflammatory cells present in CFA-injected animals (not present in saline control) were identified by an experienced pathologist, as lymphocytes, monocytes and plasma cells, as previously found in a model of trigeminal neuropathy (Filipović *et al.*, 2014). The lack of polymorphonuclear neutrophils in dura suggests the presence of a sterile inflammation. BoNT/A prevented the increased number of Giemsa positive profiles evoked by i.a. CFA (Figure 5).

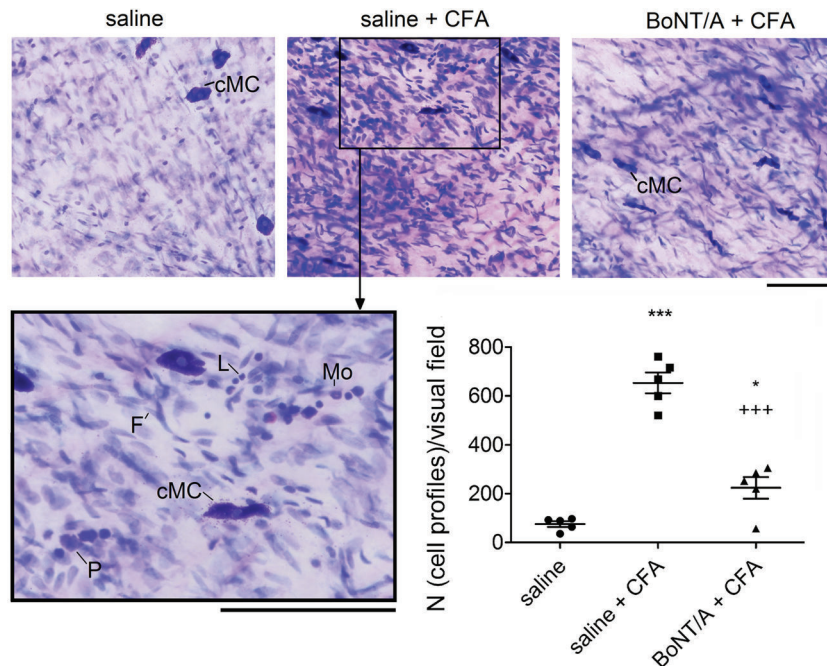
### *TMJ inflammation induces up-regulation of CGRP in dura and TNC, which is reduced by i.a. BoNT/A*

Following CFA-induced TMJ inflammation, CGRP expression was significantly increased in dura mater and ipsilateral caudal trigeminal nuclei. BoNT/A injected into the TMJ prevented the CGRP increase in dura mater. The effect of BoNT/A on CGRP expression in trigeminal nuclei was not significant. CGRP concentration was not significantly altered in trigeminal ganglion and CSF (Figure 6).



**Figure 4**

The effect of BoNT/A injection outside the TMJ on mechanical allodynia and dural Evans blue/plasma protein extravasation. BoNT/A (total dose  $5 \text{ U kg}^{-1}$ ) was injected at four sites (bilateral forehead and bilateral whisker pad injections) (A). Three days after BoNT/A rats were injected with CFA into the TMJ. Facial allodynia was measured with von Frey filaments 24 h after CFA injection. After behavioural measurement, rats were injected with Evans blue (i.v.,  $40 \text{ mg kg}^{-1}$ ) and perfused with saline. Dura was harvested for formamide extraction and spectrophotometric measurement of Evans blue dye extravasated in complex with plasma proteins. (A) Sites of BoNT/A bilateral injections and position of TMJ to be injected with CFA. (B) The effect of BoNT/A on mechanical thresholds measured by von Frey filaments (mechanical allodynia). (C) The effect of bilateral Evans blue/plasma protein extravasation in the cranial dura. Scatter plot represents individual animal values, and horizontal lines and bars indicate mean  $\pm$  SEM.  $n$  (animals per group) = 5–8. \* $P < 0.05$ , \*\* $P < 0.01$ , \*\*\* $P < 0.001$ , significantly different from saline control; + $P < 0.05$ , significantly different from saline + CFA; +++ $P < 0.001$ , significantly different from saline + CFA; one-way ANOVA followed by Newman–Keuls *post hoc* test.



**Figure 5**

The effect of BoNT/A injection into the TMJ on inflammatory cell infiltration in dura mater in CFA-treated rats. The 5 U kg<sup>-1</sup> BoNT/A or saline were injected into the TMJ 3 days before the induction of TMJ inflammation by CFA. Histological staining of ipsilateral cranial dural tissue was performed using Giemsa staining. Number of Giemsa-stained cell profiles was automatically quantified by CellSens Dimension visualizing programme (Olympus). Each data value represents mean of 4–5 visual fields per single animal. L, lymphocyte; Mo, monocyte; P, plasma cell, cMC, constitutive mast cell; F, fibrocyte. Scale bars = 100  $\mu$ m. Scatter plot represents individual animal values, and horizontal lines and bars indicate mean  $\pm$  SEM.  $n$  (animals per group) = 5. \* $P$  < 0.05, significantly different from saline control; \*\*\* $P$  < 0.001, significantly different from saline control; +++ $P$  < 0.001, significantly different from saline + CFA; one-way ANOVA followed by Newman–Keuls *post hoc* test.

### *Cleaved SNAP-25 colocalizes with CGRP-expressing afferents of the dura mater after BoNT/A peripheral treatment*

In animals injected peripherally with BoNT/A, we observed the presence of cleaved SNAP-25 in the injected-side lateral and parietal dura near the dural blood vessels after BoNT/A multiple (Figure 7) and single injections into TMJ and whisker pad (not shown). Cleaved SNAP-25 was also visible in non-vascular areas of dura. All examined fibers containing SNAP-25 co-expressed bright granular immunoreactivity for CGRP (Figure 7). Contralateral dura was devoid of cleaved SNAP-25, ruling out possible systemic BoNT/A diffusion (Figure 7). Complete colocalization of CGRP and cleaved SNAP-25 was also visible after the single injection of BoNT/A (5 U kg<sup>-1</sup>) into the TMJ (not shown).

### *Anti-nociceptive activity and enzymatic activity of BoNT/A in dura mater are axonal transport-dependent*

The anti-nociceptive actions of BoNT/A on CFA-induced pain was prevented by the axonal transport blocker colchicine injected into the trigeminal ganglion (Figure 8). This is in line with previous findings that BoNT/A antinociceptive activity is dependent on axonal transport (Filipović *et al.*, 2012). Similarly, cleaved SNAP-25 was no longer found in dura after treatment with colchicine (Figure 8). This finding suggests that, after local

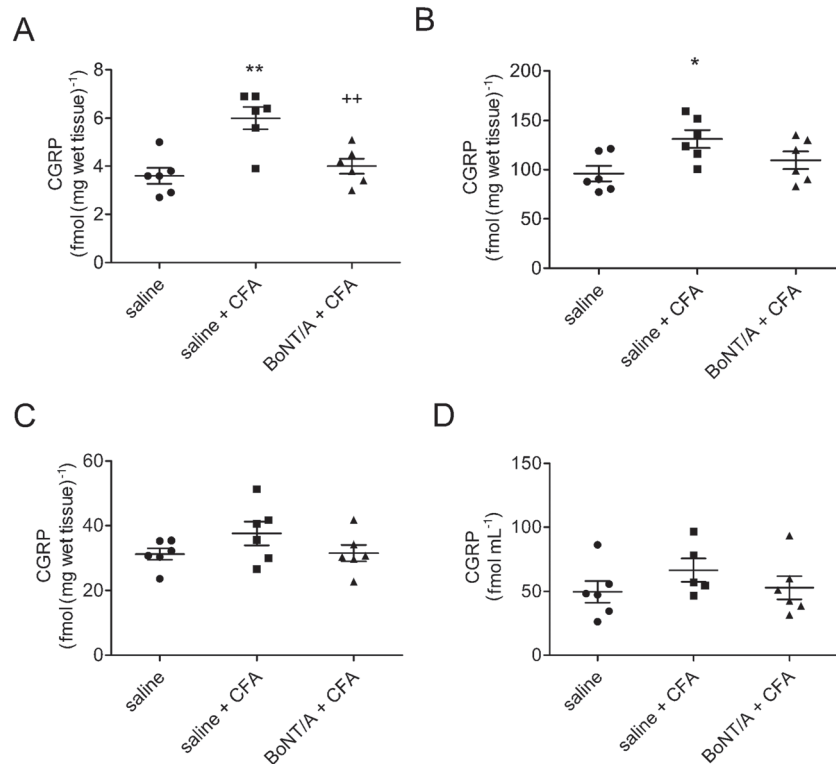
peripheral injection of 5 U kg<sup>-1</sup> in the facial area, BoNT/A is axonally transported to the ipsilateral dural primary afferents by microtubule-dependent mechanism through the ganglion.

## Discussion

By studying the TMJ inflammation evoked by CFA, we found that the pain in this experimental condition was accompanied by DNI. The neurogenic plasma protein leakage in cranial dural tissue was accompanied by increased inflammatory cell infiltration and up-regulation of CGRP peptide levels (Figures 2–4, 6).

Along with the present report, we have also shown that other painful stimuli in the trigeminal region (formalin-induced or experimental neuropathic pain) were accompanied by DNI (Filipović *et al.*, 2012, 2014). These observations demonstrate the occurrence of DNI in experimental trigeminal pain. To study migraine, other authors induced DNI more 'artificially' by different chemical or electrical stimuli (Markowitz *et al.*, 1987; Buzzi and Moskowitz, 1990; O'Shaughnessy and Connor, 1994; Arulmani *et al.*, 2006; Nelson *et al.*, 2010; Akerman *et al.*, 2013). Current opinion suggests that the migraine headache involves CNS dysfunction, accompanied by activation of the trigeminovascular system (Williamson and Hargreaves, 2001), and release of vasoactive peptides which induce DNI (Markowitz *et al.*, 1987). This is not limited to





**Figure 6**

BoNT/A effect on concentration of CGRP protein in dura, trigeminal nucleus caudalis, trigeminal ganglion and CSF in CFA-treated rats. The  $5 \text{ U kg}^{-1}$  BoNT/A was injected into the TMJ 3 days before the CFA treatment. Tissues were collected 1 day post-CFA, and the CGRP concentration was analysed by RIA. (A) Dura mater; (B) ipsilateral trigeminal nucleus caudalis; (C) ipsilateral trigeminal ganglion; and (D) CSF. Scatter plot represents individual animal values, and horizontal lines and bars indicate mean  $\pm$  SEM.  $n$  (animals per group) = 6. \* $P < 0.05$ , significantly different from saline control; \*\* $P < 0.01$ , significantly different from saline control; \*\*\* $P < 0.001$ , significantly different from saline control; + $P < 0.05$ , significantly different from saline + CFA; ++ $P < 0.01$ , significantly different from saline + CFA; one-way ANOVA followed by Newman–Keuls *post hoc* test.

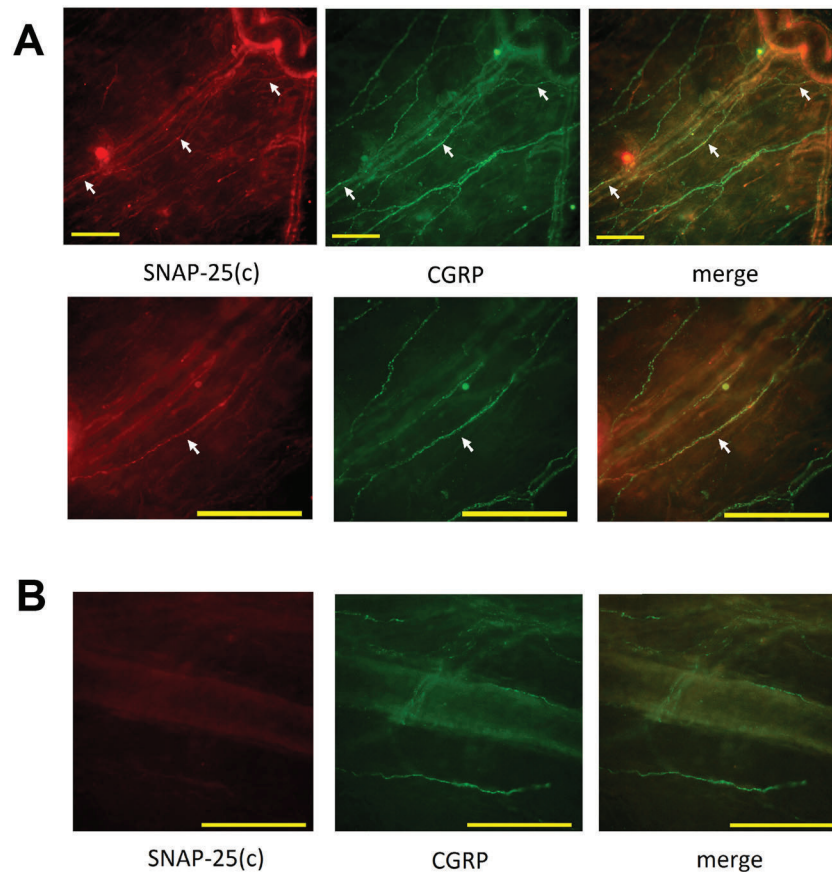
experimental animals because it was clinically observed that DNI accompanies migraine and cluster headache attacks (Göbel *et al.*, 2000; Knotkova and Pappagallo 2007). Thus, ongoing pain in the TMJ area, as well as other orofacial pain models, can be employed to study the sensitization of trigeminal dural afferents, assumed to be present in migraine and other headaches. In the present experiments, peripherally injected BoNT/A reduced mechanical allodynia and inflammatory changes in the cranial dura [plasma protein extravasation and cellular inflammatory response (Figures 1, 2)]. The similar effects of BoNT/A injections given directly into the ganglion suggests that BoNT/A action is primarily associated with the trigeminal system (Figures 1, 2).

The recommended protocol for BoNT/A application in chronic migraine consists of multiple injections to 31 head and neck sites (Diener *et al.*, 2010). A similar protocol is difficult to replicate in rats because of the smaller cranial dimensions. Thus, we injected BoNT/A bilaterally to the rat forehead region overlying the frontal bone (innervated by V1 ophthalmic trigeminal branch) and whisker pad (V2 maxillary branch). Such BoNT/A injections at four sites were effective in preventing CFA-evoked pain and DNI similarly to the single BoNT/A injection into the TMJ (Figure 4). This

demonstrates that the effects of BoNT/A on allodynia and DNI are not primarily mediated by its direct peripheral effect on CFA-stimulated neurons.

Plasma protein extravasation in cranial dura is a useful marker of trigeminal activation, often employed in preclinical screening of antimigraine drugs (Markowitz *et al.*, 1987; Buzzi and Moskowitz, 1990; O'Shaughnessy and Connor, 1994; Arulmani *et al.*, 2006; Nelson *et al.*, 2010; Akerman *et al.*, 2013). DNI consists of two main components: vasodilation, which is mediated by CGRP, and plasma protein extravasation, which is mediated by substance P. Blocking only the substance P transmission by NK<sub>1</sub> receptor antagonists did not reduce migraine symptoms, suggesting that CGRP transmission might play a more important role in the pathophysiology of migraine (Williamson and Hargreaves 2001; Peroutka, 2005). Thus, we investigated the possibility that the antimigraine actions of BoNT/A were associated with prevention of CGRP transmission. Here, we have found that peripherally injected BoNT/A prevented the CFA-induced increase in CGRP levels in the cranial dura (Figure 6). Interestingly, in chronic migraine patients responsive to BoNT/A, the pretreatment CGRP plasma levels were increased in comparison with those in BoNT/A non-responsive patients (Cernuda-Morollón *et al.*, 2014). After the





### Figure 7

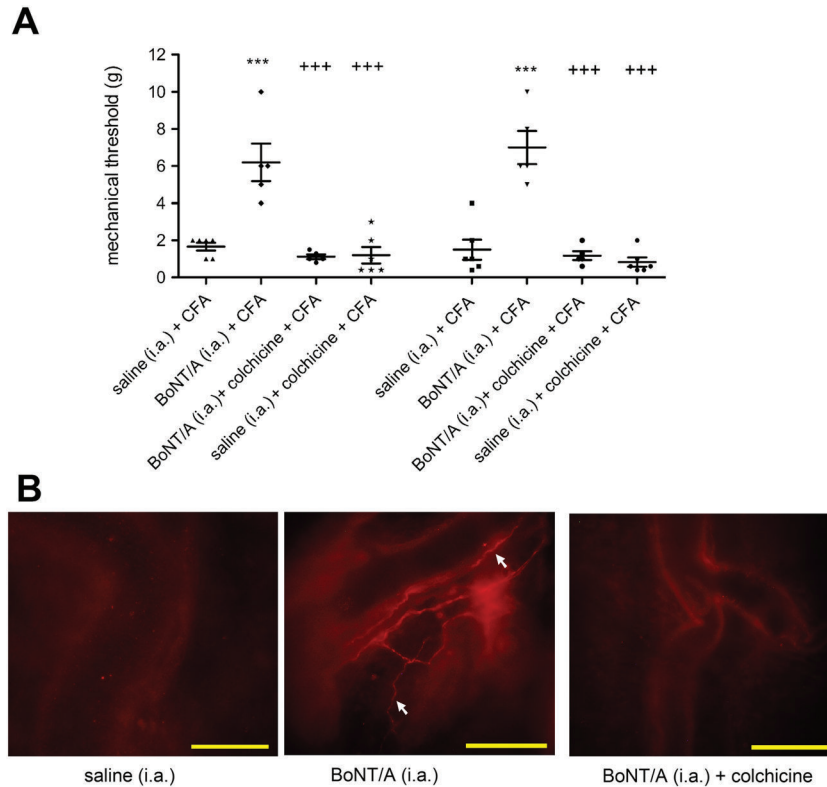
Colocalization of truncated SNAP-25 and CGRP in ipsilateral cranial dura after BoNT/A injection in the periphery. BoNT/A 20 U kg<sup>-1</sup> total dose was injected into four different sites (TMJ), whisker pad, and frontal and temporal regions; 1.75 U/20 µL per site) on the left side of the head. Animals were perfused for immunohistochemistry 6 days later. (A) Upper panel: lower magnification fluorescent microphotograph shows the course of a single-cleaved SNAP-25 [SNAP-25(c)]-immunoreactive fibre (arrows, red immunofluorescence) in the vicinity of dural blood vessels, which colocalizes with CGRP (green fibers). Lower panel: higher magnification image of the middle part of cleaved SNAP-25-immunoreactive fibre, which colocalizes with granular CGRP immunofluorescence. (B) Microphotograph of contralateral side dura of the same animal without detectable cleaved SNAP-25 in CGRP-expressing afferents. The images are representative of the data obtained from four animals. Scale bars = 100 µm.

treatment, BoNT/A normalized the elevated CGRP plasma levels (Cernuda-Morollón *et al.*, 2015). The authors posited that BoNT/A inhibits the release of CGRP from peripheral trigeminal neurons and, consequently, reduces the CGRP-mediated trigeminal sensitization in migraine (Cernuda-Morollón *et al.*, 2015).

Because the anti-migraine effect of BoNT/A is difficult to explain by its local action on peripheral, extracranial sensory nerves endings, it was suggested that BoNT/A exhibits its actions in pain and migraine by reaching dural trigeminal afferents (Matak and Lacković, 2014; Ramachandran and Yaksh, 2014). Previously, we reported that the effects of BoNT/A on trigeminal neuropathic pain and resulting DNI was prevented by colchicine injected into the ganglion, indicative of axonal transport of this toxin (Filipović *et al.*, 2012). After BoNT/A peripheral injection, we detected cleaved SNAP-25 in the cranial dura mater (Figures 7, 8). Moreover, cleaved SNAP-25 and CGRP were colocalized in the ipsilateral dura (Figure 7). Peripherally administered BoNT/A may prevent the SNAP-25-mediated release of CGRP in cranial meninges and consequent CGRP effects presumably involved

in migraine pathophysiology (Williamson and Hargreaves, 2001; Durham, 2008; Geppetti *et al.*, 2012; Karsan and Goadsby, 2015).

It was recently found that BoNT/A reduces the mechanical sensitivity of extracranially projecting collaterals of dural afferents which exit the cranium through the skull bone sutures in rats (Burstein *et al.*, 2014). However, in our experiments, BoNT/A effects on dura mater were present even if the toxin was administered away from cranial sutures (TMJ and whisker pad). Additionally, blockade of the axonal transport of the toxin by direct i.g. colchicine prevented the formation of cleaved SNAP-25 in the dura (Figure 8) and other effects of BoNT/A on DNI (Filipović *et al.*, 2012). Colchicine action is limited to the injection site (Kreutzberg, 1969; Cangiano and Fried, 1977) and, therefore any possible BoNT/A axonal traffic to the dura via extracranial collaterals of dural afferents should not be prevented by administration of colchicine into the ganglion. These observations do not support an important contribution of BoNT/A local activity on extracranially projecting dural afferent collaterals.



**Figure 8**

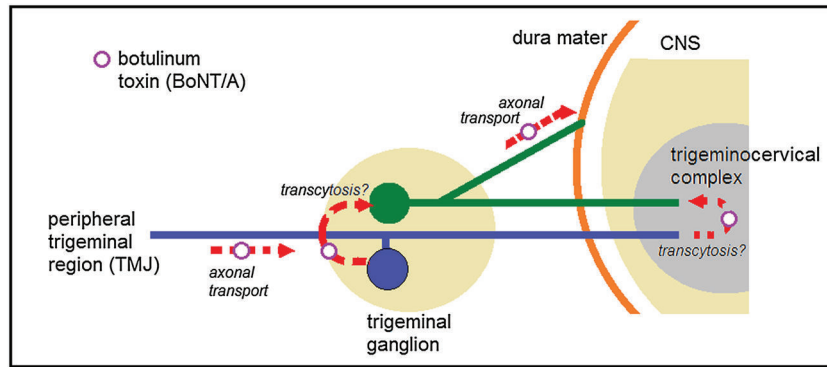
BoNT/A antinociceptive activity and occurrence of cleaved SNAP-25 in dura mater is dependent on axonal transport. (A) Preventive effect of i.a. BoNT/A ( $5 \text{ U kg}^{-1}$ ) on mechanical allodynia evoked by CFA injection into the TMJ is prevented by colchicine (5 mM) injection into the trigeminal ganglion. Scatter plot represents individual animal values, and horizontal lines and bars indicate mean  $\pm$  SEM.  $n$  (animals per group) = 5–6. \*\*\* $P < 0.001$ , significantly different from saline i.a. + CFA; +++ $P < 0.001$ , significantly different from BoNT/A i.a. + CFA; one-way ANOVA followed by Newman–Keuls *post hoc* test. (B) Colchicine prevented the occurrence of cleaved SNAP-25 immunofluorescence in dura mater. The image is representative of the data obtained from four animals per group. Scale bar = 100  $\mu\text{m}$ .

The question arising from the present experiments is how BoNT/A crosses from the trigeminal extracranial nerves to trigeminal nerve endings in dura. Dura and extracranial trigeminal regions are innervated by separate sensory neurons (Larrier and Lee, 2003; Shimizu *et al.*, 2012). Therefore, the transcytosis of BoNT/A from the extracranial sensory neurons to neurons that innervate dura seems the most logical explanation for the occurrence of cleaved SNAP-25 in dura mater after facial injection of the toxin. Up to now, transcytosis of BoNT/A between different neurons has been demonstrated directly inside the retina and brain (Restani *et al.*, 2011, 2012). In the trigeminal region, BoNT/A transcytosis within the trigeminal ganglion after its peripheral injection has been suggested by Kitamura *et al.* (2009). The authors investigated the effect of BoNT/A on vesicular neurotransmitter release in trigeminal neurons acutely isolated from neuropathic rats subjected to infraorbital nerve constriction injury. BoNT/A injected into the rat face induced a profound reduction of vesicular neurotransmitter release in all neurons isolated from the ganglion. They assumed that, in order to induce a widespread effect, BoNT/A was transcytosed within the ganglion (Kitamura *et al.*, 2009). In the trigeminal ganglion, facially injected BoNT/A reduced the expression of TRPV1 channels in neurons projecting to the dura mater (Shimizu *et al.*, 2012). These

authors proposed that the effects of BoNT/A were mediated by transcytosis of the toxin, within trigeminal ganglion from extracranially projecting neurons to neurons that innervate the dura (Shimizu *et al.*, 2012). The exact place and mechanism of such putative transcytosis remain to be elucidated. It is likely to occur within the trigeminal ganglion itself (Shimizu *et al.*, 2012), although transcytosis in the trigeminal sensory nuclei cannot be excluded (Ramachandran and Yaksh, 2014) (Figure 9).

The conventional antimigraine drug sumatriptan, an agonist of 5-HT<sub>1B/D</sub> receptors, reduced the pain supersensitivity and dural plasma protein extravasation in CFA-induced TMJ inflammation, as well (Figures 1, 2). Sumatriptan prevents the evoked release of CGRP and substance P *in vitro* and *ex vivo* (Buzzi and Moskowitz, 1990; Durham and Russo, 1999). Furthermore, sumatriptan reduces elevated CGRP concentrations in blood and saliva during migraine attacks (Goadsby *et al.*, 1990; Bellamy *et al.*, 2006). CGRP antagonists are reported to reduce the symptoms of acute migraine attacks (Edvinsson and Warfvinge, 2013). Antibodies against CGRP and CGRP receptors might also be effective as a prophylactic chronic migraine treatment (Edvinsson, 2015).

In conclusion, as demonstrated here, BoNT/A might have beneficial effect on experimental TMJ pain and the accompanying dural inflammation. The effects of BoNT/A in the cranial



**Figure 9**

Possible sites of action of axonally transported BoNT/A in migraine and other headaches. Following injection in peripheral trigeminal region, BoNT/A is taken up by the extracranial trigeminal afferent (blue pseudounipolar neuron) and retrogradely transported to trigeminal ganglion. BoNT/A is then transcytosed to meningeal afferent (green pseudounipolar neuron) and anterogradely transported to dura mater where it inhibits neuropeptide release. Alternatively, the transcytosis can take place in the trigeminocervical complex.

dura could be reconstructed as follows: after peripheral injection, BoNT/A is taken up by sensory nerve endings and axonally transported to trigeminal ganglion. After transcytosis, the toxin reaches dural nerve endings containing CGRP and suppresses the CGRP-mediated sensitization of the trigeminovascular system and DNI. At present, this seems as the most convincing hypothesis of the action of BoNT/A in migraine and other headaches.

## Acknowledgements

The work was supported by grants from Croatian Ministry of Science, Education and Sport (no. 108-1080003-0001 awarded to Z. L.), Croatian National Science Foundation (no. O-1259-2015 awarded to Z. L.), Hungarian National Brain Research Program (SROP4.2.2.A-11/1/KONV-2012-0024 and the KTIA NAP\_13-1-2013-0001 awarded to Z. H.) and National Brain Research Program B (Chronic Pain Research Group; KTIA\_NAP\_13-2014-0022; awarded to Z. L., 888819). We thank Mrs. Teréz Bagoly for her excellent technical contribution to the CGRP RIA and Prof Vladimir Trkulja for the suggestions regarding the presentation of results. Antibody to cleaved SNAP-25 was kindly provided by Assistant Prof Ornella Rossetto (University of Padua, Italy). The histological analysis was performed by pathologist Prof Mara Dominis.

## Author contributions

Z. L., B. F. and I. M. conceived and designed the study. Z. L., B. F., I. M. and Z. H. analysed and interpreted the data. Z. L., B. F., I. M. and Z. H. drafted the manuscript. All authors have approved the final version of the manuscript. All authors are accountable for all aspects of the work in ensuring that questions related to the accuracy or integrity of any part of the work are appropriately investigated and resolved.

## Conflicts of interest

The authors declare no conflict of interest.

## References

- Akerman S, Holland PR, Hoffmann J (2013). Pearls and pitfalls in experimental in vivo models of migraine: dural trigeminovascular nociception. *Cephalalgia* 33: 577–592.
- Alexander SPH, Benson HE, Faccenda E, Pawson AJ, Sharman JL, Spedding M, *et al.* (2013). The concise guide to PHARMACOLOGY 2013/14: G protein-coupled receptors. *Br J Pharmacol* 170: 1459–1581.
- Arulmani U, Gupta S, VanDenBrink AM, Centurión D, Villalón CM, Saxena PR (2006). Experimental migraine models and their relevance in migraine therapy. *Cephalalgia* 26: 642–659.
- Bellamy JL, Cady RK, Durham PL (2006). Salivary levels of CGRP and VIP in rhinosinusitis and migraine patients. *Headache* 46: 24–33.
- Bevilaqua Grossi D, Lipton RB, Bigal ME (2009). Temporomandibular disorders and migraine chronification. *Curr Pain Headache Rep* 13: 314–318.
- Bigal ME, Walter S, Rapoport AM (2013). Calcitonin gene-related peptide (CGRP) and migraine current understanding and state of development. *Headache* 53: 1230–1244.
- Blasi J, Chapman ER, Link E, Binz T, Yamasaki S, de Camilli P, *et al.* (1993). Botulinum neurotoxin A selectively cleaves the synaptic protein SNAP-25. *Nature* 365: 160–163.
- Burstein R, Zhang X, Levy D, Aoki KR, Brin MF (2014). Selective inhibition of meningeal nociceptors by botulinum neurotoxin type A: therapeutic implications for migraine and other pains. *Cephalalgia* 34: 853–869.
- Buzzi MG, Moskowitz MA (1990). The antimigraine drug, sumatriptan (GR43175), selectively blocks neurogenic plasma extravasation from blood vessels in dura mater. *Br J Pharmacol* 99: 202–206.
- Cangiano A, Fried JA (1977). The production of denervation-like changes in rat muscle by colchicine, without interference with axonal transport or muscle activity. *J Physiol* 265: 63–84.

- Cernuda-Morollón E, Martínez-Cambor P, Ramón C, Larrosa D, Serrano-Pertierra E, Pascual J (2014). CGRP and VIP levels as predictors of efficacy of onabotulinumtoxin type A in chronic migraine. *Headache* 54: 987–995.
- Cernuda-Morollón E, Ramón C, Martínez-Cambor P, Serrano-Pertierra E, Larrosa D, Pascual J (2015). OnabotulinumtoxinA decreases interictal CGRP plasma levels in chronic migraine patients. *Pain* 156: 820–824.
- Dallas FA, Dixon CM, McCulloch RJ, Saynor DA (1989). The kinetics of <sup>14</sup>C-GR43175 in rat and dog. *Cephalalgia* 9: 53–56.
- de Rossi SS, Greenberg MS, Liu F, Steinkeler A (2014). Temporomandibular disorders: evaluation and management. *Med Clin North Am* 98: 1353–1384.
- Diener HC, Dodick DW, Aurora SK, Turkel CC, Degryse RE, Lipton RB, *et al.* (2010). PREEMPT 2 Chronic Migraine Study Group. OnabotulinumtoxinA for treatment of chronic migraine: results from the double-blind, randomized, placebo-controlled phase of the PREEMPT 2 trial. *Cephalalgia* 30: 804–814.
- Dressler D (2013). Botulinum toxin therapy: its use for neurological disorders of the autonomic nervous system. *J Neurol* 260: 701–713.
- Durham PL (2008). Inhibition of calcitonin gene-related peptide function: a promising strategy for treating migraine. *Headache* 48: 1269–1275.
- Durham PL, Russo AF (1999). Regulation of calcitonin gene-related peptide secretion by a serotonergic antimigraine drug. *J Neurosci* 19: 3423–3429.
- Edvinsson L (2015). CGRP receptor antagonists and antibodies against CGRP and its receptor in migraine treatment. *Br J Clin Pharmacol*. doi:10.1111/bcp.12618.
- Edvinsson L, Warfvinge K (2013). CGRP receptor antagonism and migraine therapy. *Curr Protein Pept Sci* 14: 386–392.
- Filipović B, Matak I, Bach-Rojecky L, Lacković Z (2012). Central action of peripherally applied botulinum toxin type A on pain and dural protein extravasation in rat model of trigeminal neuropathy. *PLoS One* 7: e29803.
- Filipović B, Matak I, Lacković Z (2014). Dural neurogenic inflammation induced by neuropathic pain is specific to cranial region. *J. Neural Transm* 121: 555–563.
- Franco AL, Gonçalves DA, Castanharo SM, Speciali JG, Bigal ME, Camparis CM (2010). Migraine is the most prevalent primary headache in individuals with temporomandibular disorders. *J Orofac Pain* 24: 287–292.
- Geppetti P, Rossi E, Chiarugi A, Benemei S (2012). Antidromic vasodilatation and the migraine mechanism. *J. Headache Pain* 13: 103–111.
- Goadsby PJ, Edvinsson L, Ekman R (1990). Vasoactive peptide release in the extracerebral circulation of humans during migraine headache. *Ann Neurol* 28: 183–187.
- Göbel H, Czech N, Heinze-Kuhn K, Heinze A, Brenner W, Muhle C, *et al.* (2000). Evidence of regional plasma protein extravasation in cluster headache using Tc-99 m albumin SPECT. *Cephalalgia* 20: 287.
- Harper RP, Kerins CA, McIntosh JE, Spears R, Bellinger LL (2001). Modulation of the inflammatory response in the rat TMJ with increasing doses of complete Freund's adjuvant. *Osteoarthritis Cartilage* 9: 619–624.
- Kalandakanond S, Coffield JA (2001). Cleavage of SNAP-25 by botulinum toxin type A requires receptor-mediated endocytosis, pH-dependent translocation, and zinc. *J. Pharmacol. Exp. Ther.* 296: 980–986.
- Karsan N, Goadsby PJ (2015). Calcitonin gene-related peptide and migraine. *Curr Opin Neurol* 28: 250–254.
- Kilkenny C, Browne WJ, Cuthill IC, Emerson M, Altman DG (2010). Animal research: reporting in vivo experiments: the ARRIVE guidelines. *PLoS Biol* 8: e1000412.
- Kitamura Y, Matsuka Y, Spigelman I, Ishihara Y, Yamamoto Y, Sonoyama W, *et al.* (2009). Botulinum toxin type a (150 kDa) decreases exaggerated neurotransmitter release from trigeminal ganglion neurons and relieves neuropathy behaviors induced by infraorbital nerve constriction. *Neuroscience* 159: 1422–1429.
- Knotkova H, Pappagallo M (2007). Imaging intracranial plasma extravasation in a migraine patient: a case report. *Pain Med* 8: 383–387.
- Kreutzberg GW (1969). Neuronal dynamics and axonal flow. IV. Blockage of intra-axonal enzyme transport by colchicine. *Proc Natl Acad Sci U S A* 62: 722–728.
- Larrier D, Lee A (2003). Anatomy of headache and facial pain. *Otolaryngol Clin North Am* 36: 1041–1053.
- Markowitz S, Saito K, Moskowitz MA (1987). Neurogenically mediated leakage of plasma protein occurs from blood vessels in dura mater but not brain. *J Neurosci* 7: 4129–4136.
- Matak I, Bach-Rojecky L, Filipović B, Lacković Z (2011). Behavioral and immunohistochemical evidence for central antinociceptive activity of botulinum toxin A. *Neuroscience* 186: 201–207.
- Matak I, Lacković Z (2014). Botulinum toxin A, brain and pain. *Prog Neurobiol* 119–120: 39–59.
- Matak I, Rossetto O, Lacković Z (2014). Botulinum toxin type A selectivity for certain types of pain is associated with capsaicin-sensitive neurons. *Pain* 155: 1516–1526.
- Moskowitz MA (1990). Basic mechanisms in vascular headache. *Neurol Clin* 8: 801–815.
- Nelson DL, Phebus LA, Johnson KW, Waincott DB, Cohen ML, Calligaro DO, *et al.* (2010). Preclinical pharmacological profile of the selective 5-HT<sub>1F</sub> receptor agonist lasmiditan. *Cephalalgia* 30: 1159–1169.
- Németh J, Görcs T, Helyes Z, Oroszi G, Kocsy T, Pintér E, *et al.* (1998). Development of a new sensitive CGRP radioimmunoassay for neuropharmacological research. *Neurobiology (Bp)*. 6: 473–475.
- O'Shaughnessy CT, Connor HE (1994). Investigation of the role of tachykinin NK<sub>1</sub>, NK<sub>2</sub> receptors and CGRP receptors in neurogenic plasma extravasation in rat dura mater. *Eur J Pharmacol* 263: 193–198.
- Pawson AJ, Sharman JL, Benson HE, Faccenda E, Alexander SP, Buneman OP, *et al.* NC-IUPHAR(2014). The IUPHAR/BPS Guide to PHARMACOLOGY: an expert-driven knowledge base of drug targets and their ligands. *Nucl. Acids Res.* 42 (Database Issue): D11098–D11106.
- Peroutka SJ (2005). Neurogenic inflammation and migraine: implications for the therapeutics. *Mol Interv* 5: 304–311.
- Pozsgai G, Hajna Z, Bagoly T, Boros M, Kemény Á, Materazzi S, *et al.* (2012). The role of transient receptor potential ankyrin 1 (TRPA1) receptor activation in hydrogen-sulphide-induced CGRP-release and vasodilation. *Eur J Pharmacol* 689: 56–64.
- Ramachandran R, Yaksh TL (2014). Therapeutic use of botulinum toxin in migraine: mechanisms of action. *Br J Pharmacol* 171: 4177–4192.
- Restani L, Antonucci F, Gianfranceschi L, Rossi C, Rossetto O, Caleo M (2011). Evidence for anterograde transport and transcytosis of botulinum neurotoxin A (BoNT/A). *J Neurosci* 31: 15650–15659.
- Restani L, Novelli E, Bottari D, Leone P, Barone I, Galli-Resta L, *et al.* (2012). Botulinum neurotoxin A impairs neurotransmission following retrograde transsynaptic transport. *Traffic* 13: 1083–1089.

Schueler M, Messlinger K, Dux M, Neuhuber WL, de Col R (2013). Extracranial projections of meningeal afferents and their impact on meningeal nociception and headache. *Pain* 154: 1622–1631.

Schuh-Hofer S, Boehnke C, Reuter U, Siekmann W, Lindauer U, Arnold G, *et al.* (2003). A fluorescence-based method to assess plasma protein extravasation in rat dura mater using confocal laser scanning microscopy. *Brain Res Brain Res Protoc* 12: 77–82.

Shimizu T, Shibata M, Toriumi H, Iwashita T, Funakubo M, Sato H, *et al.* (2012). Reduction of TRPV1 expression in the trigeminal system by botulinum neurotoxin type-A. *Neurobiol Dis* 48: 367–378.

Sunil Dutt C, Ramnani P, Thakur D, Pandit M (2015). Botulinum toxin in the treatment of muscle specific Oro-facial pain: a literature review. *J Maxillofac Oral Surg* 14: 171–175.

Thalakoti S, Patil VV, Damodaram S, Vause CV, Langford LE, Freeman SE, *et al.* (2007). Neuron-glia signaling in trigeminal ganglion: implications for migraine pathology. *Headache* 47: 1008–1023.

Villa G, Ceruti S, Zanardelli M, Magni G, Jasmin L, Ohara PT, *et al.* (2010). Temporomandibular joint inflammation activates glial and immune cells in both the trigeminal ganglia and in the spinal trigeminal nucleus. *Mol Pain* 6: 89.

Williamson DJ, Hargreaves RJ (2001). Neurogenic inflammation in the context of migraine. *Microsc Res Tech* 53: 167–178.

Zimmerman M (1983). Ethical guidelines for investigations of experimental pain in conscious animals. *Pain* 16: 109–110.