

Surgical treatment of liver metastases

Tolić, Gaja

Master's thesis / Diplomski rad

2023

Degree Grantor / Ustanova koja je dodijelila akademski / stručni stupanj: **University of Zagreb, School of Medicine / Sveučilište u Zagrebu, Medicinski fakultet**

Permanent link / Trajna poveznica: <https://um.nsk.hr/um:nbn:hr:105:278861>

Rights / Prava: [In copyright](#)/[Zaštićeno autorskim pravom.](#)

Download date / Datum preuzimanja: **2025-01-03**



Repository / Repozitorij:

[Dr Med - University of Zagreb School of Medicine Digital Repository](#)



**UNIVERSITY OF ZAGREB
SCHOOL OF MEDICINE**

Gaja Tolić

Surgical treatment of liver metastases

GRADUATE THESIS



Zagreb, 2023

This graduate thesis was made at the Department of Surgery mentored by doc.dr.sc. Igor Petrović and was submitted for evaluation in the academic year 2022/2023.

LIST OF ABBREVIATIONS:

ACTH adrenocorticotrophic hormone

ALPPS associating liver partition and portal vein ligation

CDX2 caudal type homeobox transcription factor 2

CEA carcinoembryonic antigen

CRLM colorectal cancer liver metastases

CRC colorectal carcinoma

CT Computed tomography

DFS disease-free survival

EGFR epidermal growth factor receptor

EHD extrahepatic disease

FLR future liver remnant

HAI hepatic arterial infusion

IHC immunohistochemistry

INR international normalized ratio

IOUS Intra-operative ultrasound

ISL1 Islet-1

IVC inferior vena cava

LM liver metastases

LVD Liver venous deprivation

MRI magnetic resonance imaging

mTOR mammalian target of rapamycin

MWA microwave ablation

NCNN Noncolorectal, nonneuroendocrine

NET neuroendocrine tumor

PAX6 paired box gene 6

PET-CT Positron emission tomography/computed tomography

PFS progression-free survival

POHF postoperative hepatic failure

PTHrP parathyroid hormone-related protein

PVE portal vein embolization

RFA radiofrequency ablation

SSA Somatostatin analogue

VEGF vascular endothelial growth factor

VIP vasoactive intestinal peptide

WHO World Health Organization

5-FU 5-fluorouracil

TABLE OF CONTENTS

SUMMARY	i
SAŽETAK	ii
1. INTRODUCTION.....	1
2. COLORECTAL CANCER LIVER METASTASES (CRLM).....	1
2.1 Epidemiology.....	1
2.2 Diagnosis and workup	2
2.3 Role of chemotherapy in treatment of metastatic disease	2
2.4 Surgical management of resectable metachronous LM.....	4
2.5 Management of synchronous CRLM	5
2.6 Treatment of unresectable metastatic disease.....	7
3. NEUROENDOCRINE TUMOR LIVER METASTASES (NETLM)	7
3.1 NET Classification.....	8
3.2 NET liver metastases	8
3.2.1 Epidemiology	8
3.2.2 Presentation	8
3.2.3 Diagnosis	9
3.2.4 Treatment.....	10
4. NONCOLORECTAL, NONNEUROENDOCRINE LIVER METASTASES	11
5. LIVER RESECTION.....	12
5.1 Anatomy of the liver	12
5.2 Preoperative assessment.....	14
5.3 Liver resection	15
5.4 Postoperative course	16
6. SURGICAL TREATMENT OF LIVER METASTASES.....	17
6.1 Objectives	17
6.2 Materials and methods	17
6.3 Results	18
6.3.1 Primary malignancy, age, and gender	18
6.3.2 Colorectal carcinoma liver metastases	19
6.3.3 Neuroendocrine liver metastases	24
6.3.4 Noncolorectal, nonneuroendocrine liver metastases	24
6.4 Discussion and conclusion	26
ACKNOWLEDGEMENTS.....	29

REFERENCES: 30
BIOGRAPHY 37

SUMMARY

Surgical treatment of liver metastases

Gaja Tolić

Key words: liver, metastasis, hepatectomy, colorectal carcinoma, neuroendocrine tumor

Liver metastases (LM) are a heterogenous group of secondary neoplasms that originate from various primary sites but share a common pathway of metastasizing. From a surgical perspective, colorectal carcinoma (CRC) is the most significant tumor that disseminates to the liver, due to a high global burden of this disease, but also because of a significant potential for survival with a successful hepatic resection. Neuroendocrine tumors, and noncolorectal, nonneuroendocrine tumors also commonly disseminate to the liver and have potential for surgical treatment.

A retrospective study of patients who underwent hepatic resection of liver metastases was conducted at the Department of Surgery of the University Hospital Center Zagreb.

The goal of the study was to compare surgical strategies for patients with liver metastases who were treated at the University Hospital Center Zagreb from January 1st, 2017, until December 31st, 2021.

The highest proportion of liver resections (75,8%) was for colorectal cancer liver metastases. Patients were diagnosed with LM either metachronously or synchronously, and with a right- or left-sided primary tumor. Resection margins and the embryologic origin of the primary tumor demonstrated the clearest impact on survival, while resections of synchronous and metachronous LM showed comparable survival rates.

SAŽETAK

Kirurško liječenje metastatskih tumora jetre

Gaja Tolić

Ključne riječi: hepatektomija, jetra, kolorektalni karcinom, metastaza, neuroendokrini tumor

Metastaze u jetri su heterogena skupina sekundarnih neoplazmi koje potječu iz različitih primarnih sijela, ali imaju zajednički put metastaziranja. Iz kirurške perspektive, kolorektalni karcinom je najznačajniji tumor koji se širi u jetru, zbog velikog globalnog opterećenja ovom bolešću, ali i zbog značajnog potencijala za preživljavanje uz uspješnu resekciju jetre. Neuroendokrini tumori i ne-kolorektalni, ne-neuroendokrini tumori također se često šire u jetru i imaju potencijal za kirurško liječenje.

Na Klinici za kirurgiju KBC-a Zagreb provedena je retrospektivna studija pacijenata kojima je učinjena resekcija jetrenih metastaza.

Cilj istraživanja bio je usporediti kirurške strategije za pacijente s metastazama u jetri koji su liječeni u KBC-u Zagreb od 1. siječnja 2017. do 31. prosinca 2021.

Najveći udio resekcija jetre (75,8%) bio je zbog jetrenih metastaza kolorektalnog karcinoma. Pacijentima su metastaze na jetri dijagnosticirane metakrono ili sinkrono, te primarni tumor s desne ili lijeve strane. Resekcijski rubovi i embriološko podrijetlo primarnog tumora pokazali su najjasniji utjecaj na preživljenje, dok su resekcije sinkronih i metakronih metastaza pokazale usporedive stope preživljenja.

1. INTRODUCTION

Liver metastases (LM) are a heterogeneous group of secondary neoplasms that occur in the liver. They originate from various primary sites but share a common pathway of metastasizing due to the hematogenous spread through portal circulation. Portal circulation is the main venous drainage of the gastrointestinal system, which makes gastrointestinal malignancies the most frequent tumors to metastasize to the liver. From a surgical perspective, colorectal carcinoma (CRC) is the most significant tumor that disseminates to the liver, due to a high global burden of this disease, but also because of a significant potential for survival with a successful hepatic resection. Neuroendocrine tumors, pancreatic carcinoma, genitourinary tumors, breast cancer and melanoma are also some of the many malignancies that commonly disseminate to the liver and have potential for surgical treatment. (1,2)

2. COLORECTAL CANCER LIVER METASTASES (CRLM)

2.1 Epidemiology

Colorectal carcinoma is third most common malignancy diagnosed in men and second most common one for women, accounting for 10% of yearly cancer incidence and mortality globally.(3) Approximately 50% of CRC patients will be affected by liver metastases over the course of their illness. (2) They are more common in men and in individuals with a left-sided primary.(4,5) Based on the interval between primary tumor diagnosis and the detection of hepatic lesions, LM can be divided into synchronous or metachronous. Due to the lack of consensus on the exact time definition for metachronous diagnosis, data reported in the literature may vary. The proposed terminology by the EGOSLIM group is synchronous LM are metastases diagnosed at the time of diagnosis or surgery of the primary tumor and metachronous LM are diagnosed either within the 12 months of the primary diagnosis/surgery (early metachronous metastases) or more than 12 months after (late metachronous metastases). (6) 25% of CRC patients present with synchronous LM and up to 85% of metachronous LM occur within a year since the diagnosis of the primary. In 30% - 40% of patients, metastases are found only in the liver. (7–9)

2.2 Diagnosis and workup

LM can be diagnosed synchronously with the CRC, or metachronously, i.e., during treatment or follow-up of CRC. Symptomatic presentation of CRLM (pain, jaundice, ascites, weight loss, palpable mass) is generally considered a bad prognostic sign pointing to advanced malignant disease and these patients are rarely considered surgical candidates. However, due to diligent surveillance of CRC patients, they are often diagnosed with resectable metastases during follow-up, which gives them higher chances for survival. The carcinoembryonic antigen (CEA) serum values are measured every 3 to 6 months during the first 2 years since the primary diagnosis, and afterwards every 6 months until the 5-year mark, accompanied by the physical examination. If the metastatic disease is suspected, imaging is indicated. (1,2)

Computed tomography (CT) is the first choice in detecting hepatic, and potential extrahepatic metastases. The portal venous phase is the more reliable phase, with the detection rate for CRLM of 85%. The limitation of the CT is its inability to detect lesions smaller than 10mm, which makes magnetic resonance imaging (MRI) superior. MRI uses hepatocyte-specific contrast agents that are taken up by the hepatocytes, which are then observed as hyperintense, compared to metastases, which are hypointense. Positron emission tomography/computed tomography (PET-CT) is considered another accurate modality for CRLM detection but is also limited to lesions greater than 10mm. It is, however, found to be very accurate in detection of extrahepatic disease and in approximately 25% of patients course of the management changes due to the obtained results. Ultrasound is not a reliable pre-operative diagnostic tool, due to its low sensitivity of 64%. Intra-operative ultrasound (IOUS), on the other hand, has a well-established role in identifying new lesion and intraoperative planning. (1,10–15)

2.3 Role of chemotherapy in treatment of metastatic disease

The standard of systemic therapy for metastatic CRC has been 5-fluorouracil (5-FU), a fluoropyrimidine analogue, in combination with leucovorin, a thymidylate synthase inhibitor. With the addition of a platinum-based alkylating agent – oxaliplatin (FOLFOX), or a topoisomerase inhibitor – irinotecan (FOLFIRI) the response rates and PFS have increased, with a decrease in chemotherapy-induced toxicity. 5-FU

can be replaced with an orally administered capecitabine, a fluoropyrimidine antimetabolite. Biologic agents can be combined with these regimens, like monoclonal antibodies bevacizumab, cetuximab or panitumumab. Bevacizumab blocks the VEGF-A activity, while cetuximab and panitumumab block the pathway of EGFR. They have demonstrated benefit in prolonging survival and are frequently added to the FOLFOX/FOLFIRI regimens. (2,16–19)

Patients with untreated CRLM have median survival of 6 to 12 months, which increases to 22 months with chemotherapy alone. Metastasectomy without chemotherapy can yield 5-year survival of 40%, however, in 50% of patients will result in recurrence. Without the combination of liver resection and chemotherapy, chances of long-term survival are limited. A randomized control trial EORTC 40983, compared the outcomes of patients with metastatic CRC treated with chemotherapy and surgery versus surgery alone. Median overall survival (OS) of the surgery-only group was 54 months, which increased to 61 months when chemotherapy was included. The progression-free survival (PFS) was 28% and 36%, again in favor of the additional chemotherapeutic treatment. Chemotherapy was associated with a higher rate of postoperative complications, none of which increased mortality. (16,18–23)

As liver resection provides the only chance for cure, the goal is to maximize the chances of resection with systemic therapy. Patients with metachronous CRLM can be stratified according resectability into those with unresectable disease, those with resectable LM and patients with unresectable LM that could potentially be downsized and converted into resectable. (15)

For the unresectable group, it is important to consider their performance status and symptoms. Supportive care is an optimal choice for patients that are doing poorly and cannot tolerate active treatment. In others, symptom control and improvement of quality of life can be achieved with chemotherapy, and tumor shrinkage and prolongation of survival potentially as well. (15)

The up-front resectable patients can receive chemotherapy as adjuvant or neoadjuvant treatment and benefits of both approaches have been investigated. Neoadjuvant therapy presents with upsides in assessing tumor responsiveness to chemo and aiding in treatment strategy. Shrinking of the LM may increase the

chances of R0 resection and micro metastases may be eliminated. On the other hand, hepatotoxicity may interfere with surgical treatment. The EORTC 40983 trial showed an 8% increase in PFS in the group that received perioperative chemotherapy, compared to the surgery-only patients. Since significantly higher rate of complications was noticed (25% vs 16%), without a difference in the OS, neoadjuvant therapy is not routinely used in initially resectable patients. (15,23)

Adjuvant therapy, on the other hand, demonstrated an improved disease-free survival (DFS) of 33.5% at 5-year mark, compared to surgery-only group (26.7%), but without a difference in OS. Since the adjuvant therapy allows for a systemic therapy without surgical complications, it is a preferred choice over neoadjuvant therapy. (15,24)

Initially unresectable patients can be converted to resectability with chemotherapy and about 22% of them reach resectable status. For those patients, median OS is 45 months, with 19% alive and recurrence free. Downsizing regimens with FOLFIRI and FOLFOX have shown same results in efficiency. (15,25,26)

2.4 Surgical management of resectable metachronous LM

Historically, liver resection yielded 5-year survival rates between 20% and 40%. With the development of new chemotherapeutic options, patients undergoing liver resection can reach 5-year survival rates greater than 50%, and even up to 70% with solitary hepatic metastasis. Up to a quarter of these patients are considered cured. These numbers have demonstrated surgical treatment of LM as the only treatment with potential for cure, which has prompted increase in resection rates. (2) Defining resectability is approached from the clinical and technical aspect. (15) Lymph node-positive primary tumors, number and size of metastases, bilateral disease, high CEA levels, synchronous presentation, involved histologic margins and extrahepatic disease (EHD) have been considered poor prognostic factors. (1) The first five were combined into The Fong Clinical Risk Score (Table 2.1) to identify patients best suitable for surgery. Patients with a score up to 2 are considered good surgical candidates with chances of 5-year survival from 40% to 60%, while the patients with a higher score may be more suitable for chemotherapy. (2,15) Presence of extrahepatic disease, more than four metastases and inability to resect all disease were considered contraindications for resection, with only the last one still considered true today. (1) Inability of complete resection, i.e., positive resection margins, are

universally considered negative prognostic factor; however, the 1 cm width of the cancer-free margin has been replaced with a requirement of 1 mm, with no survival advantage being associated with additional width. The 1mm resection margin has demonstrated 5-year DFS of 33%. (27) In another study, R1 resections showed similar survival to the R0 group, proposing that the inability to achieve R0 resection be reconsidered as a contraindication for surgery and to accept R1 resection as appropriate in cases of lesions near structures that cannot be resected and for hepatic parenchyma preservation. (28)

Resection in cases with extrahepatic disease was traditionally not undertaken, but with newer systemic therapies has become possible. Portal lymph nodes and lung metastases have been associated with best survival rates and these patients require neoadjuvant chemotherapy to exclude fast-progressing patients who would not benefit from surgery. 5-year survival rates reach up to 30%, but recurrence develops in 84%-95% of patients, indicating that resection of EHD is usually not a curative treatment. (1,29–31)

Table 2.1 The Fong Clinical Risk Score

Criteria:		Risk
N° of lesions	>1	0-2 low 3-5 high
Size of the biggest lesion	>5 cm	
CEA	>200 ng/mL	
Disease-free interval (between primary tumor and LM diagnosis)	<12 months	
Lymph node-positive primary tumor	positive	

2.5 Management of synchronous CRLM

At the time of CRC diagnosis, 15% to 25% of patients are diagnosed with synchronous LM. (7) Many of them are considered to have unresectable disease. (6) For patients suitable for curative resection, the question is raised which site of the disease should the treatment start with, and whether the neoadjuvant chemotherapy

should precede the surgical procedure. Three strategies are available: the simultaneous approach or a staged approach where either the liver (liver-first) or the primary tumor (colorectal-first) is resected first, followed by a recovery period after which the opposite resection is done. (32)

Early resection of the primary tumor, i.e., the source of the metastases, is the argument in favor of the colorectal-first approach. Also, it reduces the risk of complications due to the primary tumor, like bleeding, obstruction, or perforation. Following the colorectal resection, patients usually undergo chemotherapy treatment, which provides an opportunity to select patients suitable for surgery and identify fast-progressing ones that would not benefit from a hepatic resection. (6,33,34) Since liver metastases are drivers of prognosis in CRC patients, liver-first approach advocates for prompt resection of LM, using the resectability window for a resection with curative intent. (35) three scenarios have been defined where liver-first approach is preferred. First, when an initially unresectable LM have been converted by a downsizing chemotherapy. If the primary tumor is asymptomatic and it seems like the opportunity window for resection is limited, it is proceeded with the hepatic resection. Second, in the case of operable LM and primary but with liver metastases that are life-threatening, due to the size, number, or location, and could become inoperable with delayed resection. Third scenario is specific to the primary tumor location and concerns rectal carcinoma with synchronous LM. In rectal cancer, which undergoes irradiation before resection, surgical procedure of the primary tumor is delayed for about 3 months. This offers a chance for LM to be resected significantly sooner, rather than wait until after the primary tumor resection. Liver- first and colorectal-first approaches have never been compared through a randomized control trial, but the retrospective studies have demonstrated similar long- and short-term outcomes. (15)

Due to the complexity and poor prognosis of the patients with synchronous CRLM, about two thirds of these patients complete both resections of the staged approach, which makes the simultaneous approach seem like the most appropriate for the OS. (36) It also requires only one operative procedure, one anesthetic induction, shorter recovery and hospital stay and lower costs of treatment. (37) Simultaneous resection of the primary combined with minor hepatectomy has demonstrated similar mortality and morbidity rates compared with minor hepatectomy alone. Major hepatectomy, however, has shown to increase mortality (8.3% vs 1.4%) and morbidity (36.1% vs

15.1%) when combined with colorectal resection, compared to the isolated major hepatectomy. (38) In line with these findings, a meta-analysis of 32 studies has shown that the synchronous LM group, which underwent hepatic resection, were found to have a lesser proportion of bilobar disease and fewer major resections were performed. Simultaneous resection can therefore be performed safely in wisely selected patients, specifically excluding major resections of more than three liver segments. (39)

2.6 Treatment of unresectable metastatic disease

Nonsurgical treatment options for truly unresectable patients include regional chemotherapy and ablation methods. Regional chemotherapy, i.e., hepatic arterial infusion (HAI), exploits the fact that LM derive blood supply largely from the hepatic artery. Compared to systemic chemotherapy, it showed prolonged survival from 20 to 24 months with improved physical condition of patients. Its role remains unclear due to a small number of randomized trials, and it has not been put into a routine use. (2,40)

Ablation therapies have a potential for similar benefits as non-anatomical resections but with less morbidity. They include radiofrequency ablation (RFA) and microwave ablation (MWA). RFA causes ionic agitation, denaturation, and coagulation of the target tissue via alternating electrical current. MWA destructs target tissue through heat generation with electromagnetic waves. Their effect is comparable, with MWA standing out as a method with lower recurrence rate. (15,41–44)

3. NEUROENDOCRINE TUMOR LIVER METASTASES (NETLM)

Neuroendocrine tumors (NETs) comprise a heterogeneous group of gastroenteropancreatic tumors including carcinoids, pancreatic endocrine and other NETs. (2) Most commonly, they are found in the gastrointestinal tract – termed carcinoid tumors, with over 40% occurring in the small bowel. Rarely, they may originate from the lungs, thyroid gland, or skin. (45) Usually, NETs affect patients in their sixties, but it is not a rule. (46)

3.1 NET Classification

According to WHO, they are classified in three categories: low-, intermediate- or high-grade, with the former two considered slow growing and less malignant than the later. The NETs found in the gastrointestinal tract are mostly low- or intermediate-grade, except for the jejunal tumors, which are usually high-grade and more aggressive. (46)

Based on the embryologic origin, NETs may arise from the foregut, midgut, or hindgut. Site of embryologic origin is considered the most important factor in prognosis of gastrointestinal NETs. Foregut tumors rarely metastasize, while the tumors of midgut origin tend to follow a more aggressive course associated with poorer outcomes. Hindgut NETs comprise a group of usually incidentally discovered tumors of benign nature and rare metastatic spread. (46)

3.2 NET liver metastases

3.2.1 Epidemiology

More than one-third of NET patients present with metastatic disease, with liver being the most affected distant site.(47,48) Metastatic disease is a negative prognostic factor, with a 4-fold mortality risk increase compared to the risk with localized disease alone. (47)

3.2.2 Presentation

Depending on whether they secrete hormones or not, NETs can be functional or nonfunctional, respectively. Carcinoid tumors primarily secrete serotonin, while the pancreatic endocrine tumors elaborate cell-specific hormones, e.g., gastrin, insulin, or glucagon. One-third of tumors remains nonfunctional, while the other, functional, tumors manifest with symptoms characteristic for the hormone they secrete, as represented in table 3.1.(2) Because bioactive products released by functional NETs get metabolized by the liver and often do not get a chance to induce symptoms, presence of symptoms may indicate hepatic involvement. In that instant, secreted substances bypass hepatic inactivation and the clinical picture points to liver metastases or high tumor burden.(49)

Table 3.1 Hormones and corresponding symptoms of functional NETs. (49,50)

NET type	Hormone	Symptoms
Carcinoid	Serotonin Histamine Kallikrein Tachykinins	Carcinoid syndrome: diarrhea, flushing, wheezing.
Pancreatic	Gastrin Insulin VIP Glucagon Somatostatin ACTH PTHrP	Zollinger-Ellison syndrome Hypoglycemia Verner-Morrison syndrome Hyperglycemia, stomatitis, weight loss Diabetes, steatorrhea, diarrhea, cholelithiasis Cushing syndrome Severe hypercalcemia

3.2.3 Diagnosis

Main diagnostic modalities for NETLM include biochemical testing, imaging, and pathological examination.(51)

In symptomatic patients, 24-hour urine collection can be performed and tested for serotonin metabolites. For monitoring of disease progression, recurrence or response to treatment, blood tumor markers are a preferred method. The most used one is chromogranin A, but pancreastatin, neurokinin A, pancreatic polypeptide and substance P are also useful.(52,53)

Since NETs commonly express somatostatin receptors, radiolabeled somatostatin analogues have been used for functional imaging: ¹¹¹indium pentetreotide scintigraphy (Octreoscan) and ⁶⁸gallium PET-CT (DOTATATE, DOTATOC or DOTANOC). (1) These radiolabeled analogues are taken up by the somatostatin receptors, aiding in disease staging.(51) CT scan of the chest, abdomen and pelvis

should be done for every patient to establish extent of the disease (1); however, MRI has shown to be more sensitive for hepatic lesions, due to its high contrast resolution. (54,55) Sensitivities for MRI, CT, Octreoscan and ⁶⁸gallium PET-CT for NETLM are 95%, 79%, 49% and 81%, respectively. (54,56)

Confirmation of the diagnosis is made by a pathological examination of hepatic tissue, after a biopsy or resection. NET liver metastases are distinguished from other neoplasms by immunohistochemistry (IHC) staining for NET characteristic markers (synaptophysin and chromogranin A) and receptors (keratin and somatostatin). After a metastasis is proven to be of a neuroendocrine primary, grading is determined by a Ki-67 proliferative index quantification. In case of an unknown primary site, an extended IHC panels or gene expression classifiers can differentiate between mid-gut or pancreatic primary location of the NET by staining positive for either CDX2 or PAX6 and ISL1, respectively. (57–59)

3.2.4 Treatment

When determining an appropriate therapy for metastatic NETs, several key points should be taken into consideration. NETs are indolent, slow-growing tumors and as such often warrant long-term survival even without treatment. On the other hand, when functional, these tumors can cause severe symptoms with debilitating sequelae. Therefore, the treatment of choice should be delivered with minimal risk of morbidity, with the aim of improving the quality of life. (1) Three modes of treatment of NETLM are possible: surgical, ablation, or systemic.

Hepatic resection is first line of treatment in patients with a satisfactory performance status. In complete resections, five-year survival rate of up to 75% has been steadily observed. Cytoreductive surgery is justified if more than 90% of the tumor load can be removed and in that case symptom relief can be expected in up to 95% of patients. Wedge resections and enucleations are acceptable techniques when operating on these tumors and wide margins are not a requisite. (1,51,60,61)

In patients who are not candidates for surgery systemic and liver-directed therapies can alleviate the symptoms and improve OS. Somatostatin analogues (SSAs) are a logical choice, since 90% of NETs have receptors for somatostatin or its analogue, octreotide. They delay progression of the disease by halting tumor growth in patients

with advanced but unresectable disease. Response to the drug can last for years, but most patients do become refractory to the effect at some point. Following SSA therapy, two molecularly targeted therapy drugs have shown promising results, everolimus, a mammalian target of rapamycin (mTOR) inhibitor, and sunitinib, a VEGF and EGFR inhibitor. They have both demonstrated improved PFS in metastatic disease. (2,51,62)

4. NONCOLORECTAL, NONNEUROENDOCRINE LIVER METASTASES

This group comprises LM from all other primary malignancies, e.g., breast and lung cancer, melanoma (cutaneous or uveal), upper gastrointestinal carcinomas (stomach, pancreas, or esophagus) or various genitourinary malignancies (bladder, prostate, cervical, uterine, ovarian, testicular). Even though these tumors are of different histopathology, research so far has tried to group them together and collect data that could give insight in their optimal medical and surgical management. (1,2)

Liver resection in NCNNLM is not the standard of care, but in precisely selected patients can improve OS. General approach is similar to the CRLM. Poor prognostic factors that should be considered in selection of surgical candidates include presence of extrahepatic disease, multiple and large tumors, and short disease-free interval. Chemotherapy should be a first-line treatment for patients with liver-only metastases, aiming to select patients with slowly progressing disease, who will benefit most from a hepatic resection and to potentially convert inoperable patients. Patients with upper gastrointestinal tumors have demonstrated least benefit from liver resection, while the genitourinary tumors have the best prognosis. Melanoma and breast cancer patients usually present with extrahepatic disease, but when they do not, resection should be considered. Overall, liver resection for this group of patients is highly case-specific and should be applied in most favorable patients. (1,2,63)

5. LIVER RESECTION

5.1 Anatomy of the liver

Liver is found beneath the right dome of the diaphragm. The inferior border runs nearly uniformly along the right costal margin, diagonally, through the epigastrium, until the left midclavicular line. It is an intraperitoneal organ, completely covered by the visceral peritoneum, except in its bare area. The bare area lies on the superior part of the liver, near the inferior vena cava (IVC), and it is here that the liver connects to the diaphragm, which is not covered by peritoneum. When dissected from its attachments, bare area is revealed as reflections of the visceral into the parietal peritoneum. It is demarcated by the coronary ligament and the right and left triangular ligaments on each side. Coronary ligaments extend anteriorly into a continuum with the falciform ligament. Falciform ligament attaches liver to the parietal peritoneum of the anterior abdominal wall. It divides the liver into the right and left lobes. The hepatoduodenal and hepatogastric ligaments connect it to the duodenum and the lesser curvature of the stomach, respectively. The visceral surface of the liver runs from posterosuperior down to the anteroinferior part of the organ. It is adjacent to the organs that lie in the proximity. Here, porta hepatis forms the entryway for the portal veins, branches of the hepatic artery proper, and the nerves, as well as the exit for the right and left hepatic ducts and lymphatic vessels. Round ligament and ligamentum venosum (containing obliterated umbilical vein and ductus venosus) run on the left of the porta hepatis, and on the right lies the gallbladder in its fossa. (64)

When performing liver resection, it is crucial for the surgeon to be familiar with the functional and surgical anatomy of the liver. The understanding of the hepatic vascular supply and functionality has led to the development of functional liver anatomy, and these principles became the most widely accepted. Couinaud's description of eight segments of the liver is based on the surface landmarks, but also the location of the three main hepatic veins and the bifurcation of the portal pedicle.

By this principle, the right and the left halves are divided by a plane, which runs between the IVC and the middle hepatic vein. The left half (or the left liver) is now formed by the segments II, III and IV, while the segments V, VI, VII and VIII form the right half (the right liver). The caudate lobe, or segment I, is found posterior to the portal pedicle, anterior to the IVC. Each segment has its pedicle (or portal triad), composed of a hepatic artery, portal vein and a bile duct. The left, middle and right hepatic veins form hepatic scissurae and further divide segments into sectors, based on their venous outflow. The main scissure (containing the middle hepatic vein) runs anteroposteriorly, along the Cantlie line and divides the liver into hemilivers. The right scissure, with the right hepatic vein, divides the right hemiliver into anterior (segments V and VIII) and posterior (segments VI and VII) sectors. The left scissure, and the corresponding hepatic vein, splits the left hemiliver into anterior (segments III and IV) and posterior (segment II) sectors. The left scissura runs posterior to the ligamentum teres. Ligamentum teres contains the remnant of the umbilical vein and runs into the umbilical fissure, contiguous with the falciform ligament. The left, right and middle hepatic veins drain into the IVC. The portal vein runs through the hepatoduodenal ligament to the hilum of the liver, where it branches into left and right portal branches. The left branch runs along the segment IV and into the umbilical fissure. There it gives off branches for segments II and III and posterior branches for the caudate lobe. The right portal branch splits into anterior and posterior sectoral branches. The portal vein accounts for about 75% of inflow to the liver and 50% - 70% of its oxygen requirements. The common hepatic artery originates from the celiac trunk, which is a direct branch off the aorta. Before it reaches the hilum, it gives off the gastroduodenal artery and becomes the proper hepatic artery. At the hilum it branches into right and left hepatic arteries. The left branch runs along the left portal branch and supplies the same segments. The right branch runs through the Calot triangle, gives off the cystic artery, and then continues to supply the liver parenchyma. The right and left hepatic ducts enter the liver at the hilum with their corresponding portal vein and hepatic artery and form portal triads, i.e., portal pedicles. (1,2)

5.2 Preoperative assessment

Sufficient future liver remnant (FLR) must be secured before a hepatic resection. Assessment of liver function is therefore a critical step in preoperative planning. Up to 75% of liver tissue can be resected in patients with normal hepatic parenchyma, assuming the proper hepatic arterial and portal venous inflow, adequate venous outflow and biliary drainage have been secured. Two strategies to predict hepatic reserve have been applied the most. First, the Child-Pugh score estimates synthetic (albumin, prothrombin time, ascites), excretory (total bilirubin) and metabolic (mental status changes and retention of ammonia) functions of the liver. Second, based on the 3D reconstruction of CT and MRI scans, volumetric measurements are done and FLR is predicted. (2,65,66)

In the case of inadequate FLR, portal vein embolization (PVE) can be done to the ipsilateral branch of the portal vein. It causes atrophy of the downstream liver segments and, as a compensatory response, hypertrophy of the FLR. The adequate hepatic response takes 4 to 6 weeks, after which resection of the diseased part of the liver can take place. (2,33,67,68)

A more rapid hypertrophy of FLR is achieved with the associating liver partition and portal vein ligation (ALPPS) technique. In a two-staged procedure, portal vein branch is ligated, and liver parenchyma divided along the falciform ligament. Additionally, bridging veins between hemilivers are ligated as well, truly isolating FLR. The more extensive separation of the liver tissue produces a more rapid hypertrophy compared to PVE. This way hepatic response takes one to two weeks, followed by a resection. While some support the faster approach to achieving the FLR and completing resection, ALPPS has been reported to have complication rates of up to 36%, highlighting the need for better patient selection criteria, and keeping PVE as the preferred method. (2,15–19,69,70)

The newer method for achieving an adequate FLR is liver venous deprivation (LVD). Considered a 'radiological ALPPS', it is a percutaneous procedure in which both portal and hepatic vein are embolized, and hypertrophy of FLR is achieved.

Advantages of this procedure have been demonstrated in a faster regeneration time (as fast as 7 days) and less complications than with ALPPS. A better gain of function was observed in a low rate of post-operative liver failure as well, but randomized control trials are still pending. (71,72)

Another thing that requires preoperative attention is chemotherapy-induced hepatotoxicity. Patients undergoing neoadjuvant chemotherapy, as can be the case with CRC patients, may present with steatosis, steato-hepatitis, or sinusoidal obstruction syndrome. Irinotecan, 5-FU and oxaliplatin are the agents commonly associated with hepatotoxicity. These agents may decrease metabolic function of the liver, which means a bigger FLR for a sufficient liver function will be required. Compared to the 25% necessary in patients with a healthy liver, those with a chronic liver disease without cirrhosis need FLR of 30%, and patients with cirrhosis of minimum 40%. (2,15,73,74)

5.3 Liver resection

Common liver resections have been classified in several ways (Table 5.1). The 2000 Brisbane consensus is the most widely used and is demonstrated in table together with the Couinaud's nomenclature of the most common liver resections. Additionally, resections of single or double segment can be referred to numerically. (1,2)

Liver resection is commonly done as a laparotomy, usually via a right subcostal incision. Patient is placed in a Trendelenburg position and central venous pressure maintained lower than 5 mmHg. The most common approach involves mobilization of the liver by division of the triangular ligament and dividing the liver from the diaphragm. Division of the vena cava is frequently also required. Inflow control is then achieved by dissecting the hilum and controlling the portal vein and hepatic artery branches to the half of the liver being resected. Vessels are ligated or divided by staplers. Bile duct is carefully divided, trying to minimize the complication of biliary injury and bile leaks. Alternatively, inflow pedicles of specific segments can be divided during parenchymal transection, as they are approached. To avoid hemorrhage, intermittent portal occlusion is done by clamping the hepatoduodenal ligament with the portal triad. This technique is called the Pringle maneuver and is

done with 10–20-minute intervals with 3-minute breaks of established blood flow. Hepatic vein is divided extrahepatically. Parenchymal transection can be done with a variety of techniques, from clamp-crushing to ultrasonic irrigation or radiofrequency coagulation. The goal is to dissect intrahepatic tissue while controlling blood loss and minimizing FLR injury. (1,2)

Table 5.1 Nomenclature of the most performed liver resections (1)

Segments	Brisbane 2000	Couinaud
II-IV	Left hemihepatectomy	Left hepatectomy
V-VIII	Right hemihepatectomy	Right hepatectomy
V-VIII and IV	Right trisectionectomy	Extended right hepatectomy
II-IV and V and VIII	Left trisectionectomy	Extended left hepatectomy
II, III	Left lateral sectionectomy	Left lobectomy
VI, VII	Right posterior sectionectomy	
V, VIII	Right anterior sectionectomy	
I	Caudate resection	

5.4 Postoperative course

Liver resection methods have evolved and with that postoperative mortality has dropped to less than 5% for metastatic disease. Characteristic phenomena for early postoperative phase are transient hyperbilirubinemia (peaks around third postoperative day), elevation of serum transaminase, hypophosphatemia, and prolonged international normalized ratio (INR). These changes are driven by the loss of hepatic parenchyma and resolve as the liver remnant regenerates. (2,30)

Complications associated with the liver resection depend on the type of surgery and the preoperative state of the liver tissue. Intraabdominal collections occur commonly along the transection line. Progressive and refractory postoperative hepatic failure (POHF) is one of the most severe complications that can occur. It has been noted in 1.2% to 32% of cases and has an associated mortality of up to 2.8%. It can happen soon after the surgery or after several weeks and may develop suddenly or progress over weeks to months. (2,29,75)

6. SURGICAL TREATMENT OF LIVER METASTASES

6.1 Objectives

The goal of the study was to describe surgical strategies for patients with liver metastases who were treated at the University Hospital Center Zagreb from 2017 to 2021.

6.2 Materials and methods

A retrospective study of patients who underwent hepatic resection of liver metastases was conducted at the Department of Surgery of the University Hospital Center Zagreb. The data was collected from the Hospital information system (Croatian: Bolnički informacijski sustav – BIS). Date of death was obtained from the Croatian National Cancer Registry for the patients that are not still alive. Patients who received surgical treatment between January 1st, 2017, until December 31st, 2021, were included. Patients which were surgically treated in this period for the recurrent metastases were excluded. 128 patients were included in total.

For all patients, demographic and clinicopathological data were collected, including age, sex, date of surgery and date of death (if it has occurred) and location of primary malignancy.

They were further stratified based on the primary malignancy into CRC, NET, and NCNN liver metastases patients.

For CRC patients, metastases were grouped into synchronous and metachronous. In synchronous metastases group, simultaneous and staged approach were compared. For metachronous LM disease free interval (DFI) was calculated. Extrahepatic

disease was analyzed, as was the status of FLR before surgery (and subsequent ALPPS procedure). Minor vs. major resections and status of resection margins (R0/R1) were also considered. Finally, overall survival for 1, 3 and 5 years were calculated.

For NET and NCNN liver metastases, primary tumor location and overall survival were analysed.

6.3 Results

6.3.1 Primary malignancy, age, and gender

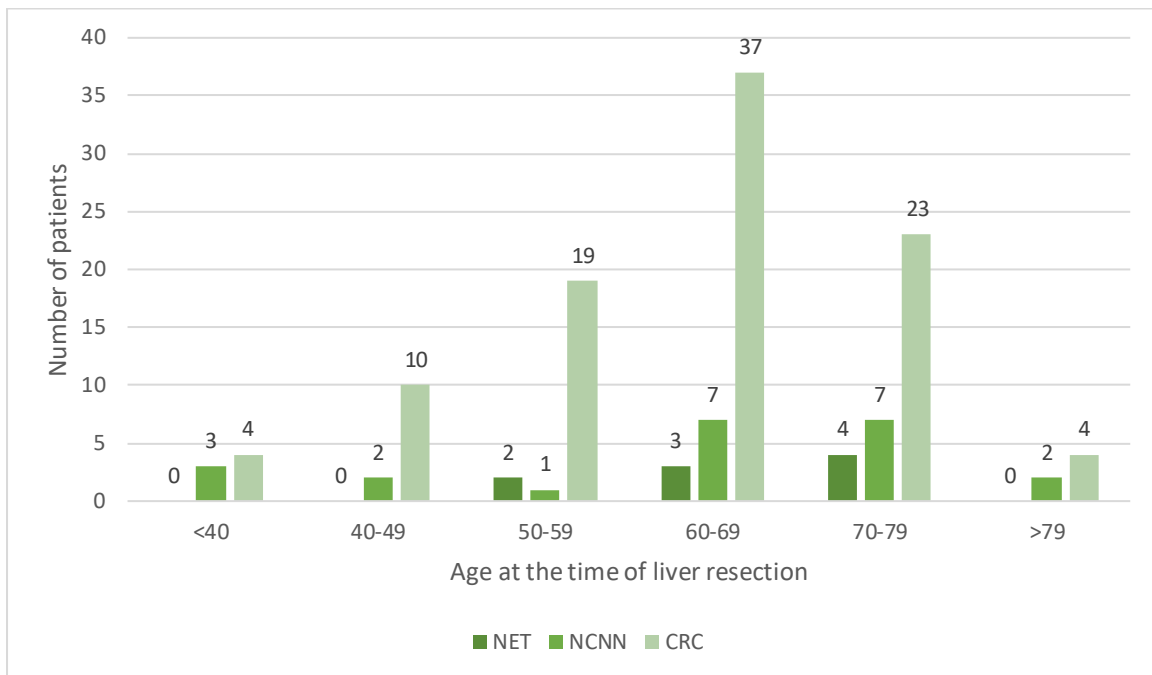
128 were included in the study. Of those, 97 (75,8%) are CRC patients, 9 (7%) are NET patients, and the leftover 22 (17,2%) patients belong to the noncolorectal, nonneuroendocrine group of patients with various primary tumors. 66 patients are male and 62 are female.

Of the 97 CRC patients, 49,5% are women and 50,5% men, and the median age is 66. Amongst the NET patients, 66,6% are men and 33,3% women. Median age is 66. In the NCNN group, there is an even distribution of men and women (50% each), and the median age is 68. A more detailed gender and age distribution is represented in Table 6.1 and Figure 6.1.

Table 6.1: Age and gender distribution of LM patients

		N (%)	Median age (range)
CRC	F	48 (49,5)	64 (37 – 80)
	M	49 (50,5)	67 (21 – 88)
	Total	97	66 (21 – 88)
NET	F	3 (33,3)	70 (64 - 71)
	M	6 (66,6)	66 (56 - 79)
	Total	9	66 (56 - 79)
NCNN	F	11 (50)	65 (35 – 80)
	M	11 (50)	69 (35 – 79)
	Total	22	68 (35 – 80)

Figure 6.1: Age distribution of LM patients



6.3.2 Colorectal carcinoma liver metastases

A total of 97 patients were surgically treated for CRCLM in the stated period. In 54 patients (55,7%) LM were diagnosed synchronously and in 43 (44,3%) metachronously to the primary tumor. Men and women are equally distributed in both categories, and age distribution is not significantly different either. The highest proportion of patients was diagnosed (and operated) in their sixties (38,1%). The youngest patient treated was only 21 and the oldest was 88.

6.3.2.1 Primary tumor location

Based on the embryologic origin of the primary tumor, left-sided tumors were found significantly more often (74,2% vs. 25,8%) than the right-sided. Sigmoid colon was the most common anatomical site (42,3), followed by the rectum (28,8%).

Synchronous and metachronous LM diagnosis was not influenced by the anatomical site of the primary but there was a slightly higher proportion of right-sided tumor in synchronous LM, compared to metachronous (29,6% vs. 11,6%).

Table 6.2

	All LM (97)	Synchronous LM (54)	Metachronous LM (43)
Sex ratio (M: F)	49:48	27:27	22:21
Age category			
<50	14 (14,4)	8 (14,8)	6 (14)
51 – 65	33 (34)	18 (33,3)	15 (34,9)
66 – 80	46 (47,4)	25 (46,3)	21 (48,8)
>80	4 (4,2)	3 (5,6)	1 (2,3)
Primary tumor location			
Right-sided	21 (21,6)	16 (29,6)	5 (11,6)
Left-sided	76 (78,4)	38 (70,4)	38 (88,4)
Primary tumor location			
Caecum/ ascending colon	15 (15,5)	13 (24,1)	2 (4,6)
Transverse colon	10 (10,3)	3 (5,6)	7 (16,3)
Descending	3 (3,1)	2 (3,7)	1 (2,3)
Sigmoid colon	41 (42,3)	24 (44,4)	17 (39,5)
Rectum	28 (28,8)	12 (22,2)	16 (37,2)

6.3.2.2 Disease free interval for metachronous LM

44,3% of patients were surgically treated for metachronous LM. Disease free interval (DFI) was calculated for these patients as the interval between the treatment of the primary tumor and the diagnosis of LM. The range of DFI is 3 – 308 months. 46,5% of patients were diagnosed with early metachronous LM, i.e., within 12 months since the primary and 76,7% of LM occurred within 3 years. Only 5 patients were disease free for longer than 5 years, with the longest DFI being 308 months for a patient treated for CRC in 1993.

6.3.2.3 Extrahepatic disease

Extrahepatic disease was found in 18,6% patients. 8 (14,8%) were synchronous and 10 (23,3%) were metachronous LM patients. Distant lymph node involvement was present in 8,2% of all patients and lung metastases occurred in 4,1%. Peritoneum was affected in 6,9% of patients with metachronous LM. One patient had LN and lung metastases. One had adrenal gland and LN metastases and one had a metastatic ovarian involvement. In one patient spleen and small intestine metastases were found. 1 peritoneal and one lymph node (synchronous LM) involvement were of a right-sided primary tumor origin. Additionally, one patient has an esophageal carcinoma simultaneously with the CRCLM diagnosis.

Table 6.3

Site of metastases	Synchronous LM	Metachronous LM
Distant lymph nodes (LN)	4	4
Lungs	4	1
Peritoneum	-	3
Adrenal gland	-	1
Ovary	-	1
Small intestine	-	1
Spleen	-	1

6.3.2.4 Future liver remnant, major vs. minor resections, resection margins and postoperative complications

In 4 patients FLR was deemed inadequate and ALPPS was performed to secure sufficient liver parenchyma after resection. 3 of the 4 patients experienced postoperative complications. One had fever, one experienced bleeding at the resection site, bile leak, fever, ascites, and liver failure. The last patient developed a subphrenic abscess with ascites and hepatic insufficiency, and subsequently died from the complications.

Minor resections of less than 3 segments were more common across all categories. Major resection was performed in 25,8% of all patients, 32,6% of metachronous LM resections and 20,4% of synchronous LM resections. Synchronous LM were resected

simultaneously with the primary tumor in 72,2% of patients, and the rest (27,8%) received a staged, colon-first, approach. Major resections amongst the synchronous LM were significantly more common in the staged approach, 33,3% versus 15,4%.

R0 resection margin was obtained in 62,9% of patients, in 68,5% of synchronous LM and 55,8% of metachronous LM. There were no significant differences between the two treatment approaches of synchronous LM (69,2% vs. 66,6%). One patient received a R2 resection and for 2 patients no data was available.

Table 6.5

	Total (97)	Metachronous LM (43)	Synchronous LM		
			Simultaneous approach (39)	Colon – first approach (15)	Total (54)
Type of resection					
Minor (<3 segments)	72 (74,2)	29 (67,4)	33 (84,6)	10 (66,6)	43 (79,6)
Major (>3 seg)	25 (25,8)	14 (32,6)	6 (15,4)	5 (33,3)	11 (20,4)
ALPPS	4 (4,1)	1 (2,3)	3 (7,8)	0 (0)	3 (5,6)
Resection margins					
R0	61 (62,9)	24 (55,8)	27 (69,2)	10 (66,6)	37 (68,5)
R1	33 (34)	17 (39,5)	11 (28,2)	5 (33,3)	16 (29,6)
R2/unclear	3 (3,1)	2 (4,7)	1 (2,6)	0 (0)	1 (1,9)

6.3.2.6 Overall survival

Survival at 1-, 3- and 5-year marks was calculated. For 2 patients data was not available because they are not Croatian citizens. 1-year survival was calculated for all patients. 3-year survival was calculated for patients resected until April of 2020; 51 patients total. And 5-year survival was obtained for those operated until April of 2018, i.e., for 18 patients.

Cumulative survival at 1-year was 87,4%, but it fell to 33,3% at 5-years and was comparable for both metachronous and synchronous LM groups at each mark.

Simultaneous and staged approach to synchronous LM was comparable at 1-year (87,2% vs. 85,7%) but differed significantly at 5 years (42,9% vs. 0%).

Resection margins demonstrated a significant difference in survival at 3- and 5-years. OS at 1-year is comparable for R0 and R1 resections but differs at 3-year (59,4% vs. 47,8%) and 5-year (37,5% vs. 22,2%) marks in favor of R0 resection.

Survival of right-sided CRCLM patients was slightly better after 1 (90,5% vs. 86,5%) and 3 years (53,8% vs. 52,3%) but was lower after 5 years (25% vs. 33,3%).

Table 6.6 Overall survival

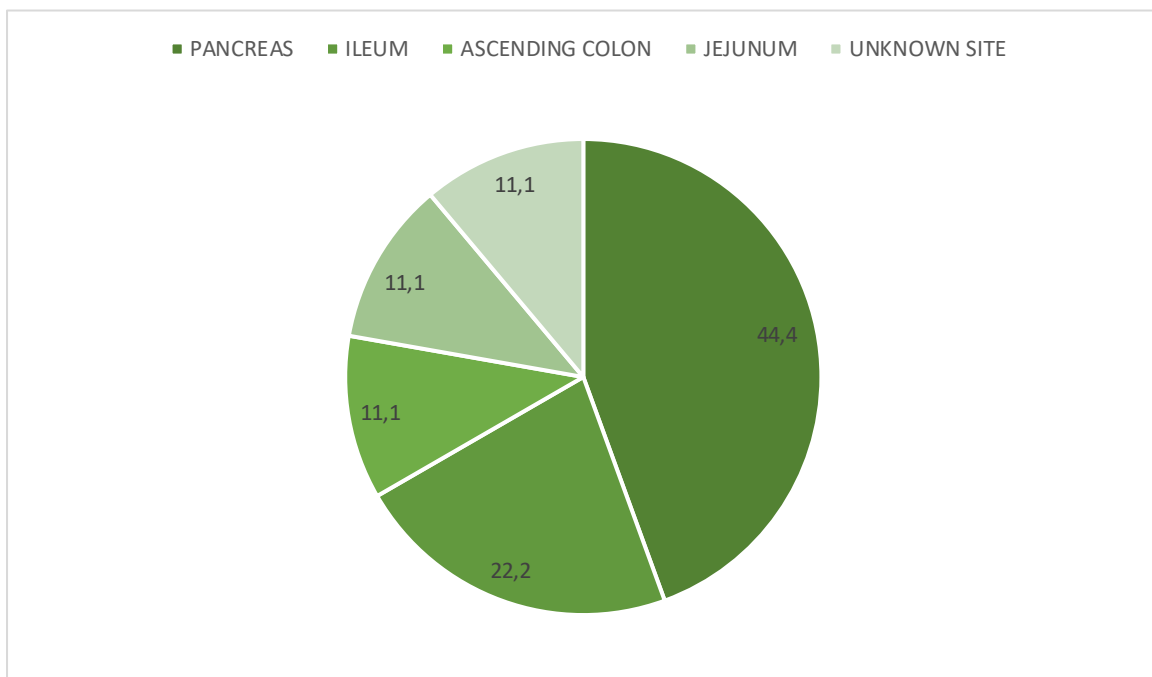
	1 - year	3 - years	5 - years
All (95)	83/95 (87,4)	30/51 (58,8)	6/18 (33,3)
Metachronous (42)	37/42 (88,1)	13/25 (52)	3/9 (33,3)
Synchronous (53)	46/53 (86,8)	17/31 (54,8)	3/9 (33,3)
Simultaneous app. (39)	34/39 (87,2)	14/25 (56)	3/7 (42,9)
Colon – first app. (14)	12/14 (85,7)	3/6 (50)	0/2 (0)
R0 (59)	50/59 (84,7)	19/32 (59,4)	3/8 (37,5)
Synchronous	30/36 (83,3)	10/19 (52,6)	1/4 (25)
Metachronous	20/23 (86,9)	9/13 (69,2)	2/4 (50)
R1 (33)	30/34 (88,2)	11/23 (47,8)	2/9 (22,2)
Synchronous	16/17 (94,1)	7/12 (58,3)	1/4 (25)
Metachronous	14/17 (82,4)	4/11 (36,4)	1/5 (20)
Right-sided	19/21 (90,5)	7/13 (53,8)	1/4 (25)
Left-sided	64/74 (86,5)	23/44 (52,3)	5/15 (33,3)

6.3.3 Neuroendocrine liver metastases

9 patients underwent liver resection due to LM of a neuroendocrine tumor during this period. Location of the primary tumor was pancreas in 4 patients (44,4%), followed by the ileum in 2 patients (22,2%). Ascending colon and jejunum were each the primary site in one patient (11,1%), and in one patient the primary site was unknown (11,1%).

88,9% of patients (8/9) reached the 1-year mark, and at 3- and 5-years survival is 100%

Figure 6.2: Primary sites of the NETs



6.3.4 Noncolorectal, nonneuroendocrine liver metastases

Twenty-two patients underwent liver resection due to NCNNLM during this period.

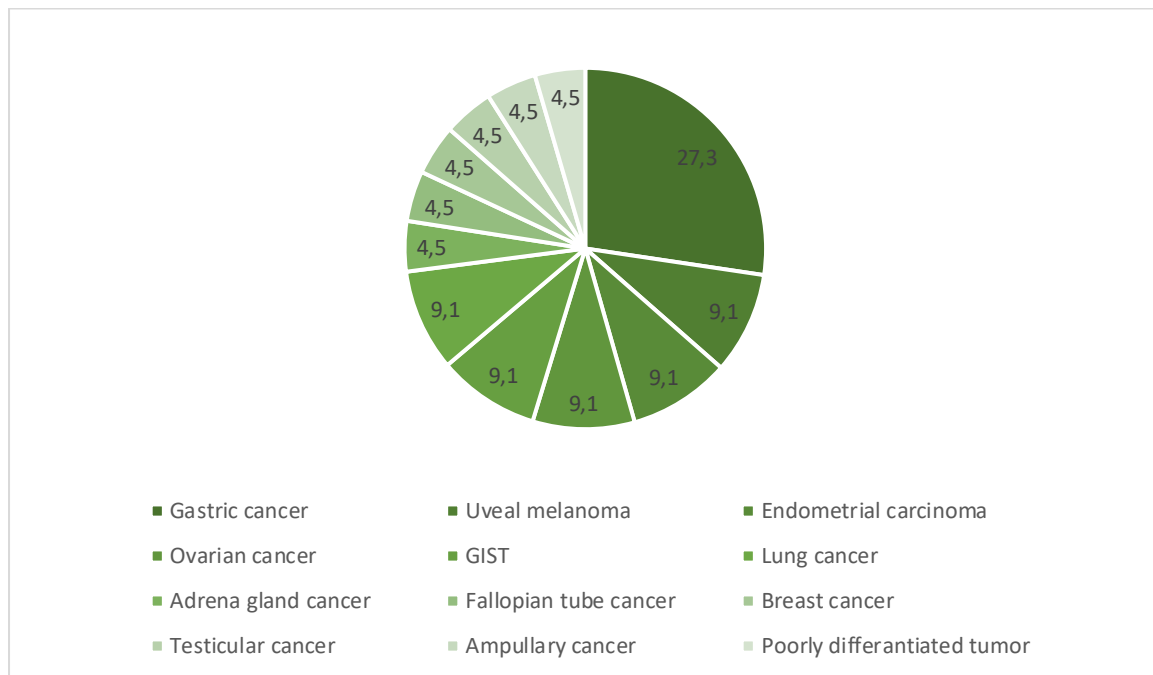
27,3% of patients suffered from gastric cancer, followed by uveal melanoma, endometrial carcinoma, ovarian and lung cancer, and GIST (9,1% each). Gastric cancer patients were all diagnosed with synchronous metastases. For the metachronous metastases DFI was 2 – 97 months (median 32). The DFI of 97 months was observed in a uveal melanoma patient, and of 2 months in a woman with endometrial carcinoma.

1-, 3- and 5-years survivals are 72,7%, 42,9% and 0%.

Table 6.7 NCNNLM survival per primary malignancy

	Total	1-year survival	3-year survival	5-year survival
Gastric cancer	6	3/6	0/3	0/3
Uveal melanoma	2	2/2	1/2	0/2
Endometrial carcinoma	2	1/2	1/2	0/1
GIST	2	2/2	2/2	-
Ovarian cancer	2	2/2	1/2	-
Lung cancer	2	2/2	1/1	-
Adrenal gland cancer	1	1/1	-	-
Fallopian tube cancer	1	0/1	0/1	0/1
Breast cancer	1	1/1	-	-
Testicular cancer	1	1/1	0/1	0/1
Ampullary cancer	1	1/1	-	-
Poorly differentiated tumor	1	0/1	x	x
TOTAL	22	16/22 (72,7%)	6/14 (42,9%)	0/8 (0%)

Figure 6.3: NCNNLM patients' primary tumor distribution



6.4 Discussion and conclusion

This retrospective study included 128 patients hospitalized and surgically treated at the University Hospital Center Zagreb for liver metastases in the period between January 1st, 2017, and December 31st, 2021. As expected, the highest proportion of liver resections (75,8%) was for colorectal cancer liver metastases.

For CRC patients, 47,4% of them were in the higher age category (66 – 80 years) and CRCLM occurred slightly more (51,6%) in men. 55,7% of LM were synchronous and 44,3% metachronous. LM were significantly more from a left-sided primary tumor (74,2%), which is in accordance with literature. (4,5,15) Synchronous and metachronous LM diagnosis were both more commonly left-sided, but there was an increased proportion of right-sided primaries among the synchronous LM (29,6% vs. 11,6), which could connect a more extensive metastatic disease with a delay in diagnosis, characteristic for a right-sided CRC. (4,76,77)

Contrary to the previous reports (4,78,79), here was demonstrated a slightly better survival of right-sided cancer patients at 1- and 3-years, but worse at 5-years.

However, LM from left-sided tumors were significantly more commonly resected (78,4%) as has been reported before. This is because right-sided LM patients usually

present with the disease later, are older and have more comorbidities – all factors that commonly exclude them as surgical candidates. (4,77,80,81)

Extrahepatic disease was most commonly found in distant lymph nodes and lungs. Lung metastases were more often diagnosed with synchronous (80%), rather than metachronous LM, and they were exclusively diagnosed in patients with left-sided primary tumors, as is the case in the study from Sweden. It differs, however, when comparing peritoneal metastases. According to the Swedish study, peritoneal involvement is more common for right-sided tumors, while our results demonstrate 66,7% of them to be of the left-sided origin. (4)

4 patients underwent ALPPS procedure and 74,2% patients underwent minor resections. Major resections were more common in metachronous LM resections (32,6% vs. 20,4%) and staged resections of synchronous LM (33,3% vs. 15,4%). They are avoided in simultaneous resection, as they have shown to increase morbidity and mortality when combined with primary tumor resection. (15,82,83)

In 62,9% of patients, R0 resection was done and 34% patients received R1 resection. A difference in survival was demonstrated at 3- and 5-years, in favor of R0 resection (59,4% vs 47,8% and 37,5% vs 22,2%, respectively), which is in accordance with a consensus that R1 resections are a negative prognostic factor for CRCLM patients. (84)

Overall survival at 1-year was 87,4% and it decreased to 33,3% at 5-years. Metachronous and synchronous LM had comparable survival outcomes but there was a significant difference in survival between simultaneous and staged approach of synchronous LM resection. Simultaneous approach was shown to be a significantly more favorable (42,9% vs. 0%) approach, which is not similar to a study from Sweden, which demonstrated no differences in survivals. This disparity may be attributed to a small sample of patients at 5 years. (32)

Finally, a small analysis of NETLM and NCNNLM was done, 9 and 22 patients, respectively. For NETLM, pancreas was the most common site of a primary tumor, and the 5-years survival was 100%. For NCNNLM patients, most common primary malignancy was gastric cancer and, opposite to the NETLM patients, 5-year survival was 0%.

Overall, CRCLM patients show better survival outcomes when liver resection is performed. Different treatment strategies and the heterogeneity of patients require a multi-disciplinary approach involving surgery, oncology, radiology, and pathology, all of which need to remain up to date with the contemporary discoveries of this fast-evolving field.

ACKNOWLEDGEMENTS

First and foremost, I would like to thank my mentor, doc.dr.sc. Igor Petrović, for his trust and guidance during the process of writing this thesis. Also, I would like to thank dr. Jurica Žedelj and doc.dr.sc. Mario Šekerija for their help with data retrieval.

Thank you to all my family, friends, and colleagues for cheering me on and sharing this journey with me.

To my best friend and favorite colleague Tea, thank you for helping me through the difficult days and for celebrating with me all the victories.

I would like to express my deepest gratitude to my mom Marija. Thank you for every sacrifice you made to see me through my studies, for supporting me and believing in me, even when I didn't.

Finally, to my dad Ivan, thank you for your love, support, and encouragement in all my pursuits. I miss you endlessly and wish I could share this accomplishment with you.

REFERENCES:

1. Townsend CM, Beauchamp DR, Evers MB, Mattox KL. Sabiston Textbook of Surgery, The biological basis of modern surgical practice. 21st ed. 2022.
2. Yeo CJ. Shackelford's Surgery of the Alimentary Tract. 8th ed. 2019.
3. Dekker E, Tanis PJ, Vleugels JLA, Kasi PM, Wallace MB. Colorectal cancer. Lancet. 2019 Oct 19;394(10207):1467–80.
4. Engstrand J, Nilsson H, Strömberg C, Jonas E, Freedman J. Colorectal cancer liver metastases - a population-based study on incidence, management and survival. BMC Cancer. 2018 Jan 15;18(1):78.
5. Manfredi S, Lepage C, Hatem C, Coatmeur O, Faivre J, Bouvier AM. Epidemiology and management of liver metastases from colorectal cancer. Ann Surg. 2006 Aug;244(2):254–9.
6. Adam R, de Gramont A, Figueras J, Kokudo N, Kunstlinger F, Loyer E, et al. Managing synchronous liver metastases from colorectal cancer: a multidisciplinary international consensus. Cancer Treat Rev. 2015 Nov;41(9):729–41.
7. Reddy SK, Barbas AS, Clary BM. Synchronous colorectal liver metastases: is it time to reconsider traditional paradigms of management? Ann Surg Oncol. 2009 Sep;16(9):2395–410.
8. Elferink MAG, de Jong KP, Klaase JM, Siemerink EJ, de Wilt JHW. Metachronous metastases from colorectal cancer: a population-based study in North-East Netherlands. Int J Colorectal Dis. 2015 Feb;30(2):205–12.
9. Chong G, Cunningham D. Improving long-term outcomes for patients with liver metastases from colorectal cancer. J Clin Oncol. 2005 Dec 20;23(36):9063–6.
10. Niekel MC, Bipat S, Stoker J. Diagnostic imaging of colorectal liver metastases with CT, MR imaging, FDG PET, and/or FDG PET/CT: a meta-analysis of prospective studies including patients who have not previously undergone treatment. Radiology. 2010 Dec;257(3):674–84.
11. Sahani D V, Bajwa MA, Andrabi Y, Bajpai S, Cusack JC. Current status of imaging and emerging techniques to evaluate liver metastases from colorectal carcinoma. Ann Surg. 2014 May;259(5):861–72.
12. Soyer P, Pocard M, Boudiaf M, Abitbol M, Hamzi L, Panis Y, et al. Detection of hypovascular hepatic metastases at triple-phase helical CT: sensitivity of phases and comparison with surgical and histopathologic findings. Radiology. 2004 May;231(2):413–20.
13. Floriani I, Torri V, Rulli E, Garavaglia D, Compagnoni A, Salvolini L, et al. Performance of imaging modalities in diagnosis of liver metastases from colorectal cancer: a systematic review and meta-analysis. J Magn Reson Imaging. 2010 Jan;31(1):19–31.
14. Deng J, Tang J, Shen N. Meta-analysis of diagnosis of liver metastatic cancers: comparison of (18) FDG PET-CT and gadolinium-enhanced MRI. J Med Imaging Radiat Oncol. 2014 Oct;58(5):532–7.

15. Martin J, Petrillo A, Smyth EC, Shaida N, Khwaja S, Cheow HK, et al. Colorectal liver metastases: Current management and future perspectives. *World J Clin Oncol*. 2020 Oct 24;11(10):761–808.
16. Hurwitz H, Fehrenbacher L, Novotny W, Cartwright T, Hainsworth J, Heim W, et al. Bevacizumab plus irinotecan, fluorouracil, and leucovorin for metastatic colorectal cancer. *N Engl J Med* [Internet]. 2004 Jun 3 [cited 2023 May 18];350(23):2335–42. Available from: <https://pubmed.ncbi.nlm.nih.gov/15175435/>
17. Twelves C, Wong A, Nowacki MP, Abt M, Burris H, Carrato A, et al. Capecitabine as adjuvant treatment for stage III colon cancer. *N Engl J Med* [Internet]. 2005 Jun 30 [cited 2023 May 18];352(26):2696–704. Available from: <https://pubmed.ncbi.nlm.nih.gov/15987918/>
18. Douillard JY, Cunningham D, Roth AD, Navarro M, James RD, Karasek P, et al. Irinotecan combined with fluorouracil compared with fluorouracil alone as first-line treatment for metastatic colorectal cancer: a multicentre randomised trial. *Lancet* [Internet]. 2000 Mar 25 [cited 2023 May 18];355(9209):1041–7. Available from: <https://pubmed.ncbi.nlm.nih.gov/10744089/>
19. Goldberg RM, Sargent DJ, Morton RF, Fuchs CS, Ramanathan RK, Williamson SK, et al. A randomized controlled trial of fluorouracil plus leucovorin, irinotecan, and oxaliplatin combinations in patients with previously untreated metastatic colorectal cancer. *J Clin Oncol* [Internet]. 2004 [cited 2023 May 18];22(1):23–30. Available from: <https://pubmed.ncbi.nlm.nih.gov/14665611/>
20. Meyerhardt JA, Mayer RJ. Systemic therapy for colorectal cancer. *N Engl J Med* [Internet]. 2005 Feb 3 [cited 2023 May 18];352(5):476–87. Available from: <https://pubmed.ncbi.nlm.nih.gov/15689586/>
21. Fong Y, Cohen AM, Fortner JG, Enker WE, Turnbull AD, Coit DG, et al. Liver resection for colorectal metastases. *J Clin Oncol* [Internet]. 1997 [cited 2023 May 18];15(3):938–46. Available from: <https://pubmed.ncbi.nlm.nih.gov/9060531/>
22. Nordlinger B, Sorbye H, Glimelius B, Poston GJ, Schlag PM, Rougier P, et al. Perioperative FOLFOX4 chemotherapy and surgery versus surgery alone for resectable liver metastases from colorectal cancer (EORTC 40983): long-term results of a randomised, controlled, phase 3 trial. *Lancet Oncol* [Internet]. 2013 Nov [cited 2023 May 18];14(12):1208–15. Available from: <https://pubmed.ncbi.nlm.nih.gov/24120480/>
23. Nordlinger B, Sorbye H, Glimelius B, Poston GJ, Schlag PM, Rougier P, et al. Perioperative chemotherapy with FOLFOX4 and surgery versus surgery alone for resectable liver metastases from colorectal cancer (EORTC Intergroup trial 40983): a randomised controlled trial. *Lancet* [Internet]. 2008 [cited 2023 May 18];371(9617):1007–16. Available from: <https://pubmed.ncbi.nlm.nih.gov/18358928/>
24. Portier G, Elias D, Bouche O, Rougier P, Bosset JF, Saric J, et al. Multicenter randomized trial of adjuvant fluorouracil and folinic acid compared with surgery alone after resection of colorectal liver metastases: FFCD ACHBTH AURC 9002 trial. *J Clin Oncol* [Internet]. 2006 Nov 1 [cited 2023 May 18];24(31):4976–82. Available from: <https://pubmed.ncbi.nlm.nih.gov/17075115/>

25. Tournigand C, André T, Achille E, Lledo G, Flesh M, Mery-Mignard D, et al. FOLFIRI followed by FOLFOX6 or the reverse sequence in advanced colorectal cancer: a randomized GERCOR study. *J Clin Oncol* [Internet]. 2004 [cited 2023 May 18];22(2):229–37. Available from: <https://pubmed.ncbi.nlm.nih.gov/14657227/>
26. Lam VWT, Spiro C, Laurence JM, Johnston E, Hollands MJ, Pleass HCC, et al. A systematic review of clinical response and survival outcomes of downsizing systemic chemotherapy and rescue liver surgery in patients with initially unresectable colorectal liver metastases. *Ann Surg Oncol* [Internet]. 2012 Apr [cited 2023 May 18];19(4):1292–301. Available from: <https://pubmed.ncbi.nlm.nih.gov/21922338/>
27. Hamady ZZR, Lodge JPA, Welsh FK, Toogood GJ, White A, John T, et al. One-millimeter cancer-free margin is curative for colorectal liver metastases: a propensity score case-match approach. *Ann Surg* [Internet]. 2014 Mar [cited 2023 May 18];259(3):543–8. Available from: <https://pubmed.ncbi.nlm.nih.gov/23732261/>
28. De Haas RJ, Wicherts DA, Flores E, Azoulay D, Castaing D, Adam R. R1 resection by necessity for colorectal liver metastases: is it still a contraindication to surgery? *Ann Surg* [Internet]. 2008 Oct [cited 2023 May 18];248(4):626–36. Available from: <https://pubmed.ncbi.nlm.nih.gov/18936576/>
29. Pulitanò C, Bodingbauer M, Aldrighetti L, De Jong MC, Castillo F, Schulick RD, et al. Liver resection for colorectal metastases in presence of extrahepatic disease: results from an international multi-institutional analysis. *Ann Surg Oncol* [Internet]. 2011 May [cited 2023 May 18];18(5):1380–8. Available from: <https://pubmed.ncbi.nlm.nih.gov/21136180/>
30. Carpizo DR, Are C, Jarnagin W, Dematteo R, Fong Y, Gönen M, et al. Liver resection for metastatic colorectal cancer in patients with concurrent extrahepatic disease: results in 127 patients treated at a single center. *Ann Surg Oncol* [Internet]. 2009 Aug [cited 2023 May 18];16(8):2138–46. Available from: <https://pubmed.ncbi.nlm.nih.gov/19495884/>
31. Elias D, Ouellet JF, Bellon N, Pignon JP, Pocard M, Lasser P. Extrahepatic disease does not contraindicate hepatectomy for colorectal liver metastases. *Br J Surg*. 2003 May;90(5):567–74.
32. Frühling P, Strömberg C, Isaksson B, Urdzik J. A comparison of the simultaneous, liver-first, and colorectal-first strategies for surgical treatment of synchronous colorectal liver metastases at two major liver-surgery institutions in Sweden. *HPB (Oxford)* [Internet]. 2022 Sep 7; Available from: <http://www.ncbi.nlm.nih.gov/pubmed/36167765>
33. Allen PJ, Kemeny N, Jarnagin W, DeMatteo R, Blumgart L, Fong Y, et al. Importance of response to neoadjuvant chemotherapy in patients undergoing resection of synchronous colorectal liver metastases. *J Gastrointest Surg* [Internet]. 2003 Jan [cited 2023 May 18];7(1):109–17. Available from: <https://pubmed.ncbi.nlm.nih.gov/12559192/>
34. Lambert LA, Colacchio TA, Barth RJ. Interval hepatic resection of colorectal metastases improves patient selection. *Arch Surg* [Internet]. 2000 [cited 2023 May 18];135(4):473–80. Available from: <https://pubmed.ncbi.nlm.nih.gov/10768715/>
35. Mentha G, Majno PE, Andres A, Rubbia-Brandt L, Morel P, Roth AD. Neoadjuvant chemotherapy and resection of advanced synchronous liver metastases before treatment of

- the colorectal primary. *Br J Surg* [Internet]. 2006 Jul [cited 2023 May 18];93(7):872–8. Available from: <https://pubmed.ncbi.nlm.nih.gov/16671066/>
36. Stureson C, Valdimarsson VT, Blomstrand E, Eriksson S, Nilsson JH, Syk I, et al. Liver-first strategy for synchronous colorectal liver metastases - an intention-to-treat analysis. *HPB (Oxford)* [Internet]. 2017 Jan 1 [cited 2023 May 18];19(1):52–8. Available from: <https://pubmed.ncbi.nlm.nih.gov/27838252/>
 37. Gavriilidis P, Sutcliffe RP, Hodson J, Marudanayagam R, Isaac J, Azoulay D, et al. Simultaneous versus delayed hepatectomy for synchronous colorectal liver metastases: a systematic review and meta-analysis. *HPB (Oxford)* [Internet]. 2018 Jan 1 [cited 2023 May 18];20(1):11–9. Available from: <https://pubmed.ncbi.nlm.nih.gov/28888775/>
 38. Reddy SK, Pawlik TM, Zorzi D, Gleisner AL, Ribero D, Assumpcao L, et al. Simultaneous resections of colorectal cancer and synchronous liver metastases: a multi-institutional analysis. *Ann Surg Oncol* [Internet]. 2007 Dec [cited 2023 May 18];14(12):3481–91. Available from: <https://pubmed.ncbi.nlm.nih.gov/17805933/>
 39. Gavriilidis P, Katsanos K, Sutcliffe RP, Simopoulos C, Azoulay D, Roberts KJ. Simultaneous, Delayed and Liver-First Hepatic Resections for Synchronous Colorectal Liver Metastases: A Systematic Review and Network Meta-Analysis. *J Clin Med Res* [Internet]. 2019 [cited 2023 May 18];11(8):572–82. Available from: <https://pubmed.ncbi.nlm.nih.gov/31413769/>
 40. Lorenz M, Müller HH, Schramm H, Gassel HJ, Rau HG, Ridwelski K, et al. Randomized trial of surgery versus surgery followed by adjuvant hepatic arterial infusion with 5-fluorouracil and folinic acid for liver metastases of colorectal cancer. German Cooperative on Liver Metastases (Arbeitsgruppe Lebermetastasen). *Ann Surg* [Internet]. 1998 Dec [cited 2023 May 18];228(6):756–62. Available from: <https://pubmed.ncbi.nlm.nih.gov/9860474/>
 41. Guenette JP, Dupuy DE. Radiofrequency ablation of colorectal hepatic metastases. *J Surg Oncol* [Internet]. 2010 Dec 15 [cited 2023 May 18];102(8):978–87. Available from: <https://pubmed.ncbi.nlm.nih.gov/21166002/>
 42. Liu Y, Li S, Wan X, Li Y, Li B, Zhang Y, et al. Efficacy and safety of thermal ablation in patients with liver metastases. *Eur J Gastroenterol Hepatol* [Internet]. 2013 Apr [cited 2023 May 18];25(4):442–6. Available from: <https://pubmed.ncbi.nlm.nih.gov/23470267/>
 43. Correa-Gallego C, Fong Y, Gonen M, D'Angelica MI, Allen PJ, DeMatteo RP, et al. A retrospective comparison of microwave ablation vs. radiofrequency ablation for colorectal cancer hepatic metastases. *Ann Surg Oncol* [Internet]. 2014 Oct 31 [cited 2023 May 18];21(13):4278–83. Available from: <https://pubmed.ncbi.nlm.nih.gov/24889486/>
 44. Lubner MG, Brace CL, Hinshaw JL, Lee FT. Microwave tumor ablation: mechanism of action, clinical results, and devices. *J Vasc Interv Radiol* [Internet]. 2010 Aug [cited 2023 May 18];21(8 Suppl). Available from: <https://pubmed.ncbi.nlm.nih.gov/20656229/>
 45. Types of NETs: About neuroendocrine tumours (NETs) [Internet]. [cited 2023 May 18]. Available from: <https://www.livingwithnets.com/about-neuroendocrine-tumours-nets/learn-about-nets/types-of-neuroendocrine-tumours-nets/>
 46. Kumar V, Abbas AK, Aster JC. *Robbins Basic Pathology* 10th ed. Vol. 3, Elsevier Saunders. 2018.

47. Dasari A, Shen C, Halperin D, Zhao B, Zhou S, Xu Y, et al. Trends in the Incidence, Prevalence, and Survival Outcomes in Patients With Neuroendocrine Tumors in the United States. *JAMA Oncol.* 2017 Oct 1;3(10):1335–42.
48. Riihimäki M, Hemminki A, Sundquist K, Sundquist J, Hemminki K. The epidemiology of metastases in neuroendocrine tumors. *Int J Cancer.* 2016 Dec 15;139(12):2679–86.
49. Vinik AI, Chaya C. Clinical Presentation and Diagnosis of Neuroendocrine Tumors. *Hematol Oncol Clin North Am.* 2016 Feb;30(1):21–48.
50. Scott AT, Howe JR. Evaluation and Management of Neuroendocrine Tumors of the Pancreas. *Surg Clin North Am.* 2019 Aug;99(4):793–814.
51. Tran CG, Sherman SK, Chandrasekharan C, Howe JR. Surgical Management of Neuroendocrine Tumor Liver Metastases. *Surg Oncol Clin N Am.* 2021 Jan;30(1):39–55.
52. Modlin IM, Bodei L, Kidd M. Neuroendocrine tumor biomarkers: From monoanalytes to transcripts and algorithms. *Best Pract Res Clin Endocrinol Metab.* 2016 Jan;30(1):59–77.
53. Shah MH, Goldner WS, Halfdanarson TR, Bergsland E, Berlin JD, Halperin D, et al. NCCN Guidelines Insights: Neuroendocrine and Adrenal Tumors, Version 2.2018. *J Natl Compr Canc Netw.* 2018 Jun;16(6):693–702.
54. Dromain C, de Baere T, Lumbroso J, Caillet H, Laplanche A, Boige V, et al. Detection of liver metastases from endocrine tumors: a prospective comparison of somatostatin receptor scintigraphy, computed tomography, and magnetic resonance imaging. *J Clin Oncol.* 2005 Jan 1;23(1):70–8.
55. Dromain C, de Baere T, Baudin E, Galline J, Ducreux M, Boige V, et al. MR imaging of hepatic metastases caused by neuroendocrine tumors: comparing four techniques. *AJR Am J Roentgenol.* 2003 Jan;180(1):121–8.
56. Haug AR, Cindea-Drimus R, Auernhammer CJ, Reincke M, Wängler B, Uebleis C, et al. The role of 68Ga-DOTATATE PET/CT in suspected neuroendocrine tumors. *J Nucl Med.* 2012 Nov;53(11):1686–92.
57. Maxwell JE, Sherman SK, Stashek KM, O’Dorisio TM, Bellizzi AM, Howe JR. A practical method to determine the site of unknown primary in metastatic neuroendocrine tumors. *Surgery.* 2014 Dec;156(6):1359–65; discussion 1365-6.
58. Sherman SK, Maxwell JE, Carr JC, Wang D, Bellizzi AM, Sue O’Dorisio M, et al. Gene expression accurately distinguishes liver metastases of small bowel and pancreas neuroendocrine tumors. *Clin Exp Metastasis.* 2014 Dec;31(8):935–44.
59. Klimstra DS, Modlin IR, Adsay NV, Chetty R, Deshpande V, Gönen M, et al. Pathology reporting of neuroendocrine tumors: application of the Delphic consensus process to the development of a minimum pathology data set. *Am J Surg Pathol.* 2010 Mar;34(3):300–13.
60. Touzios JG, Kiely JM, Pitt SC, Rilling WS, Quebbeman EJ, Wilson SD, et al. Neuroendocrine hepatic metastases: does aggressive management improve survival? *Ann Surg.* 2005 May;241(5):776–83; discussion 783-5.

61. Sarmiento JM, Heywood G, Rubin J, Ilstrup DM, Nagorney DM, Que FG. Surgical treatment of neuroendocrine metastases to the liver: a plea for resection to increase survival. *J Am Coll Surg*. 2003 Jul;197(1):29–37.
62. Wynick D, Anderson J V, Williams SJ, Bloom SR. Resistance of metastatic pancreatic endocrine tumours after long-term treatment with the somatostatin analogue octreotide (SMS 201-995). *Clin Endocrinol (Oxf)*. 1989 Apr;30(4):385–8.
63. Del Basso C, Usai S, Levi Sandri GB. Non-colorectal non-neuroendocrine liver metastasis: a narrative review of surgical treatment. *Chin Clin Oncol*. 2022 Aug;11(4):28.
64. Fritsch H, Kühnel W. *Color Atlas of Human Anatomy, Vol. 2: Internal Organs*. Color Atlas of Human Anatomy, Vol. 2: Internal Organs. 2019.
65. Fong Y, Fortner J, Sun RL, Brennan MF, Blumgart LH. Clinical score for predicting recurrence after hepatic resection for metastatic colorectal cancer: analysis of 1001 consecutive cases. *Ann Surg* [Internet]. 1999 Sep [cited 2023 May 18];230(3):309–21. Available from: <https://pubmed.ncbi.nlm.nih.gov/10493478/>
66. Aloia TA, Vauthey JN, Loyer EM, Ribero D, Pawlik TM, Wei SH, et al. Solitary colorectal liver metastasis: resection determines outcome. *Arch Surg* [Internet]. 2006 May [cited 2023 May 18];141(5):460–7. Available from: <https://pubmed.ncbi.nlm.nih.gov/16702517/>
67. Covey AM, Brown KT, Jarnagin WR, Brody LA, Schwartz L, Tuorto S, et al. Combined portal vein embolization and neoadjuvant chemotherapy as a treatment strategy for resectable hepatic colorectal metastases. *Ann Surg* [Internet]. 2008 Mar [cited 2023 May 18];247(3):451–5. Available from: <https://pubmed.ncbi.nlm.nih.gov/18376189/>
68. Ito H, Mo Q, Qin LX, Viale A, Maithel SK, Maker A V., et al. Gene expression profiles accurately predict outcome following liver resection in patients with metastatic colorectal cancer. *PLoS One* [Internet]. 2013 Dec 10 [cited 2023 May 18];8(12). Available from: <https://pubmed.ncbi.nlm.nih.gov/24339954/>
69. Eshmunov D, Raptis DA, Linecker M, Wirsching A, Lesurtel M, Clavien PA. Meta-analysis of associating liver partition with portal vein ligation and portal vein occlusion for two-stage hepatectomy. *Br J Surg* [Internet]. 2016 Dec 1 [cited 2023 May 18];103(13):1768–82. Available from: <https://pubmed.ncbi.nlm.nih.gov/27633328/>
70. Van Cutsem E, Köhne CH, Hitre E, Zaluski J, Chang Chien CR, Makhson A, et al. Cetuximab and chemotherapy as initial treatment for metastatic colorectal cancer. *N Engl J Med* [Internet]. 2009 Apr 2 [cited 2023 May 18];360(14):1408–17. Available from: <https://pubmed.ncbi.nlm.nih.gov/19339720/>
71. Guiu B, Herrero A, Panaro F. Liver venous deprivation: a bright future for liver metastases-but what about hepatocellular carcinoma? *Hepatobiliary Surg Nutr*. 2021 Apr;10(2):270–2.
72. Laurent C, Fernandez B, Marichez A, Adam JP, Papadopoulos P, Lapuyade B, et al. Radiological Simultaneous Portohepatic Vein Embolization (RASPE) Before Major Hepatectomy: A Better Way to Optimize Liver Hypertrophy Compared to Portal Vein Embolization. *Ann Surg*. 2020 Aug;272(2):199–205.
73. Kesmodel SB, Ellis LM, Lin E, Chang GJ, Abdalla EK, Kopetz S, et al. Preoperative bevacizumab does not significantly increase postoperative complication rates in patients undergoing

- hepatic surgery for colorectal cancer liver metastases. *J Clin Oncol* [Internet]. 2008 Nov 10 [cited 2023 May 18];26(32):5254–60. Available from: <https://pubmed.ncbi.nlm.nih.gov/18854565/>
74. Scappaticci FA, Skillings JR, Holden SN, Gerber HP, Miller K, Kabbinavar F, et al. Arterial thromboembolic events in patients with metastatic carcinoma treated with chemotherapy and bevacizumab. *J Natl Cancer Inst* [Internet]. 2007 Aug 15 [cited 2023 May 18];99(16):1232–9. Available from: <https://pubmed.ncbi.nlm.nih.gov/17686822/>
 75. Chua TC, Saxena A, Liauw W, Chu F, Morris DL. Hepatectomy and resection of concomitant extrahepatic disease for colorectal liver metastases--a systematic review. *Eur J Cancer* [Internet]. 2012 [cited 2023 May 18];48(12):1757–65. Available from: <https://pubmed.ncbi.nlm.nih.gov/22153217/>
 76. Brulé SY, Jonker DJ, Karapetis CS, O’Callaghan CJ, Moore MJ, Wong R, et al. Location of colon cancer (right-sided versus left-sided) as a prognostic factor and a predictor of benefit from cetuximab in NCIC CO.17. *Eur J Cancer*. 2015 Jul;51(11):1405–14.
 77. Norén A, Eriksson HG, Olsson LI. Selection for surgery and survival of synchronous colorectal liver metastases; a nationwide study. *Eur J Cancer*. 2016 Jan;53:105–14.
 78. van der Pool AEM, Damhuis RA, Ijzermans JNM, de Wilt JHW, Eggermont AMM, Kranse R, et al. Trends in incidence, treatment and survival of patients with stage IV colorectal cancer: a population-based series. *Colorectal Dis*. 2012 Jan;14(1):56–61.
 79. Price TJ, Beeke C, Ullah S, Padbury R, Maddern G, Roder D, et al. Does the primary site of colorectal cancer impact outcomes for patients with metastatic disease? *Cancer*. 2015 Mar 15;121(6):830–5.
 80. Yahagi M, Okabayashi K, Hasegawa H, Tsuruta M, Kitagawa Y. The Worse Prognosis of Right-Sided Compared with Left-Sided Colon Cancers: a Systematic Review and Meta-analysis. *J Gastrointest Surg*. 2016 Mar;20(3):648–55.
 81. Gervaz P, Usel M, Rapiti E, Chappuis P, Neyroud-Kaspar I, Bouchardy C. Right colon cancer: Left behind. *Eur J Surg Oncol*. 2016 Sep;42(9):1343–9.
 82. Reddy SK, Pawlik TM, Zorzi D, Gleisner AL, Ribero D, Assumpcao L, et al. Simultaneous resections of colorectal cancer and synchronous liver metastases: a multi-institutional analysis. *Ann Surg Oncol*. 2007 Dec;14(12):3481–91.
 83. Jones TJ, Murphy AE, Tameron A, Hussain LR, Grannan K, Guend H, et al. Trends and Outcomes of Synchronous Resection of Colorectal Metastasis in the Modern Era-Analysis of Targeted Hepatic NSQIP Database. *J Surg Res*. 2019 Jun;238:35–40.
 84. Andreou A, Aloia TA, Brouquet A, Dickson P V, Zimmitti G, Maru DM, et al. Margin status remains an important determinant of survival after surgical resection of colorectal liver metastases in the era of modern chemotherapy. *Ann Surg*. 2013 Jun;257(6):1079–88.

BIOGRAPHY

I was born on December 17th, 1995, in Zagreb, where I finished Primary School Rudeš and V. Gimnazija. After enrolling in School of Medicine, University of Zagreb, I was a member of Student Society for Neuroscience and Student Surgical Section. Also, I was an active member of CroMSIC from the very beginning of my studies and, as such, completed a month-long research exchange program twice, in 2018, in Košice, Slovakia and, in 2019, in Madrid, Spain. I wrote for Gyrus Journal and presented at several student congresses, in Zagreb and internationally. I am fluent in English, German, and French.