

# Dermatoses of pregnancy

---

**Weiss, Amit**

**Master's thesis / Diplomski rad**

**2023**

*Degree Grantor / Ustanova koja je dodijelila akademski / stručni stupanj:* **University of Zagreb, School of Medicine / Sveučilište u Zagrebu, Medicinski fakultet**

*Permanent link / Trajna poveznica:* <https://um.nsk.hr/um:nbn:hr:105:787578>

*Rights / Prava:* [In copyright](#)/[Zaštićeno autorskim pravom.](#)

*Download date / Datum preuzimanja:* **2024-06-26**



*Repository / Repozitorij:*

[Dr Med - University of Zagreb School of Medicine Digital Repository](#)



**UNIVERSITY OF ZAGREB  
SCHOOL OF MEDICINE**

**Amit Weiss**

**Dermatoses of pregnancy**

**Graduate thesis**



**Zagreb, 2023**

This graduate thesis was made at the Department of Dermatology and Venereology, University Hospital Centre, School of Medicine, University of Zagreb, mentored by Prof. Branka Marinović, MD, PhD, and was submitted for evaluation in academic year 2022/2023.

## LIST OF ABBREVIATIONS

AEP – atopic eruption of pregnancy  
AEP E-type – atopic eruption of pregnancy eczematous type  
AEP P-type – atopic eruption of pregnancy prurigo type  
BPAg2 – bullous pemphigoid antigen 2  
DIF – direct immunofluorescence  
IF – immunofluorescence  
Ig – immunoglobulin  
IL – interleukin  
ICP – intrahepatic cholestasis of pregnancy  
MHC – major histocompatibility complex  
NBUVB – narrowband ultraviolet B  
PEP – polymorphic eruption of pregnancy  
PG – pemphigoid gestationis  
PPP – pustular psoriasis of pregnancy  
PUPPP – pruritic urticarial papules and plaques of pregnancy  
PUVA – psoralen ultraviolet A radiation  
TNF- $\alpha$  – tumor necrosis factor alpha  
UCDA – ursodeoxycholic acid

## CONTENTS

<b>SUMMARY</b> .....	5
<b>SAŽETAK</b> .....	6
<b>INTRODUCTION</b> .....	7
<b>FREQUENCY AND NOMENCLATURE OF DERMATOSES OF PREGNANCY</b> .....	7
<b>CHARACTERISTICS OF THE SPECIFIC DERMATOSES RELATED TO PRGNANCY</b> ..	8
1. Atopic eruption of pregnancy (AEP).....	8
2. Polymorphic eruption of pregnancy (PEP).....	10
3. Intrahepatic cholestasis of pregnancy (ICP):.....	12
4. Pemphigoid gestationis (PG):.....	13
5. Pustular psoriasis of pregnancy (PPP):.....	15
<b>CONCLUSION</b> .....	19
<b>REFERNCES</b> .....	20
<b>BIOGRAPHY</b> .....	23

## SUMMARY

### **Dermatoses of pregnancy**

**Amit Weiss**

Key words: pregnancy, dermatoses, skin changes, dermatoses of pregnancy

Dermatoses of pregnancy are heterogenous group of dermatoses that occur exclusively during the pregnancy or immediate postpartum period. Pregnancy results in cutaneous changes in more than 90% of women. Cutaneous changes are usually so well recognized that some constitute contributory evidence of pregnancy. Most changes occur as a physiological adaptation to pregnancy and are often considered benign or of cosmetic concern only, while a minority may be an important sign to recognize as they may signify or lead to serious morbidity and complications in the gravid patient and, in some cases, in the fetus. Specific etiologies are various and most often relate to changes in the gravid female's hormonal, metabolic, and immunological processes.

This comprehensive review of the existing literature emphasizes the importance of early detection, diagnosis and treatment of the dermatoses of pregnancy, and is aimed at helping physicians to recognize, diagnose, manage, and treat these rare, yet potentially life-threatening, conditions. Only some dermatoses are associated with fetal and maternal risks; these are the more common Pemphigoid gestationis (PG), and Intrahepatic cholestasis of pregnancy (ICP) and the much rarer Pustular psoriasis of pregnancy (PPP), but nevertheless there is a necessity to be familiarized with all dermatoses of pregnancy stemming from the fact that the symptoms are highly overlapping between the diseases.

In all cases, a pregnant woman with a pruritic skin eruption requires immediate evaluation and treatment to avoid delayed or misdiagnosis. Interdisciplinary management involving dermatologists, pediatricians, obstetricians, and (in relevant cases) gastroenterologists is mandatory to acquire a better outcome for the mother and the fetus.

## SAŽETAK

### Bolesti kože u trudnoći

#### Amit Weiss

Dermatoze u trudnoći su heterogena skupina dermatoza koje se javljaju isključivo tijekom trudnoće ili neposredno nakon poroda. U trudnoći se kožne promjene pojavljuju u više od 90% žena. Promjene na koži obično se tako karakteristične da neke od njih predstavljaju znak trudnoće. Većina promjena predstavlja fiziološku prilagodbu na trudnoću i često se smatraju benignima ili samo kozmetičkim problemom, dok manji broj bolesti je iznimno važno prepoznati jer mogu dovesti do ozbiljnog morbiditeta i komplikacija kod trudnica, a u nekim slučajevima i kod ploda. Etiologija pojedinih bolesti je različita te se najčešće smatraju posljedicom promjena u hormonalnim metaboličkim i imunološkim procesima u trudnice.

U ovom preglednom radu prikazani su podatci iz literature te je naglašena važnost ranog otkrivanja, dijagnoze i liječenja dermatoza u trudnoći. Cilj rada je pomoći liječnicima da prepoznaju, dijagnosticiraju, i liječe ove rijetka, ali potencijalno po život opasne bolesti. Neke od opisanih dermatoza povezane su i s rizicima za plod; to su najčešće gestacijski pemfigoid, intrahepatalna kolestaza u trudnoći te znatno rjeđe pustulozna psorijaza u trudnoći

U svim slučajevima u kojima trudnica ima izraženi svrbež s promjenama na koži potreban je hitan pregled liječnika, dijagnostički postupak i liječenje kako bi se izbjegla kasna ili pogrešna dijagnoza. Interdisciplinarno liječenje koje uključuje dermatologe, pedijatre, opstetričare i (u relevantnim slučajevima) gastroenterologe je obavezno kako bi se postigao bolji ishod za majku i plod.

Ključne riječi: trudnoća, dermatoze, kožne promjene, dermatoze u trudnoći

## INTRODUCTION

Dermatoses of pregnancy are heterogenous group of dermatoses that occur exclusively during the pregnancy or immediate postpartum period (2). Most occur as a physiological adaptation to pregnancy and are considered to be normal, while the minority of cases may be an important sign to recognize as they may signify or lead to serious morbidity and complications in the gravid patient and, in some cases, to the fetus (2). Early identification, diagnosis, and treatment of such cases may prevent mortality (3). Pregnancy results in cutaneous changes in more than 90% of women (4). Cutaneous changes are usually so well recognized that some are contributory evidence of pregnancy (4) since they appear as a result of the changes in the physiological state of the female body. However, these dermatoses are most often benign or of cosmetic concern only. Specific etiologies are various and most often relate to changes in the gravid female's hormonal, metabolic, and immunological processes (5). Many pre-existing dermatological conditions tend to change during pregnancy; some may while others may remit. While pregnancy specific dermatoses refer to those inflammatory skin diseases occurring exclusively during and in the immediate period postpartum (5).

## FREQUENCY AND NOMENCLATURE OF DERMATOSES OF PREGNANCY

Many pre-existing, dermatological conditions tend to change during pregnancy; some may even remit completely. For the sake of clarification and differentiation, pregnancy specific dermatoses refer to those inflammatory skin diseases occurring exclusively during and in the immediate period postpartum. (5)

Listed in descending order of occurrence frequency, together with their synonyms, the specific dermatoses of pregnancy are:

- **Atopic eruption of pregnancy (AEP) (50% of all pregnancy dermatoses)**  
Prurigo of pregnancy, Besnier's prurigo gestations, nurse's early onset prurigo of pregnancy, Spangler's papular dermatitis of pregnancy, pruritic folliculitis of pregnancy, eczema in pregnancy, linear IgM disease of pregnancy (5,6).
- **Polymorphic eruption of pregnancy (PEP) (incidence: 1/200 pregnancies)**  
Pruritic urticarial papules and plaques of pregnancy (PUPPP), Bourne's "toxemic rash of pregnancy", nurse's late onset prurigo of pregnancy, toxic erythema of pregnancy, linear IgM dermatosis of pregnancy (5,6).
- **Intrahepatic cholestasis of pregnancy (ICP) (Incidence in Europe: 0.5% to 1.5%)**  
Pruritus or prurigo gravidarum, cholestasis of pregnancy, obstetric cholestasis, cholestatic jaundice of pregnancy, recurrent jaundice of pregnancy, icterus gravidarum, idiopathic jaundice of pregnancy (5,6)
- **Pemphigoid gestationis (PG) (incidence: 1/50,000-60,000 pregnancies)**  
Herpes gestationis, gestational pemphigoid, dermatitis herpetiformis of pregnancy (5).



- **Pustular psoriasis of pregnancy (PPP) (Rare)**  
Impetigo herpetiformis, generalized psoriasis of pregnancy (6).

The most common pregnancy-specific dermatoses are AEP followed by PEP; both are benign conditions with no risk to the mother or baby. PG and ICP are less common, carry fetal risk, and require prenatal surveillance (4).

## THE EVALUATION OF THE GRAVID PATIENT WITH A NEW PRURITIC ERUPTION

A common feature of all eruptions related to pregnancy is pruritus. Therefore any new pruritic skin eruption during pregnancy requires immediate evaluation and differentiation from lesions that are coincidentally occurring while pregnant but are associated with infectious, allergic, or other non-related etiology (7).

The patient's history should be emphasized on a personal and familial history of autoimmunity, atopy, and previous pregnancies (6). Case-specific history and complete body skin examination must include the time of onset, the duration of pregnancy (i.e. first, second, or third trimester), localization and character of pain if present, and pruritus to determine the distribution and nature of the eruption (7).

Depending on the physical findings – laboratory testing such as bile acids and liver function tests may be indicated in case of ICP suspicion (8).

In any case of uncertainty or case of suspicion of PG or PPP, a skin biopsy should be taken for confirmation of the diagnosis (9).

## CHARACTERISTICS OF THE SPECIFIC DERMATOSES RELATED TO PRGNANCY

### 1. Atopic eruption of pregnancy (AEP)

AEP is the most common pregnancy-specific dermatosis causing pruritus during pregnancy with a prevalence of a prevalence of 5–20% (2). AEP is a benign pruritic condition in patients with a history / predisposition to atopic dermatitis or with new onset of atopic dermatitis during pregnancy that is characterized by eczematous or papular lesions. Most often (in 80% of cases) (10) patients experience AEP skin changes for the first time during pregnancy or after a long remission (i.e. had a history of eczema during childhood), while a minority of patients suffer from an exacerbation of preexisting atopic dermatitis. Pathogenesis includes the immunological inclination towards the Th2 cytokines (IL-4 and IL-10) response (11), which is thought to be responsible for the skin changes seen in the pregnant women.

#### *Clinical features*

Symptoms characteristically appear early in the first or second trimester as a pruritic eruption and skin dryness is invariably present.

Symptoms according to subtypes:

Eczematous (E) type of the AEP presents with widespread pruritic eczematous eruption with skin dryness on, and makes up about two-thirds of the cases. It often affects the typical atopic sites such as the flexural surfaces of the extremities (10).

Prurigo (P) type of the AEP composes the other one-third, presenting with small papular erythematous lesions that are mainly disseminated on the trunk and limbs areas, in addition to typical prurigo nodules, mostly on the shins and arms (12). This group includes what was referred to previously as prurigo of pregnancy (PP) and pruritic folliculitis of pregnancy (PF) (4). PP is seen predominantly in the second to third trimester (4), lasting up to three months post partum and recurrences are common in subsequent pregnancies (13). PP is also associated with ICP, the latter is differentiated by the absence of a primary lesion (14). PF is now believed to be as common as PP, though only a few cases have been reported (14). Both PP and PF commonly begins in the last two trimesters (15). Despite its name, pruritus is not a defining feature (16), the characteristic lesions involve multiple acneiform follicular papules and pustules located on the arms, shoulders, chest, upper back and abdomen (17). The lesions last about two months post partum.

### *Differential diagnosis*

Eruptions not associated with pregnancy such as allergic contact dermatitis, pityriasis rosea, infectious, or drug related eruptions (7). Eruptions that are associated with pregnancy include PEP and PG (in its early stage) (6).

### *Diagnosis*

Mostly clinical diagnosis, after ruling out other dermatoses of pregnancy: females with personal or family history of atopy and elevated IgE- accounting for nearly half of all patients (2). Immunofluorescence (IF) studies, when performed, are negative (6). Histopathological examination is non-specific with sterile folliculitis (4), commonly with eosinophils (6).

Pustules require culture to exclude infectious etiology (6).

### *Treatment*

Treatment is symptomatic with antihistamines and topical corticosteroids.

### *Prognosis*

It carries no risk for the mother or baby; however, an infant may develop atopy later in life (2). The disease tends to reoccur in subsequent pregnancies due to the atopic background (6).

## 2. Polymorphic eruption of pregnancy (PEP)

PEP is the second most common pregnancy specific dermatoses and was seen in 21.6% pregnancies reviewed by Ambros-Rudolph et al. (10). They found that it began in late pregnancy (third trimester) in 83% of the cases and in 15% it occurred also in the postpartum period.

The disease occurs predominantly in primigravidas most often is association with a familial predisposition. It is associated with multiple gestation pregnancies and increased maternal weight gain (1).

### *Pathogenesis*

The pathogenesis is unknown (6). The leading hypotheses suggest that the abdominal skin distension leads to subsequent damage to the underlying connective tissue, evident as striae and the formation of antigens that elicit an inflammatory response (2). In addition, the differences in cortisol level in patients with PEP (2) and the role of progesterone has been suggested due to the increased progesterone receptor immune reactivity measured in the skin lesions of PEP patient (18). Another finding suggesting that PEP is an immunological response is the discovery of fetal DNA in the skin lesions of the distended abdomen; suggesting an increased permeability of blood vessels permitting chimeric cell migration into the maternal skin (19).

### *Clinical features*

Symptoms characteristically appear in the later phases of pregnancy such as in the second and third trimesters, or postpartum. Lesions are extremely pruritic, papular erythematous vesicles, as well as urticarial, those are mainly located below the breasts – on the abdominal striae distensae, sparing the periumbilical area (4), and important differentiating feature from PG. The skin eruption typically spreads over days to the extremities, chest, and back, sparing the face, palms, and soles. As the disease progresses, about 50% of patients develop more polymorphic features, such as targetoid lesions, vesicles, and eczematous plaques (6) which broadens the differential diagnoses. Linear IgM dermatosis of pregnancy has been described as a variant of PEP or PP by different authors, which is characterized by pruritic, red, follicular papules and pustules on the abdomen and proximal extremities that are seen after 36 weeks of gestation and are characterized by a linear band of IgM deposition on the basement membrane layer in direct immunofluorescence (5).

### *Diagnosis*

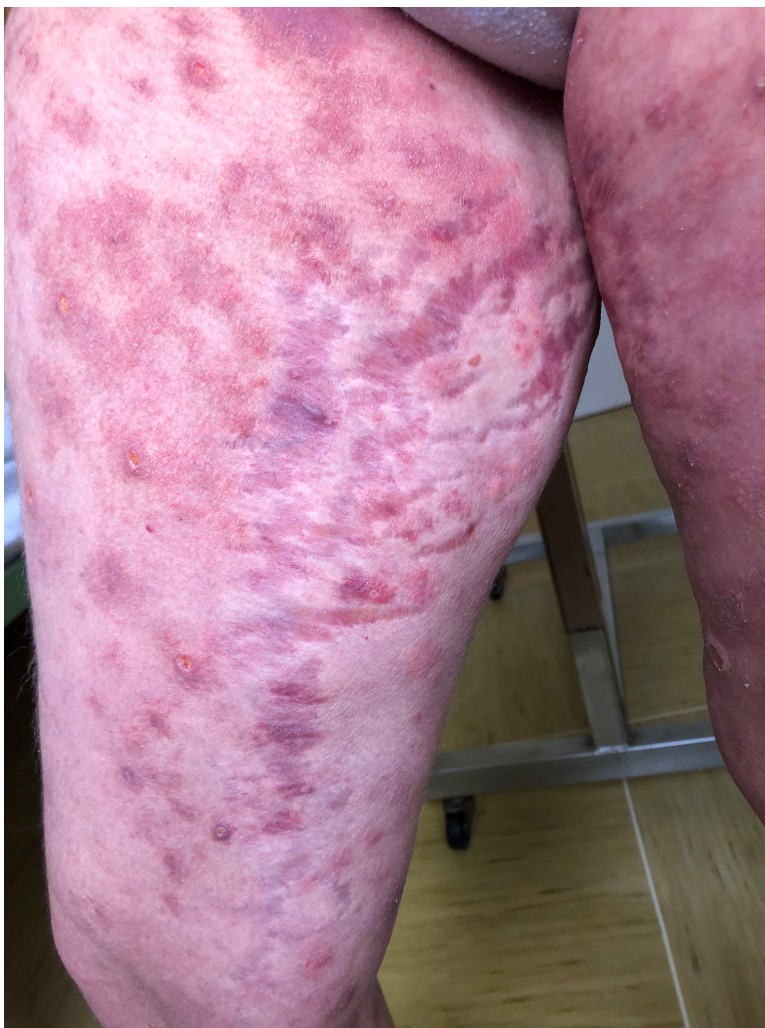Diagnosis is primarily based on clinical history and physical examination. Skin biopsies are performed in cases of inconclusive diagnosis, though histopathologic findings are generally nonspecific. DIF (direct immunofluorescence) may reveal nonspecific, granular C3 complement deposits, IgM, or IgA deposits at the dermo-epidermal junction or perivascular areas. Indirect IF is negative (6).

### *Treatment*

Mainly supportive for symptomatic relieve. Most mild cases are well treated by topical corticosteroids with oral antihistamines that are approved during pregnancy; cetirizine, loratadine, and fexofenadine are preferred. In severe cases a short treatment burst with systemic corticosteroids may be necessary. In such cases maternal adverse effects to corticosteroids should be monitored (2).

### *Prognosis*

The disease is self-limiting and the lesions usually resolve within about 5 weeks after birth, with no pigment change or scarring (2). PEP is not associated with cutaneous manifestations or risk to the newborn or fetus (6).



[Figure 1. Clinical findings of polymorphic eruption of pregnancy. Erythematous and urticarial papules and plaques within and surrounding the striae on the thigh. Courtesy of Department of Dermatology and Venereology, University Hospital Centre, School of Medicine, University of Zagreb]

### **3. Intrahepatic cholestasis of pregnancy (ICP):**

ICP is the only dermatoses of pregnancy that manifest with pruritus that is not due to a primary lesion in pregnancy, instead the skin lesions arise secondary to itching. It is also a dermatosis that merits specific attention since it carries significant morbidity especially of the fetus (8).

#### *Pathogenesis*

Pathogenesis is multifactorial. It involves hormonal changes, genetic predisposition, and exogenous factors. The increased incidence of ICP among first-degree relatives, certain ethnic groups, familial clustering, and high recurrence rates support an underlying genetic predisposition (6). Environmental factors are also thought to contribute to the development of ICP. Many patients have more mild recurrence in subsequent pregnancies, which suggests that environmental factors play a role in the development and severity of ICP. Limited studies have shown that selenium deficiency can play a role in ICP, due to its acting as a cofactor of several enzymes in the oxidative metabolism in the liver (20). Estrogen has a known role in causing cholestasis. All steroids, estrogen, progesterone, and corticosteroids are increased during pregnancy 1,000-fold at term compared with the non-pregnant state. Sex hormones exert cholestatic effects via inhibition of the hepatocellular bile salt export pump, and additionally by their association with impaired sulfation, leading to the hepatic transport mechanisms for biliary excretion to become saturated by sulfated progesterone metabolites (21). The risk is therefore highest in the third trimester when estrogen levels produced by the placenta are at their peak. Similarly, higher estrogen states such as multiple gestations are at an increased risk for developing ICP compared to singleton pregnancy. The accumulation of the bile acids in the maternal circulation, eventually pass through the placenta and produce vasoconstriction of placental veins, leading to fetal cardiomyocytes dysfunction and abnormal uterine contractility, all leading to fetal hypoxia (4) therefore carrying a significant risk of harming the fetus.

#### *Clinical features*

All dermatoses of pregnancy manifest with pruritus due to a primary lesion in pregnancy, with the exception of ICP where the skin lesions arise secondary to itching, a feature that must be differentiated (4). Intrahepatic cholestasis of pregnancy typically develops during the late second or third trimester of pregnancy, with 80–86% of affected women presenting after 30 weeks of gestation (6). Patients complain of sudden onset pruritus beginning from the palms and soles and later generalizing to the whole body. Skin lesions are secondary to scratching and range from excoriations to prurigo nodularis; extensors surfaces are more severely involved (4). Pruritus is often worse at night, and it often precedes elevation in serum bile levels by several weeks, and it gradually improves throughout pregnancy (6). Systemic symptoms of cholestasis can also develop, including jaundice, seen in 20% cases only (4) pale stools, dark urine, steatorrhea, malabsorption of fat- soluble vitamins, and increased bleeding (secondary to coagulation factors deficiency) (6).

## *Diagnosis*

ICP is diagnosed when the clinical observation of a pregnant women in the setting of pruritus is accompanied with elevated serum bile acids after all other causes are excluded. For pregnant women, elevated serum bile acids are defined as > 11.0 micromoles/L.

Severe cholestasis is defined as serum bile acids > 40 micro- moles/L, and accounts for about 20% of cases of ICP (6). In a systematic review on 11 studies, elevated serum bile acids were found to have sensitivity of 91% and a specificity of 93% in diagnosing ICP (6).

Other laboratory abnormalities seen among patients with ICP include serum aminotransferases (elevated in up to 70% of cases), alkaline phosphatase, and total and direct bilirubin concentrations (elevated in 10–20% of cases) (6). Both direct IF and indirect IF are negative, and histopathology of both skin and liver biopsies is nonspecific (6).

## *Treatment*

The goal of treatment is reduction of serum bile acids. Recent studies have implemented 2 bile acids, taurocholic and taurodeoxycholic aids, as being the specific ones elevated in ICP; luckily these are also the bile acids that are most significantly decreased by ursodeoxycholic acid (UCDA), which is currently the main pharmacological treatment (22).

UCDA is given in the dose of 15mg/kg orally daily. It is the only proven therapeutic agent that decreases fetal mortality. Topical emollients and antipruritic agents offer symptomatic relief. Antihistamines are non-effective (4). Since seasonal variations are also noted, with more severe cases in the winter months (6); thus, consultation with a dietician as well as discussion of timing for subsequent pregnancies in patients with a history of ICP should be done for caution.

## *Prognosis*

Resolution of ICP occurs soon after delivery, symptoms usually disappear with the lowering of estrogen levels, 1-2 days post partum; but in some cases may persist for 1-2 weeks (2). There is a high risk of recurrence of ICP in subsequent pregnancies (50–70%) and with the use of oral contraceptives (2). ICP is associated with significant fetal morbidity including premature births in 20-60% cases, intrapartum fetal distress including meconium aspiration in 20-30% and fetal mortality in 1-2%. Risk is particularly more if serum bile acid levels exceed 40 micromoles per liter (4).

## **4. Pemphigoid gestationis (PG):**

PG is the most clearly characterized dermatosis in pregnancy, and its importance especially stems from the risk of affecting the fetal skin as well. It is a rare, self- resolving, autoimmune bullous disease (4). The mean onset is from the end of second trimester (about 21 weeks of gestation), though it occurs even later in the postpartum period (a fifth

of all cases) (9).

### *Pathogenesis*

Pathogenesis of PG involves the production of IgG antibodies against a domain of bullous pemphigoid antigen 2 (BPAg2), in the basement membrane of the skin leading to activation of complement, and an autoimmune response resulting in tissue damage and blister formation (16). The same antibodies are believed to cross react with the amniotic epithelium of placental tissues due to an aberrant expression of MHC class II antigens of paternal haplotype that stimulate an allogenic response to placental basement membrane (4).

### *Clinical features*

The onset is characterized by constitutional symptoms, burning and itching. About 50% of patients then develop urticarial lesions particularly on the periumbilical region of the abdomen, that become a generalized bullous eruption. The vesicles distribution may be herpetiform or circinate, and usually in 90% spare the face, palms, soles and oral mucosal area is involved only in 20% (5).

### *Diagnosis*

Histology: The classical finding is a subepidermal vesicle, with spongiosis and urticarial lesions with superficial and deep perivascular infiltrates of lymphocytes, histiocytes and eosinophils (9). In early urticarial lesions, oedema in the dermal papilla is seen, giving an inverted tear drop appearance (23).

DIF – linear deposition of IgG and C3 complement at the basement membrane zone, which are present in 100% of cases and is therefore diagnostic of the disease (24).

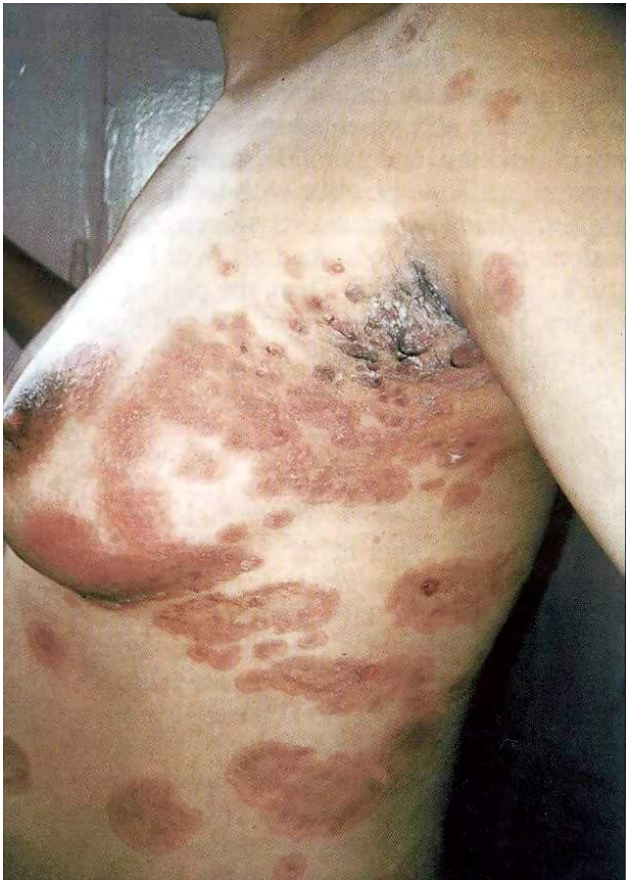### *Treatment*

Oral corticosteroids are the mainstay of therapy. Initiating daily dose of 0.5 mg/kg, gradually tapered to a maintenance dose according to the activity of the disease. In more severe cases where topical and oral corticosteroid treatments are insufficient, patients might benefit of systemic immunosuppressants such as cyclosporine A, dapsone, azathioprine, or methotrexate (postpartum only) (2).

### *Prognosis*

The disease regress spontaneously towards the late gestation phases, but recurrent flares at the time of delivery are common, occurring in 75% of cases (4). In spite of possible remission of the disease a few weeks after delivery, there has been reported long-term recurrence with menstrual cycle and use of oral contraceptive pills or conversion to bullous pemphigoid (14). PG tends to recur in a more severe form and at an early stage in subsequent pregnancies with longer duration postpartum (14). The disease is also linked with hydatiform mole and choriocarcinoma (4). About 1/10 children born to women with PG developed self resolving blisters due to the passive transfer of antibodies through the placenta. Severity of the disease has been correlated with the

risk of prematurity and small for gestational age neonates (25).



[Figure 2. Clinical findings of pemphigoid gestationis. Pruritic papules and plaques followed by clustered vesicles and tense bullae. Post inflammatory hyperpigmented lesions are also visible. Courtesy of Department of Dermatology and Venereology, University Hospital Centre, School of Medicine, University of Zagreb]

### **5. Pustular psoriasis of pregnancy (PPP):**

PPP, previously known as impetigo herpetiformis appears to be a misnomer, since it has no infectious etiology. PPP is a rare Dermatitis that occurs most often in the third trimester of pregnancy. Pustular psoriasis of pregnancy is considered to be a variant of generalized pustular psoriasis, and therefore not always included as a true “dermatosis of pregnancy”.

However, because of the importance of early recognition and prevention of life threatening maternal and fetal risks, some authors include PPP in discussions of dermatoses of pregnancy (26, 27).

#### *Pathogenesis*

The pathogenesis of PPP is poorly understood, but several hypotheses have been reported.

Genetic factors may contribute to the development of PPP, since there are reported cases in twins and siblings and among women with some specific mutations (28, 29).



Other theory is about hypocalcemic conditions being associated with the disease, especially low vitamin D, and hypoparathyroidism, which are commonly seen in late pregnancy (6). Hormonal changes, particularly of progesterone, may also play a role in the development of PPP and similarly may account for flares postpartum, during menses, and in relation to oral contraception use (6).

### *Clinical features.*

PPP most commonly occurs in the third trimester of pregnancy (26). Lesions are characterized by symmetrical erythematous plaques covered with sterile pustules, classically in circumferential rings in flexural areas and can be associated with systemic symptoms such as fever, anorexia, nausea, vomiting, diarrhea, malaise, lymphadenopathy, and seizures (26, 28). Lesions often extend centrifugally, and may erode and develop crust, and may even become impetiginized (30). The plaques may spread to involve the trunk and extremities, often sparing the hands, feet, and face. Other lesion may appear as mucosal erosions in the mouth and esophagus may develop, as well as onycholysis due to subungual pustules (26, 28). An important differentiating feature of PPP from other pregnancy dermatoses is the absence of pruritus (31).

### *Diagnosis*

PPP is often detected clinically, though given the possible life-threatening maternal and fetal complications, it is recommended to confirm the diagnosis with a skin biopsy (26). Histopathology resembles that of generalized pustular psoriasis, showing spongiform pustules that are accompanied by neutrophils, epidermal hyperplasia, and parakeratosis (26, 32). Laboratory test often shows leukocytosis with neutrophilia, hypocalcemia, hypoalbuminemia, hypoparathyroidism, low vitamin D, and an elevated erythrocyte sedimentation rate. (26, 31). Pustules cultures are usually sterile though should still be performed to exclude bacterial and fungal infections. (26, 31). Both DIF and IIF are negative (26).

Differential diagnosis to consider should include infectious etiology (impetigo, candida, tinea corporis), drug reactions (acute generalized exanthematous pustulosis), autoimmune diseases (IgA pemphigus, subcorneal pustular dermatosis, dermatitis herpetiformis), and other dermatoses of pregnancy (PEP, AEP follicular type, PG) (6).

### *Treatment*

Due to rarity of the disease, there is lack of controlled studies or guideline for treatment (30). The main challenges of treatment are the risk of mother and fetus complications against the possible teratogenicity of the drugs used in treatment of PPP. Prompt initiation of treatment is critical to prevent maternal and fetal morbidity and mortality.

Careful laboratory monitoring and supportive treatment with fluid and normalizing electrolytes imbalances especially hypovolemia, hypocalcemia, and low level of vitamin D should be corrected as soon as possible (30). Despite the absence of standardized guidelines for treating PPP, several drug treatment options have shown to be effective.

### 1. Corticosteroid

Administration of systemic prednisolone treatment is considered the mainstay of therapy (30). The main concern of corticosteroid therapy in pregnancy is the increased incidence of cleft palate, but since PPP occurs mostly in the third trimester, corticosteroid therapy can be considered as a safe choice. The use of mild to moderate topical corticosteroids is proffered over the potent ones, since the latter carry the risk of fetal growth restriction (30).

### 2. Cyclosporines

In patients unresponsive to corticosteroids, cyclosporine is a therapeutic option. Initiated in combination with corticosteroids, the prescribed dose ranges from 2 mg/kg/day to 7.5 mg/kg/day followed by tapering of the corticosteroids (30). The last dose of cyclosporine is given 3 days before delivery followed by administration of high potency topical steroid. Concerns about the safety of cyclosporine include a small risk of prematurity (30), though placental transfer of cyclosporine seems to be dose dependent, and with proper monitoring, it can be safely used. Another risk to be considered is of maternal hypertension (30), so monitoring of maternal blood pressure and creatinine are required.

### 3. Biologic agents

Tumor necrosis factor alpha (TNF- $\alpha$ ) inhibitors (infliximab and adalimumab) have also shown to be effective in treating PPP; however, the fetal risks are still not fully understood. Even though infliximab is one of the best therapies according to the board of the National Psoriasis Foundation, this is in dispute with current guideline of the European Academy of Dermatology and Venereology; given that these agents can cross the placenta, they are considered pregnancy category B drugs and their use is not recommended during pregnancy (30).

### 4. Antibiotics

Despite the fact that the pustules are sterile, Antibiotics have shown to be effective for mild cases and in the initial stages (before sepsis has been excluded), and as additive although they do not control disease completely (30). Even though overall all cephalosporins are considered safe during pregnancy, older generation cephalosporins are considered of choice (30). Other antibiotics that has shown efficacy in treatment are Ampicillin, macrolide, and clofazimine (30).

### 5. Phototherapy

Narrowband ultraviolet B (NB-UVB) is considered a safe option during pregnancy and it can be added to corticosteroids therapy when there is no adequate response (30). Psoralen ultraviolet-A radiation (PUVA) is relatively safe and has not caused increase in the risk of congenital malformations or infant mortality, but it does carry a possible risk of low birth weight infants (33).

6. Retinoids and methotrexate are two absolute contraindicated drugs while in pregnancy due to their teratogenic effects, but are usually successful as postpartum treatment in cases where the mother is not breastfeeding. An informed consent for appropriate contraception should be taken from the mother. In any case where administration of systemic retinoid is considered after the delivery (30).

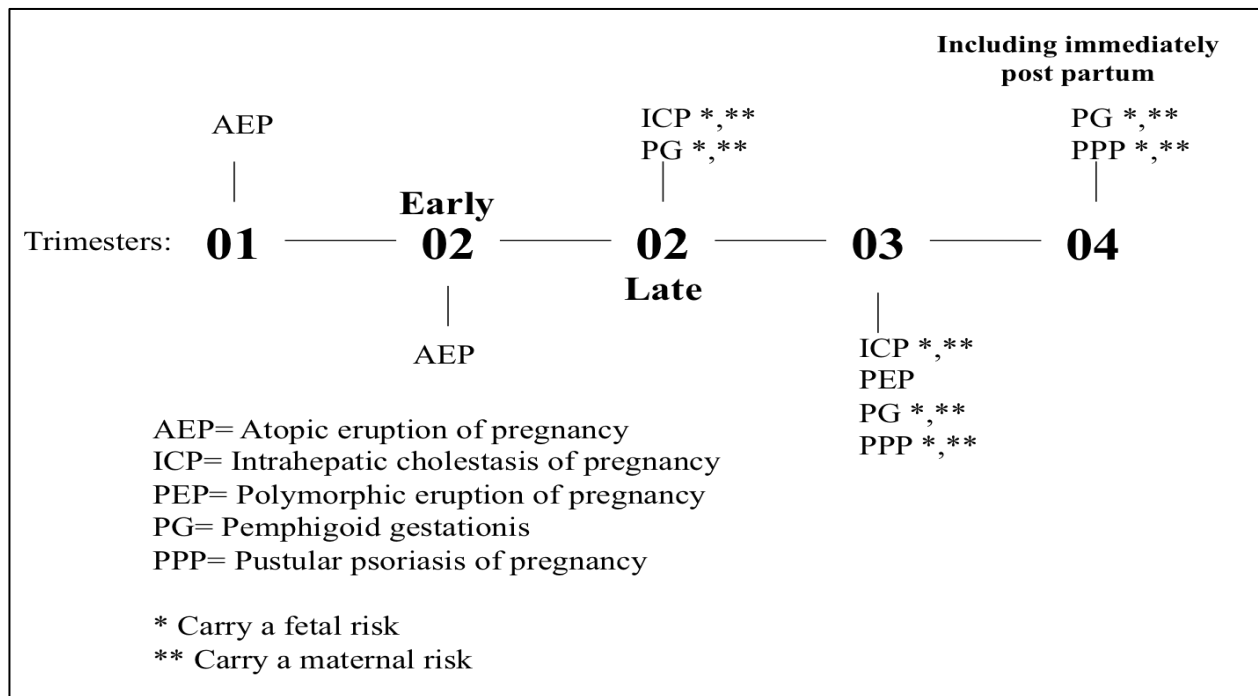
## 7. Induction of labor

Since PPP usually spontaneously resolves after delivery (6), induction of labor is also a treatment option for patients with severe or resistant disease who are near or at term (27).

### Prognosis

#### Complications:

Maternal complications include electrolytes imbalances and hypovolemia due to fluid losses, and sepsis from secondary infections (6). Low serum calcium may be complicated with delirium, tetany, and seizures (30). Additionally, there has been reports complication by gestational hypertension, and of recurrences in subsequent pregnancies in an earlier gestation period and with a more severe onset, as well as recurrence during menstruation and in relation to oral contraceptives use (6). Fetal complications include the risk of stillbirth and neonatal demise due to placental insufficiency, premature rupture of membranes, preterm labor, and intrauterine growth restrictions (6).



[Figure 3. This illustration summarizes the characteristic timeline of the dermatoses of pregnancy created by the author in 2023.]

## CONCLUSION

Pregnancy is associated with a wide variety of cutaneous changes. These may range from common, benign physiological changes to more severe conditions, posing significant risk to the mother as well as the baby. This comprehensive review of the existing literature emphasizes the importance of early detection, diagnosis and treatment of the dermatoses of pregnancy, and is aimed at helping physicians to recognize, diagnose, manage, and treat these rare, yet potentially life-threatening, conditions. In addition, some pre-existing dermatoses may aggravate during pregnancy period, posing a challenge to the treating physician. Women suffering from such conditions need to be warned of complications and risks before trying to conceive, and followed by strict monitoring for possible complications and appropriate management at an early stage when pregnant.

Careful history and examination with a judicious use of additional appropriate investigations will help in arriving at a correct diagnosis and in prompt institution of treatment.

A pregnant woman with a pruritic skin eruption requires immediate evaluation and treatment to avoid delayed or misdiagnosis. Only some dermatoses are associated with fetal and maternal risks; these are the more common PG, and ICP and the much rarer PPP, but nevertheless there is a necessity to be familiarized with all dermatoses of pregnancy stemming from the fact that the symptoms highly overlapping between the diseases.

It should be concluded that in all cases, pruritus in a pregnant patient should never be neglected; but its absence does not exclude the possibility of a risk, as is the case with PPP.

Interdisciplinary management involving dermatologists, pediatricians, obstetricians, and (in relevant cases) gastroenterologists is mandatory to acquire a better outcome for the mother and the fetus.

## REFERNCES

1. Bilgili MA, Karadaş Bilvanisi S, Gunes Bilgili S, Güler Okyay A, Dursun R, Karadağ AS. Specific and Non-specific Dermatoses of Pregnancy in the Emergency Department. *East J Med.* 2019;24(2):176–81.
2. Sävervall C, Sand FL, Thomsen SF. Dermatological Diseases Associated with Pregnancy: Pemphigoid Gestationis, Polymorphic Eruption of Pregnancy, Intrahepatic Cholestasis of Pregnancy, and Atopic Eruption of Pregnancy. *Dermatol Res Pract.* 2015;2015:1–7.
3. Puljic A, Kim E, Page J, Esakoff T, Shaffer B, LaCoursiere DY, et al. The risk of infant and fetal death by each additional week of expectant management in intrahepatic cholestasis of pregnancy by gestational age. *Am J Obstet Gynecol.* 2015;212(5):667.e1-667.e5.
4. Adil M, Arif T, Amin SS. A comprehensive review on the pregnancy dermatoses. *British Journal of Medical Practitioners,* 2016;9(1):a906.
5. Kar S, Krishnan A, Shivkumar PV. Pregnancy and Skin. *J Obstet Gynecol India.* 2012 ;62(3):268–75.
6. Himeles JR, Pomeranz MK. Recognizing, Diagnosing, and Managing Pregnancy Dermatoses. *Obstet Gynecol.* 2022;140(4):679–95.
7. Massone C, Cerroni L, Heidrun N, Brunasso AMG, Nunzi E, Gulia A, et al. Histopathological Diagnosis of Atopic Eruption of Pregnancy and Polymorphic Eruption of Pregnancy: A Study on 41 Cases. *Am J Dermatopathol.* 2014;36(10):812–21.
8. Stacey Ehrenberg-Buchner, MD Fidelma B Rigby, MD. Intrahepatic Cholestasis of Pregnancy [Internet]. 2019. Available from: <https://emedicine.medscape.com/article/1562288-overview>
9. Engineer L, Bhol K, Ahmed AR. Pemphigoid gestationis: A review. *Am J Obstet Gynecol.* 2000;183(2):483–91.
10. Ambros-Rudolph CM, Müllegger RR, Vaughan-Jones SA, Kerl H, Black MM. The specific dermatoses of pregnancy revisited and reclassified: Results of a retrospective two-center study on 505 pregnant patients. *J Am Acad Dermatol.* 2006;54(3):395–404.
11. Shah S. Hormonal Link to Autoimmune Allergies. *ISRN Allergy.* 2012 22;2012:1–5.
12. Ambros-Rudolph CM. Dermatoses of Pregnancy - Clues to Diagnosis, Fetal Risk and Therapy. *Ann Dermatol.* 2011;23(3):265.
13. Clarke RS, Doggart JR, Lavery T. Changes in liver function after different types of surgery. *Br J Anaesth.* 1976;48(2):119–28.
14. Kroumpouzou G, Cohen LM. Specific dermatoses of pregnancy: An evidence-based systematic review. *Am J Obstet Gynecol.* 2003;188(4):1083–92.

15. Roger D, Vaillant L, Fignon A, Pierre F, Bacq Y, Brechot JF, et al. Specific pruritic diseases of pregnancy. A prospective study of 3192 pregnant women. *Arch Dermatol.* 1994;130(6):734–9.
16. Vora R, Gupta R, Mehta M, Chaudhari A, Pilani A, Patel N. Pregnancy and skin. *J Fam Med Prim Care.* 2014;3(4):318.
17. Sachdeva S. The dermatoses of pregnancy. *Indian J Dermatol.* 2008;53(3):103.
18. Im S, Lee ES, Kim W, Song J, Kim J, Lee M, et al. Expression of progesterone receptor in human keratinocytes. *J Korean Med Sci.* 2000;15(6):647.
19. Aractingi S, Berkane N, Bertheau P, Le Goué C, Dausset J, Uzan S, et al. Fetal DNA in skin of polymorphic eruptions of pregnancy. *Lancet.* 1998;352(9144):1898–901.
20. Wachter RF, Briggs GP, Pedersen CE. Precipitation of phase I antigen of *Coxiella burnetii* by sodium sulfite. *Acta Virol.* 1975;19(6):500.
21. Share JB. Review of drug treatment for Down's syndrome persons. *Am J Ment Defic.* 1976;80(4):388–93.
22. Akamatsu N, Nakajima H, Ono M, Miura Y. Increase in acetyl CoA synthetase activity after phenobarbital treatment. *Biochem Pharmacol.* 1975;24(18):1725–7.
23. Chang ALS, Agredano YZ, Kimball AB. Risk factors associated with striae gravidarum. *J Am Acad Dermatol.* 2004;51(6):881–5.
24. Kalaaji AN, Nicolas MEO. *Mayo Clinic Atlas of Immunofluorescence in Dermatology: Patterns and Target Antigens* [Internet]. 0 ed. CRC Press; 2006 [cited 2023]. Available from: <https://www.taylorfrancis.com/books/9780849375736>
25. Chi CC, Wang SH, Charles-Holmes R, Ambros-Rudolph C, Powell J, Jenkins R, et al. Pemphigoid gestationis: early onset and blister formation are associated with adverse pregnancy outcomes. *Br J Dermatol.* 2009;160(6):1222–8.
26. Lehrhoff S, Pomeranz MK. Specific dermatoses of pregnancy and their treatment: Dermatoses of pregnancy and treatment. *Dermatol Ther.* 2013;26(4):274–84.
27. Trivedi MK, Vaughn AR, Murase JE. Pustular psoriasis of pregnancy: current perspectives. *Int J Womens Health.* 2018;10:109–15.
28. Tada J, Fukushiro S, Fujiwara Y, Akagi Y, Kodama H, Nohara N. Two sisters with impetigo herpetiformis. *Clin Exp Dermatol.* 1989;14(1):82–4.
29. Vicdan K, Gökay Z, Var T, Danişman N, Gökmen O. Twin sisters with impetigo herpetiformis. *Eur J Obstet Gynecol Reprod Biol.* 1995;63(2):195–6.
30. Namazi N, Dadkhahfar S. Impetigo Herpetiformis: Review of Pathogenesis, Complication, and Treatment. *Dermatol Res Pract.* 2018;2018:1–4.

31. Wamalwa EW. Recurrent impetigo herpetiformis: case report. *Pan Afr Med J* [Internet]. 2017 [cited 2023 Feb 24];27. Available from: <http://www.panafrican-med-journal.com/content/article/27/219/full/>
32. Sasseville D, Wilkinson RD, Schnader JY. Dermatoses of Pregnancy. *Int J Dermatol*. 1981 May;20(4):223–48.
33. Stern RS, Lange R. Outcomes of pregnancies among women and partners of men with a history of exposure to methoxsalen photochemotherapy (PUVA) for the treatment of psoriasis. *Arch Dermatol*. 1991 Mar;127(3):347–50.

## BIOGRAPHY

Amit Weiss is a dedicated 6th-year medical student who has been inspired by her own life experiences to make a difference in people's lives and enhance patient care and experience.

After completing their high school education, Weiss served as an officer in the Israeli Army for four impactful years. Following their military service, Weiss gained valuable experience in the fast-paced world of high tech businesses, holding a challenging position. However, their personal experiences sparked a desire to bring about change in people's lives, prompting a career shift towards medicine. Weiss's genuine compassion and thirst for knowledge led them to pursue a medical degree at the University of Zagreb, Croatia, where they have consistently excelled academically, ranking at the top of their class. With a strong academic foundation and a desire to bridge the gap between scientific discovery and patient care, Weiss aspires to become a clinician-researcher with a goal to contribute to the field of medicine and improve healthcare outcomes. Weiss approaches medicine with empathy and compassion, emphasizing evidence-based practices and a patient-centered approach to healthcare. Their dedication can be exemplified by their thesis paper, which represents the culmination of their rigorous academic journey. Amit Weiss is poised to make a significant difference in the field of medicine and positively impact the lives of individuals worldwide.

Correspondence:

[Amit.weiss6331@gmail.com](mailto:Amit.weiss6331@gmail.com)