

Ekvivalent: Reverzibilna lezija facijalnog živca tijekom putovanja zrakoplovom

Mikuš, Kristina

Professional thesis / Završni specijalistički

2023

Degree Grantor / Ustanova koja je dodijelila akademski / stručni stupanj: **University of Zagreb, School of Medicine / Sveučilište u Zagrebu, Medicinski fakultet**

Permanent link / Trajna poveznica: <https://urn.nsk.hr/urn:nbn:hr:105:734895>

Rights / Prava: [In copyright](#) / [Zaštićeno autorskim pravom.](#)

Download date / Datum preuzimanja: **2024-05-10**



Repository / Repozitorij:

[Dr Med - University of Zagreb School of Medicine Digital Repository](#)



SVEUČILIŠTE U ZAGREBU
MEDICINSKI FAKULTET

Kristina Mikuš

**Reverzibilna lezija facijalnog živca tijekom putovanja
zrakoplovom**

ZAVRŠNI SPECIJALISTIČKI RAD



Zagreb, listopad, 2023.

SVEUČILIŠTE U ZAGREBU
MEDICINSKI FAKULTET

Kristina Mikuš

**Reverzibilna lezija facijalnog živca tijekom putovanja
zrakoplovom**

ZAVRŠNI SPECIJALISTIČKI RAD



Zagreb, listopad, 2023.

Rad je prijavljen kao ekvivalent završnom specijalističkom radu sukladno Pravilniku o poslijediplomskim specijalističkim studijima Medicinskog fakulteta Sveučilišta u Zagrebu.

Objavljen u časopisu AEROSPACE MEDICAL HUMAN PERFORMANCE (pod brojem AMHP5603) , (<http://www.asma.org/journal>), kolovoz 2020.

Mentor rada: prof. dr.sc. Damir Petravić, dr.med, specijalist neurologije

Rad ima 11 stranica, 20 literaturnih navoda.

ZAHVALA

Zahvaljujem svom mentoru na uloženom trudu, korisnim savjetima i nesebičnoj pomoći.

Hvala mojoj užoj obitelji i prijateljima na podršci i strpljenju.

SADRŽAJ

1.UVOD.....	1
1.1. Facial baroparesis	1
2. PRIKAZ SLUČAJA	2
3. METODE I MATERIJALI	2
4. LIJEČENJE	3
5.REZULTATI	3
6.RASPRAVA	5
7.ZAKLJUČAK	6
8.SAŽETAK	7
9.SUMMARY	8
10.LITERATURA.....	9
11. ŽIVOTOPIS	11

1. INTRODUCTION

1.1. Facial baroparesis

Facial baroparesis is reversible palsy of the facial nerve. This rare condition may occur due to increased pressure in the middle ear and has been reported during ascent both in aviators and divers. [3,14,17]

Inability to equalize middle ear and ambient pressures due to impaired Eustachian tube functioning may cause overpressure. The excessive pressure may be exerted on the facial nerve through a dehiscence of the horizontal part of the fallopian canal (a bony canal through which the facial nerve traverses the petrous temporal bone, from the internal acoustic meatus to the stylomastoid foramen and the longest bony canal through which a nerve passes), thereby compressing the vasa nervorum, which may lead to hypoxia and consequently neuropraxia. [2,14,17]

This phenomenon usually occurs only in a single episode, even in those who have been recurrently exposed to similar barometric conditions (probably due to the coexistence of certain conditions that precipitate the palsy, e.g., transient Eustachian tube dysfunction, hypotension, or subclinical infection with one of the neurotropic viruses). [8]

Most cases of facial palsy associated with flight resolve spontaneously during descent (minutes to hours), as blood flow rapidly resumes when the pressure in the middle ear becomes less than the capillary closing pressure. [10,21]

The object of this paper is to present a rare case of facial palsy during airplane travel.

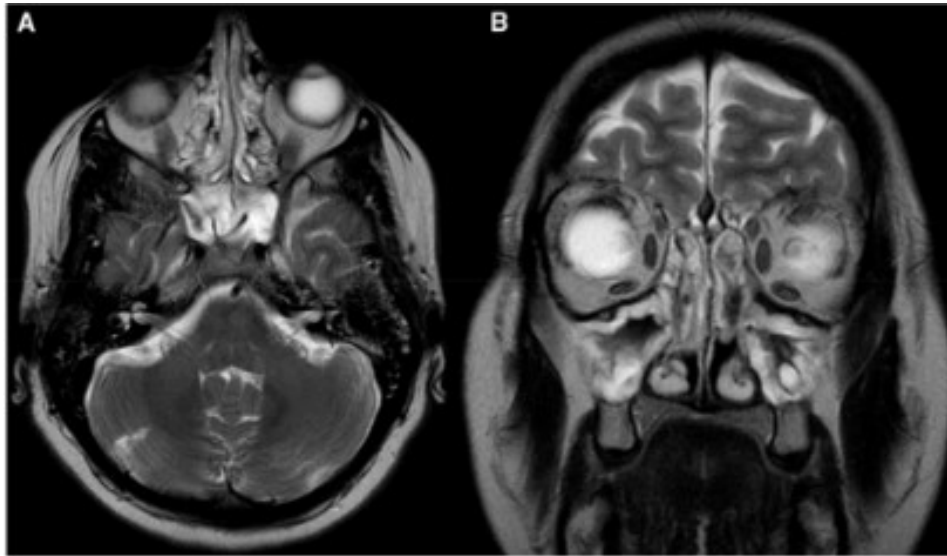
2. CASE REPORT

We present a 49-yr-old female patient from Germany who presented with a 30-min episode of transient right facial palsy with loss of taste during airplane travel. She reported having the sensation of ‘blocked ears’ and vertigo. After she ate some candy to try to relieve the symptoms, she experienced impaired taste, weakness of the right side of her face, and drooling. Symptoms resolved spontaneously at landing. Past medical history included chronic sinusitis, nasal polyps, asthma, arterial hypertension, and hyperlipidemia.

3. MATERIAL AND METHODS

Neurological examination in the emergency room (ER) was normal. In order to exclude transitory ischemic attack (TIA), brain imaging was done in the ER [computed tomography (CT) of the brain with neck/brain angiography] showing just the frontal parasagittal lipoma and left frontal calcified meningioma without compression of surrounding structures. An electroencephalogram (EEG) was unremarkable. Brain magnetic resonance imaging (MRI) with angiography upon hospitalization showed a small left parietal developmental venous anomaly, with no signs of ischemic or hemorrhagic stroke, and extensive inflammation of the paranasal sinuses, which were almost completely obstructed with thickened mucosa and mastoid cell secretion on both sides (SLIKA 1).

Ear, nose, and throat (ENT) examination discovered nasal polyposis and a tympanometry type A curve.



SLIKA 1. A) Brain MRI, T2 –weighted axial image showing normal cisternal course of the right facial nerve and congestion of mastoid cells bilaterally. B) T2-weighted image in the frontal plane shows bilateral maxillar sinusitis.

4.TREATMENT

Our patient were prescribed.nasal decongestants and antibiotics .

Treatment is based on normobaric or even hyperbaric oxygen therapy. [13]

In the airplane, the pressure variation in the eardrum is resolved upon landing, which was demonstrated in our case. Patients may take a decongestant pill or nasal spray approximately an hour before descent to help ears pop more easily, avoid sleeping during descent, and chew gum or suck on a hard candy just before take off and during a descent. Recurrent facial nerve palsy can be prevented by self-equalization techniques or by ventilation tube insertion.

[1,13,17]

5. RESULTS

During hospitalization, no new neurological signs or symptoms were noticed.The final diagnosis was peripheral facial nerve palsy.

Subsequently (more than a year after discharge from the hospital), we contacted our patient, who lives in Germany. Symptoms of facial paresis or similar have not occurred again.

Admittedly, this might be because she had not flown again since then. Later she had surgery for nasal polyps, which improved the ventilation of her sinuses.

6. DISCUSSION

We report about a patient who presented with a transient right facial paresis and loss of taste during airplane travel. There are four major functions of the facial nerve: general somatic efferent, which is responsible for motor supply to facial muscles; general visceral efferent, which is responsible for parasympathetic secretomotor supply to the submandibular and sublingual salivary glands and the lacrimal gland; special visceral afferent, responsible for taste sensation from the anterior two-thirds of the tongue; and general somatic afferent, responsible for cutaneous sensations from the pinna and the external auditory meatus. [16,18,19] .

Affection of the special visceral afferent function of the facial nerve would explain the loss of taste. Facial baroparesis is an ischemic neuropraxia of the facial nerve. It occurs after airplane trips or prolonged diving. As previously reported, commercial aircraft (during level flight) fly at a cruising altitude of 30,000 to 40,000 ft (9144 to 12,192 m), with the pressurization ("compression") of the cabin at 12 psi to 11 psi, which is equivalent to being at an altitude of 5000 to 8000 ft (1524 to 2438.4 m). [4,9,11].

It is known that this pressurization leads to expansion of gas in closed spaces in the body (e.g., the sinuses and middle ear) and non-physiological gas collections. [7,12]

Previous research also showed the higher rate of barodontalgia, barometric pressure-induced dental pain, during pressurized flights possibly because intracabin pressure in the pressurized cabin is still routinely higher than in nonpressurized aircrafts. [15]

A pressure increase in the middle ear of as little as a few feet of seawater (66 cmH₂O) may impede capillary blood flow to the facial nerve traversing the area, leading to ischemic neuropathy. Several promoting factors have been identified, including tubal dysfunction, hypotension, and neurotropic viruses. [6]

Otorhinolaryngological examination is pertinent to excluding middle ear damage. [20]

Our patient most likely had transient Eustachian tube dysfunction, probably related to chronic sinusitis and nasal polyposis. Antibiotics were prescribed by the ENT specialist due to extensive inflammation of the paranasal sinuses, almost completely obstructed with thickened mucosa and mastoid cell secretion on both sides, while ENT examination showed serous secretion and edema of the mucosa. Simple maneuvers that were found to be helpful in

improving this condition include: yawning, swallowing, the Toynbee maneuver (nose pinch followed by swallowing), and Valsalva (exhale against a closed mouth and pinched nose). [5]

7. CONCLUSION

In conclusion, reversible peripheral facial nerve palsy due to a pressure change in the middle ear should be considered in cases where present medical history includes ascent/airplane takeoff or prolonged diving and should not be mistaken for transitory ischemic attack.

8.ABSTARCT

BACKGROUND: Facial baroparesis is reversible palsy of the facial nerve that may occur due to a pressure change in the middle ear when ascending in an airplane or during scuba diving. The objective is to present a rare case of facial paresis during airplane travel.

CASE REPORT: We report a 49-yr-old female patient who presented with a 30-min episode of transient right facial paresis with loss of taste during airplane travel. Brain magnetic resonance imaging (MRI) showed a small left parietal developmental venous anomaly, extensive inflammation of the paranasal sinuses, which were almost completely obstructed with thickened mucosa and mastoid cell secretion bilaterally. Nasal decongestants and antibiotics were prescribed. No new neurological signs or symptoms were noticed.

DISCUSSION: Reversible facial baroparesis due to the pressure change in the middle ear should be considered in cases where present medical history includes ascent/airplane takeoff or prolonged diving and should not be mistaken for transitory ischemic attack.

KEYWORDS : peripheral facial nerve palsy, airplane, Eustachian tube dysfunction, facial baroparesi, facial nerve

9.SUMMARY IN CROATIAN LANGUAGE

Facijalna baropareza uzrokovana je lezijom nervusa facijalisa usljed promjena tlaka u srednjem uhu za vrijeme leta zrakoplovom ili ronjenja.

Prikazana je 49-to godišnju pacijenticu s brojnim komorbiditetima koja je razvila tranzitornu desnostranu perifernu facioparezu za vrijeme međunarodnog zrakoplovnog leta. Navedeno je bilo razlogom prizemljenja i hospitalne dijagnostičke obrade pod sumnjom na akutni cerebrovaskularni incident. Obrada uključujući magnetsku rezonacu glave s angiografijom nije pokazala neurološkog patomorfološkog korelata već opsežne upalne promjene paranazalnih šupljina. Nazalni dekongestivi i antibiotici su bili propisani. Tijekom hospitalizacije i praćenja godinu dana nisu opservirani novi neurološki simptomi niti znakovi. Reverzibilnu facijalnu parezu, kada okolnosti nastanka uključuju let zrakoplovom ili ronjenja tijekom profesionalnih ali i neprofesionalnih aktivnosti, posljedičnu barotraumi facijalnog živca potrebno je diferencijalno dijagnostički razlikovati od tranzitorne ishemijske atake.

10. REFERENCES

1. Ardehali MM, Yazdani N, Heidarali M. Transient facial nerve baroparesis: case report. *Pak J Biol Sci.* 2009; 12(5):476–479.
2. Bell DJ, Gaillard F. Fallopian canal. 2020. [Accessed 26.03]. Available from <https://radiopaedia.org/articles/fallopian-canal>.
3. Bennett DR, Liske E. Transient facial paralysis during ascent to altitude. *Neurology.* 1967; 17(2):194–198.
4. Campbell CD, Smyth MW, Brown L, Kelly E. Air travel for subjects receiving long-term oxygen therapy. *Respir Care.* 2018; 63(3):326–331.
5. Cooper JS, Hexdall EJ. Diving, alternobaric facial paresis. *Treasure Island (FL): StatPearls;* 2020
6. d'Andréa C, Méliet JL, Staikowski F. Paralysies faciales périphériques d'origine dysbarique. *Presse Med.* 2008; 37(4):643–647.
7. Graf J, Stuben U, Pump S. In-flight medical emergencies. *Dtsch Arztebl Int.* 2012; 109:591–601, quiz 602.
8. Grossman A, Ulanovski D, Barenboim E, Azaria B, Goldstein L. Facial nerve palsy aboard a commercial aircraft. *Aviat Space Environ Med.* 2004; 75(12):1075–1076.
9. Hampson NB, Kregenow DA, Mahoney AM, Kirtland SH, Horan KL, et al. Altitude exposures during commercial flight: a reappraisal. *Aviat Space Environ Med.* 2013; 84(1):27–31.
10. Hyams AF, Toynton SC, Jaramillo M, Stone LR, Bryson PJ. Facial baroparesis secondary to middle-ear over-pressure: a rare complication of scuba diving. *J Laryngol Otol.* 2004; 118(9):721–723.
11. Lee JM, Hamilton L, Baumann I, Mellert V, et al. Health effects of airline cabin environments in simulated 8-hour flights. *Aerosp Med Hum Perform.* 2017; 88(7):651–656.
12. Martin-Gill C, Doyle TJ, Yealy DM. In-flight medical emergencies: a review. *JAMA.* 2018; 320(24):2580–2590.
13. Mirza S, Richardson H. Otic barotrauma from air travel. *J Laryngol Otol.* 2005; 119(5):366–370.
14. Molvaer OI, Eidsvik S. Facial baroparesis: a review. *Undersea Biomed Res.* 1987; 14(3):277–295.
15. Nakdimon I, Zadik Y. Barodontalgia among aircrew and divers. *Aerosp Med Hum Perform.* 2019; 90(2):128–131.
16. Phillips CD, Bubash LA. The facial nerve: anatomy and common pathology. *Semin Ultrasound CT MR.* 2002; 23(3):202–217.

17. Rutten MH, Kunst HPM. Facial nerve palsy in aviation facial baroparesis. *Journal of International Advanced Otolaryngology*. 2010; 6(2):277–281.
18. Seneviratne SO, Patel BC. Facial nerve anatomy and clinical applications. Treasure Island (FL): StatPearls; 2020.
19. Takezawa K, Townsend G, Ghabriel M. The facial nerve: anatomy and associated disorders for oral health professionals. *Odontology*. 2018; 106(2):103–116.
20. Van Hoecke H, Calus L, Dhooge I. Middle ear damages. *B-ENT* 2016; Suppl. 26(1):173–183.
21. Zadik Y, Drucker S. Diving dentistry: a review of the dental implications of scuba diving. *Aust Dent J*. 2011; 56(3):265–271

11. ŽIVOTOPIS

Osobni podatci:

Ime i prezime: Kristina Mikuš

Datum i mjesto rođenja: 11.svibanj 1987., Osijek

Adresa: V.Rastovac 17, Hrastovac

Email: kristina.mikus1@gmail.com

Obrazovanje :

1994. – 2002. Osnovna škola Milka Cepelića, Vuka

2002. - 2006. I. gimnazija, Osijek

2007.- 2013. Medicinski fakultet Osijek, smjer: doktor medicine

2009. i 2010. sudjelovala na Festivalu znanosti

2015.- 2020. specijalizacija neurologije OB Virovitica

Radno iskustvo :

2009./2010. demonstrator na vježbama iz predmeta Histologije i embriologije

2010. liječnik volonter u Klinici za liječenje, rehabilitaciju i prevenciju bolesti srca i krvnih žila- Thalassotherapia Opatija

04.02.2021. liječnik specijalista neurolog OB Virovitica

Popis radova :

Reversible Peripheral Facial Nerve Palsy During Airplane Travel. *Aerosp Med HumPerform.*2020; 91(8): 679-681.

Učestalost karotidnih stenoza u bolesnika s akutnim ishemijskim moždanim udarom (Frequency

of carotid stenoses in patients with ischemic stroke); CROSB I [internet]. [cited 2013 July].

Available from:: <https://www.bib.irb.hr/641197>