

Retroperitoneal and metachronous testicular germ cell tumors with different histology and teratoma growing syndrome - a case report

Rakušić, Zoran; Mišir Krpan, Ana; Mareković, Zvonimir; Juretić, Antonio; Gašparov, Slavko

Source / Izvornik: **Collegium Antropologicum, 2011, 35, 937 - 940**

Journal article, Published version

Rad u časopisu, Objavljena verzija rada (izdavačev PDF)

Permanent link / Trajna poveznica: <https://urn.nsk.hr/urn:nbn:hr:105:065486>

Rights / Prava: [In copyright](#) / [Zaštićeno autorskim pravom.](#)

Download date / Datum preuzimanja: **2025-03-29**



Repository / Repozitorij:

[Dr Med - University of Zagreb School of Medicine
Digital Repository](#)



Retroperitoneal and Metachronous Testicular Germ Cell Tumors with Different Histology and Teratoma Growing Syndrome – A Case Report

Zoran Rakušić¹, Ana Mišir Krpan¹, Zvonimir Mareković², Antonio Juretić¹ and Slavko Gašparov³

¹ University of Zagreb, Zagreb University Hospital Center, Department of Oncology, Zagreb, Croatia

² University of Zagreb, Zagreb University Hospital Center, Department of Urology, Zagreb, Croatia

³ University of Zagreb, »Mercur« University Hospital, Department of Pathology, Zagreb, Croatia

ABSTRACT

It is presented a case of a 32-year-old male with the three primary tumors diagnosed within a time period of 3 years; retroperitoneal nonseminoma in 2002, retroperitoneal mature teratoma in 2004, and metachronous testicular seminoma in 2005. We discuss the unusual presentation of these three rare events occurring in the same patient without known risk factors.

Key words: *extragonadal germ cell tumor, metachronous testicular tumor, teratoma growing syndrome*

Introduction

In a last few decades it was achieved a great success in GCT (germ cell tumors) treatment with more than 90% of patients are being cured, but unfortunately this was not paralleled with better understanding of disease etiology. The incidence of testicular cancer has almost doubled in most Western countries over the last 25 years. Temporal and geographic variation in incidences strongly suggests environmental etiologic factors. The increasing incidence has paralleled decline in semen quality over the last several decades. It has been hypothesized that both testicular cancer and male subfertility may be caused by intrauterine exposure of the developing male embryo to factors that alter the hormonal balance. There is also evidence of genetic component to the development of testis cancer.

Case Report

A 32-year-old man was admitted to our hospital in year 2002 to evaluate an asymptomatic, palpable abdominal mass, approximately 7 cm in diameter, located on the right side of umbilicus. Computed tomography (CT) showed an aorto-caval retroperitoneal tumor which spread out into the iliac blood vessels on the right side. There

was no evidence of tumor in the testes by testicular palpation or echography.

Surgical extirpation of tumor was performed in August 2002. The diagnosis was retroperitoneal extragonadal nonseminoma with predominantly yolk-sac tumor with elements of embryonal carcinoma (Figure 1). Alpha-fetoprotein (AFP) was highly positive in pathological specimen. Postoperative AFP in serum was 2,892 kIU/L; lactate dehydrogenase (LDH) was within normal limits, as well as human chorionic gonadotropin (HCG). Postoperative CT revealed enlarged retroperitoneal lymph nodes.

The patient was advised for sperm banking. Sperm analysis confirmed normozoospermia. Patient has negative family history in relation to germ cell tumors, and he denies cryptorchidism in childhood; patient was not tested for chromosomal abnormality. He became a father of one child before onset of the disease.

Four courses of adjuvant chemotherapy BEP (bleomycin, etoposide and cisplatin) were performed. Complete remission was achieved.

After three months, retroperitoneal MRI still showed enlarged retroperitoneal lymph nodes; AFP and HCG were within normal limits. Retroperitoneal lymphaden-

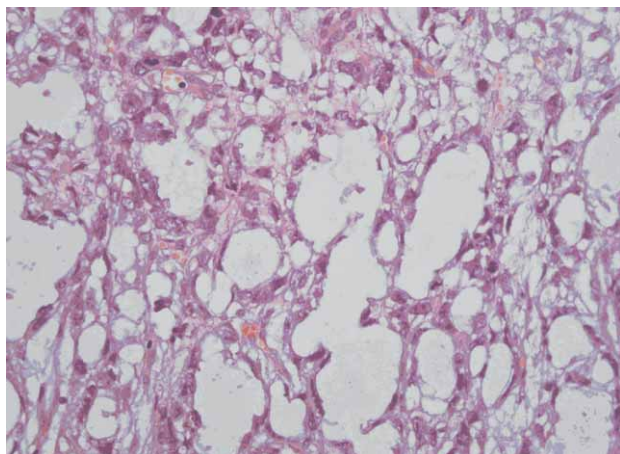


Fig. 1. Glandular-alveolar pattern of Yolk-sac tumour (irregular alveolar and gland-like spaces lined by flattened to cuboid cells). H&E x 40.

ctomy was performed in February 2004. Histopathology diagnosis was mature teratoma.

In September 2005, he noticed a lump in his right testicle. Radical right inguinal orchiectomy was performed. Pathological tests showed pure seminoma limited to the testis with the elements of intratubular germ-cell neoplasia (Figure 2), stage IA, pT1N0M0. LDH, HCG and AFP levels were not elevated. To reduce risk of relapse, we administered two cycles of VIP (cisplatin, etoposide, ifosfamide) chemotherapy and he was followed up (radiotherapy was avoided due to potential adverse effects-previous retroperitoneal operations).

After 2 years CT showed a new retroperitoneal tumor mass (Figure 3). FDG-PET demonstrated a significant radiotracer uptake in this tumor. US of the remaining left testis was normal. Tumor markers AFP, HCG and LDH were also normal. In year 2007, for the third time, retroperitoneal surgery was performed (second retroperitoneal tumor extirpation). Metastatic seminoma was diagnosed, and the patient received four cycles of VIP chemotherapy.

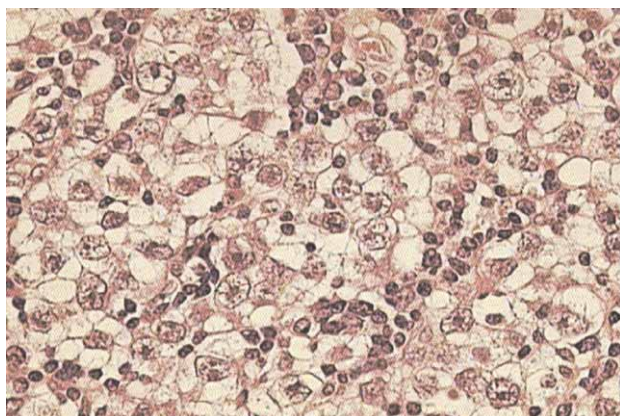


Fig. 2. Histopathological examination: seminoma, H&E x 40.

Six months later, PET showed a small focus of radiotracer uptake retroperitoneally and in left testis. It was decided to proceed with surgical exploration of solitary left testis, and intra-operative biopsy did not confirm malignant tumor (July 2008).

We decided to follow-up the patient. Up to now all laboratory findings and tumor markers have been normal, CT scans and PET/CT done in February 2010 were without signs of disease.

He has an excellent performance status without any major health problems eight years from the beginning of the treatment (Figure 4). Since surgery in 2004 he did not have ejaculation, but in last six months he has ejaculation again; however, the ejaculatory volume was decreased.

Patient has negative family history in relation to germ cell tumors, he denies cryptorchidism in childhood and was not tested for chromosomal abnormality, for example Klinefelter's syndrome, that has been associated with extragonadal GCT with highest frequency¹. Our patient became a father of one child before onset of the disease.

Discussion

Although germ cell tumors (GCT) are relatively uncommon tumors comprising only 2% of all human malignancies, they constitute the most common solid tumor in men between ages of 15 and 34 years. Germ cell tumors arise 95% in testes and remaining 5% are of extragonadal origin.

Primordial germ cells migrate by the fifth week of gestation through the mesentery to the gonadal ridge. Extragonadal tumors are presumed to arise from germ cells that have migrated aberrantly. Another hypothesis is that these tumors arise from totipotent embryonal cells that have escaped the influence of embryonic organizers controlling normal differentiation.

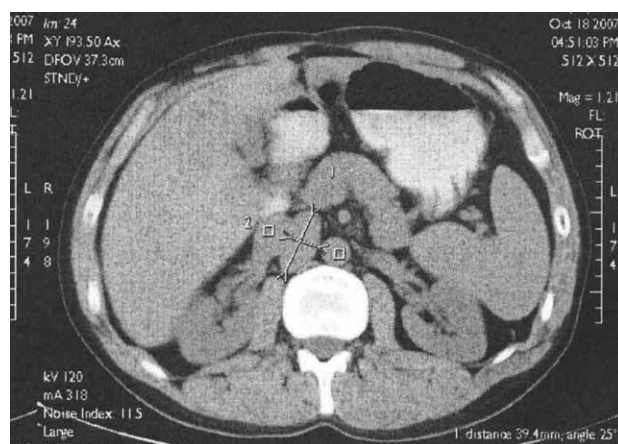


Fig. 3. Abdominal MSCT with metastatic lymph node disease (year 2007).

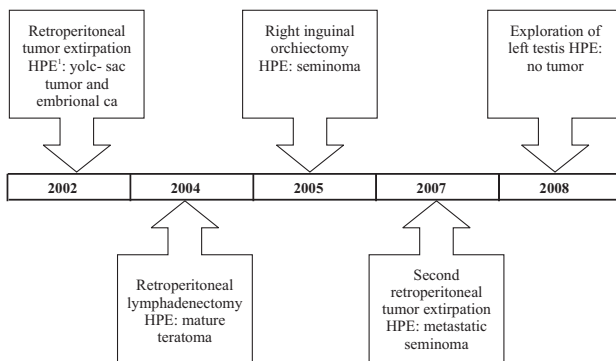


Fig. 4. Timeline with course of disease; ¹Histopathological examination.

It is a known fact that patients with testis germ cell tumor (TGCT) have increased risk for developing contralateral testis tumor as well. Most bilateral TGCT develop metachronously and are seminomas. Both synchronous and metachronous bilateral TGCT have similar, excellent prognosis. Patients with unilateral TGCT require careful long-term monitoring of the remaining testicle due to a 26-fold increased risk for contra-lateral disease and a potentially long risk interval of up to 25 years². The most reported incidence of metachronous bilateral testes tumors is between 2–4%²⁻⁴.

Even rarer is incidence for metachronous testicular germ cell tumor with primary extragonadal germ cell tumors (EGCT). Patients with EGCTs, particularly those with retroperitoneal or nonseminomatous tumors, are at an increased risk for metachronous testicular cancer. In Hartmann's retrospective study, 4.1% of patients developed metachronous testicular tumor⁵.

Various studies have suggested the presence of an inherited predisposition for the development of these tumors. Completion of the human gene map and advances in genetic research will facilitate further investigation of genetic predisposition to GCT. Insight of GCT inheritance might lead to the identification of individuals at increased risk for developing the disorder, increase our understanding of the mutation pathways that lead to sporadic cases, and contribute to improvement in diagnosis and treatment. Clinicians should record the family history of cancer and urogenital differentiation defects in patients with GCT⁶.

REFERENCES

1. AGUIRRE D, NIETO K, LAZOS M, PEÑA YR, PALMA I, KOFMAN-ALFARO S, QUEIPO G, Hum Pathol, 37 (2006) 477. — 2. AKDOGAN B, DIVRIK RT, TOMBUL T, YAZICI S, TASAR C, ZORLU F, OZEN H, J Urol, 178 (2007) 129. — 3. KLATTE T, DE MARTINO M, ARENSMEIER K, REIHER F, ALLHOFF EP, KLATTE D, Int J Urol, 15 (2008) 821. — 4. FOSSÁ SD, CHEN J, SCHONFELD SJ, MCGLYNN KA, MCMASTER ML, GAIL MH, TRAVIS LB, J Natl Cancer Inst, 97 (2005) 1056. — 5. HARTMANN JT, J NATL Cancer Inst, 93 (2001) 22. — 6. HOLZIK MF, SLJMONS RH, HOEKSTRA-WEEBERS JE, SLEIJFER DT, HOEK-

STRA HJ, Hered Cancer Clin, 6 (2008) 3. — 7. LOGOTHETIS CJ, SAMUELS ML, TRINDADE A, JOHNSON DE, Cancer, 50 (1982) 1629. — 8. GORBATTY V, SPIESS PE, PISTERS LL, Indian J Urol, 25 (2009) 186. — 9. ANDRÉ F, FIZAZI K, CULINE S, DROZ J, TAUPIN P, LHOMMÉ C, TERRIER-LACOMBE M, THÉODORE C, Eur J Cancer, 36 (2000) 1389. — 10. HASHIMOTO K, FUJIMOTO H, KOUNO T, KOSEKI M, YONEMORI K, HIRATA T, YUNOKAWA M, SHIMIZU C, KATSUMATA N, TAMURA K, ANDO M, TAKEUCHI M, NAKANISHI H, KOMIYAMA M, NAKAGAWA T, FUJIWARA Y, Urol Oncol, 2010 [Epub ahead of print].

In case of our patient, his first diagnosis was an extragonadal germ cell tumor. Pretreatment testicular biopsy was not performed because it is still a controversial issue. After surgical treatment and adjuvant cisplatin based chemotherapy, normalization of tumor marker and complete radiological response was achieved, but very shortly it became evident that retroperitoneal mass actually increased in size. Due to patohistological diagnosis of mature teratoma that appeared after successful treatment of nonseminoma, we concluded that this condition represented growing teratoma syndrome (GTS).

Growing teratoma syndrome was first described by Logothetis et al. in 1982 and was characterized by enlarging metastases of nonseminoma germ cell tumors despite appropriate chemotherapy and normalized serum markers. The prevalence was only 1.9–7.6%⁷. Despite the fact that most authors describe GTS in metastatic lesions of nonseminoma germ cell tumors, it also has been observed in primary tumors^{8,9}. Since GTS is a rare event it should be kept in mind treating nonseminoma patients.

According to analysis of Hashimoto and colleagues, HCG was a significant marker in all five reported cases, that led to detection of MTGCT¹⁰, but in our case HCG was normal during the whole course of disease, even in the retroperitoneal seminoma metastases.

We have a patient with three very rare events: extragonadal nonseminoma, metachronous gonadal seminoma and teratoma growing syndrome. Eight years from the beginning of disease he has no signs of disease or major health problems. His quality of life is excellent.

Patients with this kind of medical history require long-term close monitoring due to increased risk for contralateral testis tumors, other possible germ cell tumors or secondary tumors induced by chemotherapeutic drugs. There is also a great importance of patient's education and self-examination of testis. According to literature review, this is the 25th case of metachronous testicular tumor developing after retroperitoneal EGCT, but to our knowledge this may be the first case report published, in which two germ cell tumors with different histology occurred metachronously together with teratoma growing syndrome.

Z. Rakušić

University of Zagreb, Zagreb University Hospital Center, Department of Oncology, Kišpatićeva 12, 10 000 Zagreb, Croatia

e-mail: zoran.rakusic1@zg.htnet.hr

RETROPERITONEALNI I METAKRONI GERMINATIVNI TUMORI TESTISA RAZLIČITE HISTOLOGIJE I SINDROM RASTUĆEG TERATOMA – PRIKAZ SLUČAJA

S A Ž E T A K

Prikazujemo slučaj 32-godišnjeg bolesnika kod kojeg je unutar tri godine postavljena dijagnoza tri primarna tumora različite histologije: retroperitonealni neseminoma 2002. godine, retroperitonealni zreli teratom 2004. godine i metakroni seminom testisa 2005. godine. Ovdje raspravljamo o neobičnoj pojavi tri rijetka događaja u istog bolesnika bez poznatih rizičnih čimbenika.