

Isolated splenic metastasis from colorectal carcinoma in a high risk patient: a case report

Pavlović, Mirjana; Šeparović, Robert; Vukelić-Marković, Mirjana; Patrlj, Leonardo; Kolovrat, Marijan; Kopljar, Mario; Babić, Nenad; Košuta, Dragutin; Babić, Žarko

Source / Izvornik: **Collegium Antropologicum, 2011, 35, 1307 - 1310**

Journal article, Published version

Rad u časopisu, Objavljena verzija rada (izdavačev PDF)

Permanent link / Trajna poveznica: <https://um.nsk.hr/um:nbn:hr:105:253827>

Rights / Prava: [In copyright](#)/[Zaštićeno autorskim pravom.](#)

Download date / Datum preuzimanja: **2025-01-28**



Repository / Repozitorij:

[Dr Med - University of Zagreb School of Medicine Digital Repository](#)



Isolated Splenic Metastasis from Colorectal Carcinoma in a High Risk Patient: A Case Report

Mirjana Pavlović¹, Robert Šeparović¹, Mirjana Vukelić-Marković², Leonardo Patrij³, Marijan Kolovrat³, Mario Kopljar³, Nenad Babić⁴, Dragutin Košuta⁵ and Žarko Babić⁶

¹ University of Zagreb, School of Medicine, »Sestre Milosrdnice« University Hospital Center, Department for Internistic Oncology and Chemotherapy, Zagreb, Croatia

² University of Zagreb, School of Medicine, Dubrava University Hospital, Department of Radiology, Zagreb, Croatia

³ University of Zagreb, School of Medicine, Dubrava University Hospital, Department of Surgery, Division of Abdominal surgery, Zagreb, Croatia

⁴ University of Zagreb, School of Medicine, »Sestre Milosrdnice« University Hospital Center, Department of Radiology, Zagreb, Croatia

⁵ University of Zagreb, School of Medicine, »Sv. Duh« University Hospital, Department of Surgery, Division of Abdominal surgery, Zagreb, Croatia

⁶ University of Zagreb, School of Medicine, Dubrava University Hospital, Department of Internal medicine, Division of Gastroenterology, Zagreb, Croatia

ABSTRACT

Isolated splenic metastasis arising from a colorectal carcinoma is a rare finding. We report a case of 74-year-old man with a medical history of diabetes type II and paroxysmal atrial fibrillation, who underwent a right hemicolectomy for an adenocarcinoma of caecum in August 2004. In June 2007 the patient was diagnosed with high grade aortic valve stenosis as well as long segment stenosis of the first obtuse marginal branch of left coronary artery. He was suggested aortic valve replacement with coronary artery bypass grafting but he refused the surgery. In October 2007 the patient underwent a 18FDG – PET scanning, due to increasing values of CEA serum level, which showed a 5 cm big isolated hypermetabolic lesion in the spleen. Due to operative risk, splenectomy was refused by surgeons. The patient underwent a chemotherapy with capecitabine in total of 8 cycles before his CEA level began to rise and MSCT showed a progression in size of splenic metastasis. The patients condition was reevaluated by a team of experts and splenectomy was performed in September 2008. In May 2009 during the postoperative follow up, MSCT scanning revealed enlarged lymph nodes in celiac region and hepatic lesion suspicious of metastasis and the patient was admitted for further chemotherapy treatment. There is still no standardized treatment for this condition due to small number of cases reported in literature. Splenectomy followed by chemotherapy seems to be an optimal treatment but still no final conclusions can be made.

Key words: splenic metastasis, colorectal cancer, splenectomy, Zagreb, Croatia

Introduction

Spleen is an uncommon sight of metastasis of colorectal carcinoma and when diagnosed it is usually a manifestation of disseminated disease¹. In November 2007, group of Italian authors published a case report with a literature review in which they reported only 42 cases of isolated splenic metastases originated from colorectum since the first reported case in 1969^{2,3}. Isolated splenic metastases are very rare due to anatomic factors and the inhibitory effect of the splenic microenvironment on the

growth of metastatic cells⁴. The diagnose of solitary splenic metastasis is usually made by the imaging studies in the postoperative follow – up period during the evaluation of rising CEA level⁵. Long-term survival after splenectomy, which is a preferred treatment in these patients, varied up to 7 years. Considering the fact that splenic metastases are a form of distant visceral metastasis, prognosis is rather optimistic⁶⁻⁸. We report the case of isolated splenic metastasis from colonic carcinoma in a

patient with severe comorbidities which were the reason for postponed splenectomy. To the best of our knowledge, this is a second case of isolated splenic metastasis reported in our country⁹ and first case of splenic metastasis associated with postponed therapeutical splenectomy due to severe comorbidities reported in a literature.

Case Report

A 74-year-old man with medical history of diabetes type II and paroxysmal atrial fibrillation had had a right hemicolectomy for an adenocarcinoma of the caecum in August 2004. The tumor was clinically staged as Dukes C and the patient underwent a postoperative adjuvant chemotherapy with Mayo protocol (five cycles of 5-fluorouracil+Leucovorine in doses of 425 mg/m² and 20 mg/m²

daily for five days). After fifth cycle patient developed febrile neutropenia and pneumonia so the last sixth cycle was not indicated. He was followed up every six months with serum CEA level and abdominal ultrasound. In May 2007 his serum CEA level had risen to 38.6 mg/L and abdominal MSCT demonstrated a hypovascular lesion in a third segment of liver, which was unchanged in the comparison to postoperative MSCT scan result. An ultrasound guided needle biopsy was performed and cytological analysis did not reveal malignant cells. Chest CT scan and skeleton X-ray were unremarkable. An extensive diagnostic workup did not reveal any signs of tumor dissemination nor signs of another primary malignant lesion. Due to intermittent chest pain the invasive cardiac examination was performed in June 2007 and the patient was diagnosed with high grade aortic valve stenosis (gradient over aortic valve was 80 mmHg) as well as long seg-

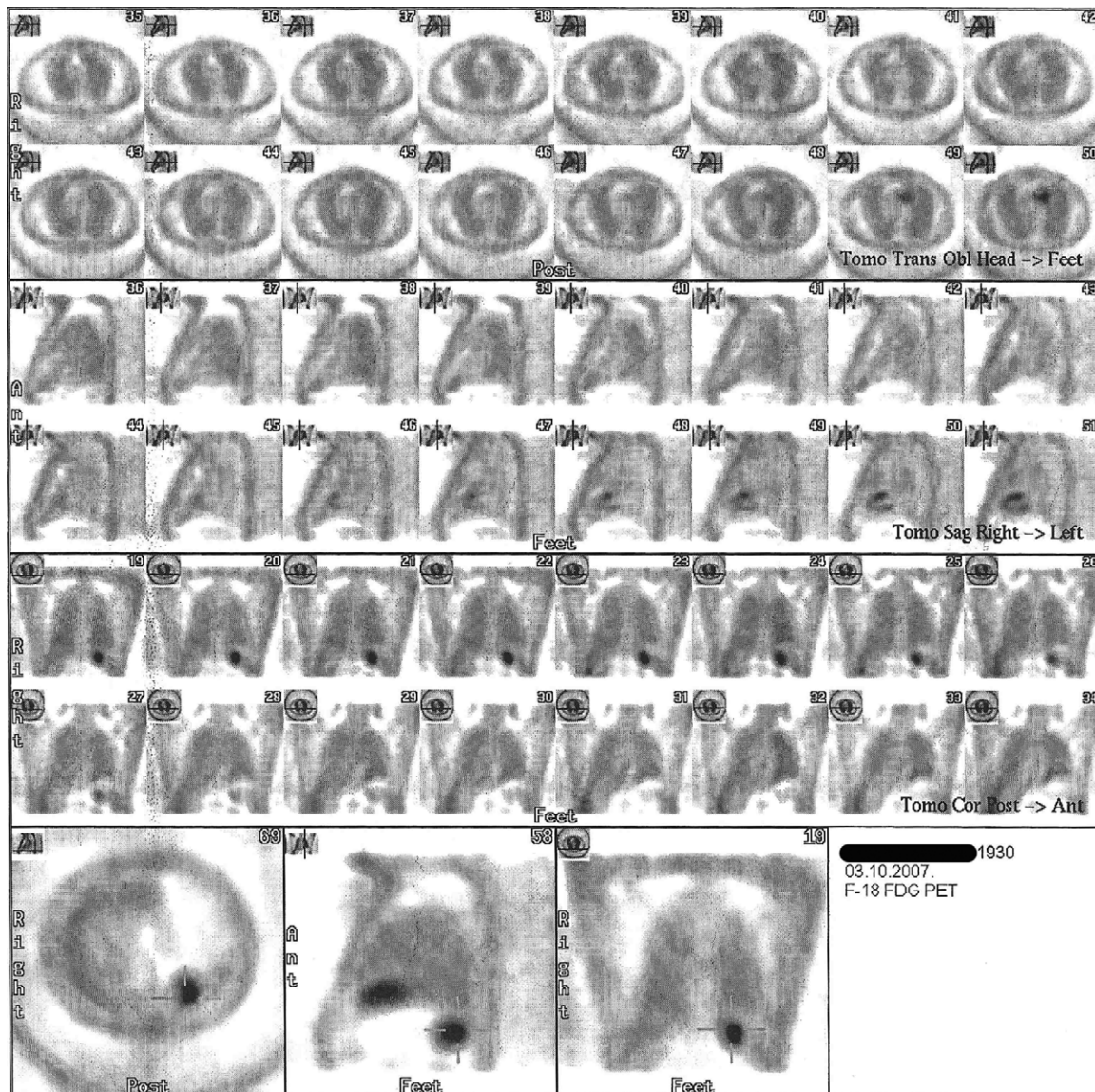


Fig. 1. F - 18 FDG PET scan demonstrating a hypermetabolic area in upper left abdomen (splenic projection area).

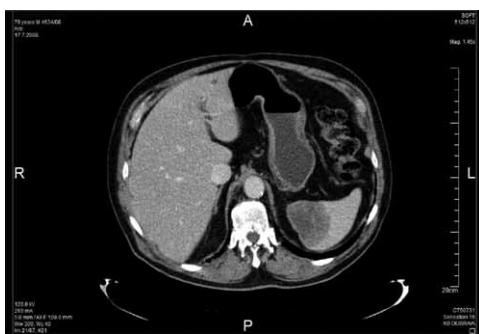

Fig. 2. MSCT demonstrates a low – attenuation area in the splenic area.

ment stenosis of the first obtuse marginal branch of left coronary artery. The patient was suggested aortic valve replacement with coronary artery bypass grafting but he refused the surgery. In October 2007 the patient underwent a 18FDG – PET scanning, which showed a 5 cm big isolated hypermetabolic lesion in the spleen. No other remote organ metastases were found by PET scanning (Figure 1). Splenectomy was considered but, due to patients serious heart condition and operative risk, it was rejected by surgeons. Oncologist indicated monotherapy with capecitabine due to patients performance status (ECOG 1–2) and severe comorbidities. The patient underwent a first line chemotherapy for metastatic colorectal cancer with capecitabine (total of 8 cycles of Xeloda in a dose of 2000 mg/m² from December 2007 to June 2008). Serum CEA level, before starting the chemotherapy, was 245.8 mg/L. He was followed up with serum CEA level and abdominal MSCT every two cycles and through the first seven cycles there were no signs of radiological and biochemical progression of the disease. MSCT performed after eight cycle showed a progression in size of splenic metastasis to 6 cm and CEA level increase to 363 mg/L (Figure 2). Chemotherapy was stopped as it proved to be ineffective. Due to the fact that the spleen was still the only sight of the disease splenectomy was reconsidered. A group of hospital experts including gastroenterologists, surgeons, cardiologists and anesthesiologists discussed the case and decided to offer surgical treatment to the patient giving him all the informations about high risks of this treatment. The patient accepted the risk and underwent splenectomy in September 2008, almost a year after a first diagnosis of splenic metastasis. Pathohistological analysis of the resected spleen confirmed a metastatic lesion composed of well – differentiated adenocarcinoma cells, 70 mm in diameter, with necrosis in the center. The postoperative recovery was uneventful. In May 2009 during the postoperative follow up, MSCT scanning revealed enlarged lymph nodes in celiac region and hepatic lesion suspicious of metastasis. A cytopunction of enlarged lymph node was performed and the result was positive to malignant cells. The patient was admitted to hospital for further chemotherapy treatment.

Discussion

An isolated splenic metastases from colorectal cancer are a rare finding in a clinical practice. In 1974 Berge conducted an autopsy examination on 7165 cases with various cancers and reported an incidence of splenic metastases as 7.1%, 1019 were cases of colorectal carcinoma with incidence of splenic metastasis of 4.4%¹. An incidence of isolated splenic metastases was not reported. A previous studies suggest a few mechanisms which prohibit the growth of the tumour cells in spleen, including anatomical, immunological and pathohistological features of the spleen. Tumour cells might disseminate to spleen haematogenously by retrograd diffusion through inferior mesenteric vein¹⁰, or through the lymphatic system¹¹. The sharp angle of the splenic artery with the celiac axis, rythmic contraction by the sinusoidal splenic architecture and absence of afferent lymphatics to the spleen are considered to be limiting factors from anatomical point of view^{7,12}. Immunological characteristics of the spleen, as the second largest organ of the reticuloendothelial system, with profuse monocytes, immunoglobulin synthesis and opsonin production, are also considered responsible for inhibiting tumour cell proliferation¹³. The diagnosis of splenic metastasis can be made by imaging studies during the diagnostic workup for colorectal cancer⁵. The literature review shows that majority of reported patients with isolated splenic metastasis were asymptomatic at the time of diagnosis and the only sign of active disease was elevated carcinoembryonic antigen (CEA) level. As Kim JC suggested in his studies, CEA appears as an immunosuppressant and acts as an adhesion molecule between cancer cells and visceral macrophages, so colonic tumour cells with positive CEA staining should behave more aggressive and could be associated with the occurrence of isolated splenic metastases^{12,14}. The majority of patients with isolated metachronous splenic metastasis reported in the literature underwent curative splenectomy and long – term survival varied from 0.5 to 7 years^{6–8}. Most of previously mentioned patients have had a disease free survival of 3 to 144 months after the primary colorectal tumour^{6,15}. It is been reported that the patients with synchronous splenic metastasis have much worse prognosis and shorter disease free survival^{2,6}.

Conclusion

Isolated splenic metastasis from colonic cancer is a rarity in clinical practise. There is no standardized treatment for this condition due to small number of cases reported in literature. Splenectomy followed by chemotherapy tends to be an optimal therapeutical approach but still no final conclusions can be made.

Acknowledgements

No sources of funding were used in the preparation of this case report.

REFERENCES

1. BERGE T, Acta Pathol Microbiol Scand A, 82 (1974) 499. — 2. PISANU A, RAVARINO A, NIEDDU R, UCCHEDDU A, World J Gastroenterol, 13 (2007) 5516. — 3. DUNBAR WH, BEAHR OH, MORLOCK CG, Mayo Clin Proc, 44 (1969) 40. — 4. COMPERAT E, BARDIER-DUPAS A, Arch Pathol Lab Med, 131 (2007) 965. — 5. GENCOSMANOGLU R, AKER F, KIR G, TOZUN N, World J Surg Oncol, 4 (2006) 42. — 6. AVESANI EC, CIOFFI U, DE SIMONE M, BOTTI F, CARRARA A, FERRERO S, Am J Clin Oncol, 24 (2001) 311. — 7. OKUYAMA T, OYA M, ISHIKAWA H, Jpn J Clin Oncol, 31 (2001) 341. — 8. WEATHERS K, MODESTO VL, GORDON D, Dis Colon Rectum, 42 (1999) 1345. — 9. BUSIĆ Z, CUPURDIJA K, KOLOVRAT M, ČAVKA V, ČAVKA M, PATRLJ L, SERVIS D, KVESIĆ A, Coll Antropol, 34 (2010) 287. — 10. INDUDHARA R, VOGT D, LEVIN HS, CHURCH J, South Med J, 90 (1997) 633. — 11. CAVALLARO A, MODUGNO P, SPECCHIA M, PONTENZA AE, LOSCHIAVO V, COLLI R, LAURIOLA L, BARONE C, J Exp Clin Cancer Res, 23 (2004) 143. — 12. KIM JC, JEONG CS, KIM HC, YU CS, KANG GH, LEE MG, J Korean Med Sci, 15 (2000) 355. — 13. GABIZON A, SMALL M, TRAININ N, Int J Cancer, 18 (1976) 813. — 14. KIM JC, HAN MS, LEE HK, KIM WS, PARK SK, PARK KC, BODMER WF, ROWAN AJ, KIM OJ, Dis Colon Rectum, 42 (1999) 640. — 15. GENNA M, LEOPARDI F, VALLONCINI E, MOLFETTA M, DE MANZONI G, CASTELLI A, Minerva Chir, 58 (2003) 811.

Ž. Babić

University of Zagreb, School of Medicine, »Dubrava« University Hospital, Department of Internal Medicine, Division of Gastroenterology, Avenija Gojka Šuška 6, 10000 Zagreb, Croatia
e-mail: zarko.babic@zg.t-com.hr

IZOLIRANA METASTAZA KOLOREKTALNOG KARCINOMA U SLEZENU U VISOKORIZIČNOG BOLESNIKA: PRIKAZ SLUČAJA

SAŽETAK

Izolirane metastaze kolorektalnog karcinoma u slezenu su rijetkost. U članku prezentiramo slučaj 74-godišnjeg muškarca s poznatom anamnezom dijabetesa tipa II i paroksizmalne fibrilacije atrijske, kojemu je, u kolovozu 2004. godine, učinjena desnostrana hemikolektomija zbog adenokarcinoma cekuma. U lipnju 2007. godine bolesniku je dijagnosticirana teška aortalna stenoza, kao i dugopotezna stenoza prve marginalne grane lijeve koronarne arterije. Predložena mu je operacija zamjene aortnog zaliska uz aortokoronarno premoštenje, no odbio je operativni zahvat. U listopadu 2007. godine bolesniku je, zbog porasta vrijednosti serumskog CEA, učinjen 18FDG – PET sken koji je pokazao 5 cm veliku izoliranu hipermetaboličku leziju u slezeni. Slučaj je prezentiran kirurzima koji se, zbog komorbiditeta i operativnog rizika, nisu odlučili za zahvat splenektomije. Provedena je kemoterapija kapecitabinom u 8 ciklusa nakon čega su vrijednosti serumskog CEA ponovno počele rasti, a kontrolni MSCCT je pokazao progresiju veličine metastaze. Tim stručnjaka je reevaluirao cijeli slučaj te je u rujnu 2008. godine bolesniku učinjena splenektomija. U svibnju 2009. godine, tijekom postoperativnog praćenja, kontrolni MSCCT je pokazao uvećane limfne čvorove u celijačnoj regiji i suspektu jetrenu metastazu nakon čega je bolesnik hospitaliziran na daljnje kemoterapijsko liječenje. Još uvijek ne postoji standardizirano liječenje predviđeno za ovakve bolesnike zahvaljujući malom broju slučajeva koji su opisani u literaturi. Splenektomija praćena kemoterapijom je vjerojatno optimalan slijed liječenja, ali konačni zaključci, odnosno smjernice liječenja, se još ne mogu donijeti.