

Clear cell variant of urothelial carcinoma in urinary bladder; a clinicopathological and immunohistochemical study - a case report

Peršec, Zoran; Buković, Damir; Peršec, Jasminka; Rako, Duje; Ljubanović, Danica; Starčević, Vito; Župić, Tomislav; Pavić, Mato

Source / Izvornik: **Collegium Antropologicum, 2012, 36, 1045 - 1047**

Journal article, Published version

Rad u časopisu, Objavljena verzija rada (izdavačev PDF)

Permanent link / Trajna poveznica: <https://urn.nsk.hr/urn:nbn:hr:105:014616>

Rights / Prava: [In copyright](#) / [Zaštićeno autorskim pravom.](#)

Download date / Datum preuzimanja: **2024-07-18**



Repository / Repozitorij:

[Dr Med - University of Zagreb School of Medicine Digital Repository](#)



Clear Cell Variant of Urothelial Carcinoma in Urinary Bladder; a Clinicopathological and Immunohistochemical Study – A Case Report

Zoran Peršec¹, Damir Buković², Jasminka Peršec³, Duje Rako¹, Danica Ljubanović⁴, Vito Starčević², Tomislav Župić² and Mato Pavić²

¹ University of Zagreb, Dubrava University Hospital, Department of Urology, Zagreb, Croatia

² University of Zagreb, Zagreb University Hospital Center, Department of Obstetrics and Gynecology, Zagreb, Croatia

³ University of Zagreb, Dubrava University Hospital, Anesthesiology, Resuscitation and Intensive Care Medicine Clinic, Zagreb, Croatia

⁴ University of Zagreb, Dubrava University Hospital, Department of Pathology, Zagreb, Croatia

ABSTRACT

The clear cell variant urothelial carcinoma of urinary bladder is very rare and unusual neoplasm defined histologically by clear cell pattern and glycogen-rich cytoplasm. Our case of clear cell carcinoma was diagnosed with immunohistochemistry stain. A 72-year-old man, presented with painless macroscopic hematuria in November 2007. Evaluation revealed papillary tumor in urinary bladder. A transurethral resection of the bladder tumor (TUR-Bt) was performed. Histopathologic evaluation showed superficial transitional cell carcinoma and carcinoma in situ. On three month follow-up, a solitary pedunculated tumor was detected again in the left wall of the urinary bladder. A repeated transurethral resection of the bladder tumor (reTUR-Bt) was performed in February 2008. The pathological diagnosis was difficult due to diffuse clear cell appearance. Immunohistochemistry stain showed urothelial carcinoma and finally it was diagnosed as clear cell variant. Urothelial carcinoma has many variants that show a variety of appearances and characteristics. These should be well known for evaluation and optimal treatment.

Key words: clear cell variant of urothelial carcinoma, urinary bladder; immunohistochemistry stain

Introduction

The clear cell variant of urothelial carcinoma is defined by clear cell pattern and glycogen-rich cytoplasm¹. This cells pattern may be either focal or extensive in tumor component¹.

The potential for divergent differentiation within urothelial cell carcinoma includes squamous, trophoblastic, glandular, and small cell differentiation, but today very little is known about many urothelial variant of carcinoma. The WHO histological classification for urothelial carcinoma has already described nine variants¹. Their appearance and progression is very characteristic and almost all variants predict for poor prognoses². In our case, we diagnosed clear cell variant superficial urothelial carcinoma of urinary bladder using immunohistochemicals staining.

This is one of many variants of urothelial carcinoma in the urinary bladder in the same patients.

Case Report

A 72-year-old man was admitted in emergency unit of Dubrava University Hospital in November 2007 with painless macroscopic hematuria. In evaluation, papillary tumor was detected in urinary bladder. We performed transurethral resection of the bladder tumor (TUR-Bt). Histopathologic evaluation showed high grade superficial transitional cell of urinary bladder and carcinoma in situ (Figure 1). On follow-up, a papillary pedunculated tumor was detected after three months in the left wall of the urinary bladder. A recurrence transurethral resection of

the bladder tumor (reTUR-Bt) was performed in February 2008. The pathological diagnosis was difficult due to diffuse clear cell appearance. Immunohistochemistry stain showed urothelial carcinoma.

Computerized tomography (CT) of abdomen and pelvis did not show progression or metastasis of tumor.

Macroscopic features showed the tumor in size 1cm, described as solitary pedunculated mass involving left wall of the bladder.

Microscopic examination of the specimen showed superficial non invasive, diffuse clear cytoplasm with severe nuclear atypia and alveolar growth pattern (Figure 2). Compared to the first pathological analysis that showed high grade papillary tumor, now we found tumor cells with clear cytoplasm. At first biopsy, when we performed immunohistochemical staining, a result was specific for urothelial carcinoma (cytokeratin 7, cytokeratin 20, cytokeratin 34betaE12, vimentin and carcinoembryonic antigen /CEA/). Immunohistochemical staining at second biopsy showed strongly positive stain with

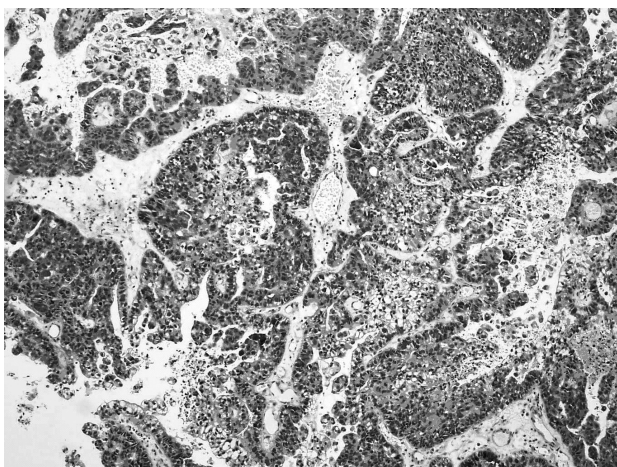


Fig. 1. Urothelial carcinoma of urinary bladder (HEx100).

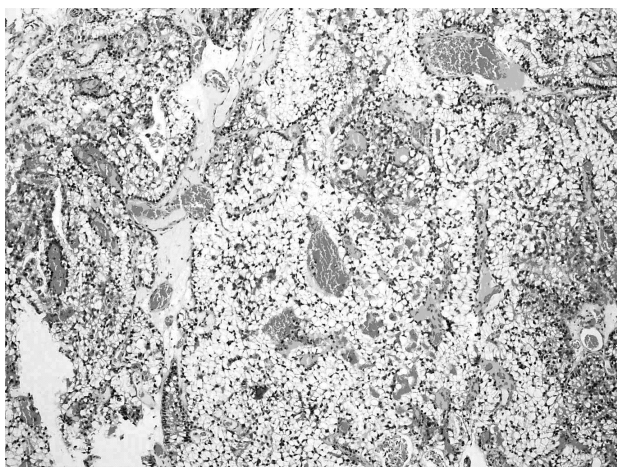


Fig. 2. Clear cell variant urothelial carcinoma of urinary bladder (HEx100).

percentage tumor positive cells of all tumor cells for CK20, CEA and vimentin.

This immunohistochemical finding defines clear cell carcinoma, so we finally diagnosed the tumor as clear cell variant of urothelial carcinoma in the urinary bladder.

After 6 months of follow-up the patient had no recurrence of tumor in the urinary bladder.

Discussion

Many different tumors show a clear cell appearance, and may originate from the kidney, bladder, prostate or female genital tract especially from uterus and ovary⁴⁻⁷.

It is sometimes difficult to diagnose the primary site of tumor growth due to morphological similarity between tumors³⁻⁷.

In this case the differential diagnosis may include metastatic tumors to the bladder of the renal cell carcinoma, clear cell adenocarcinoma and clear cell variant of urothelial carcinoma.

Renal clear cell carcinoma (CCC) may rarely metastasize to the urinary bladder and approximately 30 cases have been reported in the literature⁷. Most frequently, renal CCC is represented by a compact alveolar growth of tumor cells, hobnail cells are not a feature. Specific for renal CCC is the presence of very delicate blood vessels surrounding the nests of tumor cells.

Clear cell adenocarcinoma has unique morphology, showing one or more of typical three morphological patterns: tubulocystic, papillary, and diffuse². Hobnail cells are frequently seen, but in our case we saw neither hobnail cells nor the characteristic histological patterns, and we ruled out clear cell adenocarcinoma of urinary bladder.

In our case, it was difficult to diagnose using only the hematoxylin and eosin stain, so we used immunohistochemical staining to assist in the diagnosis.

Urothelial carcinomas exhibit many variants and some differentiation^{1,3}. Severe progression is usually predicted when variants are found. Each variant shows a characteristic appearance and specific pattern of progress. For example, micropapillary variants tend to show vascular and lymphatic invasion, with a high incidence of metastasis.

Nested variants closely resemble Brunns nests in their infiltration of lamina propria and deceptively benign appearance; however, the prognosis is extremely poor. Awareness of the clear cell variant is critical in making correct differential diagnoses^{1,2}. This cells variant of urothelial carcinoma is defined by a clear cell pattern and a glycogen-rich cytoplasm. Clear cell pattern may be either focal or extensive in the tumor component¹.

Nine cases have been reported previously but clinical information was available for only four cases^{6,8,9}. The male to female ratio was 1:1, mean age was 67.2 years². Two patients presented with macroscopic hematuria, and the others presented with bladder irritation. All

showed invasive carcinoma and open radical surgery was chosen for all cases. In our cases the tumor is superficial with no invasion of muscular layers.

According to patient age and histological analysis, we decided to observe and prevent progression of disease (cystoscopic examination, urine cytological analysis).

In conclusion, we pointed out different variation of same histological urinary bladder carcinoma. Variability as well as unpredictable malignant transformation has important role in evaluation and decision for adequate treatment.

REFERENCES

1. MONTIRONI R, LOPEZ-BELTRAN A, *Int J of Surg Pathology*, 13 (2005) 143. — 2. YAMASHITA R, YAMAGUCHI R, YUEN K, NIWAKAWA M, TOBISU K, *Int J Urol*, 13 (2006) 1448. DOI: 10.1111/j.1442-2042.2006.01569.x. — 3. LOPEZ-BELTRAN A, Further commentary: tumors of the urinary system. In: EBLE JN, SAUTER G, EPSTEIN JI, SESTERHENN IA (Eds) *Pathology and Genetics of Tumors of Urinary System and Male Genital Organs* (Lyon, IARC Press, 2004). — 4. VANG R, WHITAKER BP, FARHOOD AI, SILVA EG, RO JY, DEEVERS MT, *Int J Gynecol Pathol*, 20 (2001) 252. DOI: 10.1097/00004347-200107000-00008. — 5. OLIVA E, AMIN MB, JIMENEZ R, YOUNG RH, *Am J Surg Pathol*, 26 (2002) 190. DOI: 10.1097/00000478-200202000-00005. — 6. SIM SJ, RO JY, ORDONEZ NG, PARK YW, KEE KH, AYALA AG, *Mod Pathol*, 12 (1999) 351. — 7. MATSUO M, KOGA S, NISHIKIDO M, NOGUCHI M, SAKAGUCHI M, NOMATA K, MARUTA N, HAYASHI T, KANETAKE H, *Urology*, 60 (2002) 911. DOI: 10.1016/S0090-4295(02)01900-3. — 8. KOPHIA SN, WOOD CG, SCHAEFFER AJ, OYASU R, *Arch Pathol Lab Med*, 119 (1995) 79. — 9. BRASILIS KG, JONES A, MURPHY D, *Aust NZ J Surg*, 67 (1997) 906.

Z. Peršec

University of Zagreb, Dubrava University Hospital, Av. G. Šuška 6, 10 000 Zagreb, Croatia
e-mail: zpersec@net.amis.hr

UROTELNI KARCINOM SVJETLIH STANICA MOKRAČNOG MJEHURA; KLINIČKO-PATOLOŠKA I IMUNOHISTOKEMIJSKA ANALIZA – PRIKAZ SLUČAJA

SAŽETAK

Oblik urotelnog karcinoma mokračnog mjehura svijetlih stanica vrlo je rijetka i neobična neoplazma definirana histološki svijetlim stanicama s citoplazmom bogatom glikogenom. Naš slučaj karcinoma svijetlih stanica dijagnostičan je imunohistokemijski. Muškarac, u dobi od 72 godine, klinički prezentiran s bezbolnom makroskopskom hematurijom u studenom 2007. godine. Evaluacijom mokračnog mjehura nađena je papilarna tvorba. Učinjena je transuretralna resekcija tumora mokračnog mjehura (TUR). Histopatološka evaluacija pokazala je da se radi površnom karcinomu prijelaznog epitela i karcinomu *in situ*. Nakon 3 mjeseca praćenja, ponovno je otkriven solitarni pedunkularni tumor s lijeve lateralne strane mokračnog mjehura. Ponovna transuretralna resekcija tumora mokračnog mjehura (reTUR) učinjena je u veljači 2008. godine. Patološka dijagnoza je bila otežana zbog difuznog prisustva svijetlih stanica. Imunohistokemijska analiza je dokazala urotelni karcinom, te je postavljena konačna dijagnoza kao oblik urotelnog karcinoma svijetlih stanica. Urotelni karcinom ima mnogo varijanti koje pokazuju različite oblike i karakteristike. To bi trebalo uzeti u obzir kod evaluacije i izbora optimalnog liječenja.