

# Recurrent sinonasal melanoma - report of five surgical cases and short literature review

---

Džepina, Davor; Kalogjera, Livije; Baudoin, Tomislav

Source / Izvornik: *Collegium Antropologicum*, 2012, 36, 179 - 184

Journal article, Published version

Rad u časopisu, Objavljena verzija rada (izdavačev PDF)

Permanent link / Trajna poveznica: <https://um.nsk.hr/um:nbn:hr:105:991238>

Rights / Prava: [In copyright](#) / [Zaštićeno autorskim pravom.](#)

Download date / Datum preuzimanja: **2025-04-03**



Repository / Repozitorij:

[Dr Med - University of Zagreb School of Medicine  
Digital Repository](#)



# Recurrent Sinonasal Melanoma – Report of Five Surgical Cases and Short Literature Review

Davor Džepina<sup>1</sup>, Livije Kalogjera<sup>1,2</sup> and Tomislav Baudoin<sup>1,2</sup>

<sup>1</sup> University of Zagreb, »Sestre milosrdnice« University Hospital Center, Department of ENT – Head and Neck Surgery, Zagreb, Croatia

<sup>2</sup> University of Zagreb, School of Medicine, Zagreb, Croatia

## ABSTRACT

*The aim of this study is to present five surgical cases of recurrent sinonasal melanoma. We report the clinical course of this highly malignant disease and give a brief overview of the relevant literature. For the purpose of our presentation, inclusion criteria for all patients were initially negative surgical margins, surgery with curative intent without implementation of radiotherapy, and absence of distant metastatic spread at presentation (M0). They were diagnosed and treated at the same ENT/Head and Neck Surgery department and had clear surgical margins following first resection. The majority of five cases had local recurrences (average two) which were all amenable to at least one salvage operation. In conclusion, despite extensive disease at presentation, we recommend repeated attempts at local surgical salvage. However, this decision must be carefully considered, respecting postoperative quality of life, the estimated life expectancy as well as general socioeconomic issues in each particular case.*

**Key words:** sinonasal melanoma, surgery, recurrence, survival

## Introduction

Mucosal melanoma of the nose and paranasal sinuses is a rare clinicopathological entity; representing only 0.3–2% of all melanoma and about 4% of head and neck melanomas<sup>1</sup>. The most common mucosal head and neck presentation site is in the sinonasal area. Main characteristics include a relatively late clinical presentation with nasal obstruction and epistaxis. Pain and swelling of soft facial tissues occur in advanced stages of disease. Epidemiologically, melanoma is a disease of an older population; peak presentation is in the sixth to eighth decade of life. The incidence appears to be stable, unlike the cutaneous melanoma trend where there has been significant increase of incidence in last decade<sup>2</sup>. Relative lack of sufficiently large prospective studies presents significant limitation for clinicopathological assessment of this infrequent disease. Therefore, retrospective reviews and case reports are two significant investigative tools for clinicians and researchers.

We present five cases of primary sinonasal mucosal melanomas, which were seen and treated at the authors' institution. The main inclusion criteria were patients with localized disease, absence of distant meta-

static spread at initial presentation (M0), negative surgical margins at surgery with curative intent and no adjuvant radiotherapy.

## Case Reports

### *Case report 1 (female, 49 years)*

An 49 year old female was admitted to our department with a 3-month history of left nasal cavity obstruction, intermittent haemorrhagic nasal discharge, and a left periorbital headache. Rhinoscopy revealed an exophytic, partly ulcerated mass in left nasal cavity attached to the anterior nasal septum. A CT scan demonstrated broad-based soft tissue mass without evidence of further local extension. However, at the time of surgery it was noted that the tumour had a narrow pedicle of a few millimeters with an exophytic growth of more than 1 cm. The tumour was surgically removed in toto via an alar incision approach and the anterior septal defect was closed with a full thickness dermal graft taken from the retroauricular region. The final pathohistology revealed

**TABLE 1**  
CLINICAL DATA SUMMARY OF FIVE SINONASAL MUCOSAL MELANOMA CASES

Case #, age, gender	Site, stage*	Time to first recurrence (months)	Recurrences (local, regional)*	Disease outcome and survival
1. Female, 49 y	Nasal septum, I	15	1 L	Alive without disease, 11 years follow-up
2. Male, 62 y	Nasal cavity, I	14	2 L, 1 R	Dead 6 years from diagnosis
3. Female, 74 y	Inferior nasal turbinate, I	12	2 L	2 years alive without disease, afterwards lost to follow-up
4. Female, 68 y	Nasal septum, II	11	4 L, 2 R	Dead 29 months from diagnosis
5. Female, 68 y	Anterior ethmoid, I	25	2 L, 1 R	Alive 36 months from diagnosis, afterwards lost to follow-up

\* Stage I: localized disease, stage II: locoregional disease, stage III: distant metastases; L: local recurrence, R: regional recurrence

a completely excised anaplastic low-differentiated carcinoma. The cytokeratin reaction was slightly positive. After hospital discharge, the patient had no symptoms or signs of recurrence. Ten months later, suspicious satellite lesions appeared on septum around the postoperative scar but a biopsy consisted only of respiratory epithelium mixed with scarce infiltration of lymphocytes and plasma cells. Five months later (15 months after the first operation), another lesion appeared around postoperative scar. This time, surgery consisted of subtotal septal excision leaving an intact small dorsal strip together with additional stripping of mucosa from the nasal floor and excision of the anterior pole of the left middle nasal turbinate. Histopathological examination confirmed melanoma. Afterwards, the patient was free of disease for 9 months (24 months after first operation) when a CT detected a 20 mm recurrence in left prechoanal region without radiological signs of bone destruction. At this time, the tumour was excised via a medial maxillectomy and left sphenoidectomy. Immunohistochemistry showed focally positive reaction to HMB-45. Postoperatively, 6 cycles of chemotherapy were administered. Forty eight months after the initial diagnosis and the first operation, the patient is clinically without signs of disease and a CT scan shows an epithelialized cavity without evidence of recurrence. The last follow-up was eleven years from the diagnosis. The patient is alive without signs of disease.

#### *Case report 2 (male, 62 years)*

A 62 year old male patient had a six months complaint of right nasal obstruction and haemorrhagic discharge. A biopsy performed at an outside institution confirmed the diagnosis of mucosal melanoma. At clinical presentation, a dark red mass completely filled the right nasal cavity and protruded through the vestibule. Other clinical information was insignificant. A CT demonstrated a soft tissue mass filling the entire nasal cavity, eroding the inferior and middle nasal turbinates and protruding through the nasopharynx, leaving an intact lateral nasal wall. The nasal septum was eroded anteriorly and posteriorly. The anterior ethmoidal cells and maxillary sinuses opacified. The lacrimal apparatus showed signs of ballooning. There were no signs of orbital or intracranial space invasion and no signs of lymphadenopathy. Chest X-rays,

body scan and liver ultrasound were negative for signs of tumour dissemination. The patient underwent an external approach via a lateral rhinotomy. Medial maxillectomy, frontoethmoidectomy, subtotal resection of septum and resection of tumour were performed. The histopathology of the specimen revealed partly necrotic, atypical melanoma without signs of bone or cartilage destruction. Postoperatively, the patient was presented at our tumour conference when it was decided that radiotherapy was not indicated. After discharge from hospital, the patient was regularly followed at the outside institution. Fourteen months postoperatively, recurrence was noted, located in the right ethmoid cavity. A CT demonstrated tumour in the right ethmoidal cavity with partial destruction of the lamina papiracea and lacrimal bone, protruding into the orbit. The tumour also extended dorsally through the ethmoid recess but no sphenoidal sinus invasion was present. Bony dehiscence of the anterior cranial base near the lateral border of lamina cribrosa occurred but without intracranial invasion. The tumour was removed via an external frontoethmoidectomy combined with a lateral rhinotomy. Postoperatively, the patient did not receive tele- or brachytherapy. After discharge, the patient was regularly followed. Brain CT, chest x-rays, bone scan, neck and abdominal ultrasound were without signs of dissemination. After 12 months (26 months after diagnosis), he suffered a second local recurrence presenting with a right haemorrhagic nasal mass with dark crusts on surface. A CT scan showed recurrence in right maxillary sinus invading through alveolar process to the posterior wall and zygomatic recess of the maxillary sinus as well as adjacent parts of the hard palate. This time, an operation consisted of a partial maxillectomy with resection of the tumour. Postoperatively, the patient underwent six cycles of a DTIC chemotherapy regimen. At the follow-up, the patient is well with occasional right-sided headaches and difficult lacrimation but with a CT showing only a postoperative oroantral fistula. A neck ultrasound was good as well as lung scan. Ten months later (three years after diagnosis), the patient was well and without signs of disease. His last CT scan, performed five years after diagnosis, showed a suspicious masses at the superior mediastinum near major vascular structure and a biopsy via a mediastinotomy

was positive for recurrent nasal melanoma. An tumour conference concluded that all treatment possibilities were exhausted. One year later (six year from diagnosis), the patient died from distant incurable disease.

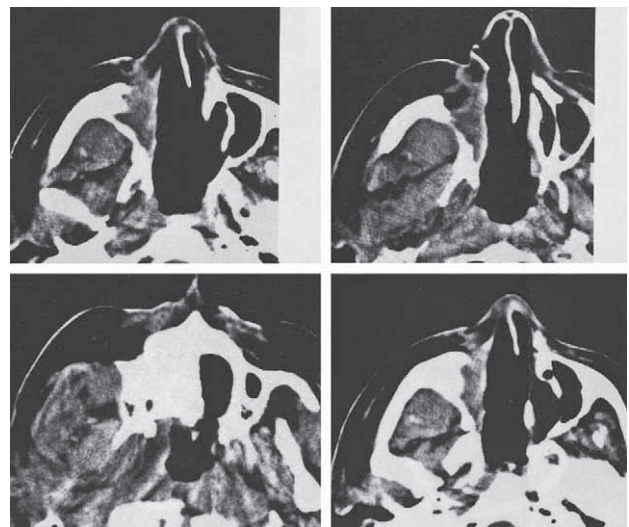
#### *Case report 3 (female, 74 years)*

A female patient at 74 years of age came to the ENT department with complaints of left nasal epistaxis and a brownish discharge as well as unilateral nasal obstruction. Her symptoms were present for about eight months and she has been treated at an outside institution for three weeks with nasal decongestants and bilateral nasal tamponade. Rhinoscopic examination revealed a brown-yellowish lobulated left nasal mass with obstruction of the medial and inferior nasal meatus. A CT scan demonstrated left sinonasal polyposis and MRI showed an expansive process filling the left nasal cavity, protruding through nasopharynx without signs of intracranial or intraorbital extension. A biopsy was suspicious for malignant melanoma. The tumour was removed via a combination of an external and endoscopic approach (left medial maxillectomy, complete left ethmoidectomy, bilateral sphenoidectomy and partial resection of septum). At the time of surgery, it was evident that the tumour invaded the left inferior and medial nasal conchae spreading towards the ethmoid roof and lamina cribrosa as well as sphenoidal sinus. Histology revealed a mucosal melanoma with metastatic foci that had been found on the septum and anterior sphenoid wall. Adjuvant postoperative chemotherapy was administered with Dacarbazine in 6 cycles. One year after diagnosis, local recurrence was noted. The entire nasal cavity was filled with tumour and scar tissue. A biopsy confirmed recurrent sinonasal melanoma. The tumour was infiltrating the sphenoorbital region. Our tumour conference concluded that any further therapeutic measures should not be taken. After one year (two years from the initial diagnosis), she was hospitalized again for second local recurrence on the posteromedial orbital wall and sphenothmoidal region which was removed endoscopically as a palliative measure. On two postoperative visits, the patient was alive with disease and afterwards lost to follow-up.

#### *Case report 4 (female, 68 years)*

A 68-year old female was hospitalized for endoscopic removal of a mass from the nasal cavity located on the anterior septum at the right side. She denied any symptoms. Histopathology revealed a malignant melanoma. The tumour was completely excised. After three months, bilateral neck metastases appeared. The patient underwent a right radical neck dissection and left modified radical neck dissection. Histopathology of both specimens was positive for metastatic melanoma. Two months later (five months from initial presentation), recurrence was noted in right buccal region which was successfully removed. Histology demonstrated metastatic melanoma. After 6 months (eleven months from the diagnosis), local recurrence was evident in right nasal cavity. A necrotic obstructing mass in the right nasal cavity with contra-

lateral septal bulge was evident. The right midface was swollen with palpable solid infiltrate blunting the nasolabial fold. A CT scan demonstrated an expansive process in the right nasal cavity spreading into the right maxillary and sphenoid sinus as well as through orbital fatty tissue. The right frontal sinus showed complete opacification. The tumour was removed from the nasal cavity, buccal and pterygoid region. A complete bilateral sphenoidectomy and septal removal were performed together with a right partial maxillectomy. Histology revealed recurrent melanoma. Postoperative chemotherapy was not recommended due to the compromised cardiovascular status of patient. Three months later (14 months from the diagnosis), a third large local recurrence was evident in the right parotid and buccal region. The tumour was resected via a partial parotidectomy including sacrifice of the buccal and marginal branches of the facial nerve. After 9 months (23 months from the diagnosis), a fourth local and regional recurrence occurred. A CT revealed bilateral lymphadenopathy in the parapharyngeal space. Lower neck and infraclavicular lymphadenopathy was evident as well. The infratemporal fossa near the posterior wall of the right maxillary sinus was filled with an expansive process (Figure 1) This time, the patient underwent surgery with a right hemimandibulectomy, neck dissection, right total parotidectomy, and left partial parotidectomy. Intraoperatively, the tumour extended to the skull base. The internal carotid artery was compressed. The patient died six months after hospital discharge (29 months from the diagnosis).



*Fig. 1. Case # 4, female, 68 years. CT scan of the nose and paranasal sinuses demonstrating findings after right ethmoidectomy and partial maxillectomy with tissue adjacent to the lateral border of the previously operated area without suspicious signs of local recurrence. There is evidence of bilateral pathological lymphadenopathy in parapharyngeal space. Massive tumour infiltrate 3 cm in diameter infratemporally, near the posterior wall of the right maxillary sinus.*

*Case report 5 (female, 68 years)*

This patient initial complaints included left nasal obstruction, epistaxis and epiphora. A nasal biopsy at the outside institution revealed squamous cell carcinoma. Four months after the first nasal symptoms appeared, the patient underwent left rhinotomy approach including a left partial maxillectomy, ethmoidectomy, subtotal septal excision. All three nasal conchae on left side were removed as well. The initial intraoperative histology was suspicious for hemangiopericytoma with anaplastic cells but final report showed atypical melanocytes and immunohistochemistry with positive reaction for HMB-45, S 100 and was negative for cytokeratine. Perineural and perivascular extension were present. On follow-up, the patient was well, without signs of recurrence until 25 months postoperatively, when recurrence was noted in the right maxillary sinus, left ethmoidal and left phenoid sinus, extending to the contralateral nasal cavity. The tumour was surgically removed and 3 cycles of chemotherapy was administered postoperatively. Five months later (30 months from the diagnosis) regional recurrence was noted with left neck metastases which were removed via a left radical neck dissection. Two more cycles of chemotherapy (DBD protocol) were administered postoperatively. Six months later (36 months from the diagnosis), the patient suffered from a second local recurrence in the posterior part of the maxilla with extension into the region of the sphenoid recess and posteriorly into the left orbital cavity and superior orbital fissure reaching the left cavernous sinus. There were no signs of expansion into the brain. This recurrence was removed. After hospital discharge, the patient was lost to follow-up.

**Discussion**

Of all mucosal sites for melanoma, the head and neck region is the most common, accounting for more than half of all cases<sup>3</sup>. Malignant melanoma of the nose and paranasal sinus mucosa occurs relatively rarely and consists only 4% of all sinonasal tract malignancies<sup>3,4</sup>. They become symptomatic relatively late with nasal obstruction, epistaxis, nasal discharge, midfacial soft tissue swelling and headache being most common. Clinical presentation is typical and includes a polypoid, fleshy nasal mass with or without pigmentation. Patients can have epistaxis or brown nasal discharge which may be explained by the presence of melanin pigment. Late findings include signs of locoregional disease progression (soft tissues, ocular, neural, cerebral). The most common involved sites is the nasal cavity alone or sinuses. Most frequently stated subsites include the nasal turbinates and septum<sup>5,6</sup>. The majority (four) of our patients presented with signs of nasal obstruction and epistaxis. One had brown nasal discharge. One had additional unilateral periorbital headache and one had epiphora. One patient whose tumour was discovered on an endoscopic exam did not report any symptoms. Tumour occurred on the nasal septum in two patients and in ethmoid sinuses

in two others. In one case, the primary subsite could not be definitively established.

The differential diagnosis can often be difficult and include the following benign and malignant neoplasms: poorly differentiated carcinoma, lymphoma, rhabdomyosarcoma, tumours of neural origin, olfactory neuroblastoma, pleomorphic and spindle cell. The most common reasons for initial misdiagnosis are amelanotic tumours and ulceration. In one of our cases, the tumour was initially misdiagnosed as an anaplastic low-differentiated tumour or carcinoma and in second patient, the intraoperative histology was suspicious for hemangiopericytoma mixed with anaplastic cells, although the final report revealed melanoma.

Exact histologic confirmation is mandatory. Mucosal melanoma has several significant differences comparing to skin melanomas. Frequently, melanin pigmentation is lacking in mucosal melanoma which is linked to worse clinical behaviour<sup>4,8</sup>. Secondly, non existence of clear histological layers and absence of typical dermo-epidermal contact together makes it difficult to estimate the depth of tumour invasion. In addition, a mass frequently is amenable only to piecemeal removal due to its brittle consistency and necrosis. Lymphocyte and plasma cell infiltration is a sign of a strong immunological response and can influence prolonged disease-free survival<sup>4</sup>. Immunohistochemistry is very helpful diagnostic tool with HMB-45, S-100, tyrosinase, melan A, vimentin, enolase, CD 56, 57, 99 and 117, synaptophysin, microphthalmia transcription factor (MITF) all been identified in melanoma tissue.

There are several proposed clinical staging systems<sup>4</sup>. The most commonly used system is relatively simple and includes three stages; disease is confined to the primary site (stage I), regional lymph node spread (stage II), or distant metastases (stage III). Other systems aim to make risk stratification according to histopathologic parameters (tumour location, size, volume, thickness)<sup>9</sup>. Four of our patients presented with stage I disease (NOM0). One patient had stage II disease. This is consistent with previously reported literature. For sinonasal melanomas, several therapeutic options are available including surgery, radiotherapy and chemotherapy<sup>10,11</sup>. The most important is aggressive surgical removal, including all invaded mucosa, soft tissues, and adjacent bone structures. Radical operations include partial or total maxillectomy, fronto-spheno-ethmoidectomy, subtotal or total septal extirpation, and orbital exenteration sparing vital structures and respecting anatomical limitations. In carefully selected cases, modern surgical options such as endoscopic removal may be as effective as other approaches<sup>12</sup>. Neck dissections are reserved for clinically, radiologically or cytologically positive nodes<sup>9</sup>.

Local recurrence is a frequent finding related to an ultimately unsuccessful outcome. There are reports that emphasize the importance of local control of disease<sup>6,13,14</sup>. This importance can be demonstrated on various levels; mainly in tumour multifocality, satellitosis, submucosal lymphatic spread, or iatrogenic tumour seeding at the

time of surgery. Relative time period between recurrences are unpredictable, with the range of one to twelve years<sup>15</sup>. All of our patients were treated with at least one surgical excision, intended to be curative. In some cases complete excision was not possible due to anatomical limitations. The majority of our five cases had local recurrences (average two) which were all amenable to at least one salvage operation. Postoperative adjuvant therapy has a limited role in overall survival improvement<sup>16</sup>. Generally, it is agreed that radiotherapeutical modalities do not significantly influence survival<sup>2</sup>. In one review, authors report better survival after postoperative radiotherapy<sup>14</sup>. The majority of studies show a small benefit to local control and found no significant benefit for survival after postoperative radiotherapy<sup>17,18</sup>. Chemotherapy with different treatment regimens was administered in three patients as a part of our therapeutical approach and radiotherapy was not included as an option in any of the cases.

Overall, unfavorable prognostic factors are greater age at presentation, obstructive symptoms without epistaxis, more than 10 mitosis figures per 10 HPF, locoregional recurrence, advanced stage, lymphovascular invasion, and distant dissemination<sup>4</sup>. Unfortunately, the overall 5-year survival ranges from 10–47% and the 10-year survival to only 20–24.3 %<sup>4,13,14,16</sup>. Most com-

monly, disease-related mortality is due to uncontrolled local or regional disease and/or distant dissemination<sup>4,8</sup>.

Despite extensive disease at presentation and an ultimately poor prognosis, we recommend repeated attempts at local surgical salvage believing that local recurrences frequently antecede regional and distant spread of disease. However, this decision must be carefully considered bearing in mind the attitude of the patient towards radical surgery, respecting quality of life postoperatively, the estimated life expectancy as well as general socio-economic issues in each particular case. Our report is intended to form a large database of similar cases of rare sinonasal tumours selected according to our criteria of recurrent cases with initially negative surgical margins, surgery with curative intent without implementation of radiotherapy and M0 stage of the disease. In summary, mucosal melanoma of the nose and paranasal sinuses is a rare clinicopathological entity. The most important therapeutic measure is aggressive surgical removal to preclude development of distant dissemination of disease. Local recurrence of melanoma is a frequent finding related to an ultimately unsuccessful outcome. Aggressive approach as with removal of locoregional recurrences offer a relatively good chance for midterm 5-year specific survival.

## REFERENCES

1. THOMPSON LDR, WIENEKE JA, MIETTINEN M, *Am J Surg Pathol*, 27 (2003) 594. — 2. LUND VJ, STAMMBERGER H, NICOLAI P, CASTELNUOVO P, BEAL T, BEHAM A, BERNAL-SPREKELSEN M, BRAUN H, CAPPABIANCA P, CARRAU R, CAVALLO L, CLARICI G, DRAF W, ESPOSITO F, FERNANDEZ-MIRANDA J, FOKKENS W, GARDNER P, GELLNER V, HELLQUIST H, HERMAN P, HOSEMANN W, HOWARD D, JONES D, JONES N, JORISSEN M, KASSAM A, KELLY D, KUSCHEL-LACKNER S, LEONG S, MCLAUGHLIN N, MAROLDI R, MINOVI A, MOKRY M, ONERCI M, ONG YK, PREVEDELLO D, SALEH H, SEHTI DS, SIMMEN D, SNYDERMAN C, SOLARES A, SPITTLE M, STAMM A, TOMAZIC P, TRIMARCHI M, UNGER F, WORMALD PJ, ZANATION A, *Rhinol Suppl*, 22 (2010) 1. — 3. CHANG AE, KARNELL LH, MENCK HR, *Cancer*, 83(8) (1998)1664. — 4. FERRARO RE, SCHWEINFURTH JM, HIGHFILL GR, *Am J Otolaryngol*, 23 (2002) 321. DOI: 10.1053/ajot.2002.124198. — 5. BATSAKIS JG, *Pathology of Tumors of the Nasal Cavity and Paranasal Sinuses*. In: THAWLEY SE, PANJE WR, BATSAKIS JG, LINDBERG (Eds) *Comprehensive Management of Head and Neck Tumours* (2nd Edition, WB Saunders, 1999). — 6. BRANDWEIN MS, ROTHSTEIN A, LAWSON W, BODIAN C, URKEN ML, *Arch Otolaryngol Head Neck Surg*, 123 (1997) 290. — 7. BILLINGS KR, WANG MB, SERCARZ JA, FU YS, *Otolaryngol Head and Neck Surg*, 112 (1995) 700. — 8. PRASAD ML, BUSAM KJ, PATEL SG, HOSHAW-WOODARD S, SHAH JP, HUVOS AG, *Arch Pathol Lab Med*, 127(8) (2003) 997. — 9. DAUER EH, LEWIS JE, ROHLINGER AL, WEAVER AL, OLSEN KD, *Otolaryngol Head Neck Surg*, 138(3) (2008) 347. DOI: 10.1016/j.otohns.2007.12.013. — 10. MENDENHALL WM, AMDUR RJ, HINERMAN RW, WERNING JW, VILLARET DB, MENDENHALL NP, *Am J Clin Oncol*, 28(6) (2005) 626. DOI: 10.1097/01.coc.0000170805.14058.d3. — 11. SVANE-KNUDSEN V, JORGENSEN KE, HANSEN O, LINDGREN A, MARKER P, *Rhinology*, 36(19) (1998) 115. — 12. LUND V, HOWARD DJ, WEI WI, *American Journal of Rhinology*, 21(1) (2007) 89. — 13. LEE SP, SHIMIZU KT, TRAN LM, JUILLARD G, CALCATERRA TC, *Laryngoscope*, 104 (1994) 121. — 14. KINGDOM TT, KAPLAN MJ, *Head Neck*, 17 (1995) 184. DOI: 10.1002/hed.2880170303. — 15. SANDERSON AR, GAYLIS B, *Ear Nose Throat J*, 86(5) (2007) 287. — 16. LUND J, HOWARD DJ, HARDING DJ, HARDING L, WEI WI, *Laryngoscope*, 109 (1999) 208. DOI: 10.1097/00005537-199902000-00007. — 17. WADA H, NEMOTO K, OGAWA Y, HAREYAMA M Wada, *Int J Radiat Oncol Biol Phys*, 59(2) (2004) 495. DOI: 10.1016/j.ijrobp.2003.11.013. — 18. OWENS JM, ROBERTS DB, MYERS JN, *Arch Otolaryngol Head Neck Surg*, 129(8) (2003) 864. DOI: 10.1001/archotol.129.8.864.

D. Džepina

University of Zagreb, »Sestre milosrdnice« University Hospital Center, Department of ENT – Head and Neck Surgery, Vinogradska 29, 10000 Zagreb, Croatia  
e-mail: dzepina.davor@gmail.com

## **RECIDIVIRAJUĆI SINONAZALNI MELANOM – PRIKAZ 5 SLUČAJEVA I KRATKI PREGLED LITERATURE**

### **S A Ž E T A K**

Cilj ovog rada bio prezentirati 5 kirurških slučajeva recidivirajućeg melanoma nosa i paranasalnih sinusa, prikazati klinički tijek ove visoko maligne bolesti te dati kratki prikaz stručne literature. Za potrebe ove prezentacije kriteriji uključenja za sve pacijente bili su inicijalni kurativni kirurški zahvat bez implementirane radioterapije, odsutnošću udaljenih metastaza (M0) kod prezentacije bolesti, te negativne patološke granice ekscizije. Svi slučajevi su bili dijagnosticirani i operirani na Klinici za otorinolaringologiju te imali čiste kirurške rubove nakon prve resekcije tumora. Većina pacijenata imala je lokalne recidive bolesti (u prosjeku dva), koji su bili dostupni najmanje jednoj operaciji. Zaključno, unatoč lokalno proširenoj bolesti u najvećem broju slučajeva, preporučujemo pokušaj reoperacije kod pojave lokalnog recidiva sinonazalnog melanoma. Ipak, potrebna je pažljiva i detaljna procjena prije donošenja odluke o daljnjim operacijama recidiva, poštujući predviđenu postoperativnu kvalitetu života, očekivanu specifičnu prognozu kao i općenito socijalno-ekonomsko stanje pacijenta u svakom pojedinačnom slučaju.