

Gastric tube ulcer perforating the pericardium after subtotal esophagectomy

Nikolić, Igor; Stančić-Rokotov, Dinko; Špiček Macan, Jasna; Korušić, Anđelko; Mikecin, Verica; Đuzel, Viktor

Source / Izvornik: **Collegium Antropologicum, 2013, 37, 615 - 618**

Journal article, Published version

Rad u časopisu, Objavljena verzija rada (izdavačev PDF)

Permanent link / Trajna poveznica: <https://um.nsk.hr/um:nbn:hr:105:815680>

Rights / Prava: [In copyright](#)/[Zaštićeno autorskim pravom.](#)

Download date / Datum preuzimanja: **2024-10-21**



Repository / Repozitorij:

[Dr Med - University of Zagreb School of Medicine
Digital Repository](#)



Gastric Tube Ulcer Perforating the Pericardium after Subtotal Esophagectomy

Igor Nikolić¹, Dinko Stančić-Rokotov², Jasna Špiček Macan³, Anđelko Korušić⁴, Verica Mikecin⁴ and Viktor Đuzel⁴

¹ University of Zagreb, University Hospital Dubrava, Department of Thoracic Surgery, Zagreb, Croatia

² University of Zagreb, »Jordanovac« University Hospital for Lung Diseases, University Department of Thoracic Surgery, Zagreb, Croatia

³ University of Zagreb, »Jordanovac« University Hospital for Lung Diseases, Department of Anesthesiology and Intensive Care, Zagreb, Croatia

⁴ University of Zagreb, University Hospital Dubrava, Clinical Department of Anesthesiology, Reanimatology and Intensive Care Medicine, Zagreb, Croatia

ABSTRACT

Subtotal esophagectomy with retrosternal transposition of the gastric tube to the neck was performed in a 62-year-old patient with squamous cell carcinoma of the proximal third of the esophagus. He developed a salivary fistula in the early postoperative period that healed spontaneously. Five months later, the patient developed partial stenosis of the esophagogastric anastomosis which required recervicotomy and excision, after numerous failed dilatation attempts. Eighteen months later, the patient presented to the hospital for severe pain in the upper abdomen. Clinical work-up revealed pericardial perforation by the gastric tube ulcer necessitating emergent surgery and gastric tube removal. We present a patient who developed both early and late complications of subtotal esophagectomy with gastric tube transposition as well as a review of the literature.

Key words: *squamous cell carcinoma, esophagectomy, thoracic surgical procedures, ulcer, pericardium*

Introduction

Subtotal esophagectomy represents one of the surgical methods utilized in the management of esophageal malignancies. It consists of subtotal resection of the esophagus and transposition of the gastric tube transmediastinally or retrosternally to the neck. The procedure is usually performed for well differentiated squamous cell carcinoma of the middle and lower third, and less frequently for adenocarcinoma of the distal third of the esophagus^{1,2}.

Adequate preoperative work-up, standardizing intraoperative steps and performing the surgery in high-volume centers by an experienced team have decreased perioperative mortality below 3% and increased 5-year survival to above 50%³.

Case Report

A 62-year-old man was admitted to our hospital for surgical treatment of squamous cell carcinoma of the

proximal third of the esophagus. For 6 months prior to hospitalization, he has suffered from dysphagia, at first for solid food and later for soft food as well, along with 15-kg weight loss. Contrast passage of the esophagus visualized a tumor of the proximal third of the esophagus, which narrowed the lumen to several millimeters along 7–8 cm in length. Bronchoscopy was indicative of extramural compression of the distal segment of the trachea, without mucosal infiltration. Esophagogastrosocopy revealed a tumorous process at 25 cm, that almost completely obstructed esophageal lumen and prevented further instrument passage. Thoracic multi-slice computerized tomography (MSCT) revealed a tumorous process of the proximal third of the esophagus of some 7 cm in length, occupying the entire wall thickness, with enlarged paratracheal lymph nodes.

Subtotal esophagectomy with retrosternal gastric tube transposition to the neck was performed. On 5th postoperative day, inflammation of the cervicotomy wound

developed, urging wound reopening and pus evacuation, with bacteriologic finding of methicillin-sensitive *Staphylococcus aureus* (MSSA). Postoperative esophageal passage revealed a minor (2 mm) fistula on the esophago-gastric anastomosis. Therefore, the oral food intake was delayed and alimentation *via* jejunostomy continued. Pneumococcal vaccination was administered after splenectomy. Over the next two weeks, cervical wound showed protracted healing due to salivary fistula developing, which has disappeared by discharge and the patient was able to swallow liquid and solid food. Histopathology finding: squamous cell carcinoma, staging T4N1M0. The patient was discharged from the hospital with regular monthly control examinations at surgical and oncology clinic.

One month later, solid food dysphagia reoccurred due to cervical salivary fistula and inflammatory stenosis. Contrast passage revealed relative stenosis of the anastomosis, whereas endoscopy revealed narrowing to 4–5 mm. Bougienage according to Savary was performed. Patient's status improved and he gained 5 kg in weight over two months.

At five months, re-dilatation of the stenosis could not be performed. Therefore, re-cervicotomy and partial excision of the esophagogastric anastomosis with re-suturing was performed. Postoperative course was uneventful, the patient could swallow liquid and solid food, and all control findings at two months (laboratory tests, abdominal ultrasonography, lung x-ray, thorax and abdomen MSCT, tumor markers, and esophagogastroscopy) were within normal limits.

Eighteen months later, the patient presented to a regional hospital for pain in the upper abdomen persisting for three days. As the discomforts increased in severity in spite of conservative therapy, patient was referred to our hospital. Due to the poor general condition, the patient was admitted to Intensive Care Unit (ICU). Chest x-ray revealed wide heart shadow, while endoscopy pointed to a suspect ulcer lesion of 6–7 mm on the posterior wall of the gastric tube at 35 cm. Gastrografin esophageal passage revealed contrast extralumination into the pericardium (Figures 1 and 2; arrow). Thorax MSCT revealed the presence of contrast medium in the pericardium (Figure 3; white arrow) and gastric tube, with bilateral reactive pleural effusion (Figure 3; blank arrow).

Emergency reoperation was indicated. An attempt was made to suture the stomach ulcer through the right thoracotomy. It had to be abandoned however, after several attempts, due to the wall fragmentation and rigidity. The gastric tube was removed, the duodenum was blindly closed, esophageal cervicostoma was performed and permanent jejunostoma created. The colon was prepared for the scheduled coloplasty, after which the patient stayed at ICU for three weeks. Pleural cavity was rinsed with diluted Betadine solution several times a day. The patient was administered antibiotic therapy and antifungal therapy. Thoracic drain from the right chest was removed on postoperative day 10. After initial improvement and mobilization with normal nutrition *via* je-

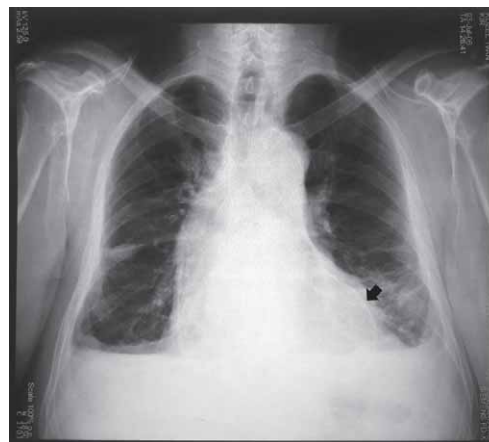

Fig. 1. Chest X-ray (AP) showing contrast extralumination into pericardium (black arrow).

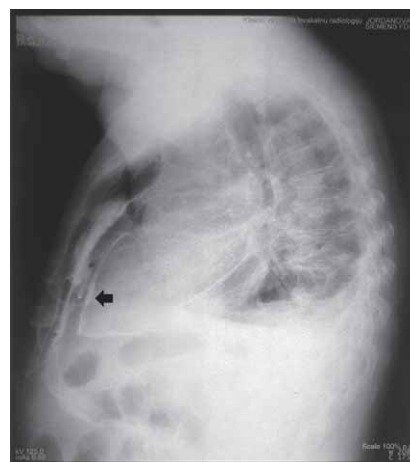


Fig. 2. Chest X-ray (lateral) showing contrast extralumination into pericardium (black arrow).

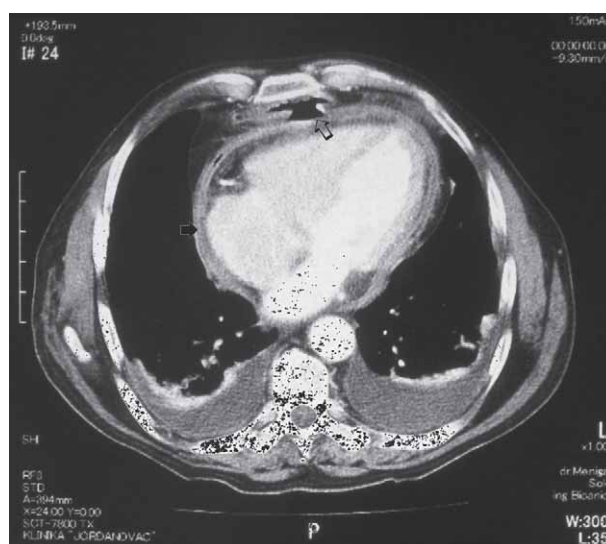

Fig. 3. MSCT scan of the thorax showing contrast in the pericardium (white arrow) and gastric tube (blank arrow). Note: bilateral pleural effusions.

junostomy, fever and increased bronchorrhoea occurred on postoperative day 15, requiring tracheostomy. Chest x-ray revealed inflammatory foci bilaterally basally, with an increase in leukocyte count, C-reactive protein, urea, creatinine and liver function tests. Five days later, the patient died from cardiorespiratory insufficiency and multiorgan failure in spite of intensive treatment.

Histopathology: gastric tube showing no signs of malignancy, however, revealing ulcer perforation opening in the mid-third, of 8 mm in diameter.

Discussion

Appropriate energy source replacement is one of the major issues encountered for the first 6–7 days postoperatively, until oral food intake is resumed after this type of surgery. Historically, alimentary algorithm consisted of total parenteral nutrition by intravenous hyperalimentation. However, for the last 20 years enteral nutrition has been applied from the first postoperative day, with patient staying in the ICU with intensive monitoring and close control by the surgeon and anesthesiologist. As the rate of complications and length of recovery upon the switch to enteral nutrition have been considerably reduced, this type of nutrition has been introduced as a standard alimentary procedure following subtotal esophagectomy^{4,5,6}.

Besides early postoperative complications such as pneumonia, hemorrhage, chylothorax, anastomosis dehiscence, or severe necrosis of the entire tube. One of the chronic changes consequential to vagus nerve lesion or organ transposition is postoperative stricture of the anastomoses, in particular of those created in the neck. Reflux of the biliary or acidic content may also occur, leading to esophagitis in the residual esophagus. Problems with tube emptying due to a reduced capacity or vagal lesions, and transient lesions of the recurrent laryngeal nerve have also been described⁷.

Development of peptic ulcer, i.e. gastric tube ulcer in spite of vagotomy represents one of the late post-esophagectomy complications. Since the gastric tube is transpositioned to the thorax, ulcerous penetration and perforation may lead to life-threatening complications due to their localization adjacent to the heart and large vascular structures⁸. Fortunately, such complications are rare, with only individual cases reported in the literature.

Takemura et al. have reported gastric tube ulcer formation after postoperative irradiation and due to *Helicobacter pylori* infection⁹.

Mori et al. confirm that vagotomy significantly reduces acidity within the gastric tube. *H. pylori* infection was found to significantly increase gastric tube acidity in comparison to stomach acidity prior to the procedure¹⁰.

Since the gastric tube in being transpositioned to the thorax, penetrating or perforating ulcers can lead to life-threatening complications due to the proximity of the vital structures (heart, great vessels, etc.). Fortunately, such complications are rare, thus literature reports consist of case reports.

Mochizuki *et al.* report on a 64-year-old patient with a gastric tube ulcer perforating the thoracic aorta. The patient underwent subtotal esophagectomy for esophageal carcinoma, with gastric tube transposition via the transmediastinal route. Several months after the surgery, he was admitted to the hospital for hemorrhagic shock and hematemesis. Routine diagnostic methods (endoscopy, angiography) failed to identify the site of hemorrhage and the patient was operated on, however, the bleeding site remained obscure, and the patient expired. A gastric tube ulcer perforating the thoracic aorta was found on autopsy¹¹.

Katsoulis et al. report on a 52-year-old patient who died after gastric tube ulcer perforation into descending aorta one year after subtotal esophagectomy¹².

Luthi *et al.* report on a 55-year-old female patient who developed neck pain four months of subtotal esophagectomy, and was prescribed nonsteroidal anti-inflammatory drugs. Three weeks later, she was admitted to the hospital for haematemesis and atrial fibrillation with rapid ventricular response. Her condition improved upon packed red blood cell transfusion; however, massive haematemesis occurred in several hours, with lethal outcome. Autopsy revealed three gastric ulcers, one of them perforating the left ventricular wall¹³.

Koide et al. report on 62 patients after subtotal esophagectomy in an attempt to elucidate the role of postoperative radiotherapy on gastric tube ulcer prevalence. Twelve of 61 patients in that series developed gastric tube ulcer. Six of them (50%) had undergone postoperative irradiation. There was no statistical difference between patients who developed gastric tube ulcer and the rest of the cohort. In patients who developed gastric tube ulcer but did not undergo postoperative irradiation, later onset of the disease was observed. Furthermore, in those patients the site of the ulcer was distal third of the gastric tube, with symptoms of cervical esophagitis rather than gastritis. Three patients in that subgroup had a verified *H. pylori* infection (two preoperatively). Authors have concluded that patients who develop gastric tube ulcers show different patterns of disease development with respect to postoperative irradiation therapy¹⁴.

Vonkemann et al. report on benefits of proton pump inhibitor (PPI) therapy in reducing bleeding and perforation complications in patients with gastric ulcers who take non-steroid anti-inflammatory drugs (NSAID). In their cohort of patients PPI significantly reduced complications of NSAID, particularly in older patients with cardiovascular comorbidities who had 10.6% mortality rate after developing complications of ulcerous disease¹⁵.

A number of patients develops gastric tube ulcers after subtotal esophagectomy, particularly those with underlying *H. pylori* infection, patients taking NSAID, and patients undergoing postoperative irradiation. Since the possible consequences of ulcer perforation into surrounding structures, those patients should receive PPI for prophylaxis. In patients who don't have aforementioned risk factors, benefits of PPI therapy remain unclear.

Conclusion

Subtotal esophagectomy with retrosternal transposition of the gastric tube to the neck is indicated in patients with squamous cell carcinoma of the proximal third of the esophagus. Operative complications can be classified into early and late ones, the latter including development of peptic ulcer on the gastric tube. Our patient had no history of previous ulcer disease or *Helico-*

bacter pylori infection. Patients with a history of previous ulcer or presence of this bacterium are at a higher risk for gastric tube ulcer development and perforation to adjacent structures. Patients undergoing chemo- or radiotherapy postoperatively should be administered PPI, particularly if they have positive ulcer anamnesis or verified *H.pylori* infection. These complications most probably occur due to vagotomy and impaired gastric motility, or underlying gastritis and esophagitis or ulcer disease.

REFERENCES

1. BAINS MS, SHIELDS TW, Squamous cell carcinoma of the esophagus. SHIELDS TW, LoCICERO J III, PONN RB, General thoracic surgery. 5 th edition. (Lippincott Williams & Wilkins, 2000, Philadelphia, USA). — 2. PAVIĆ T, HRABAR D, DUVNJAK M, Coll Antropol, 34(2) (2010). — 3. STEIN HJ, VON RAHDEN BH, FEITH M, J Surg Oncol, 92(3) (2005) DOI: 10.1002/jso.20362. — 4. SIEWERT JR, FEITH M, STEIN HJ, Chirurgische Klinik und Poliklinik, Technische Universität München, 76 (11) (2005). DOI: 10.1007/s00104-005-1096-9. — 5. SHIRAIISHI T, KAWAHARA K, YAMAMOTO S, MAEKAWA T, SHIRAKUSA T, Int Surg, 90(1) (2005). — 6. LUKIĆ, M, SEGEC A, SEGEC I, PINOTIĆ L, PINOTIĆ K, ATALIĆ B, SOLIĆ K, VCEVA, Coll Antropol, 36(3) (2012). — 7. TOTH I, SZUCS G, KISS JI, GYANI K, Magy Seb, 57(4) (2004). — 8. LERUT TE, VAN LANSCHOTT JJ, Best Pract Res Clin Gastroenterol, 18(5) (2004) DOI: 10.1016/j.bpg.2004.06.029. — 9. TAKE-

MURA M, HIGASHINO M, OSUGI H, TOKUHARA T, FUJIWARA K, KINOSHITA H, Nippon Kyobu Geka Gakkai Zasshi, 45(12) (1997). — 10. MORI N, FUJITA H, SUEYOSHI S, AOYAMA Y, YANAGAWA T, SHIROUZU K, Dis Esophagus, 20(4) (2007) DOI: 10.1111/j.1442-2050.2007.00718.x. — 11. MOCHIZUKI Y, AKIYAMA S, KOIKE M, KODERA Y, ITO K, NAKAO A, Jpn J Thorac Cardiovasc Surg, 51(9) (2003). DOI: 10.1007/BF02719601. — 12. KATSOULIS IE, VELOUDIS G, EXARCHOS D, YANNOPOULOS P, Dis Esophagus, 14(1) (2001) DOI: 10.1111/j.1442-2050.2001.00156.x. — 13. LUTHI F, KAESER P, HEBERT D, DESART T, TSCHANT P, Rev Med Suisse Romande, 119(1) (1999). — 14. KOIDE N, HIRAGURI M, NISHIO A, HANAZAKI K, J Gastroenterol Hepatol, 16(2) (2001) DOI: 10.1046/j.1440-1746.2001.02415.x. — 15. VONKEMAN HE, FERNANDES RW, VAN DER PALEN J, VAN ROON EN, VAN DE LAAR MAFJ, Arthritis Res Ther, 9(3) (2007) DOI: 10.1186/ar2207.

I. Nikolić

University of Zagreb, University Hospital Dubrava, Department of Thoracic Surgery, Av. Gojka Šuška 6, 10000 Zagreb, Croatia
e-mail: inik11@net.hr

PERFORACIJA ULKUSA ŽELUČANOG SUPSTITUTA U PERIKARD NAKON SUBTOTALNE EZOFAGEKTOMIJE

SAŽETAK

Prikazan je slučaj 62 godišnjeg muškarca kod kojega je zbog karcinoma proksimalne trećine jednjaka učinjena subtotalna ezofagektomija. Godinu i pol dana nakon operacije javila se nagla bol u epigastriju koja je nastala kao posljedica perforacije ulkusa želučanog supstituta u perikard.