

Lower limb salvage surgery: modular endoprosthesis in bone tumour treatment

Orlić, Dubravko; Smerdelj, Miroslav; Kolundžić, Robert; Bergovec, Marko

Source / Izvornik: **International Orthopaedics, 2006, 30, 458 - 464**

Journal article, Accepted version

Rad u časopisu, Završna verzija rukopisa prihvaćena za objavljivanje (postprint)

<https://doi.org/10.1007/s00264-006-0193-9>

Permanent link / Trajna poveznica: <https://um.nsk.hr/um:nbn:hr:105:746059>

Rights / Prava: [In copyright](#) / [Zaštićeno autorskim pravom.](#)

Download date / Datum preuzimanja: **2024-07-12**



Repository / Repozitorij:

[Dr Med - University of Zagreb School of Medicine
Digital Repository](#)





Središnja medicinska knjižnica

Orlić, D., Smerdelj, M., Kolundžić, R., Bergovec, M (2006) *Lower limb salvage surgery: modular endoprosthesis in bone tumour treatment*. International Orthopaedics, 30 (6). pp. 458-464.

<http://www.springerlink.com/content/h71102n634474148>
The original publication is available at www.springerlink.com

<http://medlib.mef.hr/201>

University of Zagreb Medical School Repository

<http://medlib.mef.hr/>

TITLE:

Lower limb salvage surgery: modular endoprosthesis in bone tumor treatment

AUTHORS:

Orlic D, Smerdelj M, Kolundzic R, Bergovec M
Department of Orthopaedic Surgery, Clinical Hospital Centre Zagreb and Zagreb University
School of Medicine, Croatia

AUTHOR RESPONSIBLE FOR THE CORRESPONDENCE:

Marko Bergovec, MD
Department of Orthopaedic Surgery, Clinical Hospital Centre Zagreb and Zagreb University
School of Medicine
address: Salata 6, 10000 Zagreb, Croatia
e-mail: bergovec@gmail.com
tel: +385-1-4818833
fax: +385-1-4818810

ABSTRACT

We retrospectively analyzed 90 patients who in the period 1987-2003 underwent "en bloc" resection and modular endoprosthesis reconstruction in the lower limb.

After proximal femur resection, reconstruction was performed with modular endoprosthesis (Howmedica, KFTR designed by Kotz) or with modular endoprosthesis (W.Link, Lima-Lto, designed by Wagner). Knee joint was reconstructed with modular endoprosthesis (Howmedica, KFTR designed by Kotz) after distal femur or proximal tibia resection.

The malignant bone tumors were present in 58 patients (64.5%), benign tumors in 16 (17.8%), metastasis in 8 (8.9%), tumors like lesions in 4 (4.4 %), and non-tumor related destruction of femur in 4 patients (4.4%). High grade tumors were found in the majority of malignant bone tumors (70.7%).

Treatment complications, which occurred in 26 patients, are as follows: local recurrence of tumor, deep infection, acetabular destruction following hemiarthroplasty, recurrent dislocations of endoprosthesis, periprosthetic fracture, and hardware problem. In total, 23 patients (25.6%) died due to tumor.

Endoprostheses should be considered as a treatment of choice for bone tumors in the hip and knee joint region. Advances in limb salvage surgery are and will be for a long time a great challenge for orthopaedic oncologists of the 21st century.

INTRODUCTION

Limb salvage surgery, currently an accepted bone tumor treatment method, has traditionally been a difficult problem in orthopaedic oncology. With the development of modern chemotherapy, the outlook for malignant tumors has greatly improved and encouraged surgeons to consider limb salvage surgery in most cases. The success of limb salvage is the result of advances in the understanding of the biology and staging of tumors, improvement in the reconstructive techniques, and the development of effective adjuvant chemotherapy for the primary tumors, and is still going on [7, 18].

The appropriate treatment to achieve local control after resection of bone tumor is still a subject of debate, and the long-term durability of various reconstructive methods is not known. Currently, the three most popular options are using an endoprosthesis, allograft-prosthetic composite, and biological reconstructions [6, 10, 17, 21]. Each of those methods has its short- and long-term advantages and disadvantages, and a surgeon should consider each patient individually.

Endoprosthetic replacement offers several advantages, such as early stability, mobilization and weight bearing, a shorter operating time and hospital stay in comparison to biologic reconstructions, and it allows early introduction of post-operative adjuvant therapy. Reconstruction with a modular endoprosthesis after resection of a bone tumor gives good functional results in most of the cases [14, 22].

PATIENTS AND METHODS

We retrospectively analyzed 90 patients treated by resection and reconstruction with a modular endoprosthesis in the lower extremity during 17 years (1987-2003) (Fig. 1). There were 39 males and 51 females with a median age at diagnosis of 30 (7-66) years.

Tumor was localized in proximal femur in 44 patients, distal femur in 30 patients, and proximal tibia in 16 patients. For reconstruction of the hip joint after proximal femur resection, we used modular endoprosthesis (Howmedica, KFTR designed by Kotz) in 26 and modular endoprosthesis (W.Link, Lima-Lto, designed by Wagner) in 18 patients. For knee joint reconstruction we used only modular endoprosthesis (Howmedica, KFTR designed by Kotz) in both distal femur and proximal tibia reconstruction.

All patients were given chemotherapy and radiotherapy according to the regimen in use at the time. Surgical approach was performed according to the general principles of limb salvage surgery, and resection length was determined preoperatively by radiographic and other imaging methods. In total, median resection length was 15 cm (range 6-25): the longest resections were performed in distal femur (median 16 cm, range 12-25), followed by proximal femur (median 15 cm, range 6-25) and proximal tibia (median 12 cm, range 7-15). All patients received perioperative prophylactic antibiotics and thromboprophylaxis according to the guidelines in our hospital at the time.

We analyzed data of clinical findings before primary operation, radiographic and other imaging methods, radioisotope bone scans, open biopsy findings, intraoperative findings and finally clinical results during postoperative ambulatory control examinations. All tumors were graded according to the Enneking system [8].

The mean follow-up was 9 years (range: 3-19); 72 of 90 patients had follow-up for more than 5 years.

RESULTS

The malignant bone tumors were present in 58 patients (64.5%), benign tumors in 16 (17.8%), metastasis in 8 (8.9%), and tumors like lesions in 4 (4.4 %) patients. The most common diagnose was osteosarcoma in 27 patients (30%), Ewing sarcoma in 15 patients (16.7%), and giant cell tumor of bone in 13 patients (14.4%).

High grade tumors (grade 2a and 2b) were found in the majority of malignant bone tumors: in 21 of 27 (77.8%) patients with osteosarcoma, in 10 of 15 (66.7%) patients with Ewing sarcoma, and in 41 of 58 (70.7%) of all malignant bone tumors. Active tumor grade 3 was found in the majority of patients with giant cell tumor of bone (in 7 of 13 (53.8%) patients). Detailed histological findings and tumor grades are shown in Table 1. Destruction of femur due to war wound or primary endoprosthesis instability, present in 4 patients, was also included in this analysis.

We found 6 patients with pathologic fracture prior to the primary operation: in two patients with osteosarcoma, two patients with secondary bone tumor, one patient with Ewing sarcoma and in one with giant cell tumor of bone. Five of them had pathologic fracture of proximal femur, and one of distal femur.

During treatment, 26 patients had one of the following complications: local recurrences of tumor, deep infection, acetabular destruction following hemiarthroplasty, recurrent dislocations of endoprosthesis, periprosthetic fractures, and hardware problems. Details of the complications, treatment methods, and final results are shown in Table 2.

In 10 patients we found local recurrences of tumor, and 5 of them died. Patients who died due to tumor are as follows: 9 of 27 patients with osteosarcoma (33.3%), 4 of 15 patients with Ewing sarcoma (26.7%), 4 of 8 patients with secondary bone tumor (50%), 3 of 8 patients with chondrosarcoma (37.5%), one patient with fibrosarcoma, one patient with malignant fibrous histiocytoma, and one patient with a war wound. In total, during the follow-up period, 23 patients died due to tumor.

At the last control examination, 65 patients showed no evidence of primary disease. Two patients were lost in follow-up for changing the place of living because of situation in the region.

DISCUSSION

Chemotherapy has dramatically changed the cure rate of malignant bone tumors. Since the introduction of effective neoadjuvant chemotherapy in the 1980s, >80% of patients with osteosarcoma of the extremity have been considered candidates for limb-salvage surgery [2, 15]. Increasing trend in limb-salvage surgery - using endoprosthesis is evident also in this study (Fig. 1).

More than a third of our patients (37.8%) were younger than 20, and almost half of them (47.8%) were under age of 25. For medical, surgical, and rehabilitative advances, limb-salvage surgery has surpassed amputation as the primary treatment for malignant bone tumors in young children [4, 14]. Preservation of limb function in the pediatric oncology patient is uniquely challenging. In skeletally immature patients, the functional impairment that is due to the subsequent growth inhibition must be considered in conjunction with limb-salvage surgery [1, 9].

Prosthetic reconstruction in the skeletally immature patient is demanding because of the necessity to cope with expected disruption of limb growth after resection of one or more major growth plates and the high demands placed on implants by young patients. Expandable endoprosthesis have important place in treating still growing children, but we did not use them mainly for financial reasons. Although endoprosthetic reconstruction in children is fraught with many problems, it is usually possible to obtain a good functional limb at skeletal maturity. Treatment must be strictly prioritized in terms of the patient's life, the limb, its function, length equalization, and cosmetic appearance. Orthopaedic intervention in the care of children and young adults with oncologic conditions must be individualized [1, 24].

An individual approach to every patient is essential in order to choose the most suitable surgical treatment for pathologic fractures due to primary bone tumors, metastasis or tumor like lesions. The aim of surgical treatment is primary to treat/remove tumorous tissue, and than to heal fracture, maintain or restore function, and minimize pain thus improving the patient's quality of life [23].

Relatively small number of patients with secondary bone tumor in this report does not represent the real incidence of those tumors. Our Department has no emergency units, and only exceptionally we treat such patients.

We used modular endoprosthesis model Wagner in treating bone tumors in proximal femur region mostly because of technical and financial reasons in our health system. Our Department always has on stock all sizes of Wagner stems for treating aseptic loosening, therefore in the case of emergency endoprosthesis is available immediately.

Two patients with low grade tumor-like lesions were treated by resection and endoprosthesis reconstruction: in one patient with grade 1 aneurysmal bone cyst the reason was articular surface destruction, and in a patient with fibrous dysplasia lesion size was more than 2/3 of total femur length, and proximal femur resection size was 22 cm.

More than two thirds of patients began the orthopaedic treatment of malignant bone tumor at the point when histological activity of tumor shifted to more aggressive histological grade. Malignant bone tumors are of major concern in orthopaedic surgery, and the beginning of the treatment should be as soon as possible. Losing precious time, these patients come late to a specialist of orthopaedic oncology, what is a sign of inefficiency of our health system. Education of general physicians, physicians of other specialties, and general population should also be in domain of orthopaedic oncologist.

The most common complication in treating our patients was local recurrence of tumor. That data should be analyzed together with information of tumor grade. Majority of the patients with malignant bone tumor had high grade tumor, what made the treatment more complicated. After local recurrence of tumor (in 10 patients), radical surgical treatment resulted in saving half of those patients, who are now disease-free.

Deep infection was the second most common complication, occurred in 5 patients in our study. In the previous literature, the rate of deep infection has ranged from 4 to more than 30% [5, 11]. Curettage, débridement and irrigation were performed in 3 patients, and in 2 patients we had unsatisfactory final results: amputation following local recurrence in one patient, and knee ankylosis in other patient. Staged reimplantation was performed in 1 patient, and 1 patient with tumoral

endoprosthesis implantation for a war wound (because of psychological condition - PTSD) refused treatment.

Dislocation is the most common complication after primary or secondary femur endoprosthetic reconstruction, regardless the indication. There is still no widely accepted method which helps avoiding this complication. In the orthopaedic literature the rate of hip dislocation following reconstruction of proximal femoral tumors with megaprosthesis varies from 2 to 28% [3]. In general, the main reasons for dislocated hips are extensive soft tissue resection due to the large size of the tumor. Our study, expectedly, showed that 4 of 44 (9.1%) patients had hip dislocation. We managed to perform closed reposition and applied the hip brace in all 4 of our patients for 4-6 weeks.

Reconstruction of femur after tumor resection was performed by hemiarthroplasty in 4 children. Growing acetabular bone and the selection of proper size of endoprosthetic head for achieving congruence would give satisfactory limb function during the time after operation. The main problem occurs after a few years because of the physiological enlargement of the acetabular diameter: incongruency between the endoprosthetic head and the acetabulum results in alternation of pressure on acetabulum and lateral migration of endoprosthesis head, what finally leads to destruction of acetabulum roof and subluxation of the endoprosthetic head.

Acetabuloplasty with total hip endoprosthesis in growing children will cause epiphysiodesis and restrain acetabular growth: that procedure is performed mostly on older children and adults. In younger - still growing children, in case of proximal migration of the prosthesis in hemiarthroplasty, for salvage procedure an acetabuloplasty with bone homotransplant and implantation of greater diameter femoral endoprosthetic head can be performed. The goal is to allow acetabulum to grow as normal as possible and as long as possible. The acetabuloplasty with endoprosthesis was the final step of the acetabular reconstruction in all of our 4 young patients (Fig. 2) [20].

Periprosthetic fracture occurred in 2 patients: after car accident in one, and during sport activity in the other patient. Good functional status after surgery encourages the patient to go "beyond limits" of the operated limb. If there is no primary disease, treatment of such patients should not be a difficult problem (Fig. 3).

Poor design of "bearing polyethylene shift" part of knee modular endoprosthesis (Howmedica, KFTR designed by Kotz) resulted in early wasting of that component. That model of endoprosthesis was implanted in one patient with GCT, and we performed 4 reoperations in order to change bearing polyethylene shift and solve related technical problems. Later models of the endoprosthesis removed that hardware problem [19].

Many studies were performed to investigate endoprosthetic survival rates after tumor resection, but the results cannot be summarized and systematic review cannot be performed, mostly because of a small number of patients, as well as different models and principles of endoprosthesis. Tumor endoprosthetic survival rates are mostly about 60% to 80% at five years, and 40-70% at ten years [12, 13, 16]. Specific long-term consequences of endoprosthetic reconstructions after tumor resection for the patient's affected limb are still unknown [12]. In our opinion, endoprostheses should be considered as a treatment of choice for bone tumors in the hip and knee joint region. Advances in limb salvage surgery are and will be for a long time a great challenge for orthopaedic oncologists of the 21st century.

REFERENCES

1. Abudu A, Grimer R, Tillman R, Carter S (2006) The use of prostheses in skeletally immature patients. *Orthop Clin North Am* 37:75-84
2. Bacci G, Picci P, Ferrari S, Ruggieri P, Casadei R, Tienghi A, Brach del Prever A, Gherlinzoni F, Mercuri M, Monti C (1993) Primary chemotherapy and delayed surgery for nonmetastatic osteosarcoma of the extremities. Results in 164 patients preoperatively treated with high doses of methotrexate followed by cisplatin and doxorubicin. *Cancer* 72:3227-38
3. Bickels J, Meller I, Henshaw RM, Malawer MM (2000) Reconstruction of hip stability after proximal and total femur reconstruction. *Clin Orthop* 375:218-230
4. Cara JA, Canadell J. Limb salvage for malignant bone tumors in young children (1994) *J Pediatr Orthop* 14:112-8.
5. Cool WP, Carter SR, Grimer RJ, Tillman RM, Walker PS (1997) Growth after extendible endoprosthetic replacement of the distal femur. *J Bone Joint Surg (Br)* 79:938-42
6. Donati D, Giacomini S, Gozzi E, Mercuri M (2002) Proximal femur reconstruction by an allograft prosthesis composite. *Clin Orthop* 394:192-200
7. Eckardt JJ, Eilber FR, Dorey FJ, Mirra JM (1985) The UCLA experience in limb salvage surgery for malignant tumors. *Orthopedics* 8:612-21
8. Enneking WF, Spanier SS, Goodman MA (1980) A system for the surgical staging of musculoskeletal sarcoma. *Clin Orthop* 153:106-120
9. Futani H, Minamizaki T, Nishimoto Y, Abe S, Yabe H, Ueda T (2006) Long-term follow-up after limb salvage in skeletally immature children with a primary malignant tumor of the distal end of the femur. *J Bone Joint Surg (Am)* 88:595-603
10. Gibbs CP Jr, Weber K, Scarborough MT. Malignant Bone Tumors (2001) *J Bone Joint Surg (Am)* 83:1728-45
11. Grimmer RJ, Carter SR, Tillman RM, Sneath RS, Walker PS, Unwin PS, Shewell PC (1999) Endoprosthetic replacement of proximal tibia. *J Bone Joint Surg (Br)* 81:488-494
12. Ham SJ, Schraffordt Koops H, Veth RP, van Horn JR, Molenaar WM, Hoekstra HJ (1998) Limb salvage surgery for primary bone sarcoma of the lower extremities: long-term consequences of endoprosthetic reconstructions. *Ann Surg Oncol* 5:423-36
13. Kawai A, Muschler GF, Lane JM, Otis JC, Healey JH (1998) Prosthetic knee replacement after resection of a malignant tumor of the distal part of the femur. Medium to long-term results. *J Bone Joint Surg (Am)* 80:636-47
14. Kotz R, Dominkus M, Zettl T, Ritschl P, Windhager R, Gadner H, Zielinski C, Salzer-Kuntschik M (2002) Advances in bone tumour treatment in 30 years with respect to survival and limb salvage. A single institution experience. *Int Orthop* 26:197-202
15. Link MP, Goorin AM, Horowitz M, Meyer WH, Belasco J, Baker A, Ayala A, Shuster J (1991) Adjuvant chemotherapy of high-grade osteosarcoma of the extremity. Updated results of the Multi-Institutional Osteosarcoma Study. *Clin Orthop Relat Res* 270:8-14
16. Malawer MM, Chou LB (1995) Prosthetic survival and clinical results with use of large-segment replacements in the treatment of high-grade bone sarcomas. *J Bone Joint Surg (Am)* 77:1154-65
17. Manfrini M, Innocenti M, Ceruso M, Mercuri M (2003) Original biological reconstruction of the hip in a 4-year-old girl. *Lancet* 361:140-2

18. Natarajan M, Bose JC, Rajkumar G (2003) Proximal femoral reconstruction with custom mega prosthesis. *Int Orthop* 27:175-9
19. Orlic D, Baebler B, Smerdelj M (1991) Complications of non-cemented tumoral endoprostheses. Brown K. (ed) *Complications of limb salvage. Prevention, management an outcome*. ISOLS, Montreal, 421-424
20. Orlic D, Smerdelj M, Kolundzic R, Bergovec M (2005) Acetabular Complications after resection of bone tumor localized in proximal femur in growing children with partial hip endoprosthesis - biomechanical consideration. In: *Program and abstracts of the 7th EFORT Congress, 4-7 June 2005, Lisboa, Portugal*
21. Posinkovic B, Orlic D (1983) Prosthetic replacement of the knee in the treatment of infected and recurring giant cell tumor of the distal femur. *Arch Orthop Trauma Surg* 102:131-4
22. Sanjay BK, Moreau PG (1999) Limb salvage surgery in bone tumour with modular endoprosthesis. *Int Orthop* 23:41-6
23. Wedin R (2001) Surgical treatment for pathologic fracture. *Acta Orthop Scand Suppl.* 72:2p.,1-29
24. Weisstein JS, Goldsby RE, O'Donnell RJ (2005) Oncologic approaches to pediatric limb preservation. *J Am Acad Orthop Surg* 13:544-54

LEGENDS

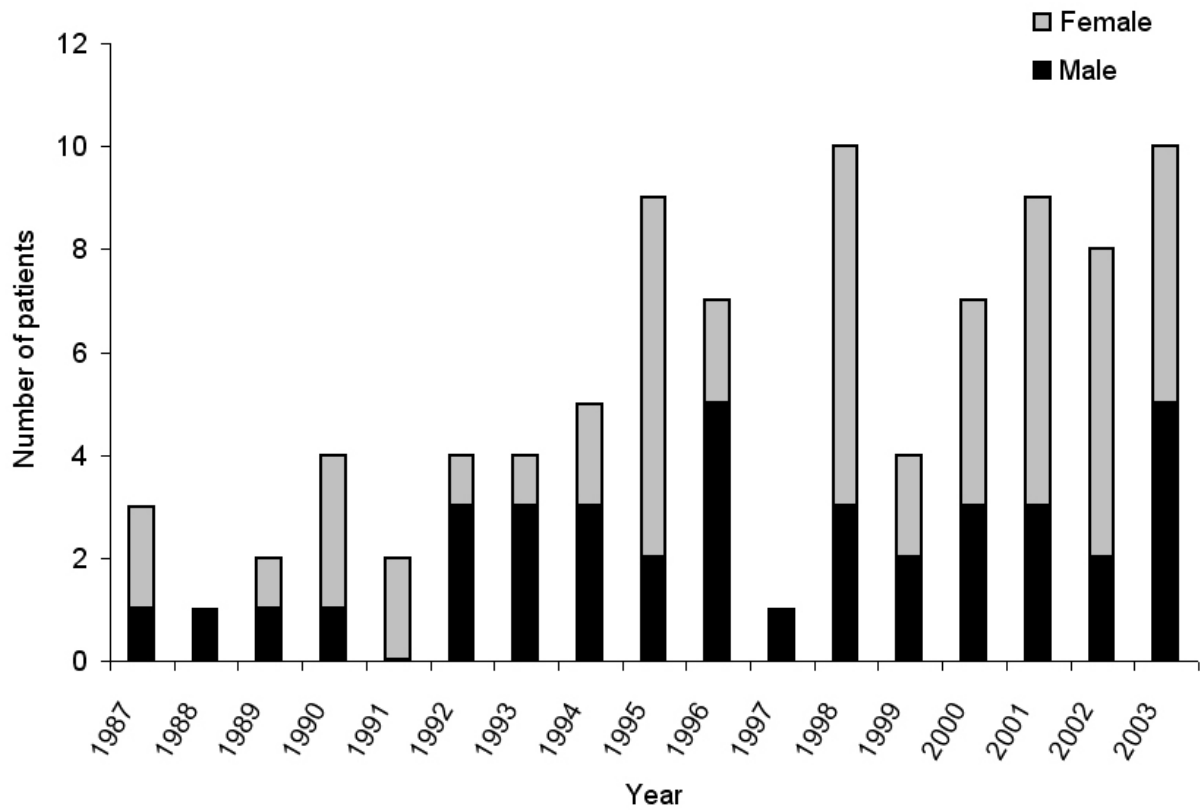


Figure 1.
Distribution of patients according to year of resection and endoprosthesis implantation.

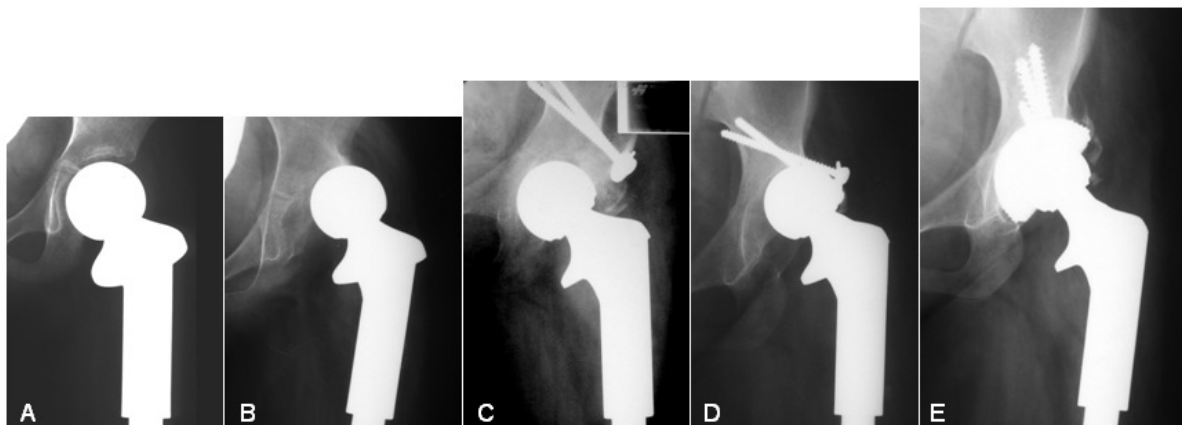


Figure 2.
A. Hemiarthroplasty after the “en bloc” resection of Ewing sarcoma localized in proximal femoral part. Patient at the age of 7. B. Subluxation of the endoprosthetic head (39 months after primary operation). C. Acetabuloplasty of the lateral roof with bone homotransplant, implantation of greater diameter endoprosthetic head (41 months after primary operation). D. Again subluxation of the endoprosthetic head (72 months after primary operation). E. Implantation of metal backed uncemented acetabular part of endoprosthesis (73 months after primary operation).

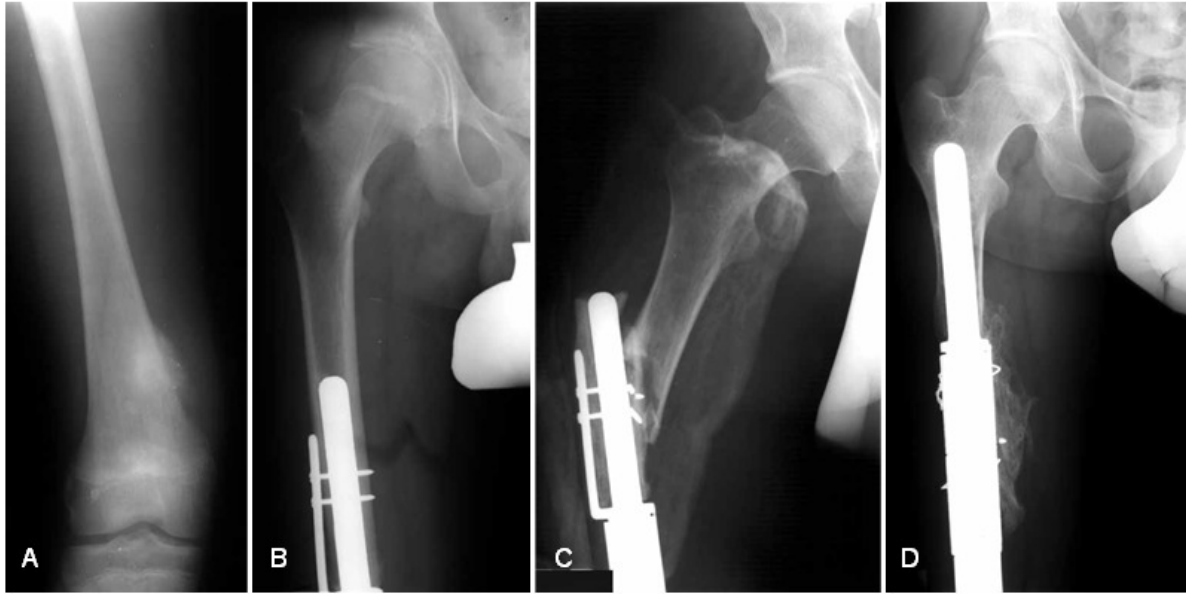

Figure 3.

A. A patient with osteosarcoma localized in distal femur. B. Implantation of knee modular endoprosthesis (Howmedica, KFTR designed by Kotz) after the "en bloc" resection of tumor. C. Periprosthetic fracture of the femur, occurred during car accident 10 years after primary operation, treated with (D) endoprosthesis elongation.

Table 1.
Number of patients according to histological type and tumor grade.

Tumor type					Total #
Benign bone tumors					
	grade 1	grade 2	grade 3		
Giant cell tumor of bone	1	5	7	13	
Chondroma		1	1	2	
Fibroma		1		1	
Total	1	7	8	16	
Primary bone tumors					
	grade 1a	grade 1b	grade 2a	grade 2b	
Osteosarcoma	3	3	10	11	27
Ewing sarcoma	3	2	2	8	15
Chondrosarcoma		3	1	4	8
Periosteal osteosarcoma		1			1
Fibrosarcoma				2	2
Plasmocytoma	1				1
Synoviosarcoma			1		1
Malignant fibrous histiocyoma				1	1
Leiomyosarcoma				1	1
Angiosarcoma		1			1
Total	7	10	14	27	58
Tumor-like lesions					
	grade 1	grade 2	grade 3		
Aneurysmal bone cyst	1		2	3	
Fibrous dysplasia		1		1	
Total	1	1	2	4	
Metastatic bone tumor					
Total					8
Other					
War wound					2
Instability of endoprosthesis					2
Total					4

Table 2.

Complications of treatment. Number in brackets represents a number of patients. Legend: DOD - died of disease; NED - no evidence of disease; EP - endoprosthesis

Complication	Diagnose	Treatment	Final result	
Local recurrence (10)	Osteosarcoma (7)	Re-resection (2)	DOD (4)	
		Amputation (4)	NED (3)	
		No therapy (1)		
	Chondrosarcoma (2)	No therapy (1)	DOD (1)	
		Re-resection (1)	NED (1)	
		Re-resection (1)	NED (1)	
Infections (5)	Osteosarcoma (3)	Curettage (2)	Local recurrence, amputation, DOD (1)	
			Knee ankylosis, NED (1)	
		Extraction of EP, rearthroplasty (1)	NED (1)	
		GCT (1)	NED (1)	
		War injury (1)	NED (1)	
Acetabular destruction (4)	Ewing sarcoma (3)	Transformation partial to total EP (4)	DOD (1)	
			NED (3)	
Dislocation of hip EP (4)	Osteosarcoma (1)	Closed reposition (4)	DOD (1)	
			Chondrosarcoma (1)	NED (3)
			Malignant fibrous histiocytoma (1)	
			Metastasis (1)	
Periprosthetic fractures (2)	Osteosarcoma (1)	Elongatio of EP (1)	NED (1)	
		GCT (1)	NED (1)	
Technical problems with EP (1)	GCT (1)	4 reoperations (1)	NED (1)	