

Percutaneous pulmonary valve implantation and surgical valve replacement in patients with right ventricular outflow tract dysfunction - a complementary treatment concept

Dilber, Daniel; Hörer, Jürgen; Malčić, Ivan; Hess, John; Ewert, Peter; Eicken, Andreas

Source / Izvornik: *International Journal of Cardiology*, 2013, 169, e3 - e5

Journal article, Accepted version

Rad u časopisu, Završna verzija rukopisa prihvaćena za objavljivanje (postprint)

<https://doi.org/10.1016/j.ijcard.2013.08.122>

Permanent link / Trajna poveznica: <https://um.nsk.hr/um:nbn:hr:105:260796>

Rights / Prava: [In copyright](#) / [Zaštićeno autorskim pravom](#).

Download date / Datum preuzimanja: **2024-07-10**



Repository / Repozitorij:

[Dr Med - University of Zagreb School of Medicine
Digital Repository](#)





Središnja medicinska knjižnica

Dilber D., Hörer J., Malčić I., Hess J., Ewert P., Eicken A. (2013)
Percutaneous pulmonary valve implantation and surgical valve replacement in patients with right ventricular outflow tract dysfunction--a complementary treatment concept. **International Journal of Cardiology, 169(1). pp. e3-5. ISSN 0167-5273**

<http://www.elsevier.com/locate/issn/01675273>

<http://www.sciencedirect.com/science/journal/01675273>

<http://dx.doi.org/10.1016/j.ijcard.2013.08.122>

<http://medlib.mef.hr/2035>

University of Zagreb Medical School Repository

<http://medlib.mef.hr/>

Percutaneous pulmonary valve implantation and surgical valve replacement in patients with right ventricular outflow tract dysfunction - A complementary treatment concept

Daniel Dilber¹, Jürgen Hörer³, Ivan Malcic¹, John Hess², Peter Ewert², Andreas Eicken²

¹Department of Pediatric Cardiology, University Hospital Zagreb at the Medical School of Zagreb, Kispaticeva 12, 10 000 Zagreb, Croatia

²Department of Pediatric Cardiology and Congenital Heart Disease, Deutsches Herzzentrum München, Technische Universität München, Germany

³Department of Cardiothoracic Surgery, Deutsches Herzzentrum München, Technische Universität München, Germany

Corresponding author:

Andreas Eicken MD

Department of Pediatric Cardiology and Congenital Heart Disease

Deutsches Herzzentrum München

Technische Universität München

Lazarettstr. 36

80636 München

eicken@dhm.mhn.de

Today surgical pulmonary valve replacement (SPVR) (1) or percutaneous pulmonary valve implantation (PPVI) (2) are the treatment options for right ventricular outflow tract (RVOT) dysfunction. The aim of this retrospective study was to evaluate results of SPVR and PPVI in a single centre.

Retrospective analysis of 109 consecutive patients who were scheduled for PPVI (53) or SPVR (56) between 05/2006 and 11/2010 at the German Heart Centre Munich. The median age at intervention was 20.2 years (8-65y) Both groups did not differ in age and gender. The median number of previous surgical procedures was significantly higher in the PPVI group (2 vs 3 procedures, respectively)(Table 1). The indication for treatment (SPVR/PPVI) was assessed according to current recommendations (3,4). Patients with prevailing stenosis and a RVOT diameter < 22 mm were treated with a Medtronic Melody® valve and patients with larger outflow tracts, usually presenting severe pulmonary regurgitation, were treated surgically. All patients received a transthoracic echocardiographical examination (5) before the intervention, at hospital discharge and at the latest follow-up examination. For calculation of RVOT obstruction the mean Doppler gradients were used. Wilcoxon rank sum tests were used to assess differences between the PPVI and surgical group. The median peak Doppler velocity across the RVOT was significantly higher before PPVI than before SPVR 4.1 m/s (1.7 – 5.1) vs 2.9 (1.3 – 5.7) (p<0.001) indicating that stenosis was the leading lesion in this group of patients. The peak Doppler flow velocity in the PPVI group decreased significantly from a median value of 4.1 m/s (1.7 – 5.1) to 2.7 (1.8 – 4.3) (Figure 1; p < 0.0001) at the latest echocardiographic examination. In the SPVR group the peak Doppler flow velocity decreased significantly from a median value of 2.9 m/s (1.3 – 5.7) to 2.1 (0.8 – 4.0)(p < 0.0001; Figure 1). Pulmonary regurgitation was more prominent in the surgical

group. In analogy to the results in term of stenosis, the PPVI patients with lower grades of pulmonary regurgitation before the procedure had significantly lower grades of pulmonary regurgitation after the procedure ($p < 0.001$, Figure 2). The median follow-up period was similar in both groups. Following PPVI, one patient developed endocarditis (*S.aureus*) six months after PPVI. The Melody® valve was replaced by a homograft. In the surgical group, two patients with severe recurrent pulmonary regurgitation needed a PPVI two and 24 months after surgery, respectively. Another patient underwent sternum re-fixation two years after surgery. The median hospital-stay after PPVI was significantly shorter after PPVI than after SPVR (2 days [1-26] vs 17 [9-56] days; $p < 0.001$). Early complications were significantly more frequent in the surgical group (21/56 ;38% vs 2/53;4%; $p < 0.001$). Complications after surgery were: urgent re-operation because of bleeding $n = 2$, pacemaker implantation (AV-block III) $n = 1$, seizures $n = 1$, fever of unknown origin $n = 13$, and arrhythmia $n = 4$. After PPVI one patient was febrile, one had transient atrioventricular conduction block. To our knowledge this is the first description of surgical valve replacement and PPVI for patients with RVOT dysfunction as a complementary treatment concept. Based on the individual morphology our interdisciplinary approach offered the adequate treatment. Patients, who were eligible for PPVI benefited from shorter hospitalization and fewer periprocedural complications. Following hospital discharge patients after PPVI can go back to their usual daily activities which is not possible after an open heart operation. In this instance some form of physical rehabilitation often is indicated, especially in adults. Hence, patients experience a significant advantage, if treated by PPVI. The most frequent complication after a cardiac operation in our cohort was fever of unknown origin, which only occurred once after PPVI. Fever is a very common complication

after open heart surgery (10) especially if biological conduits are employed. Some investigators tried to attribute this to the influence of HLA mismatch of the homografts (11). In absence of bacterial infection the post operative course in patients with fever of unknown origin usually is benign, at most the hospital stay is prolonged. Only one patient after PPVI had fever of unknown origin. However, one percutaneously implanted Melody® valve had to be exchanged due to endocarditis 6 months after PPVI. Bacterial endocarditis of a biological valve is a severe complication. Since it occurred as late as six months after PPVI, an association with the implant procedure is not probable. Prosthetic valve endocarditis is a severe form of infective endocarditis. It occurs in 1 – 6% of patients with artificial valves and equally affects bioprosthetic and mechanical valves (12). Further long term studies are needed to assess the real incidence of bacterial endocarditis after PPVI. A comparative long-term study (PPVI vs surgery) would be very helpful to address this issue. The other complications after surgery were two early re-operations for bleeding, one pacemaker implantation and one patient developed cerebral seizures without permanent residuals. Four patients had arrhythmia which led to transient medical treatment in the surgical group. One transient complete AV- block occurred in the PPVI-group during the intervention, probably due to the stiff delivery system. However, the patient was discharged home in sinus rhythm without a permanent pacemaker after three weeks and continues to be in sinus rhythm until today. The leading cardiac lesion in patients preceding PPVI was stenosis, whereas pulmonary regurgitation was prevailing in the surgical collective. These characteristics were still present at the latest follow-up examination showing a tendency for higher residual gradients in the PPVI group compared to more significant pulmonary regurgitation in the surgical collective. This made the proper interpretation of the

haemodynamic results of the study impossible. Until today, only mid-term follow-up results are available for patients after PPVI. Longer follow-up is needed to assess longevity of the percutaneous approach in comparison to surgery. In conclusion patients presenting with RVOT dysfunction can be treated effectively using a complementary treatment concept including SPVR and PPVI. The key for an optimal treatment is an individual decision making by surgeons and interventionalists. Patients, who are eligible for PPVI benefit from shorter hospitalization and lower complication rates.

Conflict of interests

Andreas Eicken, John Hess and Peter Ewert are proctors for the Medtronic melody valve.

References

1. Lange R, Weipert J, Homann M, Mendler N, Paek SU, Holper K, Meisner H. Performance of allografts and xenografts for right ventricular outflow tract reconstruction. *Ann Thorac Surg.* 2001;71:S365-367
2. Eicken A, Ewert P, Hager A, Peters B, Fratz S, Kuehne T, Busch R, Hess J, Berger F. Percutaneous pulmonary valve implantation: Two-centre experience with more than 100 patients. *Eur Heart J.* 2011;32:1260-1265.
3. Therrien J WC, Daliento L, Hess J, Hoffmann A, Marelli A, Thilen U, Presbitero P, Perloff J, Somerville J, Webb GD. Canadian cardiovascular society consensus conference 2001 update: Recommendations for the management of adults with congenital heart disease part iii. . *CanJ Cardiol.* . 2001;17:1135-1158
4. Khambadkone S, Bonhoeffer P. Nonsurgical pulmonary valve replacement: Why, when, and how? *Catheter Cardiovasc Interv.* 2004;62:401-408
5. Lai WW GT, Shirali GS, Frommelt PC, Humes RA, Brook MM, Pignatelli RH, Rychik J. Guidelines and standards for performance of a pediatric echocardiogram: A report from the task force of the pediatric council of the american society of echocardiography. *J Am Soc Echocardiogr.* 2006;19:1413-1430
6. Livelli FD, Johnson RA, McEnamy MT. Unexplained in hospital fever following cardiac surgery: Natural history, relationship to postpericardiotomy syndrome, and a prospective study of therapy with indomethacin versus placebo. *Circulation.* 1978;57:968-977
7. Boone RH, Webb JG, Horlick E, Benson L, Cao QL, Nadeem N, Kiess M, Hijazi ZM. Transcatheter pulmonary valve implantation using the edwards sapien transcatheter heart valve. *Catheter Cardiovasc Interv.* 2010;75:286-294

8. McElhinney DB, Hellenbrand WE, Zahn EM, Jones TK, Cheatham JP, Lock JE, Vincent JA. Short- and medium-term outcomes after transcatheter pulmonary valve placement in the expanded multicenter us melody valve trial. *Circulation*. 2010;122:507-516
9. Butera G, Milanese O, Spadoni I, Piazza L, Donti A, Ricci C, Agnoletti G, Pangrazi A, Chessa M, Carminati M. Melody transcatheter pulmonary valve implantation. Results from the registry of the italian society of pediatric cardiology. *Catheter Cardiovasc Interv*. 2012;June 2012 epub ahead of print
10. Livelli FD, Johnson RA, McEnamy MT. Unexplained in hospital fever following cardiac surgery: Natural history, relationship to postpericardiotomy syndrome, and a prospective study of therapy with indomethacin versus placebo. *Circulation*. 1978;57:968-977
11. Dignan R, O'Brien M, Hogan P, Passage J, Stephens F, Thornton A, Harrocks S. Influence of hla matching and associated factors on aortic valve homograft function. *J Heart Valve Dis*. 2000;9:504-511
12. Vongpatansin W, Hilis LD, Lange RA. Prosthetic heart valves. *N Engl J Med*. 1996;335:407-416

Table 1. Patient characteristics previous to RVOT surgery/percutaneous pulmonary valve procedure.

Parameter	Surgery	Percutaneous pulmonary valve implantation	p
Number of patients	56	53	
Age at procedure in years	19.1 (8–65)	22.8 (9.9–52.1)	0.173
Sex	Female 27; male 29	Female 22; male 31	0.305
Diagnosis	TOF/PA, 42; TAC, 2; TGA, 1; AoS, 1, other, 10	TOF/PA, 29; TAC, 11; TGA, 4; AoS, 4, other, 5	
RVOT characteristics	Homograft, 52; Hancock, 3; Carpentier-Edwards, 1	Homograft, 48; Hancock 2; Shelhigh 1; native 3	
Extracardiac anomalies	22q11, 8; AIDS, 1; esophageal atresia, 1	Trisomy 21, 1; 22q11, 3; severe mental retardation, 3; 8q deletion, 1	
Previous procedures	2 (1–6)	3 (1–5)	< 0.001

Numeric variables are reported as in median (range).p-Value from a Wilcoxon rank sum test for age and procedures, Fisher exact test for sex.

Figure 1

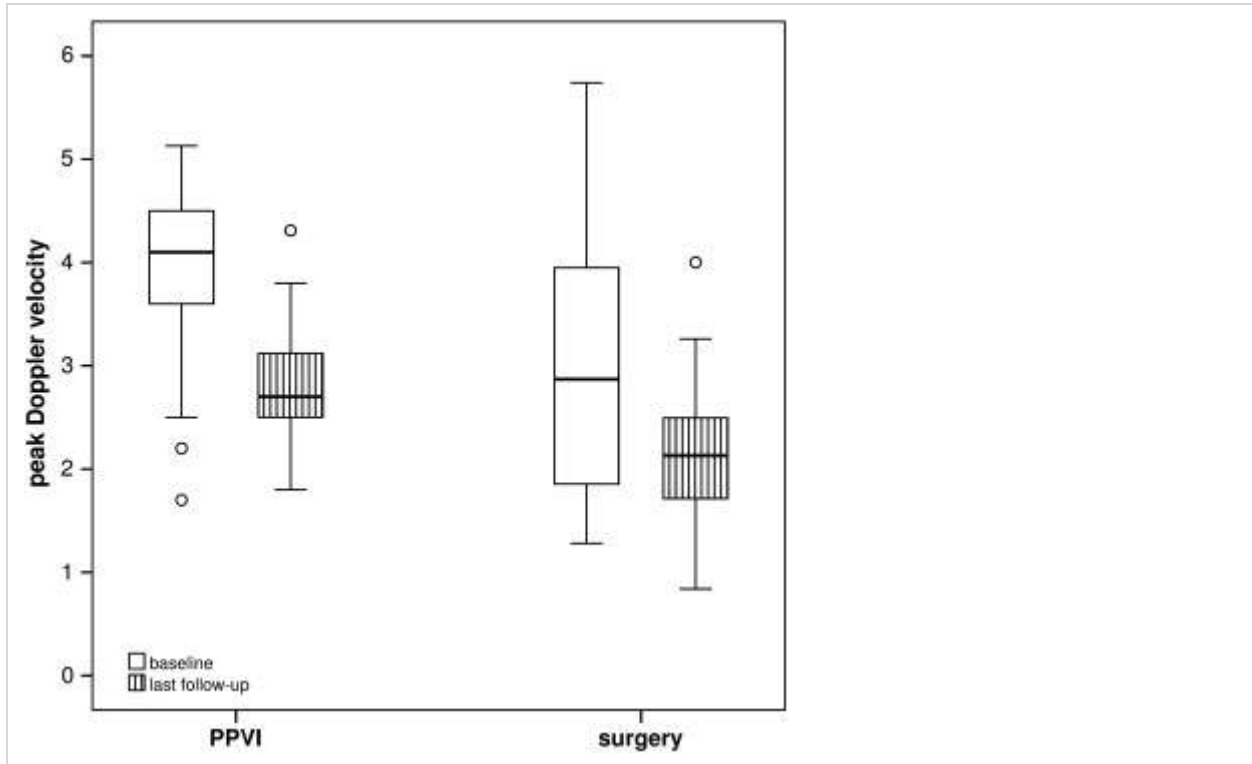


Fig. 1. Peak Doppler velocity across the right ventricular outflow tract at base line and at the latest follow-up echocardiographic examination: The median peak Doppler velocity was significantly higher before PPVI vs surgery ($p < 0.0001$). In both collectives the gradient was reduced significantly by the intervention/operation ($p < 0.0001$).

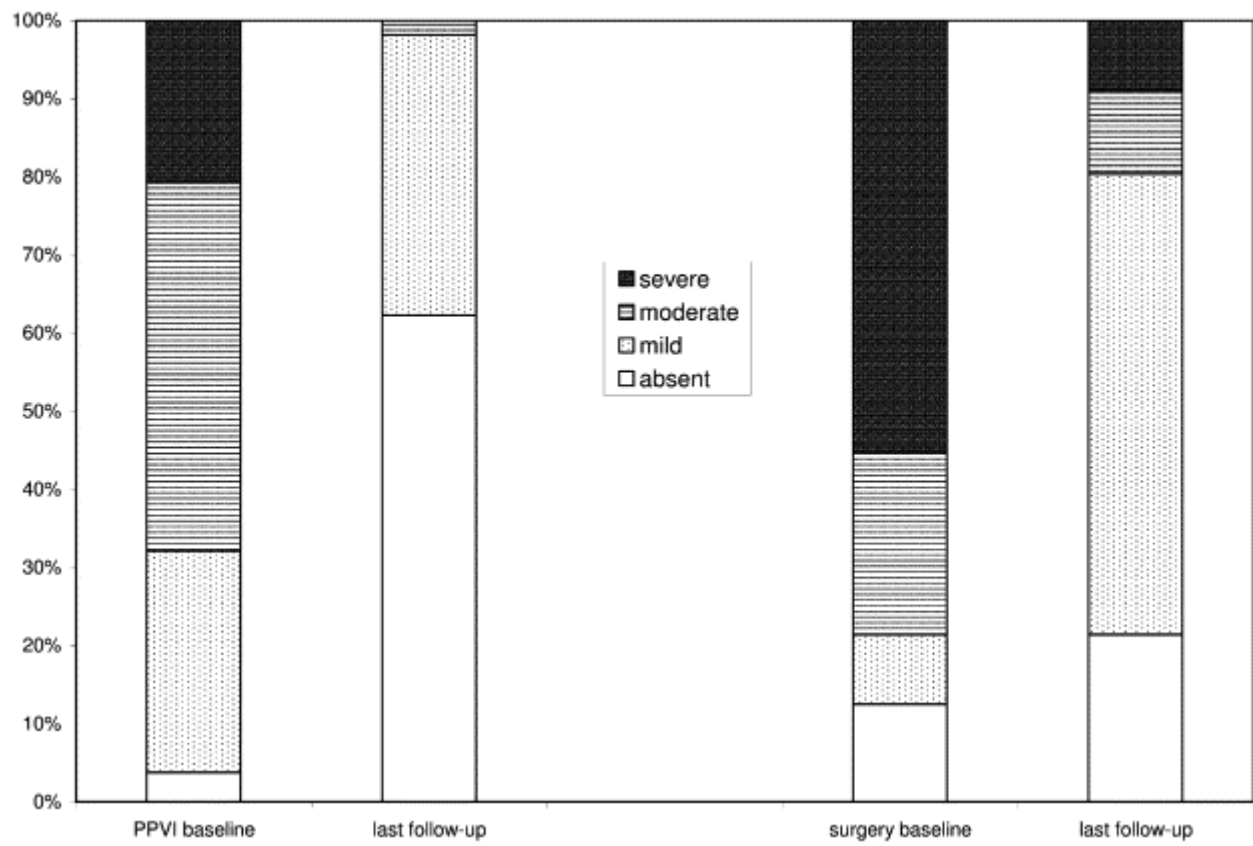


Fig. 2. Pulmonary regurgitation graded by echocardiography at base line and at the latest follow-up echocardiographic examination: More than 50% of the patients before surgery had severe pulmonary regurgitation which was improved significantly. However, at the latest follow-up 3 patients remained with significant pulmonary regurgitation. None of the patients after PPVI had severe pulmonary regurgitation at the latest follow-up examination.