

The role of preoperative lymphoscintigraphy in surgery planning for sentinel lymph node biopsy in malignant melanoma

Vučetić, Borki; Rogan, Sunčica Andreja; Balenović, Antonija; Ivkić, Mirko; Šitum, Mirna; Hudorović, Narcis; Kusić, Zvonko

Source / Izvornik: **Wiener klinische Wochenschrift, 2006, 118, 286 - 293**

Journal article, Accepted version

Rad u časopisu, Završna verzija rukopisa prihvaćena za objavljivanje (postprint)

<https://doi.org/10.1007/s00508-006-0603-4>

Permanent link / Trajna poveznica: <https://um.nsk.hr/um:nbn:hr:105:939847>

Rights / Prava: [In copyright](#)/[Zaštićeno autorskim pravom.](#)

Download date / Datum preuzimanja: **2024-07-10**



Repository / Repozitorij:

[Dr Med - University of Zagreb School of Medicine
Digital Repository](#)





Središnja medicinska knjižnica

Vučetić, B., Rogan, S. A., Balenović, A., Ivkić, M., Šitum, M., Hudorović, N., Kusić, Z. (2006) *The role of preoperative lymphoscintigraphy in surgery planning for sentinel lymph node biopsy in malignant melanoma*. Wiener klinische Wochenschrift, 118 (9-10). pp. 286-293.

The original publication is available at www.springerlink.com

<http://www.springerlink.com/content/g6261283k3879212/>

<http://medlib.mef.hr/228>

University of Zagreb Medical School Repository

<http://medlib.mef.hr/>

THE ROLE OF PREOPERATIVE LYMPHOSCINTIGRAPHY FOR SURGERY PLANNING FOR SENTINEL LYMPH NODE BIOPSY IN MALIGNANT MELANOMA

¹Borki Vučetić, ²Sunčica Andreja Rogan, ²Antonija Balenović, ³Mirko Ivkić,
⁴Mirna Šitum, ¹Narcis Hudorović, ²Zvonko Kusić

¹Department of Surgery,
²Department of Oncology and Nuclear Medicine,
³Department of Otorinolaringology and Head and Neck Surgery,
⁴Department of Dermatovenerology,
University Hospital «Sisters of Charity»;
Zagreb, Croatia

Corresponding author: Narcis Hudorović M.D., Ph.D.
Department of Surgery
Tel.
E-mail: narcis.hudorovic@zh.htnet.hr
University Hospital "Sisters of Charity"
29 Vinogradska Str., 10000 Zagreb, Croatia

ABSTRACT

Aim. To evaluate four years of preoperative lymphoscintigraphy experience, as well as accuracy of SN biopsy performed in our institution in melanoma patients with various tumor thicknesses. Also, the aim was to evaluate the recurrence rate related to pathohistological findings.

Methods and Patients. Two hundred and one patients underwent sentinel node biopsy from February 2002 to November 2005. Lymphoscintigraphy for identification of sentinel nodes was performed four to six hours prior to operation of the patient. Sentinel lymph node biopsy using intraoperative hand-held gamma probe was performed in all patients, as well as wide local excision of biopsy wound or primary lesion (N=56). Immediate complete basin dissection was performed in patients with sentinel node metastases. In four patients delayed complete lymph node dissection was performed due to definitive histopathologic examination of sentinel node. The accuracy of sentinel node biopsy was determined by comparing the intraoperative rates of sentinel node identification and the subsequent development of nodal metastases in regional nodal basins of patients with tumor negative sentinel node and in those with tumor positive sentinel node.

Results. By preoperative lymphoscintigraphy we identify sentinel node in all but one patient (99.0%). In 248 nodal basins (1.2/patient) 372 sentinel nodes (1.52 sentinel/basin; 1.8 sentinel/patient) were observed. The highest number of sentinel nodes was noticed in the groin of patients with melanoma on lower extremities (1.5/patient), followed by axilla with 1.3 per patient. Anomalous lymphatic drainage patterns were observed in 15.0% of all patients. Sentinel node identification rate was 99.0% overall; 100% for the groin basins, and 98.0% for the axilla and head and neck basin. Forty-two patients (20.8%) had tumor positive sentinel nodes. Local or distant recurrences had 10 (5.0%) patients during median follow up of 23.1 months (range 2-46 months). The rate of false-negative lymphatic mapping and

sentinel node biopsy as measured by nodal recurrence in a tumor-negative SN patients was 1.3%. During the follow-up period three of 201 patients died due to the other diseases and three patients died due to the melanoma metastases, with median follow up of 13.5 months (range 12 to 22).

Conclusion. Preoperative lymphoscintigraphy is sensitive, inexpensive and essential method for the identification of drainage basins, determination of number and position of sentinel node and its location outside the usual nodal basins. Scintigraphic findings may lead to changes in surgical management due to the unpredictability of lymphatic drainage. Low incidence of regional disease recurrence in patients with tumor negative sentinel node supports the use of preoperative lymphoscintigraphy and sentinel node biopsy as a safe and accurate procedure for staging the regional nodal basin in patients with malignant melanoma.

Key words: sentinel node biopsy, lymphoscintigraphy, melanoma

INTRODUCTION

Metastatic melanoma characteristically disseminates in an orderly progression of metastatic cells from the primary site through lymphatic vessels to the regional lymph nodes and then to more distant sites. The most important prognostic factor of the 5-year survival rate is the presence of metastases in regional lymph nodes (1). Also, the tumor thickness and ulceration are the dominant predictors of survival in patients with localized melanoma (2).

Surgical excision is the treatment of choice for primary lesion in all patients and complete lymph node dissection is not doubtful in patients with clinically obvious regional lymph node metastases. About 80% of patients with intermediate-thickness have tumor-free regional nodes and therefore would be unnecessarily placed at risk of complications which could arise from the regional lymphadenectomy, such as nerve injury and anesthetic complications of elective lymph node dissection, instead of observation after wide excision. As a result of recent investigations regarding improved survival in patients with regional nodal metastases following treatment with adjuvant interferon or vaccine therapy (3,4), accurate staging has become an additional motivation for assessing the regional nodal basin. Although some authors (5) reported a low incidence of metastases in thin melanoma (≤ 1 mm), Kalady et al. (6) presented that those melanomas are also potentially lethal lesions with 20% risk of disease recurrence, which could also change therapeutic approach in patients with thin melanoma.

Preoperative lymphoscintigraphy in melanoma has been applied to identify the localization of the true nodal drainage basins of lesions situated in regions of highly variable drainage, in particular on the trunk, head and neck. Because of the unpredictability of lymphatic drainage, preoperative scintigraphic findings may lead to changes in surgical management. The sentinel lymph node (SN) is the first lymph node to drain a cutaneous lesion, and thereby allows prediction of the metastatic status of the regional lymph node

group. The excellent results using sentinel biopsy technique that have been published from large and randomized studies (7,8,9) from experienced teams present challenge for smaller community like our, therefore we reviewed our results. Lymphoscintigraphy and SN biopsy has been adopted in our institution as a standard procedure in management of patients with melanoma according to AJCC staging system.

This study reviewed lymphatic drainage pathways and SNs location by preoperative lymphoscintigraphy, as well as accuracy of SN biopsy that has been performed. 201 patients with various tumor thicknesses were analyzed and the aim of our study was to evaluate the recurrence rate related to the pathohistological findings.

PATIENTS AND METHODS

Patients

From February 2002 to November 2005, 201 patients with cutaneous melanoma were referred to the Department of Oncology and Nuclear Medicine, University Hospital “Sisters of Charity” (National Referral Centre for Melanoma) for the preoperative lymphoscintigraphy. All patients underwent SN biopsy at the Department of Surgery and at the Department for Head and Neck Surgery (thirty patients from the learning phase were not included into this study). Dermatologists, surgeons and oncologists made selection for the procedure according to AJCC recommendations. The demographic and other clinical characteristics of the patients are listed in the Table 1. Lymphoscintigraphy was performed in 52 patients with primary lesion (proved by pathohistological examination after excision and SN biopsy) and in 149 patients with biopsy scar after excision of malignant melanoma. All patients were candidates for the SN biopsy if there was no evidence of metastatic melanoma in regional lymph nodes and/or distant sites by physical examination and staging evaluation (ultrasonography of the regional basins and abdominal cavity, chest x-ray, bone scintigraphy, tyrosinase and alkaline phosphatase). Patients were regularly followed-up at two, three or six month intervals, according to the clinical stage.

Preoperative lymphoscintigraphy

Lymphoscintigraphy was performed in all patients four to six hours prior to the operation, to delineate the lymphatic drainage and mark the location of SNs. About 18,5-74 MBq (0.2-0.5 mCi) of commercial ^{99m}Tc nanocolloid kit (rhenium sulfide nanocolloid, Nanocis, CIS Bio International, France) was prepared for the several intradermal injections with a total volume of 0.2-0.5 mL 0.9% saline. The mean diameter of the colloidal particles was averagely 100 nm.

Immediately after the administration of the radioisotope, scintigraphic dynamic acquisition was carried out (10 frames; 60 seconds/image) (Figure 1). Static five-minute images (Figure 2) in anterior, posterior and lateral views were performed following dynamic study to document the site of the identified sentinel nodes. Dual-head gamma camera (Siemens, Multispect, Illinois, USA) with large-field-of-view (matrix size 128x128) was used.

Furthermore, the exact location of the SN was preoperatively marked on the overlying skin of patients by the nuclear medicine physician, guided with ⁵⁷Co pen under a gamma camera in order to assist the surgeon to locate the SN during biopsy. All registered SNs were checked again with hand-held gamma probe (Navigator GPS, Radiation Monitoring Devices Inc., Watertown, MA, U.S.A.) and ultrasound (Vision 100, Toshiba, Japan).

Finally, patients were taken to the operating room for surgery within four to six hours following radiotracer injection.

Surgical Technique

For the intraoperative identification of SNs after preoperative lymphoscintigraphy hand-held gamma probe has been used. The SN was defined as the hottest node underlying skin mark, with radioactivity at least 2-3 fold higher than adjacent tissue. The *ex-vivo* counts were also recorded for each removed SN and nodal basin checked again for the radioactivity after SNs removal. Nuclear medicine physician was also present in the operating room for the first 50 procedures to assist the surgeon in identification of SN radioactivity.

Wide local wound excision was performed with operative margin 1-2 centimeters from primary melanoma biopsy border, depending to melanoma thickness.

Histopathologic examination of the sentinel node

All removed SNs were sent to pathologist for frozen-section analyses during the operation and complete lymph node dissection (CLND) was performed in all patients with SN specimens containing tumor and also in those patient without SN identification during biopsy. SN was further processed as a paraffin-embedded specimen for definitive diagnosis. Specimens were stained with conventional haematoxylin-eosin (H&E) and also paraffin blocks were chosen for immunohistochemical staining with monoclonal antibodies for S-100 and HMB-45. Protocol for pathological examination of SN was changed during the study, therefore in the last 156 patients immunohistochemical staining with monoclonal antibodies for S-100 was omitted.

Statistical analysis

Statistical analysis was performed using commercial software package SPSS.

RESULTS

Anatomic distribution of the primary lesions is listed in the Table 1. More than half of the studied patients have had the truncal melanoma, whereas extremity melanoma was equally distributed to upper and lower extremities. Median melanoma thickness was 2.1 mm (range 0.4-9.0 mm) and median diameter of all lesions was 18 mm (range 4 to 40). Out of all 201 patients included in the study 57 patients (28.4%) had Breslow thickness I and II (Table 2), but at the same time they had Clark level III or more.

Lymphoscintigraphic findings

SNs were lymphoscintigraphically visualized in 200 (99.5%) patients and mapping failed in only one patient with melanoma on the neck. In 248 nodal basins (1.2/patient) 372 SNs (1.52 sentinel/basin; 1.8 sentinel/patient) were observed. The highest numbers of SNs were noticed in the groins of patients with melanoma of lower extremities (1.5/patient), followed by axilla with 1.3 per patient. Anomalous lymphatic drainage patterns were observed in 15.0% of all patients.

Our data showed that one third of melanoma of the head and neck, as well as those located on the trunk, drained into more than one lymphatic basins (Table 3). Discordance of lymphatic findings compared to the historical anatomical guidelines was found in 39.0% of patients with lesions in head and neck regions and in 23.0% of those with trunk lesions. Tumors located on the extremities were drained exclusively into one nodal basin.

Aberrant lymphatic pattern was noticed in six patients (sentinel appeared in the groin and along iliac artery chain, popliteal area, subscapular area, cervical area, intercostals area) and one of those patients had also tumor deposits in SN.

Secondary lymph nodes were especially extensive in patients with primary lesions situated on the head. They appeared in all patients minutes following SNs appearance. Median

number of secondary lymph nodes was 2.5 (range 2-5) and were registered 15-30 minutes from the beginning of imaging.

Surgery identification rate

The SN identification by the surgeons was based on the highest level of radioactivity measured by the hand-held gamma probe and overall identification rate was 99.0%. Mapping of groin (100%) or axillary regions (100%) was more successful than mapping of cervical area (94.1%) or ectopic drainage sites such as parascapular area (83.3%).

Tumor-positive lymph node was found in 42 patients (20.8%) and in 42 SNs (11.3%) out of 372 lymph nodes analyzed (Table 4). In the group of patients with the melanoma thickness less than 1.5 mm 10.5% SN-positive patients were detected (6/57), although majority of patients with positive SN had thicker tumor (Table 2).

Analyses of SN-positive nodal basins demonstrated that there was no difference in the number of positive SNs between the patients with drainage to two nodal basins compared to one nodal basin (Table 3), although the number of biopsied SNs in the group with two nodal basins was significantly higher (Chi-Square Test, $p=0.045$).

Surgical morbidity

There was no operative mortality. Complications of SN biopsy were rare (seroma and hematoma in the region) and observed in 5.2% of patients (11/201 patients). After CLND postoperative complications were more frequent, wound infection in two patients (1.0%) and seroma in 23.4% of patients (47/201) were registered. Thrombophlebitis developed in one patient (0.5%) after CLND and there were no other regional complications. Also, no systemic complications were found in our patients.

Histopathologic findings

All 372 SNs were examined by frozen section and 38 of 42 positive (90.5%) nodes were confirmed during operation. Four additional SNs (9.5%) have been confirmed as positive on definitive PHD analysis, therefore delayed CLND was performed in those four patients.

Histopathologic reevaluation of SNs specimens from two SN-negative patients with recurrences didn't show any tumor cells in the original SNs specimens.

Patterns of recurrence

At median follow-up of 23.1 months (range 2 to 46), melanoma had recurred in 10 (5.0%) of the 201 patients (Table 5). First recurrence was regional in 8 patients and distant recurrence occurred in two patients. All regional first recurrences were registered in the SN drainage basin, except in one patient with non-sentinel basins recurrence. In a group of SN-positive patients, one patient developed distant metastases despite of negative in-transit node and with no regional basin recurrences. Among other SN-positive patients distant recurrence followed regional node recurrence in three patients, but in those patients in-transit metastases was not identified. Two patients (1.3%) of the 157 patients with tumor-negative SNs developed metastases: one patient had regional nodal recurrence after follow-up of 9.5 months and in other patient distant metastases was found without regional nodal involvement after 14 months of follow-up. This finding also presents the rate of false negative lymphatic mapping.

Finally, three patients out of five with distant metastases died at median follow-up of 13.5 months (range 12 to 22). Additionally, three patients had died during the follow-up period but due to the other diseases.

DISCUSSION

Preoperative lymphoscintigraphic identification of the SN has been very high in our study, with accuracy of 99.5%. The efficacy of lymphoscintigraphy could depend on the type and preparation of radiopharmaceutical, injection technique and prior surgical intervention. We confirmed that we used appropriate radiotracer who is simple for use and with acceptable consuming time for preparation. Different radiotracers are being used for SN mapping and their quality was tested in different centers. In our department we use ^{99m}Tc nanocolloid which is predominant type of radiopharmaceutical used in Europe (10). Failure to identify a lymph drainage pattern or SN visualization has been reported in up to 10% of cases (11), predominantly during the implementing of the procedure. In our group of patients, SN was not identified in only one patient, probably due to large excision scar. Our experience showed that the most important criteria for using an agent are capability of flowing rapidly from the injection site through the lymphatic vessels and localizing and retaining within the sentinel node. It should also produce high-quality images and deliver the radiation dose as low as possible.

Immediate dynamic imaging study was essential for the proper SN identification, especially for those lesions situated on the head, middle of the trunk and around the shoulders. Our data showed that sequential imaging was crucial in recognition of interval nodes in four patients. Kalady et al. (12) recommended repeated imaging immediately before surgery, because they identified additional SNs in 19% of patients at the time. This rule should be applicable for patients when lymphoscintigraphy is performing 18 to 24 hours before SN biopsy.

Reliability of lymphoscintigraphy as a method was disputed in several studies conducted in early 90-ties. Kapteijin et al. (13) noted that in even 12% of patients the number of SNs in the same patient differ on the two studies performed within 2-4 week interval. Also,

the study of Norman et al. (14) showed that agreement in SN identification at repeated lymphoscintigraphy was 83%, although in the beginning of lymphoscintigraphy implementation in the study published 1994 (15), the authors showed high SN identification rate by lymphoscintigraphy. Some lately published studies confirmed favorable results with SN identification rate using preoperative lymphoscintigraphy in 96-100% of cases (7,8,16).

Preoperative lymphoscintigraphy may be also inaccurate when melanomas have been resected with large margins (greater than 2.0 cm), especially if the wound was closed with rotation flaps and in melanomas located on the head, neck or on the trunk (17). The failure of SN visualization in our study in the patient with excision scar on the mastoid region (after three repeated imaging, up to 3 hours post injection), could have been caused by disrupted lymphatic drainage after melanoma excision.

All patients have been operated in our surgical departments and the amount of radioactivity injected 4-6 hours before biopsy was sufficient for the intraoperative SN detection using only gamma probe (without blue-dye mapping). In one patient out of 201 radioactivity was not detected after preoperative lymphoscintigraphy at subscapular region. We are aware that leading melanoma centers use both blue dye and gamma probe for intra-operative mapping, but our intra-operative SN identification rate of 99% supports thesis that gamma radiation detection could be sufficient for accurate SN biopsy.

Although majority of the studied patients have had predictable lymphatic drainage on the basis of classic anatomic guidelines, we found lymphatic drainage in two or more contiguous nodal basins and/or in-transit nodes in 24.0% of patients. Lymphatic drainage was unpredictable in some tumors (N=6, 3.0%) and SN situated at unusual place regarding to its classic anatomic position (epitrochanteric, subscapular, nuchal etc.), therefore operative intervention was changed due to this findings. In one patient with melanoma on head and neck SN was not found by preoperative lymphoscintigraphy and in another located on the

shoulder intraoperative localization failed. Despite of the fact that the accuracy of SN identification was lower at head and neck and trunk lesions comparing to extremity (94% vs. 100%), we cannot claim that anatomic site make an important difference for the accuracy of preoperative lymphoscintigraphy with SN biopsy and/or CLND. Namely, only 3 % of patients with unusual drainage pathways were included in our study. Good accuracy in our study may lie in fact that in our Center two surgeons treat all melanoma patients and thereby have enough experience required for a high degree of mapping accuracy. Also, we believe that proper selection of patients for sentinelectomy, which is made by trained specialists from Croatian National Melanoma Center including dermatologist, oncologist, nuclear medicine specialists and surgeons, was crucial in achieving high accuracy.

Some controversy also exists over the utility of different methods for intra-operative SN evaluation in patients with malignant melanoma. Because of 59% of sensitivity for FS some authors (18) not recommend FS for routine use. On the other side, a group from Slovenia (19) recommended use of intra-operative imprint cytology (touch prep) with 46% sensitivity as a valuable method for SN evaluation. Our sensitivity of 91% for FS supports FS examination as a first method for intra-operative evaluation of SN. Furthermore, we believe that recommendations from MSLT-I (7) for co-injection of carbon dye of paraffin-embedded SN specimens may further increase accuracy of the technique in patients with tumor-free specimens by H&E or immunohistochemical staining.

In the study of Uren et al. from 2001 (20), 7.2% of interval nodes were found and a real validity of this finding was confirmed in lately published studies. Namely, available data from Estourgie group (21) showed high incidence of in-transit metastasis and Balch group (2) proved that intralymphatic metastases (satellite lesion around a primary melanoma and in-transit lymph pathway) are associated with poor survival outcomes. In one of our patients with distant metastases but initial negative SN, we found no metastatic deposits in in-transit

node. One reason for systemic metastasis development without regional/local metastatic deposits is hematogeneous tumor cells spread. We found no metastatic cells in in-transit lymph nodes in none of four patients, although several studies suggests that selective lymphadenectomy could alters the incidence of local/in-transit recurrence (21,22). A review from three leading melanoma centers (23) proved that SN biopsy and CLND in SN-positive patients does not increase the incidence of in-transit metastases.

Despite of favorable results demonstrated in the data published during last 15 years regarding the use of a SN biopsy according to AJCC recommendations, several investigators (5,6,8) showed controversies about the indications for SN biopsy. Namely, Kalady et al. (6) reported that 10% of their patients with lesions <0.75 mm have had recurrence event within five years. Bleicher et al. (5) found 12% of recurrences in patients with SN metastases and in 3.7% in those with negative SNs in thin melanomas. They proposed in patients with melanomas with thickness between 0.76 and 1.00 mm a case-by-case evaluation for SN biopsy, including consideration not only a Clark level, but also the age of patients and positive tumor margin after initial biopsies. Considering those findings we performed lymphoscintigraphy with SN biopsy in almost one third (28.0%) of patients with melanoma thinner than 1.5 mm (Table 2). We found a 10.5% incidence of SN metastases from lesion thinner than 1.5 mm, but there were no nodal recurrences in those patients during relatively short follow-up. In addition, in the group with SN-negative patients with thin melanoma there were no local/regional or systemic recurrences.

Overall regional nodal and systemic recurrence of 5.0% in our study group during the 46 months follow-up period is quite similar to other recent published data (22, 24-29). The false negative rate of 1.3% is less than 5% that is generally considered acceptable (28). In the future we could expect some additional recurrences in patients with SN-negative and SN-positive patients, because in previously mentioned studies a median follow-up was much

longer than 23.1 months in our study. This number should not be change with increasing case volume (7).

We also consider that the learning period is crucial in establishing lymphoscintigraphy and SN biopsy as a standard procedure in treatment of patient with early stage melanoma and this is a period for achievement a good collaboration between the different specialists which are included in patients management, which could have a large impact on accuracy of method as well.

Conclusions

Four years of experience in our study of SN biopsy confirmed that preoperative lymphoscintigraphy in patients with malignant melanoma is essential to indicate the drainage basins, determine the number and the position of SNs and also to locate SNs outside the usual nodal basins. Sentinel biopsy comes with low postoperative morbidity of patients and the morbidity was not affected by the unusual placement of SN.

This study supports the use of intraoperative frozen section followed by conventional H&E and immunohistochemical analyses for accurate evaluation of the SN regarding micrometastases.

Independently, the low incidence of disease recurrence in patients with tumor negative SNs supports the use of preoperative lymphoscintigraphy and SN biopsy as a safe and accurate procedure for staging the regional nodal basin. According to the SN status, patients were directed for further treatment and follow-up.

The main limitations of our study are relatively short follow-up period and that subgroup of patients with disease recurrences was not analyzed regarding other known prognostic factors such as age and the presence of ulceration.

REFERENCES

1. Sim FH, Taylor WF, Ivinc JC, Pritchard DJ, Soule EH (1978) A prospective randomised study of the efficacy of routine elective lymphadenectomy in management of malignant melanoma. Preliminary results. *Cancer* 41: 948 56.
2. Balch CM, Soong SJ, Atkins MB, Buzaid AC, Cascinelli N, Coit DG, et al. (2004) An evidence-based staging system for cutaneous melanoma. *CA Cancer J Clin* 2004;54:131-149.
3. Gray RJ, Pockaj BA, Kirkwood JM (2002) An update on adjuvant interferon for melanoma. *Cancer Control* 9:16 21.
4. DiFronzo LA, Morton DL (2000) Melanoma vaccines: current status of clinical trials. *Adv Oncol* 16:23 29.
5. Bleicher RJ, Essner R, Foshag LJ, Wanek LA, Morton DL (2003) Role of sentinel lymphadenectomy in thin invasive cutaneous melanoma. *J Clin Oncol* 21: 1326 1331.
6. Kalady MF, White RR, Johnson JL, Tyler DS, Steigler HF (2003) Thin melanomas: predictive lethal characteristics from a 30-year clinical experience. *Ann Surg* 238: 528-537.
7. Morton DL, Cochran AJ, Thompson JF, Elashoff R, Essner R, Glass EC, et al. (2005) Sentinel node biopsy for early-stage melanoma. Accuracy and morbidity in MSLT-I, an international multicenter trial. *Ann Surg* 242: 302 313.
8. Nieweg OE, van Rijk MC, Valdes Olmos RA, Hoefnagel CA (2005) Sentinel node biopsy and selective lymph node clearance – impact on regional control

- and survival in breast cancer and melanoma. *Eur J Nucl Med Mol Imaging* 32: 631-634.
9. Haid A, Knauer M, Koberle-Wuhrer R, Wenzel E. (2005) [Sentinel node biopsy in breast cancer: techniques and indications] *Wien Klin Wochenschr* 117(4):212-128.
 10. Wilhelm AJ, Mijnhout GS, Franssen EJ (1999) Radiopharmaceuticals in sentinel node detection - an overview. *Eur J Nucl Med* 26(supp): S36-42.
 11. Mudun A, Murray DR, Herda SC, Eshima D, Shattuck LA, Vansant JP, et al. (1996) Early stage melanoma: lymphoscintigraphy, reproducibility of sentinel node detection, and effectiveness of the intraoperative gamma probe. *Radiology* 199:171-5.
 12. Kalady MF, White DC, Fields RC, Coleman RE, Schuler FR, Seigler HF, Tyler DS (2001) Validation of delayed sentinel lymph node mapping for melanoma. *Cancer* 7:503-8.
 13. Kapteijin BAE, Nieweg OE, Olmos V, Liem IH, Panday RK, Hoefnagel Ca, Kroon BB (1996) Reproducibility of lymphoscintigraphy for lymphatic mapping in cutaneous melanoma. *J Nucl Med* 37:972-4.
 14. Norman J, Wells K, Kearney R, Cruse CW, Berman C, Reintgen D (1993) Identification of lymphatic drainage basins in patients with cutaneous melanoma. *Semin Surg Oncol* 9:224-7.
 15. Uren RF, Howman-Giles R, Thompson JF, Shaw HM, Quin MJ, O'Brien CJ, McCarty WH (1994) Lymphoscintigraphy to identify sentinel lymph nodes in patients with malignant melanoma. *Melanoma Res*; 4:395-9.
 16. Berman C, Choi J, Hersh MR and Clark RA (2000) Melanoma lymphoscintigraphy and lymphatic mapping. *Sem Nucl Med*; 30: 49-55.

17. Kelemen PR, Essner R, Foshag LJ, Morton D (1999) Lymphatic mapping and sentinel lymphadenectomy after wide local excision of primary melanoma. *J Am Coll Surg* 189: 247-52.
18. Stojadinovic A, Allen PJ, Clary BM, Busam KJ, Coit DG (2002) Value of frozen-section analyses of sentinel lymph nodes for primary cutaneous malignant melanoma. *Ann Surg* 235: 92-98.
19. Hocevar M, Bracko M, Pogacnik A, Vidergar-Kralj B, Besic N, Zganjar J (2003) Role of imprint cytology in the intraoperative evaluation of sentinel nodes for malignant melanoma. *Eur J Cancer* 39: 2173-2178.
20. Uren RF, Howman-Giles R, Thompson JF, Mc Carthy WH, Quinn MJ, Roberts JM, Shaw HM (2000) Interval nodes: forgotten sentinel nodes in patients with melanoma. *Arch Surg* 135: 1168-1172.
21. Estourgie SH, Nieweg OE, Kroon BB, (2004) High incidence of in transit metastases after sentinel node biopsy in patients with malignant melanoma. *Br J Surg* 91: 1370-1371.
22. Thomas JM, Clark MA (2004) Selective lymphadenectomy in sentinel node-positive patients may increase the risk of local/in-transit recurrence in malignant melanoma. *Eur J Surg Onkol* 30: 686-691.
23. Pawlik TM, Ross MI, Thompson FJ, Eggermont AMM, Gershenwald JE (2005) The risk of in-transit melanoma metastases depends on tumor biology and not the surgical approach to regional lymph nodes. *J Clin Oncol* 23: 4588-4590.
24. Berk DR, Johnson DL, Uzieblo A, Kiernan M, Swetter SM (2005) Sentinel lymph node biopsy for cutaneous melanoma: the Stanford experience, 1997-2004. *Arch Dermatol* 141: 1016-1022.

25. Kretschmer L, Beckmann T, Thomas KM, Haenssle H, Bertsch HP, Neuman CH (2005) Sentinel lymphonodectomy does not increase the risk of loco-regional cutaneous metastases of malignant melanoma. *Eur J Cancer* 41: 531-538.
26. Kang JC, Wanek LA, Essner R, Faries MB, Foshag LJ, Morton DL (2005) Sentinel lymphadenectomy does not increase the incidence of in-transit metastases in primary melanoma. *J Clin Oncol* 21: 4764-4770.
27. van Akkooi ACJ, de Wilt JHW, Verhoef C, Graveland WJ, van Geel AN, Kliffen M, Eggermont AMM (2005) Prognostic indicators of locoregional and systemic recurrences after sentinel lymph node biopsy in patients with cutaneous melanomas. The European cancer conference ECCO 13, Paris, france, November. Citation: *Eur J Cancer suppl* 3, p. 344.
28. Zogakis TG, Essner R, Wang H, Turner RR, Takasumi YT, Gaffney RL, Lee JH, Morton DL (2005) Melanoma recurrence patterns after negative sentinel lymphadenectomy. *Arch Surg* 140: 865-8
29. Čizmarević B, Žargi M (2006) Sentinel-Lymphknoten bei oralen und oropharyngealen lymphoepithelialen Tumoren. *Wien Klin Wochenschr* 118: 114-119.

Table 1. Clinical characteristics of patients with melanoma with sentinel node biopsy.

Characteristics	N	%
Gender		
Male	94	46.7
Female	107	53.3
Age (years)		
Median	54.0	
Range	67.0	
Site of primary tumor		
Head and neck	17	8.5
Trunk	107	53.3
Extremity		
Upper	32	15.9
Lower	45	22.3
Basins biopted	142	70.6
One	52	25.1
Two	6	3.0
Three	1	0.5
Four		
Melanoma thicknes (mm)		
Median	2.1	
Range	8.6	
Melanoma diameter (mm)		
Median	18.0	
Range	36.2	

Table 2. Patient classifications according to Breslow thickness of primary melanoma and distribution of sentinel node positive patients by tumor depths.

Breslow classification	Patients		Sentinel node positive patients		Tumor depths (mm)	
	N	%	N	%	Median	Range
I	15	7.5	2	13.3	0.62	0.60
II	42	20.9	4	9.5	1.14	1.21
III	53	26.5	8	15.0	2.01	2
IV	28	13.9	12	42.8	2.98	4
V	63	31.4	16	25.3	5.02	7.8

Table 3. Sentinel node status of melanoma patients in relation to primary tumor location and biopsied basins, including in-transit lymph nodes status.

Primary tumor site	No. of drainage lymphatic basins									
	One		Two		Three		Four		In-trans	
	Sentinele Node Status (SN)									
	* +	♦ -	+ -	+ -	+ -	+ -	+ -	+ -	+ -	+ -
Head/neck	0	8	0	5	1	2				
Trunk	22	41	8	31	0	3	1	0	0	2
Upper extremities	3	29								
Lower extremities	7	38							0	2
Total	32	116	8	36	1	5	1	0	0	4

* + revealed sentinel node positive patients;

♦ – revealed sentinel node negative patients.

Table 4. Distribution of patients who had tumor positive sentinel nodes and patients whose melanoma recurred by drainage nodal basins.

Sentinel node basin	Total No. of patients (N=201)		Sentinel positive patients (N=42)		Patients with disease recurrence (N=10)
	N	%	N	%	
Axilla	84	41.7	15	17.8	4
Groin	45	22.3	13	28.9	4
Cervical	17	8.5	1	5.9	0
Multiple	49	24.3	12	24.5	2
Other*	6	3.0	1	20.0	0

Table 5. Incidence of regional or distant melanoma recurrences in relation to sentinel node status at patients median follow-up of 23 months.

	Sentinel positive patients (N=42)	Sentinel negative patients (N=157)
Recurrence	8	2
Local nodal/in-transit	7	1
Distant	1	1




Figure 1.

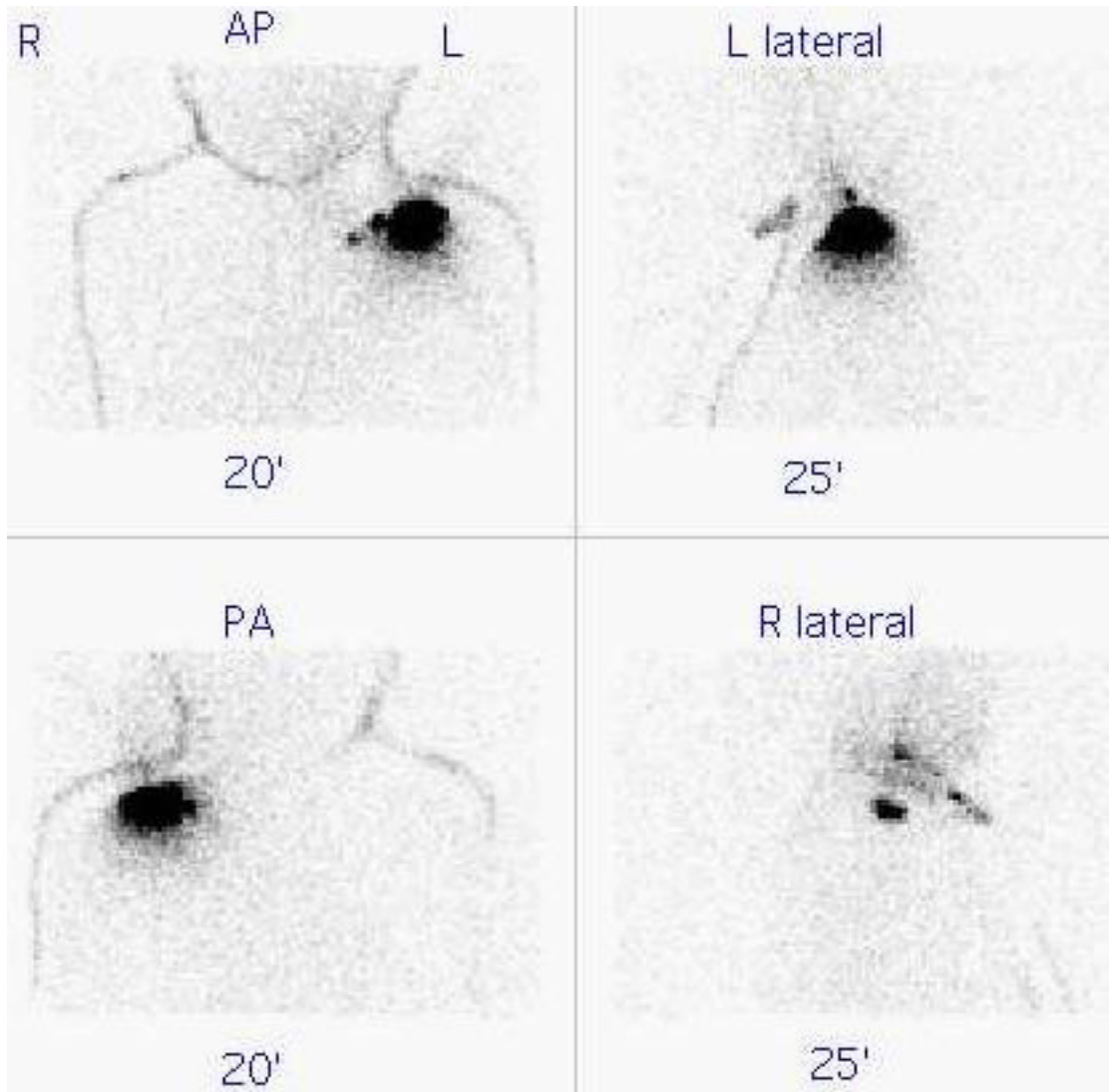


Figure 2.

Legends of the figures:

Figure 1. Dual nodal basins drainage. Dynamic images of melanoma in the middle of the abdominal wall: upper row - sequential filling from first to fifth image demonstrates drainage pathways to the right inguinal region with one sentinel node. The next five sequential images (bottom row) shows second basin in right axilla region with one sentinel lymph node and “in transit” node (circle).

Figure 2. Primary melanoma on the left shoulder (the largest hot spot). Static (5-minutes studies) in anterior (AP), posterior (PA), left (L lateral) and right lateral (R lateral) view 20 and 25 minutes post injection: lymphatic drainage from primary melanoma of the left shoulder to the left supraclavicular (retroclavicular) region and two sentinel nodes.