

Laparoscopic partial nephrectomy with diode laser: a promising technique

Knežević, Nikola; Kuliš, Tomislav; Marić, Marjan; Topalović Grković, Marija; Krhen, Ivan; Kaštelan, Željko

Source / Izvornik: **Photomedicine and Laser Surgery, 2014, 32, 101 - 105**

Journal article, Accepted version

Rad u časopisu, Završna verzija rukopisa prihvaćena za objavljivanje (postprint)

<https://doi.org/10.1089/pho.2013.3646>

Permanent link / Trajna poveznica: <https://urn.nsk.hr/urn:nbn:hr:105:476331>

Rights / Prava: [In copyright](#)/[Zaštićeno autorskim pravom.](#)

Download date / Datum preuzimanja: **2025-01-28**



Repository / Repozitorij:

[Dr Med - University of Zagreb School of Medicine
Digital Repository](#)





Središnja medicinska knjižnica

Knežević N., Kuliš T., Marić M., Topalović Grković M., Krhen I., Kaštelan Ž. (2014) *Laparoscopic partial nephrectomy with diode laser: a promising technique*. Photomedicine and Laser Surgery, 32 (2). pp. 101-5. ISSN 1549-5418

<http://www.liebertpub.com/pho>

<http://dx.doi.org/10.1089/pho.2013.3646>

<http://medlib.mef.hr/2334>

University of Zagreb Medical School Repository

<http://medlib.mef.hr/>

Laparoscopic partial nephrectomy with diode laser – promising technique

Nikola Knezevic M.D., Ph.D., Tomislav Kulis M.D., Ph.D., Marjan Maric M.D., Marija Topalovic Grkovic M.D., Ivan Krhen M.D., Ph.D., Zeljko Kastelan M.D., Ph.D.

Department of Urology, University Hospital Center Zagreb, University of Zagreb School of Medicine, Zagreb, Croatia

Running title: Laser laparoscopic partial nephrectomy

Keywords: laparoscopy, laser, nephrectomy, renal cancer, surgical technique

Nikola Knezevic

Department of Urology, University Hospital Center Zagreb

Kispaticeva 12

10000 Zagreb

Croatia

Phone: +38512388504

Fax: +38512376026

e-mail: nknezevic5@yahoo.com

Corresponding author

Tomislav Kulis

Department of Urology, University Hospital Center Zagreb

Kispaticeva 12

10000 Zagreb

Croatia

Phone: +38512388504

Fax: +38512376026

e-mail: tkulis@gmail.com

Marjan Maric

Department of Urology, University Hospital Center Zagreb

Kispaticeva 12

10000 Zagreb

Croatia

Phone: +38512388504

Fax: +38512376026

e-mail: marjan_maric@yahoo.com

Marija Topalovic Grkovic

Department of Urology, University Hospital Center Zagreb

Kispaticeva 12

10000 Zagreb

Croatia

Phone: +38512388504

Fax: +38512376026

e-mail: mtopalovicgrkovic@yahoo.com

Ivan Krhen

Department of Urology, University Hospital Center Zagreb

Kispaticeva 12

10000 Zagreb

Croatia

Phone: +38512388504

Fax: +38512376026

e-mail: ivankrhen@gmail.com

Zeljko Kastelan

Department of Urology, University Hospital Center Zagreb

Kispaticeva 12

10000 Zagreb

Croatia

Phone: +38512388504

Fax: +38512376026

e-mail: zeljko.kastelan@gmail.com

Abstract

Objective: Aim of this study was to evaluate application of diode laser in laparoscopic partial nephrectomy (LPN) and to question this technique in terms of ease of tumor excision and reduction of warm ischaemia time (WIT).

Background: LPN is standard operative method for small renal masses. Benefits of LPN are numerous, including preserving renal function and prolonging overall survival. However, reduction of WIT remains main challenge in this operation. In order to shorten WIT many techniques have been developed with variable results.

Patients and Methods: We performed a prospective collection and analysis of health records for patients who were operated between March 2011 and August 2012. Inclusion criteria were single tumor ≤ 4 cm, predominant exophytic growth and intraparenchymal depth ≤ 1.5 cm, with a minimum distance of 5 mm from the urinary collecting system.

Results: We have operated 17 patients. Median operative time was 170 min. In all patients, except two patients we had to perform hilar clamping. Median duration of WIT was 16 min.

Pathohistological evaluation revealed clear cell renal cancer and confirmed margins negative for tumor in all cases. Median size of tumor was 3 cm. Median postoperative hospitalization was 5 days. Average follow up was 11.5 months. There were no intraoperative complications. One postoperative complication was noted, perirenal haematoma.

Conclusions: Laser LPN is feasible and offers benefit of shorter WIT with effective tissue coagulation and hemostasis. With operative experience and technical advances WIT will be reduced or even eliminated and solution to some technical difficulties, such as significant smoke production, will be found.

Introduction

Renal cancer (RC) accounts for approximately 2% of all malignancies occurring in adults ¹.

Epidemiological studies report increasing incidence of renal cancer during the last two decades until recently, both worldwide and in Europe ². The incidence of RC in Croatia is 9.4 per 100.000 ³ what is significantly higher than the worldwide rate of 3.9 per 100.000 ⁴. There are some indications that a recent increase in incidence together with a stage shift to more organ confined stages can be observed ⁵. This is partially attributable to increased frequency of diagnostic imaging, such as ultrasound and computed tomography. This renders higher number of small renal masses (SRM) (i.e. tumors < 4cm). The most profound change among the many that have occurred in the management of RC is current recommendation for treatment of SRMs, if possible, with nephron sparing surgery (NSS) ⁶. Open partial nephrectomy, the erstwhile reference standard treatment for small renal masses, has demonstrated no difference in either overall or cancer-specific survival compared to radical nephrectomy with the benefit of better preservation of renal function ⁷. Reports have confirmed equal oncological outcomes with laparoscopic partial nephrectomy but with advantages of minimally invasive surgery ⁸. However, the main challenge to reduce the morbidity associated with this procedure is still remaining.

The need for hilar clamping in case of laparoscopic partial nephrectomy (LPN) is currently necessary to create a bloodless field for renal excision. However, hilar clamping places time constraint for the surgeon and increased warm ischaemia time (WIT) compromise renal function in subsequent postoperative period. Since none of the current operative techniques is the most effective there are many techniques that have been developed to achieve hemostasis, including conventional suture repair, tissue sealants, radiofrequency ablation, water dissection, microwave tissue coagulation and lasers ⁹. Different ex vivo laser assisted LPN were published ¹⁰. However, few in-vivo surgery series are available ¹¹. Aim of this study was to evaluate application of diode laser in laparoscopic partial

nephrectomy and to question this technique in terms of ease of tumor excision and reduction of WIT.

Patients and methods

We performed a prospective collection and analysis of health records for patients who were operated laparoscopically with application of laser for SRMs at University Hospital Center Zagreb, Zagreb, Croatia, from March 2011 to August 2012. Diagnosis of SRM was based on computed tomography scans and/or magnetic resonance imaging. Inclusion criteria were single tumor with size ≤ 4 cm, predominant exophytic growth and intraparenchymal depth ≤ 1.5 cm, with a minimum distance of 5 mm from the urinary collecting system. R.E.N.A.L nephrometry score was used to describe renal mass anatomy¹². Exclusion criteria were ASA-score ≥ 3 , centrally located tumor and (functional) single kidney. Both medical and surgical complications were recorded according to the modified Dindo-Clavien classification¹³. One laparoscopic surgeon (N.K.) performed all procedures.

Surgical technique

Conventional laparoscopic lateral transperitoneal approach with 4 trocars was used in all cases. Firstly, renal tumor was identified and kidney fully mobilized, allowing the manipulation for circumferential laser resection (Figure 1). Hilar vessels were always identified. For renal resection we have used diode laser 980 nm (Ceralas[®] HPD, Biolitec AG, Jena, Germany) with end fire 1000 μ m laser fibre BFF-1003-dl (Biolitec AG, Jena, Germany). For last case we have used Dual diode laser 980 and 1470 nm (Ceralas[®]HPD DUAL, Biolitec AG, Jena, Germany). Chromophore target for 980nm laser is haemoglobin and for dual laser 980/1470 nm haemoglobin/water. Laser fibre was introduced through 10mm trocar with special holder designed for laparoscopic application and in last case we have used special holder with simultaneous irrigation and suction (S064 Jet Suction Irrigator, SUS, Barnsley, UK). Power settings were continuous mode with power settings 20-80W. Demarcation of safe initial resection line around tumor was done with laser (power settings initially were 20-40W,

and in later cases 40-60W). We would continue with laser tumor resection with an adequate free resection margins in contact fashion (up to 80W) (Figure 2). At time of more significant bleeding due to resection of larger blood vessels we would tighten priorly placed laparoscopic tourniquet at renal artery. Diode laser 980nm proved to be more efficient with faster resection time in ischemic conditions. When tumor was resected, cellulose mesh was placed on the resection bed and fixed with one parenchymal suture (2-0 Vicryl) (Figure 3). Finally, tourniquet could be released without significant bleeding. If needed additional parenchymal sutures were placed. The tumor was removed using laparoscopic retrieval bag (Memo Bag, 200mL, Rüschi, Teleflex Medical). After removal, specimen was checked to ensure macroscopically tumor free surgical margin. Figure 4 illustrates representative preoperative CT images.

Results

We have operated 17 patients with small peripherally placed renal tumors (Table 1). All operations were successfully performed laparoscopically. Median operative time was 170 min (140 to 240 min). In all patients except two patients we had to perform hilar clamping. Median laser activity prior to hilar clamping was 15 min and was followed with median duration of WIT 16 min. One patient that did not require hilar clamping had small 2cm SRM mostly exophytic. Second patient had 3.5 cm large tumor which was resected with Dual diode laser. This laser system proved more effective regarding haemostasis, however due to excessive smoke production and thus impaired visibility this laser resection lasted for 40 min. Median blood loss was 70 mL (50 to 200 mL), and none of patients required postoperative transfusion.

Pathohistological evaluation revealed clear cell renal cancer and confirmed margins negative for tumor in all cases. There were no intraoperative complications. One postoperative complication was noted, perirenal haematoma, which was treated conservatively (Clavien grade 2).

Discussion

The present study includes a series of patients with SRMs treated effectively laparoscopically and utilizing laser as a method of renal resection. Our series points that laparoscopic partial nephrectomy with laser is feasible and offers benefit of shorter WIT with more effective tissue coagulation, hemostasis and potential for omission of hilar clamping.

The location, size and exophytic properties of the lesion determine potential complexity of the operation therefore objective characterization of renal mass anatomy facilitates treatment selection and prediction of surgical outcomes. R.E.N.A.L nephrometry score was developed for this purpose and in our series all tumors were scored 6 or less, suggesting a clear selection of patients at low risk for complications.

Partial nephrectomy is the prevailing method for small sized tumors and proven to be better in preservation of renal function compared to radical nephrectomy⁷. LPN is technically challenging procedure mainly because of the lack of reliable methods of hemostasis and requiring prolonged WIT. The effect of WIT on postoperative renal function is one of the central questions regarding LPN. Thus, new techniques are needed to abandon hilar clamping. Laser technology presents a promising alternative to achieve tumor excision and renal haemostasis, with or without hilar occlusion. Laser offers a possibility of both open and laparoscopic partial nephrectomy.

Several experimental studies have demonstrated the efficiency of laser assisted open or laparoscopic partial nephrectomy in various experimental set-ups. Ogan et al. have reported first experiences with diode laser 980-nm laparoscopic partial nephrectomy in porcine with conclusion that clinical trials in humans should be limited to small exophytic tumors¹⁴. Up to date twelve research groups have published small series concerning clinically tested laser assisted open or laparoscopic partial nephrectomies^{11, 15-25}. Up to our knowledge this is largest published series of laser laparoscopic partial nephrectomy.

It has been reported that renal damage is proportional to the WIT with current recommendation that WIT should stay within 20 minutes²⁶. Lane et al. estimated a decline in GFR of 2.2 ml/min/1.73m² per every 5 min of WIT²⁷. It has been traditionally considered that LPN has a longer WIT than open partial nephrectomy. In the developmental stages of LPN, mean WIT was in the 30 minute range. However, modifications to standard LPN techniques have helped improve WIT²⁸. In recently published comparative series of LPN vs. open or robotic partial nephrectomy mean WIT for LPN was in a range of 13.0 to 36.4 minutes^{29,30}. Our series with a median WIT of 16 min and with two cases without WIT is example of this improvement. Additionally, complications of partial nephrectomy include hemorrhage, urinary leak, infection, formation of urinary fistula, and the development of renal insufficiency³¹.

Laser function is achieved through absorption of its energy on chromophores³². Absorbed laser radiation is converted into heat, causing a local rise in temperature. Depending on the amount of heat produced, tissue will coagulate or even vaporize. Chromophores are chemical groups capable of absorbing light at a particular frequency and thereby imparting color to a molecule. In surgery, chromophores that are most often used are haemoglobin and water. Diode 980nm laser is absorbed on haemoglobin and we have noticed that if during kidney resection some bleeding is present it is inadequate in further resection. At this time we had to clamp the artery reducing bleeding and were able to continue with at this time even faster resection. Since dual diode 980/1470 nm laser at the same time is absorbed on water and haemoglobin it offers the possibility of tissue coagulation even if larger bleeding is present. Our experience with dual laser is limited (one case) but it proved more effective, faster and with better coagulation properties. However, it also produces more smoke. In our opinion there are several factors that can help in achieving 0 min WIT: careful patient selection (small and exophytic tumors) and lasers that are absorbed on water (e.g. Dual diode lasers or Thulium lasers). Until we achieve further clinical experience cellulose mesh and/or parenchymal sutures will continue to be used for larger tumors.

The major disadvantage of the laser is remarkable smoke production obstructing adequate visibility in laparoscopic surgery. There are several possibilities to deal with this situation. Slow saline irrigation could lower smoke production with questionable effect on laser coagulation efficiency³³. Liang et. al investigated Thulium-YAG laser and influence of several irrigation rates on coagulation efficiency. They reported acceptable influence on coagulation with suitable effect on smoke production³⁴. This might be even more acceptable in lasers with wavelength absorbed on haemoglobin such as diode laser 980nm. We have tested this effect in some parts of the operation. While it was bleeding we used water irrigation to clear resection line. However, at that time due to inability to utilize suction at the same time we limitedly used continuous irrigation. Second method to improve visibility is gas suction; however this requires capacitive insufflation system. Also this could require additional trocar for the assistant. However, we managed to acquire one instrument that can deliver laser fiber, irrigation and suction canal at the same time. We have tested it with Dual laser and found that while small rate of irrigation is indeed successful in reducing smoke production it reduces effectiveness of wavelength 1470nm therefore slowing resection and reducing coagulation effect. Furthermore, suction even though placed near the tip of the laser fiber did not adequately evacuated produced smoke while it significantly lowered pneumoperitoneum pressure.

Currently, European Association of Urology guidelines considers that a minimal tumor free margin is sufficient to avoid local tumor recurrence⁶. One possible disadvantage of laser LPN is impaired intraoperative visibility of resection plane due to coagulated and burned tissue what might increase occurrence of positive surgical margins (PSM). However, with adequate surgical technique and prior demarcation of resection line around the tumor one can achieve tumor free margins. Positive surgical margins in laparoscopic partial nephrectomy are in a range of 0.7–4%³⁵ and in our series none of the patients had PSM. Frozen section analysis for evaluation of resection margins during LPN is of minor clinical significance, as the surgeon's gross assessment of macroscopically negative

margins provides reliable results³⁵. It is also notable that tissue necrosis zone after laser resection creates additional safety margin what may render PSM clinically insignificant.

Study limitations include the small sample size, the lack of a control group and the short follow-up period.

Conclusions

Laparoscopic partial nephrectomy with laser is feasible and offers benefit of shorter WIT with more effective tissue coagulation, hemostasis and potential for omission of hilar clamping. Laser cutting should be performed at a small distance to the tissue with a slow velocity of fibre movement to achieve best cutting and coagulation properties. With operative experience and technical advances in laser and fibre production WIT will be reduced or even eliminated and solution to some technical difficulties, such as significant smoke production, will be found. LPN with laser should be attempted in carefully selected patients with favorable features of tumor anatomy. Further studies with longer follow up are needed to establish oncologic efficacy of the procedure.

Author Disclosure Statement

Authors Nikola Knezevic, Tomislav Kulis, Marjan Maric, Marija Topalovic Grkovic, Ivan Krhen, Zeljko Kastelan state that no competing financial interests exist.

References

1. Jemal A., Siegel R., Xu J., Ward E. (2010). Cancer statistics, 2010. *CA Cancer J Clin* 60, 277-300.
2. Lindblad P. (2004). Epidemiology of renal cell carcinoma. *Scand J Surg* 93, 88-96.
3. Croatian National Cancer Registry. (2011). Cancer incidence in Croatia 2009. Bulletin No 34. (Croatian National Institute of Public Health, Zagreb).
4. Ferlay J., Shin H.R., Bray F., Forman D., Mathers C., Parkin D.M. (2010). GLOBOCAN 2008, Cancer Incidence and Mortality Worldwide: IARC CancerBase No. 10: Lyon, France: International Agency for Research on Cancer.
5. Palsdottir H.B., Hardarson S., Petursdottir V., et al. (2012). Incidental detection of renal cell carcinoma is an independent prognostic marker: results of a long-term, whole population study. *J Urol* 187, 48-53.
6. Ljungberg B., Cowan N.C., Hanbury D.C., et al. (2010). EAU guidelines on renal cell carcinoma: the 2010 update. *Eur Urol* 58, 398-406.
7. MacLennan S., Imamura M., Lapitan M.C., et al. (2012). Systematic review of oncological outcomes following surgical management of localised renal cancer. *Eur Urol* 61, 972-93.
8. Lane B.R., Gill I.S. (2010). 7-year oncological outcomes after laparoscopic and open partial nephrectomy. *J Urol* 183, 473-9.
9. Walters R.C., Collins M.M., L'Esperance J.O. (2006). Hemostatic techniques during laparoscopic partial nephrectomy. *Curr Opin Urol* 16, 327-31.
10. Khoder W.Y., Zilinberg K., Waidelich R., et al. (2012). Ex vivo comparison of the tissue effects of six laser wavelengths for potential use in laser supported partial nephrectomy. *J Biomed Opt* 17, 068005.
11. Khoder W.Y., Sroka R., Siegert S., Stief C.G., Becker A.J. (2011). Outcome of laser-assisted laparoscopic partial nephrectomy without ischaemia for peripheral renal tumours. *World J Urol*.
12. Kutikov A., Uzzo R.G. (2009). The R.E.N.A.L. nephrometry score: a comprehensive standardized system for quantitating renal tumor size, location and depth. *J Urol* 182, 844-53.
13. Dindo D., Demartines N., Clavien P.A. (2004). Classification of surgical complications: a new proposal with evaluation in a cohort of 6336 patients and results of a survey. *Ann Surg* 240, 205-13.
14. Ogan K., Wilhelm D., Lindberg G., et al. (2002). Laparoscopic partial nephrectomy with a diode laser: porcine results. *J Endourol* 16, 749-53.
15. Hodgson D., Karamanolakis K., al. e. (2008). Appraisal of a novel procedure: potassium titanyl phosphate (ktp) laser laparoscopic partial nephrectomy. Abstracts of the Engineering and Urology Society, May 19, 2007, Anaheim, California, USA. Abstract #116. *J Endourol* 22, 159-212.
16. Barzilay B., Lijovetzky G., Shapiro A., Caine M. (1982). The clinical use of CO2 laser beam in the surgery of kidney parenchyma. *Lasers Surg Med* 2, 81-7.
17. Gruschwitz T., Stein R., Schubert J., Wunderlich H. (2008). Laser-supported partial nephrectomy for renal cell carcinoma. *Urology* 71, 334-6.
18. Korhonen A.K., Talja M., Karlsson H., Tuhkanen K. (1993). Contact Nd:YAG laser and regional renal hypothermia in partial nephrectomy. *Ann Chir Gynaecol Suppl* 206, 59-62.
19. Lotan Y., Gettman M.T., Ogan K., Baker L.A., Cadeddu J.A. (2002). Clinical use of the holmium: YAG laser in laparoscopic partial nephrectomy. *J Endourol* 16, 289-92.
20. Malloy T.R., Schultz R.E., Wein A.J., Carpiniello V.L. (1986). Renal preservation utilizing neodymium:YAG laser. *Urology* 27, 99-103.
21. Merguerian P.A., Seremetis G. (1994). Laser-assisted partial nephrectomy in children. *J Pediatr Surg* 29, 934-6.
22. Rosemberg S.K. (1985). Clinical experience with carbon dioxide laser in renal surgery. *Urology* 25, 115-8.

23. Loertzer H., Strauss A., Ringert R.H., Schneider P. (2013). Laser-supported partial laparoscopic nephrectomy for renal cell carcinoma without ischaemia time. *BMC urology* 13, 31.
24. Thomas A.Z., Smyth L., Hennessey D., O'Kelly F., Moran D., Lynch T.H. (2013). Zero Ischemia Laparoscopic Partial Thulium Laser Nephrectomy. *J Endourol*.
25. Mattioli S., Munoz R., Recasens R., Berbegal C., Teichmann H. (2008). [What does Revolix laser contribute to partial nephrectomy?]. *Arch Esp Urol* 61, 1126-9.
26. Becker F., Van Poppel H., Hakenberg O.W., et al. (2009). Assessing the impact of ischaemia time during partial nephrectomy. *Eur Urol* 56, 625-34.
27. Lane B.R., Novick A.C., Babineau D., Fergany A.F., Kaouk J.H., Gill I.S. (2008). Comparison of laparoscopic and open partial nephrectomy for tumor in a solitary kidney. *J Urol* 179, 847-51; discussion 52.
28. Eisenberg M.S., Brandina R., Gill I.S. (2010). Current status of laparoscopic partial nephrectomy. *Curr Opin Urol* 20, 365-70.
29. Aboumarzouk O.M., Stein R.J., Eyraud R., et al. (2012). Robotic versus laparoscopic partial nephrectomy: a systematic review and meta-analysis. *Eur Urol* 62, 1023-33.
30. Brandina R., Aron M. (2010). Laparoscopic partial nephrectomy: advances since 2005. *Curr Opin Urol* 20, 111-8.
31. Wheat J.C., Roberts W.W., Hollenbeck B.K., Wolf J.S., Jr., Weizer A.Z. (2013). Complications of laparoscopic partial nephrectomy. *Urol Oncol* 31, 57-62.
32. Herrmann T.R., Liatsikos E.N., Nagele U., Traxer O., Merseburger A.S. (2012). EAU guidelines on laser technologies. *Eur Urol* 61, 783-95.
33. Liu M., Rajbabu K., Zhu G., Petersen A., Muir G.H., Poulson J. (2006). Laparoscopic partial nephrectomy with saline-irrigated KTP laser in a porcine model. *J Endourol* 20, 1096-100.
34. Liang J.H., Pan Y.L., Kang J., Qi J. (2012). Influence of irrigation on incision and coagulation of 2.0-mum continuous-wave laser: an ex vivo study. *Surg Laparosc Endosc Percutan Tech* 22, e122-5.
35. Marszalek M., Carini M., Chlosta P., et al. (2012). Positive surgical margins after nephron-sparing surgery. *Eur Urol* 61, 757-63.

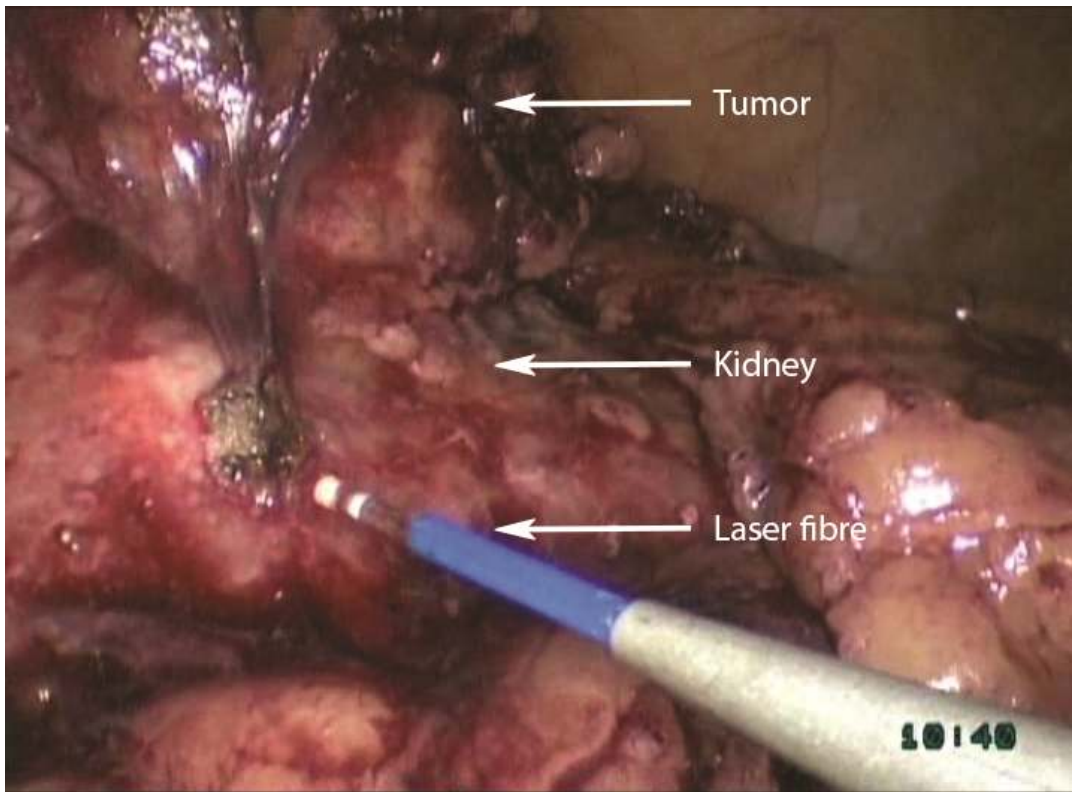


Figure 1. Beginning of the resection with the laser.

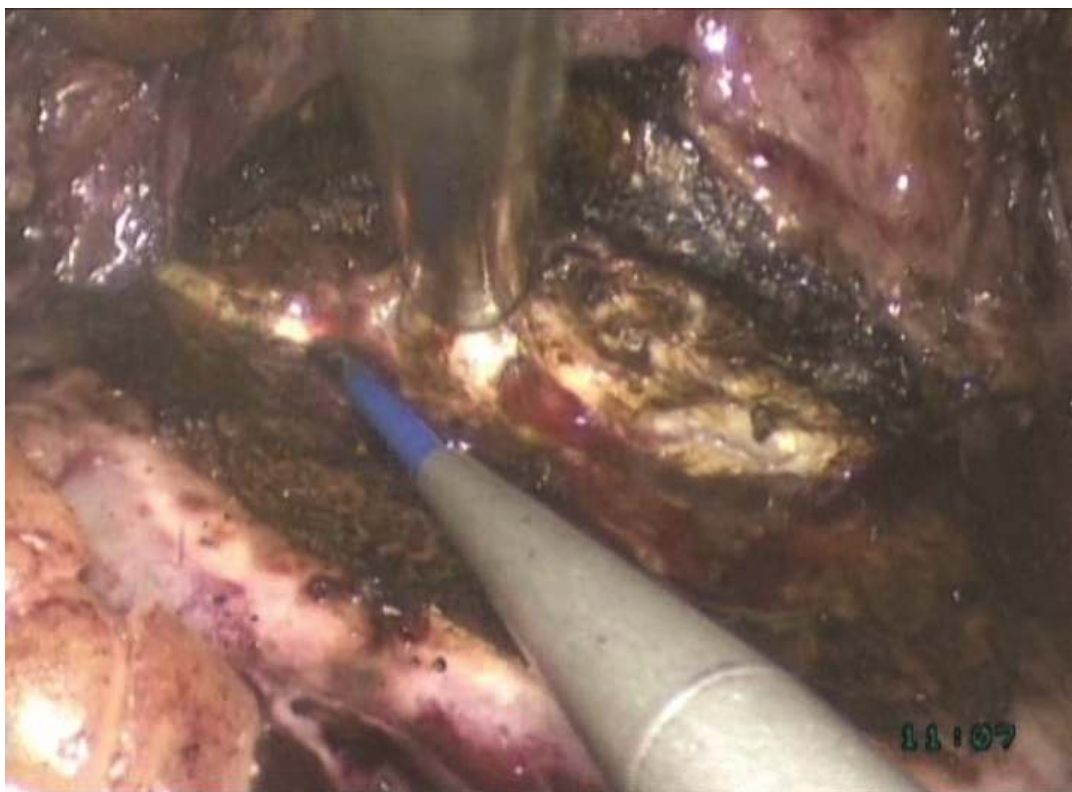


Figure 2. Laser resection and concomitant smoke suction.

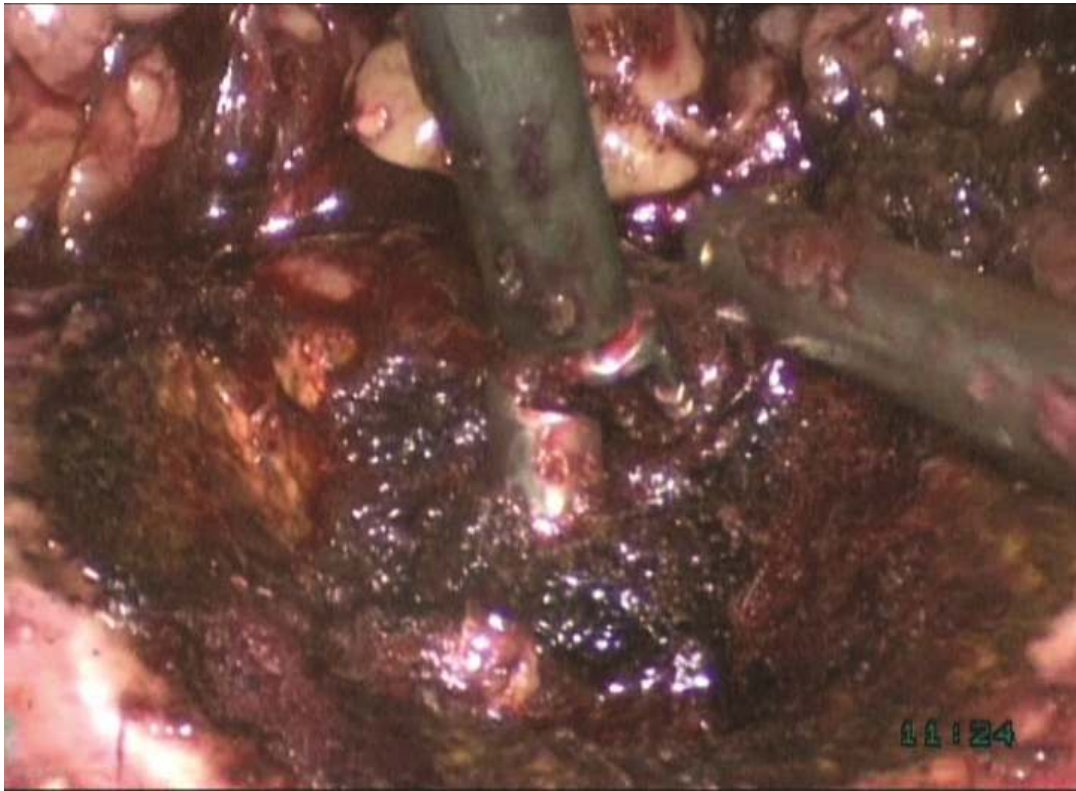

Figure 3. View of the transection bed.

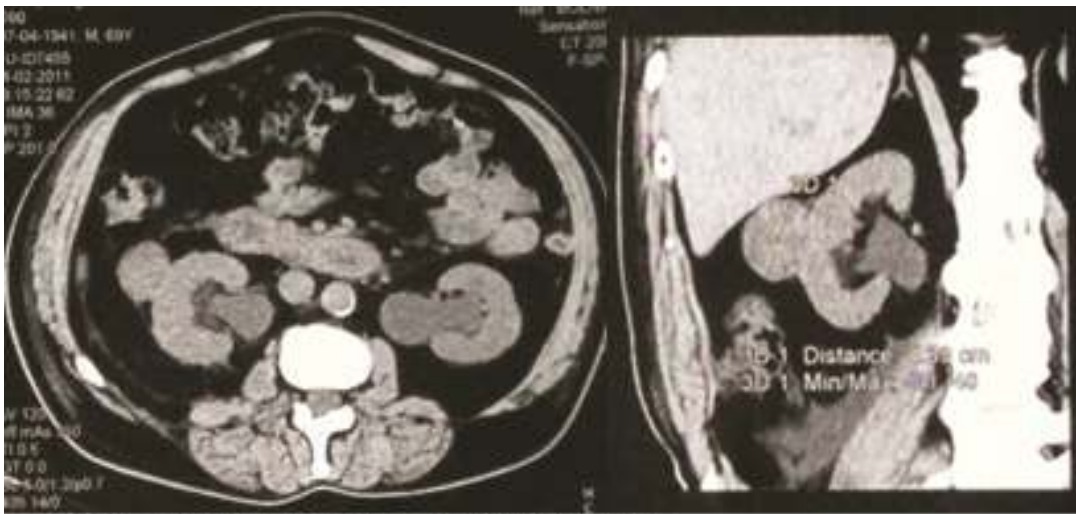

Figure 4. Preoperative CT images of renal tumor.

Table 1. Summary of demographic, intraoperative and postoperative data for laser assisted laparoscopic partial nephrectomy

No. of patients	17
Average age (years)	61.6 (41.5-75.3)
Sex (M/F)	10/7
Side (left/right)	9/8
Median operative time (min)	170 (140-240)
Median blood loss (mL)	70 (50-200)
Median warm ischaemia time (min)	16 (9-20)
Median hospitalization (days)	5 (5-9)
Average follow up (months)	11.5 (1-18)
<i>Pathohistologic evaluation</i>	
Clear cell renal cancer	17
Median tumor size	3 (2-4.8)