

Stress fractures of the femoral shaft in athletes: a new treatment algorithm

Ivković, Alan; Bojanić, Ivan; Pećina, Marko

Source / Izvornik: **British Journal of Sports Medicine, 2006, 40, 518 - 520**

Journal article, Accepted version

Rad u časopisu, Završna verzija rukopisa prihvaćena za objavljivanje (postprint)

<https://doi.org/10.1136/bjism.2005.023655>

Permanent link / Trajna poveznica: <https://um.nsk.hr/um:nbn:hr:105:530886>

Rights / Prava: [In copyright](#) / [Zaštićeno autorskim pravom.](#)

Download date / Datum preuzimanja: **2024-12-19**



Repository / Repozitorij:

[Dr Med - University of Zagreb School of Medicine
Digital Repository](#)





Središnja medicinska knjižnica

Ivković, A., Bojanić, I., Pećina, M. (2006) *Stress fractures of the femoral shaft in athletes: a new treatment algorithm*. British Journal of Sports Medicine, 40 (6). pp. 518-520.

This article has been accepted for publication in BJSM following peer review. The definitive copyedited, typeset version is available online at :
<http://bjsm.bmjournals.com/>

<http://medlib.mef.hr/243>

University of Zagreb Medical School Repository

<http://medlib.mef.hr/>

ALAN IVKOVIĆ, IVAN BOJANIĆ, MARKO PEĆINA
Department of Orthopaedic Surgery
Medical School University of Zagreb
Clinical Hospital Center Zagreb

**Stress fractures of the femoral shaft in athletes: A new
treatment algorithm**

ABSTRACT

Key words: stress fracture – femoral shaft – athlete – runners – phase treatment

Background: Femoral shaft stress fractures in athletes are uncommon but pose great diagnostic challenge to clinicians. Due to scarce clinical signs, the diagnosis and the treatment are often delayed. Furthermore, if not treated properly femoral shaft stress fractures are well known for complications and difficulties.

Objective: To develop well structured and reproducible treatment algorithm for athletes with femoral shaft stress fractures.

Materials and Methods: Proposed algorithm is carried out in four phases, each lasting three weeks, and the transfer to a next phase is based on the result of the tests carried out at the end of the respective phase. In the period of nine years we treated 7 top-level athletes, aged between 17 and 21. In all athletes diagnosis was made based on physical examination, plain radiographs and bone scan.

Results: As a result of the presented treatment method, all the athletes were fully engaged in athletic activity after 12 to 18 weeks from the beginning of the treatment. After the completion of the treatment athletes were followed throughout the period from 48 to 96 months. During the follow-up there was no recurrence of discomfort or pain, and all the athletes eventually returned to the competition level.

Conclusion: Based on our experience and available data from the literature, we may conclude that the presented algorithm is optimal treatment protocol to be used in order to avoid the otherwise occurring complications and difficulties in the treatment of femoral shaft stress fractures in athletes.

INTRODUCTION

Stress fractures are overuse injuries of bone, and may be defined as partial or complete fracture that results from repetitive application of stress of less strength than the stress required to fracture bone in single loading.[1] Imbalance between bone formation and resorption is a result of that excessive repetitive load.

Stress fractures constitute about 10% of all sport-related injuries and the most common site is tibia.[2] Stress fractures of the femur are relatively uncommon and data from the available literature suggest that they constitute only 2.8% to 7% of all sport-related stress fractures.[3][4][5] Nevertheless, they do pose great challenge both for diagnosis and treatment.

This paper presents a new treatment algorithm for athletes with femoral shaft stress fractures. Using this tool, clinicians are able to treat these injuries in uniform and structured manner, and also to compare outcome results among different institutions.

MATERIALS AND METHODS

Seven top-level track and field athletes (3 long distance and 4 middle distance runners) were diagnosed with stress fracture of the femoral shaft and treated at our Department during 1992 to 2001. Among these seven athletes six were male and one was female, aged between 17 and 21 years. The time span from the occurrence of symptoms till they reported to our outpatient unit was between 1 and 8 weeks, but mostly 2 to 4 weeks.

Historical data from the athletes showed that all of them complained of vague anterior thigh pain, especially during and after the training sessions. During the physical examination we used *hop test* as described by Matheson et al.[4] and *fulcrum test* as described by Johnson et al.[6] which turned out positive in each one of our patients. In hop test patient attempts to hop on the injured leg, inevitably reproducing the pain if an undisplaced stress fracture is present. For fulcrum test the athlete is seated on the examination table with the lower legs dangling. The examiner's arm is used as a fulcrum under the thigh and is moved distal to proximal thigh as gentle pressure is applied to the dorsum of the knee with the opposite hand. At the point of fulcrum under the stress fracture, gentle pressure on the knee produces increased discomfort that is described by patient as sharp pain and is usually accompanied with apprehension. These tests are very sensitive and were also used during follow-up to determine the eligibility of the patient for transfer to the next phase of the treatment. Both plain radiography and technetium bone scan were applied in all athletes (fig 1 and 2).

The treatment was carried out in four phases, each lasting three weeks (see diagram 1). The transfer to the next phase was based on the result of a test carried out at the end of each respective phase (fulcrum and hop test). If the tests were positive after three weeks, the patient was returned to the beginning of that respective phase. In the first phase, which was called symptomatic, an athlete walked with a help of crutches and was instructed not to weight the affected leg. In the second phase, which was called asymptomatic, normal walk was allowed. The patients started swimming in the pool and exercising in the gym (only the upper extremities and the unaffected leg). In the third

phase, which was called the basic phase, the patients were allowed to perform the exercises both for upper and lower extremities. They were instructed to use smaller weights, and were allowed to run in straight line every other day, as well as to ride stationary bicycle. The distance which they were allowed to run over gradually increased. During the fourth, so-called reversion phase, and in agreement with coach, an athlete gradually started engaging in the normal training process.

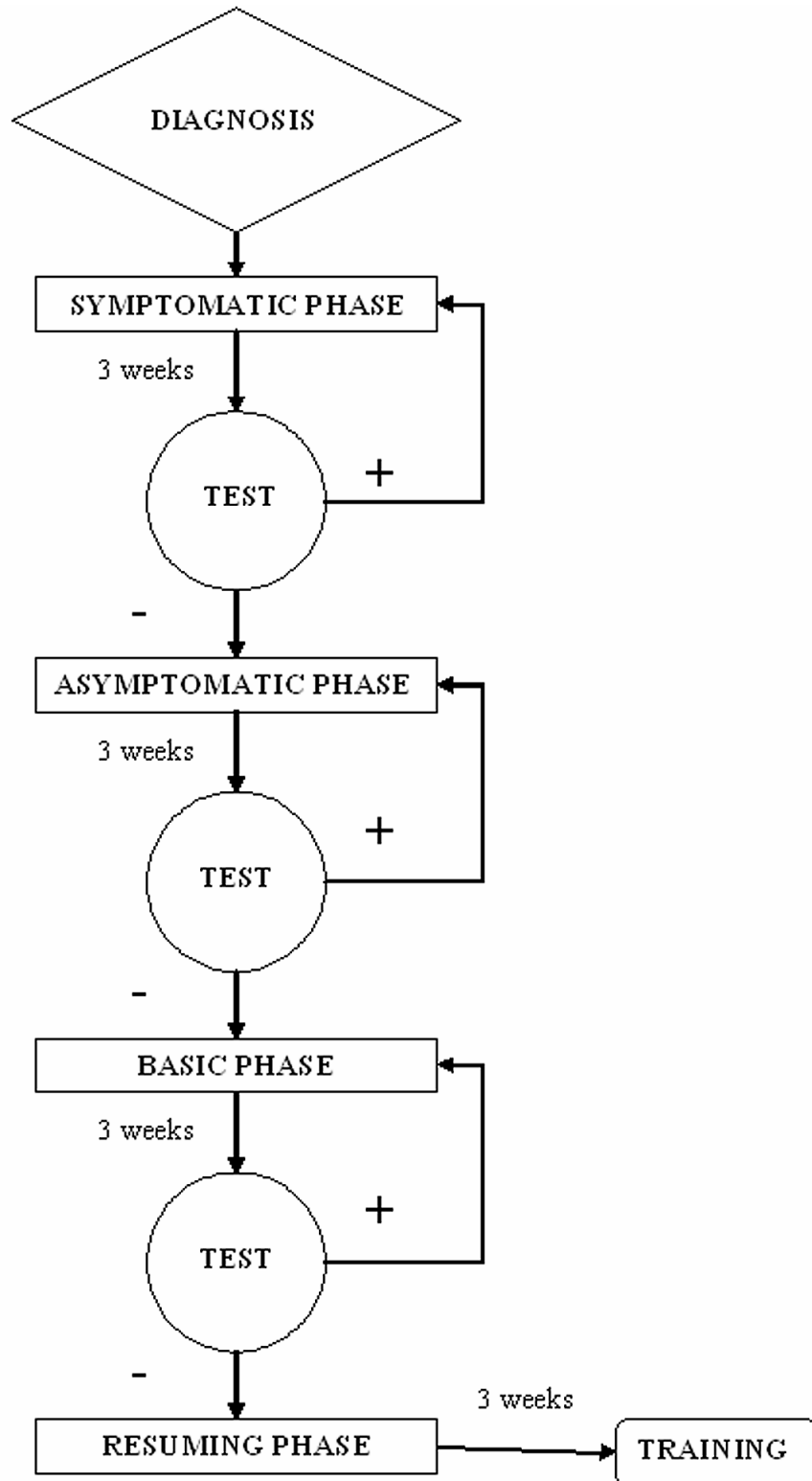


Diagram 1. Four-phase treatment algorithm for athletes with femoral shaft stress fractures.

RESULTS

As a result of the presented treatment method, all the athletes were fully engaged in athletic activity after 12 to 18 weeks from the beginning of the treatment. After the completion of the treatment athletes were followed throughout the period from 26 to 96 months. During the follow-up there was no recurrence of discomfort or pain, and all the athletes eventually returned to the competition level. All the results are summarized in the Table 1.

Table 1. Clinical data for the athletes with femoral shaft stress fractures.

CASE	SEX	AGE	SPORT	DELAY IN DIAGNOSIS (wks)	RETURN TO FULL SPORT (wks)	FOLLOW-UP (months)
1.	M	19	Runner (5 000 m)	4	12	96
2.	M	21	Runner (5 000 m)	2	12	94
3.	M	18	Runner (10 000m)	1	12	89
4.	F	17	Runner (1 500 m)	8	18	75
5.	M	19	Runner (3 000 m)	2	12	52
6.	M	17	Runner (1 500 m)	4	18	48
7.	M	19	Runner (1 500 m)	2	12	48

DISCUSSION

There are two main groups within the general population that are very susceptible to the femoral shaft stress fractures: athletes and military recruits.[7] The main difference between these two groups is the fact that more than 50% of the fractures among military personnel were located in the distal femur, and almost half of these were displaced and the majority of fractures among athletes were in the proximal femur.[6] [8][9]

Stress fractures of the femoral shaft are uncommon and occur most commonly in the proximal third of the femur.[10][11][12][13][14] It is a logical consequence of the fact that the femur has the tubular shape as well as the bowed configuration. During the dynamic stress (e.g. running) medial side is under compression and the lateral side is under the tension, as demonstrated by Koch's free body analysis of the femur.[15] By this analysis it is shown that junction of the proximal and middle third of the femur in the

subtrochanteric region particularly susceptible to repetitive submaximal stress. Indeed this was the most common localization in our series, but one should not overlook the other possible localizations such as distal femur.

In the process of diagnosis patient's history data such as sudden increase in mileage, intensity or frequency of training, a change in the running surface, or improper footwear should raise suspicion of a stress fracture. Other possible causative factors related to this injury include having high arches or a supinated foot type, increased age at the onset of menarche, and a decreased bone mineral content.[16][17][18][19] The patients usually present with vague, anterior thigh pain, and very few physical findings. Hop and fulcrum test will be positive during the physical examination. Standard radiographs are always obtained, although at the time of the symptom onset they are positive in only 30 to 70% of the cases.[3][4] [20] The diagnosis is confirmed by either bone scan or MRI. Triple-phase technetium-99m bone scan is the golden standard for the diagnosis of stress fracture, and to diagnose them correctly all three phases must be positive.[19] MRI is used to differentiate stress fractures from other pathological processes, especially from neoplastic ones.[21] In the case of stress fractures of the femoral diaphysis, MRI shows periosteal edema as well as bone marrow edema that usually involves the posteromedial aspect of the femur near the junction of the proximal and middle thirds.[22] Axial T2-weighted images usually demonstrate the patomorphology best. Compared with bone scan, MRI has a similar sensitivity but an improved specificity, and is becoming the diagnostic procedure of choice. At this point we would like to stress the importance of early diagnosis because we noticed that athletes with delay in diagnosis needed longer time to return to the full training (cases 4. and 6. in Table 1).

The main treatment for the femoral shaft stress fractures is the rest from the offending athletic activity, a concept known as "relative rest".[4] [10] [23][24] Furthermore, if not treated properly femoral shaft stress fractures are well known for complications and difficulties, such as delayed healing, fracture displacement and symptom recurrence. Taking into account those two facts we have constructed the four-phase treatment algorithm for the athletes with femoral shaft stress fractures. If conducted as previously described, it allows bone to heal but prevents detraining of the affected athlete. General conditioning is maintained by exercising other areas of body, and partaking alternative training, such as water running, swimming or cycling. Nevertheless, when returning to the training process the athlete must be cautioned to resume the sport at frequency and intensity well below the level that previously produced the symptoms. The duration of treatment may vary according to individual patient, but it is reasonable to expect that for most of the patients with stress fractures of the femur, the period of relative rest may last 12 weeks. Compliance is critical to the success of the treatment, as well as good cooperation between treating physician, athlete and his coach.

Based on our experience and available data from the literature, we may conclude that the presented four-phase algorithm is optimal treatment protocol to be used in athletes with femoral shaft stress fractures, in order to avoid the otherwise occurring complications and difficulties.

INFORMATION BOX

What is already known on this topic?

Femoral shaft stress fractures are rare, difficult to diagnose, and if not treated properly have high rate of recidives and complications. Several larger series regarding the issue have been published in the literature, but none of them addressed the issue of the treatment algorithm.

What this study adds?

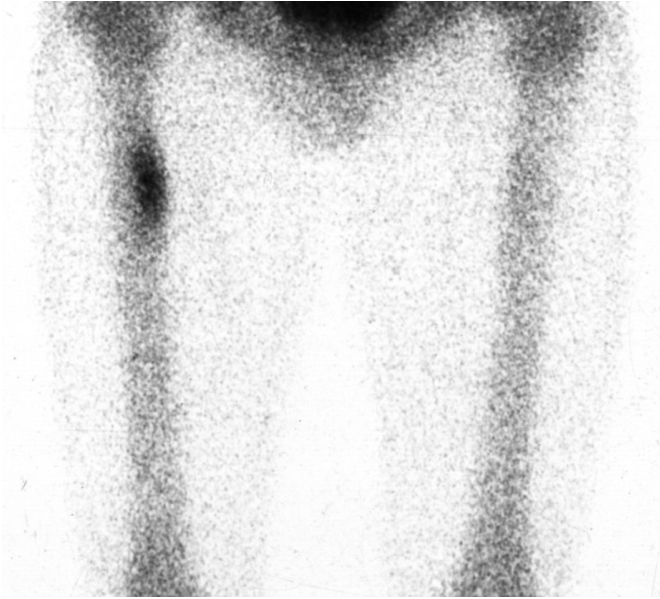
This study offers well structured and reproducible treatment algorithm for athletes with femoral shaft stress fractures. It was conceived in concordance with special demands of a high-level athlete, and if conducted properly it prevents detraining of the athlete. Our results show that it enables quick return to the training process without recidives.

FIGURE LEGENDS

Figure 1. AP and LL roentgenograms demonstrating stress fractures in the proximal third of the femoral shaft (white arrow).

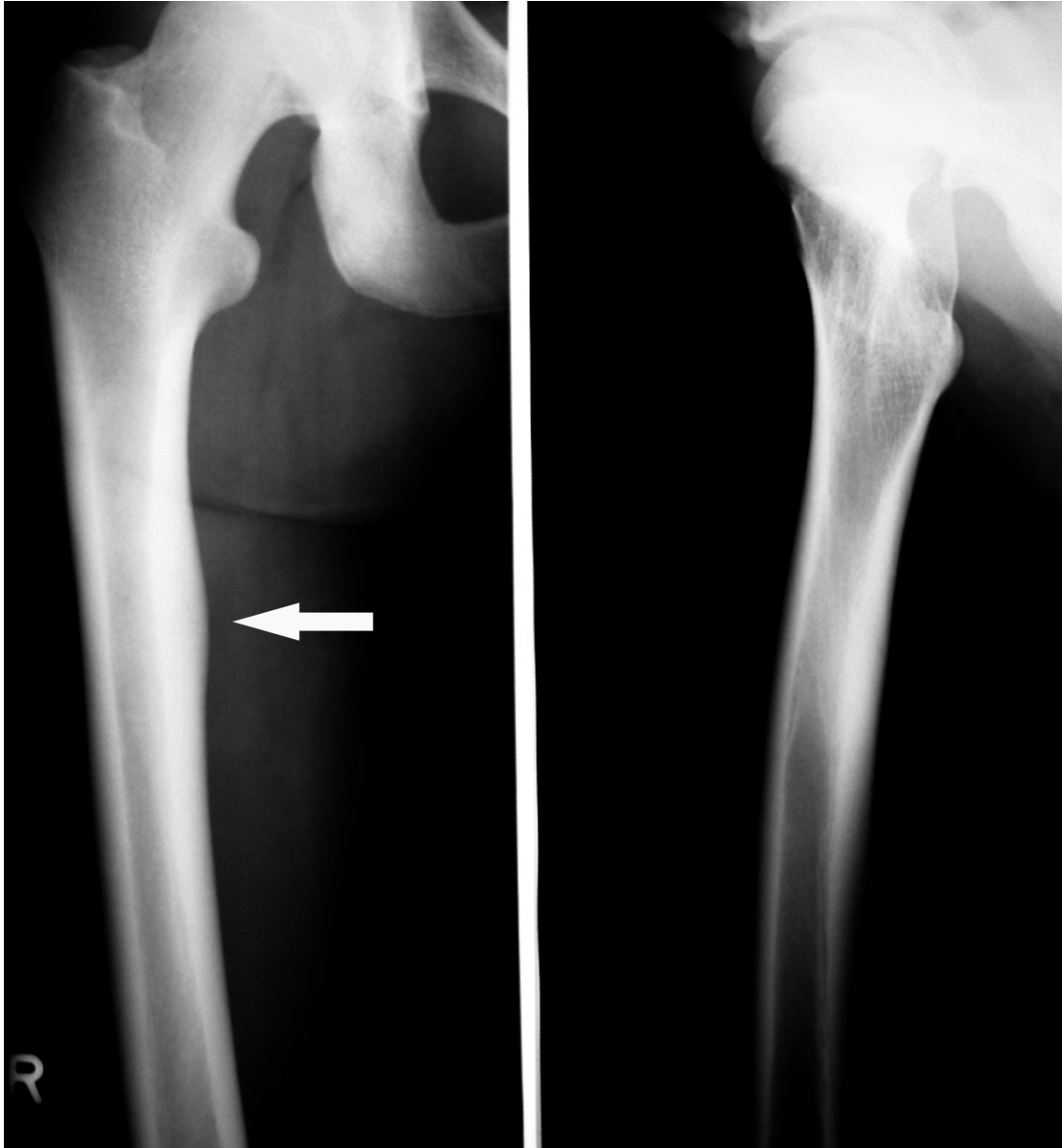

Figure 2. Bone scan of the same patient.



REFERENCES

- 1 Pećina MM, Bojanić I. *Stress fractures*. In: Pećina MM, Bojanić I, eds. *Overuse Injuries of the Musculoskeletal System*, 2nd Ed. Boca Raton: CRC Press 2003:315-349.
- 2 Brukner P, Bradshaw C, Khan K, et al. Stress fractures: a review of 180 cases. *Clin J Sport Med* 1996;**6**:85-89.
- 3 Matheson GO, Clement DB, McKenzie DC, et al. Stress fractures in athletes. A study of 320 cases. *Am J Sports Med* 1987;**15**:46-58.
- 4 Orava S. Stress fractures. *Br J Sports Med* 1980;**14**:40-44.
- 5 Bennell KL, Brukner PD. Epidemiology and site specificity of stress fractures. *Clin Sports Med* 1997;**16**:179-96.
- 6 Johnson AW, Weiss CB, Wheeler DL. Stress fractures of the femoral shaft in athletes – More common than expected. A new clinical test. *Am J Sports Med* 1994;**22**:248-56.
- 7 Volpin G, Hoerer D, Groisman G, et al. Stress fractures of the femoral neck following strenuous activity. *J Orthop Traum* 1990;**4**:394-98.
- 8 Provost RA, Morris JM. Fatigue fracture of the femoral shaft. *J Bone Joint Surg* 1969;**51**:487-98.
- 9 Murphy DF, Connolly DAJ, Beynon BD. Risk factors for lower extremity injury: a review of the literature. *Br J Sports Med* 2003;**37**:13-29.
- 10 Blatz DJ. Bilateral femoral and tibial shaft stress fractures in a runner. *Am J Sports Med* 1981;**9**:322-35.
- 11 Boden BP, Speer KP. Femoral stress fractures. *Clin Sport Med* 1997;**16**, 307-17.
- 12 Butler JE, Brown SL, McConnell BG. Subtrochanteric stress fractures in runners. *Am J Sports Med* 1982;**10**:228-32.
- 13 Clement DB, Ammann W, Taunton JE, et al. Exercise-induced stress injuries to the femur. *Int J Sports Med* 1993;**14**:347-52.
- 14 Hershman EB, Lombardo J, Bergfeld JA. Femoral shaft stress fractures in athletes. *Clin Sport Med* 1990;**9**, 111-19.
- 15 Black J. Failure of implants for internal hip fixation. *Orthop Clin North Am* 1974;**5**:833-44.
- 16 Dušek T. Influence of high intensity training on menstrual cycle disorders in athletes. *Croat Med J* 2001;**42**:72-92.
- 17 Leinberry CF, McShane RB, Stewart WG, et al. A displaced subtrochanteric stress fracture in a young amenorrhoeic athlete. *Am J Sports Med* 1992;**20**:485-87.
- 18 Dusek T, Pecina M, Loncar-Dusek M, et al. Multiple stress fractures in a young female runner. *Acta Chir Orthop Traumatol Cech* 2004;**71**:308-10.
- 19 Spitz DJ, Newberg AH. Imaging of stress fractures in athletes. *Radiol Clin North Am* 2002;**40**:313-31.
- 20 Deutsch AL, Coel MN, Mink JH. Imaging of stress injuries to bone: radiography, scintigraphy and MR imaging. *Clin Sport Med* 1997;**16**:275-90.
- 21 Martin SD, Healey JH, Horowitz S. Stress fracture MRI. *Orthopaedics* 1993;**16**:75-78.

- 22 Tyrell PN, Davis AM. Magnetic resonance imaging appearances of fatigue fractures of the long bones of the lower limb. *Br J Radiol* 1994;**67**:332-338.
- 23 Bojanić I, Ivković A, Pećina M. Stress fractures. In Wnek GE, Bowlin GL, eds. *Encyclopedia of biomaterials and biomedical engineering*. New York, NY: Marcel Dekker, Inc. 2005, in press.
- 24 Hulkko A, Orava S. Stress fractures in athletes. *Int J Sports Med* 1987;**8**:221-6.

STATEMENT

The Corresponding Author has the right to grant on behalf of all authors and does grant on behalf of all authors, an exclusive license on a worldwide basis to the BMJ Publishing Group Ltd and its Licensees to permit this article (if accepted) to be published in British Journal of Sports Medicine editions and any other BMJPGl products to exploit all subsidiary rights, as set out in your license.