

Laparoscopic surgery for large hydatide liver cyst after two previous laparotomies

Bušić, Željko; Kolovrat, Marijan; Kopljar, Mario; Servis, Dražen; Čavka, Vlatka; Patrlj, Leonardo; Bušić, Njegoslav; Čavka, Mislav; Nikolić, Igor

Source / Izvornik: **Collegium Antropologicum, 2014, 38, 577 - 581**

Journal article, Published version

Rad u časopisu, Objavljena verzija rada (izdavačev PDF)

Permanent link / Trajna poveznica: <https://um.nsk.hr/um:nbn:hr:105:950807>

Rights / Prava: [In copyright](#)/[Zaštićeno autorskim pravom.](#)

Download date / Datum preuzimanja: **2024-07-10**



Repository / Repozitorij:

[Dr Med - University of Zagreb School of Medicine Digital Repository](#)



Laparoscopic Surgery for Large Hydatide Liver Cyst After Two Previous Laparotomies

Željko Bušić^{1,2}, Marijan Kolovrat¹, Mario Kopljarić¹, Dražen Servis¹, Vlatka Čavka³, Leonardo Patrlj^{1,4}, Njegoslav Bušić⁵, Mislav Čavka^{6,7} and Igor Nikolić^{1,4}

¹ University Hospital »Dubrava«, University Department of Surgery, Zagreb, Croatia

² »J. J. Strossmayer« University, School of Medicine, Chair of Surgery, Osijek, Croatia

³ University Hospital »Sestre Milosrdnice«, University Department of Dermatovenerology, Zagreb, Croatia

⁴ University of Zagreb, School of Medicine, Chair of Surgery, Zagreb, Croatia

⁵ University Hospital Center »Split«, University Department of Otorhinolaryngology and Maxillofacial Surgery, Split, Croatia

⁶ University Hospital »Dubrava«, University Department of Diagnostic and Interventional Radiology, Zagreb, Croatia

⁷ University of Zagreb, School of Medicine, Chair of Social Medicine and Organization of Healthcare, Zagreb, Croatia

ABSTRACT

Laparoscopic surgery for hepatic echinococcosis is a technically difficult and demanding surgical procedure even for the most experienced abdominal surgeon. Surgery is performed after the conservative treatment with albendazole for 28 days. We report a case of laparoscopic partial pericystectomy with biliostasis and omentoplasty in a patient with two previously open surgeries (laparotomies) – right subcostal laparotomy for acute inflammation of the gallbladder and right pararectal laparotomy for perforated gangrenous appendix. The patient underwent extensive laparoscopic adhesiolysis due to pronounced intra-abdominal adhesions to gain access to a large hydatid cyst with the diameter of 11 cm. Laparoscopic surgery is much less traumatic to the patient with a better cosmetic effect.

Key words: hepatic echinococcosis, hydatid cyst, liver, surgery, laparoscopy, minimally invasive surgery

Introduction

According to the Croatian Institute of Public Health there were 15 new registered cases of liver echinococcosis in Croatia in 2011. Surgical treatment of liver hydatidosis is a method of choice for this common disease. In recent years we have witnessed the progress of laparoscopic surgery, which is increasingly used in the treatment of hydatid disease^{1–5}. Along with the obvious advantages of laparoscopic surgery, which is significantly less traumatic to the patient, these procedures are also technically difficult and demanding. A particular problem in laparoscopic surgery are adhesions after prior laparotomies, and in surgical treatment of echinococcosis special attention must be paid to prevent the spillage of hydatid cyst content^{4,6–8}. In this paper we describe the technique of laparoscopic partial pericystectomy with biliostasis and omentoplasty in a patient with a large echinococcal cyst measuring 11 cm in diameter, located in the segment IVb and partly in segments II, V and VIII, provided that the patient already had two laparotomies

(for acute calculous cholecystitis and acute gangrenous appendicitis).

Case report

Female patient, 47 years of age, was admitted to the Internal Clinic in one of the clinical hospitals due to vomiting, pain and tension in the abdomen and jaundice. For the last 5 years patient was aware of having »some pure« liver cyst. At admission patient was without fever with icteric sclera. Her abdomen was soft and tender on palpation in the epigastric region, where palpable, slightly painful, well circumscribed resistance was noted. The patient previously underwent appendectomy for acute gangrenous appendicitis (open technique through pararectal incision) and cholecystectomy for acute cholecystitis (open technique with subcostal incision) (Figure 1). Blood hematology and biochemistry were as follows: leu-

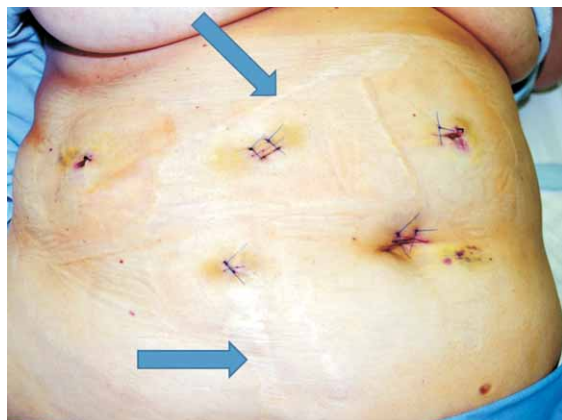


Fig. 1. Scars after previous laparotomies (arrows).

kocyte count $14.7 \times 10^9/L$, lymphocyte count $1.9 \times 10^9/L$, segmented neutrophils $7.6 \times 10^9/L$, bilirubin $75 \mu\text{mol/L}$, alkaline phosphatase 464 U/L , γGT 396 U/L , AST 291 U/L , ALT 777 U/L , LDH 299 U/L , CRP 219 mg/L . Abdominal ultrasound showed a large, multilocular cyst measuring over 11 cm in diameter, located predominantly in the left lobe, but with the expansion to the right hepatic lobe, resembling echinococcal cyst, with dilatation of bile ducts of the left liver lobe. Due to signs of obstructive jaundice, patient underwent ERCP that showed normal findings except for mild dilatation of bile ducts in the left lobe of the liver. Abdominal MSCT showed a lobular cystic lesion with diameter of 11 cm in the left lobe of the liver, which did not enhance with contrast. In the upper part of the described lesion, septa were shown that enhanced discretely with contrast. Also, within the cysts there was another smaller cyst with diameter of 3 cm (Figure 2). Due to compression in the hepatic hilum, there was discrete dilatation of bile ducts, especially for the left lobe of the liver, and compression of the portal vein was also described. The etiology of the lesion could not have been determined with certainty – differential diagnosis included hydatid cyst or other cystic liver lesion. Upper endoscopy and chest radiographs were normal. On empirical antibi-

otic therapy with ceftriaxone (Lidacef, Pliva, Croatia) and parenteral nutrition, bilirubin and transaminases normalized and inflammatory parameters regressed. Serology for echinococcus was negative. Infectious disease specialist who was consulted on the suspicion of echinococcosis indicated patient transfer to the Department of Infectious Diseases, where she underwent prophylaxis with albendazole $3 \times 400 \text{ mg}$ orally for 4 weeks, after which the patient was transferred back to the Department of Surgery for definitive treatment. The patient received antibiotic prophylaxis – cephazoline 1 g i.v. (Kefzol, Eli Lilly, Indianapolis, Indiana, USA) immediately before surgery, as well as thromboprophylaxis – Fragmin (Pharmacia AB, Stockholm, Sweden) the day before surgery and during the hospital stay.

Laparoscopic technique

The surgery was performed in November 2012 under general endotracheal anesthesia. The patient was supine with an outstretched left hand on the handle. On the left side of the patient stood the operator, first assistant holding the laparoscope and nurse. On the right side of the patient stood the second assistant. Monitor was located on the right side of the patient above her right shoulder. Supraumbilical incision was made and Veress was used to insufflate CO_2 until 13 mmHg intraabdominal pressure. After achieving pneumoperitoneum, 11-mm trocar was introduced through the same incision (trocar A), through which the laparoscope was introduced. Extensive adhesions after prior laparotomies were observed throughout the right hemiabdomen. The other 11-mm trocar was set midway between the navel and xyphoid process, slightly left to the median line (trocar B). Through this trocar, coagulating scissors were introduced and lysis of adhesions in the right hemiabdomen was performed. Upon lysis of adhesions, a large echinococcal cyst measuring about 11 cm in diameter and located in segment IVb and partly in segments II, V, VIII was observed that compressed the stomach. After that, 5-mm trocar was introduced in anterior axillary line at umbilical level (trocar C), and another 5-mm trocar was placed in medial clavicular line, little below the umbilical level (trocars

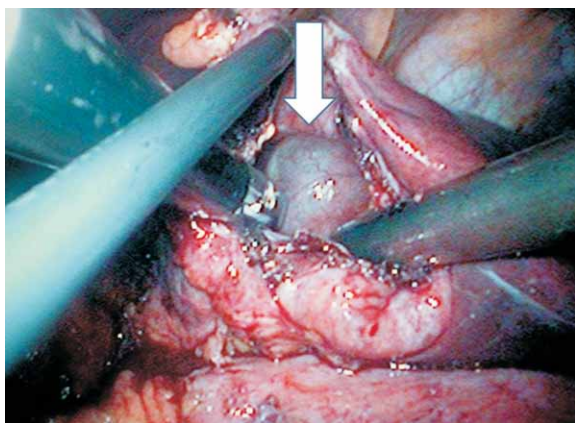


Fig. 2. Showing perforated echinococcal cyst in which there is another smaller cyst with diameter of 3 cm (marked by arrow).

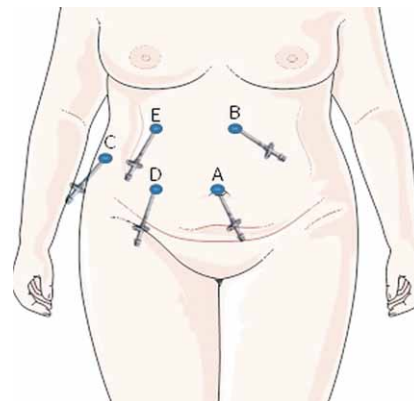


Fig. 3. Schematic representation of the introduction sites of trocars.

D). The last trocar (11-mm) was placed below the right costal margin in the medial clavicular line (trocar E) (Figure 3). Echinococcal cyst was freed from adhesions with the omentum and stomach using coagulation scissors (Figure 4). The cyst was held with laparoscopic grasper through 5-mm trocar in the anterior axillary line and opened using scissors with coagulation introduced through the 5-mm trocar placed in medial clavicular line below the navel. At the same time, a 10-mm aspirator was introduced through the working trocar placed in the middle between the navel and xyphoid process slightly to the left, and the content of the cyst was entirely evacuated (Figure 5). Cyst cavity was then rinsed with hypertonic (10%) NaCl solution. LigaSure (Covidien, Boulder, Colorado, USA) was used to perform pericystectomy up to the edges of the liver tissue, partly through an 11-mm trocar below the right costal margin and partly through trocars placed slightly to the left of the navel-xyphoid line (Figure 6). Parts of the of the cyst walls were placed in a polyurethane bag (Ethicon Endo Surgery, USA) and removed through the supraumbilical incision that was slightly enlarged. At that time the laparoscope was placed through the working trocar in the navel-xyphoid line, slightly left of the middle. After the bag was removed, 11-mm trocar with laparoscope was reintroduced through

supraumbilical incision followed by cyst cavity washing first with hypertonic (10%) and then with normal (0.9%) saline solution through a working port. The smaller cyst was managed in the same way. In the area where the cyst impressed the segment VIII, a small open biliary duct was found leaking bile. The duct was sutured with nylon suture 4-0 (Ethilon, Johnson & Johnson, Belgium) (Figure 7). Omental flap was formed using Ligasure and the patient underwent omentoplasty; the omentum was pla-

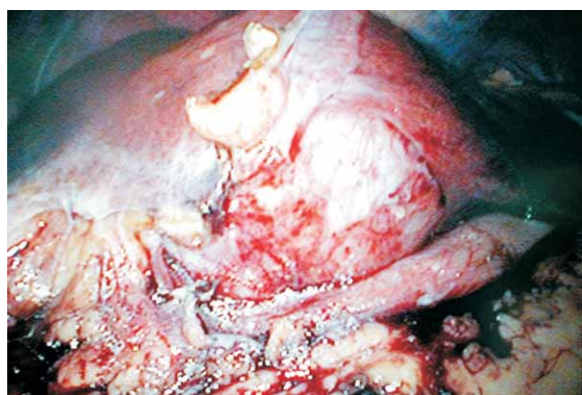


Fig. 4. Echinococcal cysts with marked adhesions with omentum and stomach. Visible is the compression of the stomach with the cyst.

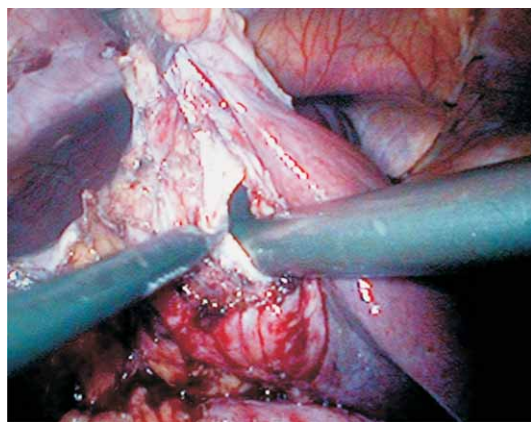


Fig. 5. Display of echinococcal cyst content aspiration.

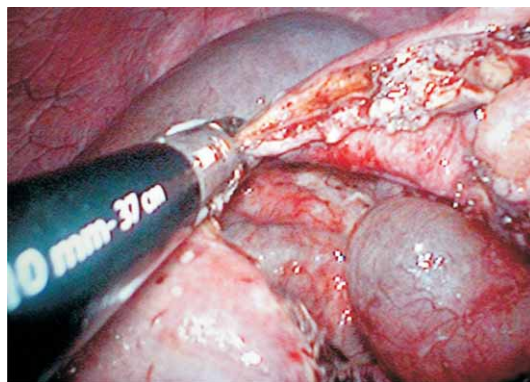


Fig. 6. Echinococcal cyst wall resection (partial pericystectomy) by means of bipolar coagulation – LigaSure Atlas.

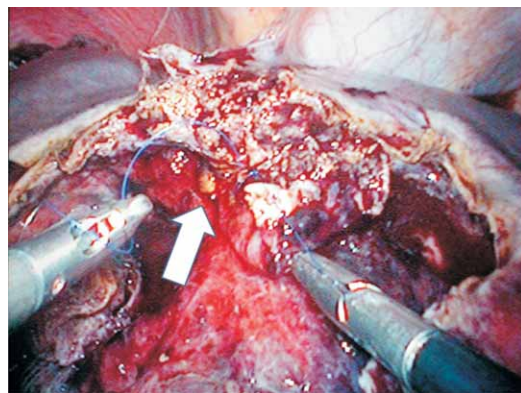


Fig. 7. Laparoscopic suturing of the open bile duct (arrow) in the bottom of echinococcus cyst.

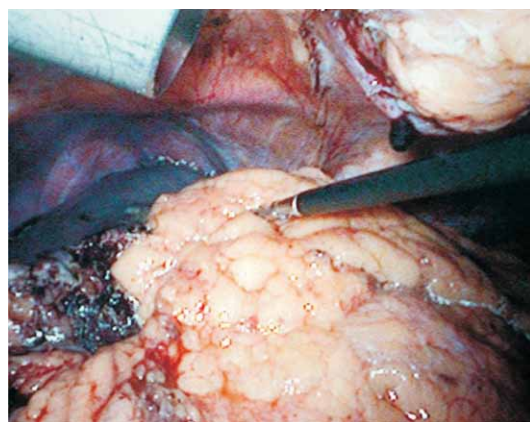


Fig. 8. Completion of laparoscopic surgery with omentoplasty.

ced in the residual cyst cavity and fixed with two polyglactine 910 sutures (Ethicon, Somerville, New Jersey, USA) (Figure 8). After controlling hemostasis and biliosis, abdominal drain was placed through the incision in the medial clavicular line slightly below the level of umbilicus. The procedure lasted 120 minutes. Postoperative recovery was uneventful. The patient was mobilized on the first postoperative day and took fluids by mouth. Drain was removed after 72 hours. The patient was discharged on the sixth day. Patohistology confirmed hepatic echinococcus.

Discussion

Echinococcosis, as a parasitic disease, is particularly common in Mediterranean countries, and in some other endemic regions of Australia and American continents⁹. In Croatia it is particularly common in Dalmatia, and may be asymptomatic for many years. In year 2011, out of 15 new cases of echinococcosis in Croatia, 3 patients with echinococcal hepatic cysts, and 1 patient with splenic echinococcus were operated at the Department of Abdominal Surgery, University Hospital Dubrava. All operations were performed laparoscopically. Main symptoms are usually the symptoms of compression of adjacent structures (part of the digestive tract, bile ducts, blood vessels) and are highly variable; also, the penetration into bile ducts may result in cholangitis^{10–12}. Particularly dangerous during the surgery is perforation and intra-abdominal cysts dissemination that can cause anaphylactic shock^{13–15}. Therefore, needle aspiration should be avoided in the diagnosis of echinococcus¹⁶. In order to avoid dissemination during surgery, it is preferable to implement treatment with albendazole before the operation^{17–20}, usually over 3 weeks to 2 months, and during the operation it is desirable that the cyst content is first aspirated and then washed with some scolicidal agents, usually hypertonic saline²¹. Even 3 years after treatment with albendazole at a dose of 10 mg/kg viable scolexes can be found in up to 30% of patients¹⁹. Adding praziquantel to albendazole therapy significantly increases success²². It is evident, therefore, that surgical therapy is the method of choice in the treatment of echinococcal disease²³. Available surgical methods include complete

excision of the cyst (pericystectomy) or partial resection of the cyst. Although some authors believe that pericystectomy is a »radical« operation, this operation is a riskier surgical procedure for a benign disease and for now there is no evidence that such procedure is better in the treatment of liver hydatidosis compared to partial resection with omentoplasty²³. Partial resection with omentoplasty is less risky in treating liver hydatidosis and can be successfully performed laparoscopically, which is less traumatic to the patient (shorter hospitalization, lower incidence of wound infections and less postoperative pain). Laparoscopic surgery, however, is much more demanding than traditional, open surgical approaches. Particularly demanding is laparoscopic surgery after previous laparotomy due to intra-abdominal adhesions, which significantly increase the risk of injury to abdominal organs and major blood vessels. To date, many techniques are described for laparoscopic approach in the abdomen, and the ways in which they can help avoid injuries of abdominal organs or at least reduce their frequency. Among some of these techniques are open Hasson approach, the use of optical trocars or the introduction of trocars in the places with the lowest incidence of adhesions. None of these methods, however, is proven to be safer than others, especially in situations with previous laparotomy²⁴. In performing laparoscopic surgery after previous laparotomy it is therefore of particular importance to carefully introduce trocars in areas with the lowest probability of adhesions, meticulous surgical technique, especially during adhesiolysis and finally a thorough exploration of the abdomen at the beginning and at the end of the operation so that any injury would not be overlooked. Even after previous two laparotomies, due to inflammation of the gall bladder and appendix, and heavy adhesions in the abdomen, liver echinococcus can be operated on using laparoscopic technique. Laparoscopic biliostasis can also be performed if necessary. Laparoscopic surgery represents significantly smaller trauma for patients, patients tolerate it much better, aesthetic effect is better, recovery faster and hospitalization is shorter⁶. We conclude that laparoscopic surgery for echinococcal liver cyst becomes increasingly important, with the assumption that it will eventually become a standard in the treatment of this disease^{4,6,7}.

REFERENCES

1. SONI HN, NAGPAL AP, ZUMKHAWALA BR, HARIBHAKTI SP, Surg Laparosc Endosc Percutan Tech, 21 (2011) 253. DOI: 10.1097/SLE.0b013e318230f732. — 2. ROOH-UL-MUGIM, KAMRAN MK, KHALIL J, GUL T, FARID S, J Coll Physicians Surg Pak, 21 (2011) 468. DOI: 08.2011/JCPS468471. — 3. RAMACHANDRAN CS, GOEL D, ARORA V, Surg Laparosc Endosc Percutan Tech, 11 (2001) 14. — 4. BUSIC Z, LEMAC D, STIPANCIC I, BUSIC V, CAVKA M, MARTIC K, Acta Chir Belg, 106 (2006) 688. — 5. POLAT FR, Surg Laparosc Endosc Percutan Tech, 22 (2012) 264. DOI: 10.1097/SLE.0b013e318251625c. — 6. BUSIC Z, LOVRIC Z, KOLOVRAT M, CAVKA V, CAVKA M, PATRLJ L, KVESIC A, Coll Antropol, 33 (2009) 181. — 7. BUSIC Z, LOVRIC Z, KOLOVRAT M, CAVKA V, PATRLJ L, CAVKA M, Lijec Vjesn, 132 (2010) 235. — 8. KOEA JB, ANZ J Surg, 82 (2012) 499. DOI: 10.1111/j.1445-2197.2012.06126.x. — 9. TSELENTIS J, KARPATIOS T, FRETZAYAS A, KORKAS A, NICOLAIDOU P, MATSANIOTIS N, Am J Trop Med Hyg, 32 (1983) 1462.

— 10. SCHWARTZ MP, SAMSOM M, Gastroenterology, 121 (2001) 1039. — 11. ABOU-KHALIL S, SMITH BM, MACLEAN JD, POENARU D, FRIED GM, BRET P, BARKUN AN, Am J Gastroenterol, 91 (1996) 805. — 12. BUSIC Z, AMIC E, SERVIS D, PREDRIJEVAC M, STIPANCIC I, BUSIC D, Coll Antropol, 28 (2004) 325. — 13. CASTANARES-ZAPATE-RO D, LATERRE PE, Hepatobiliary Pancreat Dis Int, 8 (2009) 638. — 14. YAHYA AI, PRZYBYLSKI J, FOUAD A, J R Coll Surg Edinb, 42 (1997) 423. — 15. EREL S, KILICOGLU B, KISMET K, GOLLU A, AKKUS MA, Adv Ther, 25 (2008) 943. — 16. YAMASHITA K, FURUYA K, NAMIENO T, SATO N, SHIMAMURA T, UNE Y, UCHINO J, World J Surg, 21 (1997) 856. — 17. TURKCAPAR AG, ERSOZ S, GUNGOR C, AYDINURAZ K, YERDEL MA, ARAS N, Eur J Surg, 163 (1997) 923. — 18. CRETU CM, CODREANU RR, MASTALIER B, POPA LG, CORDOS I, BEURAN M, IANULLE DA, SIMION S, Chirurgia (Bucur), 107 (2012) 15. — 19. BEN BRAHIM M, NOURI A, KSIA A, EL EZZI O, KRICHENE I, MEKKI M,

BELGHITH M, J Pediatr Surg, 43 (2008) 2024. DOI: 10.1016/j.jpedsurg.2008.04.024. — 20. AKTAN AO, YALIN R, Eur J Gastroenterol Hepatol, 8 (1996) 877. — 21. NUNNARI G, PINZONE MR, GRUTTADURIA S, CELESIA BM, MADEDDU G, MALAGUARNERA G, PAVONE P, CAPPELLANI A, CACOPARDO B, World J Gastroenterol, 18 (2012) 1448. DOI: 10.3748/wjg.v18.i13.1448. — 22. MOHAMED AE, YASAWY MI, AL

KARAWI MA, Hepatogastroenterology, 45 (1998) 1690. — 23. DZIRI C, HAOUET K, FINGERHUT A, World J Surg, 28 (2004) 731. — 24. AHMAD G, O'FLYNN H, DUFFY JM, PHILLIPS K, WATSON A, Cochrane Database Syst Rev, 2 (2012) CD006583. DOI: 10.1002/14651858.CD006583.pub3.

Ž. Bušić

University Hospital »Dubrava«, University Department of Surgery, Avenija Gojka Šuška 6, 10000 Zagreb, Croatia
e-mail: zbusic@kbd.hr

LAPAROSKOPSKA OPERACIJA VELIKE EHINOKOKNE CISTE JETRE NAKON PRETHODNO UČINJENE DVIJE LAPAROTOMIJE

SAŽETAK

Laparoskopska operacija ehinokokoze jetre je tehnički težak i zahtjevan kirurški zahvat čak i za najiskusnije abdominalne kirurge. Operacija je izvedena nakon konzervativnog liječenja albendazolom u trajanju od 28 dana. Prikazujemo slučaj laparoskopske djelomične pericistektomije s biliostazom i omentoplastikom u bolesnice s dvije prethodne otvorene operacije (laparotomije) – desna subkostalna laparotomija zbog akutne upale žučnog mjehura i desna pararektalna laparotomija zbog perforiranog gangrenoznog apendicitisa. Kod pacijenta je učinjena opsežna laparoskopska adhezioziza zbog izraženih priraslica kako bi se pristupilo velikoj hidatidnoj cisti promjera 11 cm. Laparoskopska kirurgija je mnogo manje traumatična za pacijenta s boljim kozmetičkim učinkom.