

Camurati-Engelmann disease in a family from Croatian Island: an old bone scan confirmed pattern of inheritance

Baretić, Maja; Koršić, Mirko; Potočki, Kristina; Herceg Horvatić, Gordana; Crnčević Orlić, Željka

Source / Izvornik: **Collegium Antropologicum, 2014, 38, 755 - 758**

Journal article, Published version

Rad u časopisu, Objavljena verzija rada (izdavačev PDF)

Permanent link / Trajna poveznica: <https://urn.nsk.hr/urn:nbn:hr:105:216844>

Rights / Prava: [In copyright](#) / [Zaštićeno autorskim pravom.](#)

Download date / Datum preuzimanja: **2024-07-21**



Repository / Repozitorij:

[Dr Med - University of Zagreb School of Medicine
Digital Repository](#)



Camurati-Engelmann Disease in a Family from Croatian Island: An Old Bone Scan Confirmed Pattern of Inheritance

Maja Baretić¹, Mirko Koršić¹, Kristina Potočki², Gordana Herceg Horvatić³ and Željka Crnčević Orlić⁴

¹ University of Zagreb, University Hospital Centre Zagreb, Division of Endocrinology, Department of Internal Medicine, Zagreb, Croatia

² University of Zagreb, University Hospital Center Zagreb, Department of Diagnostic and Interventional Radiology, Zagreb, Croatia

³ University of Zagreb, University Hospital Center Zagreb, Department of Nuclear Medicine and Radiation Protection, Zagreb, Croatia

⁴ University of Rijeka, University Hospital Centre Rijeka, Department of Endocrinology, Diabetes and Metabolic Diseases, Rijeka, Croatia

ABSTRACT

34-year old patient had history of muscular wasting, easy fatigability, pain in extremities and waddling gait since age of four. During the time, neuromuscular disease was suspected, but not confirmed. Elevated bone alkaline phosphatase as well as other bone turnover markers (osteocalcin, procollagen, telopeptide) indicated further skeletal evaluation. Symmetrical enhanced uptake on technetium methylene diphosphonate [99mTc]MPD bone scintigraphy at diaphyses of longitudinal bones and skull matched cortical thickening of long bones and sclerosis of the skull seen at radiograms. Those findings pointed to Camurati-Engelmann disease misdiagnosed for the long time. This rare genetic autosomal dominant disorder was retrospectively diagnosed in asymptomatic father too on the basis of bone scans done long time ago. Old family member scans confirmed heredity pattern of the disease.

Key words: Camurati-Engelmann disease, hereditary disease, progressive diaphyseal dysplasia, bone scintigraphy, bone radiograms

Introduction

In 1920 Cockayne described a case of unusual bone thickening in 9-years old child¹. Two years later, Camurati published a report of a father and a son having identical changes in lower limbs. He named this disease 'symmetrical hereditary osteitis', and determined later the identical condition in four generation of the same family². In 1929 Engelmann described similar condition in 8-years old boy and named it »osteopathica hyperostotica (sclerotisans) multiplex infantilis«³. This syndrome is called today Camurati-Engelmann disease, or progressive diaphyseal dysplasia. It is an autosomal dominant disease, a part of the group of cranio-tubular hyperostoses. Clinically, there is a great variability of symptoms. Most of the patients experience pain in the extremities, waddling gait, easy fatigability and muscle weakness⁴.

Symptoms mostly occur at younger age, although not necessarily. Some of the patients have systemic manifestation like anaemia, leucopaenia and hepatosplenomegaly. Main pathology is cortical thickening – hyperostosis, appearing on the diaphyses of the long bones. The changes are present in bilateral and symmetrical pattern; long bones of lower extremities are affected first, than long bones of upper extremities, finally metaphyses. The skull base and pelvis have sclerotic changes. Radiologically it is recognized by the symmetrical enlargement with sclerosis of the cortex of long bones. Bone scan shows abnormal uptake of technetium methylene diphosphonate- [99mTc]MPD in mentioned locations. Sclerosis of the skull and pelvis is seen too^{5,6}. High bone turnover markers point to enhanced osteoblastic activity. In

most of the cases Camurati-Engelmann disease is caused by a mutation of coding region TGFβ-1 (transforming growth factor beta 1) located on chromosome 9q13⁷. TGFβ-1 is a stimulator of osteoblastic bone formation. The result of osteoblast enhanced action is failure of bone resorption creating bilateral symmetrical cortical thickening of the diaphyses of the long bones⁸.

Case Report

34-year old patient from a northern Croatian island was presented with history of muscular wasting, easy fatigability, pain in extremities and waddling gait since the age of four. His locomotory problems could be described as severe ones, they progressed during the time. The patient had valgus deformity of the knee, scapulae alata and low subcutaneous fat (densitometry of the fat tissue showed only 18% of body fat). During the past years diagnostic procedures were directed to determine nature of his neuromuscular symptoms, though no neurological or muscular damage was confirmed (electro-neurography, neurological examination, muscular biopsies were normal). Throughout the time repeatedly measured alkaline phosphatase was elevated. This finding was consistent with other markers of bone turnover performed during patients visit. Alkaline phosphatase was elevated again (208 U/L; normal values for the lab. <147), as well as osteocalcin 106.4 μg/L (<30 yr. normal for the lab. 24–70), crosslaps 1.86 μg/L (<50 yr. normal for the lab. <0.584) and procollagen 275.4 μg/L (normal for the lab. 16.27–73.87), pointing to the bone metabolic disease⁹. [99mTc]MPD bone scan showed symmetrical enhanced uptake along longitudinal bones, scull and pel-

vis (Figure 1). Bone radiograms illustrated cortical thickening symmetrically at diaphyses of femora, tibiae, fibulae, humera (Figure 2) as well as sclerosis of scull. Those findings matched bone scintigraphy (Figures 3 and 4). Bone densitometry of forearms (BMD 1.120 T score + 8.2 Z score + 8.3) matched bone scan too. On the basis of these findings, we believed that the diagnosis is Camurati-Engelmann disease.

In differential diagnosis of the case there are several sclerosing bone dysplasias, disorders that occur due to disturbances in the pathways involved in osteoblast or osteoclast regulation, leading to abnormal accumulation of the bone. Those disorders share some clinical and radiographic findings of Camurati-Engelmann disease, though with some marked distinction. Some of them are craniodiaphyseal dysplasia (distinguished by progressive and marked enlargement of the midline cranial bones causing facial deformity), Kenny-Caffey syndrome type 2 (distinguished by dwarfism and craniofacial anomaly), juvenile Paget disease (distinguished by frequent fractures, coarse trabeculations and bowing of the long bones), diaphyseal dysplasia with anemia (distinguished by endosteal bone formation with no evidence of subperiosteal bone formation, severe anemia and frequent infections), hyperostosis corticalis generalisata – Worth type (distinguished by endosteal thickening without widening of the diaphyseal shaft and wide deep mandible) and sclerosteosis with van Buchem disease (distinguished by variable syndactyly)^{10,11}.

The most difficult to distinguish from Camurati-Engelmann disease is Ribbing disease, sclerosing dysplasia of unknown etiology. Both diseases involve the diaphyses of long tubular bones with sparing of the epiphyses, but Ribbing disease is either unilateral or, if bilateral, always asymmetric¹². Asymmetry of the bone involvement was not found in our patient. Ribbing disease is an adult condition with higher incidence in women, in contradiction with this case of male patient¹³. Finally, Ribbing disease

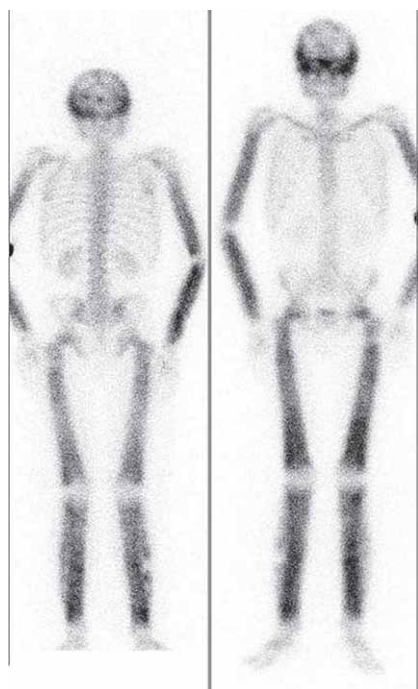


Fig. 1. Bone scintigraphy: anterior and posterior.

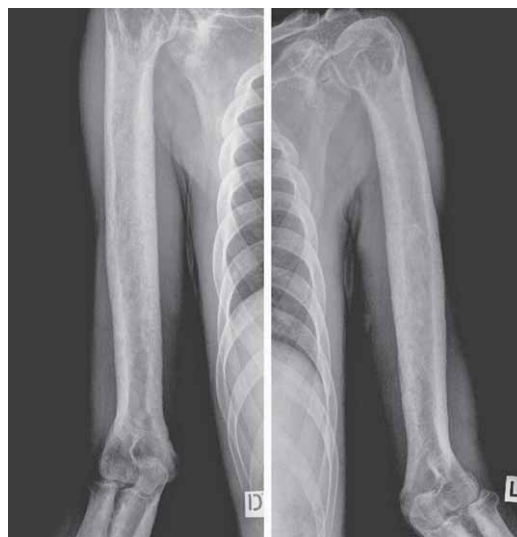

Fig. 2. Radiogram of right and left humerus.

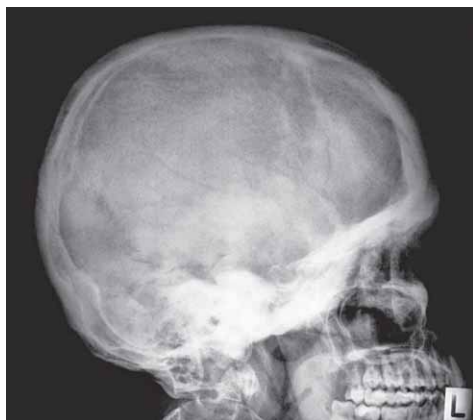

Fig. 3. Skull radiograms.

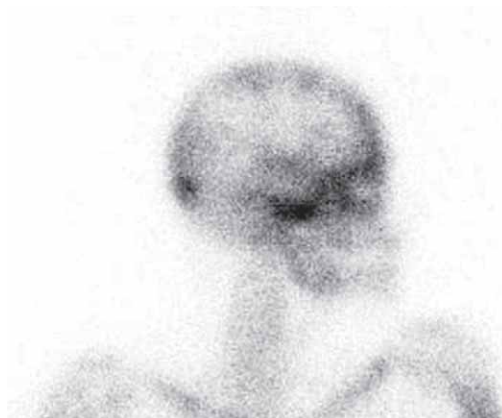


Fig. 4. Skull scintigraphy.

is nonhereditary condition and we were able to find inheritance pattern.

All reachable family members were examined (mother, both sisters, grandparents from the mothers' side), but no clinical symptoms of the disease were found. Bone scans of all family members were normal. Although patient's father was not willing to accept present family evaluation, we were able to track his old bone scan done years ago (Figure 5). The clue why those scans were performed at that time is still unclear, though it seems that family physician was on the brink of discovery of a rare diagnosis. Those old scans confirmed today that the father has got the same diagnosis as a son. According to patients and all other family member statements, father had no clinical symptoms. According to the family photos his phenotype is unobtrusive. Until now dominant inheritance from the father to son had not been suspected because of asymptomatic father.

There are not many treatment options for such rare disease. One of them is etidronate, a first generation of bisphosphonate that inhibits osteoclast-mediated bone resorption. Etidronate is analog of pyrophosphate; when a carbon is substituted for the oxygen the molecule can

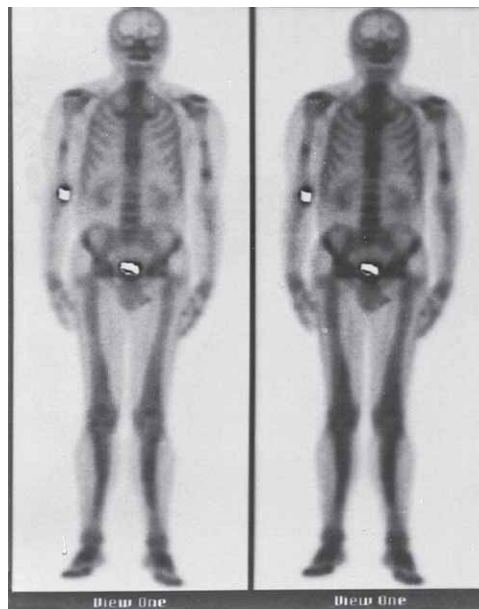


Fig. 5. Father's bone scintigraphy.

enter the bones and inhibit mineralization. In that way it binds strongly to hydroxyapatite crystals in the bone matrix, inhibits directly mature osteoclast and promotes osteoclast apoptosis. When given cyclically, etidronate is effective for increasing the bone mineral density of lumbar spine and preventing vertebral fractures in patients with osteoporosis. High etidronate doses (given continuously) cause osteomalacia. This undesired side effect in patient treated for osteoporosis is welcome in the case of Camurati Engelmann disease¹⁴. 800 mg/day of etidronate resulted in the drop of osteocalcin (a specific markers of bone formation) level from 106 to 85 $\mu\text{g/L}$ ¹⁵. Despite that finding, after 2 years of therapy patient's symptoms did not improve¹⁶.

Glucocorticoids are drugs with common side effects on bone metabolism. They reduce bone formation and increase bone resorption. The decline in bone formation is mediated by direct inhibition of osteoblast proliferation/differentiation and by an increase in the apoptosis rates of mature osteoblasts and osteocytes¹⁷. Glucocorticoids stimulate osteoclast proliferation by suppressing synthesis of osteoprotegerin, an inhibitor of osteoclast differentiation. They also stimulate osteoclast differentiation and bone resorption through RANKL (receptor activator of nuclear factor kappa-B ligand – surface-bound molecule that activates osteoclasts)¹⁸. Lower rate of bone formation and higher rate of bone resorption are progressive diaphyseal dysplasia. Steroids, the most common treatment option for Camurati-Engelmann disease, improve the quality of life, decrease the pain but do not alter the course of the disease¹⁹. In this case, only 24 mg of methylprednisolone resulted in clinical improvement. After one month of corticosteroid therapy patient reported significantly less pain and fatigue.

Discussion

There are almost 90 years since the first descriptions of the two family members, just like in this case of father and son, suffering from progressive diaphyseal dysplasia. This rare genetic autosomal dominant disorder is still often misdiagnosed. Extreme phenotypic variability in clinical presentation not only in different families, but also among family members, unpredictable severity and different age of onset often deceives physicians. In this case severe clinical manifestation, laboratory results X-rays and bone scan led towards the diagnosis of Camurati-

-Engelmann disease. Bone scintigraphy of a patient showed increased accumulation in long bones pelvis and skull, a consequence of high osteoblastic activity caused by TGF β -1 stimulation, a finding typical for this disease¹⁴. Finally, old bone scans of the father matching his son's scans confirmed heredity of the disease. An old, almost forgotten bone scan of the parent revealed the diagnosis and confirmed the inheritance pattern. Careful clinical examination of the patient and the family combined with bone scintigraphy seems to be necessary in confirming or ruling out progressive diaphyseal dysplasia, even without genetic testing²⁰.

REFERENCES

1. COCKAYNE EA, Proc Roy Soc Med, 13 (1920) 136. — 2. CAMURATI M, Chir Organi Mov, 6 (1922) 662. — 3. ENGELMANN G, Geb Roentgenstr Nukl, 39 (1929) 1101. — 4. MUNDRA V, TAXEL P, Conn Med, 7 (2012) 33. — 5. BARTUSEVICIENE A, SAMULIS A, SKUCAS J, Skeletal Radiol, 38 (2009) 1037. DOI: 10.1007/s00256-008-0642-1. — 6. HARISANKAR CN, KAMLESHWARAN KK, BHATTACHARYA A, SINGH B, BHADADA S, MITTAL BR, Indian J Nucl Med, 26 (2011) 44. DOI: 10.4103/0972-3919.84615. — 7. JANSSENS K, GERSHONI-BARUCH R, VAN HUL E, BRIK R, GUAÑABENS N, MIGONE N, VERBRUGGEN LA, RALSTON SH, BONDUELLE M, VAN MALDERGEM L, VANHOENACKER F, VAN HUL W, J Med Genet, 37 (2000) 245. — 8. SHI M, ZHU J, WANG R, CHEN X, MI L, WALZ T, SPRINGER TA, Nature, 15 (2011) 343. DOI: 10.1038/nature10152. — 9. HERNÁNDEZ MV, PERIS P, GUAÑABENS N, ALVAREZ L, MONEGAL A, PONS F, PONCE A, MUÑOZ-GÓMEZ J, Calcif Tissue Int, 61 (1997) 48. — 10. KOVACIĆ K, HAJNČIĆ TF, RONČEVIĆ S, HAT J, MARKICEVIĆ-RUZICIC K, KUSIĆ Z, Coll Antropol, 31 (2007) 359. — 11. BARTUSEVICIENE A, SAMULIS A, SKUCAS J, Skeletal Radiol, 38 (2009) 1037. DOI: 10.1007/

s00256-008-0642-1. — 12. MUKKADA PJ, FRANKLIN T, RAJESWARAN R, JOSEPH S, Indian J Radiol Imaging, 20 (2010) 47. DOI: 10.4103/0971-3026.59754. — 13. KANG S, HAN I, SHIN SH, KIM HS, Clin Orthop Relat Res, 470 (2012) 321. DOI: 10.1007/s11999-011-2165-7. — 14. JANSSENS K, VANHOENACKER F, BONDUELLE M, VERBRUGGEN L, VAN MALDERGEM L, RALSTON S, GUAÑABENS N, MIGONE N, WIENTROUB S, DIVIZIA MT, BERGMANN C, BENNETT C, SIMSEK S, MELANÇON S, CUNDY T, VAN HUL W, Med Gen, 43 (2006) 1. — 15. EASTELL R, HANNON RA, Proc Nutr Soc, 67 (2008) 157. DOI: 10.1017/S002966510800699X. — 16. CASTRO GR, APPENZELLER S, MARQUES-NETO JF, BÉRTOLO MB, SAMARA AM, COIMBRA I, Clin Rheumatol, 24 (2005) 398. — 17. MANOLAGAS SC, WEINSTEIN RS, J Bone Miner Res, 14 (1999) 1061. — 18. ABU EO, HORNER A, KUSEC V, TRIFFITT JT, COMPSTON JE, J Clin Endocrinol Metab, 85 (2000) 883. — 19. HEYMANS O, GEBHART M, ALEXIOU J, SOKOLOW Y, Acta Clin Belg, 52 (1998) 189. — 20. CLYBUOW C, DESMYTTERE S, BONDUELLE M, PIEPSZ A, Genet Couns, 5 (1994) 195.

M. Baretić

University of Zagreb, University Hospital Centre Zagreb, Division of Endocrinology, Department of Internal Medicine, Kišpatičeva 12, 10000 Zagreb, Croatia
e-mail: maja.simek@zg.t-com.hr

CAMURATI-ENGELMANNOVA BOLESTI U OBITELJI S HRVATSKOG OTOKA: STARA SNIMKA KOSTIJU POTVRDILA JE OBRAZAC NASLJEĐIVANJA

SAŽETAK

34-godišnji bolesnik od svoje četvrte godine u povijesti bolesti navodi mišićnu slabost, učestalo umaranje, bolove u rukama i nogama ti gegajući hod. Niz godina obrađivan je zbog sumnje na neuromuskularnu bolest koja nije potvrđena. Povišena koštana alkalna fosfataza, kao i ostali markeri koštane pregradnje (osteokalcin, telopeptid, prokolagen) indicirali su obradu koštanog sustava. Scintigrafija kostiju sa [99mTc]MPD pokazala je simetrično pojačano nakupljanje u dugim kostima i na bazi lubanje što odgovaralo zadebljanju kortikalisa dugih kostiju i sklerozi baze lubanje prikazane na radiološkim snimkama. Snimke su ukazale na Camurati-Engelmannovu bolest čija dijagnoza promakla dugo vremena. Radi se o rijetkoj genetskoj autosomno dominantnoj bolesti koja se kasnije dijagnosticirala i kod bolesnikova oca. Stare snimke člana obitelji potvrdile su nasljedni obrazac bolesti.