

Current practice variations in the management of anterior cruciate ligament injuries in Croatia

Mahnik, Alan; Mahnik, Silvija; Dimnjaković, Damjan; Ćurić, Stjepan; Smoljanović, Tomislav; Bojanić, Ivan

Source / Izvornik: **World Journal of Orthopedics, 2013, 4, 309 - 315**

Journal article, Published version

Rad u časopisu, Objavljena verzija rada (izdavačev PDF)

<https://doi.org/10.5312/wjo.v4.i4.309>

Permanent link / Trajna poveznica: <https://urn.nsk.hr/urn:nbn:hr:105:892478>

Rights / Prava: [In copyright](#) / [Zaštićeno autorskim pravom.](#)

Download date / Datum preuzimanja: **2024-05-18**



Repository / Repozitorij:

[Dr Med - University of Zagreb School of Medicine
Digital Repository](#)



Current practice variations in the management of anterior cruciate ligament injuries in Croatia

Alan Mahnik, Silvija Mahnik, Damjan Dimnjakovic, Stjepan Curic, Tomislav Smoljanovic, Ivan Bojanic

Alan Mahnik, Silvija Mahnik, Damjan Dimnjakovic, Tomislav Smoljanovic, Ivan Bojanic, Department of Orthopaedic Surgery, University Hospital Center Zagreb, School of Medicine, University of Zagreb, 10000 Zagreb, Croatia

Stjepan Curic, Institute of Public Health County Krapinsko-zagorska, Zlatar 49250, Croatia

Author contributions: Mahnik A, Smoljanovic T and Bojanić I contributed to the conception and design of the research; Mahnik A, Mahnik S, Dimnjakovic D and Curic S were responsible for the majority of the fieldwork, and contributed to acquisition of the data; Mahnik A and Mahnik S performed the most of the analysis and interpretation of the data; Mahnik A, Mahnik S, Dimnjakovic D, Curic S wrote a draft of the manuscript; Smoljanovic T and Bojanic I performed critical revision of the manuscript for important intellectual content; all the authors approved the submitted version of the manuscript.

Correspondence to: Tomislav Smoljanovic, MD, PhD, Department of Orthopaedic Surgery, University Hospital Center Zagreb, School of Medicine, University of Zagreb, Salata 7, 10000 Zagreb, Croatia. drsmoljanovic@yahoo.com

Telephone: +385-1-2368911 Fax: +385-1-2368937

Received: March 4, 2013 Revised: May 18, 2013

Accepted: June 18, 2013

Published online: October 18, 2013

Abstract

AIM: To investigate current preferences and opinions on the diagnosis, treatment and rehabilitation of patients with anterior cruciate ligament (ACL) injury in Croatia.

METHODS: The survey was conducted using a questionnaire which was sent by e-mail to all 189 members of the Croatian Orthopaedic and Traumatology Association. Only respondents who had performed at least one ACL reconstruction during 2011 were asked to fill out the questionnaire.

RESULTS: Thirty nine surgeons responded to the survey. Nearly all participants (95%) used semitendinosus/gracilis tendon autograft for reconstruction and only 5%

used bone-patellar tendon-bone autograft. No other graft type had been used. The accessory anteromedial portal was preferred over the transtibial approach (67% vs 33%). Suspensory fixation was the most common graft fixation method (62%) for the femoral side, followed by the cross-pin (33%) and bioabsorbable interference screw (5%). Almost all respondents (97%) used a bioabsorbable interference screw for tibial side graft fixation.

CONCLUSION: The results show that ACL reconstruction surgery in Croatia is in step with the recommendations from latest world literature.

© 2013 Baishideng. All rights reserved.

Key words: Anterior cruciate ligament; Survey; Knee; Surgery; Reconstruction

Core tip: The anterior cruciate ligament (ACL) is the prime static stabilizer against anterior translation of the tibia on the femur. We conducted a survey of members of the Croatian Orthopaedics and Traumatology Association to gain an understanding of preferences and opinions regarding the treatment of ACL injuries. Our findings are compared with those of previous surveys found in the literature to highlight temporal shifts and geographic differences in opinion.

Mahnik A, Mahnik S, Dimnjakovic D, Curic S, Smoljanovic T, Bojanic I. Current practice variations in the management of anterior cruciate ligament injuries in Croatia. *World J Orthop* 2013; 4(4): 309-315 Available from: URL: <http://www.wjgnet.com/2218-5836/full/v4/i4/309.htm> DOI: <http://dx.doi.org/10.5312/wjo.v4.i4.309>

INTRODUCTION

It has been 105 years since Hey Groves^[1] made the first

anterior cruciate ligament (ACL) reconstruction using a patient's iliotibial band as autograft. Since then, a large number of surgical techniques, graft types, and rehabilitation protocols have been described in the literature. Today, ACL reconstruction is the sixth most common surgical procedure in orthopaedics with over 300000 reconstructions performed every year in the United States^[2]. Despite the large-scale use of ACL reconstructions, questions still remain regarding indications, surgical techniques, graft selection, fixation method, and postoperative rehabilitation protocol, causing controversy regarding both nonsurgical and surgical treatment of ACL injury^[3-5]. However, not all practicing surgeons may be aware of recent trends in the management of these injuries. Until now there has been no study conducted on the graft type, surgical method, preoperative prerequisites, postoperative applications required, and rehabilitation approach in ACL reconstruction preferred by orthopaedic and traumatology surgeons in Croatia. There are several similar studies in other countries described in the literature^[3,6-11].

The primary goal of this study was to conduct a survey of members of the Croatian Orthopaedics and Traumatology Association (COTA) to gain an understanding of preferences and opinions regarding the treatment of ACL injuries. The secondary goal was to compare our findings with those of previous surveys found in the literature and to highlight temporal shifts and geographic differences in opinion.

MATERIALS AND METHODS

A questionnaire was sent by e-mail to members of COTA. An e-mail invitation was distributed *via* kwik-surveys.com with a link to the survey. Reminder e-mails were sent out 1 and 4 mo after the initial e-mail. Surgeons were asked if had they performed ACL reconstructive surgery within the past 12 mo. If so, they were asked to complete the remaining survey questions. Responses were identified using study numbers and were kept separate from the names/e-mails of the respondents.

The survey comprised 45 questions that were divided into three groups: 21 multiple-choice questions, 6 questions with yes/no answers and 18 questions containing a series of statements for which respondents indicated agreement or disagreement on a 5-point Likert scale^[3]. The questionnaire included questions regarding the natural history of ACL-injured knees, indications for ACL reconstruction, surgical technique, graft type used, postoperative rehabilitation, starting time for specific exercises and for return to sports.

Results from this study were analyzed by descriptive statistics (mean, standard deviation, minimum-maximum values, frequency values, percentages). Results are displayed numerically and graphically, thus simplifying their interpretation. In accordance with the study of Marx *et al.*^[3], a minimum of 80% in matching responses was required to achieve a clinical agreement.

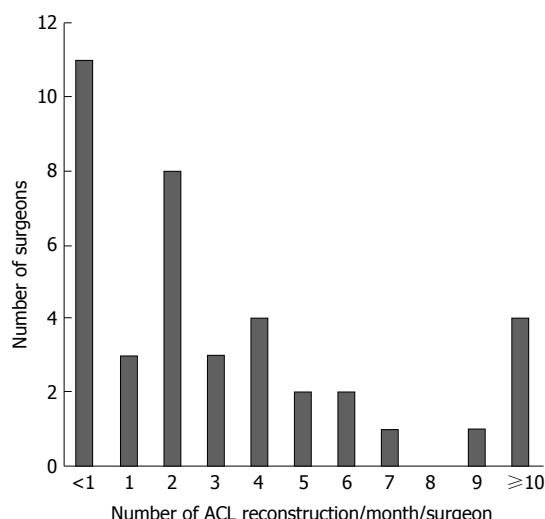


Figure 1 Frequency distribution of the number of surgeons performing anterior cruciate ligament reconstructions per month.

RESULTS

Thirty nine surgeons responded that they had performed at least one ACL reconstruction in 2011. A frequency distribution of surgeons by the number of ACL reconstructions performed per month is presented in Figure 1. Almost 75% of respondents performed four or less ACL reconstructions per month, meaning less than fifty ACL reconstructions per year. Also, among the members of COTA, ACL reconstruction is performed mostly by younger surgeons, supported by data that about 56% of respondents had spent less than ten years in surgical practice.

Ratings, from “strongly disagree” to “strongly agree”, of a series of statements regarding natural history and related clinical recommendations are presented in Table 1. The criterion of “clinical agreement” was met for only 2 statements: (1) “hamstrings and quadriceps strength affects function in ACL-deficient knees” (94.9% agreement); and (2) “ACL disruption is associated with increased rate of arthrosis” (87.2% agreement). Attitudes regarding the indications for ACL reconstruction are shown in Table 2. Surgeons agreed or strongly agreed that giving up activities of daily living (94.8%), giving up sporting events (89.7%), high-demand activity (94.8%) and patients with repairable meniscal tear (92.3%) were positive factors and that advanced degenerative changes on X-ray (87.1%) was a negative factor influencing the decision to perform an ACL reconstruction.

Most of the surgeons start ACL reconstruction by performing diagnostic arthroscopy (82%). Among the members of COTA, no one uses allograft, while a staggering 95% of participants use semitendinosus/gracilis tendon autograft for reconstruction and only 5% use bone-patellar tendon-bone (BPTB) autograft. The accessory anteromedial portal was preferred over the transtibial approach (67% *vs* 33%). Furthermore, 80% of surgeons who performed more than fifty ACL recon-

Table 1 Percentage (number) of surgeons choosing each response on a 5-Point Likert Scale regarding statements on the natural history of anterior cruciate ligament tear and related clinical recommendations *n* (%)

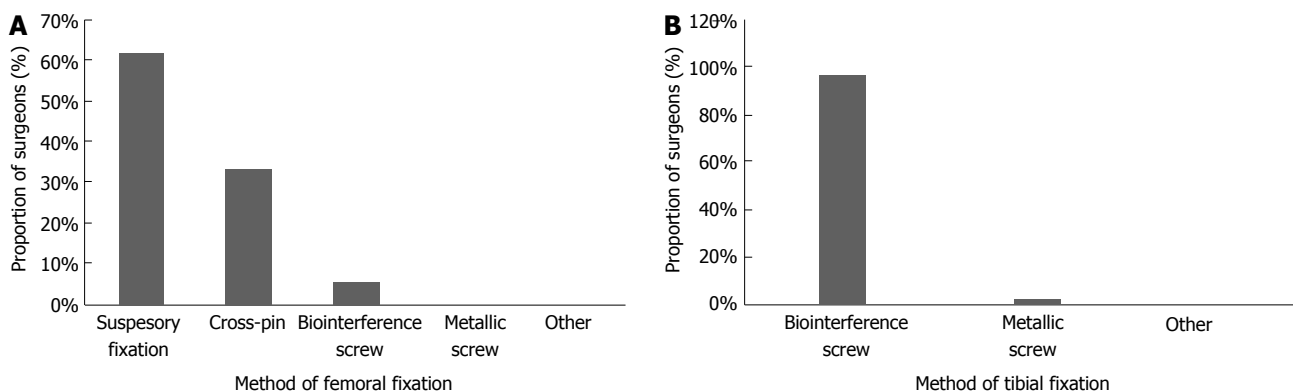
Statement	Strongly disagree	Disagree	Neutral	Agree	Strongly agree
Clinical agreement					
Hamstrings and quadriceps strength affects function in ACL-deficient knees	2 (5.1)	0 (0)	0 (0)	17 (43.6)	20 (51.3)
ACL disruption is associated with increased rate of arthrosis	0 (0)	2 (5.1)	3 (7.7)	14 (35.9)	20 (51.3)
No clinical agreement					
ACL reconstruction reduces the rate of arthrosis in ACL-deficient knees	0 (0)	4 (10.3)	7 (17.9)	15 (38.5)	13 (33.3)
ACL-deficient, ligamentously lax individuals are more symptomatic	0 (0)	6 (15.4)	5 (12.8)	22 (56.4)	6 (15.4)
Patients with ACL-deficient knees who have not had surgery are able to participate in recreational sporting activities	9 (23.1)	15 (38.5)	6 (15.4)	7 (17.9)	2 (5.1)
Patients awaiting surgery are able to participate in recreational sporting activities	10 (25.6)	17 (43.6)	9 (23.1)	3 (7.7)	0 (0)
Bracing is useful for the ACL-deficient knee treated nonoperatively	10 (25.7)	13 (33.3)	8 (20.5)	8 (20.5)	0 (0)

ACL: Anterior cruciate ligament.

Table 2 Percentage (number) of surgeons choosing each response on a 5-Point Likert Scale regarding statements on positive factors influencing the decision to proceed with anterior cruciate ligament reconstruction *n* (%)

Statement	Strongly disagree	Disagree	Neutral	Agree	Strongly agree
Clinical agreement					
Giving up activities of daily living	1 (2.6)	1 (2.6)	0 (0)	11 (28.2)	26 (66.6)
Giving up sporting activities only	1 (2.6)	1 (2.6)	2 (5.1)	22 (56.4)	13 (33.3)
High-demand activity	1 (2.6)	0 (0)	1 (2.6)	14 (35.9)	23 (58.9)
Advanced degenerative changes on the X-ray	8 (20.5)	26 (66.6)	4 (10.3)	0 (0)	1 (2.6)
Repairable meniscal tear	1 (2.6)	2 (5.1)	0 (0)	17 (43.6)	19 (48.7)
No clinical agreement					
Complaining of severe pain	0 (0)	12 (30.8)	14 (35.9)	7 (17.9)	6 (15.4)
Female sex	7 (17.9)	12 (30.8)	15 (38.5)	5 (12.8)	0 (0)
Older than 40 yr	1 (2.6)	17 (43.6)	16 (40.9)	4 (10.3)	1 (2.6)
Open growth plates	5 (12.8)	19 (48.7)	8 (20.5)	4 (10.3)	3 (7.7)
Non-repairable meniscal tear	2 (5.1)	6 (15.4)	8 (20.5)	19 (48.7)	4 (10.3)
Recurrent swelling of the knee	1 (2.6)	10 (25.6)	8 (20.5)	15 (38.5)	5 (12.8)

ACL: Anterior cruciate ligament.

**Figure 2** Method of graft fixation on femoral (A) and tibial (B) sides.

structions per year use an accessory anteromedial portal. Suspensory fixation was the most common graft fixation method for the femoral side (62%), followed by the cross-pin (33%) and bioabsorbable interference screw (IS) (5%). Astonishingly, 97% of our respondents use bioabsorbable IS for tibial side graft fixation (Figure 2). All patients received perioperative prophylactic antibiotics.

There is a large diversity of opinions regarding rec-

ommendations for the use of knee braces in patients after ACL reconstruction (Figure 3A). Some surgeons (17.95%) did not use knee braces at all. However, most surgeons (66.67%) routinely prescribed some sort of knee brace post-surgery. Of those who prescribe knee braces, most (43.59%) used post-operative functional braces and others (23.08%) used knee immobilizers. In relation to allowing full weight-bearing after surgery,

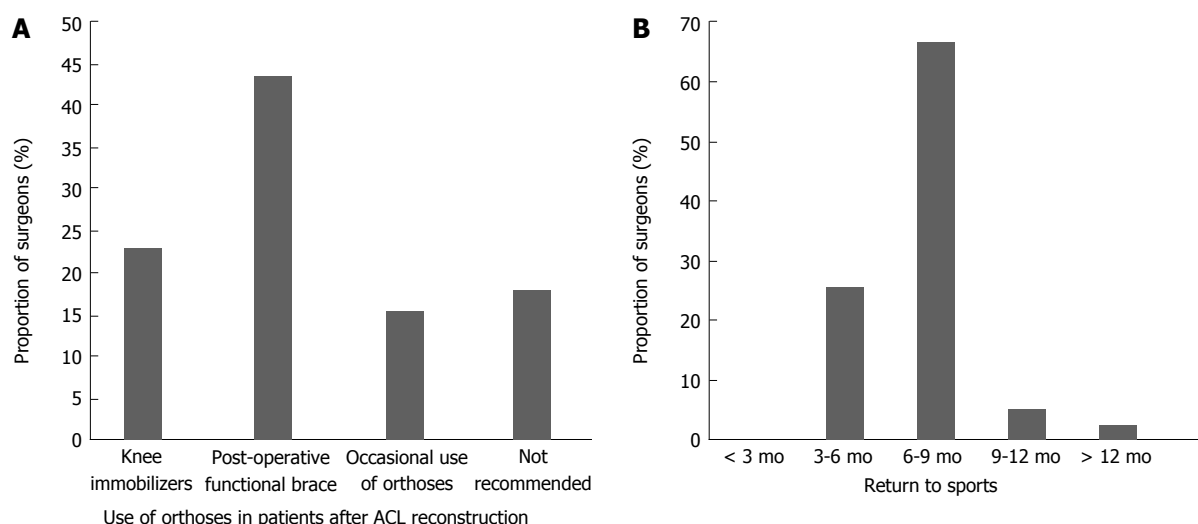


Figure 3 Recommendations. A: For the use of orthoses in patients after anterior cruciate ligament (ACL) reconstruction; B: Time until return to full sporting activity after ACL reconstruction.

25.64% surgeons initiate the full weight-bearing immediately after surgery, 33.34% preferred to wait three weeks after surgery, 38.46% allowed their patients to weight-bear on the operated knee six weeks after surgery and the remaining 2.56% waited two month before initiating complete weight-bearing. The recommended duration of physiotherapy by 66.67% surgeons was 6-12 wk. For most surgeons (66.67%) time for a complete return to sports activities after ACL reconstruction was 6 to 9 mo, 25.64% considered 3-6 mo to be sufficient for returning to sport activities, and others waited longer than 9 mo (Figure 3B).

DISCUSSION

This survey shows the diversity of opinions and approaches in ACL reconstruction surgery among orthopaedic and traumatology surgeons in Croatia. Consensus among surgeons was achieved on the decision to perform ACL reconstruction surgery if a patient has knee instability during everyday tasks or sport activities, if a patient has a physically demanding job, or if a patient has a meniscus tear that can be treated by suturing. Also, agreement was achieved on the statement that ACL injury increases degenerative changes in knee and on the statement that the strength of quadriceps and hamstrings muscles affects the knee function after ACL injury. General informed consent has to be signed in every hospital in Croatia in which surgical reconstruction of ACL is performed, yet only one third of participants claim that their institution has a specific informed consent on surgical reconstruction of ACL. Therefore, quality of patient information related to ACL reconstruction and postoperative rehabilitation might be deficient, and this should be improved in future^[12].

An ideal graft for use in ACL reconstruction is one that is easily harvested, results in little or no harvest site morbidity, has structural and biomechanical properties

similar to those of the native ligament, can be secured predictably and rapidly incorporates to the bones^[13]. Historically, ACL reconstructions were performed using BPTB autografts fixed with metal IS. That has been considered the gold standard to which other technologies are compared. Although, semitendinosus/gracilis tendon autograft was introduced at roughly the same time as BPTB autograft it was only recently that it gained popularity. Typically, semitendinosus/gracilis tendon autograft is associated with less anterior knee pain and also allows separation of the graft for performing double-bundle reconstruction, which BPTB grafting does not^[14-17]. On the other hand, a BPTB autograft has an excellent initial fixation and improved graft incorporation related to bone-to-bone healing, but its use may also be associated with patellofemoral pain and, occasionally, patellar fractures^[13,15,18-21]. Examination of data found in the literature indicates a shift in opinion regarding graft choice from BPTB autograft to semitendinosus/gracilis tendon autograft. For example, in the United States in the late nineties, BPTB autograft was commonly preferred (79%) followed by semitendinosus/gracilis tendon autograft (12%) and allografts (8%)^[3,10]. In 2006, however, in United States, BPTB autograft was preferred by 46% of surgeons, semitendinosus/gracilis tendon autograft by 32%, and allografts by 22%. Furthermore, a more recent study Chechiak *et al*^[6] showed that among North American surgeons BPTB autograft was preferred by only 39%, semitendinosus/gracilis tendon autograft by 42%, and allografts by 19%. A much stronger temporal shift can be seen among members of the Canadian Orthopaedic Association (COA). McRae *et al*^[7] conducted a study and found that in 2011 there is preference for using semitendinosus/gracilis tendon autograft over BPTB autograft (70% *vs* 28.5%). This demonstrates a shift from an earlier survey conducted in 1995 in which COA surgeons indicated a preference for BPTB autograft (63%) over semitendinosus/gracilis tendon autograft (32%)^[22]. The use

of allograft for ACL reconstruction has gained increasing popularity and is now estimated to be used in about 20% of primary reconstructions in the United States^[23,24]. Although they are associated with no harvest site morbidity, and provide predictable graft size, shorter operative time and easier recovery in the postoperative period, allografts are considered more likely to fail because of decreased mechanical properties due to the sterilization process and the possibility of triggering an inflammatory foreign body response. Chechiak *et al*^[6] conducted their research among 261 American Academy of Orthopaedic Surgeons (AAOS) and European Federation of National Associations of Orthopaedics and Traumatology (EFORT) members worldwide and found that 63% of surgeons use semitendinosus/gracilis tendon autograft, 26% use BPTB autograft and 11% use allograft. More interestingly, they found a significant difference in graft choice by geographic regions. Surgeons in Europe prefer semitendinosus/gracilis tendon autograft (72%) while 19% of surgeons use BPTB autograft. In addition, Granan *et al*^[25] published Scandinavian ACL registries and found that semitendinosus/gracilis tendon autograft was the most frequently used graft in all of Scandinavia (61% in Norway, 71% in Denmark, and 86% in Sweden), followed by BPTB autograft (38% in Norway, 22% in Denmark, and 14% in Sweden) and allografts (< 1% in Norway, 7% in Denmark, and < 1% in Sweden). Our results show extreme popularity of semitendinosus/gracilis tendon autograft among members of COTA.

Throughout history there have been two concepts to ACL reconstruction: isometric and anatomic. The biomechanical concept of graft isometry was developed in the 1960s and was based on the notion that the ideal ACL graft should be “isometric”, which means that the distance between the femoral and tibial attachment sites does not change as the knee flexes^[26,27]. By the 1990s, surgeons started to recognize that the goal to achieve isometry within a single or double tubular graft had proved an elusive one which, if achievable, would create unphysiological conditions, as none of the identifiable native ACL bundles are isometric in their own right. Thus it was realized that any reconstructive effort must restore any injured anatomic structure to its normal functional position and tension. The use of an arthroscopic accessory anteromedial portal for femoral drilling allows a more accurate placement of the femoral tunnel, thus allowing anatomic reconstruction^[28-32]. McRae *et al*^[7] divided surgeons into two groups: a “high-volume” and a “low-volume” group based on the number of ACL reconstructions performed per month and found statistically significant differences in implementation of the accessory anteromedial portal to create the femoral tunnel. Results showed that the “high-volume” group preferred creating a new, accessory anteromedial portal for femoral drilling. A survey conducted in the United States in 2006 found that 90% of surgeons perform a single-incision arthroscopic ACL reconstruction and, of those, 85% still preferred the transtibial approach, while only 15% performed an ac-

cessory anteromedial portal^[10]. In contrast, Chechik *et al*^[6] found that 68% preferred the accessory anteromedial portal over a transtibial approach in their worldwide survey in 2011. Our study showed the same results, 67% of surgeons used an accessory anteromedial portal and that the percentage was higher among surgeons who performed more than 50 ACL reconstructions per year.

Graft fixation methods can be divided into suspensory, cross-pin and metal or bioabsorbable IS. Today, the most commonly used suspensory fixation is the endobutton and the most commonly used cross-pin fixation is rigid-fix system. The fixation device must provide strong enough fixation to allow early rehabilitation with minimal movement of the graft until biological fixation is complete. While some biomechanical studies suggested that suspensory fixation is strongest in terms of load to failure^[33], others showed that the further the fixation point from the joint line, the more it allows the graft to elongate under cyclic loading^[34]. Metallic IS is the longtime gold standard^[35,36] of graft fixation and it was the preferred choice of most surgeons until 1999^[37]. Bioabsorbable and biocomposite materials were introduced, which allowed magnetic resonance imaging with fewer artifacts and image distortion and were also better handled during revision surgery^[13]. On the other hand, bioabsorbable IS have been reported to break intraoperatively. They can contribute to tunnel widening and in some cases provoke an inflammatory response and pain which requires their surgical removal^[36,38]. Chechik *et al*^[6] reported that they found no consensus among 261 AAOS and EFORT members worldwide on the choice of fixation device. Metal or bioabsorbable IS and suspensory fixation were almost equally used (40% *vs* 46%), and bioabsorbable were preferred over metallic IS (34% *vs* 12%). However, surgeons in North America use screws more often than suspensory fixation (58% *vs* 35%), while in Europe surgeons use screws and suspensory fixation equally (41% *vs* 41%). A study conducted by Sandhu^[8] reported that in 2008 the two main fixation methods used for stabilizing the graft in the Indian subcontinent were bioabsorbable IS (50%) and the metallic IS (25.50%). Among COA surgeons, McRae *et al*^[7] reported that suspensory fixation was the preferred method for fixation on the femoral side (51.5%) and bioabsorbable IS for graft fixation on the tibial side (63.2%). Our study also showed a preference among members of the COTA towards suspensory fixation, used by 62% of surgeons.

Bracing after ACL reconstruction is still a controversial subject^[39-45]. Many clinicians believe that braces improve the outcome of ACL reconstruction by improving extension, decreasing pain and graft strain, and providing protection from excessive force. However, a systematic review conducted by Wright *et al*^[39] found that there is no evidence that pain, range of motion, graft stability, or protection from subsequent injury were affected by brace use after ACL reconstruction. Our study showed the same diversity of opinions regarding use of knee braces after ACL reconstruction among the members of COTA.

This study does carry some notable limitations. It is a retrospective study that relies on the accuracy of the reporting surgeon, and this could be a source of bias. The study is also limited by the lack of comparison between surgical techniques used and patients' functional outcomes. These limitations could be solved by prospective design of future studies related to this topic. Despite its limitations, this is the first study conducted in Croatia into opinions and agreements among orthopaedic and traumatology surgeons concerning the diagnosis, treatment and rehabilitation of patients with ACL injury. The results show that ACL reconstruction surgery in Croatia follows the trend of the recommendations from the latest world literature.

COMMENTS

Background

The anterior cruciate ligament (ACL) is the prime static stabilizer against anterior translation of the tibia on the femur. Injury to the ACL is the most common ligament injury in the knee and ACL reconstruction is the sixth most common surgical procedure in orthopaedics. Despite the large-scale use of ACL reconstructions, questions still remain regarding indications, surgical techniques, graft selection, fixation method, and postoperative rehabilitation protocol, causing controversy regarding both nonsurgical and surgical treatment of ACL injury.

Research frontiers

The research aim was to investigate current preferences and opinions on the diagnosis, treatment and rehabilitation of patients with a ACL injury in Croatia and to compare the findings with those of previous surveys found in the literature and to highlight geographic differences in opinion.

Innovations and breakthroughs

The research showed that nearly all participants use semitendinosus/gracilis tendon autograft for reconstruction and only 5% use bone-patellar tendon-bone autograft. The accessory anteromedial portal was preferred over the transtibial approach (67% vs 33%). Suspensory fixation was the most common graft fixation method (62%) for the femoral side, followed by the cross-pin (33%) and bioabsorbable interference screw (5%). Almost all respondents (97%) use a bioabsorbable interference screw for tibial side graft fixation.

Applications

The research showed that ACL reconstruction surgery in Croatia is in line with the recommendations from latest world literature.

Peer review

The paper shows a common opinion of anterior cruciate ligament repair for Croatian doctors in comparison to the western countries. It is well written.

REFERENCES

- Hey Groves EW. Operation for the repair of crucial ligaments. *Lancet* 1917; **11**: 674-675
- Chang CB, Choi JY, Koh IJ, Lee KJ, Lee KH, Kim TK. Comparisons of femoral tunnel position and length in anterior cruciate ligament reconstruction: modified transtibial versus anteromedial portal techniques. *Arthroscopy* 2011; **27**: 1389-1394 [PMID: 21889869 DOI: 10.1016/j.arthro.2011.06.013]
- Marx RG, Jones EC, Angel M, Wickiewicz TL, Warren RF. Beliefs and attitudes of members of the American Academy of Orthopaedic Surgeons regarding the treatment of anterior cruciate ligament injury. *Arthroscopy* 2003; **19**: 762-770 [PMID: 12966385]
- Barrack RL, Bruckner JD, Kneisl J, Inman WS, Alexander AH. The outcome of nonoperatively treated complete tears of the anterior cruciate ligament in active young adults. *Clin Orthop Relat Res* 1990; **227**: 192-199 [PMID: 2208856]
- Shirakura K, Terauchi M, Kizuki S, Moro S, Kimura M. The natural history of untreated anterior cruciate tears in recreational athletes. *Clin Orthop Relat Res* 1995; **227**: 227-236 [PMID: 7671484]
- Chechik O, Amar E, Khashan M, Lador R, Eyal G, Gold A. An international survey on anterior cruciate ligament reconstruction practices. *Int Orthop* 2013; **37**: 201-206 [PMID: 22782378 DOI: 10.1007/s00264-012-1611-9]
- McRae SM, Chahal J, Leiter JR, Marx RG, Macdonald PB. Survey study of members of the Canadian Orthopaedic Association on the natural history and treatment of anterior cruciate ligament injury. *Clin J Sport Med* 2011; **21**: 249-258 [PMID: 21519299 DOI: 10.1097/JSM.0b013e318219a649]
- Sandhu JS. Current practice variations in the management of anterior cruciate ligament injuries among the orthopaedic surgeons of India. *J Orthopaedics* 2008; **5**: e12
- Kapoor B, Clement DJ, Kirkley A, Maffulli N. Current practice in the management of anterior cruciate ligament injuries in the United Kingdom. *Br J Sports Med* 2004; **38**: 542-544 [PMID: 15388535 DOI: 10.1136/bjsm.2002.002568]
- Duquin TR, Wind WM, Fineberg MS, Smolinski RJ, Buyea CM. Current trends in anterior cruciate ligament reconstruction. *J Knee Surg* 2009; **22**: 7-12 [PMID: 19216345]
- Cailliez J, Reina N, Molinier F, Chaminade B, Chiron P, Laffosse JM. Patient information ahead of anterior cruciate ligament reconstruction: Experience in a university hospital center. *Orthop Traumatol Surg Res* 2012; **98**: 491-498 [PMID: 22857890 DOI: 10.1016/j.otsr.2012.03.007]
- Schoderbek RJ, Treme GP, Miller MD. Bone-patella tendon-bone autograft anterior cruciate ligament reconstruction. *Clin Sports Med* 2007; **26**: 525-547 [PMID: 17920951 DOI: 10.1016/j.csm.2007.06.006]
- Biau DJ, Katsahian S, Kartus J, Harilainen A, Feller JA, Sajovic M, Ejerhed L, Zaffagnini S, Röpke M, Nizard R. Patellar tendon versus hamstring tendon autografts for reconstructing the anterior cruciate ligament: a meta-analysis based on individual patient data. *Am J Sports Med* 2009; **37**: 2470-2478 [PMID: 19709991 DOI: 10.1177/0363546509333006]
- Reinhardt KR, Hetsroni I, Marx RG. Graft selection for anterior cruciate ligament reconstruction: a level I systematic review comparing failure rates and functional outcomes. *Orthop Clin North Am* 2010; **41**: 249-262 [PMID: 20399364 DOI: 10.1016/j.joc.2009.12.009]
- Krych AJ, Jackson JD, Hoskin TL, Dahm DL. A meta-analysis of patellar tendon autograft versus patellar tendon allograft in anterior cruciate ligament reconstruction. *Arthroscopy* 2008; **24**: 292-298 [PMID: 18308180 DOI: 10.1016/j.arthro.2007.08.029]
- Mirza F, Mai DD, Kirkley A, Fowler PJ, Amendola A. Management of injuries to the anterior cruciate ligament: results of a survey of orthopaedic surgeons in Canada. *Clin J Sport Med* 2000; **10**: 85-88 [PMID: 10798788]
- Baer GS, Harner CD. Clinical outcomes of allograft versus autograft in anterior cruciate ligament reconstruction. *Clin Sports Med* 2007; **26**: 661-681 [PMID: 17920959 DOI: 10.1016/j.csm.2007.06.010]
- Cohen SB, Sekiya JK. Allograft safety in anterior cruciate ligament reconstruction. *Clin Sports Med* 2007; **26**: 597-605 [PMID: 17920955 DOI: 10.1016/j.csm.2007.06.003]
- Granan LP, Forssblad M, Lind M, Engebretsen L. The Scandinavian ACL registries 2004-2007: baseline epidemiology. *Acta Orthop* 2009; **80**: 563-567 [PMID: 19916690 DOI: 10.3109/17453670903350107]
- Cowan DJ. Reconstruction of the Anterior Cruciate Ligament by the Method of Kenneth Jones (1963). *Proc R Soc Med* 1965; **58**: 336-338 [PMID: 19994401]
- Odensten M, Gillquist J. Functional anatomy of the anterior cruciate ligament and a rationale for reconstruction. *J Bone Joint Surg Am* 1985; **67**: 257-262 [PMID: 3968118]
- Colvin A, Sharma C, Parides M, Glashow J. What is the best

- femoral fixation of hamstring autografts in anterior cruciate ligament reconstruction?: a meta-analysis. *Clin Orthop Relat Res* 2011; **469**: 1075-1081 [PMID: 21063817 DOI: 10.1007/s11999-010-1662-4]
- 23 **Elliott MJ**, Kurtz CA. Peripheral versus aperture fixation for anterior cruciate ligament reconstruction. *Clin Sports Med* 2007; **26**: 683-693 [PMID: 17920960 DOI: 10.1016/j.csm.2007.06.002]
- 24 **Chen NC**, Brand JC, Brown CH. Biomechanics of intratunnel anterior cruciate ligament graft fixation. *Clin Sports Med* 2007; **26**: 695-714 [PMID: 17920961 DOI: 10.1016/j.csm.2007.06.009]
- 25 **Emond CE**, Woelber EB, Kurd SK, Ciccotti MG, Cohen SB. A comparison of the results of anterior cruciate ligament reconstruction using bioabsorbable versus metal interference screws: a meta-analysis. *J Bone Joint Surg Am* 2011; **93**: 572-580 [PMID: 21411708 DOI: 10.2106/JBJS.J.00269]
- 26 **Delay BS**, Smolinski RJ, Wind WM, Bowman DS. Current practices and opinions in ACL reconstruction and rehabilitation: results of a survey of the American Orthopaedic Society for Sports Medicine. *Am J Knee Surg* 2001; **14**: 85-91 [PMID: 11401175]
- 27 **Gaweda K**, Walawski J, Wegłowski R, Krzyzanowski W. Comparison of bioabsorbable interference screws and posts for distal fixation in anterior cruciate ligament reconstruction. *Int Orthop* 2009; **33**: 123-127 [PMID: 18064457 DOI: 10.1007/s00264-007-0482-y]
- 28 **Wright RW**, Fetzter GB. Bracing after ACL reconstruction: a systematic review. *Clin Orthop Relat Res* 2007; **455**: 162-168 [PMID: 17279043 DOI: 10.1097/BLO.0b013e31802c9360]
- 29 **Alentorn-Geli E**, Lajara F, Samitier G, Cugat R. The trans-tibial versus the anteromedial portal technique in the arthroscopic bone-patellar tendon-bone anterior cruciate ligament reconstruction. *Knee Surg Sports Traumatol Arthrosc* 2010; **18**: 1013-1037 [PMID: 19902178 DOI: 10.1007/s00167-009-0964-0]
- 30 **Araki D**, Kuroda R, Kubo S, Fujita N, Tei K, Nishimoto K, Hoshino Y, Matsushita T, Matsumoto T, Nagamune K, Kurosaka M. A prospective randomised study of anatomical single-bundle versus double-bundle anterior cruciate ligament reconstruction: quantitative evaluation using an electromagnetic measurement system. *Int Orthop* 2011; **35**: 439-446 [PMID: 20734043 DOI: 10.1007/s00264-010-1110-9]
- 31 **Bedi A**, Musahl V, Steuber V, Kendoff D, Choi D, Allen AA, Pearle AD, Altchek DW. Transtibial versus anteromedial portal reaming in anterior cruciate ligament reconstruction: an anatomic and biomechanical evaluation of surgical technique. *Arthroscopy* 2011; **27**: 380-390 [PMID: 21035990 DOI: 10.1016/j.arthro.2010.07.018]
- 32 **Birmingham TB**, Bryant DM, Giffin JR, Litchfield RB, Kramer JF, Donner A, Fowler PJ. A randomized controlled trial comparing the effectiveness of functional knee brace and neoprene sleeve use after anterior cruciate ligament reconstruction. *Am J Sports Med* 2008; **36**: 648-655 [PMID: 18192493 DOI: 10.1177/0363546507311601]
- 33 **Bowers AL**, Bedi A, Lipman JD, Potter HG, Rodeo SA, Pearle AD, Warren RF, Altchek DW. Comparison of anterior cruciate ligament tunnel position and graft obliquity with transtibial and anteromedial portal femoral tunnel reaming techniques using high-resolution magnetic resonance imaging. *Arthroscopy* 2011; **27**: 1511-1522 [PMID: 21963097 DOI: 10.1016/j.arthro.2011.07.007]
- 34 **Cawley PW**, France EP, Paulos LE. Comparison of rehabilitative knee braces. A biomechanical investigation. *Am J Sports Med* 1989; **17**: 141-146 [PMID: 2757122]
- 35 **Coşkun D**, Bayrakçı Tunay V, Akgün I. Current trends in reconstruction surgery and rehabilitation of anterior cruciate ligament in Turkey. *Acta Orthop Traumatol Turc* 2010; **44**: 458-463 [PMID: 21358252 DOI: 10.3944/AOTT.2010.2388]
- 36 **Heijne A**, Werner S. A 2-year follow-up of rehabilitation after ACL reconstruction using patellar tendon or hamstring tendon grafts: a prospective randomised outcome study. *Knee Surg Sports Traumatol Arthrosc* 2010; **18**: 805-813 [PMID: 19851754 DOI: 10.1007/s00167-009-0961-3]
- 37 **Lubowitz JH**. Anteromedial portal technique for the anterior cruciate ligament femoral socket: pitfalls and solutions. *Arthroscopy* 2009; **25**: 95-101 [PMID: 19111224 DOI: 10.1016/j.arthro.2008.10.012]
- 38 **Matsumoto A**, Yoshiya S, Muratsu H, Yagi M, Iwasaki Y, Kurosaka M, Kuroda R. A comparison of bone-patellar tendon-bone and bone-hamstring tendon-bone autografts for anterior cruciate ligament reconstruction. *Am J Sports Med* 2006; **34**: 213-219 [PMID: 16282583 DOI: 10.1177/0363546505279919]
- 39 **Poolman RW**, Abouali JA, Conter HJ, Bhandari M. Overlapping systematic reviews of anterior cruciate ligament reconstruction comparing hamstring autograft with bone-patellar tendon-bone autograft: why are they different? *J Bone Joint Surg Am* 2007; **89**: 1542-1552 [PMID: 17606794 DOI: 10.2106/JBJS.F.01292]
- 40 **Romanini E**, D'Angelo F, De Masi S, Adriani E, Magaletti M, Lacorte E, Laricchiuta P, Sagliocca L, Morciano C, Mele A. Graft selection in arthroscopic anterior cruciate ligament reconstruction. *J Orthop Traumatol* 2010; **11**: 211-219 [PMID: 21181226 DOI: 10.1007/s10195-010-0124-9]
- 41 **Sadoghi P**, Müller PE, Jansson V, van Griensven M, Kröpfl A, Fischmeister MF. Reconstruction of the anterior cruciate ligament: a clinical comparison of bone-patellar tendon-bone single bundle versus semitendinosus and gracilis double bundle technique. *Int Orthop* 2011; **35**: 127-133 [PMID: 20442994 DOI: 10.1007/s00264-010-1037-1]
- 42 **Sterett WI**, Briggs KK, Farley T, Steadman JR. Effect of functional bracing on knee injury in skiers with anterior cruciate ligament reconstruction: a prospective cohort study. *Am J Sports Med* 2006; **34**: 1581-1585 [PMID: 16870823 DOI: 10.1177/0363546506289883]
- 43 **van Eck CF**, Schreiber VM, Mejia HA, Samuelsson K, van Dijk CN, Karlsson J, Fu FH. "Anatomic" anterior cruciate ligament reconstruction: a systematic review of surgical techniques and reporting of surgical data. *Arthroscopy* 2010; **26**: S2-12 [PMID: 20810090 DOI: 10.1016/j.arthro.2010.03.005]
- 44 **Wright RW**, Preston E, Fleming BC, Amendola A, Andrish JT, Bergfeld JA, Dunn WR, Kaeding C, Kuhn JE, Marx RG, McCarty EC, Parker RC, Spindler KP, Wolcott M, Wolf BR, Williams GN. A systematic review of anterior cruciate ligament reconstruction rehabilitation: part I: continuous passive motion, early weight bearing, postoperative bracing, and home-based rehabilitation. *J Knee Surg* 2008; **21**: 217-224 [PMID: 18686484]
- 45 **Wu GK**, Ng GY, Mak AF. Effects of knee bracing on the functional performance of patients with anterior cruciate ligament reconstruction. *Arch Phys Med Rehabil* 2001; **82**: 282-285 [PMID: 11239327 DOI: 10.1053/apmr.2001.19020]

P- Reviewer Cranford CC S- Editor Wen LL
L- Editor Hughes D E- Editor Wang CH





Published by **Baishideng Publishing Group Co., Limited**

Flat C, 23/F., Lucky Plaza, 315-321 Lockhart Road,

Wan Chai, Hong Kong, China

Fax: +852-65557188

Telephone: +852-31779906

E-mail: bpgoffice@wjgnet.com

<http://www.wjgnet.com>

