

Rectal cancer and Fournier's gangrene - current knowledge and therapeutic options

Bruketa, Tomislav; Majerović, Matea; Augustin, Goran

Source / Izvornik: **World Journal of Gastroenterology, 2015, 21, 9002 - 9020**

Journal article, Published version

Rad u časopisu, Objavljena verzija rada (izdavačev PDF)

<https://doi.org/10.3748/wjg.v21.i30.9002>

Permanent link / Trajna poveznica: <https://um.nsk.hr/um:nbn:hr:105:514166>

Rights / Prava: [In copyright](#)/[Zaštićeno autorskim pravom.](#)


Download date / Datum preuzimanja: **2024-07-30**



Repository / Repozitorij:

[Dr Med - University of Zagreb School of Medicine
Digital Repository](#)





2015 Advances in Colorectal Cancer

Rectal cancer and Fournier's gangrene - current knowledge and therapeutic options

Tomislav Bruketa, Matea Majerovic, Goran Augustin

Tomislav Bruketa, Department of Surgery, University Hospital Center Zagreb, 10000 Zagreb, Croatia

Matea Majerovic, Department of Internal Medicine, University Hospital Center Zagreb, 10000 Zagreb, Croatia

Goran Augustin, Department of Surgery, Division of Gastrointestinal Surgery, University Hospital Center Zagreb and School of Medicine, University of Zagreb, 10000 Zagreb, Croatia

Author contributions: Bruketa T, Majerovic M and Augustin G contributed equally to this work; Augustin G designed the research; Bruketa T and Majerovic M performed the research; Majerovic M analyzed the data; and Bruketa T, Majerovic M and Augustin G wrote the paper.

Conflict-of-interest statement: All the authors declare no conflict of interest regarding the manuscript "Rectal cancer and Fournier's gangrene - current knowledge and therapeutic options".

Open-Access: This article is an open-access article which was selected by an in-house editor and fully peer-reviewed by external reviewers. It is distributed in accordance with the Creative Commons Attribution Non Commercial (CC BY-NC 4.0) license, which permits others to distribute, remix, adapt, build upon this work non-commercially, and license their derivative works on different terms, provided the original work is properly cited and the use is non-commercial. See: <http://creativecommons.org/licenses/by-nc/4.0/>

Correspondence to: Goran Augustin, MD, PhD, Department of Surgery, Division of Gastrointestinal Surgery, University Hospital Center Zagreb and School of Medicine University of Zagreb, Kišpatićeva 12, 10000 Zagreb, Croatia. augustin.goran@gmail.com
Telephone: +385-1-2388196
Fax: +385-1-2376020

Received: February 20, 2015

Peer-review started: February 23, 2015

First decision: April 23, 2015

Revised: May 8, 2015

Accepted: June 15, 2015

Article in press: June 16, 2015

Published online: August 14, 2015

Abstract

Fournier's gangrene (FG) is a rapid progressive bacterial infection that involves the subcutaneous fascia and part of the deep fascia but spares the muscle in the scrotal, perianal and perineal region. The incidence has increased dramatically, while the reported incidence of rectal cancer-induced FG is unknown but is extremely low. Pathophysiology and clinical presentation of rectal cancer-induced FG *per se* does not differ from the other causes. Only rectal cancer-specific symptoms before presentation can lead to the diagnosis. The diagnosis of rectal cancer-induced FG should be excluded in every patient with blood on digital rectal examination, when urogenital and dermatological causes are excluded and when fever or sepsis of unknown origin is present with perianal symptomatology. Therapeutic options are more complex than for other forms of FG. First, the causative rectal tumor should be removed. The survival of patients with rectal cancer resection is reported as 100%, while with colostomy it is 80%. The preferred method of rectal resection has not been defined. Second, oncological treatment should be administered but the timing should be adjusted to the resolution of the FG and sometimes for the healing of plastic reconstructive procedures that are commonly needed for the reconstruction of large perineal, scrotal and lower abdominal wall defects.

Key words: Fournier's gangrene; Necrotizing fasciitis; Proctological examination; Necrotizing soft tissue infections; Oncological treatment; Rectal cancer; Surgical treatment; Reconstructive surgery

© The Author(s) 2015. Published by Baishideng Publishing Group Inc. All rights reserved.

Core tip: The reported incidence of Fournier's gangrene (FG) has increased dramatically, while the reported incidence of rectal cancer-induced FG is unknown but is extremely low. Therapeutic options are more complex than for other forms of FG. First, the causative rectal tumor should be removed - survival with rectal cancer resection is reported as 100%, while with colostomy it is only 80%. Second, the timing of the oncological treatment should be adjusted to the resolution of the FG and sometimes for the healing of plastic reconstructive procedures commonly needed for the reconstruction of large perineal, scrotal and lower abdominal wall defects.

Bruketa T, Majerovic M, Augustin G. Rectal cancer and Fournier's gangrene - current knowledge and therapeutic options. *World J Gastroenterol* 2015; 21(30): 9002-9020 Available from: URL: <http://www.wjgnet.com/1007-9327/full/v21/i30/9002.htm> DOI: <http://dx.doi.org/10.3748/wjg.v21.i30.9002>

INTRODUCTION

There has been confusion in the literature as to the precise definition of necrotizing fasciitis (NF) and Fournier's gangrene (FG), which has been compounded by the use of multiple terms. Even although NF was actually first described by Hippocrates in the 5th century BC as a complication of erysipelas (many were attacked by the erysipelas all over the body when the exciting cause was a trivial accident flesh, sinews and bones fell away in large quantities, there were many deaths)^[1], the description of the disease has been attributed by many to Avicenna (1025)^[2] and Baurienne (1764)^[3]. When NF involves the male genitalia, it is known as FG after Jean Alfred Fournier who described it in 1843 and Jones coined the term hospital gangrene in 1871^[4]. In 1952, Wilson coined the term NF to describe the disease process that can occur in other parts of the body in either gender but which, when affecting the perineum, still merits the eponym FG^[5].

Criteria for NF include: (1) fascial necrosis; (2) spreading cellulitis with undermining of fascial planes; and (3) systemic toxicity with altered mental state and hyperthermia. Some add (4) multiorgan failure as a criterion. NF is classified into four types. Type 1 is due to a mixture of aerobic and anaerobic organisms, usually following an abdominal or inguinal operation, or it is associated with diabetes mellitus. It is the most common, accounting for 80% or more of all the necrotizing soft tissue infections (NSTIs), including FG^[6]. Type 2 is due to Group A *Streptococcus* infection synergistic with a second organism (*Staphylococcus aureus*, coliforms, *Bacteroides* spp.) observed in the limbs^[7]. Type 3 stems from gram-negative marine bacteria. Type 4 is a fungal infection occurring mostly

in immunocompromised persons.

When referring to FG there are two important issues. First, it is important to define FG precisely because sometimes authors attribute other forms of infection to FG that require only simple drainage of pus and not extensive debridement^[8]. In such cases, prognosis is excellent and the inclusion of these patients in the FG group leads to wrong conclusions. Second, diagnostic, therapeutic and prognostic parameters with longer follow-up should be written in future reports to have a complete picture of FG, especially rectal cancer-induced FG, which is extremely rarely published.

PUBMED AND GOOGLE SCHOLAR SEARCH

A PubMed and Google Scholar search were conducted using the keywords "Fournier's gangrene", "necrotizing fasciitis", "rectal cancer" and "rectal tumor". Inclusion criteria were restricted to all case reports and case series in which the rectal cancer was confirmed as a cause of FG. Of the 27 articles dating from 1988 to 2014, 23 were available as full-text and were relevant to our review.

INCIDENCE

The overall (reported) incidence of FG increased dramatically in the 20th century. From 1764 to 1978 there were 386 reported cases and from 1950 to 1999, 1726 cases^[9]. The incidence is rising due to an increase in the mean age of the population, increased numbers of patients with comorbidities, widespread use of immunosuppressive therapy and those suffering from human immunodeficiency virus (HIV) infection, especially in Africa^[10,11]. The overall incidence is 1.6/100000 males and represents less than 0.02% of hospital admissions^[10]. The real incidence could be underestimated because most cases with a grave prognosis were not published.

Anorectal causes

Anorectal pathology is the most common cause in both males and females (Table 1). The incidence varies significantly, mostly between 20% and 60% depending on the (sub)population analyzed. The most common causes are perianal/ischiorectal abscess and hemorrhoidectomy (Table 2). Other common causes are rectal injury and perianal fistula (Table 2); less common causes include sigmoid/rectal carcinoma, colorectal anastomotic dehiscence, appendicitis, perforated sigmoid diverticulitis, rectal biopsy, artificial sphincter or even anal dilation.

Rectal cancer-induced FG

The incidence of rectal cancer-induced FG is unknown. The first known case (of a famous person) with FG

Table 1 Anorectal causes of Fournier's gangrene - incidence, colostomy rate, duration of hospitalization and survival

Ref.	Anorectal cause	Male:female ratio	Rectal cancer in all-cause group	Rectal cancer in anorectal cause group	Colostomy (all-cause/rectal cause)	Survival (all-cause/rectal cause)	The most common region	Duration of hospitalization (d)
Benjelloun <i>et al</i> ^[12] , 2013	70.00%	44:6	0%		10%/no data	76%/no data	scrotum	21.00
Bhatnagar <i>et al</i> ^[13] , 2008	7.30%	Male only (110)	0%		4%/no data	92.7%/no data	Scrotum	19.30
Cakmak <i>et al</i> ^[14] , 2008	63.10%	45:20:00	0%		23.1%/no data	70.3%/no data		24.40
Carroll <i>et al</i> ^[15] , 1986	50.00%	13:1			28.57%/no data	79%/no data		48.00
Czymek <i>et al</i> ^[16] , 2009	57.60%	23:10	3%	5.26%		81.9%/no data		
Efem ^[17] , 1994	0.00%	Male only (20)	0%				Scrotum	
Eke ^[9] , 2000	21.00%	10:1				84%/no data		2-278
Eskitaşcıoğlu <i>et al</i> ^[18] , 2014	20.00%	19:1	2.50%	50.00%	15%/no data		Scrotum	34.78
Fajdic <i>et al</i> ^[19] , 2007	42.85%	Male only (7)	0%		14.3%/no data	85.7%/no data	Perianal	25.80
Ghnnam <i>et al</i> ^[20] , 2008	54.05%	Male only (74)	0%		1.4%/no data	78.4%/no data		9.20
Rodríguez Hermosa <i>et al</i> ^[21] , 2001	30.00%	Male only (10)	0%		30%/50%	60%/75%	Scrotum	27.00
Jiménez-Pacheco <i>et al</i> ^[22] , 2012	29.70%	Male only (37)	0%			95%/no data		27.54
Kahramanca <i>et al</i> ^[23] , 2014	22.06%	48:20	1.47%	6.67%	22.06%/no data	92.65%/no data		15.37
Kara <i>et al</i> ^[24] , 2009	33.30%	10:5	0%		53.3%/no data	80%/no data	Scrotum and perineum	
Karbhari <i>et al</i> ^[25] , 2014	20.00%		0%			80%/no data	Scrotum	
Khan ^[26] , 2009	21.00%	Male only (19)	0%		5.3%/no data			26.00
Khandelwal ^[27] , 2013	24.60%	Male only (57)	0%		20.3%/no data	68.5%/no data		19.60
Korkut <i>et al</i> ^[28] , 2003	58.00%	37:8	2.22%	3.85%	40%/no data	80%/no data		12.00
Liang <i>et al</i> ^[29] , 2008	87.50%	Female only (8)	0%		87.5%/85.7%	75%/85.7%		32.20
Morua <i>et al</i> ^[30] , 2009		48:2			10%/no data	88%/no data	Scrotum	23.76

Table 2 Anorectal causes of Fournier's gangrene

Ref.	Abscess	Hemorrhoidectomy	Hemorrhoids	Intestinal obstruction	Perianal fistula	RT for rectal carcinoma	Rectal carcinoma	Artificial sphincter	Anal fissure	Rectal injury
Benjelloun <i>et al</i> ^[12] , 2013	88.50%		11.50%							
Bhatnagar <i>et al</i> ^[13] , 2008		75.00%		25.00%						
Cakmak <i>et al</i> ^[14] , 2008	43.90%	43.90%			12.20%					
Czymek <i>et al</i> ^[16] , 2009	68.42%				3.00%	15.79%	3.00%	3.00%		
Eskitaşcıoğlu <i>et al</i> ^[18] , 2014	56.25%				12.50%		12.50%		18.75%	
Fajdic <i>et al</i> ^[19] , 2007	33.30%		33.30%		33.30%					
Ghnnam <i>et al</i> ^[20] , 2008	90.00%	10.00%								
Rodríguez Hermosa <i>et al</i> ^[21] , 2001	75.00%									25.00%
Kahramanca <i>et al</i> ^[23] , 2014	66.66%						6.66%			26.66%
Kara <i>et al</i> ^[24] , 2009	60.00%									40.00%
Khan ^[26] , 2009	75.00%	25.00%								
Khandelwal ^[27] , 2013	75.00%	25.00%								
Korkut <i>et al</i> ^[28] , 2003	92.30%				4.16%		4.16%			
Liang <i>et al</i> ^[29] , 2008	100.00%									
Oymacı <i>et al</i> ^[31] , 2014	100.00%									
Ozkan <i>et al</i> ^[32] , 2014	62.50%						25.00%			12.50%
Singh <i>et al</i> ^[33] , 2004	100.00%									
Tan <i>et al</i> ^[34] , 2006	40.00%	40.00%					20.00%			
Unalp <i>et al</i> ^[35] , 2008	100.00%									
Villanueva-Sáenz <i>et al</i> ^[36] , 2002	88.00%				8.00%		4.00%			
Walker <i>et al</i> ^[37] , 1983							100.00%			
Wang <i>et al</i> ^[38] , 2012	91.00%						9.00%			

RT: Radiotherapy.

was that of Roman emperor Galerius. He suffered from diabetes and died of FG (in the advanced stage, worms were found in the perineal and scrotal area). Eusebius described the case and claimed that bowel cancer was the underlying cause^[39]. Rectal cancer is the third most

common cancer in the United States^[40], with 40000 patients diagnosed each year. Fortunately, there are several explanations for the low incidence of rectal cancer-induced FG. One is rectal cancer presentation before the potential development of FG and simple

diagnosis. When the upper rectum is involved, patients can present with bowel obstruction before the potential development of FG. In addition, up to 26% of obstructive large bowel perforations are proximal to the obstructing (non-perforating) tumor, presenting as acute abdomen, not FG. In addition, screening programs result in earlier stage rectal cancer diagnosis. We collected 23 cases with proven rectal cancer-induced FG (Table 3), although there are several more published^[64] which were unavailable for analysis. The average age of patients with rectal cancer-induced FG was 60 years (range 28-80) with a male: female ratio of 21:2. The incidence of rectal cancer-induced FG in all-cause FG ranged from 1.47% to 16.6% and in the anorectal group varied significantly from 3.85% to 100% (Table 1). These percentages should be interpreted with caution because the studies included different etiological groups of patients.

RISK FACTORS

All-cause FG

Predisposing factors for all-cause FG are poor perfusion (peripheral vascular disease), hypertension, renal insufficiency, trauma, diabetes mellitus, malnutrition, smoking, obesity, immunocompromised status, intravenous drug abuse, malignancy and spinal cord injury^[1]. Alcoholism and diabetes mellitus are the most common in western countries, with rates of 25%-50% and 10%-60%, respectively^[65-68]. Old age is not a predisposing factor; however, elderly patients with poor self-care and poor nutritional status are more susceptible^[1]. Female to male ratio varies significantly (Table 1). The lower incidence in women is ascribed to better drainage of the perineal region through vaginal secretions^[9,43]. In addition, the reported ratio depends on the type of clinic in which the data are collected, namely urology, surgery or gynecology. Reports from urology clinics tend to contain fewer female patients, while the incidence of females is higher in reports from general surgery clinics.

Anorectal causes of FG

From the published data, it is not possible to define specific risk factors for this group. General risk factors could be applied here. The proportion of anorectal causes ranges from 0% to 92.6% (average 40%) (Table 1).

Rectal cancer-induced FG

Seven of 23 articles (Table 3) mentioned general risk factors for rectal cancer-induced FG; the most common being diabetes mellitus. A specific risk factor is rectal cancer perforation. The risk of rectal cancer perforation besides its growth is neoadjuvant or therapeutic chemoradiotherapy. Colorectal carcinoma constitutes 9.2% of all colorectal perforations^[69]. Of all colorectal carcinomas, 5.9% perforate and of

these, 5.8% are located in the rectum^[70]. In 1977, 50% of perforated colorectal cancers were at the rectosigmoid junction^[71]. The site of perforation of the primary colorectal tumor is related to the primary tumor site in 50%^[72]. One should be cautious with interpretation because ulceration at the site of a primary tumor (with or without chemoradiotherapy) may be a non-specific finding as ulceration and deep necrosis are typical features in malignancies overall. Rectal cancer perforation as an adverse effect of preoperative (chemo)radiotherapy is extremely rare^[73,74]. With increased use of bevacizumab, a monoclonal immunoglobulin G₁ antibody directed against VEGF, gastrointestinal perforation as a side effect was observed in 1.7% of patients. Only 4.2% of these were from the rectal cancer^[75]. In a study by Hurwitz *et al.*^[76], the gastrointestinal perforation rate was 1.5% in the group with previously untreated metastatic colorectal cancer. There are no data about the perforation site.

PATHOPHYSIOLOGY

FG exists due to synergism between low aggressive multiple aerobic and anaerobic organisms that are normally present within the distal rectum and perianal area. Aerobes cause platelet aggregation, accelerate coagulation by fixing complement and produce heparinase^[77]. The presence of sialic acids on the cell walls of the *Streptococcus* spp. and *Escherichia coli* (*E. coli*) helps to inactivate the alternate complement pathway^[78]. Microthrombosis of nutrient vessels reduces local blood supply, causing dermal necrosis, and allows the growth of facultative anaerobes and microaerophilic organisms such as *E. coli*, *Bacteroides* spp. that inhibits phagocytosis of many aerobes^[79]. These produce the relatively insoluble gases composed of hydrogen, hydrogen sulphide, nitrogen and nitrous oxide, causing subcutaneous gas collections. Whether subcutaneous emphysema is merely the manifestation of a perforated rectal cancer or from bacterial gas production can be difficult to determine. The synergistic activity of aerobes and anaerobes leads to the production of various exotoxins and enzymes like collagenase, heparinase, hyaluronidase, streptokinase and streptodornase. This leads to digestion of fascial barriers, thus fueling the rapid spread of the infection and hemolytic anemia due to streptococcal hemolysins^[78,80]. It does not appear that the origin of the infection (rectum, urinary, dermal) has any impact on the specificity of the species cultivated^[68].

Urogenital origin

The infection originates from the urogenital triangle, usually secondary to urethral instrumentation. If the source is penile, then after the tough fibrous tunica albuginea is penetrated, the infection spreads to involve Buck's fascia^[81] which initially limits the

Table 3 Case reports of Fournier's gangrene as associated with perforated rectal cancer

Ref.	Age/Sex	Risk factors	Duration of symptoms/hospitalization	L/CRP	Starting point	DRE	MSCT (tumor, air)	Rectoscopy	Distance from AC border	Microbiology	Operation	Day of operation	Outcome/survival
Ash <i>et al</i> ^[41] , 2005	33/ m		2/ nd	10/ nd	Scrotum		Yes (tumor, air)	No			Colostomy	1	
Carr ^[42] , 2010	54/ m	Alcoholism	nd/ 23	nd	Scrotum, perineum, gluteus		Yes (tumor, no air)				APR	1	Alive
Chan <i>et al</i> ^[43] , 2013	78/ m	Smoker, hypertension, cerebrovascular accident, dyslipidemia	5/ nd	36.8/ nd	Perineum, scrotum	Neg	Yes (tumor, air)	Yes	10 cm	<i>E. coli</i>	Colostomy	5	Alive
Eke <i>et al</i> ^[44] , 1999	65/ m	Diabetes	nd/ nd	nd	Penis					<i>S. aureus</i>	Sigmoid colostomy		Alive
Ganagami <i>et al</i> ^[45] , 1998	45/ m	Diabetes	4/ nd	nd	Perianal	Pos		Yes		<i>E. coli</i> , Enterococi	Loop colostomy/ APR	1/ 28	Alive/ 1 yr df
Gupta ^[46] , 2010	55/ m		7/ nd	14.4/ 149		Pos		Yes		<i>E. coli</i> , Bacteroides	Colostomy		Died
Highton <i>et al</i> ^[47] , 2009	79/ m		2/ nd	nd	Right thigh	Neg		Yes	Upper	<i>E. coli</i> , anaerobes	End colostomy and mucous fistula	1	Alive
Katusić <i>et al</i> ^[48] , 2010	65/ m		nd/ 23	nd	Scrotum, perianal, right groin	Pos				<i>E. coli</i> , Pseudomonas	No colostomy		Alive
Khalil <i>et al</i> ^[49] , 2010	71/ m	No	10/ nd	20/ 424	Right thigh	Neg	Yes (tumor, air)				Hartmann procedure		Alive/ 6 yr Survival
Kojima <i>et al</i> ^[50] , 2007	56/ m	Diabetes	nd/ nd	23/ 196	Scrotum	Pos	Yes (tumor, air)		4 cm	<i>E. coli</i> , <i>M. morganii</i> , Enterococcus spp., Microaerophilic streptococcus, <i>B. fragilis</i>	Colostomy/ APR	1/ 121	Alive
Lamy <i>et al</i> ^[51] , 2003	71/ f	Diabetes	14/ nd	33/ 270	Gluteal, left thigh	Pos	Yes (tumor, air)	Yes	10 cm	Bacteroides spp.	Colostomy/ APR	1/ 60	Alive/ 1 mo survival
Lawrentschuk <i>et al</i> ^[52] , 2003	55/ m	No	6/ 43	n/ nd	Perineum, scrotum	Neg	Yes (air, no tumor)	Yes	5 cm	<i>E. coli</i> , Enterococcus species mixed, anaerobes, <i>S. epidermidis</i> group G streptococcus	End colostomy/ APR	1/ 16	Alive
Liu <i>et al</i> ^[53] , 2006	56/ m	Alcoholic cirrhosis, diabetes, renal insufficiency	nd/ nd	nd		Pos		Yes	8 cm		No colostomy		Died

Author	Age	Sex	Time to diagnosis	Time to surgery	Time to death	Location of infection	Yes (tumor, air)	No	Yes (tumor, no air)	3 cm	<i>E. coli</i> , Enterococcus, Bacteroides spp.	Colectomy + APR	Survival
McMullin <i>et al.</i> ^[84] , 2006	70	m	nd/26	33/nd	Scrotum	Pos	Yes (tumor, air)	3 cm	Yes	3 cm	Enterococcus, Bacteroides spp.	Colectomy + APR	Alive/2 yr survival
Moslemi <i>et al.</i> ^[85] , 2009	48	m	nd/nd	18/nd	Penis, perianal	Pos	Yes (tumor, no air)	Yes	Yes	AC border	Streptococcus viridans, <i>E. coli</i> , Bacteroides spp. and diphtheroids	Loop colostomy Hartmann procedure	Alive/1 yr df
Mulholland <i>et al.</i> ^[86] , 1990	73	m	nd/nd	nd	Scrotum, penis	Pos	Yes (tumor, no air)	Yes	Yes	Low	Streptococcus viridans, <i>E. coli</i> , Bacteroides spp. and diphtheroids	Loop colostomy	4 alive
O'Connor <i>et al.</i> ^[87] , 2009	80	m	nd/nd	ml/nd	Scrotum	Pos	Yes (tumor, no air)	Yes	Yes	Low	Streptococcus viridans, <i>E. coli</i> , Bacteroides spp. and diphtheroids	Loop colostomy	Alive
Öner <i>et al.</i> ^[88] , 2013	57	m	nd/25	22/nd	Scrotum	Pos	Yes	Yes	Yes	Yes	Streptococcus viridans, <i>E. coli</i> , Bacteroides spp. and diphtheroids	End colostomy/ APR	1/11 Alive/1 yr df
Rajendran <i>et al.</i> ^[89] , 2011	73	f	nd/nd	nd	Perianal	Pos	Yes (tumor, air)	Yes	Yes	Yes	Streptococcus viridans, <i>E. coli</i> , Bacteroides spp. and diphtheroids	Colostomy	4 Died
Villa Sánchez <i>et al.</i> ^[90] , 2014	43	m	nd/nd	2.7/270	Thigh, groin	Pos	Yes (tumor, air)	Yes	Yes	Yes	Streptococcus viridans, <i>E. coli</i> , Bacteroides spp. and diphtheroids	Colostomy	Died
Scott <i>et al.</i> ^[91] , 1988	63	m	nd/130	nd	Perianal	Pos	Yes (tumor, air)	Yes	Yes	Yes	Streptococcus viridans, <i>E. coli</i> , Bacteroides spp. and diphtheroids	APR	Alive
Tai <i>et al.</i> ^[92] , 2012	28	m	nd/nd	13/195	Right leg	Pos	Yes (tumor, air)	Yes	Yes	Yes	Streptococcus viridans, <i>E. coli</i> , Bacteroides spp. and diphtheroids	Colostomy	Alive
Woodcock <i>et al.</i> ^[93] , 2006	66		nd/59	nd	Perineum, scrotum perianal, inguinal	Pos	Yes (tumor, air)	Yes	Yes	Low	Streptococcus viridans, <i>E. coli</i> , Bacteroides spp. and diphtheroids	Loop colostomy/ APR	1/180+ Alive

infection to the ventral aspect of the penis. If the infection is not initially treated and Buck's fascia is penetrated, the infection may progress along the dartos fascia^[82,83]. The dartos fascia of the penis is a direct extension of the Colles' scrotal fascia, which is the continuation of the Scarpa's fascia of the anterior abdominal wall. Thus, the progression of the infection can spread freely to the scrotum and the Scarpa's fascia of the abdominal wall^[81]. The scrotum readily develops dermal gangrene because it has virtually no subcutaneous fat^[84]. If the Colles' scrotal fascia is penetrated, the infection can spread to the buttock, thigh, back and ischioanal space. Perineal fascia is attached to the perineal body and urogenital diaphragm posteriorly and the pubic rami laterally, thus limiting progression in these directions. Laterally and inferiorly it connects with the fascia lata of the lower limbs. Posteriorly it is limited by the levator ani muscle. If the anal sphincter is damaged, infections gain access to the retroperitoneum through pararectal spaces.

Anorectal origin

If infection originates from an anorectal source (anal triangle), it penetrates the muscles of the anal sphincter to reach the Colles' fascia^[85]. It penetrates the Colles' fascia and progresses anteriorly along the dartos fascia to involve the scrotum and penis. There is some evidence to indicate that the Colles' fascia is not a continuous layer but rather a condensation of fibrous tissue with interstices that could allow the spread of a perirectal process involving the scrotum and penis^[81]. If the sphincter apparatus is damaged, the infection can spread to the rectum into the presacral space, the retrovesical space and the pelvic space. This can involve the retroperitoneal space to the level of the upper abdomen. Ultimately, the infection can penetrate into the peritoneal cavity. Therefore, anorectal sources of infection usually start perianally and this variation in initial clinical presentation can serve as a guide to localizing the foci of infection^[3]. Infection can pass superiorly along the Scarpa's fascia to involve the anterior abdominal wall. If the Colles' fascia is interrupted, the infection can spread to the ischioanal fossa and subsequently to the

buttocks and thighs.

There are three different etiopathogenetic paths of infection with rectal perforation. First is iatrogenic retroperitoneal rectal perforation without the presence of rectal carcinoma. This mechanism is found during rectal instrumentations, barium enemas and diagnostic/therapeutic colonoscopy. The second mechanism is external rectal trauma sometimes with a foreign body retained through the rectal wall. The third mechanism is true spontaneous perforation of rectal cancer that can develop into two clinical forms. More commonly it presents as ischioanal and/or gluteal abscess or rarely in a form of FG. Tumor infiltration (with or without necrosis) of the rectal wall and surrounding tissues spreads the infection. Infection is much more fulminant than in iatrogenic extraperitoneal rectal perforation^[86-88]. This is due to pre-procedural bowel preparation with or without prophylactic antibiotics which significantly reduces the incidence and severity of the infection.

Whatever the cause of FG, testicular involvement is rare because of the separate blood supply to the testes and the testicles are always spared if the disease affects the subcutaneous tissue only^[89]. If necrotic testicles are found, an intra-abdominal process which leads to thrombosis of the testicular artery should be strongly suspected^[45].

CLINICAL PRESENTATION

Local findings

It is difficult to determine the exact time point at which the disease progresses from a primary infection to an FG. Clinical presentation of perianal or scrotal FG has many similarities. When the disease progresses slowly, patients are often unable to remember a specific date of symptom onset or sometimes report a date more recent than the actual date. In this way, they attempt to avoid giving the impression that they were reluctant to seek medical help or that they underestimated their disease. Most patients seek medical attention an average of 5 d after the onset of symptoms^[65]. Where mentioned in rectal cancer-induced FG, the duration of symptoms lasted 2-14 d (Table 3).

The course of the disease can be divided into two phases that are characterized by different rates of disease progression. A first phase, stable and sometimes long, during which the body's immune system prevents local inflammation from spreading, is followed by a second phase during which infection progresses rapidly to the fulminant illness. It begins with a prodromal period of genital discomfort and pruritus followed by sudden onset of perianal or perineal pain out of proportion to the physical findings^[1]. As the FG progresses, the pain is replaced by numbness and subsequent anesthesia caused by damage to cutaneous nerves^[90]. Irrespective of the bacterial species, the initial bacterial growth takes place in the subcutaneous tissues, *i.e.*, the subcutaneous fat, superficial fascia

and the superficial layer of the deep fascia. The skin remains intact initially and the extent of the subdermal gangrene may not be apparent^[91]. Later, skin develops patchy necrosis and becomes gangrenous. The swollen, shiny scrotum skin is a typical early symptom of scrotal infection. Due to a lack of subcutaneous fat in the scrotum, necrosis of dartos fascia leads to exposure of the testes that may be coated with a thick layer of creamy pus. Sometimes small skin ulcers drain thin, reddish-brown, foul-smelling fluid ("dishwater fluid"). An odor characteristic of anaerobic infection may be present. Surrounding these draining wounds are variable amounts of skin necrosis. Induration or distinct margins are absent, with the diseased area gradually fading into normal skin. A black spot or dusky area in the perineal skin surrounded by erythema is considered pathognomonic of FG^[61]. Crepitus and subcutaneous gas (gaseous emphysema) indicate the presence of dead tissue^[92]. Crepitus in all-cause FG is found in 19%-64% of patients^[93,94] and depends on the duration of FG and the underlying cause. There are no data about the incidence of crepitus in rectal cancer-induced FG. It commonly occurs in the first 48-72 h^[95-97]. Some patients have blisters and bullas of adjacent tissues, initially filled with serous and then hemorrhagic fluid^[98-100]. Lymphangitis and lymphadenitis are rare^[101,102]. FG progresses at the speed of 2-3 cm²/h^[36,103].

Initial localization of pain, edema and redness could lead to the underlying group of etiologies. If the initial presentation involves scrotum and penis or only penis, urogenital pathology could be the cause^[17]. All-cause FG starts as scrotal edema (Table 1) and therefore a group of causes cannot be defined only due to scrotal edema. Gangrene extension to the perineal/perianal region in delayed presentation complicates the possibility of identification of the cause. The scrotum should be checked for generalized crepitus, edema, erythema, tenderness, superficial ulcerations, odor and discharge. Both testicles should be palpated and compared. The penis should be checked for lesions and discharge. The patients should be asked about recent urinary catheterization. Prostate infiltration by the rectal tumor can present with prostatic symptoms and can be misleading.

The most common initial localization of rectal cancer-induced FG is the scrotum (Table 3). When scrotal edema develops in patients with anorectal pain, rectal bleeding, tenesmus or alteration of bowel habits and unintentional weight loss, rectal cancer should be suspected. Cachexia, weight loss, anemia, rectal bleeding, constipation and diarrhea were present in this group (Table 3). Urinary retention was present in one patient. There are several mechanisms and risk factors for this presentation. Old age is a risk factor for urinary retention and benign prostatic hyperplasia. Also perianal/perineal pain plus infection that disturbs sympathetic and parasympathetic neuronal pathways in the surrounding area causes urinary retention that

can mislead to the conclusion of the urogenital origin of FG.

Systemic findings

Systemic findings can also be misleading. Patients may have a fever, malaise for a few days^[104], nonspecific abdominal pain^[105] and general symptoms of infection without symptoms from the perineal area^[106,107]. The septic state develops with the rapid development of severe toxemia, causing pyrexia with or without hypothermia, tachycardia, hypotension and reduced urine output^[90]. Sepsis may occur in just a few hours, progressing to organ failure and death^[90]. The clinical picture is similar regardless of the bacterial species involved. All patients with fever or sepsis of unknown origin require a thorough genital, perineal and proctological examination.

DIFFERENTIAL DIAGNOSIS

Differential diagnosis includes two groups of diseases. The first group consists of other forms of NSTIs, also called infectious gangrene or gangrenous cellulitides (Table 4^[91,108-111]), and the other consists of diseases that resemble gangrenous/necrotic infections. These are not progressive bacterial infections but rather presentations of systemic or localized diseases or an immunocompromized host.

DIAGNOSIS

FG per se

The diagnosis is usually a clinical one. Early clinical recognition of FG is difficult as the disease is often indistinguishable from cellulitides/abscesses early in its evolution (Table 4). To aid in diagnosis, a risk score was developed - the Laboratory Risk Indicator for Necrotizing Fasciitis (LRINEC) score. A score of ≥ 6 raises the suspicion of NF and a score of ≥ 8 is strongly predictive of the disease.

Laboratory findings define the disease severity, septic state and metabolic derangements. A full blood count, C-reactive protein (CRP), urea, creatinine, glucose, calcium, potassium, sodium, coagulation studies, fibrinogen/fibrin degradation product levels and acid-base status should be checked. Diabetics may present with ketoacidosis^[112]. A mid-stream urine sample excludes/confirms urinary tract infection. One should be cautious because it can also be present despite a causative rectal tumor. Hypocalcemia due to bacterial lipase is an important indicator of the early stage^[113] and develops from extensive fat necrosis^[114]. Total protein and albumin levels show obligatory hypoalbuminemia, especially in the advanced presentation. Full blood count, calcium and CEA marker are rarely mentioned in articles with rectal cancer-induced FG. CRP was noted in 26% of these cases and ranged from 149 to 424 mg/L (Table 3).

Leukocytes were noted in 57% with a range of 10000/mm³-36800/mm³ with one patient with 2700 mm³ due to sepsis (Table 3).

The following two clinical courses should increase the likelihood of FG: (1) an infectious process that does not respond well to antibiotics; and (2) septic symptoms disproportionate to scrotal cutaneous manifestations in the early stage of infection^[3].

The finger test is diagnostic. This is a bedside procedure where under local anesthesia a 2 cm incision is made over most prominent cutaneous changes down to the deep fascia and a gentle probing maneuver with the index finger is performed at the level of the deep fascia. The lack of bleeding, presence of characteristic dishwater pus and easy blunt finger dissection of subcutaneous tissue off the fascia are features of a positive test^[115].

Tissue biopsies and pus (during finger test and intraoperatively) define causative microorganisms and possible underlying pathology. The histopathological features of FG are necrosis of the superficial fascia with blood vessel thrombosis and suppuration^[101,116]. Other consistent features include severe subcutaneous fat necrosis, severe inflammation of the dermis and subcutaneous fat, vasculitis, often with endarteritis, and local hemorrhage^[101,116]. In the early stage, the epidermis shows no major changes^[116].

Underlying cause

Digital rectal examination was performed in 70% of rectal cancer-induced FG cases and was positive in 75%, performed mostly preoperatively (Table 3). Microperforation can be confirmed or ruled out in palpable tumors. Impalpable perforation does not exclude microperforation.

Rectoscopy (as a bedside or intraoperative procedure) is mandatory in the following situations: (1) blood (any form) on digital rectal examination; (2) history and other/previous diagnostic modalities that refer to rectal carcinoma; (3) urogenital and dermatological causes have been excluded; (4) bacteria highly specific for (intestinal) rectal malignancy such as *Clostridium septicum*^[117]; and (5) fever or sepsis of unknown origin with perianal symptoms/signs. Rectoscopy was performed in 52% of rectal cancer-induced FG with equal frequency preoperatively and during the initial operation (Table 3).

Gas may be detected on plain X-ray, indicating the presence of dead tissue^[92]. X-rays were done in only 13% of rectal cancer-induced FG (Table 3).

Gas within the scrotal wall on ultrasound may be seen prior to clinical crepitus. Reactive unilateral or bilateral hydroceles may be present. If testicular involvement occurs, there is likely an intra-abdominal or retroperitoneal source of infection. Ultrasound is also useful in differentiating FG from incarcerated inguinoscrotal hernia, the data unknown for rectal cancer-induced FG.

Table 4 Classification, clinical aspects, anatomopathology and microbiology of necrotizing soft tissue infections^[9,6,113-116]

	Necrotizing fasciitis				Clostridium myonecrosis (gas gangrene)	Fungal necrotizing fasciitis	Clostridium fasciitis	Progressive bacterial synergistic gangrene	Synergistic necrotizing cellulitis	Pseudomonas gangrenous cellulitis	Streptococcal myonecrosis (necrotizing myositis)
	Type 1	Type 2	Type 3	Type 4							
Pain	+ / +++	++ / +++	+++	+++	+++	+	+++	+++	++ / +++	+ / +++	++ / +++
Anaesthesia of lesions	In advanced stages	In advanced stages									
Cutaneous signs	Edema, erythema, bullae, necrotic and ulcerated lesions	Edema, erythema, necrotic bullae	Pale, Yellow-brown discoloration of skin, Necrotico-hemorrhagic (brown) bullae	Edema, erythema	Minor edema, pale skin		Necrotic ulcer dusky margin and erythematous periphery at the margins of the wound		Cellulitis with foul-smelling, thick discharge from necrotic skin	Black/gray eschar. Dark discharge with surrounding erythema, hemorrhagic bullae	Edema, copper colored, blisters in advanced stage
Subcutaneous appearance of infection	Subcutaneous tissue and fascial necrosis	Subcutaneous tissue and fascial necrosis	Necrotic area composed of green-black patches. Serosanguinous. "mousy"-smelling discharge, bluish muscles	Subcutaneous tissue, fascial and muscle necrosis			Subcutaneous tissue necrosis and gangrene		Dark pus or 'dishwasher' fluid		Seropurulent discharge
Systemic toxicity	+ to +++	+ to +++ (Toxic shock syndrome)	+++	+++	+	+	+	+	++ to +++	+++	+ to +++ (Streptococcal Toxic Shock Syndrome)
Fever	High	High	Moderate to high	High	Moderate	Moderate	Minimal or absent	Moderate	Moderate	High	
Progression	Moderate (3-14 d)	Very fast (1-3 d)	Very fast (1-3 d)	Very fast (1-3 d)	Moderate (>3 d)	Moderate (>3 d)	Moderate (3-14 d)	Moderate (3-14 d)	Moderate (3-14 d)	Moderate (3-14 d)	Fast (1-4 d)
Crepitus (gas)	- / +	-	+++	++ / +++	++	++	-	-	+	-	- / +
Deep fascias infection	- to ++	+ to +++	+++	+++	+	+	-	-	- to ++	-	- / +
Muscular infection	- / + (secondary)	- / + (secondary)							+ to +++		+++
Site of entry, initiating factor	Wound, vascular lesion, surgery, local infection	Trauma, surgery, cutaneous lesion, burn, erysipelas, varicella	Non penetrating trauma, limb crushing, in. injection, sepsis	Trauma, surgery	Wound, surgery	Wound, surgery	Surgery	Prior local lesions, perirectal lesions		Trauma, surgery	Trauma, surgery, muscle strain
Risk factors	Diabetes mellitus	Vascular disease	Immunosuppression	Immunosuppression	Diabetes mellitus	Diabetes mellitus			Diabetes mellitus	Immunosuppression	Immunosuppression
Microbiology	Enterobacteraceae, Anaerobes, Streptococcus, Staphylococcus	Group A Streptococcus, methicillin-resistant <i>S. aureus</i> (MRSA)	<i>C. perfringens</i> , <i>C. septicum</i> / <i>Vibrio</i> spp.	<i>C. albicans</i> , <i>C. neoformans</i>	<i>C. perfringens</i> , <i>C. septicum</i>	<i>C. perfringens</i> , <i>C. septicum</i>	Staphylococcus aureus, microaerophilic streptococci, Enterobacteriaceae		Mixed aerobes and anaerobes	Pseudomonas aeruginosa	Group A Streptococcus

Imaging modalities define the cause and the disease extent. CT has greater specificity than radiography or ultrasonography for defining the cause and the disease extent^[82,83]. CT can demonstrate asymmetric fascial thickening, any coexisting fluid collection or abscess, fat stranding around the involved structures and subcutaneous emphysema. In rectal cancer-induced FG, abdominal CT was performed in 56% of cases. Of these, tumor and air were detected in 61.5%, only air in 7.7% and only tumor in 23%. In 7.7%, no pathology was found. The finding of a rectal tumor does not mean it is the cause of FG. Perforation or infiltration of the rectal tumor is highly probable when increased soft tissue density with abscess and/or gas bubbles is present around the tumor. In 43.5%, the abscess was detected: one retroperitoneal (intraoperative finding), four ischiorectal (one on CT and three intraoperatively), one in the mesorectum (on CT) and one perirectal (intraoperatively). In three cases, the location was not defined.

MRI gives greater soft tissue detail and fistulous tracts than CT^[118] but is mostly unavailable in emergency settings.

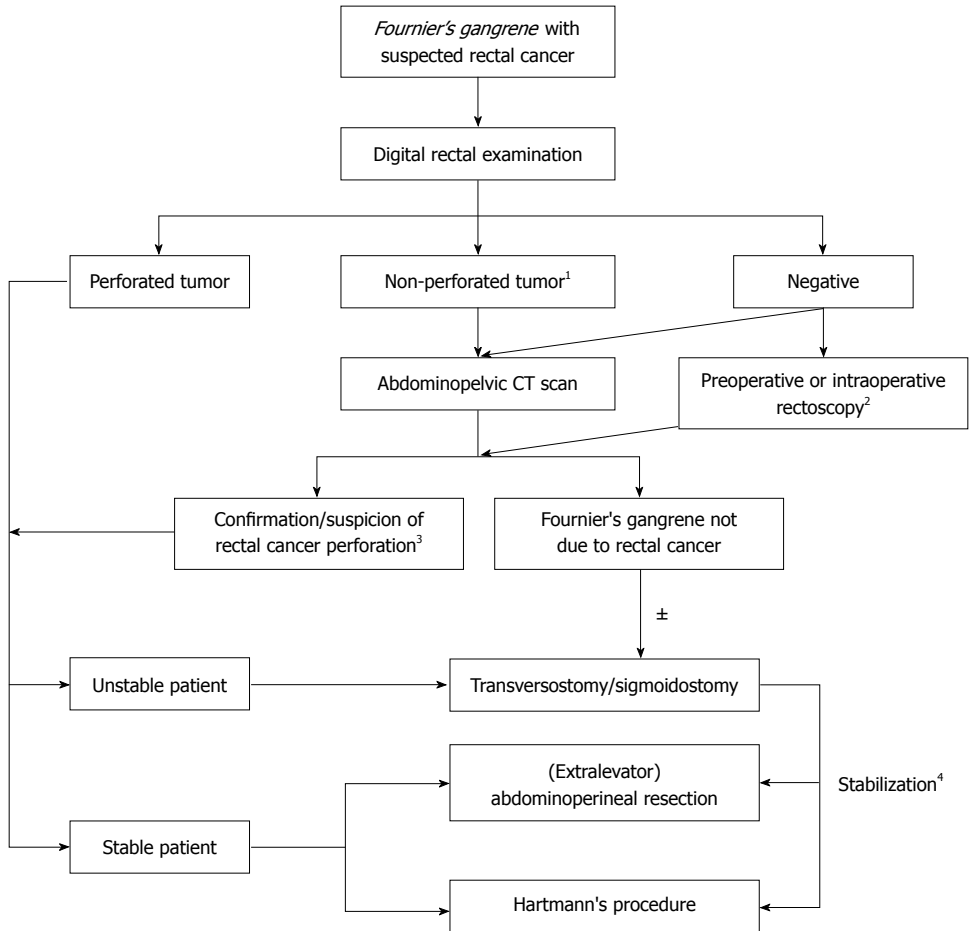


Figure 1 Diagnostic-therapeutic algorithm for suspected/proven Fournier's gangrene due to rectal cancer. Perioperative management and necrosectomy are excluded which are standard procedures in Fournier's gangrene treatment in all patients. ¹Impalpable perforation does not exclude microperforation; ²(1) Blood (any form) on digital rectal examination; (2) history and other/previous diagnostic modalities refer to rectal carcinoma; (3) urogenital and dermatological causes excluded; (4) bacteria highly specific for (intestinal) rectal malignancy such as Clostridium septicum; and (5) fever or sepsis of unknown origin with perianal symptoms/signs; ³Increased soft tissue density with abscess and/or gas bubbles around the tumor; ⁴After confirmation of rectal cancer, definitive oncological operation is performed after stabilization and neoadjuvant chemoradiotherapy if indicated. Reconstructive surgery after consultation with plastic surgeon.

TREATMENT

Proctological examination under general anesthesia identifies the cause of the disease and determines its extent. A proposed diagnostic/therapeutic algorithm for rectal cancer-induced FG is presented in Figure 1.

Rectal cancer treatment modalities

Colostomy: Colostomy has been used for fecal diversion in cases of severe perineal involvement in all-cause FG with: (1) anal sphincter involvement; (2) fecal incontinence; and (3) continuous fecal contamination of the wound's margins.

Rectal diversion decreases the number of germs in the perineal region and improves wound healing. The primary colostomy rate is 16%-17%, whereas the secondary colostomy rate is 35%-40%^[119,120]. In an anorectal female group, colostomy rate was 83.7%, with a primary colostomy in 37.5% and a secondary colostomy in 50%^[29]. Colostomy rate in the anorectal group varies from 50% to 100% (only four articles have adequate data) (Table 1).

A transverse loop colostomy is preferred because it yields solid and formed stools with little contamination of the surrounding skin. The abdomen above the umbilicus is ideal because FG often extends into the lower abdominal wall^[121]. Necrosis around the stoma causes stomal detachment necessitating stomal translocation. In addition, colostomy should not be brought through the rectus muscle until the plastic surgery team has selected the possible reconstructive option. Most commonly, the vertical rectus abdominis myocutaneous flap (VRAM) with skin from the supraumbilical area provides excellent soft tissue bulk to obliterate perineal dead space^[122-124]. Stool and urinary diversion ostomies can be brought out through one rectus muscle only after elevation of the contralateral VRAM^[125].

Colostomy, as the only (mentioned) treatment of rectal cancer-induced FG, was performed in 43% of cases, with mortality of 20%. Three important parameters from published articles are not known: (1) rectal cancer operability and whether the colostomy was definitive surgical treatment; (2) long-term follow-

up and therefore additional procedures that could be performed at later date are unknown; and (3) the location of the colostomy.

The therapeutic algorithm is not defined if rectal cancer infiltrates the prostate. Should colostomy be made first, followed by chemoradiotherapy and as a final act abdominoperineal resection (APR)^[50], or should the APR be made as the first and definitive operation? If a patient presents with multiple bilobar liver metastases colostomy could be the first line therapy.

Rectal diversion device(s): The Flexi-Seal[®] Fecal Management System by Convatec is a silicone catheter that protects the wounds from fecal contamination. It is an excellent alternative to colostomy for a shorter period (several weeks). The device avoids complications related to stomas, including better psychological recovery, and may have an economic benefit. Unfortunately, recommendations from the manufacturer contraindicate its use when (perforated) rectal cancer with FG or any anorectal cause with FG is present^[126]. On the contrary, Ozkan *et al.*^[32] recommended its use in FG with excellent results.

Rectal cancer resection: Rectal carcinoma is different from most other, even anorectal, causes of FG because elimination of systemic risk factors and purulent collection(s) does not eliminate the source of infection. Perforation of rectal cancer *per se* produces infection; therefore, resection of the perforated rectal tumor is mandatory (see Prognosis). If the tumor did not perforate, other causes should be ruled out. In this situation, initial resection of the rectal cancer is not mandatory. The most experienced surgeon available should perform the operation.

Localization of rectal cancer was described as the lower or upper rectum (imprecise localization) in 13% and distance from the anocutaneous line was noted in 30%, ranging from the anocutaneous line to 10 cm (Table 3). APR as the initial operation was performed in 13% of cases; colostomy as an initial procedure with delayed APR in 26% of cases (Table 3). The latter option could be for the patients with poor operative risk, presence of the septicemia, old age or hemodynamically unstable patients. These factors eliminate the possibility of an aggressive approach and at the first instance, necrotic and infected tissue is removed and major surgery postponed until the patient's condition improves^[46]. There are two advantages to this approach: (1) subsequent colonoscopy with pathohistological diagnosis of the rectal tumor; and (2) detection of synchronous colorectal tumors, eliminating the need for subsequent resections. Unfortunately, when rectal cancer-induced FG is present, a delay of up to 7 d is intolerable due to the rapid progression of FG and the need for rapid elimination of the infective source. The patients should

be warned about possibility of permanent stoma.

In high rectal cancers, the dilemma is whether to do anterior rectal resection, Hartmann's procedure or APR. Hartmann's procedure adds safety due to fecal diversion and was performed in 8.7% of cases as primary treatment (Table 3). The problem could be the revascularization of the rectal stump due to extensive debridement of the perirectal area. Therefore, even in high rectal cancer associated with FG, APR has the advantage of eliminating all infective focuses in the perineal/perianal region. The perineum is not closed primarily but packed with several gauze rolls. When the spread of FG is stopped and the hemostasis is achieved with packs, then vacuum assisted closure (VAC) minimizes skin defects and speeds tissue healing. The location of the perineal wound makes it difficult to maintain an adequate seal due to the irregular surfaces surrounding the gluteal folds and perineum. Enemas could be applied before changing the VAC dressings in patients without a diverting colostomy. VAC dressings are changed every 72 h or when the progression of gangrene is found. Ozkan *et al.*^[32] recommend a lower limit of pressure (without explanation) which was originally recommended to be between 50 and 125 mmHg.

Currently, extralevator APR (eAPR) is recommended for elective low rectal cancers^[127]. It consists of wider excisions with *en bloc* resection of the distal rectum, sphincter complex and levator muscles, resulting in a cylindrical specimen. This reduces the rate of positive resection margins and tumor perforation in distal rectal cancer and improves oncological outcome, especially in perforated forms, as in FG. Wider excisions and increased use of neoadjuvant chemoradiotherapy have significantly increased perineal wound healing problems, in up to 59%^[128,129]. Furthermore, perineal hernia is more likely - found in up to 20%^[130]. Clinical outcome of biological meshes during eAPR appeared comparable to flap assisted perineal closure in a non-randomized studies based on a systematic review^[131]. Perineal hernias after biological mesh closure following eAPR were 8.2%^[130,132-135]. One of the assumptions for successful use in FG is that gangrene (mostly) does not affect muscles; therefore, mesh can be securely sutured to the muscles surrounding the defect after eAPR. The unsolved issue is the timing of application of biological mesh in FG patients.

Extensive debridement

Current estimates of all-cause FG mortality are 21% (range 7% to 75%), similar to 22% mortality from the pre-antibiotic era^[136]. This suggests that initial therapy needs to be more aggressive and the first operation more extensive and definite. This also suggests that antibiotic therapy is not the main therapy. If in doubt, cut it out is a truism in FG^[61]. Intraoperative lack of resistance of normally adherent fascia to blunt dissection is confirmation of NF^[7,114]. Debridement

should be stopped when the separation of the skin and the subcutaneous tissue is not performed easily because the cutaneous necrosis is not a good marker. Surgical reexamination of the infected area and detachment of the necrotic tissue is advocated within 24 h and should be carried out repeatedly. In all-cause FG, an average of 3.5 procedures is required^[137]. Most studies on anorectal etiology declare multiple procedures without absolute numbers. This is also true for rectal cancer-induced FG (Table 3). Duration of hospitalization is unknown for the anorectal group. Duration of hospitalization for the rectal cancer-induced FG was noted in 30% of cases, with a range of 23-130 (average 47) d.

The crucial significance of testicular infarction, implying thrombosis of the testicular artery, must be recognized as an absolute indication for laparotomy and retroperitoneal exploration. The posterior peritoneum may need to be incised before necrotic retroperitoneal tissues are exposed.

Hemorrhage or perioperative blood loss is inevitable due to: (1) extensive debridement; (2) possible DIC; and (3) rectal resection. In addition, microcytic anemia can be present preoperatively due to a bleeding rectal tumor.

Antibiotic therapy

The optimal approach to empiric antibiotic therapy for FG is uncertain; data are limited since most clinical trials exclude FG patients. The optimal duration of antibiotic treatment has not been defined. Antibiotics should be continued until no further debridements are needed and the patient's hemodynamic status and temperature has normalized; this duration must be tailored to individual patient circumstances or laboratory parameters such as leukocyte count or CRP level. High intravenous doses should be used. Antibiotics should be adjusted to culture results. Most common initial (empiric) combinations used for all-cause FG are: (1) penicillin G or ampicillin, aminoglycoside or 3rd generation cephalosporin plus metronidazole or clindamycin^[138]; (2) benzylpenicillin plus clindamycin plus gentamicin. If penicillin-allergic, meropenem plus clindamycin plus gentamicin. Review the need for gentamicin daily^[139]; (3) meropenem plus clindamycin^[140]; (4) clindamycin plus ciprofloxacin plus metronidazole^[141]; and (5) for suspected *Vibrio* spp. include a tetracycline and 3rd generation cephalosporin (e.g., doxycycline plus ceftazidime), ciprofloxacin may be an alternative^[142,143].

Nutritional support

Due to extensive debridement, physiological changes are similar to extensive and deep burns. Patients with infected wounds or sepsis have increased requirements for nutrients and often have a reduced food intake. Early nutritional support had a significantly shorter duration before split thickness skin grafting than

the conventional support^[144]. The catabolic effect of primary malignancy and/or cachexia could be present.

A nasogastric tube is placed when mechanical ventilation is required and when patients are unable to eat a satisfactory diet. Total parenteral nutrition (TPN) is used only if patients are unable to be fed enterally. Enteral nutrition is provided with high protein formulas. Attempts to estimate nutrient requirements based on any formula will inevitably lead to over- or under-feeding. Indirect calorimetry (IC) remains the most precise method to determine energy requirements. When IC is not available, provide calories at 25 kcal/kg per day or about 124% of estimated basal needs^[145,146]. Energy expenditure should be measured by IC 2-3 times a week. Respiratory therapists measure oxygen consumption, production and resting energy expenditure and respiratory quotient in the early morning before patients began daily activities. Due to their clinical status (*i.e.*, symptoms consistent with sepsis syndrome), patients are generally sedated, intubated and receiving analgesics during IC. Resting energy expenditure is recorded when measurements are stable for at least 10 min. Patients on TEN or TPN had feedings continued at a steady rate throughout each measurement; patients on oral diets are measured before breakfast after an overnight fast.

Adjunctive therapy

Underlying risk factors and metabolic derangements should be corrected. Honey, royal jelly, hyperbaric oxygen therapy, sodium hypochlorite, lyophilized collagenase, growth hormones, protein synthesis inhibitors and intravenous immunoglobulins are all adjunctive methods but without definitive proof of their positive therapeutic effect.

Reconstructive surgery

There are two main timing options for reconstructive surgery: (1) at the time of initial admission^[21]; or (2) after the acute process has fully resolved. Reconstructive surgery is considered when an extensive healthy granulation tissue formation on the wound base is present. Secondary healing or delayed primary closure is applied for small residual defects (< 10 cm²)^[16]. Eventually, testes can be covered with remaining scrotal skin or implanted in the subcutaneous tissue of the thigh or abdomen if viable.

To improve healing of the large perineal wound, sutured perineal pedicled retrocolic omentoplasty can be added to the procedure of APR^[147,148]. The great omentum is pediculated on the left gastroepiploic artery and tightly sewn to the subcutaneous fatty tissue of the perianal skin. Although a high level of evidence is lacking, the procedure adds well vascularized, non-irradiated tissue to the pelvic cavity^[149]. The well-vascularized muscle flap demonstrates greater resistance to bacterial inoculums and in wounds with some degree of contamination^[150]. In the only study

with follow-up of all-cause FG during the first 12 mo after hospital discharge, 12% of patients required inpatient hospital treatment for fistulas and needed revision surgery for new inflammatory processes^[16]. In elective settings, after APR, VRAM and gluteal flap have been used for closure of large perineal defects^[123,151-153]. The problem arises when large areas are debrided, eliminating the possibility for the use of standard flaps. In addition, if adjuvant chemoradiotherapy is indicated, the questions are: (1) should the flaps be used; and (2) the timing of flap application. Also, due to the donor site morbidity, increased operative time and higher costs, it is questionable whether autologous tissue flaps should be applied when VAC and skin grafting is available.

Adjuvant chemoradiotherapy

Due to the extremely small number and emergent presentation, there are no studies and recommendations as to when to start this form of therapy after complex surgical treatment of rectal cancer-induced FG. Only two articles mentioned adjuvant chemoradiotherapy after initial colostomy - an insufficient pool of data for making conclusions^[47,63]. If oncologically indicated, it should be offered when all wounds have healed completely. If flaps were used, consultation with a plastic/reconstructive surgeon is advisable.

PROGNOSIS

All-cause FG

The mortality from all-cause FG has dropped significantly in the last century. In 1871, Jones claimed 46% mortality for all NSTIs. Unfortunately, mortality has changed little since Meleney in 1924 first recognized the need for early surgical intervention^[154]. Currently, the survival rate is in the range of 60% to even 100% (Table 1). Since many studies were conducted on males, the difference in male-female survival is unknown.

There are several issues here. First, mostly all-cause FG survival or mortality is reported. Second, reports are from different decades. Third, the specific underlying cause is not always presented and prognosis could be etiology dependent. Fourth, non-catastrophic soft tissue infections are sometimes defined as FG, declaring a better prognosis falsely. Fifth, when true FG is present, the underlying cause is sometimes not attributed correctly due to the confounding factors^[155].

Poor prognostic factors include age over 60, peripheral vascular disease, poor nutritional status^[1], sepsis^[84], positive blood cultures^[84] and delayed presentation/treatment^[156]. The duration of symptoms is prognostic and none of the patients admitted within 48 hours of symptom onset died^[1,35]. Female pelvic anatomy has been claimed to be better for drainage of secretions through the vagina^[157]. On the other

hand, some suggested that it is a disadvantage related to rapid dissemination of the disease^[158,159]. Other poor prognostic parameters include high serum creatinine, lactate, sodium and calcium or low bicarbonate^[160,161], low magnesium at admission^[162] and renal function impairment on admission^[12,163,164]. Increased serum calcium may be due to renal failure, bacteremia or TPN. Lactate level > 4.0 mmol/L is an independent predictor of mortality^[165]. High neutrophil-lymphocyte ratio and the platelet-lymphocyte ratio values were associated with significant increases in the number of debridements, hospital stay duration, cost and mortality rate^[23]. The influence of diabetes mellitus^[12,25,166-169] on mortality is controversial but the extent to the abdominal wall has been reported to be directly related to mortality^[1,12,170,171]. The involved body surface area (BSA) and the number of debridements did not predict the outcome in some series^[66,167,169]. In contrast, BSA ≥ 15 cm² had a mortality of 75%^[24]. Therefore, this issue remains controversial^[161,163,168,169].

Mean age, race, the prevalence of comorbid conditions and number of debridements were similar in both genders. However, twice as many women required mechanical ventilation and dialysis with longer hospital stay and mortality but without statistical significance^[10]. Table 1 shows the average duration of hospitalization in all-cause FG of 24 d (range 1 to 278 d).

Of all the anaerobic species isolated in all-cause FG, none was present as the sole organism. No differences in clinical course, morbidity or mortality were demonstrated with different bacteria(s) isolated^[172-174].

Prognostic indices for mortality predictions such as Fournier's Gangrene Severity Index (FSGI) are still controversial^[24,175,176]. Many studies show significant mortality with FSGI > 9% and 100% mortality with FSGI > 11^[35,167,177]. Some claim usefulness in predicting survival but not the length of hospital stay^[137]. Of the nine parameters of FSGI, temperature, heart rate and respiratory rate were considered to be the most important^[1]. APACHE II score correlated with the prognosis with a significant increase in mortality with a score over 25^[178]. Other indices include age-adjusted Charlson Comorbidity Index (ACCI)^[179] and the surgical Apgar Score (sAPGAR)^[180], which are easily calculated at the bedside but the prognostic power is controversial^[181].

Anorectal causes of FG

The disease usually behaves more aggressively, produces severe systemic toxicity and is associated with higher mortality than FG from other causes^[68,94,156,182]. The survival of female patients is 71%^[29]. Survival varied from 0% to 85.7% and was presented in only four articles (Table 1). The real incidence and prognosis of any specific cause cannot be calculated from the available data.

One of the inaccuracies with previously mentioned indices is that these do not evaluate the influence

of the underlying cause on prognosis, duration of hospitalization, number of debridements or other parameters. It was previously stated that different primary locations and causes (could) have different prognoses. Yilmazlar *et al.*^[183] modified FGSI, adding the dissemination score (plus age), making the Uludag FSGI (UFGSI) for all-cause FG.

Rectal cancer-induced FG

Rectal cancers that spontaneously perforate without the development of FG seem to be much more aggressive than rectal cancer in general as a significantly larger proportion of these patients have metastatic disease at the time of diagnosis (64% vs 29%). Survival in patients with locally contained perforated rectal cancer is very much dependent on the presence of metastatic disease. In the absence of the latter, if a wide margin clear of all macroscopic tumor is achieved, the survival curve approximates that of patients with a non-perforated tumor^[184].

Duration of hospitalization cannot be obtained for disease-specific or even etiology group-specific FG (Table 1). Duration of hospitalization of rectal cancer-induced FG ranges from 23-130 d. Unfortunately, only 30% of cases have these data (Table 3). None of the articles presented BSA and correlation with survival could not be made (Table 3).

FSGI was calculated in only one of 23 rectal cancer-induced FG cases and no other scoring systems were used or have data for calculations (Table 3). The overall prognosis is as follows: survival 74%, mortality 13% and for 13% there was no data (Table 3).

There are many limitations in these studies for final conclusions. First, long-term follow-up is lacking. Therefore, only prognosis of FG (due to rectal cancer), not the prognosis of rectal cancer itself after surviving FG, is known. Long-term survival is unknown because less than 50% of surviving patients had follow-up for one year or more (Table 3). Second, prognostic comparison between T4 rectal cancer, perforated rectal cancer and rectal cancer-induced FG groups considering long-term survival cannot be made. The presumption is that the prognosis of rectal cancer-induced FG could be worse due to: (1) significant delay in starting adjuvant chemoradiotherapy in survivors; and (2) inflammation due to perforation of rectal cancer aids in spreading or promoting cancer cell dissemination. Third, analysis of the influence of the type of surgical procedure is insufficient due to the rarity of this pathology and (potentially) low rate of published cases that did not survive any form of surgical treatment. In the group that underwent APR, whether as an initial operation (13%) or delayed after colostomy (26%), survival was 100%. Hartmann's procedure as the initial operation was performed in 8.7% with the survival of 100% (Table 3). On the contrary, the survival with only a loop colostomy was 80% (Table 3). Conclusions cannot be drawn because there is no possibility of comparison.

Therefore, patients with the more advanced disease, poor general status, older age or hemodynamic instability could be offered only colostomy. Finally, it is important to emphasize that all patients that underwent rectal cancer resection survived.

REFERENCES

- 1 **Yeniyoğlu CO**, Suelozgen T, Arslan M, Ayder AR. Fournier's gangrene: experience with 25 patients and use of Fournier's gangrene severity index score. *Urology* 2004; **64**: 218-222 [PMID: 15302463 DOI: 10.1016/j.urology.2004.03.049]
- 2 **Nathan B**. Fournier's gangrene: a historical vignette. *Can J Surg* 1998; **41**: 72 [PMID: 9492752]
- 3 **Smith GL**, Bunker CB, Dinneen MD. Fournier's gangrene. *Br J Urol* 1998; **81**: 347-355 [PMID: 9523650]
- 4 **Jones J**. Investigation upon the nature, causes, and treatment of hospital gangrene as prevailed in the Confederate armies 1861-1865. In: *Surgical Memoirs of the War of the Rebellion*. New York: Riverside Press, 1871: pp 143
- 5 **Wilson B**. Necrotizing fasciitis. *Am Surg* 1952; **18**: 416-431 [PMID: 14915014]
- 6 **Ustin JS**, Malangoni MA. Necrotizing soft-tissue infections. *Crit Care Med* 2011; **39**: 2156-2162 [PMID: 21532474 DOI: 10.1097/CCM.0b013e31821cb246]
- 7 **Chelsom J**, Halstensen A, Haga T, Høiby EA. Necrotising fasciitis due to group A streptococci in western Norway: incidence and clinical features. *Lancet* 1994; **344**: 1111-1115 [PMID: 7934492]
- 8 **Gu GL**, Wang L, Wei XM, Li M, Zhang J. Necrotizing fasciitis secondary to enterocutaneous fistula: three case reports. *World J Gastroenterol* 2014; **20**: 7988-7992 [PMID: 24976737 DOI: 10.3748/wjg.v20.i24.7988]
- 9 **Eke N**. Fournier's gangrene: a review of 1726 cases. *Br J Surg* 2000; **87**: 718-728 [PMID: 10848848 DOI: 10.1046/j.1365-2168.2000.01497.x]
- 10 **Sorensen MD**, Krieger JN, Rivara FP, Broghammer JA, Klein MB, Mack CD, Wessells H. Fournier's Gangrene: population based epidemiology and outcomes. *J Urol* 2009; **181**: 2120-2126 [PMID: 19286224 DOI: 10.1016/j.juro.2009.01.034]
- 11 **Ugwumba FO**, Nnabugwu II, Ozoemena OF. Fournier's gangrene -- analysis of management and outcome in south-eastern Nigeria. *S Afr J Surg* 2012; **50**: 16-19 [PMID: 22353315]
- 12 **Benjelloun el B**, Souiki T, Yakla N, Ousadden A, Mazza K, Louchi A, Kanjaa N, Taleb KA. Fournier's gangrene: our experience with 50 patients and analysis of factors affecting mortality. *World J Emerg Surg* 2013; **8**: 13 [PMID: 23547796 DOI: 10.1186/1749-7922-8-13]
- 13 **Bhatnagar AM**, Mohite PN, Suthar M. Fournier's gangrene: a review of 110 cases for aetiology, predisposing conditions, microorganisms, and modalities for coverage of necrosed scrotum with bare testes. *N Z Med J* 2008; **121**: 46-56 [PMID: 18551153]
- 14 **Cakmak A**, Genç V, Akyol C, Kayaoğlu HA, Hazinedaroğlu SM. Fournier's gangrene: is it scrotal gangrene? *Adv Ther* 2008; **25**: 1065-1074 [PMID: 18821069 DOI: 10.1007/s12325-008-0103-1]
- 15 **Carroll PR**, Cattolica EV, Turzan CW, McAninch JW. Necrotizing soft-tissue infections of the perineum and genitalia. Etiology and early reconstruction. *West J Med* 1986; **144**: 174-178 [PMID: 3953086]
- 16 **Czymek R**, Hildebrand P, Kleemann M, Roblick U, Hoffmann M, Jungbluth T, Bürk C, Bruch HP, Kujath P. New insights into the epidemiology and etiology of Fournier's gangrene: a review of 33 patients. *Infection* 2009; **37**: 306-312 [PMID: 19629386 DOI: 10.1007/s15010-008-8169-x]
- 17 **Efem SE**. The features and aetiology of Fournier's gangrene. *Postgrad Med J* 1994; **70**: 568-571 [PMID: 7937450]
- 18 **Eskitaşcıoğlu T**, Özyazgan I, Coruh A, Günay GK, Altıparmak M, Yontar Y, Doğan F. Experience of 80 cases with Fournier's gangrene and "trauma" as a trigger factor in the etiopathogenesis. *Ulus Travma Acil Cerrahi Derg* 2014; **20**: 265-274 [PMID: 24976737 DOI: 10.3748/wjg.v20.i24.7988]

- 25135021]
- 19 **Fajdic J**, Bukovic D, Hrgovic Z, Habek M, Gugic D, Jonas D, Fassbender WJ. Management of Fournier's gangrene--report of 7 cases and review of the literature. *Eur J Med Res* 2007; **12**: 169-172 [PMID: 17509961]
 - 20 **Ghnam WM**. Fournier's gangrene in Mansoura Egypt: a review of 74 cases. *J Postgrad Med* 2008; **54**: 106-109 [PMID: 18480526]
 - 21 **Rodríguez Hermosa JI**, Codina Cazador A, García Oria MJ, Pont Vallés J, Rodríguez Higuera MI, Codina Barreras A, Roig García J, Gironès Vilà J, Farrés Coll R, Tuca Rodríguez F. Gangrena de Fournier. *Cir Esp* 2001; **69**: 128-135
 - 22 **Jiménez-Pacheco A**, Arrabal-Polo MÁ, Arias-Santiago S, Arrabal-Martín M, Noguera-Ocaña M, Zuluaga-Gómez A. Fournier gangrene: description of 37 cases and analysis of associated health care costs. *Actas Dermosifiliogr* 2012; **103**: 29-35 [PMID: 22445562 DOI: 10.1016/j.adengl.2011.04.007]
 - 23 **Kahramanca S**, Kaya O, Ozgehan G, Irem B, Dural I, Küçükpınar T, Kargıcı H. Are neutrophil-lymphocyte ratio and platelet-lymphocyte ratio as effective as Fournier's gangrene severity index for predicting the number of debridements in Fournier's gangrene? *Ulus Travma Acil Cerrahi Derg* 2014; **20**: 107-112 [PMID: 24740336]
 - 24 **Kara E**, Müezzinoğlu T, Temeltas G, Dinçer L, Kaya Y, Sakarya A, Coskun T. Evaluation of risk factors and severity of a life threatening surgical emergency: Fournier's gangrene (a report of 15 cases). *Acta Chir Belg* 2009; **109**: 191-197 [PMID: 19499680]
 - 25 **Karbhari SS**, Kriplani A, Devani RG. Prognostic factors in Fournier's gangrene. *J Evol Med Dent Sci* 2014; **3**: 9398-9405 [DOI: 10.14260/jemds/2014/3212]
 - 26 **Khan I**. Experience in Management of Fournier's Gangrene: A Review of 19 Cases. *Gomal J Med Sci* 2009; **7**: 65-67
 - 27 **Khandelwal R**. Fournier's Gangrene Severity Index as a Predictor of Outcome in Patients with Fournier's Gangrene: A Prospective Clinical Study at a Tertiary Care Center. *J Young Med Res* 2013; **1**: 1 [DOI: 10.7869/jymr.2]
 - 28 **Korkut M**, İçöz G, Dayangaç M, Akgün E, Yeniay L, Erdoğan O, Cal C. Outcome analysis in patients with Fournier's gangrene: report of 45 cases. *Dis Colon Rectum* 2003; **46**: 649-652 [PMID: 12792442 DOI: 10.1097/01.DCR.0000059329.29085.E9]
 - 29 **Liang SG**, Chen HH, Lin SE, Chang CL, Lu CC, Hu WH. Fournier's gangrene in female patients. *J Soc Colon Rectal Surg Taiwan* 2008; **19**: 57-61
 - 30 **Morua AG**, Lopez JA, Garcia JD, Montelongo RM, Guerra LS. Fournier's gangrene: our experience in 5 years, bibliographic review and assessment of the Fournier's gangrene severity index. *Arch Esp Urol* 2009; **62**: 532-540 [PMID: 19815967]
 - 31 **Oymaci E**, Coşkun A, Yakan S, Erkan N, Uçar AD, Yıldırım M. Evaluation of factors affecting mortality in Fournier's Gangrene: Retrospective clinical study of sixteen cases. *Ulus Cerrahi Derg* 2014; **30**: 85-89 [PMID: 25931901 DOI: 10.5152/UCD.2014.2512]
 - 32 **Ozkan OF**, Koksall N, Altinli E, Celik A, Uzun MA, Cıkman O, Akbas A, Ergun E, Kiraz HA, Karaayvaz M. Fournier's gangrene current approaches. *Int Wound J* 2014; Epub ahead of print [PMID: 25145578 DOI: 10.1111/iwj.12357]
 - 33 **Singh G**, Chawla S. Aggressiveness - The key to a successful outcome in Fournier's gangrene. *Med J Armed Forces India* 2004; **60**: 142-145 [DOI: 10.1016/S0377-1237(04)80105-9]
 - 34 **Tan Ö**, Atik B, Ergen D. Fournier gangreni'nde rekonstrüfif aklaşımlarımız: 27 hastada retrospektif bir çalışma. *Türk Plast Rekonstrüktif Ve Estet Cerrahi Derg Turk Plast Surg* 2006; **15**: 1-7
 - 35 **Unalp HR**, Kamer E, Derici H, Atahan K, Balci U, Demirdoven C, Nazli O, Onal MA. Fournier's gangrene: evaluation of 68 patients and analysis of prognostic variables. *J Postgrad Med* 2008; **54**: 102-105 [PMID: 18480525]
 - 36 **Villanueva-Sáenz E**, Martínez Hernández-Magro P, Valdés Ovalle M, Montes Vega J, Alvarez-Tostado F JF. Experience in management of Fournier's gangrene. *Tech Coloproctol* 2002; **6**: 5-10; discussion 11-3 [PMID: 12077634 DOI: 10.1007/s101510200001]
 - 37 **Walker M**, Hall M. Necrotizing fasciitis: the Howard University Hospital experience. *J Natl Med Assoc* 1983; **75**: 159-163 [PMID: 6827608]
 - 38 **Wang L**, Han X, Liu M, Ma Y, Li B, Pan F, Li W, Wang L, Yang X, Chen Z, Zeng F. Experience in management of Fournier's gangrene: a report of 24 cases. *J Huazhong Univ Sci Technolog Med Sci* 2012; **32**: 719-723 [PMID: 23073803 DOI: 10.1007/s11596-012-1024-4]
 - 39 **Kousoulis AA**, Economopoulos KP, Hatzinger M, Eshraghian A, Tsiodras S. The fatal disease of Emperor Galerius. *J Am Coll Surg* 2012; **215**: 890-893 [PMID: 22863796 DOI: 10.1016/j.jamcollsurg.2012.05.039]
 - 40 **Jemal A**, Siegel R, Ward E, Hao Y, Xu J, Murray T, Thun MJ. Cancer statistics, 2008. *CA Cancer J Clin* 2008; **58**: 71-96 [PMID: 18287387 DOI: 10.3322/CA.2007.0010]
 - 41 **Ash L**, Hale J. CT findings of perforated rectal carcinoma presenting as Fournier's gangrene in the emergency department. *Emerg Radiol* 2005; **11**: 295-297 [PMID: 16133625 DOI: 10.1007/s10140-005-0417-0]
 - 42 **Carr JA**. Perforated rectal cancer presenting as Fournier's gangrene. *J Clin Oncol* 2010; **28**: e605-e606 [PMID: 20713863 DOI: 10.1200/JCO.2010.29.5394]
 - 43 **Chan CC**, Williams M. Fournier gangrene as a manifestation of undiagnosed metastatic perforated colorectal cancer. *Int Surg* 2013; **98**: 43-48 [PMID: 23438275 DOI: 10.9738/CC168.1]
 - 44 **Eke N**, Onwuchekwa AC. Fournier's gangrene of the penis associated with adenocarcinoma of the rectum and diabetes mellitus, Onwuchekwa, A.C. *Acta Urol Ital* 1999; **13**: 207-209
 - 45 **Gamagami RA**, Mostafavi M, Gamagami A, Lazorthes F. Fournier's gangrene: an unusual presentation for rectal carcinoma. *Am J Gastroenterol* 1998; **93**: 657-658 [PMID: 9576470 DOI: 10.1111/j.1572-0241.1998.189_b.x]
 - 46 **Gupta PJ**. Rectal cancer presenting as ischio-rectal abscess and Fournier's gangrene--a case report. *Eur Rev Med Pharmacol Sci* 2010; **14**: 139-140 [PMID: 20329573]
 - 47 **Highton L**, Clover J, Critchley P. Necrotising fasciitis of the thigh secondary to a perforated rectal cancer. *J Plast Reconstr Aesthet Surg* 2009; **62**: e17-e19 [PMID: 18316255 DOI: 10.1016/j.bjps.2007.08.031]
 - 48 **Katusić J**, Stimac G, Benko G, Grubišić I, Soipić S, Dimanovski J. Management of Fournier's gangrene: case report and literature review. *Acta Clin Croat* 2010; **49**: 453-457 [PMID: 21830457]
 - 49 **Khalil H**, Tsilividis B, Schwarz L, Scotté M. Necrotizing fasciitis of the thigh should raise suspicion of a rectal cancer. *J Visc Surg* 2010; **147**: e187-e189 [PMID: 20708997 DOI: 10.1016/j.jvisurg.2010.07.003]
 - 50 **Kojima Y**, Kamano T, Sakamoto K, Matsuda M, Sengoku H, Takita N, Yaginuma Y, Nonaka E, Kitamura D, Ono S. A Case of Fournier's Gangrene caused by Perforation of Rectal Carcinoma. *Jpn J Gastroenterol Surg* 2007; **40**: 485-490
 - 51 **Lamy A**, Tissot B, Pigot F. [Perineal necrotizing cellulitis disclosing rectal adenocarcinoma]. *Ann Chir* 2003; **128**: 630-632 [PMID: 14659620]
 - 52 **Lawrentschuk N**, Young AB, Nguyen H. Necrotizing fasciitis: an unusual presentation for rectal carcinoma. *ANZ J Surg* 2003; **73**: 865-867 [PMID: 14525587]
 - 53 **Liu SY**, Ng SS, Lee JF. Multi-limb necrotizing fasciitis in a patient with rectal cancer. *World J Gastroenterol* 2006; **12**: 5256-5258 [PMID: 16937546]
 - 54 **McMullin NR**, Gering S, Levoyer T. Necrotizing Fournier's gangrene from a perforated rectal carcinoma. *Surg Rounds* 2006; **29**: 275
 - 55 **Moslemi MK**, Sadighi Gilani MA, Moslemi AA, Arabshahi A. Fournier gangrene presenting in a patient with undiagnosed rectal adenocarcinoma: a case report. *Cases J* 2009; **2**: 9136 [PMID: 20062653 DOI: 10.1186/1757-1626-2-9136]
 - 56 **Mulholland CK**, Diamond T, Ritchie A, Harvey C, Hanna WA. Fournier's gangrene: two unusual cases. *Ulster Med J* 1990; **59**: 90-92 [PMID: 2349756]
 - 57 **O'Connor H**, Nusrat N, Jaffry S. Fournier's Gangrene, an unusual presentation of a rectal tumour! *Scott Med J* 2009; **54**: 59-59 [DOI: 10.1258/rsmsmj.54.4.59d]
 - 58 **Öner OZ**, Karakaş BR, Demirci RK, Öngen NA, Habibi M, Bülbüller N. Two staged surgical treatment of a low rectal tumor

- presented with Fournier's gangrene: A case report. *Int J Case Rep Images* 2013; **5**: 270-274
- 59 **Rajendran S**, Khan A, Murphy M, O'Hanlon D. Rectocutaneous fistula with Fournier's gangrene, a rare presentation of rectal cancer. *BMJ Case Rep* 2011; **2011**: [PMID: 22689729 DOI: 10.1136/bcr.06.2011.4372]
- 60 **Villa Sánchez LM**, Cuervo Maldonado SI, Gómez Rincón JC, Rolón Cadena MC. Infección necrosante de tejidos blandos y neoplasia gastrointestinal. *Infectio* 2014; **18**: 28-33 [DOI: 10.1016/S0123-9392(14)70737-4]
- 61 **Scott SD**, Dawes RF, Tate JJ, Royle GT, Karran SJ. The practical management of Fournier's gangrene. *Ann R Coll Surg Engl* 1988; **70**: 16-20 [PMID: 3408131]
- 62 **Tai HCH**, Yao CT, Chen WL, Chen JH, Shen YS. Necrotizing fasciitis as an initial manifestation of perforated rectal cancer in a young man. *J Acute Med* 2012; **2**: 62-64 [DOI: 10.1016/j.jacme.2012.05.003]
- 63 **Woodcock N**, Sebag-Montefiore D, Mannion R, Alexander D, Miller G. Necrotising fasciitis secondary to locally advanced rectal cancer. *Ann R Coll Surg Engl* 2006; **88**: W7-9 [DOI: 10.1308/147870806X95249]
- 64 **Hurtado Santos J**, Corella Monzón I, Valenzuela Sarriá A, Laguna Cuesta F, Turrión Sanz F, Fernández Guerrero M, Arnal Arambillet P. [Synergistic bacterial cellulitis secondary to carcinoma of the rectum. Presentation of a case]. *Rev Clin Esp* 1982; **167**: 185-188 [PMID: 7163555]
- 65 **Paty R**, Smith AD. Gangrene and Fournier's gangrene. *Urol Clin North Am* 1992; **19**: 149-162 [PMID: 1736475]
- 66 **Spirnak JP**, Resnick MI, Hampel N, Persky L. Fournier's gangrene: report of 20 patients. *J Urol* 1984; **131**: 289-291 [PMID: 6699959]
- 67 **Stephens BJ**, Lathrop JC, Rice WT, Gruenberg JC. Fournier's gangrene: historic (1764-1978) versus contemporary (1979-1988) differences in etiology and clinical importance. *Am Surg* 1993; **59**: 149-154 [PMID: 8476151]
- 68 **Baskin LS**, Carroll PR, Cattolica EV, McAninch JW. Necrotising soft tissue infections of the perineum and genitalia. Bacteriology, treatment and risk assessment. *Br J Urol* 1990; **65**: 524-529 [PMID: 2354320]
- 69 **Hsu C**, King T, Wang J, Wang H. Colorectal perforation: spectrum of the disease and its mortality. *J Soc Colon Rectal Surg Taiwan* 2007; **81**: 88
- 70 **Welch JP**, Donaldson GA. Perforative carcinoma of colon and rectum. *Ann Surg* 1974; **180**: 734-740 [PMID: 4423043]
- 71 **Wood CD**. Acute perforations of the colon. *Dis Colon Rectum* 1977; **20**: 126-129 [PMID: 844396]
- 72 **Tol J**, Cats A, Mol L, Koopman M, Bos MM, van der Hoeven JJ, Antonini NF, van Krieken JH, Punt CJ. Gastrointestinal ulceration as a possible side effect of bevacizumab which may herald perforation. *Invest New Drugs* 2008; **26**: 393-397 [PMID: 18335169 DOI: 10.1007/s10637-008-9125-4]
- 73 **Shimizu J**, Kinoshita T, Tatsuzawa Y, Takehara A, Kawaura Y, Takahashi S. Gluteal abscess caused by perforating rectal cancer: case report and review of the literature. *Tumori* 2001; **87**: 330-331 [PMID: 11765183]
- 74 **Lee J**, Chen F, Steel M, Keck J, Mackay J. Perforated rectal cancer associated with neoadjuvant radiotherapy: report of four cases. *Dis Colon Rectum* 2006; **49**: 1629-1632 [PMID: 17039387 DOI: 10.1007/s10350-006-0687-y]
- 75 **Badgwell BD**, Camp ER, Feig B, Wolff RA, Eng C, Ellis LM, Cormier JN. Management of bevacizumab-associated bowel perforation: a case series and review of the literature. *Ann Oncol* 2008; **19**: 577-582 [PMID: 18024857 DOI: 10.1093/annonc/mdm508]
- 76 **Hurwitz H**, Fehrenbacher L, Novotny W, Cartwright T, Hainsworth J, Heim W, Berlin J, Baron A, Griffing S, Holmgren E, Ferrara N, Fyfe G, Rogers B, Ross R, Kabbinavar F. Bevacizumab plus irinotecan, fluorouracil, and leucovorin for metastatic colorectal cancer. *N Engl J Med* 2004; **350**: 2335-2342 [PMID: 15175435 DOI: 10.1056/NEJMoa032691]
- 77 **Bjornson HS**, Hill EO. Bacteroidaceae in thromboembolic disease: effects of cell wall components on blood coagulation in vivo and in vitro. *Infect Immun* 1973; **8**: 911-918 [PMID: 4594118]
- 78 **Fearon DT**, Austen KF. Current concepts in immunology: the alternative pathway of complement--a system for host resistance to microbial infection. *N Engl J Med* 1980; **303**: 259-263 [PMID: 6900901 DOI: 10.1056/NEJM198007313030505]
- 79 **Ingham HR**, Sisson PR, Tharagotnet D, Selkon JB, Codd AA. Inhibition of phagocytosis in vitro by obligate anaerobes. *Lancet* 1977; **2**: 1252-1254 [PMID: 73952]
- 80 **Goyette M**. Group A streptococcal necrotizing fasciitis Fournier's gangrene--Quebec. *Can Commun Dis Rep* 1997; **23**: 101-103 [PMID: 9509640]
- 81 **Yang SC**, Wu TJ. Fournier's gangrene--Taiwan experience. *Zhonghua Yi Xue Zazhi (Taipei)* 2001; **64**: 239-243 [PMID: 11458762]
- 82 **Amendola MA**, Casillas J, Joseph R, Antun R, Galindez O. Fournier's gangrene: CT findings. *Abdom Imaging* 1994; **19**: 471-474 [PMID: 7950832]
- 83 **Rajan DK**, Scharer KA. Radiology of Fournier's gangrene. *AJR Am J Roentgenol* 1998; **170**: 163-168 [PMID: 9423625 DOI: 10.2214/ajr.170.1.9423625]
- 84 **Benizri E**, Fabiani P, Migliori G, Chevallier D, Peyrottes A, Raucoules M, Amiel J, Mouiel J, Toubol J. Gangrene of the perineum. *Urology* 1996; **47**: 935-939 [PMID: 8677598 DOI: 10.1016/S0090-4295(96)00058-1]
- 85 **Yaghan RJ**, Al-Jaberi TM, Bani-Hani I. Fournier's gangrene: changing face of the disease. *Dis Colon Rectum* 2000; **43**: 1300-1308 [PMID: 11005502]
- 86 **de Feiter PW**, Soeters PB, Dejong CH. Rectal perforations after barium enema: a review. *Dis Colon Rectum* 2006; **49**: 261-271 [PMID: 16328608 DOI: 10.1007/s10350-005-0225-3]
- 87 **Fry RD**, Shemesh EI, Kodner IJ, Fleshman JW, Timmcke AE. Perforation of the rectum and sigmoid colon during barium-enema examination. Management and prevention. *Dis Colon Rectum* 1989; **32**: 759-764 [PMID: 2758944]
- 88 **Katz R**, Borkowski T, Hoznek A, Salomon L, de la Taille A, Abbou CC. Operative management of rectal injuries during laparoscopic radical prostatectomy. *Urology* 2003; **62**: 310-313 [PMID: 12893341]
- 89 **Gupta A**, Dalela D, Sankhwar SN, Goel MM, Kumar S, Goel A, Singh V. Bilateral testicular gangrene: does it occur in Fournier's gangrene? *Int Urol Nephrol* 2007; **39**: 913-915 [PMID: 17323114 DOI: 10.1007/s11255-006-9126-1]
- 90 **Cameron JL**. Current Surgical Therapy. 8th ed. Philadelphia: Elsevier Mosby, 2004: 1079-1085
- 91 **Tehrani MA**, Ledingham IM. Necrotizing fasciitis. *Postgrad Med J* 1977; **53**: 237-242 [PMID: 876929]
- 92 **Uppot RN**, Levy HM, Patel PH. Case 54: Fournier gangrene. *Radiology* 2003; **226**: 115-117 [PMID: 12511678 DOI: 10.1148/radiol.2261010714]
- 93 **Kane CJ**, Nash P, McAninch JW. Ultrasonographic appearance of necrotizing gangrene: aid in early diagnosis. *Urology* 1996; **48**: 142-144 [PMID: 8693639]
- 94 **Laucks SS**. Fournier's gangrene. *Surg Clin North Am* 1994; **74**: 1339-1352 [PMID: 7985069]
- 95 **Cavalini F**, Moriya TM, Pelá NT. [Fournier syndrome: the perception of the patient]. *Rev Esc Enferm USP* 2002; **36**: 108-114 [PMID: 12599733]
- 96 **Carvalho JP**, Hazan A, Cavalcanti AG, Favorito LA. Relation between the area affected by Fournier's gangrene and the type of reconstructive surgery used. A study with 80 patients. *Int Braz J Urol* 2007; **33**: 510-514 [PMID: 17767755]
- 97 **Roje Z**, Roje Z, Matic D, Librenjak D, Dokuzovic S, Varvodic J. Necrotizing fasciitis: literature review of contemporary strategies for diagnosing and management with three case reports: torso, abdominal wall, upper and lower limbs. *World J Emerg Surg* 2011; **6**: 46 [PMID: 22196774 DOI: 10.1186/1749-7922-6-46]
- 98 **Stone HH**, Martin JD. Synergistic necrotizing cellulitis. *Ann Surg* 1972; **175**: 702-711 [PMID: 4555030]

- 99 **Anaya DA**, Dellinger EP. Necrotizing soft-tissue infection: diagnosis and management. *Clin Infect Dis* 2007; **44**: 705-710 [PMID: 17278065 DOI: 10.1086/511638]
- 100 **Buchanan CS**. Necrotizing fasciitis due to group A beta-hemolytic streptococci. *Arch Dermatol* 1970; **101**: 664-668 [PMID: 5424482]
- 101 **Barker FG**, Leppard BJ, Seal DV. Streptococcal necrotizing fasciitis: comparison between histological and clinical features. *J Clin Pathol* 1987; **40**: 335-341 [PMID: 3558868]
- 102 **Janevicius RV**, Hann SE, Batt MD. Necrotizing fasciitis. *Surg Gynecol Obstet* 1982; **154**: 97-102 [PMID: 7031943]
- 103 **Frezza EE**, Atlas I. Minimal debridement in the treatment of Fournier's gangrene. *Am Surg* 1999; **65**: 1031-1034 [PMID: 10551751]
- 104 **Gould SW**, Banwell P, Glazer G. Perforated colonic carcinoma presenting as epididymo-orchitis and Fournier's gangrene. *Eur J Surg Oncol* 1997; **23**: 367-368 [PMID: 9315070]
- 105 **Berg A**, Armitage JO, Burns CP. Fournier's gangrene complicating aggressive therapy for hematologic malignancy. *Cancer* 1986; **57**: 2291-2294 [PMID: 3697930]
- 106 **Lévy V**, Jaffarbay J, Aouad K, Zittoun R. Fournier's gangrene during induction treatment of acute promyelocytic leukemia, a case report. *Ann Hematol* 1998; **76**: 91-92 [PMID: 9540765]
- 107 **Fialkov JM**, Watkins K, Fallon B, Kealey GP. Fournier's gangrene with an unusual urologic etiology. *Urology* 1998; **52**: 324-327 [PMID: 9697806]
- 108 **Smeets L**, Bous A, Heymans O. Necrotizing fasciitis: case report and review of literature. *Acta Chir Belg* 2007; **107**: 29-36 [PMID: 17405595]
- 109 **Brook I**. Microbiology and management of soft tissue and muscle infections. *Int J Surg* 2008; **6**: 328-338 [PMID: 17720643 DOI: 10.1016/j.ijssu.2007.07.001]
- 110 **Eisen DB**, Brown E. Necrotizing fasciitis following a motor vehicle accident with *Candida* species as the sole organisms. *Can J Plast Surg* 2004; **12**: 43-46 [PMID: 24115874]
- 111 **File TM**. Necrotizing soft tissue infections. *Curr Infect Dis Rep* 2003; **5**: 407-415 [PMID: 13678571]
- 112 **Slater DN**, Smith GT, Mundy K. Diabetes mellitus with ketoacidosis presenting as Fournier's gangrene. *J R Soc Med* 1982; **75**: 530-532 [PMID: 6806474]
- 113 **Miller JD**. The importance of early diagnosis and surgical treatment of necrotizing fasciitis. *Surg Gynecol Obstet* 1983; **157**: 197-200 [PMID: 6612567]
- 114 **Canoso JJ**, Barza M. Soft tissue infections. *Rheum Dis Clin North Am* 1993; **19**: 293-309 [PMID: 8502773]
- 115 **Andreasen TJ**, Green SD, Childers BJ. Massive infectious soft-tissue injury: diagnosis and management of necrotizing fasciitis and purpura fulminans. *Plast Reconstr Surg* 2001; **107**: 1025-1035 [PMID: 11252099]
- 116 **Umbert IJ**, Winkelmann RK, Oliver GF, Peters MS. Necrotizing fasciitis: a clinical, microbiologic, and histopathologic study of 14 patients. *J Am Acad Dermatol* 1989; **20**: 774-781 [PMID: 2654217]
- 117 **Larson CM**, Bublick MP, Jacobs DM, West MA. Malignancy, mortality, and medicosurgical management of *Clostridium* septicum infection. *Surgery* 1995; **118**: 592-597; discussion 597-598 [PMID: 7570310]
- 118 **Burch DM**, Barreiro TJ, Vanek VW. Fournier's gangrene: be alert for this medical emergency. *JAAPA* 2007; **20**: 44-47 [PMID: 18035764]
- 119 **Corman JM**, Moody JA, Aronson WJ. Fournier's gangrene in a modern surgical setting: improved survival with aggressive management. *BJU Int* 1999; **84**: 85-88 [PMID: 10444130]
- 120 **Chen CS**, Liu KL, Chen HW, Chou CC, Chuang CK, Chu SH. Prognostic factors and strategy of treatment in Fournier's gangrene: a 12-year retrospective study. *Changgeng Yi Xue Zazhi* 1999; **22**: 31-36 [PMID: 10418207]
- 121 **Li YD**, Zhu WF, Qiao JJ, Lin JJ. Enterostomy can decrease the mortality of patients with Fournier gangrene. *World J Gastroenterol* 2014; **20**: 7950-7954 [PMID: 24976731 DOI: 10.3748/wjg.v20.i24.7950]
- 122 **Buchel EW**, Finical S, Johnson C. Pelvic reconstruction using vertical rectus abdominis musculocutaneous flaps. *Ann Plast Surg* 2004; **52**: 22-26 [PMID: 14676694 DOI: 10.1097/01.sap.0000099820.10065.2a]
- 123 **Houvenaeghel G**, Ghouti L, Moutardier V, Buttarelli M, Lelong B, Delpero JR. Rectus abdominis myocutaneous flap in radical oncopelvic surgery: a safe and useful procedure. *Eur J Surg Oncol* 2005; **31**: 1185-1190 [PMID: 16126359 DOI: 10.1016/j.ejso.2005.07.004]
- 124 **Ooi BS**, Nyam DC, Cheng C, Tan KC, Koo WH, Lee KS. Transpelvic rectus abdominis flap for perineal reconstruction following abdominal perineal resection with en bloc partial cystectomy and prostatectomy for locally advanced rectal cancer. *Singapore Med J* 1999; **40**: 654-655 [PMID: 10741195]
- 125 **Tran NV**. Scrotal and perineal reconstruction. *Semin Plast Surg* 2011; **25**: 213-220 [PMID: 22851913 DOI: 10.1055/s-0031-1281491]
- 126 Guidelines for the Management of Fecal Incontinence with Flexi-Seal® SIGNAL®. Fecal Management System (FMS), ©2012 ConvaTec Inc. AP-012616-US
- 127 **Monson JR**, Weiser MR, Buie WD, Chang GJ, Rafferty JF, Buie WD, Rafferty J. Practice parameters for the management of rectal cancer (revised). *Dis Colon Rectum* 2013; **56**: 535-550 [PMID: 23575392 DOI: 10.1097/DCR.0b013e31828cb66c]
- 128 **Bullard KM**, Trudel JL, Baxter NN, Rothenberger DA. Primary perineal wound closure after preoperative radiotherapy and abdominoperineal resection has a high incidence of wound failure. *Dis Colon Rectum* 2005; **48**: 438-443 [PMID: 15719190 DOI: 10.1007/s10350-004-0827-1]
- 129 **El-Gazzaz G**, Kiran RP, Lavery I. Wound complications in rectal cancer patients undergoing primary closure of the perineal wound after abdominoperineal resection. *Dis Colon Rectum* 2009; **52**: 1962-1966 [PMID: 19934916 DOI: 10.1007/DCR.0b013e3181b71e9f]
- 130 **Christensen HK**, Nerstrøm P, Tei T, Laurberg S. Perineal repair after extralevator abdominoperineal excision for low rectal cancer. *Dis Colon Rectum* 2011; **54**: 711-717 [PMID: 21552056 DOI: 10.1007/DCR.0b013e3182163c89]
- 131 **Foster JD**, Pathak S, Smart NJ, Branagan G, Longman RJ, Thomas MG, Francis N. Reconstruction of the perineum following extralevator abdominoperineal excision for carcinoma of the lower rectum: a systematic review. *Colorectal Dis* 2012; **14**: 1052-1059 [PMID: 22762519 DOI: 10.1111/j.1463-1318.2012.03169.x]
- 132 **Han JG**, Wang ZJ, Wei GH, Gao ZG, Yang Y, Zhao BC. Randomized clinical trial of conventional versus cylindrical abdominoperineal resection for locally advanced lower rectal cancer. *Am J Surg* 2012; **204**: 274-282 [PMID: 22920402 DOI: 10.1016/j.amjsurg.2012.05.001]
- 133 **Dalton RS**, Smart NJ, Edwards TJ, Chandler I, Daniels IR. Short-term outcomes of the prone perineal approach for extra-levator abdomino-perineal excision (eLAPE). *Surgeon* 2012; **10**: 342-346 [PMID: 22088407 DOI: 10.1016/j.surge.2011.10.001]
- 134 **Han JG**, Wang ZJ, Gao ZG, Xu HM, Yang ZH, Jin ML. Pelvic floor reconstruction using human acellular dermal matrix after cylindrical abdominoperineal resection. *Dis Colon Rectum* 2010; **53**: 219-223 [PMID: 20087098 DOI: 10.1007/DCR.0b013e3181b715b5]
- 135 **Peacock O**, Simpson JA, Tou SI, Hurst NG, Speake WJ, Tierney GM, Lund JN. Outcomes after biological mesh reconstruction of the pelvic floor following extra-levator abdominoperineal excision of rectum (APER). *Tech Coloproctol* 2014; **18**: 571-577 [PMID: 24435472 DOI: 10.1007/s10151-013-1107-7]
- 136 **McCrea LE**. Fulminating gangrene of the penis. *Clinics* 1945; **4**: 796-829
- 137 **Chawla SN**, Gallop C, Mydlo JH. Fournier's gangrene: an analysis of repeated surgical debridement. *Eur Urol* 2003; **43**: 572-575 [PMID: 12706005]
- 138 **Vick R**, Carson CC. Fournier's disease. *Urol Clin North Am* 1999; **26**: 841-849 [PMID: 10584624]
- 139 Antibiotic guidelines, April 2011, Acute Medicine website; Hospital antibiotic guidelines from Coventry, UK. Website written by UK consultants, junior doctors and nurses
- 140 Antimicrobial guidelines. Necrotising fasciitis, East Kent Hospitals,

- 2011
- 141 First-line empirical antibiotic therapy in hospitalised adults, Southern Health and Social Care Trust, Northern Ireland. February 2010
- 142 Shimizu T, Tokuda Y. Necrotizing fasciitis. *Intern Med* 2010; **49**: 1051-1057 [PMID: 20558917]
- 143 Machado N. Necrotizing fasciitis: The importance of early diagnosis, prompt surgical debridement and adjuvant therapy. *North Am J Med Sci* 2011; **3**: 107-118
- 144 Ungpinitpong W. Early nutritional support in necrotizing fasciitis. *Med J Srisaket Surin Buriram Hosp* 2011; **23**: 327-332
- 145 Cerra FB, Benitez MR, Blackburn GL, Irwin RS, Jeejeebhoy K, Katz DP, Pingleton SK, Pomposelli J, Rombeau JL, Shrouts E, Wolfe RR, Zaloga GP. Applied nutrition in ICU patients. A consensus statement of the American College of Chest Physicians. *Chest* 1997; **111**: 769-778 [PMID: 9118718]
- 146 Graves C, Saffle J, Morris S, Stauffer T, Edelman L. Caloric requirements in patients with necrotizing fasciitis. *Burns* 2005; **31**: 55-59 [PMID: 15639366 DOI: 10.1016/j.burns.2004.07.008]
- 147 Cresti S, Ouaissi M, Sielezneff I, Chaix JB, Pirro N, Berthet B, Consentino B, Sastre B. Advantage of vacuum assisted closure on healing of wound associated with omentoplasty after abdominoperineal excision: a case report. *World J Surg Oncol* 2008; **6**: 136 [PMID: 19102785 DOI: 10.1186/1477-7819-6-136]
- 148 Poston GJ, Smith SR, Baker WN. Retrocolic pelvic omentoplasty in abdominoperineal excision of the rectum. *Ann R Coll Surg Engl* 1991; **73**: 229-232 [PMID: 1863044]
- 149 De Broux E, Parc Y, Rondelli F, Dehni N, Turet E, Parc R. Sutured perineal omentoplasty after abdominoperineal resection for adenocarcinoma of the lower rectum. *Dis Colon Rectum* 2005; **48**: 476-481; discussion 481-482 [PMID: 15714245 DOI: 10.1007/s10350-004-0784-8]
- 150 Chen SY, Fu JP, Wang CH, Lee TP, Chen SG. Fournier gangrene: a review of 41 patients and strategies for reconstruction. *Ann Plast Surg* 2010; **64**: 765-769 [PMID: 20407363 DOI: 10.1097/SAP.0b013e3181ba5485]
- 151 Holm T, Ljung A, Häggmark T, Jurell G, Lagergren J. Extended abdominoperineal resection with gluteus maximus flap reconstruction of the pelvic floor for rectal cancer. *Br J Surg* 2007; **94**: 232-238 [PMID: 17143848 DOI: 10.1002/bjs.5489]
- 152 Loessin SJ, Meland NB, Devine RM, Wolff BG, Nelson H, Zincke H. Management of sacral and perineal defects following abdominoperineal resection and radiation with transpelvic muscle flaps. *Dis Colon Rectum* 1995; **38**: 940-945 [PMID: 7656741]
- 153 Petrie N, Branagan G, McGuinness C, McGee S, Fuller C, Chave H. Reconstruction of the perineum following anorectal cancer excision. *Int J Colorectal Dis* 2009; **24**: 97-104 [PMID: 18688618 DOI: 10.1007/s00384-008-0557-2]
- 154 Meloney FL. Hemolytic streptococcus gangrene. *Arch Surg* 1924; **9**: 317-364 [DOI: 10.1001/archsurg.1924.01120080083007]
- 155 Afonso F, Gómez Pavón J, Balaguera J. Necrotizing fasciitis (fournier's gangrene) as a result of vesical catheterization. *Internet J Surg* 2007; **16**: 5
- 156 Oh C, Lee C, Jacobson JH. Necrotizing fasciitis of perineum. *Surgery* 1982; **91**: 49-51 [PMID: 7054907]
- 157 Gürdal M, Yücebas E, Tekin A, Beyse M, Aslan R, Sengör F. Predisposing factors and treatment outcome in Fournier's gangrene. Analysis of 28 cases. *Urol Int* 2003; **70**: 286-290 [PMID: 12740493]
- 158 Czymek R, Frank P, Limmer S, Schmidt A, Jungbluth T, Roblick U, Bürk C, Bruch HP, Kujath P. Fournier's gangrene: is the female gender a risk factor? *Langenbecks Arch Surg* 2010; **395**: 173-180 [PMID: 19139915 DOI: 10.1007/s00423-008-0461-9]
- 159 Elliott D, Kufera JA, Myers RA. The microbiology of necrotizing soft tissue infections. *Am J Surg* 2000; **179**: 361-366 [PMID: 10930480]
- 160 Luján Marco S, Budía A, Di Capua C, Broseta E, Jiménez Cruz F. Evaluation of a severity score to predict the prognosis of Fournier's gangrene. *BJU Int* 2010; **106**: 373-376 [PMID: 19922543 DOI: 10.1111/j.1464-410X.2009.09075.x]
- 161 Corcoran AT, Smaldone MC, Gibbons EP, Walsh TJ, Davies BJ. Validation of the Fournier's gangrene severity index in a large contemporary series. *J Urol* 2008; **180**: 944-948 [PMID: 18635215 DOI: 10.1016/j.juro.2008.05.021]
- 162 Erol B, Tuncel A, Hanci V, Tokgoz H, Yildiz A, Akduman B, Kargi E, Mungan A. Fournier's gangrene: overview of prognostic factors and definition of new prognostic parameter. *Urology* 2010; **75**: 1193-1198 [PMID: 20451745 DOI: 10.1016/j.urology.2009.08.090]
- 163 Roghmann F, von Bodman C, Löppenber B, Hinkel A, Palisaar J, Noldus J. Is there a need for the Fournier's gangrene severity index? Comparison of scoring systems for outcome prediction in patients with Fournier's gangrene. *BJU Int* 2012; **110**: 1359-1365 [PMID: 22494217 DOI: 10.1111/j.1464-410X.2012.11082.x]
- 164 Ersoz F, Sari S, Arikan S, Altioek M, Bektas H, Adas G, Poyraz B, Ozcan O. Factors affecting mortality in Fournier's gangrene: experience with fifty-two patients. *Singapore Med J* 2012; **53**: 537-540 [PMID: 22941132]
- 165 Norton KS, Johnson LW, Perry T, Perry KH, Sehon JK, Zibari GB. Management of Fournier's gangrene: an eleven year retrospective analysis of early recognition, diagnosis, and treatment. *Am Surg* 2002; **68**: 709-713 [PMID: 12206606]
- 166 Nisbet AA, Thompson IM. Impact of diabetes mellitus on the presentation and outcomes of Fournier's gangrene. *Urology* 2002; **60**: 775-779 [PMID: 12429294]
- 167 Laor E, Palmer LS, Tolia BM, Reid RE, Winter HI. Outcome prediction in patients with Fournier's gangrene. *J Urol* 1995; **154**: 89-92 [PMID: 7776464]
- 168 Martinschek A, Evers B, Lampl L, Gerngroß H, Schmidt R, Sparwasser C. Prognostic aspects, survival rate, and predisposing risk factors in patients with Fournier's gangrene and necrotizing soft tissue infections: evaluation of clinical outcome of 55 patients. *Urol Int* 2012; **89**: 173-179 [PMID: 22759538 DOI: 10.1159/000339161]
- 169 Clayton MD, Fowler JE, Sharifi R, Pearl RK. Causes, presentation and survival of fifty-seven patients with necrotizing fasciitis of the male genitalia. *Surg Gynecol Obstet* 1990; **170**: 49-55 [PMID: 2294630]
- 170 Ruiz-Tovar J, Córdoba L, Devesa JM. Prognostic factors in Fournier gangrene. *Asian J Surg* 2012; **35**: 37-41 [PMID: 22726562 DOI: 10.1016/j.asjsur.2012.04.006]
- 171 Aridogan IA, Izol V, Abat D, Karsli O, Bayazit Y, Satar N. Epidemiological characteristics of Fournier's gangrene: a report of 71 patients. *Urol Int* 2012; **89**: 457-461 [PMID: 23076238 DOI: 10.1159/000342407]
- 172 Rouse TM, Malangoni MA, Schulte WJ. Necrotizing fasciitis: a preventable disaster. *Surgery* 1982; **92**: 765-770 [PMID: 7123497]
- 173 Freeman HP, Oluwole SF, Ganepola GA, Dy E. Necrotizing fasciitis. *Am J Surg* 1981; **142**: 377-383 [PMID: 7283033]
- 174 Giuliano A, Lewis F, Hadley K, Blaisdell FW. Bacteriology of necrotizing fasciitis. *Am J Surg* 1977; **134**: 52-57 [PMID: 327844]
- 175 Tuncel A, Aydin O, Tekdogan U, Nalcacioglu V, Capar Y, Atan A. Fournier's gangrene: Three years of experience with 20 patients and validity of the Fournier's Gangrene Severity Index Score. *Eur Urol* 2006; **50**: 838-843 [PMID: 16513250 DOI: 10.1016/j.eururo.2006.01.030]
- 176 Altarac S, Katušin D, Crnica S, Papeš D, Rajković Z, Arslani N. Fournier's gangrene: etiology and outcome analysis of 41 patients. *Urol Int* 2012; **88**: 289-293 [PMID: 22433163 DOI: 10.1159/000335507]
- 177 Ersay A, Yilmaz G, Akgun Y, Celik Y. Factors affecting mortality of Fournier's gangrene: review of 70 patients. *ANZ J Surg* 2007; **77**: 43-48 [PMID: 17295820 DOI: 10.1111/j.1445-2197.2006.03975.x]
- 178 López-Sámamo V, Ixquiac-Pineda G, Maldonado-Alcaraz E, Montoya-Martínez G, Serrano-Brambila E, Peralta-Alarcón J. [Fournier's gangrene. Experience of the CMN SXXI Hospital]. *Arch Esp Urol* 2007; **60**: 525-530 [PMID: 17718206]
- 179 Charlson ME, Pompei P, Ales KL, MacKenzie CR. A new method of classifying prognostic comorbidity in longitudinal studies: development and validation. *J Chronic Dis* 1987; **40**: 373-383 [PMID: 3558716]

- 180 **Gawande AA**, Kwaan MR, Regenbogen SE, Lipsitz SA, Zinner MJ. An Apgar score for surgery. *J Am Coll Surg* 2007; **204**: 201-208 [PMID: 17254923 DOI: 10.1016/j.jamcollsurg.2006.11.011]
- 181 **Tuncel A**, Keten T, Aslan Y, Kayali M, Erkan A, Koseoglu E, Atan A. Comparison of different scoring systems for outcome prediction in patients with Fournier's gangrene: experience with 50 patients. *Scand J Urol* 2014; **48**: 393-399 [PMID: 24521184 DOI: 10.3109/21681805.2014.886289]
- 182 **Ferreira PC**, Reis JC, Amarante JM, Silva AC, Pinho CJ, Oliveira IC, da Silva PN. Fournier's gangrene: a review of 43 reconstructive cases. *Plast Reconstr Surg* 2007; **119**: 175-184 [PMID: 17255671 DOI: 10.1097/01.prs.0000244925.80290.57]
- 183 **Yilmazlar T**, Işık Ö, Öztürk E, Özer A, Gülcü B, Ercan İ. Fournier's gangrene: review of 120 patients and predictors of mortality. *Ulus Travma Acil Cerrahi Derg* 2014; **20**: 333-337 [PMID: 25541844]
- 184 **Kagda FH**, Nyam DC, Ho YH, Eu KW, Leong AF, Seow-Choen F. Surgery may be curative for patients with a localized perforation of rectal carcinoma. *Br J Surg* 1999; **86**: 1448-1450 [PMID: 10583294 DOI: 10.1046/j.1365-2168.1999.01238.x]

P- Reviewer: Riss S, Santoro GA, Tsimogiannis K, Wittmann T
S- Editor: Ma YJ **L- Editor:** Roemmele A **E- Editor:** Ma S





Published by **Baishideng Publishing Group Inc**

8226 Regency Drive, Pleasanton, CA 94588, USA

Telephone: +1-925-223-8242

Fax: +1-925-223-8243

E-mail: bpgoffice@wjgnet.com

Help Desk: <http://www.wjgnet.com/esps/helpdesk.aspx>

<http://www.wjgnet.com>



ISSN 1007-9327



9 771007 932045