

Mandibular osteonecrosis due to the pulpal-periodontal syndrome: a case report and review of the literature

Gabrić, Dragana; Seiwert, Sven; Baraba, Anja; Vučićević Boras, Vanja

Source / Izvornik: *Acta Stomatologica Croatica*, 2017, 51, 65 - 71

Journal article, Published version

Rad u časopisu, Objavljena verzija rada (izdavačev PDF)

<https://doi.org/10.15644/asc51/1/9>

Permanent link / Trajna poveznica: <https://um.nsk.hr/um:nbn:hr:105:151871>

Rights / Prava: [In copyright](#) / [Zaštićeno autorskim pravom.](#)

Download date / Datum preuzimanja: **2024-09-30**



Repository / Repozitorij:

[Dr Med - University of Zagreb School of Medicine Digital Repository](#)



Dragana Gabrić¹, Sven Seiwerth², Anja Baraba³, Vanja Vučićević Boras⁴

Osteonekroza mandibule kao posljedica pulpo-parodontnog sindroma: prikaz slučaja i pregled literature

Mandibular Osteonecrosis due to the Pulpal-Periodontal Syndrome: a Case Report and Review of the Literature

¹ Zavod za oralnu kirurgiju Stomatološkog fakulteta Sveučilišta u Zagrebu – Klinički bolnički centar Zagreb, Zagreb, Hrvatska
Department of Oral Surgery, School of Dental Medicine, University of Zagreb, University Hospital Center Zagreb, Zagreb, Croatia

² Zavod za patologiju Medicinskog fakulteta Sveučilišta u Zagrebu – Klinički bolnički centar Zagreb, Zagreb, Hrvatska
Department of Pathology, School of Medicine, University of Zagreb, University Hospital Center Zagreb, Zagreb, Croatia

³ Zavod za endodonciju i restorativnu stomatologiju Stomatološkog fakulteta Sveučilišta u Zagrebu, Hrvatska
Department of Endodontics and Restorative Dentistry, School of Dental Medicine, University of Zagreb, Croatia

⁴ Zavod za oralnu medicinu Stomatološkog fakulteta Sveučilišta u Zagrebu – Klinički bolnički centar Zagreb, Hrvatska
Department of Oral Medicine, School of Dental Medicine, University of Zagreb, University Hospital Center Zagreb, Zagreb, Croatia

Sažetak

Dosadašnje spoznaje: Ishemične koštane bolesti multifaktorijalne su etiologije. Potrebno je eliminirati kronične upale odontogene etiologije u svrhu prevencije osteonekroze čeljusti. **Prikaz slučaja:** Opisan je neobičan slučaj osteonekroze nastale zbog pulpo-parodontnog sindroma i posljedične nekroze pulpe. Riječ je o 38-godišnjoj ženi kojoj je nađena eksponirana kost u promjeru od osam milimetara u lingvalnoj regiji u području donjega desnog trećeg molara. Pacijentica je inače anamnestički bila zdrava i nije uzimala nikakve lijekove. Nakon iscrpne anamneze nisu nađene nikakve ranije bolesti. Opovrgnuta je bilo kakav oblik lokalne traume. Kompletna krvna slika bila je uredna. Na ortopantomogramu uočen je dubok parodontni džep između zuba 47 i 48, a na CBCT-u dubok parodontni džep između molara i koštani sekvestar u području lingvalnog kortikalisa. Primijenjena je topikalna terapija u obliku adhezivnog parodontnog zavoja te betametazon mast u orabazi, ali bezuspješno. Zbog toga je određena jednotjedna terapija amoksicilinom. S obzirom na to da i dalje nije bilo rezultata, ekstrahiran je treći molar te uklonjena nekrotična kost, modeliran je alveolarni greben i rana sašivena primarno. Nakon šivanja ponovno je postavljen intraoralni resorptivni zavoj. Uzet je bris iz rane za mikrobiološku obradu, no nije bilo polimorfonukleara ili mikroorganizama. Mikrobiološki uzorak nekrotične kosti pokazao je mnoštvo gram-pozitivnih koka, ali polimorfonukleari također nisu nađeni. Nakon histopatološke analize postavljena je dijagnoza akutne kronične upale. Rana je potpuno zacijelila sedam dana nakon kirurškoga zahvata. **Zaključak:** Prikazani slučaj opisuje mogućnost nastanka osteonekroze čeljusti kao posljedice pulpo-parodontnog sindroma, odnosno nekroze pulpe.

Zaprimljen: 10. listopada 2016.
Prihvaćen: 12. siječnja 2017.

Adresa za dopisivanje

Doc. dr. sc. Dragana Gabrić
Sveučilište u Zagrebu
Stomatološki fakultet
Klinički bolnički centar Zagreb
HR-10000 Zagreb, Gundulićeva 8
tel:+38514802138
dgabric@sfz.hr

Ključne riječi

donja čeljust; kost, nekroza; zubna pulpa, nekroza; koki, gram-pozitivni

Uvod

Osteonekrozu čeljusti obilježava stvaranje sekvestra koji je fragment avitalne kosti separirane od okolne kosti, što je rezultat lokalizirane koštane nekroze obično povezane s ishemijom (1). U većini slučajeva s osteonekrozom čeljusti povezani su lokalni i sistemski čimbenici. Osteonekroza čeljusti može biti sistemski uzrokovana, primjerice, zbog zračenja u području glave i vrata, uzimanja bisfosfonata (liječenje osteoporoze ili malignih bolesti, poput multiplog mijeloma itd.) (2) ili kortikosteroida, uzivanja kokaina, poremećaja u zgrušavanju krvi te uzimanja lijekova koji djeluju na mehanizme zgrušavanja. Ostali čimbenici uključuju dijabetes, leukemiju, Pagetovu bolest, fibroznu displaziju, malnutriciju i trovanje teškim metalima (3). Osteonekrozu čeljusti mogu uzrokovati i lokalni čimbenici, poput traume nakon stomatološkog za-

Introduction

Osteonecrosis of the jaw is characterized by formation of sequestrum which is a fragment of avital bone separated from adjacent sound bone as a result of focal bone necrosis which is usually associated with ischemia (1). In most cases, known local and systemic factors associated with jaw osteonecrosis are present. Osteonecrosis of the jaws might be systemically induced i.e. due to radiation treatment of head and neck cancers, due to bisphosphonate therapy (either for osteoporosis or treatment of malignancies such as multiple myeloma, etc.) (2), due to corticosteroid therapy, cocaine abuse, clotting disorders and intake of drugs which affect clotting mechanisms. Other factors might include diabetes, leukemia, Paget's disease of bone, fibrous dysplasia, malnutrition and heavy metal poisoning (3). Necrosis of the jaws might have local causes

hvata (ekstrakcija umnjaka, postavljenje koferdama ili ozljede kemijskim tvarima itd.), bulimije ili lezija prouzročenih samoozljeđivanjem osoba s psihološkim poremećajima (4–6). Khullar i suradnici (7) opisali su šezdeset slučajeva ekstremne osteonekroze i osteonekroze gornje i donje čeljusti uzrokovanih koagulopatijama i osteopetrozom, Gorhamovom bolešću, infektivnim stanjima (tuberkuloza, herpes zoster, HIV i osteomijelitis), intoksikacijom (bisfosfonati, ugrizi pauka) te utjecajem okoliša znanim pod nazivom radijska i fosfatna čeljust. U posljednjih sedam godina objavljen je na *PubMedu* veći broj prikaza slučajeva osteonekroze čeljust nastalih zbog različitih i rijetkih etioloških čimbenika.

Svrha ovog prikaza slučaja jest opisati osteonekrozu čeljusti kao posljedicu pulpo-parodontnog sindroma i posljedične nekroze pulpe.

Prikaz slučaja

Pacijentica čiji je slučaj opisan u ovom tekstu potpisala je suglasnost te je rad odobrio Etički odbor Stomatološkog fakulteta Sveučilišta u Zagrebu.

Pacijentica u dobi od 38 godina došla je zbog ekspanzivnog nekrotičnog koštanog areala na lingvalnoj strani u području donjega desnog umnjaka, veličine osam milimetara u promjeru. Inače je prema anamnezi bila zdrava i nije uzimala nikakve lijekove te je također izjavila da nije doživjela nikakvu lokalnu traumu, nije bila na stomatološkim zahvatima unatrag tri mjeseca, te nije imala bulimiju ili lezije nastale samoozljeđivanjem. Nikada joj nisu bili propisani bisfosfonati, kortikosteroidi te nikada nije bila na terapiji zračenjem.

Kompletna krvna slika pacijentice bila je unutar granica normale. Učinjeni ortopantomogram nije pokazao nikakve patološke promjene u području donje čeljusti desno u regiji molara (slika 1.). CBCT je pokazao dubok parodontni džep između drugoga i trećega molara, što je upućivalo na kronični upalni proces (slika 2.). Pronađen je egzofitični koštani otok na lingvalnoj kortikalnoj ploči veličine osam milimetara u promjeru, te koštani sekvistar (slike 3. i 4.).

Biostimulacijska laserska terapija i plazmaterapija u području lezije nisu bile učinkovite. Postavljen je adhezivni parodontni zavoj na bazi celuloze tijekom prva tri dana (ResoPac, Hager&Werken, Duisburg, Njemačka) te mast betametazon u orabazi, koja se sastoji od želatine, pektina i natrijeve karboksimetilne celuloze u plastificiranom hidrokarbonskom gelu (Orabase, ConvaTec), tijekom sljedeća tri dana. Lokalna terapija i dalje nije bila klinički uspješna. Pacijentici je zato propisana jednodnevna peroralna antibiotska terapija amoksicilinom, ali također bez rezultata. Zbog toga se pristupilo kirurškom liječenju. Aplicirane su dvije ampule artikaina u provodnoj anesteziji donje čeljusti s desne strane (Ubistesin™, 3M ESPE, Diegem, Belgija). Nakon sulcularne incizije i odizanja mukoperiostalnog režnja, slobodni koštani sekvistar uklonjen je hemostatom. Preostala egzofitična kost uklonjena je kirurškim čekićem i dljetom. Za završnu modelaciju koštane površine korišteno je okruglo čelično kirurško svrdlo. Donji desni umnjak uklonjen je kirurški, s obzirom na to da je postojao dubok parodontni džep između drugoga i trećega donjeg desnog molara (7 mm – izmje-

such as previous trauma caused by dental treatment (extraction of third molars, placement of rubber dam or injuries due to use of chemicals in dentistry, etc.), bulimia or self-inflicted lesions in persons with psychological disturbances (4-6). Khullar *et al.* (7) reported on the sixty cases of extreme osteonecrosis and osteomyelitis of the mandible and maxilla caused by coagulopathies and osteopetrosis, Gorham's disease, infective conditions (tuberculosis, herpes zoster, HIV and osteomyelitis), toxicity (bisphosphonates, spider bites) and environmental effects such as phossy jaw, radium jaw. Over the last 7 years, the occurrence of osteonecrosis due to different and rare causes has increasingly been reported on PubMed.

Therefore, we present an unusual case of osteonecrosis due to the pulpal-peridontal syndrome and a subsequent pulp necrosis.

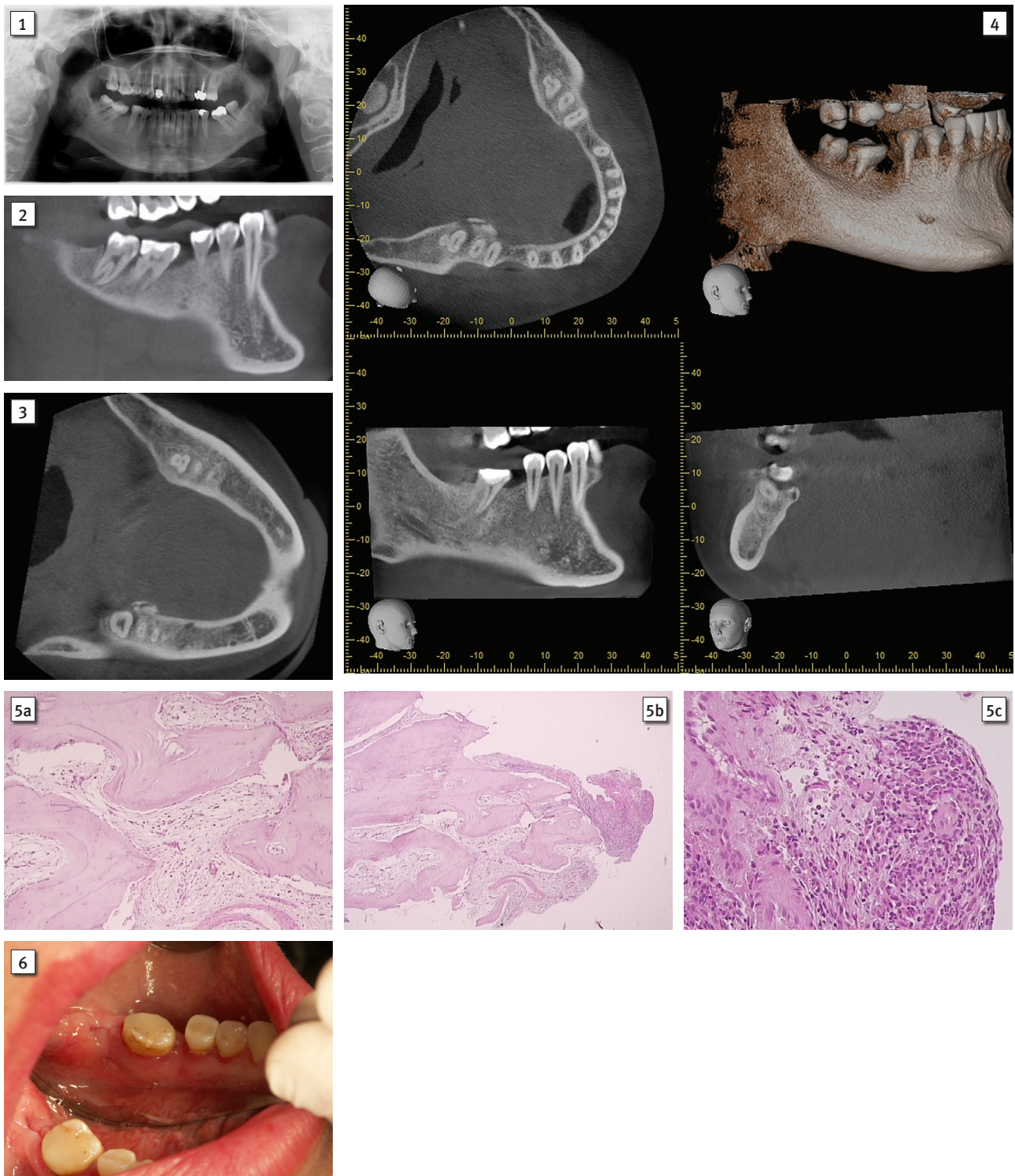
Case report

The patient presented in this case report has signed the informed consent approved by the Ethics Committee of the School of Dental Medicine, University of Zagreb.

A 38-year-old female patient presented with exposed necrotic bone area on the lingual side of the right lower third molar with a diameter of 8mm. The patient was otherwise healthy and was not taking any medications. The patient denied local trauma, dental treatments in the past three months, bulimia or self-inflicted causes of the lesion. The patient had never been prescribed any byphosphonates, corticosteroids and had never been exposed to irradiation.

A complete blood count was within normal ranges. The orthopantomograph was normal without any pathological changes in the right molar area of the lower jaw (Figure 1). The CBCT showed a deep periodontal pocket between second and third molar, indicating chronic inflammatory process (Figure 2). An exophytic bone island, 8 mm in diameter, and a bone sequestrum were found on the lingual cortical plate (Figures 3 and 4).

Low level laser therapy and plasmatherapy of the lesion were not effective. Therefore, adhesive periodontal cellulose dressing (ResoPac, Hager&Werken, Duisburg, Germany) and betamethasone ointment in orabase which is composed of gelatin, pectin and sodium carboxymethylcellulose in plasticised hydrocarbon gel (Orabase, ConvaTec) were applied for the following three days. However, both treatments were without any improvements. The patient was subsequently prescribed peroral antibiotic amoxicillin during the period of one week, again without any improvement. Therefore, surgical treatment was performed. Two ampoules of articaine (Ubistesin™, 3M ESPE, Diegem, Belgium) were used for regional nerve block anesthesia. After sulcular incision and elevation of the mucoperiosteal flap, a free bone sequestrum was removed using haemostat. The remaining exophytic bone was removed using surgical hammer and chisel. Final modelation of the bone surface was performed using round steel surgical bur. Since there was a periodontal pocket (7 mm measured with periodontal probe) between lower right second and third molar, the third molar was surgically removed. A swab was taken from this area for microbiological analysis. Gran-



Slika 1. Inicijalni ortopantomogram 38-godišnje pacijentice

Figure 1 Initial orthopantomogram of a 38-year-old female patient.

Slika 2. CBCT donje čeljusti pokazuje dubok paradontni džep između drugoga i trećega donjeg desnog molara

Figure 2 CBCT of the mandible showing a deep periodontal pocket between lower right second and third molar.

Slika 3. CBCT donje čeljusti prikazuje egzofitičan koštani otočić na lingvalnoj kortikalnoj ploči

Figure 3 CBCT of the mandible showing an exophytic bone island on the lingual cortical plate.

Slika 4. CBCT donje čeljusti prikazuje koštani sekvistar veličine 8 mm u promjeru

Figure 4 CBCT of the mandible showing bone sequestrum 8 mm in diameter.

Slika 5. Bojenje HE-a, originalno povećanje a) x 4, b) x 10, c) x 40; uzorak pokazuje koštani fragment s reaktivnim promjenama te u područjima granulacijskog tkiva i novostvorenog vezivnog tkiva prožetog uglavnom mononuklearnim stanicama, uz ponešto granulocita

Figure 5 Staining HE, original magnification a) x4, b) x10, c) x40. Specimen shows bone fragment with reactive changes and an area of granulation tissue and newly formed connective tissue permeated with mainly mononuclear cells with some granulocytes.

Slika 6. Kliničkim pregledom ustanovljena je potpuna epitelizacija rane i područja prethodno nekrotične alveolarne kosti.

Figure 6 Clinical examination at the recall visit showing complete epithelisation of the wound and area of the previously necrotic alveolar bone.

reno parodontnom sondom). Uzet je obrisak iz kirurškoga polja za mikrobiološku analizu. Granulacijsko tkivo u području postekstrakcijske alveole bilo je mehanički uklonjeno. Uklonjena kost i granulacijsko tkivo pripremljeni su za patohistološku obradu. U područje kirurške rane aplicirana je fotoaktivna tvar u svrhu provođenja antimikrobne fotodinamske terapije niskoenergijskim diodnim laserom (LaserHF, Hager&Werken, Duisburg, Njemačka) radi redukcije mikroorganizama. Rana je sašivena neresorptivnim koncem na okrugloj atraumatskoj igli (Mersilk 4, Ethicon, Škotska). Područje prije eksponirane kosti također je primarno sašiveno. Cijelo kirurško polje na kraju je prekriveno resorptivnim intraoralnim zavojem (ResoPac, Hager&Werken, Duisburg, Njemačka). Analiza mikrobiološkog obriska rane nije dokazala polimorfonukleare i mikroorganizme, a mikrobiološka analiza biopirane kosti i koštanog sekvestra pokazala je prisutnost mnoštva gram-pozitivnih koka, ali polimorfonukleari nisu pronađeni. U obrisku rane nije bilo ni mikroorganizama, ni polimorfonukleara.

Histopatološkom analizom postavljena je dijagnoza kronične upale (slike 5. a, b i c). Detaljnije, novostvoreno glatko vezivno tkivo nađeno unutar koštanog fragmenta, koštano tkivo blizu postekstrakcijske alveole i granulacijsko tkivo bili su prožeti miješanim upalnim infiltratom, uz velik broj histiocita, mononuklearnih stanica i eozinofila te ponešto granulocita (slike 5. a, b i c). Šavovi su uklonjeni osmoga poslijeoperacijskog dana. Pacijentica nije navela nikakve poslijeoperacijske komplikacije tijekom cijeljenja, ni subjektivne znakove ili simptome. Tijekom kliničkoga pregleda nađena je potpuna epitelizacija rane i područja prethodno nekrotične alveolarne kosti (slika 6.).

Rasprava

Osteonekroza čeljusti obično se povezuje s pacijentima koji su bili izloženi zračenju zbog tumora glave i vrata te su uzimali bisfosfonate za liječenje osteoporoze ili malignih bolesti, poput multiplog mijeloma. Iako su čimbenici koji uzrokuju osteonekrozu čeljusti poznati, u literaturi je nekoliko prikaza slučajeva u kojima se ne mogu prepoznati uobičajeni uzročnici spomenutog stanja. Uporaba različitih kemijskih sredstava u dentalnoj medicini, poput kiselina za jetkanje, pasta koje sadržavaju arsen ili paraformaldehid tijekom endodontskog liječenja, mogu oštetiti gingivu i alveolarnu kost (5, 6). Određeni zahvati, poput intraosealne anestezije i produžene rotacije svrdla za perforaciju u kosti, također mogu uzrokovati nekrozu kosti (8). Mogu je izazvati i određeni medicinski zahvati, poput laringoskopije ili postavljanja endotrahealne tube (9). Jackson i Malden (2) opisali su tri slučaja lingvalne ulceracije mukoze sa sekvestracijom mandibule, od kojih su dva nastala nakon ekstrakcije zuba u donjoj čeljusti, a treći je vjerojatno povezan s uzimanjem bisfosfonata. Magremanne i suradnici (10) opisali su slučaj pacijenta upućenog u bolnicu nakon vađenja nekoliko zuba, što je rezultiralo gubitkom velikoga fragmenta kosti. Isti autor zaključio je da je avaskularna nekroza mandibule u spomenutom slučaju posljedica poremećaja u zgrušavanju krvi. Prema Magremanneu i suradnicima, nekroza čeljusti ri-

ulation tissue around postextracted socket was mechanically removed. The bone and granulation tissue removed during the surgical procedure were prepared for histopathological analysis. After application of the photosensitizer, antimicrobial photodynamic therapy (aPDT) was performed using low power diode laser (LaserHF, Hager&Werken, Duisburg, Germany), in order to reduce the microbiota at the surgical site. Silk sutures with round needle (Mersilk 4.0, Ethicon, Scotland) were used. The area of the previously exposed bone was also sutured. The whole surgical area was finally covered with resorbable intraoral bandage (ResoPac, Hager&Werken, Duisburg, Germany). A microbial swab of the wound aspirate did not reveal polymorphonuclears or the presence of microorganisms. The microbial swab of the biopsy specimen of the necrotic bone particle and sequestrum showed plenty of gram-positive cocci, however, polymorphonuclears were not found. The wound swab revealed no microorganisms or polymorphonuclears.

Histopathological analysis revealed chronic inflammation (Figure 5. a, b and c). A newly formed loose connective tissue was found in the bone fragment on the other part of the bone sample (close to the postextraction socket). Abundant granulation tissue permeated with mixed inflammatory infiltration, with huge amount of histiocytes, mononuclear cells and eosinophils and with some granulocytes (Figure 5. a, b and c). The sutures were removed eight days after surgery. The patient did not report any postsurgical complications during the healing period, or subjective clinical signs and symptoms. Clinical examination revealed complete epithelisation of the wound and area of the previously necrotic alveolar bone (Figure 6.).

Discussion

Traditionally, osteonecrosis of the jaw has been usually correlated with irradiation of patients due to head and neck malignancies and bisphosphonate intake either for treatment of osteoporosis or malignant diseases such as multiple myeloma. Usually, factors that lead to jaw osteonecrosis are known, however, there have been few case reports in the literature where no known factors for the development of osteonecrosis could be identified. The misuse of various chemicals in dentistry such as acid etchants, arsenic paste as well as paraformaldehyde containing pastes during endodontic treatment may cause damage to the gingiva and alveolar bone (5,6). Some dental techniques such as intraosseous anesthesia and prolonged rotation of the perforator drills in the bone might also lead to bone necrosis (8). Other medical procedures such as laryngoscopy and endotracheal tube placement might also induce osteonecrosis (9). Jackson and Malden (2) reported three cases of lingual mucosal ulceration with mandibular sequestration, two of which occurred after extraction of mandibular teeth and the third occurred possibly after bisphosphonate therapy. Magremanne *et al.* (10) reported a case of a patient who was referred to the hospital for several tooth extractions which ended with spontaneous loss of voluminous bone fragment. The same authors concluded that avascular mandibular necrosis in their case was due to the blood co-

jetko je posljedica bakterijske, virusne infekcije ili infekcije gljivicama, iako je opisano nekoliko slučajeva osteonekroze nakon infekcije herpesom zosterom. Osim bisfosfonata, i drugi lijekovi prepoznati su kao mogući uzročnici osteonekroze čeljusti. Fleissig i suradnici (11) istaknuli su slučaj osteonekroze kod žene u dobi od 58 godina u području desnog kutnjaka donje čeljusti koji je bio izvađen prije osam mjeseci. Pacijentica je bila pod terapijom sunitinibom (antiangiogeni lijek) zbog karcinoma bubrega. Nakon što je dobila antibiotike i bila na fizioterapiji 12 tjedana, potpuno se oporavila. Antineoplastični lijekovi koji interferiraju s antiangiogenim mehanizmom mogu izazvati nastanak osteonekroze, posebno ako pacijenti uzimaju bisfosfonate (12). Serra i suradnici (13) opisali su slučaj nekroze kosti jedan tjedan nakon vađenja kutnjaka u donjoj čeljusti kod pacijenta koji je imao adenokarcinom pluća s metastazama. Nakon ekstrakcije taj je pacijent dobio bevacizumab koji je vjerojatno uzrokovao nekrozu kosti. Kao terapija ordinirani su mu antibiotici i ispiranje klorheksidinom. Infekcija herpesom zosterom također je opisana kao mogući uzrok osteonekroze čeljusti kod dva pacijenta (14, 15). Jain i suradnici (14) opisali su slučaj neuobičajene oralne komplikacije tijekom infekcije herpesom zosterom mandibularnog dijela trigeminalnog živca koji je rezultirao osteonekrozom, spontanom ekfolijacijom zuba i posljedičnom patološkom frakturom mandibule, bez drugih poznatih predisponirajućih čimbenika. Pushpanshu i suradnici (15) također su opisali slučaj herpesa zostera u lijevom maksilarnom dijelu trigeminalnog živca s nekrozom kosti i brzom ekfolijacijom zuba. De Visscher i suradnici (16) opisali su slučaj 47-godišnjeg pacijenta koji je imao ulceraciju s izloženom kosti na lingvalnoj strani zuba 47 i 48. Isti autori zaključili su da se opisano stanje može pojaviti spontano ili nakon oštećenja mukozne membrane (16). Kao terapijske mogućnosti predložili su kirurško zaglađivanje eksponirane kosti, kirurško uklanjanje nekrotične kosti ili spontanu sekvestraciju. Sonnier i Horning (17) opisali su četiri slučaja spontanog otvaranja i sekvestracije alveolarne kosti. Dok je u jednom slučaju bio u pitanju alergijski mukozitis, preostala tri su bila idiopatska, uz velike lingvalne egzostoze. Peters i suradnici (18) opisali su spontanu sekvestraciju lingvalnog dijela kosti donje čeljusti u području kutnjaka kod jedanaest pacijenata. Slično kao i kod naših slučajeva, nije bilo ni kliničkih ni radioloških znakova osteomijelitisa. Peters i suradnici (18) istaknuli su da je zahvaćeno područje kod njihovih pacijenata imalo malu ulceraciju (2, 2 – 4,6 mm) s centralnim sekvestrom, što je istovjetno našem nalazu. No za razliku od slučaja Petersa i suradnika, naši pacijenti nisu imali mandibularne toruse koji mogu biti predisponirajući čimbenik za osteonekrozu, jer je poznato da takve osobe imaju neuobičajeno labilan periostalni odgovor na iritaciju.

Kao što je istaknuto i u sličnim prikazima slučajeva, sekvestri su bili povezani s ulceracijom mukoze koja je trajala od nekoliko dana do tri mjeseca. U prezentiranom slučaju možda je lokalna trauma tijekom uzimanja hrane ili pranja zuba rezultirala ishemijom koja je dovela do nekroze kosti. Određena mjesta u usnoj šupljini podložnija su ovoj vrsti traume, poput prominencije milohoidnog grebena u mandibuli.

agulation disorder. As suggested by Megremann *et al.*, necrosis of the jaw is rarely due to bacterial, viral or fungal infection although few case reports on osteonecrosis have been described after herpes zoster infection. Apart from bisphosphonates, other medications have been identified as a possible cause of jaw osteonecrosis. Recently, Fleissig *et al.* (11) described a case of osteonecrosis in a 58 year old woman in the area of the right mandibular molar which had been extracted eight months before the treatment. The patient had been treated with sunitinib (antiangiogenic drug) for renal cell carcinoma. In addition to that, the patient was treated with antibiotics and physiotherapy during the period of 12 weeks with complete recovery. Antineoplastic drugs that act via an antiangiogenic mechanism could trigger or facilitate osteonecrosis especially if patients are being treated with bisphosphonates (12). Serra *et al.* (13) reported a case of jaw bone necrosis one week after extraction of the mandibular molar in a patient with lung adenocarcinoma with metastasis. After the extraction, he was given bevacizumab which probably led to bone necrosis. The patient was treated with chlorhexidine rinses and antibiotics. Recently, herpes zoster infection has been reported as a cause of jaw osteonecrosis in two patients (14, 15). Jain *et al.* (14) reported a case of unusual oral complication of herpes zoster infection involving mandibular division of trigeminal nerve which resulted in osteonecrosis, spontaneous exfoliation of teeth and subsequent pathologic fracture of the mandible in the absence of other known predisposing factors. Pushpanshu *et al.* (15) also reported a case of the herpes zoster of the left maxillary division of the trigeminal nerve with bone necrosis and rapid tooth exfoliation. De Visscher *et al.* (16) reported a case of 47 year old patient who had ulcer with exposed bone on the lingual side of the teeth 47 and 48. The same authors stated that condition might appear spontaneously or following damage to the mucous membrane (16). They suggested that surgical smoothing of the exposed bone, surgical removal of necrotic bone or spontaneous sequestration could be treatment options that could help. Sonnier and Horning (17) described four cases of spontaneous exposure and sequestration of alveolar bone. While one case was associated with an allergic mucositis, the other three were idiopathic involving large lingual exostoses. Peters *et al.* (18) reported spontaneous sequestration on the lingual mandibular bone in the molar region in eleven patients. As also seen in our case, there were no any clinical and radiological features of osteomyelitis. Peters *et al.* (18) reported that the affected area in their patients showed a single small ulcer (2.2-4.6 mm) with central sequestrum which is also consistent with our finding. Contrary to the finding of Peters *et al.*, our patient did not have mandibular tori which might be a predisposing factor for osteonecrosis since it is a known fact that patients with osteonecrosis have unusually labile periostal response to irritation.

As seen in other similar case reports, the sequestra were associated with ulceration of the overlying mucosa which persisted from few days to as long as three months. In our case, it might be that local trauma from food intake or tooth-brushing caused ischemia which led to the jaw necrosis. Some sites in the oral cavity are more prone to this type of

Lingvalna inklinacija donjih kutnjaka štiti lingvalnu gingivu od iritacija tijekom žvakanja, no ako pacijentima nedostaju kutnjaci ili u slučaju restauracija s neodgovarajućim konturama, uz prisutne čestice hrane, povećava se rizik od stalne traume u ovom području (1). U našem slučaju, pacijent je imao donje kutnjake, ali bila je prisutna nekroza kosti koja je sanirana vađenjem zuba 48. Drugi eventualni uzrok jest mogućnost da je lingvalni mandibularni korteks smješten na najudaljenijem dijelu od alevolarnih arterija koje donju čeljust opskrbljuju krvlju. Posljedično, spomenuto područje može biti podložnije sekvencijama (18).

Smatramo da je lezija na lingvalnoj gingivi u donjoj čeljusti posljedica zuba 48 s dubokim parodontnim džepom. Čini se da je osteonekroza nastala zbog nekroze pulpe zuba 48 te pulpo-parodontnog sindroma i zato je zub izvađen.

Diferencijalna dijagnoza uključuje limfome, sarkome, kronični osteomijelitis, uporabu kokaina, neutropenične ulceracije, lokalne traume nakon stomatološkog zahvata, ozljede koje je izazvao sam pacijent i topikalnu uporabu adstringensa (19).

Nekoliko je mogućnosti za terapiju avitalne kosti. Ona kirurška obično se ne preporučuje jer može uzrokovati daljnju ishemiju kortikalne kosti koja može kompromitirati opskrbu krvlju podležće kosti. Ako je moguće, avitalna se kost ostavlja da sekvencira. Takav fragment kosti ostavlja se da spontano izađe ili se pažljivo uklanja (1). Pacijenti obično dobiju antibiotike, vazodilatatore i kisik u hiperbaričnoj komori ili je potreban kirurški zahvat, no rezultati nisu uvijek dosljedni.

Zaključak

Ovaj slučaj pokazuje da pacijenti s ekspaniranom kosti zbog pulpo-parodontnog sindroma i nekrotične pulpe mogu razviti nekrozu kosti. Ispravno liječenje osteonekroze čeljusti uzrokovane pulpo-parodontnim sindromom sastoji se od ekstrakcije upalom zahvaćenog zuba, uklanjanja nekrotične kosti i granulacijskog tkiva te modelacije okolne kosti.

trauma such as prominence of the mylohyoid ridge on the mandible.

Lingual inclination of the mandibular molars protects the lingual gingiva from irritation during mastication, however in patients with missing molars or in the case of restorations with incorrect contours, food particles are not sufficiently rinsed thus increasing the risk of continuous trauma to the area (1). In our case, the patient had lower molars, albeit necrosis of the jaw was seen, moreover lesion healed after the tooth 48 was extracted. The other possible cause might be the lingual mandibular cortex which was located at the most distant point from the intrabony alveolar arteries that supply the mandible. Therefore, this zone might be more susceptible to sequestration (18).

We believe that the lesion on the lingual mandibular gingiva occurred due to the tooth 48 with a deep periodontal pocket. It seems that osteonecrosis was due to the pulp necrosis on the tooth 48 and consequential pulpal-periodontal syndrome, hence the tooth was surgically removed.

Differential diagnosis might include: lymphomas, sarcoma, chronic osteomyelitis, cocaine abuse, neutropenic ulcerations, local trauma from dental treatment, self-inflicted lesions, topical use of adstringent solutions (19).

The treatment of the avital bone might include several options. Generally, surgical treatment is usually not recommended due to the fact that this might foster further ischemia of the dense cortical bone with probable underlying compromised vascular supply. Whenever possible, avital bone is left to sequester by itself. A bone fragment can be left to spontaneously exfoliate or is carefully removed (1). The patients are usually treated with antibiotics, vasodilators and hyperbaric oxygen or surgical debridement is performed, however the results are very inconsistent.

Conclusion

This case highlights the fact that in some patients bone exposure might develop due to the pulpal-periodontal syndrome i.e. pulp necrosis. An adequate treatment of osteonecrosis due to the pulpal-periodontal syndrome consists of extraction of diseased tooth, removal of the necrotic bone and granulation tissue as well as bone remodelling.

Abstract

Objective: Ischemic bone disease has multifactorial etiologies. Chronic dental infections should be eliminated to prevent osteonecrosis of the jaw. **Case report:** We report an unusual case of osteonecrosis due to the pulpal-periodontal syndrome and subsequent pulp necrosis. A case of 38 year old woman who presented with exposed bone, 8 mm in diameter, in the lingual area of the right lower third molar. The patient was otherwise healthy and was not taking any medications. A detailed medical history showed no previous diseases. Patient denied any type of local trauma. A complete blood count showed no abnormalities. The panoramic radiograph revealed a deep periodontal pocket between teeth 47 and 48. The CBCT revealed a deep periodontal pocket between molars and bone sequestrum of the lingual plate. Topical treatment consisted of adhesive periodontal dressing based on the cellulose and betamethasone ointment together with orabase, without improvement. Therefore, peroral amoxicillin was prescribed for a week. Since there was no improvement, the third molar was removed as well as necrotic bone; the alveolar bone was remodelled and sutures were placed. After suturing, the whole area was covered using intraoral resorbable bandage. Microbial swab of the wound aspirate did not reveal polymorphonuclears or the presence of microorganisms. Microbial swab of the biopsy specimen of the necrotic bone particle and sequestrum showed a large amount of gram-positive cocci, however, polymorphonuclears were not found. Histopathological analysis revealed acute chronic inflammation. One week after the surgery, the area healed completely. **Conclusion:** This case highlights the fact that in some patients bone exposure might develop due to the pulpal-periodontal syndrome i.e. pulp necrosis.

Received: October 10, 2016

Accepted: January 12, 2017

Address for correspondence

Assistant Professor Dragana Gabrić,
DDM, PhD
University of Zagreb
School of Dental Medicine
Department of Oral Surgery
University Hospital Center Zagreb
HR-10000 Zagreb, Gundulićeva 5
phone:+38514802138
dgabric@sfg.hr

Key words

Mandible; Osteonecrosis, Dental Pulp Necrosis; Gram-Positive Cocci

References

1. Farah CS, Savage NW. Oral ulceration with bone sequestration. *Aust Dent J*. 2003 Mar;48(1):61-4.
2. Badros A, Weikel D, Salama A, Goloubeva O, Schneider A, Rapoport A, et al. Osteonecrosis of the jaw in multiple myeloma patients: clinical features and risk factors. *J Clin Oncol*. 2006 Feb 20;24(6):945-52.
3. Topazian R, Goldberg M - editors *Oral and maxillofacial infections*. Philadelphia: WB Saunders; 1987.
4. Jackson I, Malden N. Lingual mucosal ulceration with mandibular sequestration. *Dent Update*. 2007; 34(9):573-4, 576-7.
5. Akman AC, Demiralp B, Güncü GN, Kiremitçi A, Sengün D. Necrosis of gingiva and alveolar bone caused by acid etching and its treatment with subepithelial connective tissue graft. *J Can Dent Assoc*. 2005 Jul-Aug;71(7):477-9.
6. Yavuz MS, Kaya GS, Yalçın E, Aras MH. Mandibular bone necrosis caused by use of arsenic paste during endodontic treatment: two case reports. *Int Endod J*. 2008 Jul;41(7):633-7.
7. Khullar SM, Tvedt D, Chapman K, Herlofson BB. Sixty cases of extreme osteonecrosis and osteomyelitis of the mandible and maxilla in a West African population. *Int J Oral Maxillofac Surg*. 2012 Aug;41(8):978-85.
8. Woodmansey KF, White RK, He J. Osteonecrosis related to intraosseous anesthesia: report of a case. *J Endod*. 2009 Feb;35(2):288-91.
9. Almazroo SA, Chen K, Nascimben L, Woo SB, Treister N. Case report: osteonecrosis of the mandible after laryngoscopy and endotracheal tube placement. *Anesth Analg*. 2010 Aug;111(2):437-41.
10. Magremanne M, Dufresne L, Vervaeet C, Daelemans P, Legrand W. Avascular mandibular necrosis. *Rev Stomatol Chir Maxillofac*. 2007 Dec;108(6):539-42.
11. Fleissig Y, Regev E, Lehman H. Sunitinib related osteonecrosis of jaw: a case report. *Oral Surg Oral Med Oral Pathol Oral Radiol*. 2012 Mar;113(3):e1-3.
12. Salort-Llorca C, Mínguez-Serra MP, Silvestre-Donat FJ. Maxillary osteonecrosis associated to antiangiogenic drugs. *Med Oral Patol Oral Cir Bucal*. 2011 Mar 1;16(2):e137-8. *Med Oral Patol Oral Cir Bucal*. 2011;16(2):e137-8.
13. Serra E, Paolantonio M, Spoto G, Mastrangelo F, Tetè S, Dolci M. Bevacizumab related osteonecrosis of the jaw. *Int J Immunopathol Pharmacol*. 2009 Oct-Dec;22(4):1121-3.
14. Jain MK, Manjunath KS, Jagadish SN. Unusual oral complications of herpes zoster infection: report of a case and review of literature. *Oral Surg Oral Med Oral Pathol Oral Radiol Endod*. 2010 Nov;110(5):e37-41.
15. Pushpanshu K, Kaushik R, Srivastava S, Punyani SR. An unusual complication of tooth exfoliation and osteonecrosis following herpes zoster infection of trigeminal nerve: a case report and literature review. *Minerva Stomatol*. 2013 Jun;62(6):241-5.
16. de Visscher JG, Dietvorst DP, van der Meij EH. Lingual mandibular osteonecrosis. *Ned Tijdschr Tandheelkd*. 2013 Apr;120(4):189-93.
17. Sonnier KE, Horning GM. Spontaneous bony exposure: a report of 4 cases of idiopathic exposure and sequestration of alveolar bone. *J Periodontol*. 1997 Aug;68(8):758-62.
18. Peters E, Lovas GL, Wysocki GP. Lingual mandibular sequestration and ulceration. *Oral Surg Oral Med Oral Pathol*. 1993;75(6):739-43.
19. Megremanne M, Picheca S, Reyckler H. Etiologic diagnosis of jaw osteonecrosis, other than bisphosphonates and radiotherapy related osteonecrosis. *Rev Stomatol Chir Maxillofac Chir Orale*. 2014 Feb;115(1):45-50.