

Expression of small leucine-rich extracellular matrix proteoglycans biglycan and lumican reveals oral lichen planus malignant potential

Lončar-Brzak, Božana; Klobučar, Marko; Veliki-Dalić, Irena; Sabol, Ivan; Kraljević Pavelić, Sandra; Krušlin, Božo; Mravak-Stipetić, Marinka

Source / Izvornik: **Clinical Oral Investigations**, 2018, 22, 1071 - 1082

Journal article, Accepted version

Rad u časopisu, Završna verzija rukopisa prihvaćena za objavljivanje (postprint)

<https://doi.org/10.1007/s00784-017-2190-3>

Permanent link / Trajna poveznica: <https://um.nsk.hr/um:nbn:hr:105:615495>

Rights / Prava: [In copyright](#) / [Zaštićeno autorskim pravom.](#)

Download date / Datum preuzimanja: **2024-05-15**



Repository / Repozitorij:

[Dr Med - University of Zagreb School of Medicine](#)
[Digital Repository](#)



Supplementary material

Immunohistochemistry results of IGF2 and IGF2R expression in normal oral mucosa, OLP and primary OSCC tissue sections

In the CONTROL group, IGF2 expression was not detected in 1 sample (6%) while low positive and moderate positive IGF2 reactivity was found in 13 samples (72%) and 4 samples (22%), respectively (Figure 1 and Figure 2).). In the OLP group, 8 (33%) samples showed low and 7 (29%) samples moderate positive IGF2 reaction while in 9 samples (38%) IGF2 immunoreactivity was not observed (Figure 1). Within the OSCC group, IGF2 positive reaction has not been determined in 4 samples (20%), while weak and moderate or strong positive reactions were determined in 13 (65%) and 3 (15%) samples, respectively (Figure 1). In addition, observed IGF2R immunostaining was mostly intracellular and varied from moderate to strong intensity in majority of analysed samples (Figure 1). In the CONTROL group, 83 % of cases (15 samples) showed strong and 17% (3 samples) moderate IGF2R reactivity while weak and moderate positive IGF2R reactions were not observed (Figure 1). In the OLP group, strong and moderate positive IGF2R reactions were determined in 10 samples (42%), while weak positive and negative IGF2R reactions were determined in 2 samples (8%), respectively (Figure 1). In the OSCC group, IGF2R strong positive reaction has been determined in 11 samples (58%), while moderate and weak positive reactions were determined in 5 (26%) and 4 (21%) samples, respectively (Figure 1). Statistical analysis showed no significant differences in final IGF2 and IGF2R IRS scores between OSCC and CONTROL groups, although a trend of increased IGF2R expression was observed in CONTROL group (data not shown). In addition, statistically significant differences ($p < 0.05$) in final IRS scores between IGF2 and IGF2R between analysed groups were assessed (Figure 3).

Figures




Figure 1. Graphical representation of final IRS scores expressed as percentages (%) of strong, moderate, weak and negative IGF2 (A) and IGF2R (B) reactions in normal mucosa (CONTROL), oral lichen planus (OLP) and primary oral squamous cell carcinoma (OSCC) histological sections. Abbreviations: CONTROL- normal mucosa tissue sections; OLP-oral lichen planus tissue sections; OSCC-primary oral squamous cell carcinoma tissue sections.

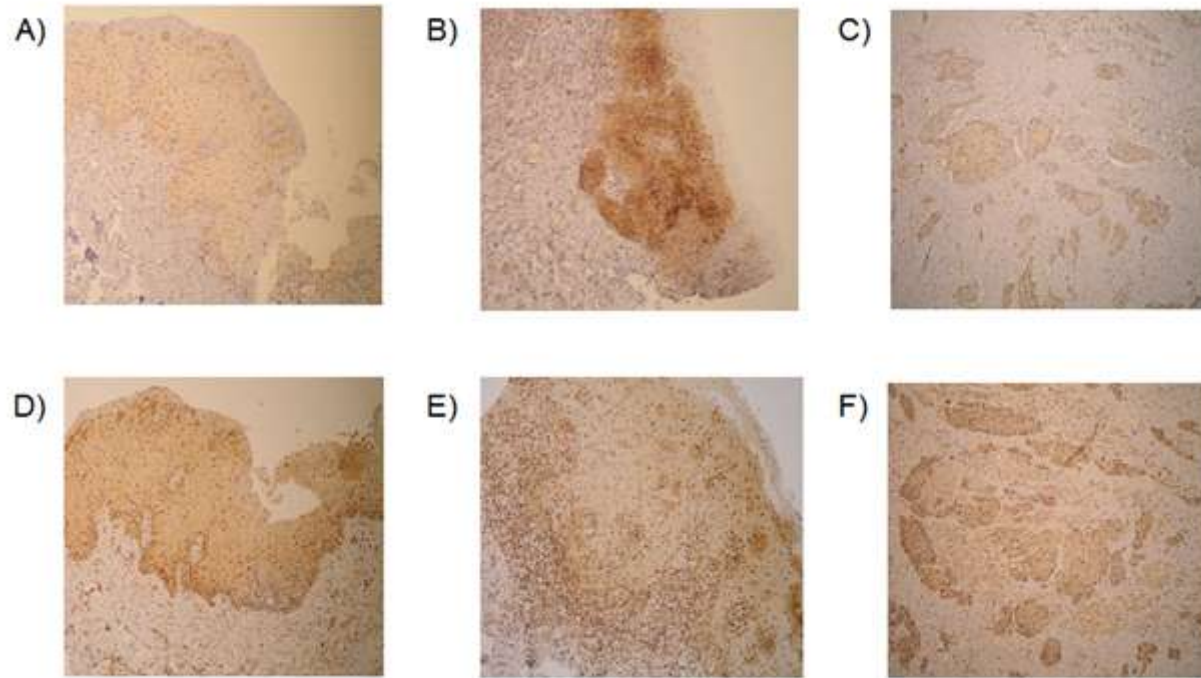


Figure 2. Representative immunohistochemistry pictures. IGF2 and IGF2R staining in normal mucosa, oral lichen planus (OLP) and oral squamous cell carcinoma (OSCC) is visible as brown staining. (A) Weak IGF2 staining intensity in normal mucosa, magnification 200x (B) strong IGF2 staining intensity in OLP, magnification 200x (C) moderate IGF2 staining intensity in OSCC, magnification 100x (D) IGF2R strong staining intensity in normal mucosa, magnification 200x (E) moderate IGF2R staining intensity in OLP, magnification 200x (F) strong IGF2R staining intensity in OSCC, magnification 100x

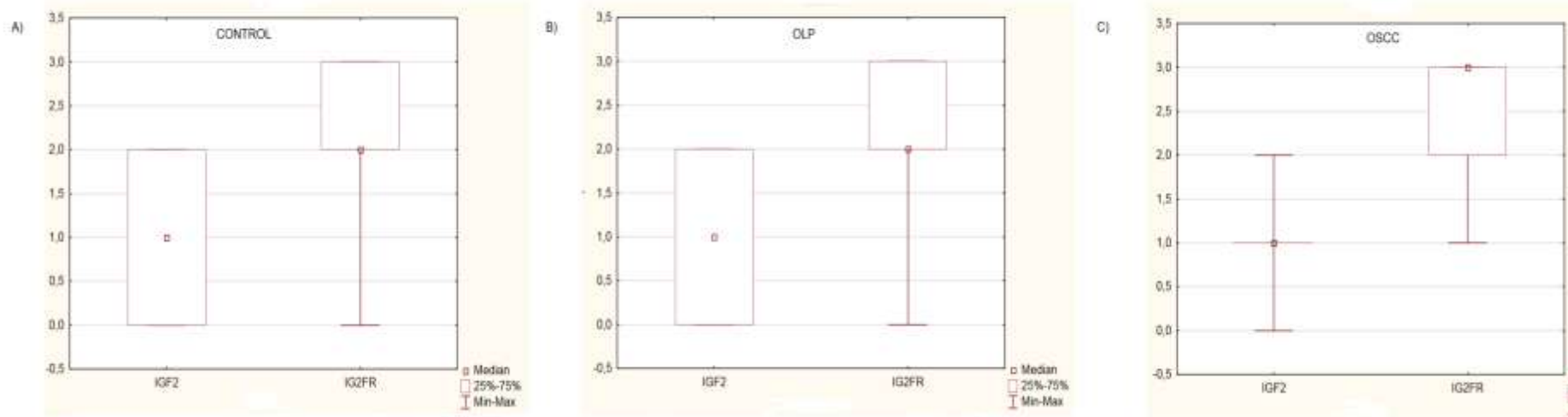


Figure 3. Whisker-Box plot of statistically significant differences ($p < 0.05$) determined for the staining intensity between IGF2 and IGF2R in A) CONTROL group B) OLP group and C) OSCC group of samples. Abbreviations: CONTROL - normal mucosa tissue sections; OLP-oral lichen planus tissue sections; OSCC- primary oral squamous cell carcinoma tissue sections.