

The effect of delayed anti-NMDAR encephalitis recognition on disease outcome

Šulentić, Vlatko; Petelin Gadže, Željka; Derke, Filip; Santini, Marija; Bažadona, Danira; Nanković, Sibila

Source / Izvornik: **Journal of Neurovirology**, 2018, 24, 638 - 641

Journal article, Accepted version

Rad u časopisu, Završna verzija rukopisa prihvaćena za objavljivanje (postprint)

<https://doi.org/10.1007/s13365-018-0648-y>

Permanent link / Trajna poveznica: <https://urn.nsk.hr/urn:nbn:hr:105:552319>

Rights / Prava: [In copyright](#) / [Zaštićeno autorskim pravom.](#)

Download date / Datum preuzimanja: **2024-05-16**



Repository / Repozitorij:

[Dr Med - University of Zagreb School of Medicine
Digital Repository](#)





Središnja medicinska knjižnica

Šulentić V., Petelin Gadže Ž., Derke F., Santini M., Bažadona D., Nanković S. (2018)
The effect of delayed anti-NMDAR encephalitis recognition on disease outcome.
Journal of Neurovirology, 24 (5). pp. 638-641. ISSN 1355-0284

<http://link.springer.com/journal/13365>

<http://dx.doi.org/10.1007/s13365-018-0648-y>

<http://medlib.mef.hr/3531>

University of Zagreb School of Medicine Repository

<http://medlib.mef.hr/>

The effect of delayed anti-NMDAR encephalitis recognition on disease outcome

Sulentic Vlatko¹, Petelin Gadze Zeljka¹, Derke Filip², Santini Marija³, Bazadona Danira¹, Nankovic Sibila¹

¹Department of Neurology, School of Medicine, University of Zagreb, Referral Centre of the Ministry of Health of the Republic of Croatia for Epilepsy, University Hospital Centre Zagreb, Kispaticeva 12, Zagreb 10000, Croatia

²School of Medicine, University of Zagreb, Salata 3, Zagreb, Croatia

³Clinic for Infectious Diseases "Dr. Fran Mihaljević", School of Medicine, University of Zagreb, Mirogojska 8, Zagreb, Croatia

Corresponding author:

Filip Derke
e-mail address: fderke@me.com
tel: 00385 1 2388 374
fax: 00385 1 2376 021

University of Zagreb
School of Medicine
Salata 3, HR- 10 000 Zagreb,

Keywords:

anti-NMDAR encephalitis, autoimmune encephalitis, cognitive disorders, treatment outcome

TITLE:

The effect of delayed anti-NMDAR encephalitis recognition on disease outcome

ABSTRACT:

Anti-NMDA receptor encephalitis is an acute form of brain inflammation that is potentially lethal but has a high probability for recovery with treatment. Although the clinical picture of anti-NMDAR encephalitis is usually recognizable due to its relatively well known symptoms the disorder can sometimes present itself in an unpredictable and atypical way. In this case report we wish to present the influence of different delay times prior to the establishment of diagnosis. Thus, our first patient was diagnosed with anti-NMDAR encephalitis four years after the initial symptoms, the second one after eight years and the third one after thirteen months. The outcomes of the three presented patients indicate the importance of being aware of many clinical presentations of this disorder, as its early diagnosis greatly affects the outcome and may reduce permanent damage, especially in cognitive functions.

TEXT:

Anti-N-Methyl-D-aspartate receptor (NMDAR) encephalitis is an autoimmune disorder characterized by the presence of specific IgG antibodies against heteromers of NR1 and NR2 subunits of cell-surface NMDA receptors which can be found in serum or cerebral spinal fluid (CSF). Although it can be a pure autoimmune disorder, anti-NMDAR encephalitis is frequently associated with an underlying malignancy, commonly occult ovarian teratoma (Titulaer et al. 2013). The disease symptoms are relatively well known and in the majority of cases it usually has a good outcome (Graus et al. 2016; Dalmau et al. 2011). However, clinical picture of this multiphasic disorder can sometimes be unpredictable and atypical, leading to a delay in the diagnosis establishment. It is usually evident in encephalitis presenting exclusively with psychiatric symptoms. The major problem is a lack of the characteristic ones that would imply the need for specific antibody testing, which usually leads to prolonged and more demanding treatment with increased tendency of worse outcome, cognitive impairment and unpredictable relapses (Herken and Pruss 2017; Kayser et al. 2013).

We are presenting three case reports with different time lapse to diagnosis establishment and successfulness of immunosuppression treatment.

Case report 1

At the age of seventeen a female patient was admitted to a psychiatry clinic due to psychomotor agitation, anxiety, disorganization of thoughts, logorrhea, cognitive impairment, visual and auditory hallucinations and insomnia. In spite of initiated antipsychotic therapy (olanzapine, risperidone, quetiapine, clozapine and sodium valproate) she developed catatonia and incontinence. Her EEG recording showed predominant beta activity, brain MRI was unremarkable, while CSF tests revealed mild pleocytosis (55/3) with lymphocyte predomination. On haloperidol and later ziprasidone her psychiatric condition ameliorated and for the next four years she was in remission. At the age of twenty-one she developed

relapse characterized by auditory hallucinations, insomnia, disorganized behavior and psychomotor agitation with fever and elevated creatine kinase. Soon after she also developed quantitative disorder of consciousness, generalized tonic-clonic seizures that were treated successfully with levetiracetam, autonomic dysfunction and respiratory insufficiency. At that point NMDAR antibodies were isolated both in serum and CSF. Corticosteroid therapy followed by plasmapheresis was conducted without any significant improvement and still in need of mechanical ventilation. The induction of cyclophosphamide led to complete symptom resolution and two years after she is still seizure free and without any symptoms (mRS 0).

Case report 2

Nineteen-year-old patient was admitted to our Department of Neurology due to status epilepticus. Her previous medical history revealed frequent hospitalizations in pediatric intensive care unit due to status epilepticus, prolonged disorder of consciousness, respiratory insufficiency, autonomic instability with sometimes cognitive impairment, language difficulties and associated dyskinesias. In the eight-year-period she has been hospitalized approximately once a year. Although extensive diagnostic workup was conducted, no etiological factor was found. During that period she was treated with corticosteroid therapy but there was no clear data of their effectiveness and no other immunosuppressive treatment was applied. At the admission to our hospital she was in convulsive status epilepticus with autonomic dysfunction and in need of mechanical ventilation. Brain MRI showed unspecific T2 and FLAIR hyperintensities (figure 1) and additional workup revealed NMDAR antibodies in serum and CSF. She was treated with corticosteroid therapy followed by six cycles of intravenous immunoglobulin and, at last, cyclophosphamide, which led to resolution of status epilepticus and other aforementioned symptoms. In a four-year period there was no disease relapse, but she still has focal seizures, despite three antiepileptic drugs (oxcarbazepine, levetiracetam and clobazam), as well as mild cognitive impairment (mRS 1).

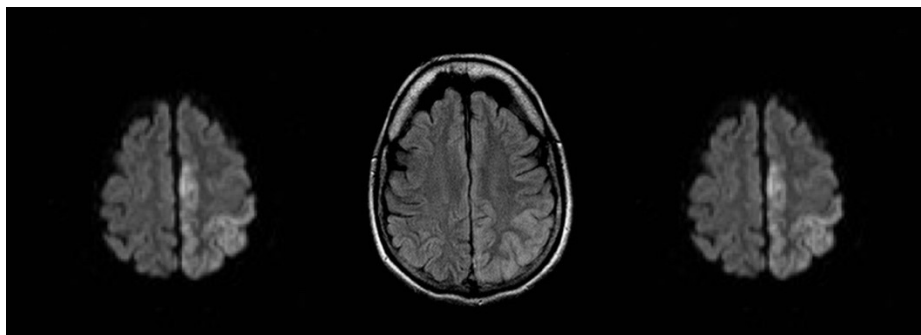


Figure 1. The brain MRI of the patient in second case report showing unspecific T2 and FLAIR hyperintensities.

Case report 3

Our third patient had focal aware sensory and cognitive (vertiginous sensations, blurring of vision, derealisation and depersonalisation) seizures with interictal concentration and behavior changes since the age of sixteen. Her brain MRI showed T2 and FLAIR hyperintensity in the left temporal lobe (figure 2), CSF pleocytosis, type II oligoclonal bands and left temporal focal EEG changes. After including

oxcarbazepine in the therapy her seizures were under control as were her psychiatric symptoms. Diagnostic workup revealed no etiological factor of her condition. Brain MRI conducted 3 months later was without any pathological changes. After eight months her seizures started again, this time with evolution to bilateral tonic-clonic convulsions. Repeated brain MRI was unremarkable (figure 3) as was EEG recording. CSF analysis was still showing oligoclonal bands type II. In the next few weeks she experienced cognitive and psychic deterioration (disorientation in time and space, inadequacy in contact without understanding of instructions, she was hostile, had dissociated thoughts with confabulations, inadequate answers, difficulties in reconstruction of events, delusions and deterioration of cognitive functions). During the two months period large number of typical and atypical antipsychotics were used without any improvement. She was then transferred to our Department and corticosteroid therapy was started with mild improvement of mental functions, but with persistent epileptic seizures. After proving NMDAR antibodies in serum and CSF, intravenous immunoglobulin therapy was started in combination with oxcarbazepine, with complete resolution of symptoms (mRS 0). She is without relapse for more than one year now.

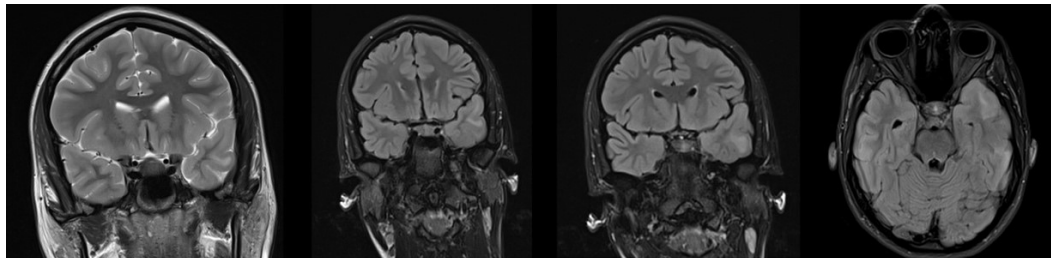


Figure 2. The brain MRI of the patient in third case report showing T2 and FLAIR hyperintensity in the left temporal lobe

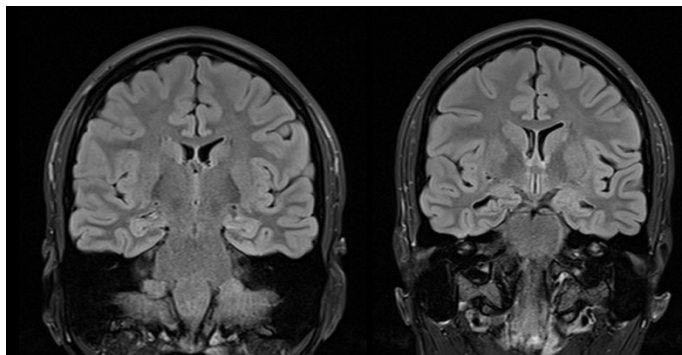


Figure 3. The brain MRI of the patient in third case report after eight months.

In neither of three patients malignancy was found on frequent controls according to Bonn protocol (Bien et al. 2007).

Discussion and conclusion

In our three patients anti-NMDAR encephalitis was diagnosed one or more years after the initial presentation. Symptomatology, disease progression, MRI findings, frequency and time of relapses were different in all three cases. The most common cause of prolonged time to diagnosis establishment is

unawareness of psychiatric symptoms as possible initial presentation of anti-NMDAR encephalitis. It is widely known that 77% of patients are initially presented with psychiatric changes (Herken and Pruss 2017; Dalmau et al. 2008; Barry et al. 2011; Chapman et al. 2011; Lejuste et al. 2016). Psychiatric symptoms were initially present in our three patients, being the dominant symptom in the two of them. Relapses have been reported in approximately 10-29% of anti-NMDAR encephalitis cases, being more common in patients without malignancies, which was also the case in our three patients (Titulaer et al. 2013; Dalmau et al. 2011; Irani et al. 2011).

Although randomized controlled trials of anti-NMDAR encephalitis therapy are yet to be conducted, large retrospective studies suggest that good prognosis, including fewer relapses, is associated with early diagnosis and treatment, milder symptoms, and removal of tumor when present (Dalmau et al. 2011; Irani et al. 2011; Gabilondo et al. 2011). In our three cases relapses were present in different time intervals without adequate immunosuppressive treatment. The first patient had relapse few years after the initial presentation while the other one had disease outbreak before the discovery of specific antibodies. In the third case, relapses occurred despite the withdrawal of changes in brain MRI. In all the cases corticosteroid therapy was inadequate as a first line of treatment in relapses. The administration of immunoglobulin, cyclophosphamid or rituximab was necessary. In correlation with other studies it is possible that early administration of immunoglobulin therapy or plasmapheresis could have better results and prevent relapses (Titulaer et al. 2013; Gabilondo et al. 2011; Barry et al. 2015; Venkatesan and Adatia 2017). Late diagnosis establishment can probably cause permanent damage especially in cognitive functions (McKneon et al. 2018; Finke et al. 2018). In spite of delayed diagnosis in our case series, there was no permanent cognitive damage in two patients and the third one with frequent relapses had mild cognitive impairment and pharmacoresistant seizures. The permanent cognitive damage is probably due to repetitive status epilepticus, longer disease duration and more frequent relapses (Sutter et al. 2013; Lergiel et al. 2008).

All three cases had beneficial outcome in spite of delayed diagnostic process which could be due to the lack of the underlying malignancy or to a natural history of the disease which can sometimes be benign. Nevertheless, the timely diagnosis establishment is of the highest priority, considering that early treatment could prevent progression to consciousness impairment, autonomic dysfunction, respiratory insufficiency and the need for intensive care unit treatment (de Montmollin et al 2017).

Anti-NMDAR encephalitis can have different initial presentations, disease course, relapse frequency, treatment response and outcome. The recognition of the aforementioned variations can help in timely and adequate treatment administration and improve the final outcome of anti-NMDAR encephalitis patients.

Authors contribution: VS and ZPG prepared the case report. ZPG, SN and VS are consultant neurologist responsible for the care of the patients. MS has been consulted as a specialist in infectious diseases and intensive medicine. DB and FD are responsible for the reference managing and preparing the text for submission.

Conflicts of interests: The authors declare that they have no conflict of interest.

References:

- Barry, H, Hardiman, O, Healz, DG, Keogan, M, Moroney, J, Molnar, PP, Cotter, DR, Murphy, KC (2011). Anti NMDA receptor encephalitis: an important differential diagnosis in psychosis. *Br J Psychiatry*, 199(6):508-9. doi: 10.1192/bjp.bp.111.092197
- Barry, H, Byrne, S, Barrett, E, Murphy, KC, Cotter, DR (2015). Anti-N-methyl D-aspartate receptor encephalitis: review of clinical presentation, diagnosis and treatment. *BJPsych Bull*, 39(1):19-23. doi: 10.1192/pb.bp.113.045518
- Bien, CG, Elger, CE (2007). Limbic encephalitis: A cause of temporal lobe epilepsy with onset in adult life. *Epilepsy Behav*, 10(4):529-38.
- Chapman MR, Vause HE (2011). Anti NMDA receptor encephalitis: diagnosis, psychiatric presentation, and treatment. *Am J Psychiatry*, 168(3):245-51. doi: 10.1176/appi.ajp.2010.10020181
- Dalmau, J, Gleichman, AJ, Hughes, EG, Rossi, JE, Peng, X, Lai, M, Dessain, SK, Rosenfeld, MR, Balice-Gordon, R, Lynch, DR (2008). Anti-NMDA-receptor encephalitis: case series and analysis of the effects of antibodies. *Lancet Neurol*, 7(12):1091-8. doi: 10.1016/S1474-4422(08)70224-2
- Dalmau, J, Lancaster, E, Martinez-Hernandez, E, Rosenfeld, MR, Balice-Gordon, R (2011). Clinical experience and laboratory investigations in patients with anti-NMDAR encephalitis. *Lancet Neurol*, 10(1):63-74. doi: 10.1016/S1474-4422(10)70253-2
- de Montmollin, E, Demeret, S, Brulé, N, Conrad, M, Dailler, F, Lerolle, N, Navellou, JC, Schwebel, C, Alves, M, Cour, M, Engrand, N, Tonnelier JM, Maury, E, Ruckly, S, Picard, G, Rogemond, V, Magalhaes, É, Sharshar, T, Timsit, JF, Honnorat, J, Sonnevile, R (2017). Anti-N-Methyl-d-Aspartate Receptor Encephalitis in Adult Patients Requiring Intensive Care. *Am J Respir Crit Care Med*, 195(4):491-499. doi: 10.1164/rccm.201603-0507OC
- Finke, C, Kopp, UA, Pruss, H, Dalmau, J, Wandinger, K-P, Ploner, CJ (2018). Cognitive deficits following anti-NMDA receptor encephalitis. *J Clin Exp Neuropsychol*, 40(3):234-252. doi: 10.1080/13803395.2017.1329408
- Gabilondo I, Saiz A, Galan L, González, V, Jadraque, R, Sabater, L, Sans, A, Sempere, A, Vela, A, Villalobos, F, Viñals, M, Villoslada, P, Graus F (2011). Analysis of relapses in anti-NMDAR encephalitis. *Neurology*, 77(10):996-9. doi: 10.1212/WNL.0b013e31822cfc6b
- Graus F, Titulaer MJ, Balu R, Benseler, S, Bien, CG, Cellucci, T, Cortese, I, Dale, RC, Gelfand, JM, Geschwind, M, Glaser, CA, Honnorat, J, Höftberger, R, Iizuka, T, Irani, SR, Lancaster, E, Leypoldt, F, Prüss, H, Rae-Grant, A, Reindl, M, Rosenfeld, MR, Rostásy, K, Saiz, A, Venkatesan, A, Vincent, A, Wandinger, KP, Waters, P, Dalmau, J (2016). A clinical approach to diagnosis of autoimmune encephalitis. *Lancet Neurol*, 15(4):391-404. doi: 10.1016/S1474-4422(15)00401-9

Herken, J, Pruss, H (2017). Red flags: Clinical signs for Identifying Autoimmune Encephalitis in Psychiatric Patients. *Front Psychiatry*, 16;8:25. doi: 10.3389/fpsyt.2017.00025

Irani, SR, Bera, L, Waters, P, González, V, Jadraque, R, Sabater, L, Sans, A, Sempere, A, Vela, A, Villalobos, F, Viñals, M, Villoslada, P, Graus, F (2011). N-methyl-D-aspartate receptor (NMDAR) encephalitis: temporal progression of clinical and paraclinical observations in a predominantly non paraneoplastic disorders of both sexes. *Neurology*, 6;77(10):996-9. doi: 10.1212/WNL.0b013e31822cfc6b

Kayser, MS, Titulaer, MJ, Gresa-Arribas, N, Dalmau, J (2013). Frequency and characteristics of isolated psychiatric episodes in anti-N-methyl-d-aspartate receptor encephalitis. *JAMA Neurol*, 1;70(9):1133-9.

Lejste, F, Thomas, L, Picard, G, Desestret, V, Ducray, F, Rogemond, V, Psimaras, D, Antoine, JC, Delattre, JY, Groc, L, Leboyer, M, Honnorat, J (2016). Neuroleptic intolerance in patients with anti-NMDAR encephalitis. *Neurol Neuroimmunol Neuroinflamm*, 29;3(5):e280. doi: 10.1212/NXI.0000000000000280

Lergiel, S, Mourvillier, B, Bele, N, Amro, J, Fouet, P, Manet, P, Hilpert, F (2008). Outcomes in 140 critically ill patients with status epilepticus. *Intensive Care Med*. 2008 Mar;34(3):476-80.

McKneon GL, Robinson GA, Ryan AE, Blum S, Gillis, D, Finke, C, Scott, JG (2018). Cognitive outcomes following anti N-methyl-D-aspartate receptor encephalitis: A systematic review. *J Clin Exp Neuropsychol*, 40(3):234-252. doi: 10.1080/13803395.2017.1329408

Sutter R, Marsch S, Fuhr P, Rüegg S (2013). Mortality and recovery from refractory status epilepticus in the intensive care unit: a 7-year observational study. *Epilepsia*, 54(3):502–11.

Titulaer, MJ, McCracken, L, Gabilondo, I, Armangué, T, Glaser, C, Iizuka, T, Honig, LS, Benseler, SM, Kawachi, I, Martinez-Hernandez, E, Aguilar, E, Gresa-Arribas, N, Ryan-Flanagan, N, Torrents, A, Saiz, A, Rosenfeld, MR, Balice-Gordon, R, Graus, F, Dalmau, J (2013). Treatment and prognostic factors for long-term outcome in patients with anti-N-Methyl-D-aspartate (NMDA) receptor encephalitis: a cohort study. *Lancet Neurol*, 12: 157-165. doi: 10.1016/S1474-4422(12)70310-1

Venkatesan A, Adatia K (2017). Anti-NMDA-Receptor Encephalitis: From Bench to Clinic. *ACS Chem Neurosci*, 20;8(12):2586-2595. doi: 10.1021/acscchemneuro.7b00319