

Current concepts in the diagnosis of transverse myelopathies

Brinar, Vesna V.; Habek, Mario; Zadro, Ivana; Barun, Barbara; Ozretić, David; Vranješ, Davorka

Source / Izvornik: **Clinical Neurology and Neurosurgery, 2008, 110, 919 - 927**

Journal article, Accepted version

Rad u časopisu, Završna verzija rukopisa prihvaćena za objavljivanje (postprint)

<https://doi.org/10.1016/j.clineuro.2008.07.002>

Permanent link / Trajna poveznica: <https://urn.nsk.hr/urn:nbn:hr:105:054724>

Rights / Prava: [In copyright](#) / [Zaštićeno autorskim pravom.](#)

Download date / Datum preuzimanja: **2024-06-01**



Repository / Repozitorij:

[Dr Med - University of Zagreb School of Medicine
Digital Repository](#)





Središnja medicinska knjižnica

Brinar, V. V., Habek, M., Zadro, I., Barun, B., Ozretić, D., Vranješ, D. (2008)
Current concepts in the diagnosis of transverse myelopathies. Clinical Neurology
and Neurosurgery, [Epub ahead of print, Corrected Proof].

<http://www.elsevier.com/locate/issn/0303-8467>

<http://dx.doi.org/10.1016/j.clineuro.2008.07.002>

<http://medlib.mef.hr/417>

University of Zagreb Medical School Repository

<http://medlib.mef.hr/>

Current concepts in the diagnosis of transverse myelopathies

Vesna V. Brinar,¹ Mario Habek,¹ Ivana Zadro¹, Barbara Barun¹, David Ozretić² and Davorka Vranješ¹

From the: From the:

¹Referral Center for Demyelinating diseases of the Central Nervous System, University Department of Neurology, Zagreb School of Medicine and University Hospital Center, Zagreb, Croatia

²Department of Radiology, Zagreb School of Medicine and University Hospital Center, Zagreb, Croatia

CORRESPONDENCE

Mario Habek

Referral Center for Demyelinating diseases of the Central Nervous System, University Department of Neurology, Zagreb School of Medicine and University Hospital Center, Zagreb, Croatia

P: +38512421891; F: +38512421891; E-mail: mhabek@mef.hr

Word count: 2042

Role of the funding source: none.

Aknowledgements: None.

Conflict of interest: None.

Abstract

The clinical symptoms and MRI characteristics of transverse myelopathy (TM) due to non-compressive causes are reviewed, with special emphasis on the differential diagnosis between inflammatory demyelinating lesions, and metabolic and vascular myelopathies. Inflammatory transverse myelopathies are the commonest and most difficult ones to identify. The differentiation between clinically isolated syndromes, multiple sclerosis, neuromyelitis optica, acute disseminated encephalomyelitis and metabolic causes is based on both clinical symptoms and paraclinical signs including magnetic resonance imaging, cerebrospinal fluid analysis, and immunologic and biochemical parameters. The most intriguing form of TM is that where there is clinical evidence of complete spinal cord transection, with normal findings in magnetic resonance imaging in the acute phase, but subsequent cord atrophy.

KEYWORDS

Transverse myelopathies, neuromyelitis optica, disseminated encephalomyelitis, clinically isolated syndrome, multiple sclerosis

Introduction

The clinical symptoms of complete or incomplete transverse myelopathy (TM) indicate the presence of a lesion of the spinal cord in need of urgent therapy. However, the exact diagnosis is often complicated by extensive differential diagnosis (1,2,3,). Transverse myelopathies may result from pathogenetically heterogeneous disorders of the spinal cord. Although they are most commonly inflammatory in origin, including autoimmune disorders such as systemic lupus erythematosus (4), Sjögren's syndrome (5,6), antiphospholipid antibody syndrome (7), mixed connective tissue disease (8), systemic sclerosis (9), ankylosing spondylitis (10) and sarcoidosis (11), vascular and metabolic causes are more common than usually suspected. TM can also result from different bacterial or viral infections (12-16).

In addition to its rapid clinical development, clues to the exact diagnosis of TM will be obtained from cerebrospinal fluid (CSF) analysis, magnetic resonance imaging (MRI), neurophysiological features and immunological studies. Spinal cord MRI is very important in order to exclude compressive lesions of the spinal cord (17,18,19).

Inflammatory lesions often produce local enlargement of the spinal cord and increased signal intensity on T2 weighted sequences of MRI (17). However, in some cases it is difficult to differentiate inflammatory lesions from intramedullary tumors, compressive spinal cord diseases (17,18,19), hematomas, and ischemic events. CSF study is mostly useful in identifying bacterial and viral infections; biochemical parameters such as deficiencies of vitamins E and B12, and serum copper levels can rule out other metabolic etiologies of myelopathy.

Inflammatory myelopathies

Inflammation is not only the commonest basis of TM but is also the most difficult to differentiate. The majority of incomplete TM in young persons are diagnosed as multiple sclerosis (MS) (20,21,22) or clinically isolated syndrome (CIS) . This was the case in our previous study where 31 patients with TM: six cases were originally called CIS ,who all later converted to MS (2). The clinical symptoms in CIS are characterized by dominant and asymmetrical sensory signs and symptoms, mostly paraesthesias, usually slowly spreading from the legs to the upper part of the body, more pronounced on one side, often with a band-like sensation or pressure around the abdomen or chest. MRI is also quite typical with small demyelinating lesions, involving less than two segments, most often located in the posterior or lateral part of the spinal cord (22,23) (Fig 1). Patients with MS commonly also have demyelinating lesions of the brain, while in CIS, spinal lesions are the only sign of disease (Fig 1,2). There is a small group of patients with isolated spinal cord demyelination and typical relapsing course for many years, sometimes called spinal MS. In MS, and often in CIS oligoclonal bands (OCB) are present in the CSF. Even in fulminating MS, MRI of the spinal cord is most typical, although brain MRI may point to other differential diagnosis, eg to DEM or granulomatous demyelination as it is seen in presented case (Fig 3).

Another diagnostic problem is posed by patients with, more or less symmetrical TM and with long hyperintense MRI lesions, involving three or more segments of the spinal cord, the so-called longitudinal extensive transverse myelitis (LETM). The TM may be associated with optic neuritis. Nowadays such patients are designated as part of the

neuromyelitis optica (NMO) spectrum (24). The differential diagnosis of patients with LETM is quite complex. The typical NMO consists of a LETM, occupying the central gray matter in the acute stage (24, 25). The symptoms are rarely monophasic, more often aggressively relapsing, limited to the optic nerve and spinal cord, mostly sparing the brain (25-27). For a long time NMO was regarded as an MS variant, although the clinical symptoms were different. ON in NMO tends to be more severe and leaves a more severe visual impairment compared to attacks of ON in the context of MS, although the clinical presentation of ON in both diseases is similar. Spinal cord relapses typically consist of a complete TM myelitis with bilateral motor weakness, a sensory level, sphincter dysfunction, prominent dysesthetic and even radicular pain. Brain stem involvement can occur, usually as an extension of a severe cervical myelitis, and may cause hiccups, intractable nausea, or respiratory failure (26,28). Paroxysmal tonic spasms are more common in NMO compared with prototypic MS. This characteristic symptom of demyelination is believed to represent ephaptic transmission across demyelinated axons (27,29). The finding that some cases of NMO are associated with a highly specific serum autoantibody marker aquaporin-4 antibody, also known as the “NMO-IgG,” makes possible to differentiate NMO from MS (27-29). Specific serum autoantibody marker (NMO-IgG) against aquaporin 4 derived from peripheral B cells cause the activation of complement, inflammatory demyelination and necrosis typical for NMO (Fig 4). Whether NMO-IgG titers correlate with disease and attack severity or favorable response to therapy is unknown (30). As NMO-IgG can be detected at the first attack of myelitis or ON, this suggests that the antibody is more likely an integral part of the pathogenesis of the disease rather than an epiphenomenon of the tissue injury (27,29,30). In seropositive

patients who are presented with typical or limited clinical symptoms of NMO, immediate treatment with corticosteroids or plasmapheresis in more serious clinical presentation is necessary (31). Patients also need preventive treatment with azathioprine or mycophenolate mofetil. Seronegative patients with clinical symptoms of NMO (Fig 4) should be treated in the same manner (31). While in our previous study three patients out of 31 presented with seronegative NMO, in recent years new 3 seropositive patients were identified. NMO antibodies are very important in the diagnosis of other patients with LETM. However around 30% of patients presenting with NMO symptoms are NMO negative (Fig 5). On the other hand, there are several reports of seropositivity in patients with classical MS (32).

In some instances, severe clinical symptoms, like tetraparesis or respiratory insufficiency, should raise suspicion for NMO (fig 6) despite the absence of the specific LETM lesion on MRI.

Neuromyelitis optica and autoimmune diseases

LETM or NMO or both are known complications of systemic lupus erythematosus (SLE) or Sjögren's syndrome (SS) although some patients may lack sufficient clinical manifestations for their formal diagnosis (33-35). A pathophysiological link between SLE and NMO has not yet been established, although some authors have suggested a role for lupus anticoagulant, and antinuclear antibody (ANA) in the development of CNS lesions. Approximately half the patients with NMO and connective tissue disorders are seropositive for NMO-IgG, whereas patients with SLE or SS who do not have manifestations of NMO are uniformly seronegative (35) (Fig 7). It is likely that these

patients have two coexisting autoimmune disorders rather than a vasculitic complication of a systemic autoimmune disease such as SLE or SS (35, 36). Similarly, NMO may coexist with myasthenia gravis or other systemic autoimmune diseases (37, 38) (Fig 8).

Parainfectious or postinfectious TM are not rare although the triggering infectious agent is identified in only very few patients (39,40). Parainfectious or postvaccinal demyelinating disorders of the CNS are characterized by signs of encephalopathy, meningismus and multifocal signs of CNS dysfunctions, and are diagnosed as acute disseminated encephalomyelitis (ADEM (39,40). Brain MRI reveals multiple medium-sized or large white matter lesions, also involving the deep grey matter as well as cortical structures (39-42). ADEM may also present as isolated LETM (Fig 9). The selective involvement of the posterior columns is, in a way, similar to what is seen in NMO. It suggest that these parts of the CNS are immunologically more vulnerable (39-42). Previous respiratory infection, and mild , monophasic course of the disease of this particular patient point to the diagnosis of ADEM and against NMO. In our previous study of TM, 11 of 31 patients were diagnosed as DEM.

Recently, gadolinium enhancement (GDE) was explained as a diagnostic parameter that may help in differentiating between ADEM and NMO (43,44). The former, without lesion enhancement in MRI may represent a manifestation of NMO. The lack of enhancement suggests an intact blood-brain barrier and supports a unique mechanism of edema induction due to dysfunction of water channels (43). But in some cases, especially in cases with a subacute course, spinal cord demyelination is not followed by GDE

enhancement(40,41). In such patients right diagnosis is based on follow up , especially in patients without LEMT. Some of these patients (Fig 10) in the future will develop MS. A different diagnostic problem is encountered in patients who develop a complete transverse spinal syndrome without signs of demyelination or other abnormalities of the spinal cord in MRI. Two such patients were young women. One developed pain in the back after swimming and within a few minutes developed severe flaccid paraparesis and urinary incontinence. Brain and entire spinal cord MRI were normal. After a month she developed severe spastic paraparesis, and her spinal MRI showed only atrophic changes. The neurologic deficit had remained unchanged. Similar symptoms developed in another young woman, with the sudden onset of paraplegia, urinary incontinence and a sensory level below T9. Spinal and brain MRI were normal. After a few months she still had severe spastic paraparesis with the same sensory level below T9 and atrophy in T10-T11 was identified in spinal cord MRI.

In our previous study four of our 31 patients had the similar osent symptoms and clinical course. (2)

Analysis of the CSF in these patients with normal spinal MRI, demonstrated the presence of OCB or elevated protein levels, but no vigorous inflammatory reaction, along with the lack of demyelination, suggest that parenchymatous neurons are the sites of the pathologic involvement, and are are analogous to the acute lesions of axonal polyneuropathy. Such cases could be variants of DEM although similar cases **were** described in patient with SLE and was regarded as part of NMO spectrum (45). It was found that about 40% of acute transverse myelopathies cannot be documented by MRI (17)

Metabolic myelopathies

Metabolic myelopathies most commonly occur in patients with vitamin B12 (cyanocobalamin) (Fig. 11), copper (Cu) and vitamin E deficiencies (46,47). The neurological manifestations may be the earliest and not infrequently the only signs of B12 deficiency. They may have a relatively sudden onset, that include spastic paraparesis, impaired perception of joint position and vibration, commonly involving the hands (Fig 11). The myelopathy may be associated with neuropathy, cognitive impairment and paraesthesias. MRI of the spinal cord typically shows hyperintensive changes, mainly involving the posterior and lateral columns (46). Contrast enhancement may be present. Cu deficiency is caused by low serum copper due to malabsorption, gastric surgery, or excessive zinc consumption. The clinical symptoms are characterized by myelopathy that resembles subacute combined degeneration seen in B12 deficiency. MRI similarly shows increased signal involving the dorsal and lateral column (47).

Vascular myelopathies

Vascular myelopathies may arise from haemorrhage, infarction, a vascular 'steal' syndrome, or venous congestion (48). Spinal ischaemia may be due to vasculitis (polyarteritis nodosa, Behcet disease, giant cell arteritis), systemic hypoperfusion (in cardiac arrest, aortic rupture, aortic dissection or coarctation), embolism (atrial myxoma, mitral disease, endocarditis, fibrocartilaginous emboli from a ruptured intervertebral disc) and infectious causes (syphilitic arteritis, bacterial meningitis) (48,49). The symptoms of spinal cord ischaemia are often stuttering or stepwise, and not necessarily maximal at

onset. The clinical symptom may include spastic paraparesis or tetraparesis, dissociation of sensation, and perseveration of proprioception that are typical for vascular lesions of the spinal cord. MRI in vascular TM is characterized by pencil-like lesions in the anterior part of the spinal cord with typical hypodense and hyperintense long lesions (Fig 12). Diffuse weight imaging (DWI) is promising but mostly not helpful.

Conclusion

The differential diagnosis of TM is complex due to the heterogeneity of the pathological processes. In MS, the most common inflammatory disorder of the spinal cord, the differential diagnosis is relatively simple. Differentiation of NMO, especially of the NMO spectrum is more difficult, and it is especially important to differentiate seronegative NMO from DEM. Spinal cord DEM is remarkably similar in many aspects to NMO. Differentiation according to GDE is unreliable.

It has been suggested that patients with multifocal lesions in the spinal cord, demyelinating lesions in the brain and optic nerves, OCB in the CSF and clinical or laboratory evidence of systemic autoimmune disorder are at greater risk of recurrence of TM. A special problem is the patient with symmetrical spastic paraparesis or tetraparesis, but without hyperintense or other lesions in spinal cord MR, who subsequently develop severe cord atrophy.

REFERENCES

- 1) Transverse Myelitis Consortium Working Group. Proposed diagnostic criteria and nosology of acute transverse myelitis. *Neurology* 2002;59:499–505.
- 2) Brinar V, Habek M, Brinar M, et al. The differential diagnosis of acute transverse myelitis. *Clin Neurol Neurosurg* 2006;108:278-83.
- 3) Harzheim M, Schlegel U, Urbach H, et al. Discriminatory features of acute transverse myelitis: a retrospective analysis of 45 patients. *J Neurol Sci* 2004;217;217-223.
- 4) Krishnan A, Halmagyi G. Acute transverse myelitis in SLE. *Neurology* 2004;62: 2087.
- 5) Anantharaju A, Baluch M, Van Thiel DH. Transverse myelitis occurring in association with primary biliary cirrhosis and Sjögren's syndrome. *Dig Dis Sci* 2003;48:830-3.
- 6) Hummers L, Krishnan C, Casciola-Rosen L, et al. Recurrent transverse myelitis associates with anti-Ro (SSA) autoantibodies. *Neurology* 2004;62:147-9.
- 7) Lee D, Jeon H, Yoo W. Transverse myelitis in a patient with primary antiphospholipid syndrome. *Yonsei Med J* 2003;44:323-7.
- 8) Mok C, Lau C. Transverse myelopathy complicating mixed connective tissue disease. *Clin Neurol Neurosurg* 1995;97:259-60.
- 9) Torabi A, Patel R, Wolfe G, et al. Transverse myelitis in systemic sclerosis. *Arch Neurol* 2004;61:126-8.
- 10) Oh D, Jun J, Kim H, et al. Transverse myelitis in a patient with long-standing ankylosing spondylitis. *Clin Exp Rheumatol* 2001;19:195-6.

- 11) Kumar N, Frohman EM. Spinal neurosarcoidosis mimicking an idiopathic inflammatory demyelinating syndrome. *Arch Neurol* 2004;61:586-9.
- 12) Mantiene C, Albucher J, Catala I, et al. MRI in Lyme disease of the spinal cord. *Neuroradiology* 2001;43:485-8.
- 13) Mills R, Schoolfield L. Acute transverse myelitis associated with *Mycoplasma pneumoniae* infection: a case report and review of the literature. *Pediat Infect Dis J* 1992;11:228-31.
- 14) Dodson D. Transverse myelitis and spastic paraparesis in a patient with HIV infection. *N Engl J Med* 1990;322:1322.
- 15) Junker A, Roland E, Hahn G. Transverse myelitis and Epstein-Barr virus infection with delayed antibody responses. *Neurology* 1991;41:1523.
- 16) Fux C, Pfister S, Nohl F, et al. Cytomegalovirus-associated acute transverse myelitis in immunocompetent adults. *Clin Microbiol Infect* 2003;9:1187-90.
- 17) Scotti G, Gerevini S. Diagnosis and differential diagnosis of acute transverse myelopathy. The role of neuroradiological investigations and review of the literature. *Neurol Sci* 2001;22 Suppl 2:S69-73.
- 18) Choi K, Lee K, Chung S, et al. Idiopathic transverse myelitis: MR characteristics. *AJNR* 1996;17:1151-60.
- 19) Brinar M, Radoš M, Habek M, et al. Enlargement of the spinal cord: Inflammation or neoplasm. *Clin Neurol Neurosurg* 2006;108:284-290.
- 20) Poser C. The diagnosis and management of multiple sclerosis. *Acta Neurol Scand* 2005;112:199-201.

- 21) Poser C, Brinar V. Multiple sclerosis 2001. Clin Neurol Neurosurg 2002;104:165-7.
- 22) Poser C. MRI of spinal cord in multiple sclerosis. Lancet 1993;341:1025.
- 23) Nakamura M, Miyazawa I, Fujihara K, et al. Preferential spinal gray matter involvement in neuromyelitis optica. An MRI study. J Neurol 2008;255:163-70.
- 24) Wingerchuk D, Lennon V, Lucchinetti C, et al. The spectrum of neuromyelitis optica. Lancet Neurol 2007;6:805-15.
- 25) Wingerchuk D. Evidence for humoral autoimmunity in neuromyelitis optica. Neurol Res 2006;28:348–353.
- 26) Wingerchuk D, Hogancamp W, O'Brien P, et al.. The clinical course of neuromyelitis optica (Devic's syndrome). Neurology 1999;53:1107–1114.
- 27) Jacob A, Matiello M, Wingerchuk DM, et al. Neuromyelitis optica: changing concepts. J Neuroimmunol 2007;187:126-38.
- 28) Misu T, Fujihara K, Nakashima I, Sato S, et al. Intractable hiccup and nausea with periaqueductal lesions in neuromyelitis optica. Neurology 2005;65:1479–1482.
- 29) Weinshenker B, Wingerchuk D. Neuromyelitis optica: clinical syndrome and the NMO-IgG autoantibody marker. Curr Top Microbiol Immunol. 2008;318:343-56.
- 30) Weinshenker B, Wingerchuk D, Vukusic , et al. Neuromyelitis optica IgG predicts relapse after longitudinally extensive transverse myelitis. Ann Neurol 2006;59:566–569.

- 31) Wingerchuk D, Weinshenker B. Neuromyelitis optica. *Curr Treat Options Neurol* 2008;10:55-66.
- 32) Poser C, Brinar V. Disseminated encephalomyelitis and multiple sclerosis: two different diseases - a critical review. *Acta Neurol Scand* 2007;116:201-6.
- 33) Pittock S, Lennon V, Wingerchuk D, et al. The prevalence of non-organ-specific autoantibodies and NMO-IgG in neuromyelitis optica (NMO) and related disorders. *Neurology* 2006;66:A307.
- 34) Pittock S, Lennon V, de Seze J, et al. Neuromyelitis optica and non organ-specific autoimmunity. *Arch Neurol* 2008;65:78-83.
- 35) Arabshahi B, Pollock A, Sherry D, et al. Devic disease in a child with primary Sjogren syndrome. *J Child Neurol* 2006;21:285–286.
- 36) Mehta LR, Samuelsson MK, Kleiner AK, et al. Neuromyelitis optica spectrum disorder in patient with systemic lupus erythematosus and anti-phospholipid antibody syndrome. *Mult Scler* 2008;14:425-7.
- 37) Gotkine M, Fellig Y, Abramsky O. Occurrence of CNS demyelinating disease in patients with myasthenia gravis. *Neurology* 2006;67:881–883.
- 38) Kister I, Gulati S, Boz C, ET AL. Neuromyelitis optica in patients with myasthenia gravis who underwent thymectomy. *Arch. Neurol* 2006;63:851–856.
- 39) Poser C. Multiple sclerosis and recurrent disseminated encephalomyelitis are different diseases. *Arch Neurol* 2008;65:674-5.
- 40) Brinar V, Poser C. The spectrum of disseminated encephalomyelitis. *Clin Neurol Neurosurg.* 2006;108:295-310.

- 41) Brinar V. Non MS recurrent demyelinating diseases. Clin. Neurol. Neurosurg 2004;106:197-210.
- 42) Brinar V, Habek M. Monophasic acute, recurrent, and multiphasic disseminated encephalomyelitis and multiple sclerosis. Arch Neurol 2008;65:675-6
- 43) Young N, Weinschenker B, Lucchinetti C. Acute disseminated encephalomyelitis: Current understanding and controversies. Semin Neurol 2008;28:84-94.
- 44) Eichel R, Meiner Z, Abramsky O, et al... Acute disseminating encephalomyelitis in neuromyelitis optica: closing the floodgates. Arch Neurol 2008;65:267-71.
- 45) Jacobi C, Stinge K, Kretz R, et al: Neuromyelitis optica (Devic's syndrome) as first manifestation of systemic lupus erythematosus Lupus. 2006;15(2):107-9
- 46) Locatelli ER, Laureno R, Ballard P, et al.. MRI in Vitamin B₁₂ Deficiency Myelopathy. Can J Neurol Sci 1999;26:60-3.
- 47) Kumar N, Ahlskog JE, Klein CJ, et al.. Imaging features of copper deficiency myelopathy: a study of 25 cases. Neuroradiology 2006;48:78-83.
- 48) Cheshire W, Santos C, Massey E, et al.. Spinal cord infarction: etiology and outcome. Neurology 1996;47:321-30.
- 49) Novy J, Carruzzo A, Maeder P, et al.. Spinal cord ischemia: clinical and imaging patterns, pathogenesis, and outcomes in 27 patients. Arch Neurol 2006;63:1113-20.

Figures

Figure 1. A young man with clinical symptoms of incomplete TM. MRI showed demyelinating lesion of spinal cord, extending less than two segments; brain MRI showed typical periventricular lesions characteristic for MS.

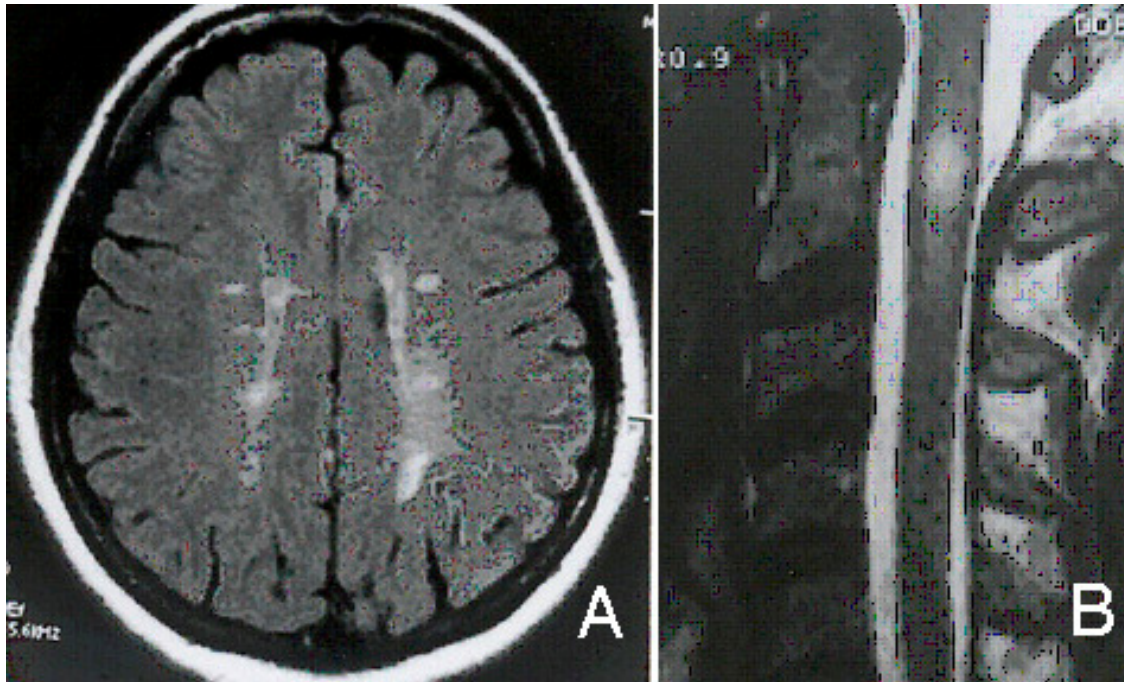


Figure 2. Patient with CIS presenting clinically with incomplete TM, positive OCB .

Spinal cord MRI shows hyperintense lesion involving less than two segments. Brain MRI was normal. Immunological work-up was normal. Three month later she developed optic neuritis. A year later new T2 supratentorial lesions developed. Diagnosis: CIS evolving to clinically definitive MS

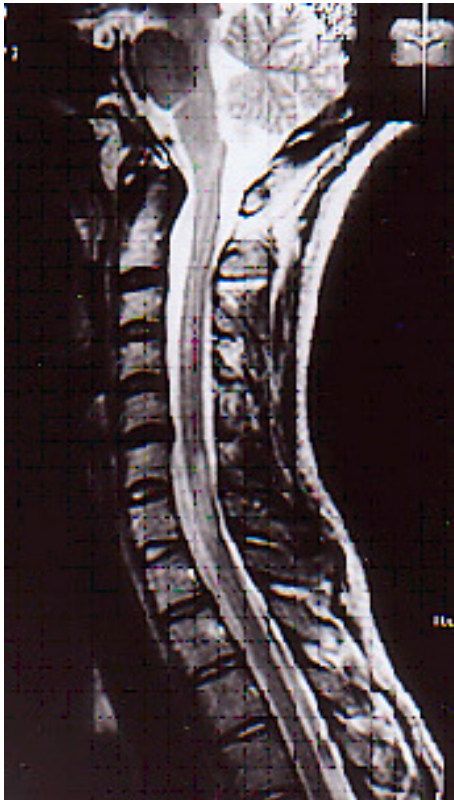

Figure 3. Patient with severe relapsing remitting course of MS, died in two years from onset. Spinal cord MRI showed typical small posterior demyelinating lesions, not extending over the entire diameter of the spinal cord.

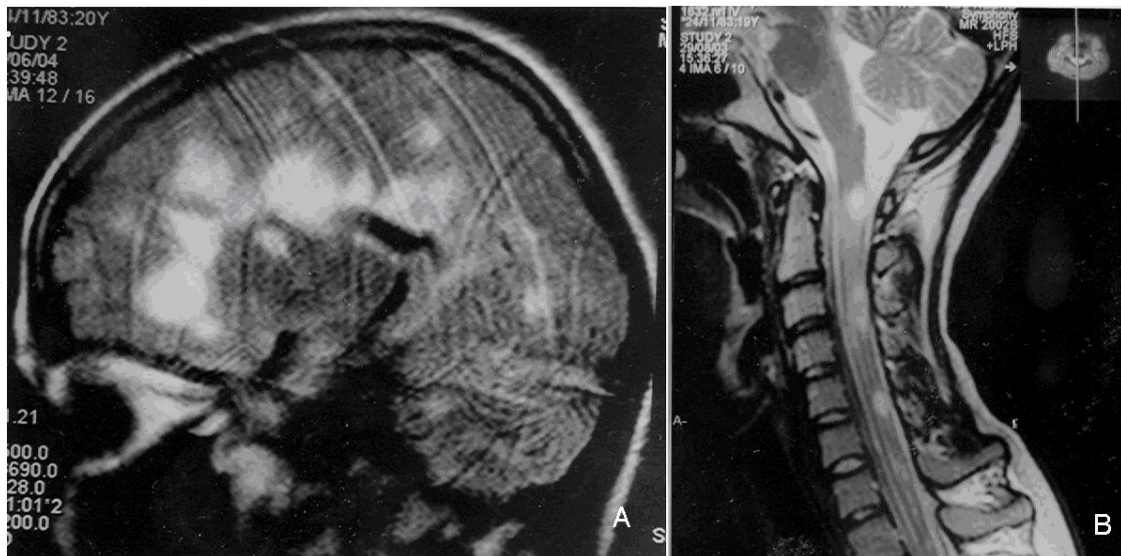


Figure 4. Patient was admitted blind and with spastic paraparesis. Spinal cord MRI showed long extensive lesion, Brain MRI was normal except for hyperintense lesion of optic nerves. NMO antibodies were positive. She was treated with plasmapheresis with good recovery of sight and motor functions. She currently taking azathioprine to prevent recurrences.

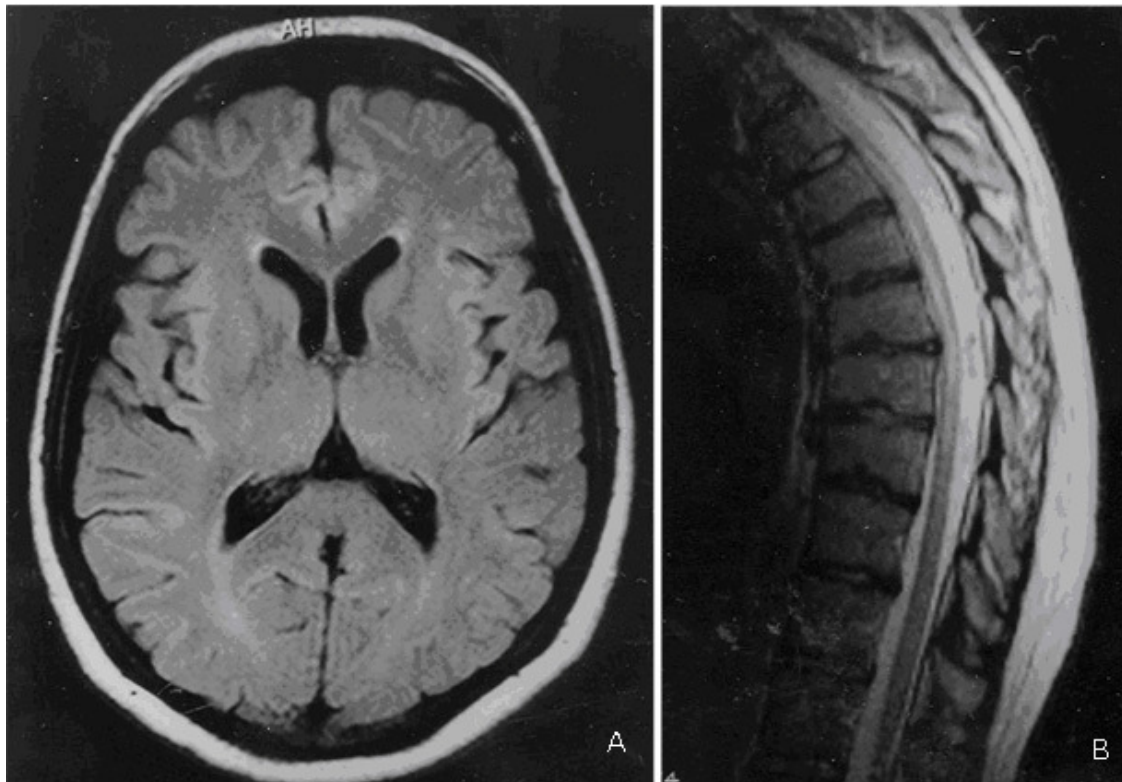

Figure 5. A 34 year old woman had the onset of optic neuritis that resolved with corticosteroid therapy. Soon after, she had a series of relapses with incomplete, and finally complete paraparesis. The disease was temporarily stopped after plasmapheresis, but soon started again and patient died two years after onset of the disease. MRI showed LETM demyelination in T2 images, and extensive destruction in T1 images.

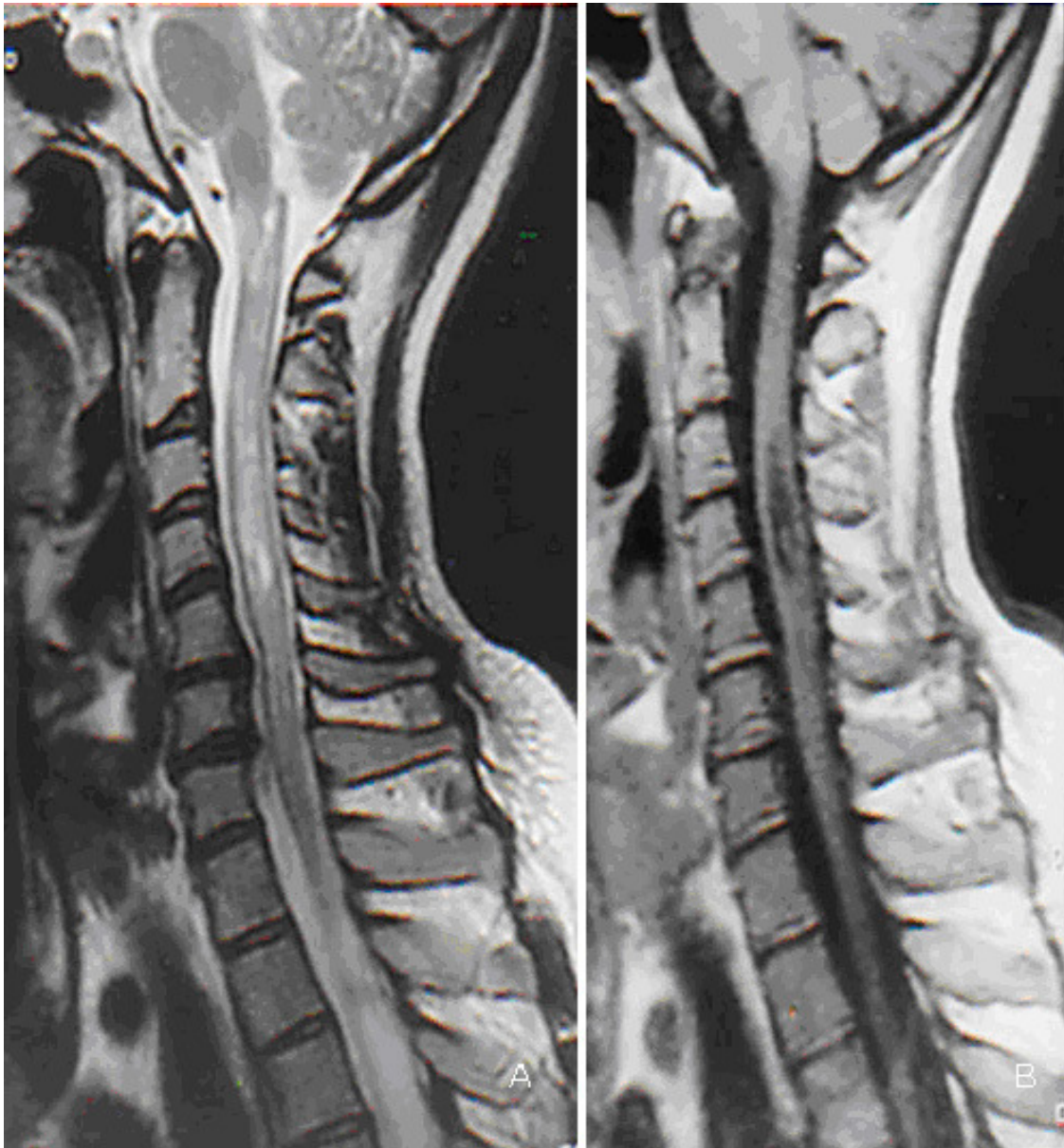


Figure 6. A 9-year-old boy suddenly developed flaccid tetraparesis with respiratory insufficiency and refractory hiccups. MRI showed LETM in the anterior part of the cord. CSF was normal, OCB were negative, biochemical parameters and immunological work up were unremarkable. After corticosteroid treatment and plasmapheresis he was better, there was no more need for ventilation, and he was partially able to move his extremities. LEMT with respiratory insufficiency, as well as brain MRI findings pointed to the diagnosis of NMO.

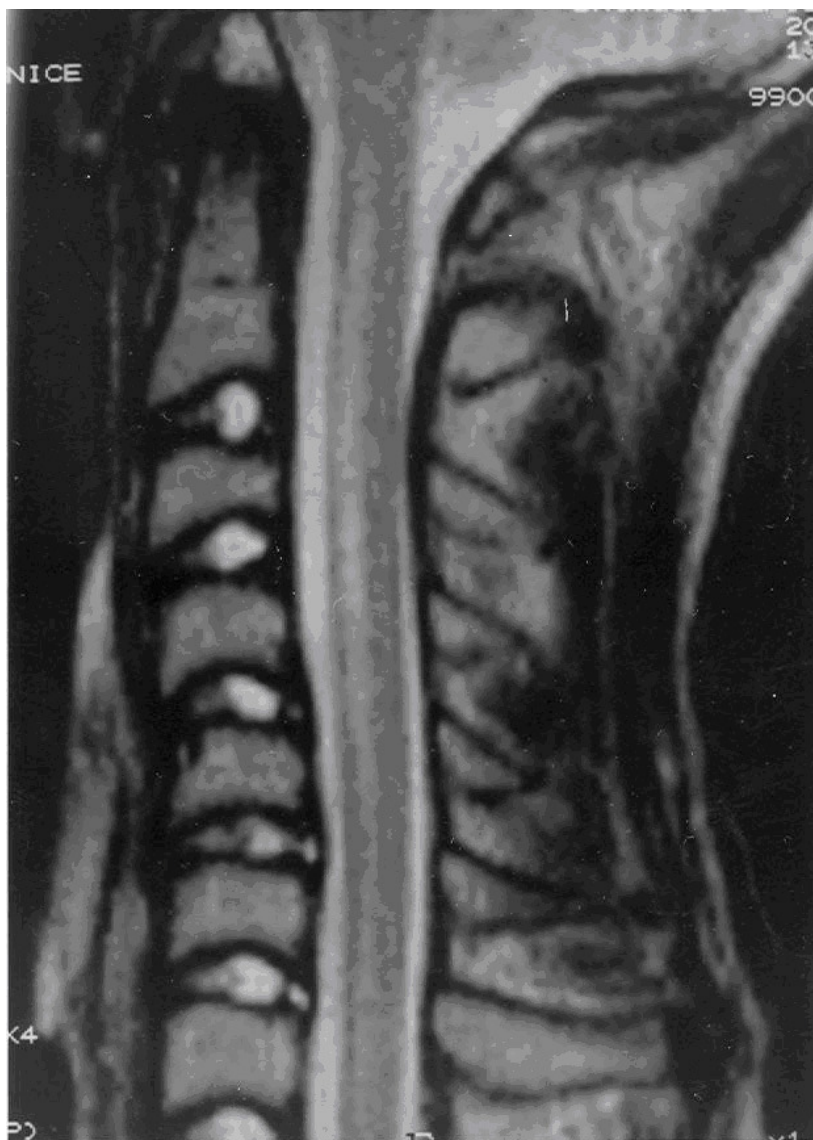

Figure 7. Patient with lupus and development of spastic paraparesis. MRI showed LETM of the spinal cord. NMO antibodies were negative.

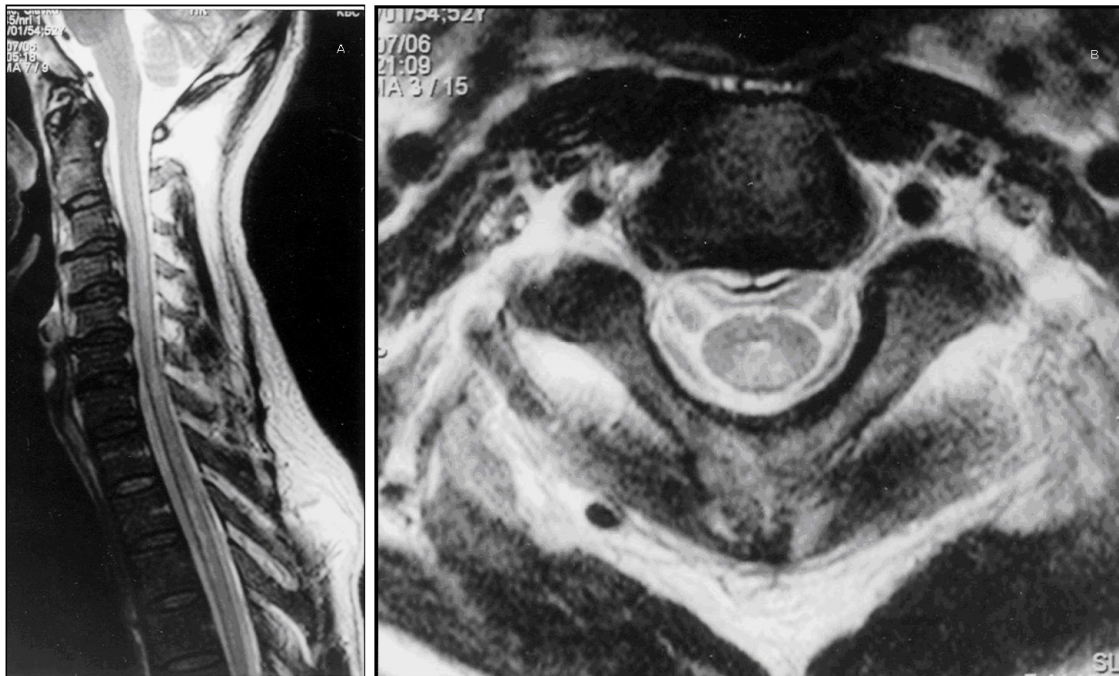


Figure 8. Patient with congenital myasthenia and development of spastic paraparesis due to LETM lesion of the spinal cord. Immunological work up as well as biochemical parameters were normal. NMO antibodies were negative.

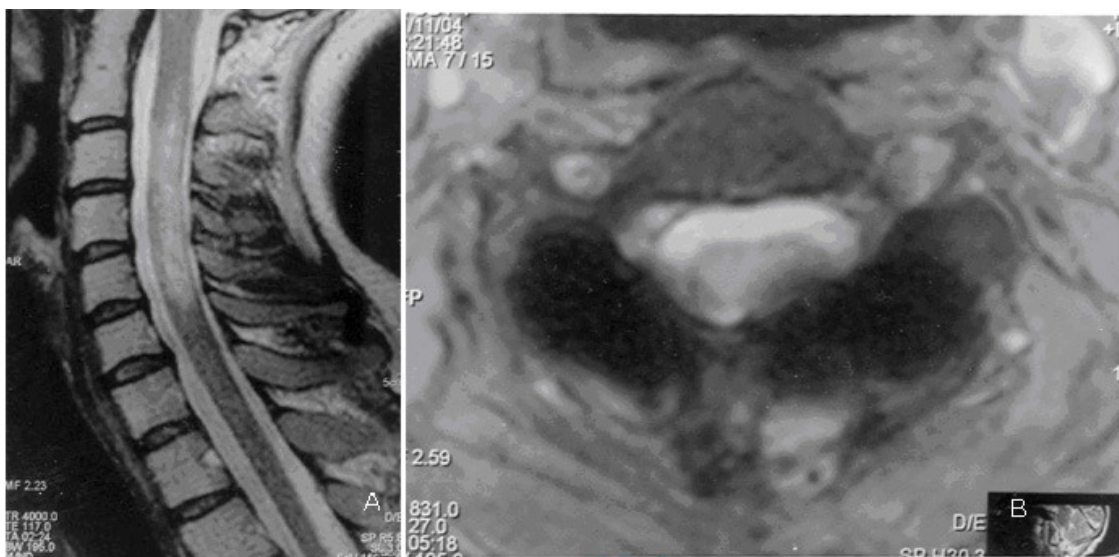


Figure 9. Patient with monophasic course of disease characterized with paraesthesia in arms and loss of vibratory sensation. MRI showed selective involvement of posterior columns. Good response to corticosteroid therapy (presented in the spectrum of DEM).

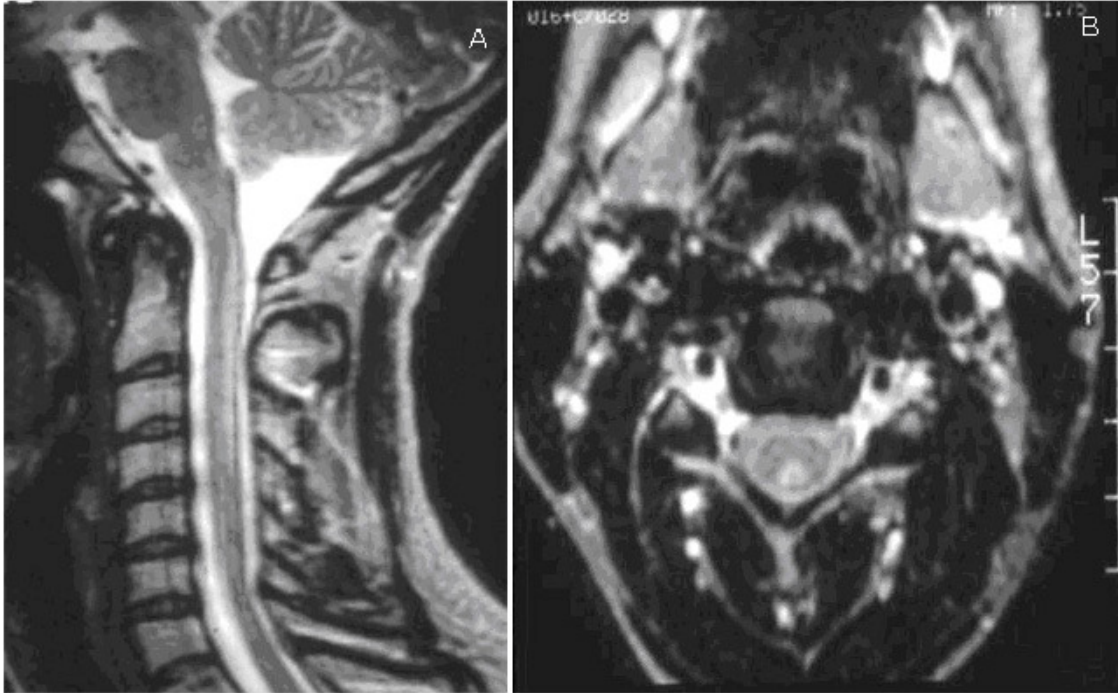


Figure 10. A young woman developed symptoms of paraesthesia in both legs. First MRI performed in 2003 was diagnosed as spinal tumor, and she was scheduled for operation, but a second MRI showed regression of the lesion. A year later the lesion was smaller, and at the end of 2005 it had completely disappeared. Patient has had no new lesions or clinical symptoms since.

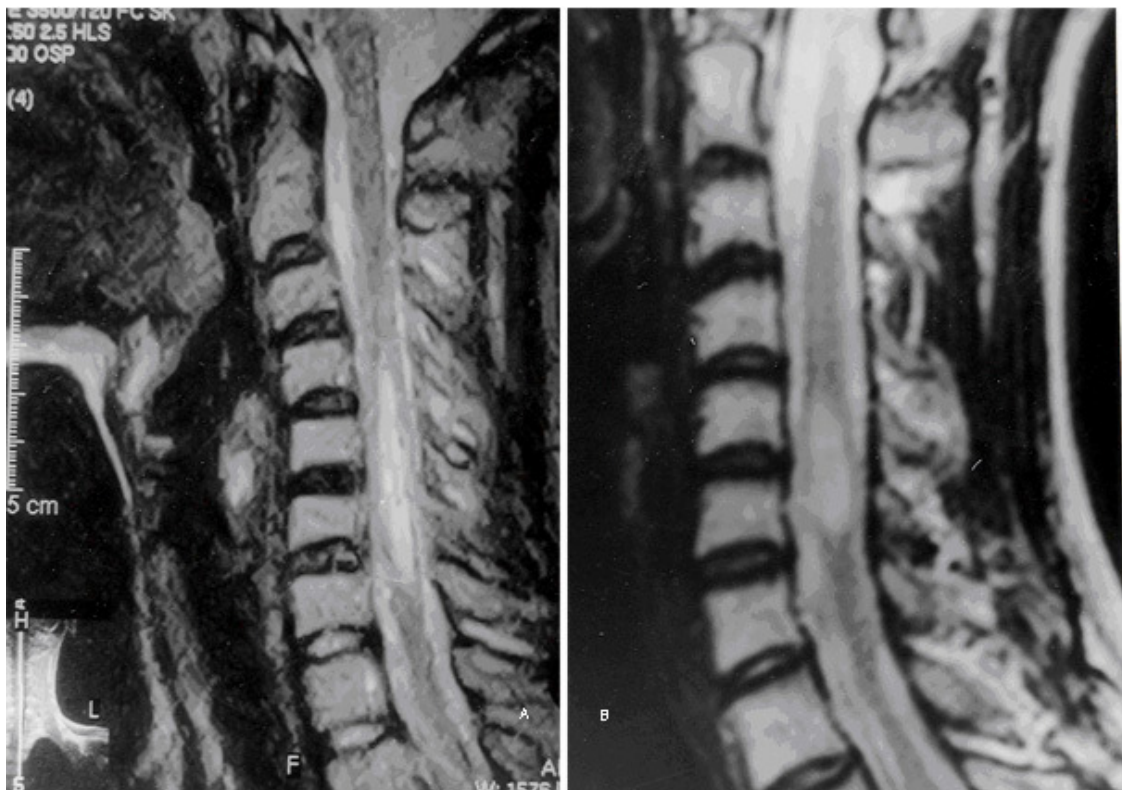


Figure 11. A woman born in 1953, a strict vegetarian, presented with spastic paraparesis and proprioceptive sensory impairment due to LETM in the posterior columns due to cyacobolamin deficiency. CSF was normal. Brain MRI normal.

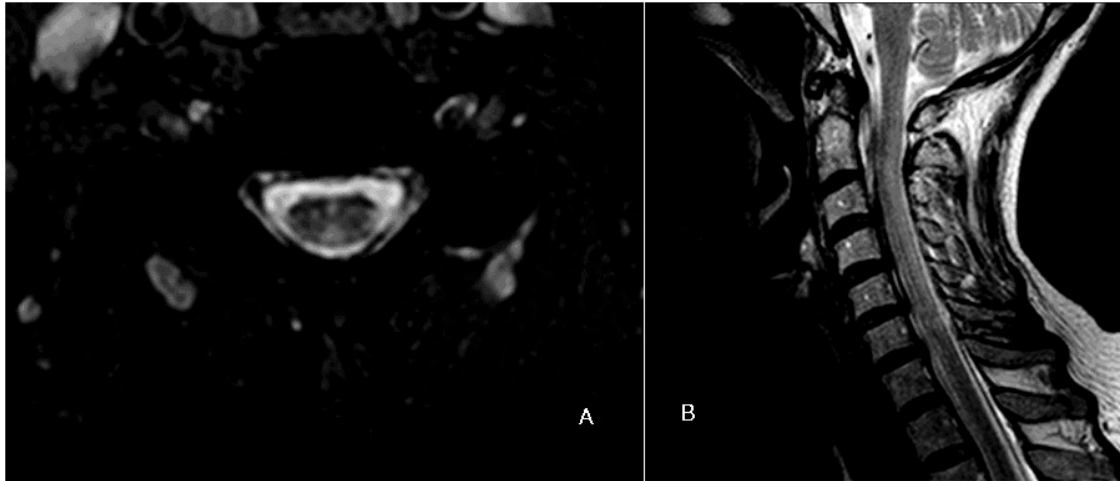


Figure 12. Pencil like hyperintense lesion in anterior part of spinal cord due to infarction.

Characteristic hyperintense and hypointense lesions are seen.

The patient presented with the sudden development of severe flaccid tetraparesis and respiratory insufficiency. After one month he was referred in our department.

Neurological examination revealed flaccid paraparesis of upper extremities and spastic lower paraparesis with incontinence. The MRI lesions of patients with ischemic myelopathy are discontinuous, partially hyperintense and partially hypointense in T2-weighted images as it is seen in this patient.

