

Isolated central nervous system sarcoidosis: a great mimicker

Brinar, Vesna V.; Habek, Mario

Source / Izvornik: **Clinical Neurology and Neurosurgery, 2008, 110, 939 - 942**

Journal article, Accepted version

Rad u časopisu, Završna verzija rukopisa prihvaćena za objavljivanje (postprint)

<https://doi.org/10.1016/j.clineuro.2007.12.020>

Permanent link / Trajna poveznica: <https://um.nsk.hr/um:nbn:hr:105:522048>

Rights / Prava: [In copyright](#) / [Zaštićeno autorskim pravom.](#)

Download date / Datum preuzimanja: **2025-03-29**



Repository / Repozitorij:

[Dr Med - University of Zagreb School of Medicine
Digital Repository](#)





Središnja medicinska knjižnica

Brinar, V. V., Habek, M. (2008) *Isolated central nervous system sarcoidosis: A great mimicker*. Clinical Neurology and Neurosurgery, [Epub ahead of print, Corrected Proof].

<http://www.elsevier.com/locate/issn/0303-8467>

<http://dx.doi.org/10.1016/j.clineuro.2007.12.020>

<http://medlib.mef.hr/420>

University of Zagreb Medical School Repository

<http://medlib.mef.hr/>

Isolated central nervous system sarcoidosis: a great mimicker

Vesna V Brinar, MD, PhD¹, Mario Habek, MD¹

From the:

¹ Referral Center for Demyelinating Diseases of the Central Nervous System, University Department of Neurology, Zagreb School of Medicine and University Hospital Center, Zagreb, Croatia

Corresponding author:

Mario Habek, MD
University Department of Neurology
Zagreb School of Medicine and University Hospital Center
Kišpatićeva 12
HR-10000 Zagreb
Croatia
Phone: +38598883323; Fax: +38512421891; e-mail: mhabek@mef.hr

Word count: 935

Key words: sarcoidosis, neurosarcoidosis, isolated

Authors' contributions

Study concept and design: Brinar and Habek. Acquisition of data: Brinar. Analysis and interpretation of data: Brinar. Drafting of the manuscript: Habek. Critical revision of the manuscript for important intellectual content: Brinar and Habek. Administrative, technical, and material support: Habek.

Conflict of interest statement: There is no conflict of interest.

Abstract

A patient is described who presented with focal brain lesion considered to be a tumor and later developed disseminated white matter disease. After 21 years of clinical and MRI follow up, the diagnosis of isolated neurosarcoidosis was confirmed by histology. The follow up of more than 21 years in this patient supported the existence of isolated neurosarcoidosis as a separate disease entity.

Introduction

The prevalence of clinical involvement of the nervous system in sarcoidosis is estimated to 5%-15%, and very rarely it may selectively involve the nervous system (1). We describe a patient who presented with focal lesion considered to be a tumor and later developed disseminated white matter disease. After 21 years of clinical and MRI follow up, the diagnosis of isolated neurosarcoidosis was verified by histology.

Case Report

In February 1986, a 19-year-old female patient presented with partial motor seizure on the right limbs followed by tonic-clonic grand mal seizure for the first time in her life. Neurologic examination revealed right upper quadrantanopsia, right hypoesthesia and brisk reflexes on the right extremities. Brain CT scan revealed a tumor mass in the left parietal lobe, digital subtraction angiography was normal, and the patient was scheduled for biopsy. Laboratory examination was normal, except for mildly elevated erythrocyte sedimentation rate (ESR). Brain MRI revealed a mass lesion in the left temporal lobe, surrounded with edema without gadolinium enhancement (Figure 1a). Biopsy specimen revealed granulomatous inflammation in both meninges and white matter, so the diagnosis of tuberculous meningoencephalitis was suspected and antituberculous treatment was started for the next year. **The patient denied any contacts with tuberculosis and tuberculin test was not performed.** She had no new symptoms in the next four years; then she developed right-sided hemiparesis and right homonymous hemianopsia again. In August 1990, brain MRI revealed extensive white matter hyperintensities on T2 and FLAIR sequences, again without gadolinium enhancement (Figure 1b). Repeat laboratory examination showed mildly elevated ESR. Cerebrospinal fluid (CSF) examination revealed 60 lymphocytes, with normal protein and glucose level. Chest x-ray was normal. CSF cultures for *Mycobacterium tuberculosis* and CSF serology for fungi, parasites,

herpes simplex virus (HSV) and toxoplasmosis were negative. She had control brain MRI every year, which showed progression of the lesions (Figure 1 c-l). Despite radiological worsening, the patient was clinically well, reporting occasional headaches and vertigo. In this period, she did not receive corticosteroid therapy. In 1996, brain MRI showed progression of the lesions and CSF examination was repeated to reveal 2 cells, slightly elevated protein level (0.54 g/L) and positive oligoclonal bands. Repeat cultures for *Mycobacterium* and CSF serology for *Borrelia* and HSV were negative. Revision of the brain biopsy specimen obtained at the beginning of the disease (Figure 2) was compatible with the diagnosis of neurosarcoidosis. Repeat laboratory examination revealed elevated ESR of 34 mm/h, and elevated serum ACE of 67. CSF ACE was not performed. Serum calcium, ANF, ENA, ANCA, anticardiolipin antibodies, abdominal ultrasound and chest CT scan were normal. Total body gallium scintigraphy was normal. Corticosteroid therapy was initiated (methylprednisolone 500 mg for 5 days, gradually tapered to 16 mg every other day). Her condition stabilized and she had no new symptoms during the next 6 years on low-dose methylprednisolone every other day. Then she developed mental impairment, motor dysphasia and worsening of her right-sided hemiparesis. Repeat brain MRI revealed extensive white matter hyperintensities in the left temporal and parietal lobes, in the right cerebellar hemisphere and periventricularly bilaterally. Since then, her condition progressed despite corticosteroid therapy and a series of brain MRIs also showed progression of brain lesions (Figure 1 c-l). Throughout the period of illness, there were no signs of involvement of any organs other than the brain. Treatment with azathioprine 50 mg BID was tried, but the patient developed liver enzyme elevation and this therapy was discontinued. Cyclosporine therapy was suggested, but the patient refused it due to potential side effects. At the last control visit, the patient had severe cognitive impairment and tetraplegia.

Discussion

Our patient met the criteria for definitive diagnosis of neurosarcoidosis: clinical presentation compatible with neurosarcoidosis, exclusion of other possible causes and positive nervous system histology (2). However, the diagnosis of isolated neurosarcoidosis remains very difficult despite the established criteria. As it can affect any part of the nervous system, clinical presentation may range from headaches to altered consciousness and severe motor deficits. Some clinical presentations are often associated with a higher rate of morbidity and death. In contrast to an isolated mass lesion, which has a favorable outcome, poor outcome is associated with seizures, hydrocephalus, chronic meningitis and multifocal parenchymal disease (3). In our patient, the initial manifestation was partial motor seizure caused by the solitary mass lesion. This finding, along with later development of disseminated white matter disease, put this patient at a high risk of poor outcome.

Mass lesions are frequently reported in patients with neurosarcoidosis and they may mimic primary or metastatic tumor or tumefact demyelination (4,5). However, adjacent leptomeningeal involvement is frequently seen, a finding that may help reach an accurate diagnosis (5). These patients often present with seizures, which were a presenting feature in our patient, however, leptomeningeal involvement was absent. Later, when diffuse involvement of the white matter ensues, the lesions may be indistinguishable from those seen in multiple sclerosis.

A typical and most common imaging feature in neurosarcoidosis is thickening and enhancement of basilar leptomeninges, followed by enhancing or nonenhancing parenchymal lesions and hydrocephalus (6). Imaging findings in neurosarcoidosis can mimic astrocytoma, meningioma, intracranial metastatic disease, CNS vasculitis, other granulomatous diseases such as tuberculosis, parasitic and fungal infections, and Wegener's or lymphomatous granulomatosis, and multiple sclerosis (7). If there is a known history of pulmonary

sarcoidosis, the diagnosis of neurosarcoidosis is straightforward. However, when CNS involvement is a first manifestation, all the diseases mentioned above should be excluded. This makes neurosarcoidosis one of the great mimickers in neurology. The follow up of more than 21 years in the patient presented supports the existence of isolated neurosarcoidosis as a separate disease entity.

Acknowledgment. We thank Prof. Lassmann for his expert analysis of histopathology.

References

1. Hoitsma E, Faber CG, Drent M, Sharma OP. Neurosarcoidosis: a clinical dilemma. *Lancet Neurol* 2004;3:397-407.
2. Zajicek JP, Scolding NJ, Foster O, Rovaris M, Evanson J, Moseley IF, Scadding JW, Thompson EJ, Chamoun V, Miller DH, McDonald WI, Mitchell D. Central nervous system sarcoidosis – diagnosis and management. *QJM* 1999;92:103-17.
3. Sponsler JL, Werz MA, Maciunas R, Cohen M. Neurosarcoidosis presenting with simple partial seizures and solitary enhancing mass: case reports and review of the literature. *Epilepsy Behav* 2005;6:623-30.
4. Urbach H, Kristof R, Zentner J, Brechtelsbauer D, Solymosi L, Wolf HK. Sarcoidosis presenting as an intra- or extra-cranial mass: report of two cases. *Neuroradiology* 1997;39:516-9.
5. Smith JK, Matheus MG, Castillo M. Imaging manifestations of neurosarcoidosis. *AJR Am J Roentgenol* 2004;182:289-95.
6. Spencer TS, Campellone JV, Maldonado I, Huang N, Usmani Q, Reginato AJ. Clinical and magnetic resonance imaging manifestations of neurosarcoidosis. *Semin Arthritis Rheum* 2005;34:649-61.
7. Lury KM, Smith JK, Matheus MG, Castillo M. Neurosarcoidosis – review of imaging findings. *Semin Roentgenol* 2004;39:495-504.

Figures

Figure 1

Series of brain MRIs performed during the 20-year period: a) 1986, FLAIR sequence; b) 1990, T2 sequence; c) 1991, T2 sequence; d) 1992, FLAIR sequence; e) 1993, FLAIR sequence; f) 1994, FLAIR sequence; g) 1996; T2 sequence; h) 1997, T2 sequence; i) 1998, T2 sequence; j) 2000, FLAIR sequence; k) and l) 2003, FLAIR sequences. Note the progression of lesions as well as development of brain atrophy and ventriculomegaly.

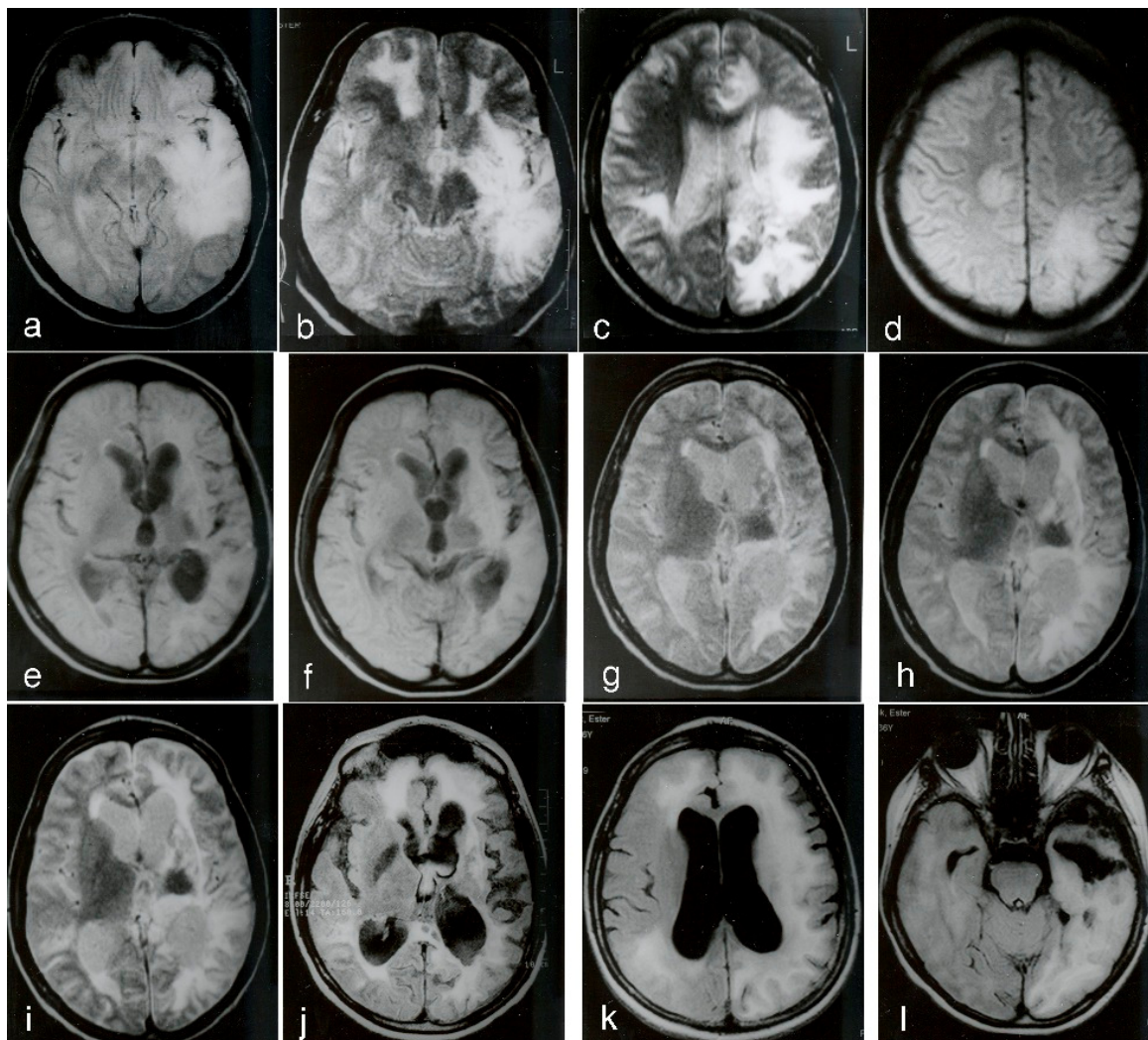


Figure 2

a) Small meningeal granuloma with a large multinucleated giant cell; H&E; b) multiple granulomatous lesions in the cerebral white matter; H&E; c) parenchymal granulomatous lesion in the white matter; H&E; d) higher magnification showing lymphocytes, plasma cells and a multinucleated giant cell; H&E; e) CD3 staining shows dense T-cell infiltrates in the periphery of the granuloma; immunocytochemistry for CD3; f) CD68 staining shows profound macrophage infiltrates, especially in the center; immunocytochemistry for CD 68; g) giant cells stained for CD68 (macrophages); immunocytochemistry for CD 68; h) small perivascular granuloma with multinucleated giant cell; immunocytochemistry for CD68; and i) plasma cells within the periphery of the granuloma stained for immunoglobulins; immunocytochemistry for immunoglobulins.

