

Thrombosis of bare metal and patent drug eluting stent in patient operated for colorectal carcinoma: the utility of new guidelines in patients with malignancy

Šikić, Jozica; Starčević, Boris; Ivković, Mira; Sičaja, Mario; Manojlović, Spomenka

Source / Izvornik: **International Journal of Cardiology, 2010, 142, e17 - e19**

Journal article, Accepted version

Rad u časopisu, Završna verzija rukopisa prihvaćena za objavljivanje (postprint)

<https://doi.org/10.1016/j.ijcard.2008.11.165>

Permanent link / Trajna poveznica: <https://um.nsk.hr/um:nbn:hr:105:314558>

Rights / Prava: [In copyright](#) / [Zaštićeno autorskim pravom.](#)

Download date / Datum preuzimanja: **2025-03-09**



Repository / Repozitorij:

[Dr Med - University of Zagreb School of Medicine Digital Repository](#)





Središnja medicinska knjižnica

Šikić, J., Starčević, B., Ivković, M., Sičaja, M., Manojlović, S. (2009) *Thrombosis of bare metal and patent drug eluting stent in patient operated for colorectal carcinoma: The utility of new guidelines in patients with malignancy*. International Journal of Cardiology, [Epub ahead of print, Corrected Proof]. ISSN 0167-5273.

<http://www.elsevier.com/locate/issn/0167-5273>

<http://dx.doi.org/10.1016/j.ijcard.2008.11.165>

<http://medlib.mef.hr/570>

University of Zagreb Medical School Repository

<http://medlib.mef.hr/>

Thrombosis of bare metal and patent drug eluting stent in patient operated for colorectal carcinoma: The utility of new guidelines in patients with malignancy

Jozica Sikic ^a, Boris Starcevic ^a, Mira Ivkovic ^a, Mario Sicaja ^{a,□}, Spomenka Manojlovic ^b

^a Cardiology Unit, Department of Internal Medicine, University Hospital Dubrava, Avenija Gojka Šuška 6, 10000 Zagreb, Croatia

^b Department of Clinical Pathology, University Hospital Dubrava, Avenija Gojka Šuška 6, 10000 Zagreb, Croatia

Abstract

Percutaneous coronary intervention with stent placement is widely used to achieve revascularization of the myocardium, especially in acute coronary syndrome. There is increasing number of reports published concerning stent thrombosis both in bare metal stents as in drug eluting stents. According to the newest ACC/AHA/SCAI 2007th guidelines, bare-metal stent or balloon angioplasty is recommended as an optimal solution if surgery is to be performed in 6–12 months time after stent placement. We present a case of a 56-year-old male with colon carcinoma who suffered from post-operational myocardial infarction due to bare metal stent thrombosis, while the drug eluting stent remained patent. Currently, in our opinion, high level evidence is lacking in the literature in support for recommendations published in current ACC, AHA and SCAI 2007th guidelines regarding the choice of stent, antiaggregation and anticoagulation therapy. This case, together with others previously published suggests a need for development of an applicable strategy for selection and treatment of patients with increased perioperative risk of in-stent thrombosis in order to ensure optimal medical treatment.

Keywords: DES; BMS; Stent; Thrombosis; Colorectal carcinoma; Myocardial infarction

1. Background

Percutaneous coronary intervention (PCI) with stent placement is widely used to achieve revascularization of the myocardium, especially in acute coronary syndrome [1]. There are an increasing number of patients treated with PCI with stent implantation subsequently requiring non-cardiac surgery [2]. The issue of antiaggregation and anticoagulation therapy in the coronary artery patients with stent implantation requiring non-cardiac surgery is controversial [2]. According to the newest ACC/AHA guidelines, bare-metal stent (BMS) or balloon angioplasty is recommended as an optimal solution if surgery is to be performed in 6–12 months time after stent placement [3]. Furthermore, same recommendations were proposed by some authors published in this journal [4]. We present a unique case of a patient with colon carcinoma who suffered from post-operational myocardial infarction due to BMS thrombosis after discontinuation of an antiplatelet therapy and introduction of low-molecular weight heparin prior to colorectal cancer surgery, while the drug eluting stent (DES) remained patent.

2. Case presentation

We present a case of a 56-year-old male with a positive family history of coronary artery disease and colonic cancer, who was admitted to hospital in 1996, for elective coronarography due to angina pectoris. Significant circular narrowing of proximal left anterior descending artery (LAD) and nonsignificant atherosclerotic changes in other coronary arteries were found. PCI of LAD was performed without coronary stent placement. Following this procedure, the patient was asymptomatic with repeatedly negative stress testing. In November 2006, he was again admitted to hospital because of an unstable angina pectoris. Significant stenosis of proximal LAD (in the segment of previous PCI) was found, combined with occlusion of proximal left circumflex artery (LCx) with significant stenosis of first marginal branch (OM1). Primary PCI with stent implantation was performed. Bare metal stents were placed in a proximal segment of LAD and proximal segment of OM1. In the previously occluded LCx, DES was implanted. After the PCI patient had no chest pain and was discharged from hospital in an excellent condition. Six months later, in the same patient a colorectal carcinoma (Dukes C) was diagnosed and elective operation was planned for May 2007. Because of indicated abdominal surgery a dual antiaggregation therapy (aspirin+ clopidogrel) was discontinued 5 days prior, and low-molecular weight heparin (enoxaparine 0.5 mg/kg) was started as requested by anesthesiologist and attending surgeon. The planned resection of descending colon was performed successfully and patient was admitted to the surgical intensive care unit (ICU). Five hours after admittance in the ICU a patient developed myocardial infarction with ST segment elevation (STEMI) of the anteroseptal region. Our patient was admitted to cardiac catheterization laboratory for urgent PCI. He received

600 mg of clopidogrel before procedure, heparin and eptifibatide infusion during and after PCI procedure. Coronary angiography showed a thrombotic occlusion of BMS in proximal LAD and fairly patent DES and other BMS in LCx/OM1 (Fig. 1). Occluded segment was dilated with a balloon and TIMI III flow was established (Fig. 2). Immediately after procedure, patient had chest pain relief and rapid resolution of STsegment elevation, and no signs of a significant hemorrhage. He was discharged from hospital 9 days later on a dual antiplatelet therapy.

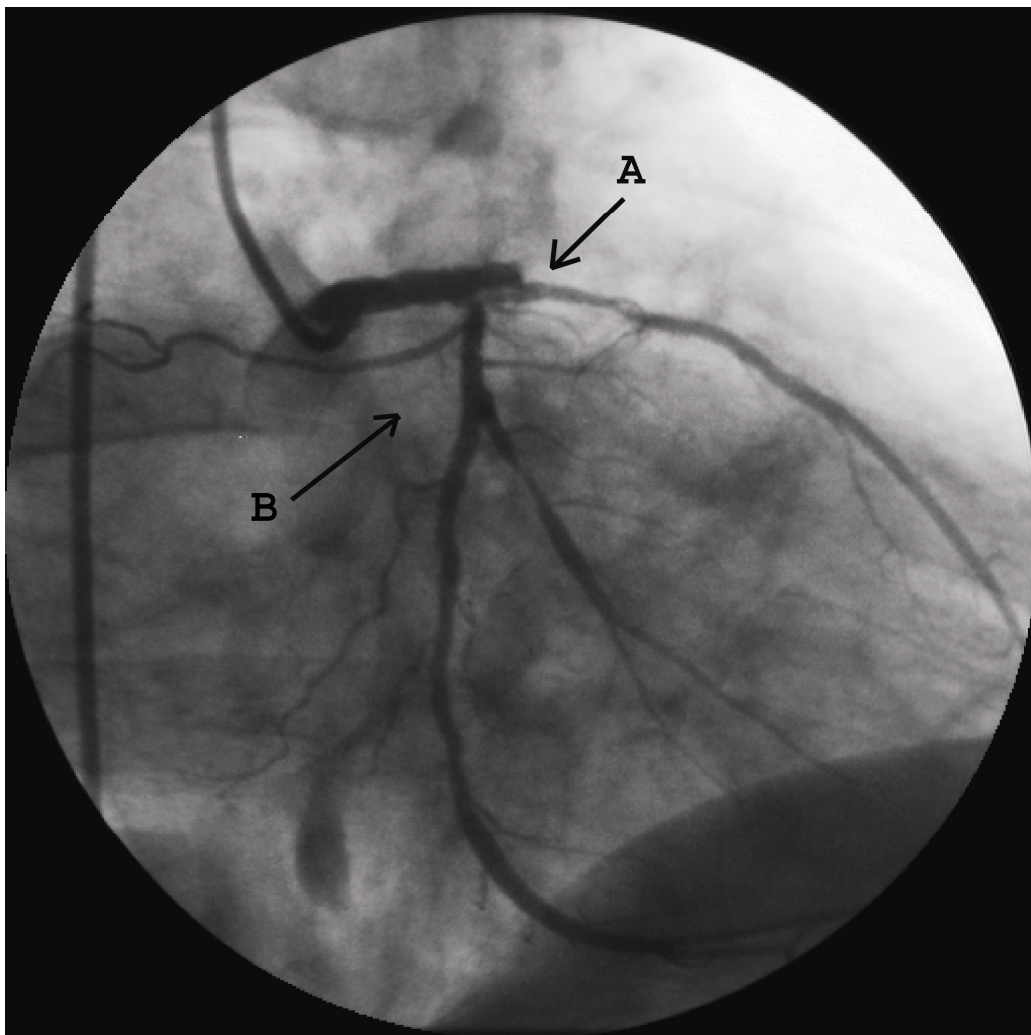


Fig. 1. Coronarography: occluded LAD with thrombi in previously implanted BMS (A). DES in ACx is fairly patent (B).

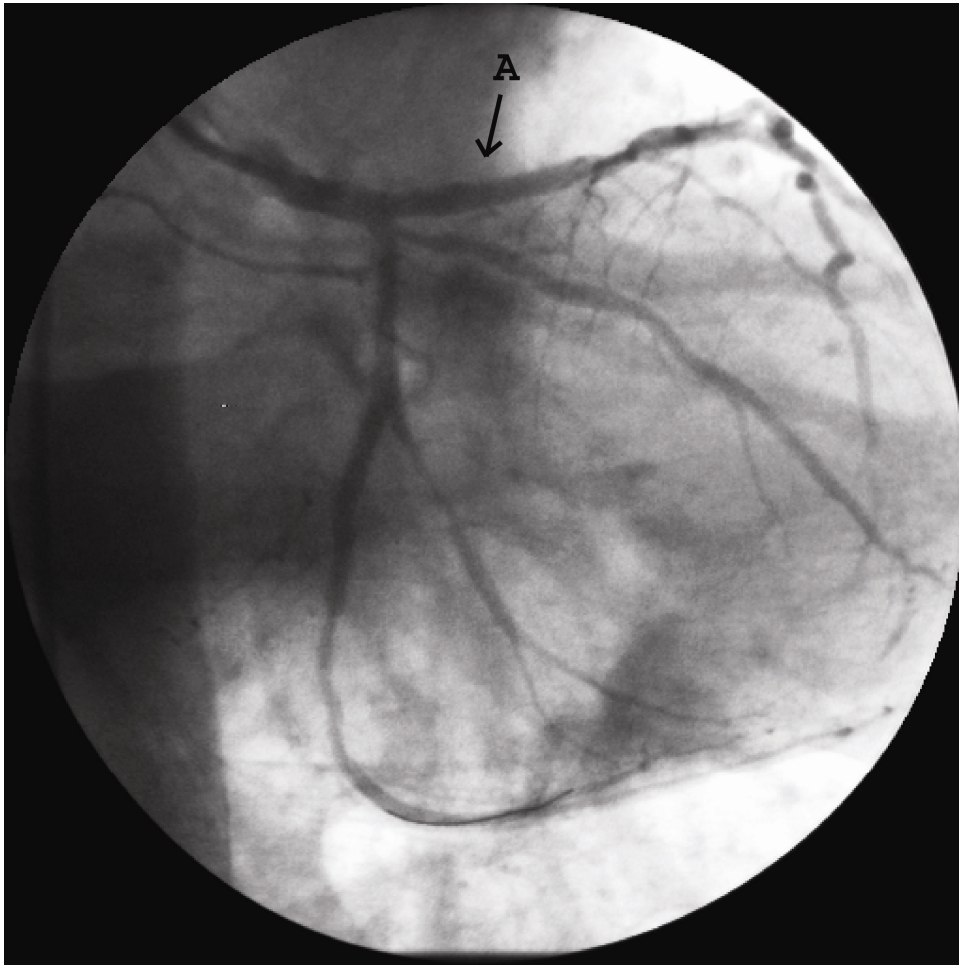


Fig. 2. Coronarography: TIMI 3 flow in LAD after eptifibatide bolus and ballooning (A).

3. Discussion

An increasing number of patients have history of recent coronary stent implantation and may subsequently require noncardiac surgery [2]. According to some authors a discontinuation of antiplatelet therapy prior to surgery is suggested to prevent major bleeding [5]. This brings to a high risk of in-stent thrombosis resulting in myocardial infarction with catastrophic outcomes in such patients [5]. Since DES have been introduced, they have been proven at least as safe as BMS in the follow-up period up to 12 months, with tremendous improvement in issue of restenosis [6]. However some studies, especially Basket Late Study, showed that late stent thrombosis (resulting in acute myocardial infarction/death) is 2–3 times more frequent among

patients who had received DES than among those who had received BMS. It is considered that is mostly due to postponed reendothelisation of DES [7]. Therefore, new ACC, AHA and SCAI 2007th updated guidelines for PCI recommended use of BMS or balloon angioplasty for patients that may need noncardiac surgery within 6–12 months [3]. The same recommendation is preferred by authors published in this journal [4].

We present a unique case of late bare metal stent thrombosis in a patient operated for colorectal carcinoma, while drug eluting stent remained patent. This case together with other similar which were published [8], suggests that application of these guidelines is hardly acceptable in patients with an aggressive malignancy. The risk of in-stent thrombosis and myocardial infarction in this group of patients is not only due to whether the stent is BMS or DES, but also because of acute surgical stress, inflammatory response and blood loss with haemodilution [9]. Furthermore, the abbreviated coagulation mechanism in patients with malignancies combined with discontinuation of antiaggregation therapy brings additional risk of stent thrombosis [10].

We would suggest a development of an applicable strategy for selection of patients with increased risk of in-stent thrombosis in order to reduce potentially catastrophic post-operative complications and to ensure development of optimal therapy protocols in the setting of non-cardiac surgery.

Acknowledgement

The authors of this manuscript have certified that they comply with the Principles of Ethical Publishing in the International Journal of Cardiology [11].

References

- [1] Boden WE, Shah PK, Gupta V, Ohman EM. Contemporary approach to the diagnosis and management of non-ST-segment elevation acute coronary syndromes. *Prog Cardiovasc Dis* 2008;50(5):311–51.
- [2] Kałuza GL, Joseph J, Lee JR, et al. Catastrophic outcomes of noncardiac surgery soon after coronary stenting. *J Am Coll Cardiol* 2000;35(5):1288–94 2000;35(5):1288–94.
- [3] Writing Group to Review New Evidence and Update the ACC/AHA/SCAI 2005 Guideline Update for Percutaneous Coronary Intervention: 2007 Focused Update of the ACC/AHA/SCAI 2005 Guideline Update for Percutaneous Coronary Intervention: A Report of the American College of Cardiology/American Heart Association Task Force on Practice Guidelines. *Circulation* 2008;117:261–95.
- [4] Kim HL, Park KW, Kwak JJ, et al. Stent-related cardiac events after non-cardiac surgery: drug-eluting vs. bare metal stent. *Int J Cardiol* 2008;123(3):353–4.
- [5] Howard-Alpe GM, de Bono J, Hudsmith L, et al. Coronary artery stents and non-cardiac surgery. *Br J Anaesth* 2007;98(5):560–74.
- [6] Williams DO, Abbott JD, Kip KE. Outcomes of 6906 patients undergoing percutaneous coronary intervention in the era of drug-eluting stents: report of the DEScover Registry. *Circulation* 2006;114:2154–62.
- [7] Pfisterer M, Brunner-La Rocca HP, BASKET-LATE Investigators. Late clinical events after clopidogrel discontinuation may limit the benefit of drug-eluting stents: an observational study of drug-eluting versus baremetal stents. *J Am Coll Cardiol* Nov 2 2006;48(12):2584–91 [Electronic

publication 2006].

[8] Rossi ML, Zavalloni D, Gasparini GL, Presbitero P. Very late multivessel thrombosis of bare metal stents with concomitant patent drug-eluting stents after withdrawal of aspirin. *Int J Cardiol* Sep 18 2007 [Electronic publication ahead of print].

[9] de Man FH, Stella PR, Nathoe H, et al. Stent thrombosis in real-world patients: a comparison of drug-eluting with bare metal stents. *Neth Heart J* 2007;15(11):382–6.

[10] Hron G, Kollars M, Weber H, et al. Tissue factor-positive microparticles: cellular origin and association with coagulation activation in patients with colorectal cancer. *Thromb Haemost* 2007;97(1):119–23.

[11] Coats AJ. Ethical authorship and publishing. *Int J Cardiol* 2009;131:149–50.