

Endomedullary radiofrequency ablation of metastatic lesion of the right femur 5 years after primary breast carcinoma: a case report

Majerović, Mate; Augustin, Goran; Jelinčić, Željko; Buković, Damir; Burcar, Ivan; Smuđ, Dubravko; Kekez, Tihomir; Kinda, Emil; Matošević, Petar; Turčić, Josip

Source / Izvornik: *Collegium Antropologicum*, 2008, 32, 1267 - 1269

Journal article, Published version

Rad u časopisu, Objavljena verzija rada (izdavačev PDF)

Permanent link / Trajna poveznica: <https://um.nsk.hr/um:nbn:hr:105:948865>

Rights / Prava: [In copyright](#) / [Zaštićeno autorskim pravom](#).

Download date / Datum preuzimanja: **2024-12-03**



Repository / Repozitorij:

[Dr Med - University of Zagreb School of Medicine Digital Repository](#)



Endomedullary Radiofrequency Ablation of Metastatic Lesion of the Right Femur 5 years after Primary Breast Carcinoma: A Case Report

Mate Majerović¹, Goran Augustin¹, Željko Jelinčić¹, Damir Buković², Ivan Burcar³, Dubravko Smud¹, Tihomir Kekez¹, Emil Kinda¹, Petar Matošević¹ and Josip Turčić⁴

¹ Department of Surgery, Division of Abdominal Surgery, University Hospital Center »Zagreb«, Zagreb, Croatia

² Department of Obstetrics and Gynecology, University Hospital Center »Zagreb«, Zagreb, Croatia

³ Department of Cardiac Surgery, University Hospital Center »Zagreb«, Zagreb, Croatia

⁴ Department of Surgery, Division of Traumatology, University Hospital Center »Zagreb«, Zagreb, Croatia

ABSTRACT

Metastatic tumors of the long bones usually present with severe pain refractory to analgesic therapy. Pathologic fractures of the bone may lead to the significant decrease of patient's quality of life and necessitate further surgical therapy. We present 66 year old female with metastatic left breast carcinoma (T2N0M0) diagnosed 5 years before presentation of the metastatic lesion of the right femur causing severe pain in the middle of the right upper leg. Pain persisted after palliative irradiation therapy. We performed radiofrequency ablation of the metastatic lesion of the right femur using R.I.T.A. Medical System Generator. This resulted in total necrosis of the tumor mass that caused osteolysis of the internal part of the femoral cortex. First three months after RFA procedure, the pain and tenderness were absent and normal daily activities were performed without restrictions.

Key words: bone metastasis, femur, radiofrequency ablation, tumor necrosis

Introduction

Metastatic tumors of the long bones usually present with severe pain refractory to analgesic therapy. Pathologic fractures of the bone may lead to the significant decrease of patient's quality of life and necessitate further surgical treatment. Osteosynthesis, as a preventive or therapeutic procedure for the treatment of pathologic fractures, is usually performed by an intramedullar rod. This approach spreads tumor tissue through the medullar canal and accelerates progression of focal metastatic disease. Ablation of the metastasis in the femur with preserved cortex of the bone by radiofrequency ablation (RFA) is a procedure which coagulates the tumor with minimal destruction of surrounding tissue. Application of radiofrequency current on tumor results in tumor necrosis, destroying the tumor tissue¹. This stops the tumor growth and further osteolysis of the bone. RFA of the tumor results in reduction of pain because coagulation necrosis of the tumor prevents its osteolytic impact to the surrounding cortex. Our goal is to present this new

method in treatment of metastatic lesions of the long bones associated with severe pain refractory to analgesic therapy.

Case Report

We present a 66 year old female patient with diagnosed left breast carcinoma (T2N0M0) in 1998 and long-standing hypertrophic cardiomyopathy. Quadrantectomy was performed for breast cancer followed by chemotherapy. The patient was symptom-free until 2002., when she presented with severe pain in the middle of the right upper leg while moving or resting. Radiographic studies performed showed an osteolytic lesion in a medullar canal of the right femur with minimal involvement of the cortical layer (Figure 1b). The treatment with palliative irradiation therapy failed and pain persisted with same intensity. With unsuccessful palliative irradiation of met-

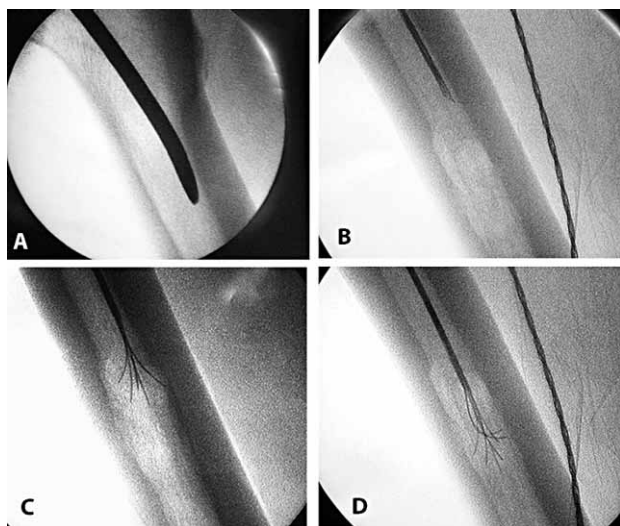


Fig. 1. RFA procedure in the right femur. a) introduction of intramedullary nail through major trochanter for creation of a canal for probe insertion, b) insertion of a probe through the canal, c) probe position in a proximal half of tumor mass, d) probe position in distal half of tumor mass.

astatic lesion there was a significant risk of pathologic fracture with further progress of the femoral disease. Persistent pain was also a significant problem. This was an indication for RFA².

After written consent obtained from the patient, in general anesthesia, we made 3 cm incision over major trochanter of the right femur. The hole in the cortex was made with curved awl and the probe connected to Radiofrequency Generator Model 1500 and StarBurst Ablation Device (R.I.T.A. Medical Systems, Inc., Mountain View, Ca, USA, www.ritamedical.com) was inserted containing electrodes into the medullar canal (Figure 1a). In order to destroy the whole volume of the tumor mass in one application, the procedure was performed with probe in two different positions. In the first position, probe was in the proximal half of the tumor mass, and in the second position in the distal half of the tumor mass (Figure 1c and d). Coagulation temperature in the medullar canal in the region where the tumor was located was 90 °C. Duration of the procedure was 15 minutes for each position of the probe. The patient was mobilized on postoperative day 1. She complained of mild paroxysmal pain in the femoral region. A week later there was complete absence of pain. Multislice computed tomography (MSCT) of the diaphysis of the right femur was performed 6 days after the procedure³. The cortex of the diaphysis at the osteolytic location is preserved but slightly narrowed. The medullar canal of the bone was widest at the ablation location. There were also nonmineral parts presenting nonmineralized organic tissue. Tissue with absorption coefficient of grease was located at the widest part of the medullar canal of the femur (Figure 2).

Chemotherapy was continued. The patient was thoroughly examined clinically once every month for three

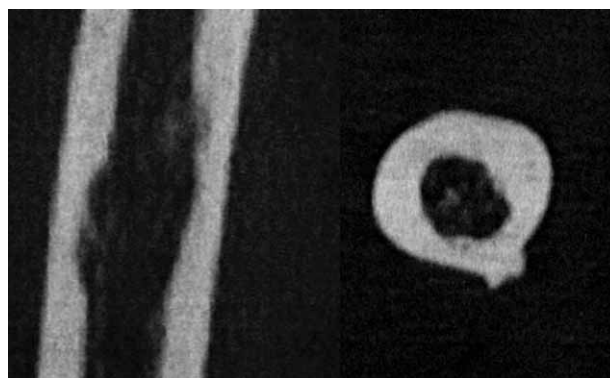


Fig. 2. MSCT of the right femur following the RFA procedure. Slightly narrowed cortex in the location of previously destroyed metastatic osteolytic lesion.

months and she was without pain and was performing normal daily activities without restrictions. CT scan was planned after six months and one year after the procedure but the patient died probably of acute cardiac failure.

Discussion

A generator with high frequency alternating electric current is needed for performing RFA as well as a probe with electrodes. Electrodes are placed directly in the tumor tissue. Electrodes connect the tissue to the high frequency alternating current resulting in ion agitation of the tissue. Friction of the ions causes generation of the thermal energy. Temperature of the tissue increases to 90 °C and it can reach 110 °C. The diameter of thermal injury for abovementioned electrode is 2–3 cm. Tissue coagulation is not limited to the tumor. It involves a thin layer of normal tissue. This partial destruction of normal tissue layer results in reaching the surgical line of resection. Dimension of the coagulation necrosis depends on several factors. Those include the type of the probe used and length of the electrodes, temperature, duration of the ablation and strength of the current. Thermo-indicators placed in the tips of the electrodes allow measurement of the temperature in target tissue, electric current and impedance of the tissue. The exposition time is also measured. These parameters are visible on the screen of the generator. They can also be followed on the monitor of the computer attached to the generator. This is the way to control efficiency of the procedure with 100% certainty. Those improvements positioned RFA as a standard procedure in the treatment of unresectable primary and metastatic tumors of the liver^{4–9}. The method is efficient in treatment of malignant lung tumors¹⁰. RFA is a successful method in osteoid osteoma treatment. First successful radiofrequent thermal ablation of the bone was first described by Tillotson et al. (1989) on the dog model¹¹.

According to the literature reports this is the first report of human endomedullar bone metastasis ablation. There were few reports of percutaneous CT or ultra-

sound-guided radiofrequency thermal ablation of bone metastases¹²⁻¹⁵. Further evaluation on larger number of cases is necessary to precisely evaluate the efficacy of this method for different types of metastases and rate of operative and postoperative complications. Preliminary, rate of operative and postoperative complications should be

lower than other techniques used for elimination of pain and prevention of pathologic fractures.

RFA can be a successful method in treatment of endomedullar tumor metastases of the long bones and its symptoms, especially the pain and pathologic fractures but further evaluation is necessary.

REFERENCES

- GROENEMEYER DHW, SCHIRP S, GEVARGEZ A, Acad Radiol, 9 (2002) 467. — 2. SINGLETARY SE, Semin Surg Oncol, 20 (2001) 246. — 3. RYBAK LD, ROSENTHAL DI, Q J Nucl Med, 45 (2001) 53. — 4. BLEICHER RJ, ALLEGRA DP, NORA DT, WOOD TF, FOSHAG LJ, BILCHIK AJ, Ann Surg Oncol, 10 (2003) 52. — 5. CHAN RP, ASCH M, KACHURA J, HO CS, GREIG P, LANGER B, SHERMAN M, WONG F, FELD R, GALLINGER S, Can Asso. Radiol J, 53 (2002) 272. — 6. JIANG HC, LIU LX, PIAO DX, XU J, ZHENG M, A. L. ZHU AL, QI SY, ZHANG WH, WU LF, World J Gastroenterol, 8 (2002) 624. — 7. LIU LX, JIANG HC, PIAO DX, World J Gastroenterol, 8 (2002) 393. — 8. IANNITTI DA., DUPUY DE, MAYO-SMITH WW, MURPHY B, Arch Surg, 137 (2002) 422. — 9. WONG SL, EDWARDS MJ, CHAO C, SIMPSON D, MCMASTERS KM, Am J Surg., 182 (2001) 552. — 10. BELFIORE G, MOGGIO G, TEDESCHI E, GRECO M, CIOFFI R, CINCOTTI F, ROSSI R, Am J Roentgenol, 183 (2004) 1003. — 11. TILLOTSON CL, ROSENBERG AE, ROSENTHAL DI, Invest Radiol, 24 (1989) 888. — 12. POGGI G, GATTI C, MELAZZINI M, BERNARDO G, STRADA M, TERAGNI C, DELMONTE A, TAGLIAFERRI C, BONEZZI C, BARBIERI M, BERNARDO A, FRATINO P, Anticancer Res, 23 (2003) 4977. — 13. GOETZ MF, CALLSTROM MR, CHARBONEAU JW, FARRELL MA, MAUS TP, WELCH TJ, WONG GY, SLOAN JA, NOVOTNY PJ, PETERSEN IA, BERES RA, REGGE D, CAPANNA R, SAKER MB, GRONEMEYER DH, GEVARGEZ A, AHRAR K, CHOTI MA, DE BAERE TJ, RUBIN J, J Clin Oncol, 22 (2004) 300. — 14. MARUYAMA, M., T. ASANO T, T. KENMOCHI T, O. KAINUMA O, K. IWASAKI K, H. MIYAUCHI H, SAIGO K, MIURA F, KOBAYASHI S, OCHIAI T, Anticancer Res, 23 (2003) 2987. — 15. NEEMAN Z, WOOD BJ, Tech Vasc Interv Radiol, 5 (2002) 156.

G. Augustin

*Department of Surgery, Division of Abdominal Surgery, University Hospital Center »Zagreb«, Kišpatičeva 12, 10000 Zagreb, Croatia
e-mail: augustin.goran@gmail.com*

ENDOMEDULARNA RADIOFREKVENCIJSKA ABLACIJA METASTATSKE LEZIJE DESNOG FEMURA 5 GODINA NAKON PRIMARNOG KARCINOMA GRUDI: PRIKAZ SLUČAJA

SAŽETAK

Metastatski tumori dugih kostiju obično se prezentiraju jakom boli refrakternom na analgetsku terapiju. Patološke frakture kostiju dovode do značajnog smanjenja kvalitete života tih bolesnika i zahtijevaju daljnju kiruršku terapiju. U ovom radu prikazujemo 66-godišnju bolesnicu sa metastatskim karcinomom primarnog tumora lijeve dojke (T2N0M0) dijagnosticiranim 5 godina prije prezentacije metastatske lezije dijafize desnog femura koja je uzrokovala izrazitu bol u srednjem dijelu natkoljenice. Bol je perzistirala i nakon palijativne iradijacijske terapije. Nakon neuspjele iradijacije učinjena je radiofrekvencijska ablacija metastatske lezije dijafize desnog femura pomoću uređaja R.I.T.A. Medical System. Procedura je rezultirala potpunom nekrozom tumorske mase uz minimalnu osteolizu okolnog korteksa femura. Prva tri mjeseca nakon procedure bol i bolnost bili su odsutni uz mogućnost izvršavanja svih dnevnih aktivnosti bez ikakvih ograničenja.