

Persistent accumulation of 4-hydroxynonenal-protein adducts in gastric mucosa after *Helicobacter pylori* eradication

Cherkas, Andriy; Yelisyeyeva, Olha; Semen, Khrystyna; Žarković, Kamelija; Kaminsky, Danylo; Čipak Gašparović, Ana; Jaganjac, Morana; Lutsyk, Alexander; Waeg, Georg; Žarković, Neven

Source / Izvornik: **Collegium Antropologicum, 2009, 33, 815 - 821**

Journal article, Published version

Rad u časopisu, Objavljena verzija rada (izdavačev PDF)

Permanent link / Trajna poveznica: <https://um.nsk.hr/um:nbn:hr:105:305431>

Rights / Prava: [In copyright](#)/[Zaštićeno autorskim pravom.](#)

Download date / Datum preuzimanja: **2025-01-05**



Repository / Repozitorij:

[Dr Med - University of Zagreb School of Medicine
Digital Repository](#)



Persistent Accumulation of 4-Hydroxynonenal-Protein Adducts in Gastric Mucosa after *Helicobacter Pylori* Eradication

Andriy Cherkas¹, Olha Yelisyeyeva², Khrystyna Semen¹, Kamelija Žarković³, Danylo Kaminskyy⁴, Ana Čipak Gašparović⁵, Morana Jaganjac⁵, Alexander Lutsyk², Georg Waeg⁶ and Neven Žarković⁵

¹ Department of Internal Medicine No.1, Danylo Halytskyi National Medical University, Lviv, Ukraine

² Department of Histology, Cytology, and Embryology, Danylo Halytskyi National Medical University, Lviv, Ukraine

³ Division of Pathology, University Hospital Centre »Zagreb«, Zagreb, Croatia

⁴ Department of Pharmaceutical Chemistry, Danylo Halytskyi National Medical University, Lviv, Ukraine

⁵ Division of Molecular Medicine, Institute »Ruder Bošković«, Zagreb, Croatia

⁶ Institute of Molecular Bioscience, University of Graz, Graz, Austria

ABSTRACT

Recent studies indicate that oxidative stress caused by *Helicobacter pylori* and insufficient host antioxidant defense could play important role in pathogenesis of gastrointestinal ulcerations. By specific monoclonal antibodies we have detected weak presence of the major lipid peroxidation bioactive marker 4-hydroxynonenal (HNE) in healthy human gastric mucosa, which strongly increased in case of *H. pylori*-associated peptic ulcer. Considering physiological presence of HNE on one hand, and high prevalence of *H. pylori* associated disorders on the other, evaluation of oxidative stress after treatment is important. Therefore, in current study immunohistochemical accumulation and distribution of HNE-protein adducts in gastric mucosa was evaluated with 21 patients having *H. pylori*-associated duodenal peptic ulcer (DPU) before and one month after eradication of *H. pylori*. Although dramatic decrease in histological manifestations of inflammation was demonstrated after eradication of *H. pylori*, initially high immunopositivity for the HNE-protein adducts remained elevated in antrum and even increased in stomach corpus. The observed accumulation and redistribution to higher grades of HNE-immunopositivity in nuclei of glandular cells in gastric corpus indicate augmentation of oxidative stress after treatment and open possibilities for adjuvant antioxidant treatments to protect gastric mucosa from progressive oxidative stress after eradication of *H. pylori* infection.

Key words: 4-hydroxynonenal, oxidative stress, *Helicobacter pylori*, eradication, peptic ulcer

Introduction

Eradication of *Helicobacter pylori* became the standard treatment strategy for duodenal peptic ulcer (DPU) and other disorders associated with this microorganism since 1996. Moreover, such approach has been demonstrated to decrease the incidence of gastric adenocarcinoma. It is known, that *H. pylori* causes chemotaxis of neutrophils and macrophages, their activation with excessive release of reactive oxygen species (ROS), mainly superoxide anion leading to development of inflammation. Activation of free radical reactions and lipid peroxidation triggers a number of metabolic cascades aimed to increase an antioxidant defense. Oxidative stress (OS) would develop as a result of excessive oxidative destruc-

tion of macromolecules (lipids, proteins, and nucleic acids) and consecutive accumulation of their oxidized products in cells. Its substantial role in initiation and progression of *H. pylori* – associated diseases is well known. Accumulation of products of lipid peroxidation and oxidative modification of proteins and nucleic acids in gastric mucosa of *H. pylori* infected subjects was documented. However, the depth of OS and clinical manifestations, which can vary from asymptomatic bearing to DPU and even malignancy, would depend upon the balance between the strength of pathogenic impact (*H. pylori*) and power of defensive mechanisms of the affected mucosa and entire body.

4-hydroxy-2,3-*trans*-nonenal (HNE) is well known secondary product of peroxidation of ω -6 polyunsaturated fatty acids and exhibits concentration-dependent action. Its excessive accumulation has been associated with OS while in physiologic concentrations HNE has been found to be an important signaling molecule regulating processes of differentiation, proliferation, apoptosis, inflammation, and energy metabolism. Our recent findings showed little amount of HNE in normal human gastric mucosa and excessive HNE-histidine conjugates accumulation in *H. pylori* positive DPU patients. Therefore, the aim of our study was to evaluate if eradication of *H. pylori* would result in attenuation of the HNE-presence in the gastric mucosa. That could be helpful to determine if standard eradication therapy is sufficient for recovery of mucosa with DPU patients including elimination OS and would provide insights into the role of the macroorganism in the ulcerogenesis.

Materials and Methods

Subjects

Twenty nine *H. pylori* positive patients aged 18–44 with endoscopically proved active DPU were enrolled into the study (mean age 32.1±1.7, 18 males and 11 females). 20 healthy volunteers (mean age 29.7±1.4, 13 males and seven females) without any gastrointestinal complaints and other registered health problems were used as a control group. Out of these patients eight were positive and 12 were negative for *H. pylori* presence. All *H. pylori* positive DPU patients were prescribed triple therapy (Lansoprazole 30 mg, Amoxicillin 1000 mg, and Clarithromycin 500 mg twice per day for seven days). After four to five weeks from the completion of the antimicrobial treatment patients underwent control endoscopic examination. The design of the study was approved by local Ethics Committee at Lviv National Medical University and informed consent was obtained from all patients and healthy volunteers.

Histology and assessment of *H. pylori* infection

Two biopsy specimens were obtained endoscopically from antrum and two from corpus of the stomach in all cases for histological examination. Namely, it is known that *H. pylori* are living in gastric mucosa predominantly in antrum and less likely in corpus of the stomach. Because of that, the specimens used for analytical and diagnostic purposes are taken from antrum and corpus. In duodenum this microorganism is rarely observed, while the risk of complications (perforation, haemorrhage) is much higher. Therefore, biopsies of duodenum are considered as relative risk and are not performed without good medical indices. Biopsy specimens were immediately fixed in buffered 10.0% formalin, then dehydrated in ethanol and embedded in paraffin, cut into 5-mm thick sections and examined with haematoxylin-eosin and modified Giemsa staining. Histologically, *H. pylori* infection was considered as negative if *H. pylori* were absent

in all biopsies obtained from one patient and positive if it was found in at least one sample. Inflammation, contamination of *H. pylori*, glandular atrophy and intestinal metaplasia were classified qualitatively as negative (0) or positive (1); and semi-quantitatively into four grades according to updated Sydney System as follows: 0, none; 1, mild; 2, moderate and 3, severe.

Determination of HNE-histidine conjugates

Paraffin blocks obtained only from patients with successful eradication of *H. pylori* (n=21) before and after treatment were further used for immunohistochemical staining: one slice of each specimen was cut into 5-mm thin sections, mounted on the slide coated with 3-aminopropyl-triethoxy silane, deparaffinated in xylene and rehydrated through a series of ethanol. Immunohistochemistry for HNE-modified proteins was carried out using monoclonal antibodies obtained from culture medium of the clone 'HNE 1g4', produced by a fusion of Sp2-Ag8 myeloma cells with B-cells of a BALB-c mouse immunized with HNE-modified keyhole limpet hemocyanine. The antibody is specific for the HNE-histidine epitope in HNE-protein (peptide) conjugates and gives only 5% cross-reactivity with HNE-lysine and 4% with HNE-cysteine.

Immunohistochemistry was done in a three step procedure as described before using LSAB kit (DAKO, Denmark) where the first step was incubation with anti-HNE monoclonal antibodies (dilution 1:10) during 2 h in humid chambers at room temperature. The second step was incubation with biotinylated secondary goat anti-mouse and anti-rabbit immunoglobulins (AB2) during 30 min. The third step was incubation with streptavidin peroxidase during 30 min. Finally, the reaction was visualized by a DAB (3,3-diaminobenzidine tetrahydrochloride in organic solvent) after 10 min. Negative control was done on one histological slice of the same tissue, without application of HNE-histidine specific monoclonal antibodies. Intensity and distribution of the HNE-immunostaining in the gastric mucosa from antrum and corpus of the stomach were evaluated semi-quantitatively. The absence of immunopositivity in cytoplasm and nuclei of glandular epithelial cell was marked with (0), while with (1) we marked weak immunopositivity in less than 25% of the cells, with (2) medium immunopositivity in 25–50% of cells and finally with (3) strong immunopositivity in more than 50% of cells. In superficial and foveolar epithelium, as well as in lamina propria of gastric mucosa, we distinguished only positive (1) and negative (0) immunostaining. All immunohistochemical analyses were done by a pathologist experienced in the HNE immunohistochemistry without prior knowledge of the study group design.

Statistical analysis

The prevalence of *H. pylori* infection, inflammation, glandular atrophy and intestinal metaplasia, as well as incidence of HNE in gastric tissues, was evaluated by χ^2 -test after classifying the marker as positive or nega-

tive. Possible difference in *H. pylori* contamination and intensity of HNE staining were done by Mann-Whitney U-test, using numerical description of positivity corresponding to respective standard grading of positivity as described above. Calculations were carried out using statistical software SPSS 9.0.

Results

Manifestations of inflammation in gastric mucosa, predominantly macrophagic and less frequently neutrophilic infiltration, were found much more commonly in DPU patients before *H. pylori* eradication than in control group (Table 1). *H. pylori* were found in four patients after treatment with acceptable eradication rate 81% (17 cases of 21). Eradication of *H. pylori* was associated with dramatic decrease in inflammatory markers in gastric mucosa of DPU patients: neutrophilic infiltration was not observed ($p < 0.05$) while macrophagic infiltration remained in only two patients ($p < 0.05$).

Immunohistochemical analysis revealed the presence of the HNE-histidine conjugates in gastric mucosa of DPU patients, as well as in control group (Table 2). Before eradication of *H. pylori* in DPU patients we found accumulation of HNE-histidine adducts in nuclei of glandular

epithelium in antrum of nine patients (42.9%) and in corpus of the stomach of the four patients (19.0%) in contrast to control group where HNE-positivity was not found in the epithelial nuclei at all (Table 2).

After eradication of *H. pylori* the HNE presence significantly decreased only in superficial epithelium ($p < 0.05$) while in foveolar epithelium of gastric corpus it even increased ($p < 0.05$). In other parts of stomach the accumulation of the HNE-histidine adducts did not change obviously while it even increased in nuclei of glandular cells in corpus (Table 2).

Further semiquantitative analysis showed different effects of *H. pylori* eradication on the accumulation HNE-protein adducts in antrum and in corpus of the stomach (Table 3).

In glandular epithelium of antrum before treatment we observed HNE-positivity of the epithelial cytoplasm in all 21 patients out of which four cases (19.1%) were of first grade, three (14.3%) were of second and 14 (66.7%) of third grade of the HNE-immunopositivity. The presence of HNE in the epithelial nuclei was observed in 9/21 (42.9%) patients, out of which six cases (28.6%) were of second and three (14.3%) were of the third grade of positivity. After *H. pylori* eradication no significant change of the HNE presence was noted according to the inci-

TABLE 1
PREVALENCE OF *H. PYLORI* INFECTION AND RESULTS OF HISTOLOGICAL EXAMINATION OF GASTRIC MUCOSA OF DUODENAL PEPTIC ULCER PATIENTS

Parameters	Healthy control (n=20)		DPU patients before eradication (n=21)		DPU patients after eradication (n=21)	
	Antrum	Corpus	Antrum	Corpus	Antrum	Corpus
<i>H. pylori</i>	8 (40.0)	7 (35.0)	21 (100.0)*	19 (90.5)*	2 (9.5)*#	2 (9.5)*#
Neutrophils	2 (10.0)	2 (10.0)	5 (23.8)	3 (14.3)	0 (0.0) #	0 (0.0)
Monocytes	8 (40.0)	7 (35.0)	21 (100.0)*	21 (100.0)*	2 (9.5)*	2 (9.5)*
Atrophy	0 (0.0)	0 (0.0)	2 (9.5)	3 (14.3)	1 (4.8)	2 (9.5)
Metaplasia	0 (0.0)	0 (0.0)	1 (4.8)	0 (0.0)	1 (4.8)	0 (0.0)
Dysplasia	0 (0.0)	0 (0.0)	1 (4.8)	0 (0.0)	0 (0.0)	0 (0.0)
Lymphoid follicles	2 (10.0)	2 (10.0)	7 (33.3)	5 (23.8)	1 (4.8) #	0 (0.0) #

§the relative incidence values (%) are given in brackets; *the difference comparing to control group by χ^2 – test significant at < 0.05 ; #the difference before and after treatment by χ^2 – test significant at < 0.05 .

TABLE 2
4-HYDROXYNONENAL-IMMUNOHISTOCHEMISTRY OF GASTRIC MUCOSA IN HEALTHY SUBJECTS AND IN PATIENTS WITH DUODENAL PEPTIC ULCER (DPU)

Parameters	Healthy control (n=20)		DPU patients before eradication (n=21)		DPU patients after eradication (n=21)	
	Antrum	Corpus	Antrum	Corpus	Antrum	Corpus
Superficial epithelium	2 (10.0)§	0 (0.0)	7 (33.3)	15 (71.4)*	8 (38.1)*	6 (28.6)*#
Foveolar epithelium	1 (5.0)	0 (0.0)	10 (47.6)*	10 (47.6)*	8 (38.1)*	17 (81.0)*#
Lamina propria	7 (35.0)	8 (40.0)	16 (76.2)*	16 (76.2)*	17 (81.0)*	20 (95.2)*
Cytoplasm of glandular cells	20 (100.0)	19 (95.0)	21 (100.0)	21 (100.0)	19 (90.5)	21 (100.0)
Nuclei of glandular cells	0 (0.0)	0 (0.0)	9 (42.9)*	4 (19.0)*	8 (38.1)*	9 (42.9)*

§the relative incidence values (%) are given in brackets; *the difference comparing to control group by χ^2 – test significant at < 0.05 ; #the difference before and after treatment by χ^2 – test significant at < 0.05 .

TABLE 3
SUBCELLULAR 4-HYDROXYNONENAL-IMMUNOHISTOCHEMISTRY OF GASTRIC MUCOSA IN DUODENAL PEPTIC
ULCER PATIENTS BEFORE AND ONE MONTH AFTER ERADICATION TREATMENT

	Grade of positivity*	Antrum (n=21)		Corpus (n=21)	
		Before eradication	After eradication	Before eradication	After eradication
Glandular cytoplasm	0	0 (0.0) [§]	2 (9.5)	0 (0.0)	0 (0.0)
	1	4 (19.1)	0 (0.0)	1 (4.76)	0 (0.0)
	2	3 (14.3)	6 (28.6)	14 (66.7)	2 (9.5)
	3	14 (66.7)	13 (61.9)	6 (28.6)	19 (90.5)
Glandular nuclei	0	12 (57.1)	13 (61.9)	17 (81.0)	12 (57.1)
	1	0 (0.0)	1 (4.8)	2 (9.5)	0 (0.0)
	2	6 (28.6)	5 (23.8)	2 (9.5)	3 (14.3)
	3	3 (14.3)	2 (9.5)	0 (0.0)	6 (28.6)

*Semi-quantitative staging as described in Material and methods; [§] relative incidence values are given in brackets (%)

dence of the immunopositive subjects when antrum mucosa was analysed.

Quite different findings were noted in corpus of stomach (Table 3). Before *H. pylori* eradication we observed HNE-positivity in the cytoplasm of glandular cells in every patients being mild in one patient (4.8%), moderate in 14 (66.7%) and very prominent in six volunteers (28.6%). Epithelial nuclei were HNE-positive in only four (19.0%) subjects expressing mild to moderate HNE presence. However, one month after *H. pylori* eradication significant further increase in HNE-protein adducts was observed ($p < 0.001$ in cytoplasm and $p = 0.037$ in nuclei). Redistribution of HNE-histidine adducts resulted in higher grades of immunopositivity both in cytoplasm and in nuclei of these patients (Table 3).

Discussion

Major risk factors of peptic ulcer include *H. pylori*, emotional stress, tobacco and alcohol abuse, gastric hyperacidity, and heredity, which facilitates imbalance between factors of aggression and defense. In this process the leading role belongs to cellular hypoxia accompanied by microcirculatory dysfunction, OS, and inflammation with subsequent reduction of protective mechanisms in gastric and duodenal mucosa. The derangements of cyto-protection appear mainly due to decline in intensity, efficiency and coupling of redox reactions in cells. The latter are needed for utilization of oxidative destruction products and maintenance of pO_2 by oxygen generation in radical reactions. Recently, essential trigger role of ROS in various signaling pathways, activation of mitochondrial function, and consequential increase in energy and adaptive potential is widely discussed as vital property of the living system. In this regard, excessive accumulation of oxidatively modified products appears to be due to the high rate of their production on the one hand, while on the other it can reflect decrease in their elimination. In other words, metabolically active tissues produce significant amounts of ROS and their derivatives, but detoxifi-

cation systems efficiently eliminate them, thus keeping them at physiological levels. However, decreased rate of electron transfer in respiratory chain with consequent increased leak of and extreme production of superoxide, which cannot be compensated, causes free radical destruction of cell structures, failure of mitochondrial function, decline of ATP production, fall of membrane potential, lack of detoxification activity and accumulation of these waste products.

HNE is ubiquitous product of lipid peroxidation and exerts concentration-dependent action on regulation of inflammation (limitation of NF- κ B and enhancement p38 pathways activities), proliferation and apoptosis (activation of JNK and inhibition of p53 pathways respectively), reinforcement of antioxidant defense and detoxification through Nrf2/ARE cascades induction, and energy metabolism by stimulation of PPAR nuclear receptors. Thus, HNE possesses dual properties in cell metabolism, and in physiological concentrations it is important regulatory molecule, while in high concentrations serves as valuable marker of OS.

In accordance with our previous findings the results presented in this study indicate excessive accumulation of HNE-histidine adducts in gastric mucosa in foveolar epithelium, lamina propria, and especially in nuclei of glandular cells with PUD patients comparing to healthy volunteers. Our current study revealed that eradication of *H. pylori* dramatically reduces inflammatory cells infiltration of mucosa and improves clinical symptoms as assessed one month after treatment completion. It can be assumed that decrease of OS manifestations could be expected due to pathogen removal. However, the only significant decrease in HNE accumulation after treatment was observed in superficial epithelium of the stomach corpus. This can be attributed to removal of *H. pylori* impact on superficial epithelium due to eradication of microorganism, and, probably, only superficial gastric epithelium is significantly suffering from oxidative damage induced by this microb. At the same time accumulation of HNE-histidine adducts in other locations did not de-

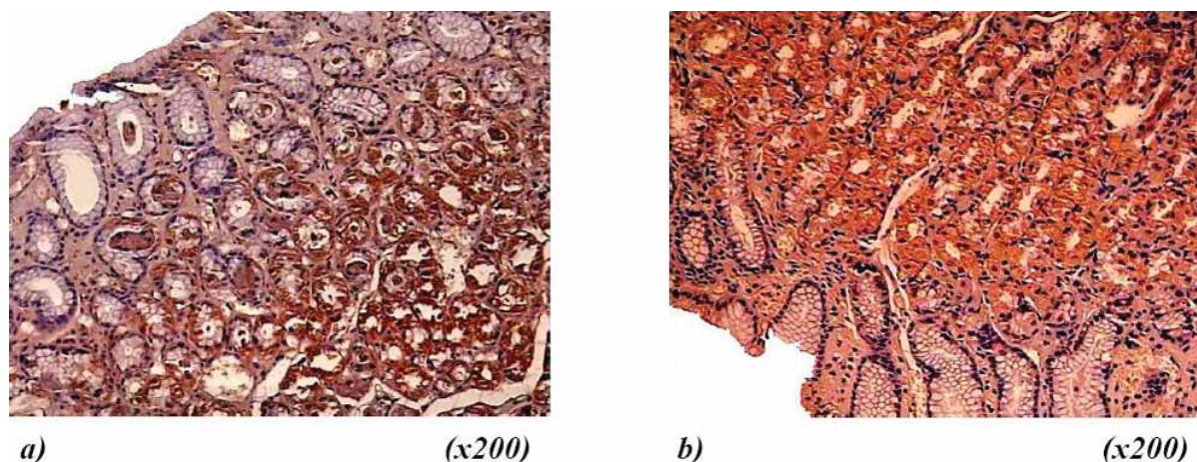


Fig. 1. Immunohistochemical appearance of 4-hydroxynonenal (HNE) in gastric mucosa of healthy volunteers: a) mild accumulation of HNE-histidine conjugates was found in cytoplasm and no HNE-positivity in nuclei of glandular cells in *H. pylori*-negative healthy subject, magnification 200 \times ; b) weak HNE-immunopositivity of gastric mucosa of *H. pylori*-positive asymptomatic subject, magnification 200 \times .

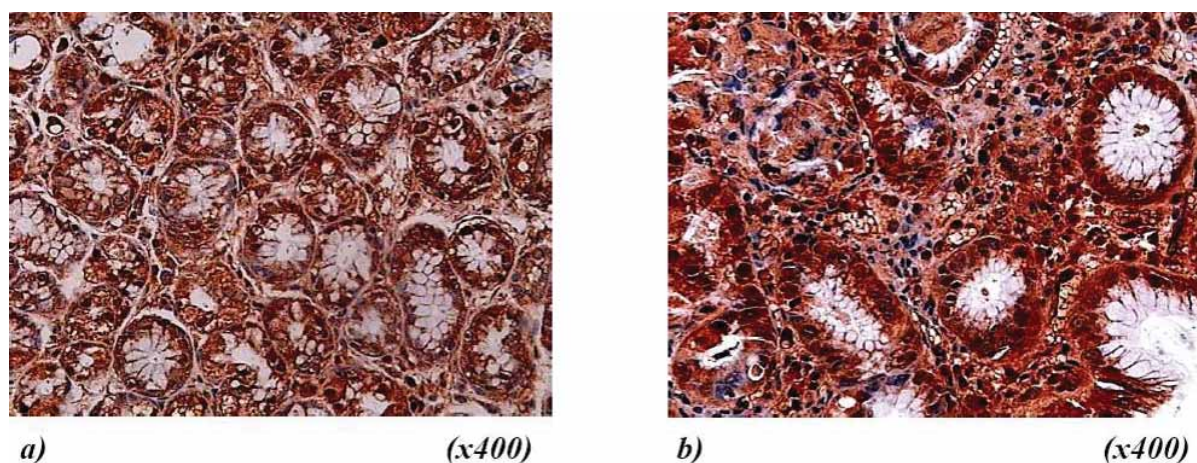


Fig. 2. Immunohistochemical appearance of 4-hydroxynonenal (HNE) in gastric mucosa of *H. pylori*-positive duodenal peptic ulcer patients: a) accumulation of HNE-histidine conjugates was found in cytoplasm and in some nuclei of glandular cells before treatment, magnification 400 \times ; b) HNE-immunopositivity increased, especially prominent accumulation of HNE in nuclei of glandular cells, 4-5 weeks after *H. pylori* eradication, magnification 400 \times .

crease markedly and even increased in foveolar epithelium, lamina propria and glandular nuclei of gastric corpus.

Further semiquantitative analysis in glandular cells allowed specifying intracellular accumulation of HNE-histidine adducts. Significant redistribution of HNE adducts on account of more pronounced immunopositivity (predominantly grade 3) after treatment, especially in corpus of the stomach was observed. Hence, our results indicate persistence and even progression of OS and lipid peroxidation in gastric mucosa one month after *H. pylori* eradication.

The current literature data do not allow conclusions in respect to the OS manifestations after *H. pylori* eradication in human mucosa. Most studies report successful elimination or decrease of products of oxidative degradation after *H. pylori* eradication. However some studies indicate persistence of OS manifestations after *H. pylori*

eradication with many patients. These data together with our findings support clinical observation of recurrence of DPU, persistence of dyspepsia and even high risk of gastric adenocarcinoma development with some patients despite successful *H. pylori* eradication. Severe accumulation of HNE-protein adducts after eradication could explain recurrence of clinical manifestations due to chemoattractive properties of this aldehyde, which supports migration of macrophages and neutrophils to gastric mucosa, maintaining local inflammation. Thus, excessive HNE accumulation in gastric mucosa could depend not only on *H. pylori* infection but also on host factors, e.g. individual resistance to oxidative challenge. This possibility is also supported by commonly found small accumulation of HNE in all *H. pylori* positive healthy volunteers. In other words, the excessive accumulation of HNE-protein adducts appears as a result of decreased re-

sistance to OS, while normal or high resistance is associated with its mild accumulation.

Although these aspects of eradication therapy require further studies, they point to the importance of ulcerogenic mechanisms, other than *H. pylori* infection. Our study also signifies the importance of administration of antioxidant treatment aimed to reduce of OS manifestations in complex DPU management (such as plant oils containing polyunsaturated fatty acids, caloric restriction, etc.) with subsequent induction of endogenous antioxidant mechanisms.

Conclusions

Successful *H. pylori* eradication dramatically reduced inflammatory cells infiltration in gastric mucosa, as assessed in four to five weeks after treatment. However, it

did not decrease the presence of HNE-protein adducts in gastric mucosa. *H. pylori* eradication even caused increase in HNE accumulation in cytoplasm and especially in nuclei of glandular cells in gastric corpus. Taken together, these findings indicate persistence of oxidative stress after elimination of pathogenic microorganism with DPU patients and necessity of adjuvant treatment options aimed at protection from oxidative challenge.

Acknowledgements

This study is dedicated to the memory on our teacher Professor Mykhailo Tymochko who left us valuable scientific acquirement in the field of free radical and oxygen homeostasis and died too early. The study was supported by Croatian Ministry of Science and Sports and by COST B35 Action.

REFERENCES

- EGAN BJ, KATICIC M, O'CONNOR HJ, O'MORAIN CA, Helicobacter, 12 Suppl 1 (2007) 31. — 2. PAKODI F, ABDEL-SALAM OM, DEBRECENI A, MOZSIK G, J Physiol Paris, 94 (2000) 139 — 3. VAKIL N, MEGRAUD F, Gastroenterol, 133 (2007) 985. — 4. CORREA P, FONTHAM ET, BRAVO JC, BRAVO LE, RUIZ B, ZARAMA G, REALPE JL, MALCOM GT, LI D, JOHNSON WD, MERA M, J Natl Cancer Inst, 92 (2000) 1881. — 5. KONTUREK PC, KONTUREK SJ, BRZOZOWSKI T, J Physiol Pharmacol, 57 Suppl (2006) 51. — 6. YELISYEYEA OP, SEMEN KO, CHERKAS AP, KAMINSKY DV, Contemporary gastroenterology, 7 (2008) 38. — 7. AUGUSTO AC, MIGUEL F, MENDONCA S, PEDRAZZOLI JJR, GURGUEIRA SA, Clin Biochem, 40 (2007) 615. — 8. EVERETT SM, SINGH R, LEURATTI C, WHITE KL, NEVILLE P, GREENWOOD D, MARNETT LJ, SCHORAH CJ, FORMAN D, SHUKER D, AXON AT, Cancer Epidemiol Biomarkers Prev, 10 (2001) 369. — 9. KHALED MA, SARKER SA, Nutr Res, 18 (1998) 1463. — 10. MASHIMO M, NISHIKAWA M, HIGUCHI K, HIROSE M, WEI Q, HAQUE A, SASAKI E, SHIBA M, TOMINAGA K, WATANABE T, FUJIWARA Y, ARAKAWA T, INOUE M, Helicobacter, 11 (2006) 266. — 11. MATTHEWS GM, BUTLER RN, Helicobacter, 10 (2005) 298. — 12. YELISYEYEA O, CHERKAS A, ZARKOVIC K, SEMEN K, KAMINSKY D, WAEG G, ZARKOVIC N, Free Radic Res, 42 (2008) 205. — 13. KONTUREK SJ, KONTUREK PC, KONTUREK JW, PLONKA M, CZESNIKIEWICZ-GUZIK M, BRZOZOWSKI T, BIELANSKI W, J Physiol Pharmacol, 57 Suppl 3 (2006) 29. — 14. KWIECIEN S, BRZOZOWSKI T, KONTUREK SJ, J Physiol Pharmacol, 53 (2002) 39. — 15. FELLEJ CP, PIGNATELLI B, VAN MELLE GD, CRABTREE JE, STOLTE M, DIEZI J, CORTHESEY-THEULAZ I, MICHETTI P, BANCEL B, PATRICOT LM, OHSHIMA H, FELLEJ-BOSCO E, Helicobacter, 7 (2002) 342. — 16. LI C-Q, PIGNATELLI B, OHSHIMA H, Dig Dis Sci, 46 (2001) 836. — 17. PIGNATELLI B, BANCEL B, PLUMMER M, TOYOKUNIS, PATRICOT L-M, OHSHIMA H, Am J Gastroenterol, 96 (2001) 1758. — 18. BI LC, KAUNITZ JD, Curr Opin Gastroenterol, 19 (2003) 526. — 19. MANJARI V, DAS UN, Prostaglandins, Leukotrienes & Essential Fatty Acids, 59 (1998) 401. — 20. ESTERBAUER H, SCHAUR RJ, ZOLLNER H, Free Radic Biol Med, 11 (1991) 81. — 21. SIEMS W, GRUNE T, SOMMERBURG O, FLOHE L, CADENAS E, Biofactors; 24 (2005) 1. — 22. UCHIDA K, Progress in Lipid Research, 42 (2003) 318. — 23. ZARKOVIC N, Mol Asp Med, 24 (2003) 281. — 24. WAEG G, DIMISITY G, ESTERBAUER H, Free Radic Res, 25 (1996) 149. — 25. ECKL P, ORTNER A, ESTERBAUER H, Mutat Res, 290 (1993) 183. — 26. ZARKOVIC N, ZARKOVIC K, SCHAUR RJ, STOLC S, SCHLAG G, REDL H, WAEG G, BOROVIC S, LONCARIC I, JURIC G, HLAVKA V, Life Sci, 65 (1999) 1901. 27. POGROMOV AP, LASHKEVICH AV, Clinical Medicine (Russian), (1996) 3. — 28. BAGCHI D, MCGINN TR, YE X, BAGCHI M, KROHN RL, CHATTERJEE A, STOHS SJ, Dig Dis Sci, 47 (2002) 1405. — 29. PEEK RM JR, Am J Physiol Gastrointest Liver Physiol, 289 (2005) G8. — 30. TYMOCHKO MF, YELISYEYEA OP, KOBYLINSKA LI, TYMOCHKO IF, Metabolic aspects of the oxygen homeostasis formation in the extremal states, (Missioner, Lviv, 1998). — 31. JONES DP, Chem Biol Interact, 163 (2006) 38. — 32. PACKER L, CADENAS E, Free Radic Res, 41 (2007) 951. — 33. VOEIKOV VL, Cell Mol Biol, 51 (2005) 663. — 34. VOEIKOV VL, J Altern Complem Med, 12 (2006) 111. — 35. VOEIKOV VL, J Altern Complem Med, 12 (2006) 265. — 36. COLEMAN JD, PRABHU KS, THOMPSON JT, REDDY PS, PETERS JM, PETERSON BR, VANDEN HEUVEL JP, Free Radic Biol Med, 42 (2007) 1155. — 37. PODOPRIGOROVA VG, Oxidative stress and ulcer disease (Medicina, Moscow, 2004). — 38. AHMED N, Annals Clin Microbiol Antimicrobials, 4 (2005) 17. — 39. HUNT RH, FALLONE C, VELDHYUZEN VZ, SHERMAN P, SMAILL F, THOMSON AB, Can J Gastroenterol, 16 (2002) 57. — 40. ZHANG C, YAMADA N, WU Y-L, WEN M, MATSUHISA T, MATSUKURA N, World J Gastroenterol, 11 (2005) 976. — 41. NITTI M, DOMENICOTTI C, D'ABRAMO C, ASSERETO S, COTTALASSO D, MELLONI E, POLI G, BIASI F, MARINARI UM, PRONZATO MA, Biochem Biophys Res Commun, 268 (2002) 642. — 42. UCHIDA K, KUMAGAI T, Mol Asp Medicine, 24 (2003) 213.

Neven Žarković

Division of Molecular Medicine, Institute »Ruđer Bošković«, Bijenička 54, HR-10000 Zagreb, Croatia.
E-mail: zarkovic@irb.hr

POVEĆANO NAKUPLJANJE 4-HIDROKSINONENAL-PROTEINSKIH KONJUGATA U ŽELUČANOJ SLUZNICI ZAOSTAJE NAKON IZLJEČENJA *HELICOBACTER PYLORI*

S A Ž E T A K

Dosadašnja istraživanja pokazala su da bi oksidacijski stres uzrokovan bakterijom *Helicobacter pylori*, zajedno sa smanjenom antioksidacijskom zaštitom domaćina, mogao igrati značajnu ulogu u patogenezi želučanog ulkusa. U prijašnjem radu dokazali smo izvornim monoklonskim protutijelima slabi pozitivitet 4-hidroksinonenala (HNE), glavnog bioaktivnog biljega lipidne peroksidacije, u fiziološkim uvjetima u zdravoj ljudskoj želučanoj sluznici. Pozitivitet HNEa pojačavao se u slučaju infekcije s *H. pylori* kao i kod peptičnog ulcua. Obzirom na fiziološku prisutnost HNEa s jedne strane i visoke učestalosti bolesti vezane uz *H. pylori* s druge strane, procjena oksidacijskog stresa nakon tretmana mogla bi biti važan progostički parametar. U ovom radu praćena je imunohistokemijska distribucija HNE-proteinskih konjugata u želučanoj sluznici kod 21 pacijenta sa ulcusom dvanaesnika (DPU) izazvanim *H. pylori* prije liječenja i mjesec dana poslije liječenja. Uočeno povećanje i preraspodjela HNE-pozitiviteta u jezgri žljezdanih stanica u tijelu želuca ukazuju na povećanje oksidacijskog stresa nakon tretmana te time pruža mogućnost adjuvantnog antioksidacijskog tretmana za zaštitu sluznice želuca od razvoja oksidacijskog stresa i lipidne peroksidacije u i nakon infekcije s *H. pylori*. Nakon izliječenja *H. pylori*, histološki pokazatelji upale su drastično sniženi, no količina HNE- proteinskih konjugata je i dalje povišena u antrumu, te dodatno povišena u tijelu želuca.