

# Digital morphometry of cytologic aspirate endometrial samples

---

**Mahovlić, Vesna; Ovanin-Rakić, Ana; Škopljanac-Maćina, Lada; Barišić, Ana; Rajhvajn, Sanda; Jurič, Danijela; Šamija Projić, Ivana; Ilić-Forko, Jadranka; Babić, Damir; Škrablin-Kučić, Snježana; ...**

*Source / Izvornik:* **Collegium Antropologicum, 2010, 34, 45 - 51**

**Journal article, Published version**

**Rad u časopisu, Objavljena verzija rada (izdavačev PDF)**

*Permanent link / Trajna poveznica:* <https://um.nsk.hr/um:nbn:hr:105:239585>

*Rights / Prava:* [In copyright](#)/[Zaštićeno autorskim pravom.](#)

*Download date / Datum preuzimanja:* **2024-08-29**



*Repository / Repozitorij:*

[Dr Med - University of Zagreb School of Medicine  
Digital Repository](#)



# Digital Morphometry of Cytologic Aspirate Endometrial Samples

Vesna Mahovlić<sup>1</sup>, Ana Ovanin-Rakić<sup>1</sup>, Lada Škopljanač-Maćina<sup>1</sup>, Ana Barišić<sup>1</sup>, Sanda Rajhvajn<sup>1</sup>, Danijela Jurić<sup>1</sup>, Ivana Šamija Projić<sup>1</sup>, Jadranka Ilić-Forko<sup>2,5</sup>, Damir Babić<sup>2,5</sup>, Snježana Škrablin-Kučić<sup>3,5</sup> and Jadranka Božikov<sup>4,5</sup>

<sup>1</sup> Department of Gynecologic Cytology, University Department of Gynecology and Obstetrics, University Hospital Center Zagreb, Zagreb, Croatia

<sup>2</sup> Department of Gynecologic and Perinatal Pathology, University Department of Clinical Pathology, University Hospital Center Zagreb, Zagreb, Croatia

<sup>3</sup> Department of Perinatal Medicine, University Department of Gynecology and Obstetrics, University Hospital Center Zagreb, Zagreb, Croatia

<sup>4</sup> School of Public Health »Andrija Štampar«, School of Medicine, University of Zagreb, Zagreb, Croatia

<sup>5</sup> University of Zagreb, School of Medicine, Zagreb, Croatia

## ABSTRACT

Unlike cervical cytology, morphological cytology criteria in the differential diagnosis of endometrium have not yet been clearly defined, and methods to allow for more precise evaluation of endometrium status have been searched for. The aim of the present study was to assess the value of morphometric nucleus analysis of cytologic aspirate endometrial samples in proliferative, hyperplastic and malignant endometrium by use of digital image analysis. Morphometric analysis was performed on archival cytologic aspirate endometrial samples (at least 10 per group) stained according to Papanicolaou ( $n=77$ ) and May-Grünwald-Giemsa (MGG;  $n=80$ ) with the following histopathologic diagnoses: proliferative endometrium, hyperplasia simplex, hyperplasia complex, hyperplasia complex atypica, and adenocarcinoma endometrioides endometrii (grade I, II and III). Interactive image analysis (nuclear area, convex area, perimeter, maximum and minimum radius, length and breadth, as well as nucleus form factor and elongation factor) was performed by use of the SFORM software (VAMSTEC, Zagreb) on at least 50 (Papanicolaou stain) and 100 (MGG stain) well preserved endometrial epithelial cell nuclei without overlapping, at magnification of  $\times 1000$ . Statistical data analysis was done by use of the Statistica Ver. 6 statistical package. Multivariate analysis (ANOVA) distinguished malignant, hyperplastic and proliferative endometrium according to all morphometric variables with both staining methods ( $p < 0.05$ ). However, on interactive testing of the groups (Kruskal-Wallis test), hyperplasias without atypia yielded no significant differences ( $p > 0.05$ ) from atypical hyperplasia, adenocarcinoma and proliferative endometrium only according to the nucleus form factor and elongation factor (Papanicolaou stain), whereas malignant and atypical hyperplastic endometrium (MGG stain) differed statistically significantly ( $p < 0.05$ ) from proliferative and hyperplastic endometrium without atypia according to all study parameters except for the nucleus form factor ( $p > 0.05$ ). According to the cytologic staining method, morphometric parameters were considerably higher in MGG stained endometrial samples, reaching the level of statistical significance ( $p < 0.05$ ) except for the nucleus form factor and elongation factor ( $p > 0.05$ ) in the groups of hyperplasia simplex and complex, well differentiated adenocarcinoma (form factor) and atypical hyperplasia (elongation factor). A combination of cytomorphology and the morphometric variables assessed in this study can yield useful information on the cytologic state of endometrium, with special reference to the possible differentiation of the group of hyperplasia without atypia from the group of adenocarcinoma and atypical hyperplasia.

**Key words:** endometrial cytology, digital image analysis, morphometry

## Introduction

In direct cytologic endometrial samples, morphological criteria to differentiate normal from reactive and hyperplastic endometrial cells, and hyperplastic from malignant endometrial cells have not yet been clearly defined. In particular, difficulties are encountered on distinguishing endometrial cells in certain types of endometrial hyperplasia as well as atypical complex hyperplasia from well differentiated malignant endometrial cells<sup>1–4</sup>. The presence of glandular and stromal fragments in endometrial cytologic samples enables the cytologist to use histopathologic criteria on diagnosing particular types of endometrial hyperplasia<sup>2,3</sup>. These differential diagnostic difficulties encountered on the analysis of both cytologic and histopathologic samples have led to the intensive search for methods that would enable more precise evaluation of the endometrium. In order to upgrade cytologic diagnosis, morphometric methods have been used on direct endometrial cytology samples<sup>5–8</sup>.

According to Baak's definition, morphometry is a quantitative description of the form<sup>9,10</sup>, and unlike other morphological methods, it enables the finding to be numerically expressed. The method is inexpensive and technically simple, thus being applicable on the material processed by standard procedure<sup>11</sup>, while morphometric parameters are objective and reproducible<sup>9–11</sup>. The method of interactive computer-assisted image analysis is most widely used. Contours of the structures to be measured are delineated partly automatically and partly manually. Various planimetric parameters can thus be determined, i.e. simple (area, diameter, radius, longest and shortest axis of the object); shape factors (describing object irregularity, e.g., form factor-FF and elongation factor); biphasic parameters (nucleo-cytoplasmic ratio – N/C, nucleo-nucleolar ratio – N/N; contextual parameters (accumulation area, number of elements *per* accumulation, distance between accumulations, etc.)<sup>10–12</sup>; texture parameters; parameters related to the level of grayness; and densitometric parameters<sup>7,13,14</sup>.

The aim of the present study was to assess the value of morphometric analysis of nuclei in aspirate cytology samples of proliferative, hyperplastic and malignant endometrium by use of digital image analysis.

## Patients and Methods

Digital morphometric analysis was employed on archival aspirate cytology endometrial samples with the following histopathologic diagnoses: proliferative endometrium, hyperplasia simplex (HS), hyperplasia complex (HC), hyperplasia complex atypica (HA), adenocarcinoma endometrioides endometrii grade I (adenoCa gr. I), adenocarcinoma endometrioides endometrii grade II (adenoCa gr. II), and adenocarcinoma endometrioides endometrii grade III (adenoCa gr. III). Cytologic samples were stained by the standard methods of Papanicolaou (proliferation n=12; HS n=13; HC n=12; HA n=10, adenoCa gr. I n=10; adenoCa gr. II n=10; and adenoCa

gr. III n=10) and May-Grünwald-Giemsa (MGG) (proliferation n=12; HS n=13; HC n=13; HA n=10, adenoCa gr. I n=12; adenoCa gr. II n=10; and adenoCa gr. III n=10). The SFORM system (VAMSTEC, Zagreb, Croatia) was used for digital image morphometry. The system includes a high-resolution CCD color TV camera transferring the image from the microscope (Olympus BHS, Tokyo, Japan) to a PC-compatible computer *via* a picture digitizer, with a resolution of 512×512 pixels, whereby each of them can assume a value described by 24 bits. The digital image (Figure 1a, b) is subject to morphometric parameter object analysis. Namely, the measured results of selected objects marked by mouse are automatically transferred and logged in previously defined tables. The analysis was performed on at least 50 (Papanicolaou stain) and 100 (MGG stain) well preserved nuclei of endometrial epithelial cells without overlapping, at magnification ×1000 (immersion objective). Morphometric measurements of the cytoplasm characteristics were not performed because of the unsharp cell margins and overlapping, as also reported elsewhere<sup>7</sup>. Interactive morphometric analysis was performed to measure nucleus area and perimeter, maximal and minimal nucleus radius, nucleus convexity, length and breadth of the nucleus, nucleus form factor ( $FF = 4\pi \text{ area}/r^2$ ) and nucleus elongation factor (breadth/length).

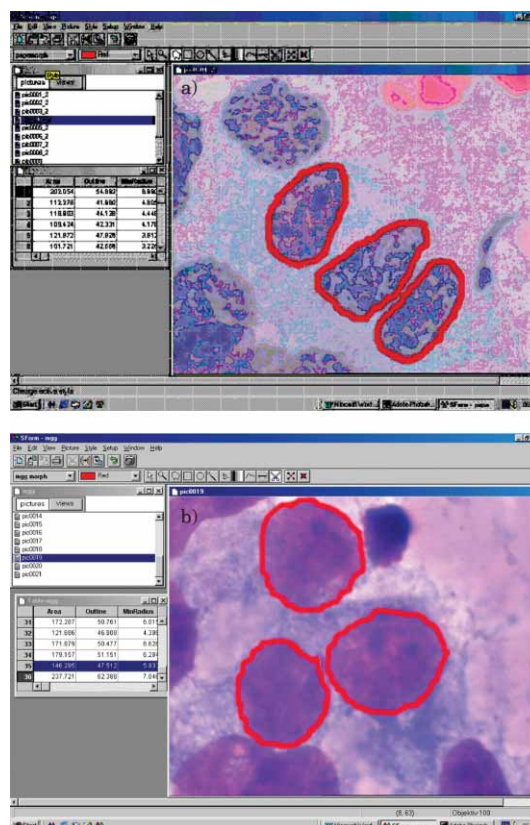


Fig. 1. Digital image – morphometric nuclei analysis of cytologic aspirate endometrial sample: a – Papanicolaou stain, b – May-Grünwald Giemsa stain (×1000).

**TABLE 1**  
NUCLEAR PARAMETERS ( $\bar{X}\pm SD$ ) IN CYTOLOGIC ASPIRATE ENDOMETRIAL SAMPLES (PAPANICOLAOU STAIN)

Cytologic sample	Area ( $\mu\text{m}^2$ )	Outline ( $\mu\text{m}$ )	Min. radius ( $\mu\text{m}$ )	Max. radius ( $\mu\text{m}$ )	Convex area ( $\mu\text{m}^2$ )	Length ( $\mu\text{m}$ )	Breadth ( $\mu\text{m}$ )	Form factor*	L/B**
AdenoCa gr. III	89.66±43.21	37.99±8.23	3.90±1.11	6.75±1.47	92.46±43.91	12.90±2.81	9.00±2.27	0.76±0.09	1.48±0.35
AdenoCa gr. II	79.58±31.63	35.71±7.04	3.70±0.96	6.43±1.35	81.86±32.30	12.30±2.57	8.43±1.91	0.77±0.09	1.51±0.38
AdenoCa gr. I	66.06±19.85	31.91±4.72	3.45±0.73	5.81±1.00	67.54±20.17	11.15±1.93	7.77±1.47	0.80±0.67	1.48±0.34
HA	73.26±21.72	33.64±5.18	3.65±0.79	6.07±1.05	74.79±22.02	11.65±2.00	8.18±1.51	0.80±0.08	1.46±0.34
HC	57.84±16.21	30.50±4.60	3.16±0.67	5.52±0.97	59.43±16.63	10.57±1.85	7.20±1.31	0.77±0.08	1.51±0.37
HS	57.23±15.57	30.60±4.44	3.11±0.66	5.57±0.96	58.82±15.83	10.66±1.81	7.09±1.29	0.76±0.09	1.55±0.39
Proliferation	51.18±19.15	28.14±5.19	2.93±0.75	5.20±1.05	52.41±19.41	9.95±2.04	6.66±1.50	0.79±0.08	1.54±0.37
P***	0.000	0.000	0.000	0.000	0.000	0.000	0.000	0.000	0.000

SD – standard deviation; min. – minimum; max. – maximum; \*nuclear regularity ( $4\pi \text{ area}/r^2$ ), \*\*nuclear elongation (length/breadth); AdenoCa gr. – adenocarcinoma grade; HA – hyperplasia endometrii atypica; HC – hyperplasia endometrii complex; HS – hyperplasia endometrii simplex; \*\*\*probability (ANOVA by ranks)

**TABLE 2**  
STATISTICALLY SIGNIFICANT QUANTITATIVE IMAGE VARIABLES (KRUSKAL-WALLIS TEST) IN HYPERPLASTIC ENDOMETRIUM WITHOUT ATYPIA *VERSUS* PROLIFERATIVE, ATYPICAL HYPERPLASTIC AND MALIGNANT ENDOMETRIUM (PAPANICOLAOU STAIN)

Nucleus	AdenoCa gr. III p*	AdenoCa gr. II p*	AdenoCa gr. I p*	HA p*	HC p*	HS p*	Proliferation p*
Area	0.000	0.000	0.000	0.000	1.000	1.000	0.000
Outline	0.000	0.000	0.000	0.000	1.000	1.000	0.000
Minimum radius	0.000	0.000	0.000	0.000	1.000	1.000	0.000
Maximum radius	0.000	0.000	0.000	0.000	1.000	1.000	0.000
Convex area	0.000	0.000	0.000	0.000	1.000	1.000	0.000
Length	0.000	0.000	0.000	0.000	1.000	1.000	0.000
Breadth	0.000	0.000	0.000	0.000	1.000	1.000	0.000

AdenoCa gr. – adenocarcinoma grade; HA – hyperplasia endometrii atypica; HC – hyperplasia endometrii complex; HS – hyperplasia endometrii simplex; \*probability (statistically significant,  $p < 0.05$ ; statistically nonsignificant,  $p > 0.05$ )

Statistical data analysis was done on a PC by use of the Statistica Ver. 6 statistical package<sup>15</sup>. Data were analyzed by the methods of descriptive statistics (arithmetic mean, standard deviation, proportions) and by nonparametric tests (analysis of variance, Kruskal-Wallis test, Mann-Whitney U test), at the level of statistical significance of  $p < 0.05$ .

## Results

### *Cytologic aspirate endometrial samples stained by Papanicolaou method*

In aspiration cytology specimens of the endometrium stained by Papanicolaou method, the analysis of variance (ANOVA) yielded statistically significant differences ( $p < 0.05$ ) in all the nuclear parameters measured among benign, hyperplastic and malignant endometrium (Table 1). The mean nucleus area increased with the severity of endometrial lesion (Table 1), being minimal in simple hyperplasia ( $57.23 \pm 15.57 \mu\text{m}^2$ ), gradually increasing in complex ( $57.84 \pm 16.21 \mu\text{m}^2$ ) and atypical ( $73.26 \pm 21.72 \mu\text{m}^2$ ) hyperplasia, to reach maximum in poorly differenti-

ated adenocarcinoma ( $89.66 \pm 43.21 \mu\text{m}^2$ ). The mean nucleus area was smaller in well differentiated adenocarcinoma ( $66.06 \pm 19.85 \mu\text{m}^2$ ) than in atypical hyperplasia.

The mean values of nucleus perimeter, minimum and maximum nucleus radius, and nucleus convexity also showed a rising tendency with the increasing severity of endometrial lesion (Table 1). It should be noted that all values were lower in well differentiated adenocarcinoma as compared with atypical hyperplasia (Table 1).

Comparison of the two groups (Kruskal-Wallis test) according to nucleus area, convexity and breadth produced no statistically significant difference ( $p > 0.05$ ) between moderately differentiated adenocarcinoma and atypical hyperplasia, or between simple and complex hyperplasia of the endometrium. The parameters of nucleus perimeter, maximum radius and length showed no statistically significant difference ( $p > 0.05$ ) between simple and complex hyperplasia.

On comparison of the two groups, the parameter of minimal radius yielded no statistically significant differentiation between simple and complex hyperplasia, atypical hyperplasia and moderately differentiated adenocar-

cinoma, or between well and moderately differentiated adenocarcinoma ( $p > 0.05$ ). The parameter of FF factor differentiated proliferative endometrium from particular types of hyperplastic and malignant endometrium ( $p < 0.05$ ). There was no statistically significant difference between hyperplasia without atypia, well differentiated adenocarcinoma and atypical hyperplasia, moderately and poorly differentiated adenocarcinoma, or between complex hyperplasia and moderately differentiated adenocarcinoma of the endometrium ( $p > 0.05$ ).

The factor of nucleus elongation was highest in proliferative endometrium and simple hyperplasia, however, difference between these two groups did not reach statistical significance ( $p > 0.05$ ); however, statistically significant difference was found between atypical hyperplasia and various stages of adenocarcinoma ( $p < 0.05$ ).

Study results indicated the variables of nucleus area, perimeter, minimum and maximum radius, convex area, length and breadth to differentiate hyperplasias without atypia (simplex and complex) from atypical hyperplasia, adenocarcinoma and proliferative endometrium ( $p < 0.05$ , Table 2).

*Cytologic aspirate endometrial samples stained by MGG method*

Similar to the specimens stained by Papanicolaou method, the analysis of variance (ANOVA) yielded statistically significant differences ( $p < 0.05$ ) in all nucleus parameters among proliferative, hyperplastic and malignant endometrium in cytologic aspirate endometrial samples stained by MGG (Table 3).

The mean nuclear area was minimal in simple hyperplasia ( $89.89 \pm 38.36 \mu\text{m}^2$ ) and increased gradually through complex ( $101.68 \pm 46.28 \mu\text{m}^2$ ) and atypical ( $113.31 \pm 41.75 \mu\text{m}^2$ ) hyperplasia to endometrial adenocarcinoma (well differentiated  $136.98 \pm 56.47 \mu\text{m}^2$ ; moderately differentiated  $150.66 \pm 55.32 \mu\text{m}^2$ ; and poorly differentiated  $168.83 \pm 101.43 \mu\text{m}^2$ ). The mean nuclear area was somewhat greater in proliferative endometrium as compared with simple hy-

perplasia ( $95.28 \pm 35.51 \mu\text{m}^2$  vs.  $89.89 \pm 38.36 \mu\text{m}^2$ ) (Table 3).

The mean nuclear perimeter, minimum and maximum radius, convex area, and length and breadth showed a similar increasing tendency as the mean nuclear area, from hyperplasia with and without atypia to adenocarcinoma of various degrees of differentiation. Nuclear regularity (FF) showed highest values in well differentiated endometrial adenocarcinoma ( $0.80 \pm 0.08$ ), whereas greatest degree of nuclear elongation was recorded in simple hyperplasia ( $1.55 \pm 0.42$ , Table 1).

Between-group comparison (Kruskal-Wallis test) according to nuclear area and convexity, minimal radius and breadth yielded statistically significant differences ( $p < 0.05$ ), except for moderately and poorly differentiated adenocarcinoma, complex hyperplasia and proliferation ( $p > 0.05$ ). Statistically significant differences ( $p < 0.05$ ) were also found in nuclear perimeter and maximum nuclear radius, with the exception of moderately differentiated vs. poorly differentiated adenocarcinoma and simple hyperplasia vs. proliferation ( $p > 0.05$ ).

Between-group comparison according to FF showed statistically significant differences ( $p < 0.05$ ) between proliferative and hyperplastic endometrium vs. malignant endometrium, but not between atypical hyperplasia and poorly differentiated endometrial adenocarcinoma ( $p > 0.05$ ).

According to the factor of nuclear length and breadth, proliferative and hyperplastic endometrium without atypia differed statistically significantly ( $p < 0.05$ ) from atypical hyperplastic and malignant endometrium. The nuclei showed a higher degree of elongation in proliferative endometrium and hyperplasia simplex and complex than in endometrial lesions with pronounced nuclear atypia.

Study results indicated the variables of nuclear area, convex area, perimeter, minimal and maximal radius, length and breadth to differentiate hyperplasias without atypia (simplex and complex) and proliferation from atypical hyperplasia and adenocarcinoma ( $p < 0.05$ ). The nu-

**TABLE 3**  
NUCLEUS PARAMETERS ( $\bar{X} \pm \text{SD}$ ) IN CYTOLOGIC ASPIRATE ENDOMETRIAL SAMPLES (MGG STAIN)

Cytologic sample	Area ( $\mu\text{m}^2$ )	Outline ( $\mu\text{m}$ )	Min. radius ( $\mu\text{m}$ )	Max. radius ( $\mu\text{m}$ )	Convex area ( $\mu\text{m}^2$ )	Length ( $\mu\text{m}$ )	Breadth ( $\mu\text{m}$ )	Form factor*	L/B**
AdenoCa gr. III	168.83±101.43	50.70±13.87	5.54±1.83	8.75±2.39	173.14±103.19	16.80±4.59	12.51±3.79	0.77±0.10	1.39±0.33
AdenoCa gr. II	150.66±55.32	48.07±8.68	5.27±1.33	8.56±1.70	154.11±55.95	16.41±3.27	11.87±2.62	0.79±0.08	1.42±0.33
AdenoCa gr. I	136.98±56.47	45.59±9.05	5.00±1.36	8.15±1.70	139.92±57.01	15.63±3.29	11.25±2.70	0.80±0.08	1.43±0.33
HA	113.31±41.75	42.21±7.46	4.46±1.14	7.56±1.50	116.41±42.39	14.47±2.84	10.22±2.26	0.78±0.08	1.46±0.37
HC	101.68±46.28	40.05±8.77	4.08±1.24	7.28±1.69	104.79±47.06	13.90±3.24	9.46±2.48	0.76±0.09	1.52±0.41
HS	89.89±38.36	37.98±7.55	3.82±1.10	6.91±1.54	92.64±38.91	13.21±2.93	8.87±2.20	0.76±0.10	1.55±0.42
Proliferation	95.28±35.51	38.88±7.07	4.00±1.03	7.07±1.44	98.00±36.01	13.50±2.77	9.25±2.05	0.77±0.09	1.51±0.37
P***	0.000	0.000	0.000	0.000	0.000	0.000	0.000	0.000	0.000

SD – standard deviation; min. – minimum; max. – maximum; \*nuclear regularity ( $4\pi \text{ area}/r^2$ ), \*\*nuclear elongation (length/breadth); AdenoCa gr. – adenocarcinoma grade; HA – hyperplasia endometrii atypica; HC – hyperplasia endometrii complex; HS – hyperplasia endometrii simplex; \*\*\*probability (ANOVA by ranks)

clei showed a higher degree of regularity (mean value 0.77–0.80) in various grades of endometrial adenocarcinoma as compared with proliferative and hyperplastic endometrium (mean value 0.77–0.78), the difference being statistically significant ( $p < 0.05$ , Table 4).

#### *Cytologic aspiration endometrial samples stained by Papanicolaou and MGG methods*

Morphometric analysis of nuclear parameters (area, convex area, perimeter, minimum and maximum radius, length and breadth) according to the staining method employed produced considerably higher values in the air-dried and MGG stained samples (Tables 1 and 3), the difference being statistically significant ( $p < 0.05$ ) for all the study parameters in proliferative, hyperplastic and malignant endometrium. Exceptions were recorded in the values of FF and L/B factors, where differences did not reach statistical significance ( $p > 0.05$ ) in endometrial hyperplasia simplex and complex. Non-significant differences ( $p > 0.05$ ) between the two staining methods were also found for FF factor in well differentiated adenocarci-

noma, and for L/B factor in atypical hyperplasia (Table 5).

## Discussion

Numerous studies have used morphometry based on the analysis of objective parameters, emphasizing its diagnostic and prognostic value. Morphometric measurement of nuclear area, and determination of the nucleus/cytoplasm ratio, area of cell deposits, nuclear FF and L/B factors, and nucleolar count and area are most frequently reported in the literature<sup>5–14,16–18</sup>.

Proliferation, hyperplasia and carcinoma of the endometrium can be morphometrically differentiated in cytologic samples according to the mean area of endometrial cell area<sup>5–8</sup>. Skaarland<sup>5</sup> performed morphometric nuclear measurement on endometrial cytologic samples stained by Papanicolaou method, reporting on 20 well preserved nuclei *per case*. The cut-off nuclear area to differentiate malignant from normal endometrial cells was  $45 \mu\text{m}^2$  that yielded 17% of false-negative and 25% of false-positives.

**TABLE 4**  
STATISTICALLY SIGNIFICANT QUANTITATIVE IMAGE VARIABLES (KRUSKAL-WALLIS TEST) IN PROLIFERATIVE AND HYPERPLASTIC ENDOMETRIUM WITHOUT ATYPIA *VERSUS* ATYPICAL HYPERPLASTIC AND MALIGNANT ENDOMETRIUM (MGG STAIN)

Nucleus	AdenoCa gr. III p*	AdenoCa gr. II p*	AdenoCa gr. I p*	HA p*	HC p*	HS p*	Proliferation p*
Area	0.000	0.000	0.000	0.000	0.3255	0.000	0.3255
Outline	0.000	0.000	0.000	0.000	0.000	0.1205	0.1205
Minimum radius	0.000	0.000	0.000	0.000	1.000	0.000	1.0000
Maximum radius	0.000	0.000	0.000	0.000	0.000	0.4210	0.4210
Convex area	0.000	0.000	0.000	0.000	0.1788	0.000	0.1788
Length	0.000	0.000	0.000	0.000	0.000	0.5991	0.5991
Breadth	0.000	0.000	0.000	0.000	1.000	0.000	1.0000
L/B**	0.000	0.000	0.000	0.000	1.000	1.000	1.0000

AdenoCa gr. – adenocarcinoma grade; HA – hyperplasia endometrii atypica; HC – hyperplasia endometrii complex; HS – hyperplasia endometrii simplex; \*probability (statistically significant,  $p < 0.05$ ; statistically nonsignificant,  $p > 0.05$ ); \*\*nuclear elongation (length/breadth)

**TABLE 5**  
EFFECT OF FIXATION AND STAINING ON NUCLEAR PARAMETERS IN CYTOLOGIC ASPIRATE ENDOMETRIAL SAMPLES (MANN-WHITNEY U TEST)

Sample	Area p*	Outline p*	Min. radius p*	Max. radius p*	Convex area p*	Length p*	Breadth p*	Form factor** p*	L/B*** p*
AdenoCa gr. III	0.000	0.000	0.000	0.000	0.000	0.000	0.000	0.000	0.000
AdenoCa gr. II	0.000	0.000	0.000	0.000	0.000	0.000	0.000	0.000	0.000
AdenoCa gr. I	0.000	0.000	0.000	0.000	0.000	0.000	0.000	0.3421	0.0044
HA	0.000	0.000	0.000	0.000	0.000	0.000	0.000	0.000	0.2788
HC	0.000	0.000	0.000	0.000	0.000	0.000	0.000	0.0581	0.8558
HS	0.000	0.000	0.000	0.000	0.000	0.000	0.000	0.1211	0.2208
Proliferation	0.000	0.000	0.000	0.000	0.000	0.000	0.000	0.000	0.0059

min – minimum; max – maximum; \*probability (statistically significant,  $p < 0.05$ ; statistically nonsignificant,  $p > 0.05$ ); \*\*nuclear regularity ( $4\pi \text{ area}/r^2$ ); \*\*\*nuclear elongation (length/breadth); AdenoCa gr. – adenocarcinoma grade; HA – hyperplasia endometrii atypica; HC – hyperplasia endometrii complex; HS – hyperplasia endometrii simplex

tive results. Hence, the author concludes that nuclear area alone is inadequate as a screening method. In another study, Skaarland<sup>6</sup> compared cystic and adenomatoid hyperplasia with benign and malignant endometrium. The mean nuclear area was significantly lower in cystic hyperplasia than in adenomatoid hyperplasia. Although the two types of hyperplasia differed from normal endometrium, there was no difference from malignant lesions.

Fu et al.<sup>7</sup> also analyzed endometrial samples stained by Papanicolaou method and found both nuclear area and cell area to increase in proliferative, hyperplastic and malignant endometrial epithelium, which is consistent with the cytomorphological features described<sup>1–4</sup>. In addition, Fu et al.<sup>7</sup> point to the mean cell area as the most important parameter on differentiating particular endometrial conditions. The mean nuclear area values were lower in the studies by Fu et al.<sup>7</sup> (proliferation 36.63  $\mu\text{m}^2$ , hyperplasia 49.93  $\mu\text{m}^2$ , and carcinoma 62.09  $\mu\text{m}^2$ ) and by Nunobiki et al.<sup>8</sup> (proliferation 39.8  $\mu\text{m}^2$ , hyperplasia simplex 42.1  $\mu\text{m}^2$ , hyperplasia simplex atypica 43.2  $\mu\text{m}^2$ , hyperplasia complex 45.8  $\mu\text{m}^2$ , hyperplasia complex atypica 46.0  $\mu\text{m}^2$ , and adenocarcinoma gr. I 49.0  $\mu\text{m}^2$ ) than those reported by Vrdoĭjak-Mozetić<sup>16</sup> (proliferation 58.69  $\mu\text{m}^2$ , hyperplasia simplex 58.30  $\mu\text{m}^2$ , hyperplasia complex 61.26  $\mu\text{m}^2$ , hyperplasia complex atypica 59.07  $\mu\text{m}^2$ , adenocarcinoma gr. I 78.66  $\mu\text{m}^2$ , gr. II 71.21  $\mu\text{m}^2$ , and gr. III 77.55  $\mu\text{m}^2$ ). In our study, the mean endometrial cell nuclear area also increased with lesion severity in endometrial samples stained by Papanicolaou method, being lowest in proliferation (51.18  $\mu\text{m}^2$ ), then rising gradually from hyperplasia simplex (57.23  $\mu\text{m}^2$ ) through hyperplasia complex (57.84  $\mu\text{m}^2$ ) and atypical hyperplasia (73.26  $\mu\text{m}^2$ ) to reach highest value in poorly differentiated adenocarcinoma (89.66  $\mu\text{m}^2$ ). While Vrdoĭjak-Mozetić<sup>16</sup> reports on the highest mean nuclear area value in well differentiated adenocarcinoma (78.67  $\mu\text{m}^2$ ), in our study the respective value was lower than that recorded in atypical hyperplasia (66.06  $\mu\text{m}^2$  vs. 73.26  $\mu\text{m}^2$ ). This discrepancy could be attributed to the selection of nuclei obtained and stained by different methods.

In our study, the parameters of maximum nuclear length and breadth showed a statistically significant difference between normal proliferative endometrium and hyperplasia simplex and complex, atypical hyperplasia and all types of endometrial carcinoma, which is consistent with literature reports<sup>8</sup>.

In the study by Vrdoĭjak-Mozetić<sup>16</sup>, atypical hyperplasia was associated with the highest, statistically significant grade of nuclear irregularity and elongation as compared with hyperplasias without atypia and well differentiated carcinoma, where the problem of cytologic differential diagnosis was encountered. In our study, the nuclei were found to be most spherical and regular in atypical

hyperplasia, in contrast to hyperplasias without atypia and proliferation where the nuclei were less spherical but more elongated in shape. Comparable findings have also been reported by Fu et al.<sup>7</sup>, however, they did not analyze atypical hyperplasia as a separate entity. Skaarland<sup>6</sup> notes that nuclear area and shape should not be used as a screening method for endometrial malignancy, and other criteria such as tissue fragment architecture and quality of sample background should be considered instead<sup>19</sup>.

In MGG stained aspiration cytology specimens of the endometrium, the unit values of the study parameters (nuclear area and perimeter, convex area, minimum and maximum radius, length and breadth) by far exceeded the values measured in the samples stained by Papanicolaou method in our study (statistically significant at the level of  $p < 0.05$ ) and those reported in the literature<sup>5–8</sup>. This variation in the measured variables is primarily ascribed to different fixation rather than staining methods employed<sup>20</sup>. Namely, air drying results in flattened nuclei and cells, which remain spherical upon wet fixation. However, the non-unit values, i.e. nuclear shape (regularity and elongation), did not differ in hyperplasias without atypia, well differentiated adenocarcinoma (regularity) and atypical hyperplasia (elongation) according to the staining method used. To the best of our knowledge, apart from our report<sup>21</sup>, digital morphometric analysis has not been employed on MGG stained cytologic aspirate endometrial samples.

Our results obtained by digital morphometric analysis suggest that hyperplastic endometrium without atypia (Papanicolaou stain), or a group including proliferation and hyperplasia without atypia (MGG stain) could be distinguished from malignant and atypical hyperplastic endometrium by the parameters of nuclear area, convex area, perimeter, minimum and maximum radius, length and breadth (Papanicolaou and MGG stain), or nuclear elongation (MGG stain).

Like other authors<sup>5–9,16–18</sup>, we also observed the values of some morphometric parameters to overlap between particular endometrial categories, thus a combination of several qualitative<sup>2–4</sup> and quantitative<sup>7,8,16,21</sup> parameters, including clinical ones<sup>9,22–24</sup> should be used for their reliable differentiation.

## Conclusion

The group of proliferative and hyperplastic endometrium without atypia can be differentiated from the group of atypical hyperplasia and carcinoma of endometrium using a combination of various morphometric features of endometrial cell nuclei along with cytomorphological analysis of cytologic aspirate endometrial samples stained by standard methods.

## REFERENCES

1. REAGAN JW, NG ABP, The cells of uterine adenocarcinoma. In: WIED GL (Ed) Monographs in clinical cytology (S Karger, Basel, 1973).
2. KOSS LG, Proliferative disorders and carcinoma of the endometrium. In: KOSS LG (Ed), MELAMED, MR, (co-Ed): Koss' diagnostic cytology and its histopathologic bases (Lippincott Williams & Wilkins, Philadelphia, 2006).
3. NG ABP, Endometrial hyperplasia and carcinoma and extrauterine cancer. In: BIBBO M (Ed) Comprehensive cytopathology (WB Saunders, Philadelphia, 1997).
4. JIMENÉZ-AYALA, M, JIMENÉZ-AYALA PORTILLO B, IGLESIAS GOY E, RIOS VALLEJO M, Endometrial adenocarcinoma: prevention and early diagnosis. In: ORELL SR (Ed) Monographs in clinical cytology (S Karger, Basel, 2008).
5. SKAARLAND E, J Clin Pathol, 38 (1985) 496.
6. SKAARLAND E, J Clin Pathol, 38 (1985) 501.
7. FU YS, FERENCZY A, HUANG I, GELFAND MM, *Analyt Quant Cytol Histol*, 10 (1988) 139.
8. NUNOBIKI O, SATO M, TANIGUCHI E, NAKAMURA Y, MORI I, KAKUDO K, *Analyt Quant Cytol Histol*, 23 (2001) 201.
9. BAAK JPA, WISSE-BREKELMANS ECM, LANGLEY FA, TALERMAN A, DELEMARRE JFM, *J Clin Pathol*, 39 (1986) 1340.
10. BAAK JPA, *Analyt Quant Cytol Histol*, 9 (1987) 89.
11. VAN DIEST PJ, BAAK JPA, Morphometry. In: BIBBO M, (Ed) Comprehensive cytopathology (WB Saunders, Philadelphia, 1997).
12. COLLAN Y, TORKKELI T, PESONEN E, JANTUNEN E, KOSMA VM, *Analyt Quant Cytol Histol*, 9 (1987) 79.
13. OBERHOLZER M, CHRISTEN H, ETTLIN R, BUSER M, OESTRECHER M, GSHWIND R, *Analyt Quant Cytol Histol*, 13 (1991) 316.
14. BIBBO M, BARTELS PH, CHRISTEN R, XIAO J, WIED GL, Cell image analysis. In: BIBBO M, (Ed) Comprehensive cytopathology (WB Saunders, Philadelphia, 1997).
15. STATISTICA for Windows (computer programme), Version 6.0. (StatSoft Inc., Tulsa, OK, USA, 2001).
16. VRDOLJAK-MOZETIĆ D, Digitalna morfometrijska analiza argirofilnih nukleolarnih organizacijskih regija u citološkim uzorcima endometrija. MS Thesis. In Croat (University of Zagreb, Zagreb, 2003).
17. ŠTEMBERGER-PAPIĆ S, STANKOVIĆ T, VRDOLJAK-MOZETIĆ D, VERŠA-OSTOJIĆ D, KRAŠEVIĆ M, ŠTIFTER S, AUDY-JURKOVIĆ S, *Cytopathology*, 17 (2006) 382.
18. VERŠA-OSTOJIĆ D, STANKOVIĆ T, ŠTEMBERGER-PAPIĆ S, VRDOLJAK-MOZETIĆ D, MANESTAR M, KRAŠEVIĆ M, *Analyt Quant Cytol Histol*, 30 (2008) 160.
19. SKAARLAND E, *J Clin Pathol*, 39 (1986) 36.
20. BEYER-BOON ME, VAN DER VOORN-DEN HOLLANDER MJA, VAN DER ARENTZ PW, CORNELISSE CJ, SCHABERG A, FOX CH, *Acta Path Microbiol Scand Sect A*, 87 (1979) 63.
21. MAHOVLJIĆ V, AUDY-JURKOVIĆ S, OVANIN-RAKIĆ A, ŠKOPLJANAC-MAČINA L, ANTULOV J, BARIŠIĆ A, ILIĆ-FORKO J, ŠKRABLIN-KUČIĆ S, BOŽIKOV J, *Cytopathology*, 16 Suppl 2 (2005) 134.
22. SEILL-BEKAFIGO I, Primjena novih citoloških tehnika u dijagnozi i prognozi akutnih limfatičnih leukemija u odraslih. MS Thesis. In Croat (University of Zagreb, Zagreb, 2001).
23. KARDUM-SKELIN I, Morfometrijski i kinetički parametri kao dijagnostički i prognostički čimbenici leukemijskih oblika kroničnih limfoproliferativnih bolesti. PhD Thesis. In Croat (University of Zagreb, Zagreb, 2008).
24. KARDUM-SKELIN I, JAKSIC O, OSTOJIC KOLONIC S, VRHOVAC R, FABJANIĆ I, JELIC-PUSKARIC B, MILAS M, JAKSIC B, *Analyt Quant Cytol Histol*, 31 (2009) 313.

V. Mahovlić

Department of Gynecologic Cytology, University Department of Gynecology and Obstetrics, University Hospital Center Zagreb, Petrova 13, 10000 Zagreb, Croatia  
e-mail: vesna.mahovlic@zg.t-com.hr

## DIGITALNA MORFOMETRIJSKA ANALIZA CITOLOŠKIH UZORAKA ASPIRATA ENDOMETRIJA

## SAŽETAK

Za razliku od cervikalne citologije, nema jasno definiranih morfoloških citoloških kriterija u diferencijalnoj dijagnostici endometrija, te se traga za metodama koje bi omogućile precizniju evaluaciju endometralnog statusa. Cilj rada bio je procijeniti vrijednost morfometrijske analize jezgara u citološkim uzorcima aspirata materijata kod proliferativnog, hiperplastičnog i malignog endometrija putem digitalne analize slikovnog prikaza. Morfometrijska analiza primijenjena je na arhivskim citološkim uzorcima aspirata endometrija (najmanje 10 po skupini) obojenim metodom po Papanicolaou (n=77) i May-Grünwald-Giems (MGG; n=80) sa sljedećim patohistološkim dijagnozama: proliferativni endometrij, *hyperplasia simplex*, *hyperplasia complex*, *hyperplasia complex atypica* i *adenocarcinoma endometriodes endometrii* (I., II. i III. stadij). Interaktivna analiza slikovnog prikaza (površina, konveksnost površine, opseg, najveći i najmanji polumjer, duljina i širina jezgre te »faktor pravilnosti« i »faktor izduženosti« jezgre) izvršena je programom Sform (Vamstec, Zagreb) na najmanje 50 (bojenje po Papanicolaou) odnosno 100 (bojenje po MGG) dobro očuvanih jezgara epitelnih endometralnih stanica bez preklapanja, pri povećanju od  $\times 1000$ . Statistička analiza podataka učinjena je primjenom statističkog paketa Statistica ver. 6. Multivarijantnom analizom (ANOVA) razlikuje se maligni, hiperplastični i proliferativni endometrij po svim morfometrijskim varijablama u oba bojenja ( $p < 0,05$ ). Međutim, međusobnim testiranjem skupina (Kruskal-Wallisov test) hiperplazije bez atipija značajno se ne razlikuju jedino po faktoru pravilnosti i izduženosti ( $p > 0,05$ ) od atipične hiperplazije, adenokarcinoma i proliferativnog endometrija (bojenje po Papanicolaou), odnosno maligni i atipični hiperplastični endometrij (bojenje MGG) statistički se značajno razlikuje ( $p < 0,05$ ) s obzirom na sve mjerene parametre od proliferativnog i hiperplastičnog endometrija bez atipija, osim za faktor pravilnosti jezgre ( $p > 0,05$ ). S obzirom na citološko bojenje, morfometrijski parametri su znatno veći u aspiratima materijata obojenim MGG metodom, što je i statistički značajno ( $p < 0,05$ ), osim za faktor pravilnosti i faktor izduženosti jezgre ( $p > 0,05$ ) za skupinu hiperplazije simpleks i kompleks, odnosno dobro diferencirani adenokarcinom (faktor pravilnosti) i atipičnu hiperplaziju (faktor izduženosti) uspoređujući oba bojenja. Kombinacijom citomorfologije i ispitivanih morfometrijskih varijabli mogu se dobiti korisne informacije o citološkom statusu endometrija s naglaskom na mogućnost odvajanja skupine hiperplazija bez atipija od skupine adenokarcinoma i atipične hiperplazije.