

# Mollusca contagiosa. From paediatric dermatology to sexually transmitted infection

---

**Skerlev, Mihael; Husar, Karmela; Sirotković-Skerlev, Maja**

*Source / Izvornik:* **Hautarzt, 2009, 60, 472 - 476**

**Journal article, Accepted version**

**Rad u časopisu, Završna verzija rukopisa prihvaćena za objavljivanje (postprint)**

<https://doi.org/10.1007/s00105-009-1772-7>

*Permanent link / Trajna poveznica:* <https://urn.nsk.hr/urn:nbn:hr:105:926441>

*Rights / Prava:* [In copyright](#) / [Zaštićeno autorskim pravom.](#)

*Download date / Datum preuzimanja:* **2024-05-12**



*Repository / Repozitorij:*

[Dr Med - University of Zagreb School of Medicine  
Digital Repository](#)





## **Središnja medicinska knjižnica**

**Skerlev M., Husar K., Sirotković-Skerlev M. (2009) *Mollusca contagiosa. From paediatric dermatology to sexually transmitted infection*. Hautarzt, 60 (6). pp. 472-6. ISSN 0017-8470**

<http://www.springer.com/journal/105/>

<http://www.springerlink.com/content/0017-8470/>

<http://dx.doi.org/10.1007/s00105-009-1772-7>

<http://medlib.mef.hr/883>

University of Zagreb Medical School Repository

<http://medlib.mef.hr/>

## ***MOLLUSCA CONTAGIOSA FROM PAEDIATRIC DERMATOLOGY TO SEXUALLY TRANSMITTED INFECTION***

***Mihael Skerlev, Karmela Husar, <sup>1</sup>Maja Sirotković-Skerlev***

*Authors' address: Mihael Skerlev, M.D., Ph.D; Karmela Husar, M.D., M.A.; University Department of Dermatology and Venereology, Zagreb University Hospital Centre and Medical School of Zagreb University, Šalata 4, 10000 Zagreb, Croatia.*

*<sup>1</sup>Maja Sirotković-Skerlev, M.D., Ph.D; Department of Pathophysiology, Medical School of Zagreb University, Kišpatićeva 12, 10000 Zagreb, Croatia.*

*Correspondence to: Prof. Mihael Skerlev, M.D., Ph.D, University Department of Dermatology and Venereology, Zagreb University Hospital Centre and Medical School of Zagreb University, Šalata 4, 10000 Zagreb, Croatia.*

*E-mail address: mskerlev@kbc-zagreb.hr*

### **ABSTRACT**

Mollusca contagiosa (MC) as a common cutaneous viral infection caused by *Molluscipox* virus (MCV) might affect both children and adults. Whereas mollusca contagiosa are rather frequent in the 1-5 years old children and can be localised almost anywhere on the body, their appearance in adults is mostly regarded as sexually transmitted infection (STI). MCV might be transmitted directly from person to person or, by autoinoculation. MC in adults characteristically involve the genital area. However, the extragenital appearance of MC in adults can be more typically noticed in patients with immunosuppressive conditions, especially in HIV/AIDS patients. The onset of MC in HIV-positive individuals can be, according to the current literature data,

regarded as a part of immune reconstitution inflammatory syndrome (IRIS). It is most probable that MC affect both sexes equally in children's age, whereas it seems that in adult age the incidence in males prevails. Thus, in STD clinics, slightly more than twice as many men as woman were diagnosed with MC. Therapy is still controversial and sometimes very frustrating, but may be, on the other hand, considerably beneficial in preventing transmission or autoinoculation. Unfortunately, there is no aetiological treatment of MC so far, and majority of treatment options are mechanical, causing sometimes a certain degree of discomfort, or are not enough "evidence-based". Special attention should be given to the extragenital site of involvement of MC in adults, and HIV serology testing should certainly be recommended in such patients. Both children and adults with MC should be educated to avoid skin contact and scratching with others to prevent transmission and autoinoculation. Besides, the adult patients with MC should be carefully screened for other STIs and counselled appropriately.

**Key words:** mollusca contagiosa, STIs, children, IRIS, treatment

**Background.** Mollusca contagiosa (MC) are defined as a common cutaneous viral infection caused by *Molluscipox* virus affecting both children and adults. MC are clinically characterized by small, waxy, dome-shaped umbilicated papules. [16] (Fig. 1) (Synonyms - epithelioma contagiosum or dimple warts. [16] Whereas mollusca contagiosa are rather frequent in the 1-5 years old children and can be localised almost anywhere on the body, their appearance in adults is mostly regarded as sexually transmitted infection (STI).

**Historical aspects.** The clinical features of MC have been most likely for the first time described by Bateman in 1817 [16] Intracytoplasmic inclusion bodies ("molluscum bodies")

have been described in 1841 by Henderson and Paterson. [16,22] In 1905, the viral nature of MC was revealed by Juliusberg as a successful “transmissibility by a filterable agent“ [22] followed with the description of the Lipschütz granules within the molluscum bodies in 1911. [22]

**Aetiological and Pathogenetic considerations.** *Molluscipox virus* [MCV] replicates in the cytoplasm of host epithelial cells, producing cytoplasmic inclusions, and may cause enlargement of infected cells. [29] Only humans are known to be affected except for one report each of molluscum contagiosum occurring in chimpanzees and a horse. [34] MCV might be transmitted directly from person to person or, which seems to be more frequent, by autoinoculation – i.e. by scratching or touching a lesion and transferring the virus from one site to another on the skin of the same individual. MC in adults is most typically a sexually transmitted infection (STI) , characteristically involving the genital area. [3, 19, 20] However, the extragenital appearance of MC in adults can be more typically noticed in patients with immunosuppressive conditions, especially in HIV/AIDS patients. [12] The onset of MC in HIV-positive individuals can be, according to the current literature data, regarded as a part of immune reconstitution inflammatory syndrome (IRIS) . [27] IRIS is a recently described entity in which severely immunosuppressed HIV patients, after being started on highly active antiretroviral treatment (HAART), develop inflammatory reactions to several pathogens. [9] With the progression of immunoreconstitution, the lesions healed spontaneously. Molluscum contagiosum lesions are common in IRIS but presumably underreported. For example, disseminated eruptive giant mollusca contagiosa in an adult psoriasis patient during Efalizumab therapy have been very recently reported. [38]

**Epidemiological aspects.** The incidence of MC and their clinical forms may somehow be different in Europe as compared with other parts of the World. [14,16,17] Among children 1-5 years of age, prevalence was approximately 25% in Papua New Guinea and Fiji. [23] It is most probable that MC affect both sexes equally in children's age, whereas it seems that in adult age the incidence in males prevails. Thus, in STD clinics in England and Wales, slightly more than twice as many men as woman were diagnosed with MC. [20] However, we believe that certain number of cases of MC in both children and adults remain underreported.

**Clinical variations.** Typically, MC have a central umbilication at their top from which a plug of cheesy material can be expressed. As previously mentioned, in adults, mollusca contagiosa are most often a sexually transmitted infections (STI), thus, their site of involvement are usually genitals, lower abdomen, inner upper thighs and buttocks. (Fig. 2) Exuberant forms of MC, as well as their extragenital localisation in adults (eyelids!) can be much more often observed in the immunocompromised patients, especially in HIV/AIDS (up to the 20% of patients) comparing to the HIV-negative patients. [35] (Fig. 3) In children, the papules may occur anywhere on the body, but the face, eyelids, neck, axillae, cubital creases and thighs are sites of predilection. MC lesions are found often as solitary (rather than confluent) lesions of varying size, and their number may be even up to several hundred. MC can become inflamed in immunologic resistance or by contamination with a pyogenic organism [14]. Lesions on the eyelid margin can produce unilateral conjunctivitis; rarely, lesions may appear on the cornea. [21] Lesions on patients with AIDS, in children with leukemia and other immunodeficiencies, or in children undergoing cytostatic or glucocorticoid therapy can be large and numerous, particularly on the face. [24, 30] In patients with chronic dermatitis or even atopic dermatitis, especially in areas of skin treated with steroids (local immune deficiency), hundreds of MCs

may develop (eczema molluscatum) . [31] Unlike ordinary warts, the palms and soles are not involved. [21, 30] Like all forms of warts, eventually the MC lesions disappear spontaneously in 6–9 months, but they may also last much longer. Complications include secondary impetiginization and orbital spread if the face is involved. Infection can become widespread and prolonged in children with compromised cutaneous barriers.

**Considerations on Diagnosis and Differential Diagnosis.** Clinical findings are the most important for obtaining the diagnosis, and cytologic tests [17] might be sometimes required for the confirmation. To diagnose molluscum bodies, eosinophilic viral inclusion bodies in the lower epidermis [29] , punch skin biopsy is required. Abnormal keratinization process in lesional epidermis of MC can be proved by specific antibodies to filaggrin, loricrin, Ted-H-1 antigen, involucrin, cystatin A, and CD95 ligand. [26, 34] Cell-mediated immunity seems to be important in host defence. The virus of MC has not been grown in tissue culture. [34] Histological examination after haematoxylin and eosin staining confirmed that the proliferative lesion was due to MC, and demonstration of the presence of molluscum bodies in a section can be revealed by in situ hybridization. Sequence analysis in the polymerase chain reaction is more sensitive than in situ hybridization and in dual infection with both MCV and *Human papillomavirus* (HPV) , the immunosuppressive genes of *Molluscipox* virus could enhance survival of the oncogenic types of HPV. [26]

In **differential diagnosis**, papular warts in the genital region (a form of condylomata acuminata, i.e. HPV-associated lesions) , ectopic sebaceous glands, trichoepithelioma, basal-cell carcinoma, syringoma, hydrocystoma, keratoacanthoma, warty dyskeratoma, common warts, varicella, milia, and cutaneous cryptococcus presenting as molluscum-like eruptions should be considered.

[15] We also report on our clinical observation of the Langerhans cell histiocytosis mimicking the molluscum-like lesion on the eyelid of the 4-year-old boy. [13]

**Treatment controversies.** MC are generally self-limited and heal after several months or years though therapy may be beneficial in preventing transmission or autoinoculation. Unfortunately, there is no aetiological treatment of MC so far, and majority of treatment options are mechanical, or are not enough “evidence-based”. *Topical Applications.* Cryotherapy with liquid nitrogen (6–9 seconds) works best if the patient does not mind the certain discomfort and pain. [37] Curettage only, or followed by either electrodessication or application of caustic agent has been shown to be an effective treatment in children as well as adults. The papules can also be destroyed by expressing the plug with a needle, or a comedo extractor, (EMLA® 5% topical anaesthetic cream can be applied under occlusion 1–2 hours before the procedure) . Such anaesthesia before the curettage (or punch biopsy) provides effective local analgesia without serious application- site reactions in both children with atopic dermatitis and/or adults experiencing the involvement of the sensitive skin of the genital region. [5] Cantharidin (single application every 3–4 weeks needs to be repeated, and the area should be washed thoroughly about 30-60 minutes after every application) , is sometimes painful, and carries the risk of serious skin erosion. [28,39] Topical imiquimod 5% cream three times a week represents comparatively new and „elegant“ option, however, sometimes, the irritating side effects might be significant. [2,6] Besides, this is a comparatively expansive treatment option providing the number of MC lesion, thus, it seems that imiquimod might be more appropriate for the treatment of the HPV rather than MC lesions. Tretinoin cream 0.05% or gel 0.025% applied once or twice daily to individual lesions or cidofovir 0.1% gel [36] might sometimes be beneficial. Salicylic acid applied each day [with or without tape occlusion] , tincture of iodine,



silver nitrate 40% paste [25] or phenol have also been described as treatment options curing MC without scars. Trichloroacetic acid 70%, 5-fluorouracil (5 FU), bleomycin-intralesional injection or scarification are sometimes too painful and might cause severe irritation. Some “organic” and “natural” preparations [18] have been also mentioned as „natural healing of mollusca“, however, more evidence based studies are required. Electrosurgery, laser therapy with ultrapulsed dye or CO2 laser, and excision are some of the treatment options, as well. [1]

*Systemic Agents.* Cimetidine stimulates the immune system to reject the wart (an “off-label” indication), thus oral cimetidine, 40 mg/kg/day might be prescribed in two divided doses [37]

Treatment of HIV/AIDS patients with disseminated MC with the use of HAART, intralesional interferon-alfa, and topical injection of streptococcal antigen OK-43228 is very beneficial. [10]

Intralesional interferon-alfa (weekly for 4 weeks) for the treatment of recalcitrant MC in AIDS patients [11], 70% trichloroacetic acid and inosiplex [7] systemically enhance underlying defective immunologic mechanisms and might be, thus, very beneficial under the circumstances. [4, 8]

In general treatment is rather effective, though sometimes causing a certain degree of discomfort, especially in small children. Overall prognosis is excellent in immunocompetent patients.

**Preventive measures.** Both children and adults with MC should be educated to avoid skin contact and scratching with others to prevent transmission and autoinoculation (see Fig. 1!).

**Conclusions.** Unfortunately, there is no aetiological treatment of MC so far, and majority of treatment options are mechanical, causing sometimes a certain degree of discomfort, or are not enough “evidence-based”. Special attention should be given to the extragenital site of involvement of MC in adults, and HIV serology testing should certainly be recommended in

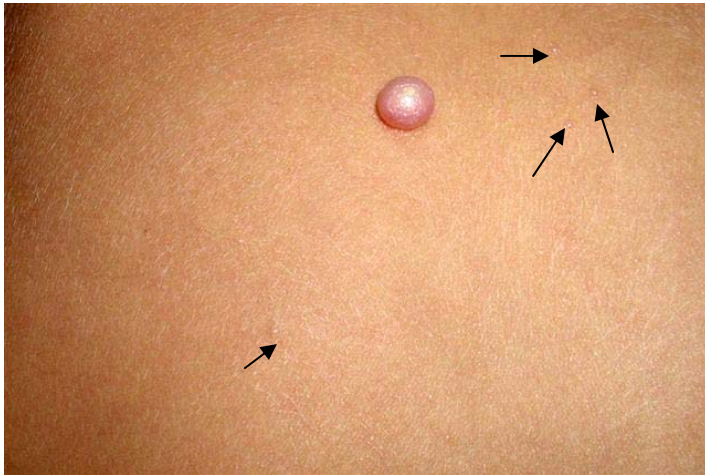
such patients. Both children and adults with MC should be educated to avoid skin contact and scratching with others to prevent transmission and autoinoculation. Besides, the adult patients with MC should be carefully screened for other STIs and counselled appropriately.

## References

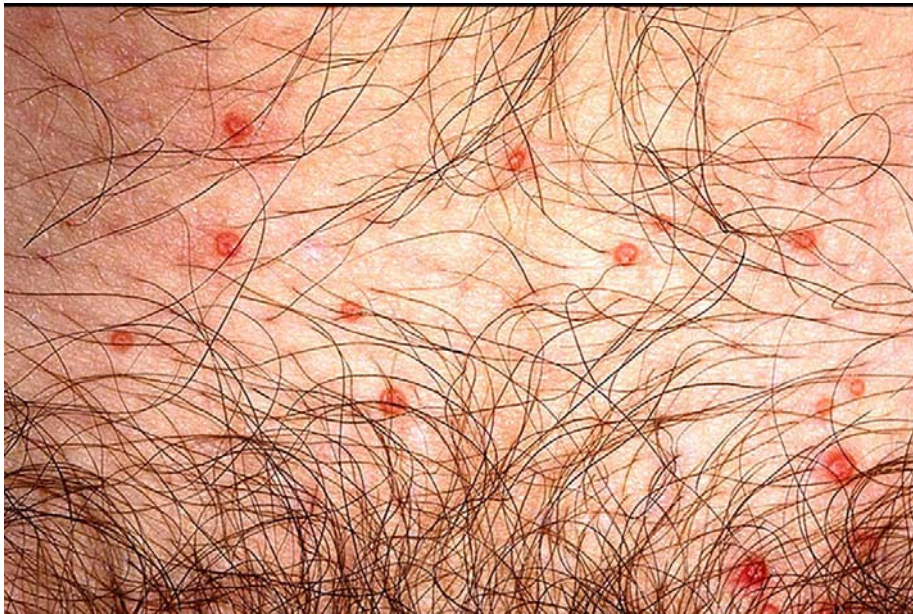1. Binder B, Weger W, Komericki P, Kopera D (2007) Treatment of molluscum contagiosum with a pulsed dye laser: Pilot study with 19 children. *Journal der Deutschen Dermatologischen Gesellschaft* 6 (2) : 121 – 125.
2. Buckley R, Smith K (1999) Topical imiquimod therapy for chronic giant molluscum contagiosum in a patient with advanced human immunodeficiency virus 1 disease. *Arch Dermatol* 135:1–6.
3. Choong KY, Roberts LJ (1999) Molluscum contagiosum, swimming and bathing: a clinical analysis. *Australas J Dermatol* 40:89–92.
4. Conant MA (2000) Immunomodulatory therapy in the management of viral infections in patients with HIV infection. *J Am Acad Dermatol* 43:S27–30.
5. DeWaard-van der Spek FB, Mulder PGH, Oranje A (1997) Prilocaine/ lidocaine patch as a local premedication for skin biopsy in children. *J Am Acad Dermatol* 37:418–21.
6. Edwards L (2000) Imiquimod in clinical practice *J Am Acad Dermatol* 43:12–7.
7. Gross G, Jogerst C, Schopf E (1986) Systemic treatment of mollusca contagiosa with inosiplex. *Acta Derm Venereol* 66:76–80.
8. Harms G, Blume-Peytavi U, Bunikowski R, et al. (1995) Mollusca contagiosa bei einem afrikanischen Kind mit Aids. *Hautarzt* 46:799–803.
9. Hirsch H, Kaufmann G, Sendi P, Battegay M (2004) Immune reconstitution in HIV-infected patients. *Clin Infect Dis* 38: 1159-66
10. Horneff G, Wahn V (2000) Mollusca contagiosa in HIV-infected children receiving optimal antiretroviral therapy. *Klin Pediatr* 212:83–4.
11. Hourihane J, Hodges E, Smith J et al. (1999) Interferon a treatment of molluscum contagiosum in immunodeficiency. *Arch Dis Child* 80:77–9.

12. Husak R, Garbe C, Orfanos CE (1997) Mollusca contagiosa bei HIV-Infection  
Klinische Manifestation, Beziehung zum Immunstatus und prognostische Wertigkeit bei  
39 Patienten. *Hautarzt* 48:103–9.
13. Husar K, Murat-Sušić S, Skerlev M, Dobrić I, Lakoš Jukić I (2006) Langerhans cell  
histiocytosis - report of two cases. 4<sup>th</sup> EADV Spring Symposium, Saariselkä, Finland,  
Feb. 09-12, 2006. Book of Abstracts: P-058.
14. Husar K, Skerlev M (2002) Molluscum contagiosum from infancy to maturity. *Clin  
Dermatol* 20 (2) :170-172.
15. Itin PH, Gilli L (1994) Molluscum contagiosum, mimicking sebaceous nevus of  
Jadassohn, ecthyma and giant condylomata acuminata in HIV-infected patients.  
*Dermatology* 189:396–8.
16. Ive FA, Wilkinson DS. Diseases of the umbilical, perianal and genital regions. In: Rook  
A, Wilkinson DS, Ebling GJG, Champion RH, Burton JL, eds. (1986) *Textbook of  
Dermatology*, 4th ed. Oxford-Edinburgh: Blackwell Scientific Publications: 2184.
17. Jain S, Das DK, Malhotra V, et al. (2000) Molluscum contagiosum: a case report with  
fine needle aspiration cytologic diagnosis and ultrastructural features. *Acta Cytol* 44: 63–  
6.
18. Kauffman CL, Yoon SW (2000) Molluscum contagiosum: medicine free online  
medical reference textbooks for doctors, medical professionals and consumers 270:1–6.
19. Koning S, Bruijnzeels MA, van Suijlekom-Smit LW, van der Wouden JC (1994)  
Molluscum contagiosum in Dutch general practice. *Br J Gen Pract* 44:417–9.
20. Lewis EJ, Lam M, Crutchfield CE (1997) An update on molluscum contagiosum. *Cutis*  
60:29–34.
21. Matoba A (1984) Ocular viral infections. *Pediatr Infect Dis* 3:358–68.
22. Nagingto J, Rook A, Highet AS. Virus and related infections. In: Rook A, Wilkinson DS,  
Ebling GJG, Champion RH, Burton JL, eds. (1986) *Textbook of Dermatology*, 4th ed.  
Oxford-Edinburgh: Blackwell Scientific Publications: 696-700.
23. Nakamura J, Arao Y, Yoshida M, Nii S (1992) Molecular epidemiological study of  
molluscum contagiosum virus in two urban areas of western Japan by the in-gel  
endonuclease digestion method. *Arch Virol* 125:339–45.
24. Nio MMS, Bergonese FN, Godoy AM (2001) Molluscum contagiosum in herpes  
zoster scars. *Int J Dermatol* 40: 521–4.
25. Niizeki K, Hashimoto K (1999) Treatment of molluscum contagiosum with silver  
nitrate paste. *Pediatr Dermatol* 16:395–7.
26. Payne D, Yen A, Tying S (1997) Coinfection of molluscum contagiosum with human  
papilloma-virus. *J Am Acad Dermatol* 36:641–4.

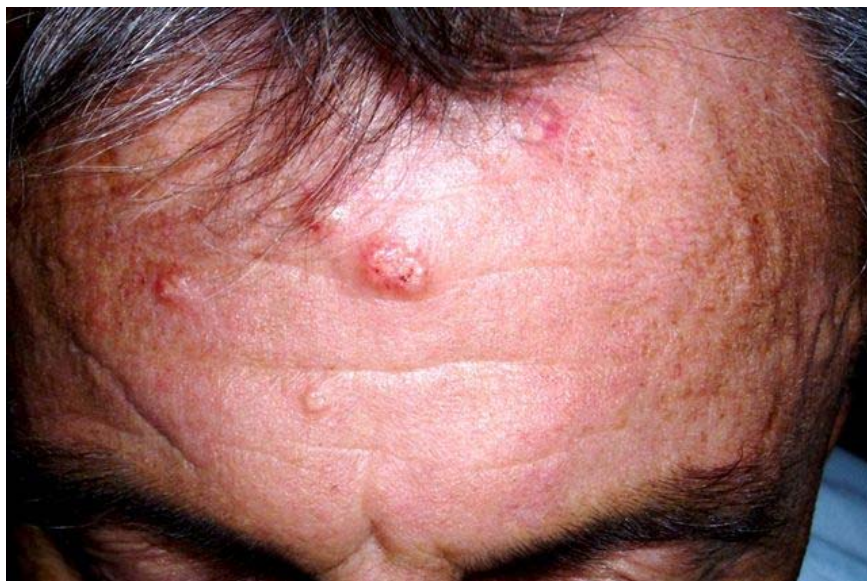27. Pereira B, Fernandes C, Nachiambo E et al. (2007) Exuberant molluscum contagiosum as a manifestation of the immune reconstitution inflammatory syndrome. *Dermatology Online Journal* 13 (2) : 6.
28. Ronnerfalt L, Fransson J, Wahlgren CF (1998) EMLA cream provides rapid pain relief for the curettage of molluscum contagiosum in children with atopic dermatitis without causing serious application-site reactions. *Pediatr Dermatol* 15:309–12.
29. Rook A, Wilkinson DS, Champion RH. The principles of diagnosis. In: Rook A, Wilkinson DS, Ebling FJG, Champion RH, Burton JL, eds. (1986) *Textbook of Dermatology*, 4<sup>th</sup> ed. Oxford-Edinburgh: Blackwell Scientific Publications: 79–81.
30. Rüsç R (1998) Augeninfektionen bei Aids-Patienten. *Exp Opin Invest Drugs* 7:437-449.
31. Siegfried EC (1997) Warts and molluscum contagiosum on children: an approach to therapy. *Dermatol Ther* 2:51–67.
32. Silverberg NB, Sidbury RS, Mancini AJ (2000) Childhood molluscum contagiosum: experience with cantharidin therapy in 300 patients. *J Am Acad Dermatol* 43:503- 507.
33. Simonart T, De Maertelaer V (2008) Curettage treatment for molluscum contagiosum: a follow-up survey study. *British Journal of Dermatology* 159 (5) :1144-1147.
34. Takahashi M, Izutani A, Tezuka T (1999) An immunohistochemical study of abnormal keratinocyte differentiation in molluscum contagiosum. *Br J Dermatol* 141:116–8.
35. Thompson CH, de Zwarf-Steffe RT, Donovan B (1992) Clinical and molecular aspects of molluscum contagiosum infection in HIV-1 positive patients. *Int J STD* 3:101–6.
36. Toro JR, Wood LV, Patel NK, Turner ML (2000) Topical cidofovir: a novel treatment for recalcitrant molluscum contagiosum in children infected with human immunodeficiency virus 1. *Arch Dermatol* 136:1–5.
37. Verbov J (1999) How to manage warts. *Arch Dis Child* 80: 97–9.
38. Weisenseel P, Kuznetsov AV, Flaig M, Prinz JC (2008) Disseminated Eruptive Giant Mollusca Contagiosa in an Adult Psoriasis Patient during Efalizumab Therapy. *Dermatology* 217:85-86.
39. Werfel S, Boeck K, Abeck D, Ring J (1998) Special characteristics of topical treatment in childhood. *Hautarzt* 49:170–5.



**Fig. 1. Molluscum contagiosum – typical dome-shaped papule on the healthy skin. Note the big (“mother”) molluscum with many smaller skin-coloured (“daughters”) mollusca on the surrounding skin (black arrows)!**



**Fig. 2. Mollusca contagiosa as STI in adults typically involving lower abdomen and pubic region.**



**Fig. 3. Solitary and confluent mollusca contagiosa on the forehead (extragenital localisation!) in HIV/AIDS patient.**