

Malignancy risk assessment in adenomatoid nodules and suspicious follicular lesions of the thyroid obtained by fine needle aspiration cytology

Dabelić, Nina; Mateša, Neven; Mateša-Anić, Dubravka; Kusić, Zvonko

Source / Izvornik: **Collegium Antropologicum, 2010, 34, 349 - 354**

Journal article, Published version

Rad u časopisu, Objavljena verzija rada (izdavačev PDF)

Permanent link / Trajna poveznica: <https://urn.nsk.hr/urn:nbn:hr:105:629922>

Rights / Prava: [In copyright](#)/[Zaštićeno autorskim pravom.](#)

Download date / Datum preuzimanja: **2024-12-10**



Repository / Repozitorij:

[Dr Med - University of Zagreb School of Medicine](#)
[Digital Repository](#)



Malignancy Risk Assessment in Adenomatoid Nodules and Suspicious Follicular Lesions of the Thyroid Obtained by Fine Needle Aspiration Cytology

Nina Dabelić¹, Neven Mateša¹, Dubravka Mateša-Anić² and Zvonko Kusić^{1,3}

¹ Department of Oncology and Nuclear Medicine, »Sestre milosrdnice« University Hospital, Zagreb, Croatia

² Department of Otorhinolaryngology, Special Hospital for Medical Rehabilitation »Thalassoterapia«, Crikvenica, Croatia

³ Zagreb University, School of Medicine, Zagreb, Croatia

ABSTRACT

Our aim was to assess malignancy risk in adenomatoid nodules and suspicious follicular lesions of the thyroid obtained by fine needle aspiration (FNA) cytology. Retrospective research was performed of 276 patients who underwent thyroid surgery after preoperative ultrasound-guided FNA diagnosis of either adenomatoid nodule, cellular follicular lesion, »suspicious for follicular neoplasm« or follicular neoplasm. Out of 276 patients, FNA reports showed 15 diagnoses (5%) of adenomatoid nodules, 73 (26%) cellular follicular lesions, 76 (28%) »suspicious for follicular neoplasm«, and 112 diagnoses (41%) of follicular neoplasm. FNA reports were compared with pathohistological findings. In FNA reports of adenomatoid nodule (N=15), there were seven (47%) pathohistological diagnoses (PHDs) of nodular goiter, and eight (53%) PHDs of follicular adenoma. In FNA reports of cellular follicular lesion (N=73), there were 2 (3%) PHDs of thyroiditis, 32 (44%) PHDs of nodular goiter, 38 (52%) PHDs of follicular adenoma, and one (1%) PHD of papillary carcinoma. In FNA reports of »suspicious for follicular neoplasm« (N=76), there was one (1%) PHD of thyroiditis, 24 (32%) PHDs of nodular goiter, 47 (62%) PHDs of follicular adenoma and four (5%) diagnoses of papillary carcinoma. In FNA reports of follicular neoplasm (N=112), there were 25 (22%) PHDs of nodular goiter, 72 (64%) PHDs of follicular adenoma, and 15 (14%) PHDs of thyroid carcinoma. We found significant difference ($p < 0.01$) between investigated FNA report groups according to malignancy risk. Stratification of cytologic diagnoses of follicular thyroid lesions into different subcategories with various probabilities of malignancy allows more accurate estimation of malignancy risk and individualized patient treatment, when deciding between immediate operation and close follow-ups with repeat FNA.

Key words: thyroid nodule, follicular, fine needle, aspiration cytology

Introduction

Fine-needle aspiration (FNA) biopsy has become the dominant method in the evaluation of thyroid nodules¹, because it is rapid, reliable, safe, minimally invasive and cost-effective. The results of FNA are used to assess the need for resection of thyroid nodules, eliminating those that do not require surgery, thus decreasing the number of diagnostic surgical procedures²⁻⁵. Nevertheless, there are certain limitations to the method, which results in indeterminate results for neoplasm in 5–29% of patients (patients)⁶. Such patients still need to be operated to fully evaluate their status on pathohistological diagnosis

(PHD), and are therefore submitted to potential preoperative morbidity, with additional costs to health-care system.

Management of patients with FNA-diagnosis of follicular lesions of the thyroid is the most controversial, because the diagnosis of follicular thyroid carcinoma can be made only histopathologically, by identification of capsular or vascular invasion, extrathyroidal tissue invasion, or nodal or distant metastasis. Cytological findings in aspirates from adenomatoid nodules, follicular ade-

nomas, well-differentiated follicular carcinomas, and follicular variant of papillary carcinomas or papillary carcinomas with prominent follicular component are often very similar and overlapping, with limited possibilities of accurate cytological diagnosis, causing discrepancies between FNAs and PHDs, and often resulting in indeterminate FNA diagnoses of follicular lesions of the thyroid^{7–12}.

Our aim was to assess risk of malignancy in adenomatoid nodules and suspicious follicular lesions of the thyroid obtained by fine needle aspiration cytology.

Patients and Methods

Patients

We undertook a retrospective research of 276 patients who underwent thyroid surgery at our hospital from March 1995 until July 2007 and had preoperative ultrasound guided FNA diagnosis of adenomatoid nodule, cellular follicular lesion, »suspicious for follicular neoplasm« or follicular neoplasm, respectively. There were 37 men and 239 women. The mean age of patients was 48.5 ± 14.1 years (median 51; range 13–79 years).

Methods

Routine percutaneous, ultrasonographically guided, FNA was performed by cytopathologist, using a 23-gauge needle attached to a 10-mL syringe. Aspirated material was smeared onto glass slides, air-fixed, stained by May-Grünwald-Giemsa method, and consecutively examined with light microscope. Cytomorphological criteria for each of the above mentioned FNA diagnostic categories for follicular lesions were strictly followed.

Cytomorphological criteria for adenomatoid nodule were at least one of these characteristics: many sheets of follicular cells with few colloid or enlarged follicular cells or many microfollicles (Figure 1). Differential diagnosis includes: adenomatoid nodule of nodular goiter and follicular adenoma. Cytomorphological criteria for cellular follicular lesion were at least one of these characteristics: few acinar structures with predominance of normal ap-

pearing sheets of follicular cells or slightly atypical nuclei (Figure 2). Differential diagnosis includes: adenomatoid nodule of nodular goiter, follicular adenoma and low possibility of well-differentiated carcinoma. Cellular follicular lesion is best described as »probably neoplastic«. A cytomorphological criterion for »suspicious for follicular neoplasm« was: many acinar structures with predominance over normal appearing sheets of follicular cells (Figure 3). Differential diagnosis includes: adenomatoid nodule of nodular goiter, follicular adenoma and well-differentiated carcinoma. Cytomorphological criteria for follicular neoplasm were at least one of these characteristics: acinar structures without presence of normal appearing sheets of follicular cells or acinar structures with moderately atypical nuclei (Figure 4). Differential diagnosis includes: follicular adenoma, well-differentiated carcinoma, and low possibility of adenomatoid nodule of nodular goiter. Fine-needle aspiration results were subsequently compared with final PHDs, which were used as »gold standard«. Statistical analysis was performed with Fisher's exact test. A p value of <0.05 was considered significant.

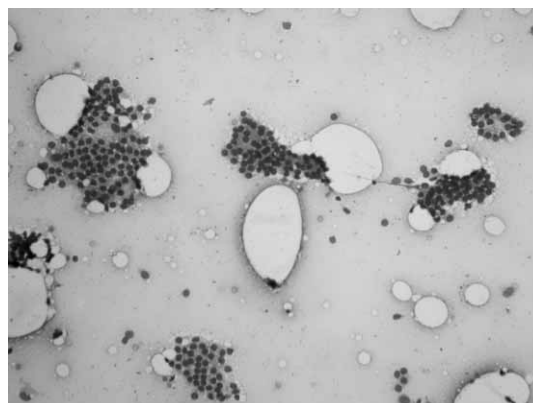


Fig. 2. Fine-needle biopsy smear of cellular follicular lesion – PHD nodular goiter (May-Grünwald-Giemsa stain, x 200).

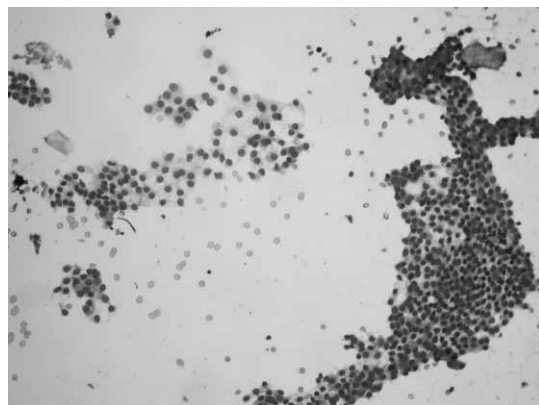


Fig. 1. Fine-needle biopsy smear of adenomatoid nodule – PHD nodular goiter (May-Grünwald-Giemsa stain, x 200).

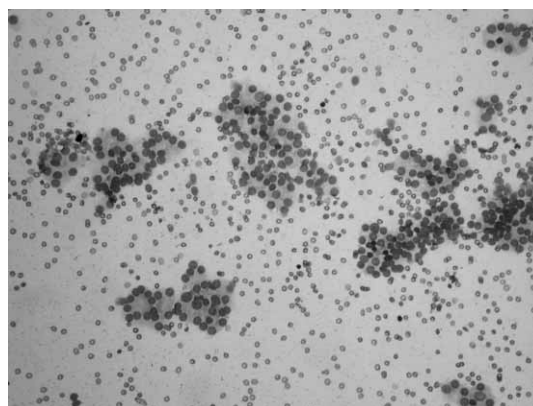


Fig. 3. Fine-needle biopsy smear of »suspicious for follicular neoplasm« – PHD follicular adenoma (May-Grünwald-Giemsa stain, x 200).

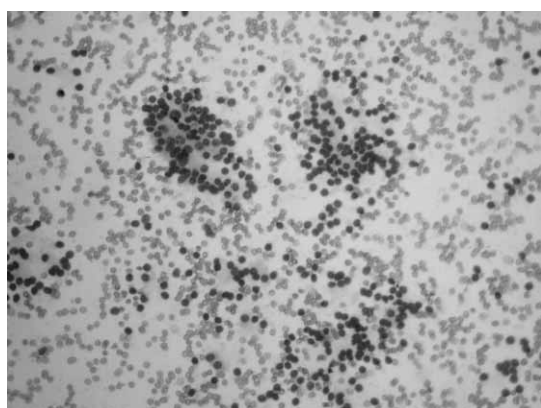


Fig. 4. Fine-needle biopsy smear of follicular neoplasm – PHD follicular adenoma (May-Grünwald-Giemsa stain, x200).

Results

Out of 276 patients examined, FNA reports showed 15 diagnoses (5%) of adenomatoid nodules, 73 diagnoses (26%) of cellular follicular lesions, 76 patients (28%) were cytologically diagnosed as »suspicious for follicular neoplasm«, and the remaining 112 patients (41%) were diagnosed as having follicular neoplasm on FNA smears. FNA reports were compared with pathohistological findings, and the following results were found (Table 1). In FNA reports of adenomatoid nodule (N=15), PHDs revealed 7 cases (47%) of nodular goiter, and 8 (53%) of follicular adenoma. In FNA reports of cellular follicular lesion (N=73), PHDs were in 2 cases (3%) consistent with thyroiditis, in 32 (44%) with nodular goiter, in 38 (52%) with follicular adenoma, and in one (1%) with papillary carcinoma. In FNA reports of »suspicious for follicular neoplasm« (N=75), according to the subsequent PHDs, there was one patient (1%) with thyroiditis, 24 (32%) with nodular goiter, 47 (62%) with follicular adenoma, and 4 (5%) with papillary carcinoma. In FNA reports of follicular neoplasm (N=112), there were 25 PHDs (22%) of nodular goiter, 72 (64%) of follicular adenoma, and 15 (14%) of thyroid carcinoma (14 pri-

mary, 1 metastatic renal cell carcinoma). We found significant difference (Fisher's exact test, $p < 0.01$) between investigated FNA report groups according to the risk of malignancy (Table 2).

Discussion and Conclusion

Follicular lesions have always been the sore point of thyroid FNA, because its inability to distinguish them reliably, due to the inherent limitation of the method, based on the overlapping cytological criteria of different types of follicular lesions, both benign and malignant¹³. Several decades ago, it was presumed that smears that are highly cellular with little or no colloid were characteristic of neoplasms, while aspirates from colloid nodules showed abundant colloid and a relative paucity of follicular cells^{14,15}. However, soon afterwards it was noted by several investigators that smears from nodular goiters with adenomatous hyperplasia could be cellular and could lack significant amount of colloid^{5,16–18}, while, in contrast, others showed the presence of colloid in some smears from papillary carcinoma¹⁹. These findings were in contradiction with previous postulates that the presence of a significant amount of colloid ruled out a neoplasm. Follicular thyroid lesions account for up to 30% of all cytologic diagnoses^{6,20}, and present an ongoing challenge in thyroid cytology^{21,22}.

In our study, out of 276 patients with FNA reports of adenomatoid nodule, cellular follicular lesion, »suspicious for follicular neoplasm« or follicular neoplasm, 67% (185 patients) correlated histologically with thyroid neoplasm, benign or malignant, while 91 patients (33%) had non-tumor diseases (either thyroiditis or nodular goiter). In comparison, 78% of FNA reports of follicular neoplasms correlated with neoplasms on subsequent histological examination. This is in concordance with findings from other authors¹². There were 256 PHD diagnoses of benign lesions (93%), and 20 PHD diagnoses of malignant lesions (7%). Higher proportion of malignant diseases is often reported by other authors, ranging from 23%–31%^{5,12,23–26}. Others report similar rates of malignancy,

TABLE 1
CORRELATION BETWEEN FINE-NEEDLE ASPIRATION CYTOLOGIC FINDINGS (FNA) AND PATHOHISTOLOGIC DIAGNOSES (PHD) IN PATIENTS WITH FOLLICULAR LESIONS OF THE THYROID

FNA	PHD										Total
	NG	HT	FA	HCA	HCC	IC	META CA	FC	MC	PC	
Adenomatoid nodule	7	0	8	0	0	0	0	0	0	0	15
Cellular follicular lesion	32	2	38	0	0	0	0	0	0	1	73
»Suspicious for follicular neoplasm«	24	1	44	3	0	0	0	0	0	4	76
Follicular neoplasm	25	0	68	4	2	1	1	4	2	5	112
Total	88	3	158	7	2	1	1	4	2	10	276

NG – nodular goiter; HT – Hashimoto thyroiditis; FA – follicular adenoma; HCA – Hürthle cell adenoma; HCC – Hürthle cell carcinoma; IC – insular carcinoma; META CA – metastatic carcinoma; FC – follicular carcinoma; MC – medullary carcinoma; PC – papillary carcinoma.

TABLE 2
RISK OF MALIGNANCY ACCORDING TO THE FINE-NEEDLE ASPIRATION CYTOLOGIC FINDINGS OF DIFFERENT SUBCATEGORIES OF FOLLICULAR LESIONS OF THE THYROID

FNA	PHD		
	Nodular goiter/Hashimoto thyroiditis (%)	Adenoma (%)	Carcinoma (%)
Adenomatoid nodule	47	53	0
Cellular follicular lesion	47	52	1
»Suspicious for follicular neoplasm«	33	62	5
Follicular neoplas	22	64	14

nancies as in our study (10.8%–12%)^{3,21}. One must keep in mind that different authors often use different cytologic terminology and subclassifications. Different terms are used to convey the same meaning, while the same term could have varied significances in different publications. Authors often do not include the reports of adenomatoid nodule, or even cellular follicular lesion in their analyses, two cytologic diagnoses that carry very little, if any, risk of malignant thyroid carcinoma. Different reporting schemes are used (two- to six or more category schemes) in an attempt to find the best way to estimate the probability of risk of malignancy, and act accordingly²⁷. The other explanation for these differences in the distribution of malignant *vs.* benign entities may be due to different prevalence of them in various patient populations.

The true incidence of follicular carcinoma is in fact, currently unknown. Historically, it has been estimated to account for 10% to 20% of all thyroid cancers, but clinical practice as well as statistical data in many countries suggests that these figures are no longer accurate^{28,29}. Follicular carcinoma has been associated with iodine deficiency, which has been successfully eliminated in many countries due to iodine prophylaxis via iodine supplementation in food products. Eradication of iodine deficiency disorders corresponded with decreasing absolute incidence of follicular carcinoma^{28–30}. Lower relative incidence of follicular carcinoma in recent decades partly comes as a result of changing pathohistological criteria³¹, and partly because of a relative increase in the incidence of papillary carcinoma, as a result of improved diagnostic techniques and more frequent³² (often excessive and unnecessary) use of ultrasound. It seems that nowadays the prevalence of follicular thyroid cancer is truly less than 10%, according to some reports even less than 5%^{14,29} and on the decline, thus decreasing the probability that a »follicular neoplasm« on FNA report will eventually prove to be a follicular cancer on PHD³³. Considering the continuing decline in the incidence of follicular thyroid carcinoma, it is comprehensible that in our study, out of the 20 patients with histologically confirmed thyroid carcinoma, half of them i.e. 10 patients had PHDs of papillary carcinoma, originally reported as cellular follicular lesion (one out of 73), »suspicious for follicular neoplasm« (4 out of 76), and follicular neoplasm (5 out of 112).

Explanations for these occasional cytologic misclassifications of papillary thyroid carcinoma, or more often, follicular variant of papillary thyroid carcinoma, lies in the fact that there are cytologic overlapping in the diagnostic criteria with these two entities and follicular neoplasm or even an adenomatoid nodule. For example, smears of the follicular variant of papillary carcinoma may display syncytial-type tissue fragments with a follicular pattern instead of characteristic features such as monolayer sheets of uniform follicular cells with nuclear grooves and intranuclear inclusions^{19,34,35}. Thus, FNA, by itself, is limited in predicting the specific histological type of neoplasm. In patients with FNAs of follicular neoplasm (N=112), out of 15 with PHDs of thyroid carcinoma, besides 5 with the above mentioned papillary carcinoma, 4 had PHDs of follicular carcinoma, while others had Hürthle cell carcinoma (N=2), medullary carcinoma (N=2), poorly differentiated (insular) carcinoma (N=1), and metastatic renal adenocarcinoma (N=1). Reasons for these discrepancies between cytologic and histological diagnoses often lie in cytologic limitations. For instance, Hürthle cell lesions/neoplasms are in some schemes included with follicular lesions as their variant, but sometimes described as a separate entity^{36,37}. In contrast to the follicular cells of follicular neoplasms, in Hürthle cell neoplasms, dyshesion of the Hürthle cells could be a useful diagnostic criterion³⁸, but it is not always present in smears. Medullary thyroid carcinoma may be difficult to differentiate cytologically from certain follicular lesions when Hürthle-like cells are present³⁹. Therefore, immunocytochemical and ultrastructural studies should be performed in dubious cases⁴⁰. In our two cases of medullary carcinoma misinterpreted as follicular neoplasm on FNA, smears contained numerous monolayers of round to oval cells with moderate degree of pleomorphism, moderate to abundant cytoplasm, and slightly enlarged round nuclei. The case of insular carcinoma was histologically verified seven yrs after initial cytological diagnosis; therefore dedifferentiation of the primary, well-differentiated tumor probably occurred.

Thyroid is a frequent site of hematological spread of the kidney, breast, lung and gastrointestinal carcinomas, and melanoma^{41–43}. Differentiation between primary thyroid tumor and metastatic one is especially challenging when no medical history of previous malignancy is present, even though diagnosis is often difficult to obtain

even in patients with known primary tumor of non-thyroid origin, if the new thyroid nodule emerges. Metastases to the thyroid from renal cell carcinomas are sometimes especially difficult to diagnose, because cells contain intranuclear inclusions that mimic primary thyroid neoplasm^{44,45}. Immunocytochemistry is the most helpful adjunct in the evaluation of thyroid nodules in patients with medical history of malignancy⁴⁶. In our case of cytologically unrecognized metastatic renal cell carcinoma (FNA resembled follicular neoplasm), the aspirate showed clusters and single round cells with medium-sized nuclei and abundant, wispy cytoplasm in patient with no previous medical history of renal carcinoma. Fortunately, misinterpreted cytologic reports, when it comes to the type of malignant neoplasm, do not alter the therapeutic approach; total thyroidectomy (usually with *ex tempore* histological analysis on frozen section, with immediate total thyroidectomy in clear cases of malignancy) is the generally accepted patient management¹.

The important message that evolves from the results of our study, however, is that different subcategories of follicular lesions on FNA findings have significantly differing likelihood of being malignant (Table 2). Thus, out of 15 FNA diagnoses of adenomatoid nodule, on histological reports there were no patients with carcinoma, and the ratio between benign follicular diagnosis (i.e. adenoma) and non-tumor thyroid disease was practically the same (1.1:1). Out of 73 patients diagnosed on FNA as having cellular follicular lesion, only one (1%) had histologically confirmed thyroid carcinoma, while 38 (52%) had PHD of follicular adenoma, and the remaining 34 (47%) had non-tumor thyroid diseases. Out of 76 patients diagnosed on FNA as having lesions »suspicious for follicular neoplasm«, four of them (5%) had histological diagnoses of thyroid carcinoma, 47 (62%) had follicular adenoma, and 25 (33%) had non-tumor thyroid disorders. Finally, out of 112 patients cytologically diagnosed as having follicular tumor, there were 15 (14%) histologically confirmed diagnoses of thyroid carcinoma, 72 (64%) PHDs of follicular adenoma, and 25 (22%) of non-

-tumor diseases. Statistical analysis revealed significant ($p < 0.01$) difference between investigated FNA report groups according to the risk of malignancy. Despite difficulties encountered in the diagnosis of follicular lesions of the thyroid, FNA remains valuable and widely accepted primary screening tool used to assess the need for resection of thyroid nodules^{22,47}. Taking into account decreasing incidence of follicular thyroid carcinoma, indeterminate follicular lesions on FNA reports often undergo surgical excision to be ultimately determined as benign diseases histopathologically⁴⁸. It is estimated that 70% to 84% of thyroid lesions showing follicular cytology on FNAs, are ultimately found to be benign on PHDs^{6,26,49}.

Management of thyroid nodules is based on statistical data correlating a specific cytologic reading with the probability of malignancy⁵⁰. Accordingly, stratification of cytologic diagnoses into different subcategories with various probabilities of malignancy allows more accurate assessment of the risk of malignancy^{51,52}. In our study, only 7% of patients overall had malignant tumors. Risk of malignancy with FNA of adenomatoid nodule was in our series 0%. Standard procedure in our institution for this diagnosis is follow-up with FNA repeated after one year. Risks of malignancy for cytologic diagnoses of cellular follicular lesion, »suspicious for follicular neoplasm«, and follicular neoplasm, were 1%, 5%, and 14%, respectively.

In conclusion, we suggest conservative management⁵³ of patients with cytologic diagnoses of cellular follicular lesion and »suspicious for follicular neoplasm«, especially when associated with low risk features, such as negative tumor markers⁵⁴ and without suspicious clinical characteristics^{55,56}. Patients with cytologic diagnosis of follicular neoplasm should undergo surgical treatment⁵⁷. Following this approach, positive repercussions on patients are in minimizing diagnostic, non-therapeutic surgical procedures, with all the negative implications that surgery carries along.

REFERENCES

1. THE PAPANICOLAOU SOCIETY OF CYTOPATHOLOGY TASK FORCE ON STANDARDS OF PRACTICE, *Diagn Cytopathol*, 15 (1996) 84.
2. GHARIB H, GOELLNER JR, *Ann Intern Med*, 118 (1993) 282.
3. ATKINSON B, *Fine-Needle Aspiration of Thyroid*. IN: LIVOLSI VD, DELELLIS RA (Eds) *Pathobiology of the Parathyroid and Thyroid Glands* (Williams&Wilkins, Baltimore, 1993).
4. SUEN KC, QUENVILLE N, *J Clin Pathol*, 36 (1983) 1036.
5. MOSLAVAC S, MATEŠA N, KUSIĆ Z, *Coll Antropol*, 34 (2010) 197.
6. BALOCH ZW, SACK MJ, YU GH, LIVOLSI VA, GUPTA PK, *Thyroid*, 8 (1998) 565.
7. HALL TL, LAYFIELD LJ, PHILIPPE A, ROSENTHAL DL, *Cancer*, 63 (1989) 718.
8. BUSSENIERS AE, OERTEL YC, *Diagn Cytopathol*, 9 (1993) 581.
9. GARDNER HA, DUCATMAN BS, WANG HH, *Cancer*, 71 (1993) 2598.
10. FADDA G, RABITTI C, MINIMO C, IERACI A, VERZI A, BIANCHI A, LANCIA M, GULLOTTA G, CAPELLI A, *Anal Quant Cytol Histol*, 17 (1995) 247.
11. COSTA MJ, SIDAWY MK, *Mod Pathol*, 2 (1989) 521.
12. SIDAWY MK, DEL VECCHIO DM, KNOLL SM, *Cancer*, 81 (1997) 253.
13. BALOCH ZW, FLEISHER S, LIVOLSI VA, GUPTA PK, *Diagn Cytopathol*, 26 (2002) 41.
14. LÖWHAGEN T, *Monogr Clin Cytol*, 4 (1974) 67.
15. FRABLE WJ, *Thin needle aspiration biopsy*. IN: BENNINGTON JL (Ed) *Major problems in pathology* (WB Saunders, Philadelphia, 1983).
16. JAYARAM G, *Acta Cytol*, 29 (1985) 967.
17. KINI SR, MILLER JM, HAMBURGER JI, SMITH-PURSLOW MJ, *Diagn Cytopathol*, 1 (1985) 123.
18. HSU C, BOEY J, *Acta Cytol*, 31 (1987) 699.
19. MILLER TR, BOTTLES K, HOLLY EA, FRIEND NF, Abele JS, *Acta Cytol*, 30 (1986) 285.
20. SUEN KC, *Can Med Assoc J*, 167 (2002) 491.
21. GOLDSTEIN RE, NETTERVILLE JL, BURKEY B, JOHNSON JE, *Ann Surg*, 235 (2002) 656.
22. CARLING T, UDELSMAN R, *Thyroid*, 15 (2005) 583.
23. GRANT CS, HAY ID, GOUGH IR, MCCARTHY PM, GOELLNER JR, *Surgery*, 106 (1989) 980.
24. GHARIB H, GOELLNER JR, ZINSMEISTER AR, GRANT CS, VAN HERDEN JA, *Ann Intern Med*, 101 (1984) 25.
25. CHEN H, NICOL TL, UDELSMAN R, *Ann Surg*, 222 (1995) 101.
26. GREAVES TS, OLVERA M, FLORENTINE BD, RAZA AS, COBB CJ, TSAO-WEI DD, GROSHEN S, SINGER P, LOPRESTI JJ, MARTIN SE, *Cancer Cytopathol*, 90 (2000) 335.
27. WANG HH, *Diagn Cytopathol*, 34 (2006) 67.
28. LIVOLSI VA, ASA SL, *Thyroid*, 4 (1994) 233.
29. DEMAY RM, *Am J Clin Pathol*, 114 (2000) 681.
30. KUSIĆ Z, LECHPAMMER S, LUKINAC LJ, PETROVIĆ I, NÖTHIG-HUS D, *J Endocrinol Invest*, 22 (1999) 747.
31. WORLD HEALTH ORGANIZATION, *INTERNATIONAL HISTOLOGICAL CLASSIFICATION OF TUMOURS*. 2nd ed. (Springer-Verlag,

- Berlin, 1988). — 32. LIN J-D, CHAO T-C, HUANG B-Y, CHEN S-T, CHANG H-Y, HSUEH C, Thyroid, 15 (2005) 708. — 33. YANG GCH, LIEBESKIND D, MESSINA AV, Cancer Cytopathol, 99 (2003) 69. — 34. HARACH HR, ZUSMAN SB, Acta Cytol, 36 (1992) 142. — 35. MARTINEZ-PARRA D, CAMPOS FERNANDEZ J, HIERRO-GUILMAIN CC, SOLA PEREZ J, PEREZ-GUILLEMO M, Diagn Cytopathol, 15 (1996) 12. — 36. GIORGADZE T, ROSSI ED, FADDA G, GUPTA PK, LIVOLSI VA, BALOCH Z, Diagn Cytopathol, 31 (2004) 307. — 37. PU RT, YANG J, WASSERMAN PG, BHUIYA T, GRIFFITH KA, MICHAEL CW, Diagn Cytopathol, 34 (2006) 330. — 38. RENSCHAW AA, Diagn Cytopathol, 29 (2003) 183. — 39. MENDONCA ME, RAMOS S, SOARES J, Cytopathology, 2 (1991) 93. — 40. RASTAD J, WILANDER E, LINDGREN PG, LJUNGHALL S, STENKVIST BG, AKERSTROM G, Acta Cytol, 31 (1987) 45. — 41. CHACHO MS, GREENEBAUM E, MOUSSOURIS HF, SCHREIBER K, KOSS LG, Acta Cytol, 31 (1987) 705. — 42. WATTS NB, Am J Med Sci, 293 (1987) 13. — 43. MICHELOW PM, LEIMAN G, Diagn Cytopathol, 13 (1995) 209. — 44. GRITSMAN AY, POPOK SM, RO JY, DEKMEZIAN RH, WEBER RS, Diagn Cytopathol, 4 (1988) 125. — 45. GREEN LK, RO JY, MACKAY B, AYALA AG, LUNA MA, Cancer, 63 (1989) 1810. — 46. PORCELL AI, HITCHCOCK CL, KEYHANI-ROFAGHA S, Acta Cytol, 44 (2000) 393. — 47. SMITH J, CHEIFETZ RE, SCHNEIDERREIT N, BEREAN K, THOMSON T, Am J Surg, 189 (2005) 592. — 48. SAHIN M, GURSOY A, TUTUNCU NB, GUVENER DN, Clin Endocrinol (Oxf), 65 (2006) 514. — 49. SCHLINKERT RT, VAN HEERDEN JA, GOELLNER JR, GHARIB H, SMITH SL, ROSALES RF, WEAVER AL, Mayo Clin Proc, 72 (1997) 913. — 50. FAQUIN WC, BALOCH ZW, DOI: 10.1002/dc.21292 — 51. WILLIAMS MD, SULIBURK JW, STAERKEL GA, BUSAIDY NL, CLAYMAN GL, EVANS DB, PERRIER ND, Ann Surg Oncol, 16 (2009) 3146. — 52. NAYAR R, IVANOVIC M, Cancer Cytopathol, 117 (2009) 195. — 53. MIHAI R, PARKER AJ, ROSKELL D, SADLER GP, Thyroid, 19 (2009) 33. — 54. BALOCH ZW, LIVOLSI VA, Best Pract Res Clin Endocrinol Metab, 22 (2008) 929. 55. — MATEŠA N, ŠAMIJA I, KUSIĆ Z, Coll Antropol, 34 (2010) 53. — 56. RAPARIA K, MIN SK, MODY DR, ANTON R, AMRIKACHI M, Arch Pathol Lab Med, 133 (2009) 787. — 57. KURU B, GULCELIK NE, GULCELIK MA, DINCER H, Head Neck, 31 (2009) 856.

N. Dabelić

Department of Oncology and Nuclear Medicine, University Hospital »Sestre milosrdnice«, Vinogradska 29,
10000 Zagreb, Croatia
e-mail: ndabelic@kbsm.hr

PROCJENA RIZIKA OD MALIGNOSTI U ADENOMATOIDNIH ČVOROVA I SUSPEKTNIH FOLIKULARNIH PROMJENA ŠTITNJAJE DOBIVENIH CITOLOŠKOM PUNKCIJOM

SAŽETAK

Cilj istraživanja bio je procijeniti rizik od malignosti u adenomatoidnih čvorova i suspektne folikularne promjene štitnjače dobivenih citološkom punkcijom. Učinjena je retrospektivna analiza 276 bolesnika kojima je provedena operacija štitnjače nakon predoperacijske citološke punkcije pod kontrolom ultrazvuka i citološke dijagnoze bilo adenomatoidnog čvora, celularne folikularne promjene, »suspektne folikularne tumora« ili folikularnog tumora. Od 276 bolesnika, nalazi citološke punkcije ukazali su na 15 dijagnoza (5%) adenomatoidnih čvorova, 73 (26%) celularnih folikularnih promjena, 76 (28%) »suspektne folikularne tumora« i 112 (41%) folikularnih tumora. Citološke dijagnoze uspoređivane su s patohistološkim dijagnozama (PHD). Kod citološke dijagnoze adenomatoidnog čvora (N=15), PHD je u 7 slučajeva (47%) ukazao na nodularnu strumu, a u 8 (53%) na folikularni adenom. Kod citološke dijagnoze celularne folikularne promjene (N=73), PHD je u 2 slučaja (3%) ukazao na tireoiditis, u 32 (44%) na nodularnu strumu, u 38 slučajeva (52%) na folikularni adenom, te u 1 bolesnika (1%) na papilarni karcinom. U slučaju citološke dijagnoze »suspektne folikularne tumora« (N=76), PHD je u 1 slučaju (1%) ukazao na tireoiditis, u 24 slučaja (32%) na nodularnu strumu, u 47 bolesnika (62%) na folikularni adenom i u 4 bolesnika (5%) na papilarni karcinom. Kod citološke dijagnoze folikularnog tumora (N=112), PHD je u 25 slučajeva (22%) odgovarao nodularnoj strumi, u 72 slučaja (64%) folikularnom adenomu, te u 15 bolesnika (14%) karcinomu štitnjače. Utvrđena je značajna razlika ($p < 0,01$) između ispitivanih skupina citoloških dijagnoza u odnosu na rizik od malignosti. Raspodjela citoloških dijagnoza folikularne promjene štitnjače u podskupine s različitom vjerojatnošću malignosti omogućuje točniju procjenu rizika od malignosti i individualizirani pristup liječenju, kada je potrebno odlučiti treba li bolesnika odmah uputiti na operaciju ili preporučiti česte kontrole s ponavljanjem citološke punkcije.