

Thrombotic thrombocytopenic purpura: the role of ADAMTS13 assay in clinical practice

Duraković, Nadira; Radonić, Radovan; Gašparović, Vladimir

Source / Izvornik: **Collegium Antropologicum, 2010, 34, 1087 - 1091**

Journal article, Published version

Rad u časopisu, Objavljena verzija rada (izdavačev PDF)

Permanent link / Trajna poveznica: <https://um.nsk.hr/um:nbn:hr:105:116100>

Rights / Prava: [In copyright](#) / [Zaštićeno autorskim pravom.](#)

Download date / Datum preuzimanja: **2025-03-29**



Repository / Repozitorij:

[Dr Med - University of Zagreb School of Medicine
Digital Repository](#)



Thrombotic Thrombocytopenic Purpura – The Role of ADAMTS13 Assay in Clinical Practice

Nadira Duraković, Radovan Radonić and Vladimir Gašparović

Department of Internal Medicine, Divisions of Intensive Care Medicine and Hematology, University Hospital Center Zagreb, Zagreb, Croatia

ABSTRACT

Thrombotic thrombocytopenic purpura (TTP) is a disorder characterized by disseminated thrombotic occlusions of the microcirculation. Identification of ADAMTS13 protease and its place in the pathophysiology of TTP led to better understanding of the disease and better survival for the diseased. Here we show a case report of a patient that had a normal ADAMTS13 protease activity and an unusual clinical presentation and utilize that case to highlight how the absence of a severe ADAMTS13 protease deficiency does not preclude a diagnosis of TTP and how early initiation and continuation of plasma exchange therapy can lead to a positive outcome, even in a severely ill patient. Even though ADAMTS13 protease determination has no immediate influence on the decision whether or not to start the plasma exchange therapy, it has great impact on future management of the patient and should be determined whenever possible.

Key words: thrombotic thrombocytopenic purpura, ADAMTS13 protease, plasma exchange therapy

Introduction

Thrombotic thrombocytopenic purpura (TTP) was first described by Moschcowitz in 1924. It is a disease characterized by disseminated thrombotic occlusions of the microcirculation, clinically described as being distinguished by a pentad of symptoms: microangiopathic hemolytic anemia, thrombocytopenia, neurological symptoms, fever and renal dysfunction. However, lately fewer patients are described presenting with fever and severe neurological symptoms¹, which is probably due to the early start of treatment, shown to be crucial for the success of the therapy. Until 1991 the mortality of TTP was around 90%², and there were just anecdotal evidence that plasma infusions might improve chances of survival in these patients. A pivotal study was done by the Canadian Apheresis Study Group that showed superiority of plasma exchange therapy over plasma infusion, with overall mortality of 29% in both groups, mortality in plasma exchange group being 21%³. Pathogenesis of the disease was unknown until 1997, when acquired antibodies were first identified in adults with TTP that inhibit von Willebrand factor (vWF) cleaving protease, which is normally found in plasma and is responsible for cleaving

large multimeres of vWF that are otherwise capable of agglutinating circulating platelets^{4,5}. It was also found that there is a subset of patients with familiar thrombotic thrombocytopenic purpura that lacked vWF-cleaving protease activity but had no inhibitor. In 2001 vWF-cleaving protease was purified and cloned, it was shown to be a new member of the »a disintegrin and metalloprotease with thrombospondin type 1 repeats« family, and named ADAMTS13 protease^{6–10}. There was a lot of excitement generated, because now pathogenesis of TTP could finally be explained: autoantibodies are generated against ADAMTS13 protease, and the absence of ADAMTS13 protease activity allows VWF and platelets to accumulate in microvascular thrombi, which leads to platelet consumption, hemolysis, and microvascular occlusion, leading to infarction damage of brain and kidney. Plasma exchange is efficacious because it removes pathogenic autoantibodies and replenishes the missing ADAMTS13 protease, restoring the normal regulation of VWF-dependent platelet adhesion. However, reality proved not to be as simple. In the following years a lot of studies were done looking into activity of ADAMTS13

protease in various populations and their response to plasma exchange therapy^{11–14}. Studies have confirmed the specificity of severe ADAMTS13 protease deficiency (<5%) for idiopathic TTP, but sensitivity remains controversial. Severe ADAMTS13 deficiency is rare in »secondary« TTP, associated with hematopoietic stem cell transplantation, cancer, pregnancy, systemic infections, drug toxicity, or other predisposing conditions, and it was not shown in diarrhea-associated hemolytic uremic syndrome (HUS) caused by Shiga toxin-producing *E. coli*^{1,12}. In that respect, determination of ADAMTS13 protease deficiency rules out the possibility of secondary TTP, and proves beyond suspicion the diagnosis of idiopathic TTP. However, the incidence of severe ADAMTS13 protease deficiency in patients with idiopathic TTP has varied from 33% to 100% in different studies^{1,4,5,14}. Furthermore, even patients with shown severe ADAMTS13 protease deficiency can achieve clinical responses with plasma exchange therapy despite persistent low ADAMTS13 protease activity¹⁵. It is important to emphasize that patients regardless of their ADAMTS13 protease activity status will equally respond to plasma exchange therapy¹. A difference in early response to therapy and survival between two groups has not yet been shown, but there is evidence that severe ADAMTS13 protease deficiency and high antibody titers are associated with delayed response to plasma exchange therapy and increased risk of relapse^{15–18}. Relapse is frequent in TTP, rates about 30–35%, but there has been shown statistically significant difference in the frequency of relapses in the patients with severe ADAMTS13 deficiency¹. Even though ADAMTS13 protease determination has no immediate influence on the decision whether or not to start the plasma exchange therapy, it certainly has great impact on future dealings with the patient. As shown, if ADAMTS13 deficiency is found, the diagnosis of TTP has been proven with certainty, and we need not look any further trying to find causes of secondary TTP. Also, such a patient should be closely monitored for relapse and in the case of thrombocytopenia with elevated lactate dehydrogenase (LDH), plasma exchange therapy should be promptly started in order to avoid organ tissue damage.

The purpose of presenting this case is to highlight how the absence of a severe ADAMTS13 protease deficiency does not preclude a diagnosis of TTP and how early initiation and continuation of plasma exchange therapy can lead to a positive outcome, even in a severely ill patient.

Case Report

The patient is a 61 year old female, with no other illnesses apart from hypertension, initially presented with symptoms of fever up to 40°C, with chills, general poor condition and abdominal pain present for three days. She was then seen by an infectious disease physician. Initial work-up showed thrombocytopenia of $75 \times 10^9/L$, but no clinical findings indicated infectious etiology. She was referred to internal medicine specialist in an outside clinic.

Platelet count at that point was $17 \times 10^9/L$, LDH was elevated. No anemia was present. She was conscious, but slow in response. During the next days non-oliguric acute renal failure developed. After platelet (PLT) substitution a kidney biopsy was performed and hemodialysis started. Histological examination showed extensive tubular damage with focal eccentric accumulation of hyaline material in walls of some arteriolas. These findings were indicative of TTP, so plasma exchange and steroids were initiated, and she was started on iv. antibiotics because of fever, although there were no signs of infection. Progression of alteration in mental status dominated the further clinical presentation, she became confused, altered, but without signs of focal damage, and CT scan was normal. Of note is, that the microimmunofluorescent test for antiplatelet antibodies was positive, both direct and indirect. The patient was then transferred to our intensive care unit for further treatment.

Upon admission to our clinic her mental status had deteriorated, she was somnolent, reacting only to painful stimuli, with numerous hematoma on extremities. Blood pressure was somewhat higher 160/90 mmHg, pulse was 94/min, she was still febrile, although not over 38.4°C. Initial lab work-up showed leukocytosis with 7% of non-segmented granulocytes, moderate anemia (hemoglobin 110 g/L, erythrocytes $3.55 \times 10^9/L$) with schistocytes on the peripheral blood smear, platelet count was $62 \times 10^9/L$. Serum creatinine was elevated (465 $\mu\text{mol/L}$), urea was 25.1 mmol/L, she had mild elevation of both conjugated and unconjugated bilirubin (16 $\mu\text{mol/L}$ and 7 $\mu\text{mol/L}$, respectively) and of liver enzymes (AST 138 U/L, ALT 143 U/L, GGT 135 U/L). LDH was elevated (503 U/L), haptoglobin was within normal ranges (0.67 g/L). Coombs test was negative. Fibrinogen degradation products were elevated (D-dimers were 5.34 mg/L) and fibrinogen decreased (1.8 g/L), with normal prothrombin time (0.9) and activated partial thromboplastin time (APTT) (28.2 s). C-reactive protein (CRP) was low, which was indicative of non-infectious origin of fever. Blood cultures were also done repeatedly, and were all negative. All other microbiological samples did not indicate infectious etiology, including cytomegalovirus (CMV) early antigen test. There was no evidence of malignant disease found. Initial immunology tests were done and showed no signs of autoimmune disease (antinuclear factor (ANF) negative, rheumatoid factor (RF) 9.75, anti-neutrophil cytoplasmic antibody (ANCA) negative, complement components tested were within normal range). ADAMTS13 protease activity was determined and it was normal (64% and 60% activity), of note is that serum for testing was obtained after 2 sessions of plasma exchange had been done.

Daily plasma exchange was continued, along with immunosuppressive therapy (methylprednisolone 80 mg iv. daily). Her condition did not improve during the first week; it actually worsened, hemoglobin level fell from >100 g/L to <60 g/L warranting packed erythrocyte transfusion, and her state of consciousness deteriorated. There was modest improvement around day 6 from admission, PLT count rose to $>75 \times 10^9/L$, but improvement

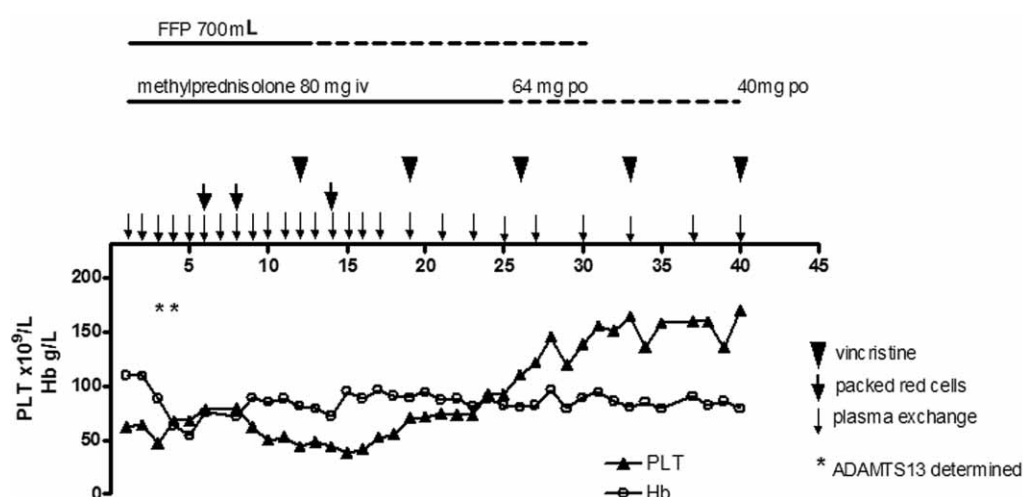


Fig. 1. Overview of therapy administered. PLT – platelets, Hb – hemoglobin, FFP – fresh frozen plasma, po – per os.

was transient. At that time she was conscious, but agitated, and transiently confused. There were hints of alcohol abuse, and alcohol withdrawal crisis was also considered. On day 12 the patient received 2mg of vincristine iv, to be continued in weekly applications. On day 19 PLT count was around $70 \times 10^9/L$, and around day 24, after the second application of vincristine, there was considerable improvement in PLT count ($92 \times 10^9/L$), and plasma exchange procedure could be tapered. Around that time the patient started to feel better and her mental status improved. Treatment was continued with weekly vincristine injections, corticosteroids and plasma exchange therapy were tapered, and the state of the patient further improved (Figure 1). She was released on day 40 after admission, after receiving total of 27 plasma exchanges, and 5 weekly injections of vincristine (2mg/injection). Before release her PLT count was $169 \times 10^9/L$, hemoglobin was 79 g/L, Htc 0.241, creatinine 129 $\mu\text{mol/L}$, LDH 246

U/L. She continued with regular follow up visits, her hemoglobin level improved shortly after discharge, she did not need red blood cell substitution. In the follow up period of 2 years she had no relapses.

Discussion and Conclusion

Even though the pathogenesis of TTP is explained, and ADAMTS13 protease assay is widely available, we still rely predominantly on clinical symptoms when establishing the diagnosis of TTP. Nowadays, the pentad of symptoms is rarely encountered, and since early therapy initiation is crucial for therapy success, it is generally believed that evidence of microangiopathic hemolytic anemia (schistocytes, increased serum levels of lactate dehydrogenase, indirect bilirubin, and a negative direct Coombs' test) and thrombocytopenia are sufficient to

TABLE 1
OVERVIEW OF TYPES OF THROMBOTIC THROMBOCYTOPENIC PURPURA

Category	Clinical Features*	Mechanism / ADAMTS13	Treatment
Idiopathic TTP	Coombs negative, absence of conditions associated with secondary TTP. Severe renal failure is rare.	Autoimmune ADAMTS13 deficiency in a majority of patients	>80% response to plasma exchange. Consider immunosuppression
Secondary TTP	Associated conditions include cancer, infection, hematopoietic stem cell transplantation, solid organ transplantation, SLE, chemotherapy, certain drugs (ticlopidin)	Mechanisms are mostly unknown. ADAMTS13 deficiency is rare. With SLE severe ADAMTS13 deficiency described	Not likely to respond to plasma exchange therapy. Treatment and prognosis are dictated by the specific associated conditions
Diarrhea-associated HUS (D+HUS)	Acute renal failure, preceded by bloody diarrhea.	Endothelial damage by Shiga toxin-producing <i>E. coli</i> . ADAMTS13 deficiency is rare	No demonstrated efficacy of plasma exchange.
Atypical HUS	Acute renal failure, no diarrhea	Complement regulatory protein defects in at least 50% of patients; ADAMTS13 deficiency is rare	No demonstrated efficacy of plasma exchange, except possibly for factor H deficiency

*Other than microangiopathic hemolytic anemia and thrombocytopenia, TTP – thrombotic thrombocytopenic purpura, HUS – Hemolytic-uremic syndrome, SLE – *systemic lupus erythematosus*, ADAMTS13 – a disintegrin and metalloprotease with thrombospondin type 1 repeats

consider a diagnosis of TTP, particularly in the absence of signs and symptoms indicative of secondary cause, such as sepsis, malignant disease, pregnancy, or malignant hypertension (Table 1). Our patient had somewhat unusual initial presentation: abdominal pain, high fever with chills and thrombocytopenia without considerable anemia. When developed renal failure, physicians from an outside clinic performed kidney biopsy, not usually done to establish diagnosis of TTP, but it was still helpful. It was not until she was transferred to our intensive care unit that she became somnolent, and there were signs of intravascular destruction of platelets and Coombs-negative microangiopathic hemolytic anemia, which assured us it was a case of TTP. Misleading were the positive result of antiplatelet antibodies, and an anamnesis of high fever and chills, which are more indicative of infection, although all cultures taken were sterile, CRP was not elevated and there was no evidence of pneumonic infiltration or any other infection. We relied on clinical presentation and continued plasma exchange therapy; severe anemia that developed later only proved to our opinion the initial working diagnosis. Absence of a severe ADAMTS13 protease deficiency did not influence our diagnosis or our treatment plan; as it was shown not all patients with TTP have decreased ADAMTS13 protease activity and it should not be an exclusion factor in the diagnosis of TTP. Even though ADAMTS13 protease analysis was done after at least 2 plasma exchange sessions, we believe that this patient had no decreased ADAMTS13 protease activity, since generally more plasma exchange therapies are

needed to eliminate antibodies and reinstitute metalloprotease activity¹⁵.

In conclusion, thrombotic thrombocytopenic purpura is a disease in which a considerable progress was made in deciphering the pathogenesis, improving therapy options and patients' chances of survival. Today clinicians, when considering TTP as diagnosis, still mostly rely on the presence of thrombocytopenia and microangiopathic hemolytic anemia, and the absence of other causes for it. In the case of our patient we eliminated most of the more frequent causes for secondary TTP: malignant disease, pregnancy, toxic effect of drugs, systemic infection, and also could not prove that it was a case of idiopathic TTP.

We do agree that ADAMTS13 deficiency determination is needed and necessary, and plasma should be taken for testing prior to starting plasma exchange therapy. Negative result does not exclude TTP diagnosis, but positive one reassures clinicians of their suspected diagnosis and is an important piece of information when planning future care for the patient in question.

Acknowledgements

The authors would like to thank Dr. J. A. Kremer Hovinga, department of Hematology and Central Hematology Laboratory, Inselspital, Bern, Switzerland for measuring ADAMTS13 activity and for critical reading of the manuscript

REFERENCES

1. VESELY SK, GEORGE JN, LÄMMLER B, STUDD JD, ALBERIO L, EL-HARAKE MA, RASKOB GE, Blood, 102 (2003) 60. — 2. AMOROSI EL, ULTMANN JE, Medicine, 45 (1966) 139. — 3. ROCK GA, SHUMAK KH, BUSKARD NA, BLANCHETTE VS, KELTON JG, NAIR RC, SPASSOFF RA, N Engl J Med, 325 (1991) 393. — 4. FURLAN M, ROBLES R, GALBUSERA M, REMUZZI G, KYRLE PA, BRENNER B, KRAUSE M, SCHARRER I, AUMANN V, MITTLER U, SOLENTHALER M, LÄMMLER B, N ENGL J MED, 339 (1998) 1578. — 5. TSAI HM, LIAN EC, N Engl J Med, 339 (1998) 1585. — 6. FUJIKAWA K, SUZUKI H, MCMULLEN B, CHUNG D, Blood, 98 (2001) 1662. — 7. GERRITSEN HE, ROBLES R, LÄMMLER B, FURLAN M, Blood, 98 (2001) 1654. — 8. LEVY GG, NICHOLS WC, LIAN EC, FOROUD T, MCCLINTICK JN, MCGEE BM, YANG AY, SIEMIENIAK DR, STARK KR, GRUPPO R, SARODE R, SHURIN SB, CHANDRASEKARAN V, STABLER SP, SABIO H, BOUHASSIRA EE, UPSHAW JD JR, GINSBURG D, TSAI HM, Nature, 413 (2001) 488. — 9. SOEJIMA K, MIMURA N, HIRASHIMA M, MAEDA H, HAMAMOTO T, NAKAGAKI T, NOZAKI C, J Biochem, 130 (2001) 475. — 10. ZHENG X, CHUNG D, TAKAYAMA TK, MAJERUS EM, SADLER JE, FUJIKAWA K, J Biol Chem, 276 (2001) 41059. — 11. GASPAROVIC V, RADONIC R, MEJIC S, PISL Z, RADMAN I, Intensive Care Med, 26 (2000) 1690. — 12. KREMER HOVINGA JA, STUDD JD, ALBERIO L, LÄMMLER B, Semin Hematol, 41 (2004) 75. — 13. STUDD JD, HOVINGA JA, RADONIC R, GASPAROVIC V, IVANOVIC D, MERKLER M, WIRTHMUELLER U, DAHINDEN C, FURLAN M, LÄMMLER B, Blood, 103 (2004) 4195. — 14. VEYRADIER A, OBERT B, HOULLIER A, MEYER D, GIRMA JP, Blood, 98 (2001) 1765. — 15. BÖHM M, BETZ C, MIESBACH W, KRAUSE M, VON AUER C, GEIGER H, SCHARRER I, Br J Haematol, 129 (2005) 644. — 16. COPPO P, WOLF M, VEYRADIER A, BUSSEL A, MALOT S, MILLOT GA, DAUBIN C, BORDESSOULE D, PÈNE F, MIRA JP, HESHMATI F, MAURY E, GUIDET B, BOULANGER E, GALICIER L, PARQUET N, VERNANT JP, RONDEAU E, AZOULAY E, SCHLEMMER B, Br J Haematol, 132 (2006) 66. — 17. TSAI HM, LI A, ROCK G, Clin Lab, 47 (2001) 387. — 18. ZHENG XL, KAUFMAN RM, GOODNOUGH LT, SADLER JE, Blood, 103 (2004) 4043.

V. Gašparović

Department of Internal Medicine, Division of Intensive Care Medicine, University Hospital Center Zagreb, Kišpatičeva 12, 10000 Zagreb
e-mail: vgasparovic111948@yahoo.com

TROMBOTSKA TROMBOCITOPENIČNA PURPURA – ULOGA TESTA ADAMTS13 PROTEAZE U KLINIČKOJ PRAKSI

S A Ž E T A K

Trombotska trombocitopenična purpura (TTP) je bolest karakterizirana diseminiranim trombotskim okluzijama mikrocirkulacije. Identifikacija ADAMTS13 proteaze i njenog mjesta u patofiziologiji bolesti dovelo je do boljeg razumijevanja bolesti i boljeg preživljenja oboljelih. Ovaj rad je prikaz slučaja bolesnica s normalnom razinom ADAMTS13 aktivnosti i neobičnom kliničkom prezentacijom uz pomoć kojega želimo naglasiti kako odsustvo teškog pomanjkanja ADAMTS13 aktivnosti ne izuzima dijagnozu TTP i kako rano započinjanje i nastavak terapije izmjenom plazme može dovesti do pozitivnog ishoda, čak i u teško oboljelih. Iako određivanje nedostatka ADAMTS13 aktivnosti nema trenutni utjecaj na odluku da li ili ne započeti terapiju izmjenom plazme, ima veliki utjecaj na daljnje terapijske odluke i trebala bi biti pokušana kad god je to moguće.