

Primary synovial sarcoma of the parotid gland in 15-year-old boy

Lukšić, Ivica; Virag, Mišo; Manojlović, Spomenka; Obradović, Bojan;
Macan, Darko; Stepan, Jasminka

Source / Izvornik: **Journal of Cranio-Maxillo-Facial Surgery**, 2011, 39, 445 - 448

Journal article, Accepted version

Rad u časopisu, Završna verzija rukopisa prihvaćena za objavljivanje (postprint)

<https://doi.org/10.1016/j.jcms.2010.10.010>

Permanent link / Trajna poveznica: <https://urn.nsk.hr/urn:nbn:hr:105:028248>

Rights / Prava: [In copyright](#)/[Zaštićeno autorskim pravom](#).

Download date / Datum preuzimanja: **2024-11-16**



Repository / Repozitorij:

[Dr Med - University of Zagreb School of Medicine
Digital Repository](#)





Središnja medicinska knjižnica

Lukšić I., Virag M., Manojlović S., Obradović B., Macan D., Stepan J.
(2010) *Primary synovial sarcoma of the parotid gland in 15-year-old boy.* Journal of Cranio-Maxillofacial Surgery, [Epub ahead of print].
ISSN 1010-5182

<http://www.elsevier.com/locate/issn/10105182>

<http://www.sciencedirect.com/science/journal/10105182>

<http://dx.doi.org/10.1016/j.jcms.2010.10.010>

<http://medlib.mef.hr/921>

University of Zagreb Medical School Repository

<http://medlib.mef.hr/>

Primary synovial sarcoma of the parotid gland in 15-year-old boy

Ivica Lukšić, MD, PhD¹, Mišo Virag, MD, PhD, FRCS¹, Spomenka Manojlović, MD, PhD², Bojan Obradović, MD, DMD, MSc³, Darko Macan, DMD, PhD¹, Jasminka Stepan, MD, PhD⁴

¹Department of Maxillofacial Surgery (Head: Mišo Virag, MD, PhD, FRCS), University of Zagreb School of Medicine and School of Dental Medicine, University Hospital Dubrava, Zagreb, Croatia

²Department of Pathology, University of Zagreb School of Medicine, University Hospital Dubrava, Zagreb, Croatia

³Department Chair of Maxillofacial Surgery, Medical School University of Banja Luka, Banja Luka, Bosnia and Herzegovina

⁴Department of Haematology and Oncology, Paediatric Clinic, Children's Hospital Zagreb, Zagreb, Croatia

Correspondence:

Ivica Lukšić, MD, PhD

Department of Maxillofacial Surgery, University of Zagreb School of Medicine, University Hospital Dubrava

Ave. Gojko Susak 6

10 000 Zagreb, Croatia

Phone: +38512903067

Fax: +385 1 286 4250

E-mail: luksic@kbd.hr

INTRODUCTION

Synovial sarcoma is an unusual malignant tumour, derived from soft tissue mesenchymal cells. It arises most commonly in the deep soft tissues of lower extremities, especially in the region of the lower thigh, with a predilection for sites in proximity to large joints, such as the knee and ankle (*Shmookler et al., 1982; Miloro et al., 1994*). The peak incidence is in adolescents and young adults between 16 and 49 years of age (median 34 years), and the tumour affects males more often than females (*Shmookler et al., 1982*). Synovial sarcoma represents approximately 5-10% of all soft tissue sarcomas, only 3% of which occur in the head and neck region (*Kartha and Bumpous, 2002*). The most common site is the hypopharynx, with the larynx being the least common site (*Dei Tos et al., 1998*).

Primary synovial sarcoma of the parotid gland is exceptionally uncommon, with few cases reported in the literature (*Amble et al., 1992*). In cases with adequate clinical documentation, tumours present as painless masses and mostly in the parotid gland of young and middle-aged men (*Amble et al., 1992*). Diagnostic methods are clinical examination, CT or MR imaging, and histological examination. Therapy included primary surgical wide excision with elective neck dissection. The tumour is moderately sensitive to chemotherapy and radiotherapy, and these treatment modalities may prove useful as adjunctive therapy (*Shmookler et al., 1982*). The prognosis depends on the size and grade of the tumor (*Thompson et al., 2000*).

CASE REPORT

A 15-year-old boy with a painless swelling in the right parotid gland was previously examined by the paediatrician and referred for further treatment. The patient's medical history was unremarkable and his general condition was good. Clinical examination revealed a nonmobile mass on the right side of his face, in the front of ear, about 4 cm in diameter, of solid consistency, and with clinically negative neck. The patient did not complain of any pain or neurological deficit in the facial region. Opening of the mouth was not restricted and functions of the facial nerve were completely normal. Results of routine laboratory tests were within normal limits. Cytological analyses (FNA) of the mass pointed to a tumour of mesenchymal origin. MR imaging with contrast showed an expansile mass in the deep lobe of the right parotid gland with infiltration of the superficial lobe without evidence of metastatic lymphadenopathy (Fig. 1 and 2). The first step of therapy was a surgical procedure, including wide excision and total parotidectomy with selective neck dissection (levels II, III and Va).

Histopathological findings:

The surgical specimen consisted of the parotid gland and lymph nodes from the selective neck dissection (Fig. 3). A multinodular, well-demarcated, rubbery, gray-white tumour, measuring 4 cm in diameter at its widest, presented within the parotid gland. Microscopic analysis revealed highly cellular whirling fascicles of spindle-shaped cells with uniform, oval, vesicular, dark-staining nuclei and indistinct cytoplasm (Fig. 4). The cellular portions alternated with acellular hyalinized collagen bands. The central portion of the largest

tumour nodule contained ill-defined myxoid areas. Mitotic activity was moderate (3-5 mitotic figures per 10 high-power fields). Tumour cells revealed diffusely and strongly positive immunostaining for vimentin, calponin, bcl-2 and Ki67 (>50%), weakly positive staining for S100 and smooth-muscle actin and negative staining for pancytokeratin, CK7, EMA and desmin (Fig. 5). RT-PCR analysis revealed positive SYT/SSX1 and SYT/SSX2 translocations. The definitive histopathological diagnosis was synovial sarcoma of monophasic type with clear margins.

In the specimen after selective neck dissection of levels II, III and Va, 15 lymph nodes were examined, all of which were histological negative.

Following consultation with a paediatric oncologist, the next step in treatment were 9 cycles of ifosfamide- based chemotherapy (CWS protocol - high risk group). After chemotherapy, radiotherapy followed in 30 dosages applying a total of 60 Gy.

Two years later, the condition of the patient is generally good, the surgical area has healed without complications, the patient is free of loco-regional recurrence and distant metastasis, and the control MRI of the head, neck and chest was negative for any evidence of neoplastic disease.

DISCUSSION

Synovial sarcoma is a rare tumour, classified as a soft tissue sarcoma. The origin of these tumours is believed to be from an undifferentiated mesenchymal cell that undergoes synovial differentiation (Barnes, 2001; Grayson et al., 1998). Despite its name, synovial sarcoma is not restricted to periarticular sites (Goebel et al., 2004). Three percent of cases arise in the head and neck region (Kariha and Bumpous, 2002). Because of the rarity of the neoplasm in the head and neck region the possibility of misdiagnosis is a likely event. The most common site in the head and neck is the hypopharynx, with the larynx being the least common site (Dei Tos et al., 1998). In the neck, they typically occur at the level of the bifurcation of the carotid artery, intimately associated with the prevertebral fascia (Barnes, 2001). Synovial sarcomas have been detected on unusual sites in the oral and maxillofacial region such as cheek mucosa (Goebel et al., 2004), maxillary sinus (Sun et al., 2003), mandible (Tilakaratne, 2006), tongue (Guzmán Patraca et al., 1975; Carrillo et al., 1992), floor of the mouth (Meer et al., 2003), soft palate (Massarelli et al., 1978), and parotid gland (Grayson et al., 1998; Jay et al., 2008; Barkan and El-Naggar, 2004; Cho et al., 2008). Similarly to synovial sarcomas at more conventional sites, this is a disease of young adults: ages ranging from 16-49 years (median 34 years) (Shmookler et al., 1982). It has been reported that synovial sarcoma of the head and neck is seen most commonly in patients who are more than a decade younger than patients who have the same neoplasm in the trunk and extremities (Milorio et al., 1994). To the best of our knowledge, this is the youngest recorded patient with synovial sarcoma of the parotid gland.

Salivary gland tumours are rare in children (*Zernial et al., 2007*). Primary synovial sarcoma of the parotid gland is a rare occurrence that may commonly cause differential diagnostic difficulties (*Barkan and El-Naggar, 2004*). A painless neck mass was the single most common presenting symptom (*Amble et al., 1992*). The diagnosis of synovial sarcoma proved difficult and approximately one third of the patients initially received incorrect pathologic diagnosis. Synovial sarcoma is a mesenchymal spindle cell tumour, which may display variable epithelial differentiation. It may present as biphasic or monophasic variant. Biphasic SS has epithelial and spindle cell components in varying proportions, and in monophasic SS the spindle cell component often occurs alone (*Fisher, 1998*). *Shmookler et al. (1982)* stressed that differential diagnosis, depending on the proportion of the biphasic components, ranged from spindle cell mesenchymal neoplasms to various adenocarcinomas, including those arising in mixed tumours of the salivary gland. In the parotid gland, it is most likely to be misdiagnosed as a myoepithelial, primary mesenchymal, or metastatic neoplasm (*Jay et al., 2008*). The criteria for establishing a primary salivary gland origin are: (1) the patient must not have, or have had, a sarcoma in another site; (2) patient evaluation has excluded the likelihood of metastatic disease; (3) the gross and microscopic appearances support primary origin rather than invasion from adjacent soft tissue, and (4) carcinosarcoma has been excluded (*Ellis and Auclair, 1996*). In our case, the tumour was monophasic. Epithelial differentiation could not be confirmed even by immunostaining. Although even monophasic SS can sometimes reveal an epithelial component, this is not necessary for diagnosis. Sensitive immunohistochemical markers for neoplastic myoepithelium, such as calponin, S-100 protein and smooth muscle actin are not specific for myoepithelial carcinoma since numerous normal and neoplastic cells, including

spindle cells in synovial sarcoma, may express reactivity for these markers (*Ellis and Auclair, 2008*). In general, age of the patient, histological pattern of the tumour, lack of the epithelial component and, most important, molecular demonstration of the characteristic translocations excluded carcinosarcoma and myoepithelial carcinoma, and were definitive for monophasic variant of synovial sarcoma as a final diagnosis.

During preoperative analysis of our patient we performed an FNA biopsy, which suggested tumour of mesenchymal origin. Analysis pointed to a tumour of mesenchymal origin, which was one of the important criteria for our differential diagnosis and the planning of therapy. Radiographic findings (CT or MR imaging) are helpful in defining the location and extent of the neoplasm and may, at times, even suggest the correct diagnosis. Because the appearance of synovial sarcomas varies and other nonmucosal head and neck masses may appear similar, no specific imaging characteristics define the entity (*Hirsch et al., 1997*).

Due to the rarity of this neoplasm in the head and neck region, information regarding appropriate therapy for this neoplasm is limited. We performed a complete surgical resection (total parotidectomy) with an elective neck dissection of levels II, III and Va, postoperative chemotherapy and radiotherapy. Many authors agree that tumour size is the most important prognostic factor (*Fisher, 1998; Wang et al., 2008*). *Thompson et al. (2000)* stressed that patients with tumours with a widest diameter greater than 5 cm have a poorer prognosis than those with tumours less than 5 cm in diameter. Also, the authors urge that a multicenter trial for neoadjuvant chemotherapy should be initiated for patients presenting with a synovial sarcoma greater than 10 cm in diameter (*Thompson et al., 2000*).

Metastases are not frequent at diagnosis, but distant metastases remain a predominant cause of death. The most common site of distant metastasis is the lung (97%) and it may occur

years after initial therapy, with an average duration from initial treatment to detection of 30.8 months (*Amble et al., 1992; Goebel et al., 2004*). The article by *Lee and Shin (2008)* from Memorial Sloan-Kettering Cancer Center highlights the importance of a multidisciplinary approach in the treatment of this disease. *Harb et al. (2007)* stressed that survival rates were associated with tumour location, size, and extension. *Giaoui et al. (1999)* say that favourable prognostic findings include age less than 20 years and complete initial resection. Post treatment recurrence rate for synovial sarcoma arising from all body sites is 50%, most cases recur in the first two years after treatment (*Fisher, 1998*). Follow-up of patients with synovial sarcoma of the head and neck indicate that 21-44% will develop local recurrence and 24-48% distant metastases (especially to the lung), with an overall 5-year survival of 47-58% (*Barnes, 2001*). However, some authors have shown 5 year survival rates of up to 65-70% (*Ladenstein et al., 1993*) while other authors emphasize that despite a five year survival rate of 25-50%, the 10 year survival rate is only 10-15% (*Sun et al., 2003*). One other report describes that prognosis for patients with synovial sarcoma in the head and neck is better than for patients with synovial sarcoma in the trunk and extremities because this tumour in the head and neck presents in younger patients and is treated earlier after the onset of symptoms (*Hirsch et al., 1997*).

Besause of low reported incidence there is a global lack of experience in dealing with synovial sarcoma of the head and neck. *Kartha and Bumpous (2002)* stressed a more aggressive behaviour of the synovial sarcoma of the head and neck than of the same neoplasm in the extremities. Because of the aggressive nature of synovial sarcoma, some modification of accepted treatment modalities may be required. Most authors agree that adequate primary surgery is essential to both local control and overall outcome for synovial

sarcoma patients (*Bergh et al., 1999*). Some of them propose that a neck dissection is not warranted, because only 3-4% of synovial sarcoma of head and neck are associated with cervical lymph node metastasis (*Shmookler et al., 1982; Amble et al., 1992*). One other report has shown that twenty-five percent of the cases involve regional lymph nodes (*Tilakaratne, 2006*). Moreover, lymph node metastases develop more frequently than in other nonrhabdomyosarcoma soft tissue sarcomas (*Ferrari et al., 1999*). In our opinion the surgical procedure would be radical excision with some type of elective neck dissection because at the time of operation we didn't know true histological diagnosis. Frozen section analysis hasn't been done, because it wouldn't change the extent of surgical treatment. However, in most instances at the time of surgery histopathological diagnosis is unknown. The only guidance is clinical appearance and the fine needle biopsy.

A number of authors report diverse opinions concerning the value of radiation therapy and chemotherapy in treatment of synovial sarcoma in the head and neck region (*Goebel et al., 2004; Ferrari et al., 1999*). *Amble et al. (1992)* proposed wide local excision with postoperative radiotherapy of 65 Gy and considered prophylactic neck dissection and chemotherapy to be less effective. Synovial sarcoma is often chemosensitive, and given its poor prognosis, multicenter trials of adjuvant therapy are warranted (*Spillane et al., 2000*).

CONCLUSION

The primary synovial sarcoma of the parotid gland is extremely rare, especially in children. Two years after therapy our young patient is well with no evidence of disease. That is a short follow-up period, but we can say that multimodal therapy with aggressive surgical excision followed by early postoperative chemotherapy and radiotherapy can be a promising factor.

REFERENCES

1. Amble FR, Olsen KD, Nascimento AG, Foote RL: Head and neck synovial cell sarcoma. *Otolaryngol Head Neck Surg* 107(5): 631-637, 1992.
2. Barkan GA, El-Naggar AK: Primary synovial sarcoma of the parotid gland. *Ann Diagn Pathol* 8(4): 233-236, 2004.
3. Barnes L: Tumors and tumor-like lesions of the soft tissues. In: Barnes L (ed.), *Surgical Pathology of the Head and Neck, Second Edition, Revised and Expanded* (in three volumes), Volume 2. New York, Basel: Marcel Dekker, Inc., 889-1048, 2001.
4. Bergh P, Meis-Kindblom JM, Gherlinzoni F, Berlin O, Bacchini P, Bertoni F, Gunterberg B, Kindblom LG: Synovial sarcoma: identification of low and high risk groups. *Cancer* 85(12): 2596-2607, 1999.
5. Carrillo R, el-Naggar AK, Rodriguez-Peralto JL, Batsakis JG: Synovial sarcoma of the tongue: case report and review of the literature. *J Oral Maxillofac Surg* 50(8): 904-906, 1992.
6. Cho KJ, Ro JY, Choi J, Choi SH, Nam SY, Kim SY: Mesenchymal neoplasms of the major salivary glands: clinicopathological features of 18 cases. *Eur Arch Otorhinolaryngol* 265 Suppl 1: S47-56, 2008.
7. Dei Tos AP, Dal Cin P, Sciot R, Furlanetto A, Da Mosto MC, Giannini C, Rinaldo A, Ferlito A: Synovial sarcoma of the larynx and hypopharynx. *Ann Otol Rhinol Laryngol* 107(12): 1080-1085, 1998.
8. Ellis GL, Auclair PL: Atlas of tumor pathology. Fourth Series Fascicle 9. Tumors of the salivary glands. Washington, DC: Armed Forces Institute of Pathology, 347-368, 2008.

9. Ellis GL, Auclair PL: Atlas of tumor pathology. Third Series Fascicle 17. Tumors of the salivary glands. Washington, DC: Armed Forces Institute of Pathology, 375–385, 1996.
10. Ferrari A, Casanova M, Massimino M, Luksch R, Cefalo G, Lombardi F, Galimberti S, Riganti G, Fossati-Bellani F: Synovial sarcoma: report of a series of 25 consecutive children from a single institution. *Med Pediatr Oncol* 32(1): 32-37, 1999.
11. Fisher C: Synovial sarcoma. *Ann Diagn Pathol* 2(6): 401-421, 1998.
12. Giaoui L, Salvan D, Casiraghi O, Mamelle G, Julieron M, Janot F, Leridant AM, Marandas P, Schwaab G, Luboinski B: Primary synovial sarcoma of head and neck. Materials of the Gustave Roussy Institute. Report of 13 cases. *Ann Otolaryngol Chir Cervicofac* 116(2): 71-77, 1999.
13. Goebel WM, High CJ, Kiviat J, Stoeckel DC: Anterior buccal mucosal mass. *Oral Surg Oral Med Oral Pathol Oral Radiol Endod* 97(6): 667-671, 2004.
14. Grayson W, Nayler SJ, Jena GP: Synovial sarcoma of the parotid gland. A case report with clinicopathological analysis and review of the literature. *S Afr J Surg* 36(1): 32-34; discussion 34-35, 1998.
15. Guzmán Patraca C, Ortíz Torres H, Garza Garza R: Synovial sarcoma of the oral cavity (foramen caecum) Report of a case and review of the literature. *Prensa Med Mex* 40(7-8): 215-220, 1975.
16. Harb WJ, Luna MA, Patel SR, Ballo MT, Roberts DB, Sturgis EM: Survival in patients with synovial sarcoma of the head and neck: association with tumor location, size, and extension. *Head Neck* 29(8): 731-740, 2007.

17. Hirsch RJ, Yousem DM, Loevner LA, Montone KT, Chalian AA, Hayden RE, Weinstein GS: Synovial sarcomas of the head and neck: MR findings. *AJR Am J Roentgenol* 169(4): 1185-1188, 1997.
18. Jay A, Hutchison I, Piper K, Farthing PM, Richards PS: Synovial sarcoma presenting as a parotid mass: case report and review of literature. *Head Neck* 30(12): 1654-1659, 2008.
19. Kartha SS, Bumpous JM: Synovial cell sarcoma: diagnosis, treatment, and outcomes. *Laryngoscope* 112(11): 1979-1982, 2002.
20. Ladenstein R, Treuner J, Koscielniak E, d'Oleire F, Keim M, Gadner H, Jürgens H, Niethammer D, Ritter J, Schmidt D: Synovial sarcoma of childhood and adolescence. Report of the German CWS-81 study. *Cancer* 71(11): 3647-3655, 1993.
21. Lee N, Shin E: Treatment outcomes for patients with synovial sarcoma of the head and neck. *Expert Rev Anticancer Ther* 8(3): 371-373, 2008.
22. Massarelli G, Tanda F, Salis B: Synovial sarcoma of the soft palate: report of a case. *Hum Pathol* 9(3): 341-345, 1978.
23. Meer S, Coleman H, Altini M: Oral synovial sarcoma: a report of 2 cases and a review of the literature. *Oral Surg Oral Med Oral Pathol Oral Radiol Endod* 96(3): 306-315, 2003.
24. Miloro M, Quinn PD, Stewart JC: Monophasic spindle cell synovial sarcoma of the head and neck: report of two cases a review of the literature. *J Oral Maxillofac Surg* 52(3): 309-313, 1994.
25. Shmookler BM, Enzinger FM, Brannon RB: Orofacial synovial sarcoma: a clinicopathologic study of 11 new cases and review of the literature. *Cancer* 50(2): 269-276, 1982.

26. Spillane AJ, A'Hern R, Judson IR, Fisher C, Thomas JM: Synovial sarcoma: a clinicopathologic, staging, and prognostic assessment. *J Clin Oncol* 18(22): 3794-3803, 2000.
27. Sun JJ, Rasgon BM, Wild TW, Hilsinger RL Jr: Synovial cell sarcoma of the maxillary sinus: a first reported case. *Otolaryngol Head Neck Surg* 129(5): 587-590, 2003.
28. Thompson RC Jr, Garg A, Goswitz J, Cheng EY, Clohisy DR, Dusenbery K: Synovial sarcoma. Large size predicts poor outcome. *Clin Orthop Relat Res* (373): 18-24, 2000.
29. Tilakaratne WM: Synovial sarcoma of the mandible. *J Oral Pathol Med* 35(1): 61-63, 2006.
30. Wang H, Zhang J, He X, Niu Y: Synovial sarcoma in the oral and maxillofacial region: report of 4 cases and review of the literature. *J Oral Maxillofac Surg* 66(1): 161-167, 2008.
31. Zernial O, Springer IN, Warnke P, Härle F, Risick C, Wiltfang J: Long-term recurrence rate of pleomorphic adenoma and postoperative facial nerve paresis (in parotid surgery). *J Craniomaxillofac Surg* 35(3): 189-192, 2007.

FIGURE LEGENDS

FIGURE (1) MRI axial image (native) showing multinodular well demarcated mass occupying right parotid gland

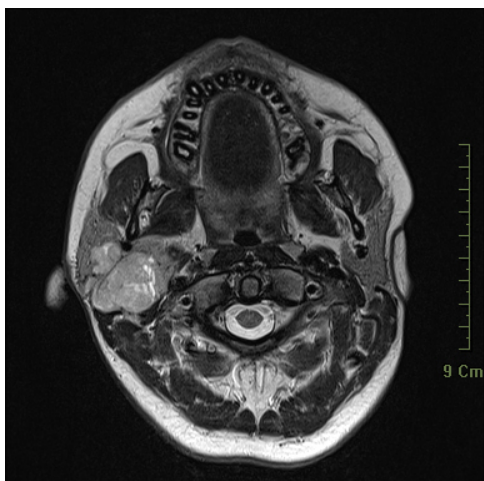


FIGURE (2) MRI coronal image (with contrast)

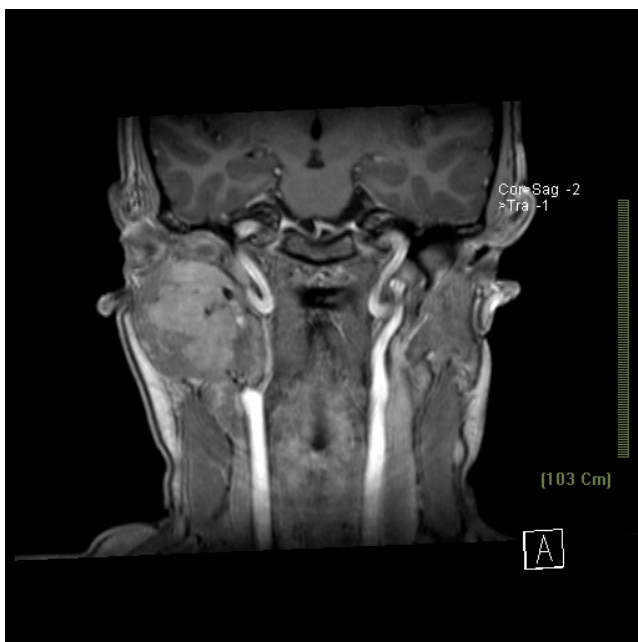

FIGURE (3) Surgical specimen including wide excision and total parotidectomy with selective neck dissection (levels II, III and Va)

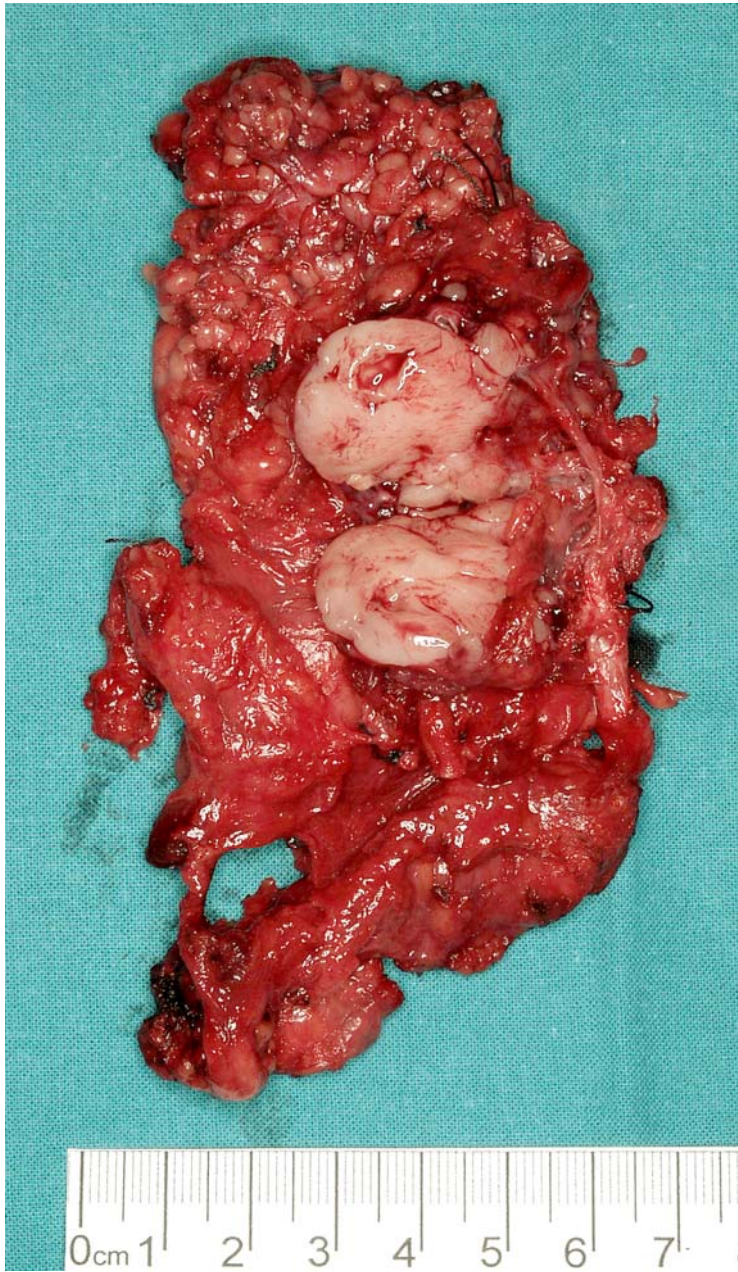


FIGURE (4) The tumour within parotid gland composed of highly cellular whirling fascicles of spindle-shaped cells with indistinct cytoplasm (haematoxylin-eosin stain, original magnification x 100)

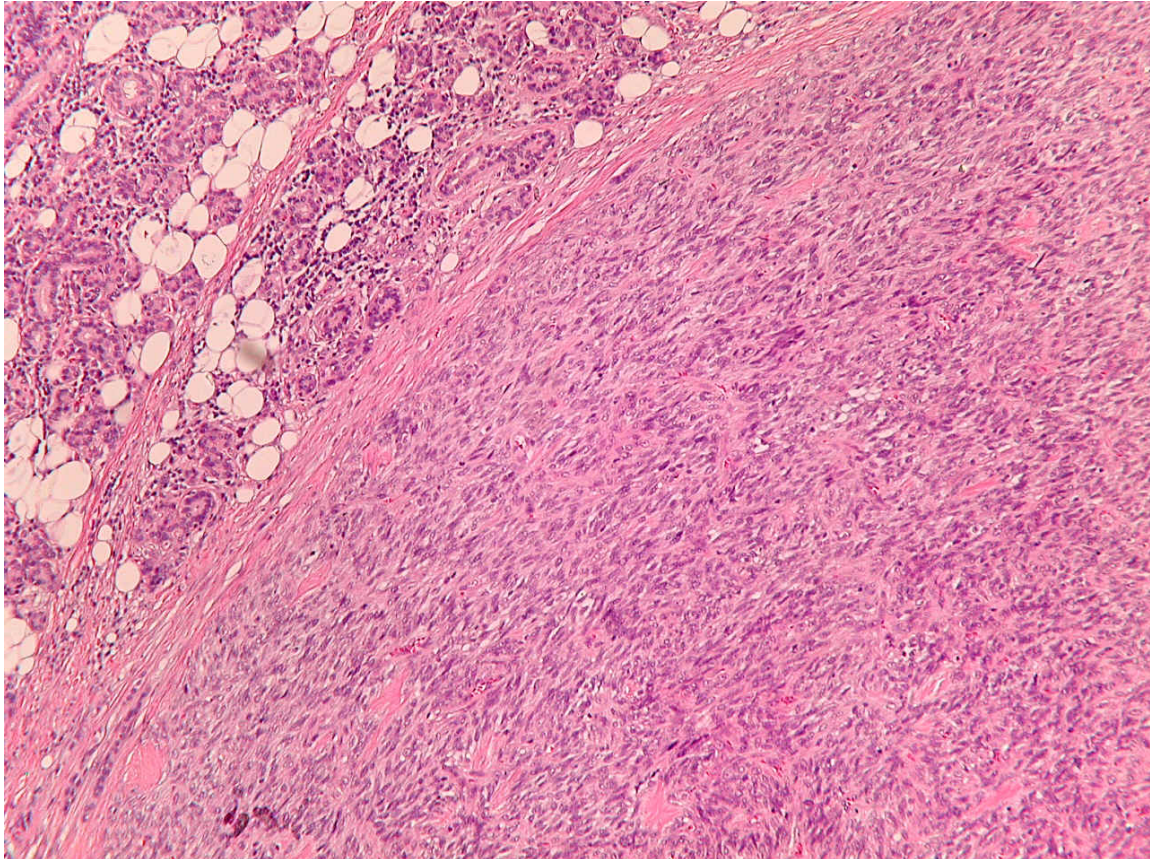


FIGURE (5) Diffusely and strongly positive bcl-2 immunostaining

