

# AXIN-1 protein expression and localization in glioblastoma

---

**Pećina-Šlaus, Nives; Nikuševa Martić, Tamara; Kokotović, Tomislav; Kušec, Vesna; Tomas, Davor; Hrašćan, Reno**

*Source / Izvornik:* **Collegium Antropologicum, 2011, 35, 101 - 106**

**Journal article, Published version**

**Rad u časopisu, Objavljena verzija rada (izdavačev PDF)**

*Permanent link / Trajna poveznica:* <https://um.nsk.hr/um:nbn:hr:105:938585>

*Rights / Prava:* [In copyright](#)/[Zaštićeno autorskim pravom.](#)

*Download date / Datum preuzimanja:* **2025-02-24**



*Repository / Repozitorij:*

[Dr Med - University of Zagreb School of Medicine  
Digital Repository](#)



# AXIN-1 Protein Expression and Localization in Glioblastoma

Nives Pećina-Šlaus<sup>1,2</sup>, Tamara Nikuševa Martić<sup>1,2</sup>, Tomislav Kokotović<sup>1</sup>, Vesna Kušec<sup>3</sup>, Davor Tomas<sup>4</sup> and Reno Hrašćan<sup>5</sup>

<sup>1</sup> University of Zagreb, Croatian Institute for Brain Research, Laboratory of Neurooncology, Zagreb, Croatia

<sup>2</sup> University of Zagreb, School of Medicine, Department of Biology, Zagreb, Croatia.

<sup>3</sup> University of Zagreb, Zagreb University Hospital Center, Clinical Institute of Laboratory Diagnosis, Zagreb, Croatia

<sup>4</sup> University of Zagreb, »Sestre milosrdnice« University Hospital, »Ljudevit Jurak« Department of Pathology, Zagreb, Croatia

<sup>5</sup> University of Zagreb, Faculty of Food Technology and Biotechnology, Department of Biochemical Engineering, Zagreb, Croatia

## ABSTRACT

*The etiology and pathogenesis of tumors of the central nervous system are still inadequately explained. In the present study the expression patterns of a critical molecular component of wnt signaling pathway – axin 1 was investigated in 42 patients with glioblastoma, the most aggressive form of glial tumors. Immunostaining and image analysis revealed the quantity and localization of the protein. Downregulation of this tumor suppressor expression was observed in 31% of tumors when compared to the levels of axin in healthy brain tissues. Axin was observed in the cytoplasm in 69% of glioblastoma samples, in 21.4% in both the cytoplasm and nucleus and 9.5% had expression solely in the nucleus. Mean values of relative axin's expression obtained by image analysis showed that the highest relative quantity of axin was measured when the protein was in the nucleus and the lowest relative quantity of axin when the protein was localized in the cytoplasm. Investigation on axin's existence at the subcellular level in glioblastomas suggests that axin's expression and spatial regulation is a dynamic process. Despite increasing knowledge on glioma biology and genetics, the prognostic tools for glioblastoma still need improvement. Our findings on expression of axin 1 may contribute to better understanding of glioblastoma molecular profile.*

**Key words:** axin, AXIN-1, glioblastomas, brain tumors, immunohistochemistry, Image analysis

## Introduction

Our study analyzed the brain tumor glioblastoma, with regard to the role of the tumor suppressor protein – axin 1, a critical component of wnt signaling pathway. AXIN-1 gene, located at 16p13.3, consists of 10 exons, encodes a 96 kDa protein, and is an inhibitor of wnt signaling. The so called classical canonical wnt pathway, mediated through beta-catenin, plays an essential role in development of many cancers<sup>1</sup> and lately this pathway has been implicated in brain tumorigenesis as well<sup>2-7</sup>. New knowledge on wnt signaling shows that wnt proteins and other components of the wnt signaling cascade, namely beta-catenin and axin, regulate critical developmental processes of normal CNS development<sup>8-11</sup>. Molecular components of wnt signaling perform important functions in CNS tissues.

Axin 1 is a key negative regulator of the Wnt signaling pathway<sup>12</sup>. It down-regulates beta-catenin, wnt pathway's main effector signaling molecule, by facilitating its phosphorylation by GSK3-beta<sup>1</sup>. It binds directly to APC (adenomatous polyposis coli), beta-catenin, GSK3-beta and dishevelled forming a so called »beta-catenin destruction complex« in which phosphorylated beta-catenin is targeted for quick ubiquitination and degradation in the 26S proteasome<sup>1,13</sup>. In response to wnt signaling, or under the circumstances of mutated axin or APC, beta-catenin is stabilized, accumulates in the cytoplasm and enters the nucleus, where it finds a partner, a member of the DNA binding protein family LEF/TCF. Together they stimulate the expression of target genes including c-myc, c-jun, fra-1 and cyclin D1<sup>14-16</sup>.

The etiology and pathogenesis of the tumors of the central nervous system are still inadequately explained. Our knowledge on genetic background of specific histopathological type of brain tumor still needs to be elucidated although great progress has been achieved along with the increasing advances in molecular genetics. Glioblastoma is the most aggressive form of glial brain tumor. The majority of glioblastomas arise without clinical or histological evidence of less malignant lesion and this kind of glioblastoma is categorized as primary or *de novo* glioblastoma. They manifest in older patients (mean age 55 years) after a short clinical history. In contrast, secondary glioblastomas develop more slowly by malignant progression from diffuse or anaplastic astrocytoma and they manifest in younger patients (mean age 40 years)<sup>17,18</sup>. At present specific genetic alterations found to be associated with glioblastoma are emerging<sup>19–21</sup>. Nevertheless, the genetic basis of primary as well as reoccurring glioblastoma is unclear, and much work is still required to determine the final list of genes involved.

In this study we offer a new candidate, axin 1, to fill in the puzzle of genetic basis of glioblastoma. Novel genes and molecular candidates involved in mechanisms of brain tumor formation will offer improvement in comprehension, diagnosis and treatment of this disease.

## Materials and Methods

### *Tumor specimen*

Samples of 42 glioblastomas were collected from the Department of Neurosurgery, and Department of Pathology Ljudevit Jurak at the »Sestre milosrdnice« University Hospital, Zagreb, Croatia. Using magnetic resonance imaging (MRI), tumor lesions were found in different cerebral regions (predominantly in the temporal and parietal region), with the surrounding zone of perifocal oedema. During surgery, the tumor was removed using a microneurosurgical technique. The patients had no family history of brain tumors, nor had they undergone chemotherapy or radiotherapy prior to surgery. All tumors were studied by pathologists and classified according to the WHO criteria. Majority as primary glioblastomas because the diagnosis of glioblastoma was made at the first biopsy, without clinical or histopathologic evidence of a less malignant precursor lesion, while five samples were classified as secondary since they developed from previously diagnosed tumors of lower malignancy grade.

There were 54.76% of male, and 45.24% of female patients. Patient age ranged from 31 to 80. The mean age at diagnosis was 59.9 years.

The local Ethical Committee approved our study, and patients gave their informed consent.

### *Immunohistochemistry*

Immunohistochemistry was performed in order to establish the level of axin protein expression. The samples were formalin-fixed, paraffin-embedded, and 4- $\mu$ m thick sections were placed on Capillary gap microscope slides

(DakoCytomation, Denmark). The sections were immunostained using the peroxidase-anti-peroxidase method. Deparaffinized and rehydrated sections were microwaved in Dako Target Retrieval Solution (Dako Corporation, USA) three times for 5 min at 800 W to unmask epitopes. To block endogenous peroxidase activity, we fixed the cells in methanol containing 3% H<sub>2</sub>O<sub>2</sub>. Non-specific binding was blocked by the application of normal mouse or rabbit serum for 30 min in a humid chamber. Slides were blotted and the primary antibodies at optimized dilutions of 1:100 for axin were applied for 30 min at room temperature<sup>22</sup>. The antibodies used were rabbit polyclonal anti-human AXIN1 antibody (Zymed Laboratories, San Francisco, CA, USA). After incubation, the slides were washed three times in phosphate-buffered saline/goat serum. Secondary LINK antibody was applied for 25 min. The washing was repeated, and the slides were incubated with streptavidin horseradish peroxidase for another 25 min. All chemicals were from DakoCytomation. Negative controls were samples that underwent same staining procedure with the exclusion of the primary antibodies. Cortex of the frontal part of the normal brain, as well as normal skin, served as positive controls. The analysis of the labeling was performed by two independent observers, pathologists experts in the field blinded to the conditions of the experiment, on an Olympus BH-2 microscope. Weak expression was labeled as +, moderate expression as ++, and strong expression as +++.

### *Image analysis*

Protein expression was then quantified with the aid of Image Analyzer. For each sample, the intensity of staining in a well-defined area was evaluated using image-analyzing software manufactured by Vamstec (Zagreb, Croatia). The area covered by microscopic assessment was 200,000 square micrometers (200,000  $\mu$ m<sup>2</sup>), i.e. approximately area 0.447x0.447 mm, with magnification x100. The chosen area was located in the central part of the excised tissue containing most characteristics of malignant tissue. All density measurements were »calibrated« against its slide characteristics, i.e. transparency. Density was depicted as the intensity of light retained by tissue or tissue transparency and expressed in grey scale pixels ranging from 0 to 222 for axin protein, zero representing no transmission of light and 222 total transparency. Density in the area of tumor location was compared with density of the normal brain tissue sections.

### *Statistical methods*

All individuals were analyzed for the following features: PHD status, sex, age, AXIN1 protein expression and localization. The Kolmogorov-Smirnov statistics tests the hypothesis that the data are normally distributed. A low significant value (less than 0.05) indicates that the distribution of the data differs significantly from a normal distribution. If there are less than 50 cases the Shapiro-Wilk test is also used with the same provision. In our case the significance was  $p=0.221$  indicating that the



distribution was sufficiently normal to use the Pearson's correlation test.

Differences in the frequencies of the analyzed features were tested with the T-student test and Pearson's correlation when appropriate.

## Results

From 42 glioblastoma samples 88.1% appeared to have developed *de novo*, while five samples developed from previously diagnosed tumors of lower malignancy grade, one from diffuse astrocytoma (GII), one from anaplastic astrocytoma (GIII), two from oligoastrocytoma and one from oligodendroglioma. The histopathological diagnosis of glioblastoma (malignancy grade IV) was based on recognition of poorly differentiated astrocytic tumor cells with brisk mytotic activity and marked nuclear atypia. Differentiated elements were intermingled with bizarre multinucleated tumor giant cells. Prominent microvascular hyperplasia, in which proliferating blood vessels come to be lined by cells heaped up in disorderly fashion and transformed into glomeruloid or solid tufts, and necrosis were also recognized as diagnostic features.

The examination of axin's expression levels demonstrated samples with lower but also samples with higher expression than observed in normal brain tissue. The expression of axin in the sections of normal brain white matter, in which we analyzed microglia (astocytes and oligodendrocytes), was observed in the cytoplasm and labeled as moderate expression ++. Of 42 glioblastoma 31% had downregulation of this tumor suppressor gene expression when compared to the levels of axin in healthy brain tissues. Part of our investigated sample showed lower levels of axin expression, but, on the other hand, in 38.1% of the sample (16/42) higher levels were observed. The expression levels were evenly distributed in both females and males, and there was no correlation to any age group.

Immunostaining also revealed localization of axin proteins (Figure 1). The majority of glioblastomas (69.04% of samples) had axin localized in the cytoplasm. Axin was observed in both the cytoplasm and nucleus in 21.42% of glioblastoma samples and 9.52% of glioblastomas had axin expressed solely in the nucleus (Figure 2 A, B).

The pathohistological grade of the glioblastomas analyzed, the results of staining intensities and the localizations of proteins are shown in Table 1.

The obtained results were then evaluated by image analysis as staining density, i.e. light permeability (LP). Density was depicted as the intensity of light retained by tissue or tissue transparency, and expressed in grey scale pixels and it is reversely proportional to the protein quantities. The results of immunostaining obtained by three independent observers and by image analysis were compatible and the correlation was very strong at the  $p=0.003$  level.

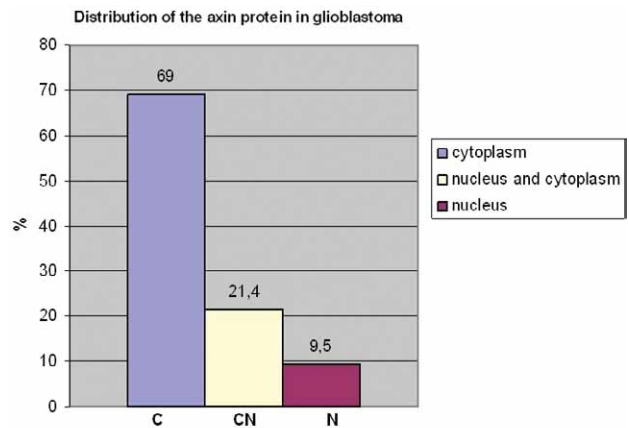


Fig. 1. Axin protein distribution in glioblastomas according to localization.

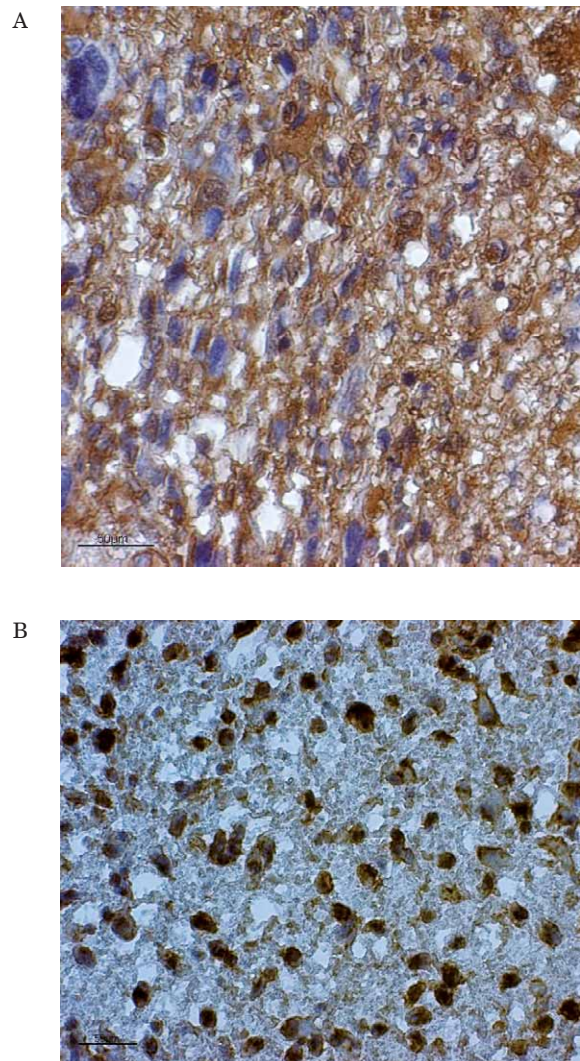


Fig. 2. Glioblastoma samples immunohistochemically stained for protein expression of axin. (A) Cytoplasmic localization of axin and (B) nuclear localization of axin.

**TABLE 1**  
PATHOHISTOLOGICAL GRADE, EXPRESSION LEVELS AND LOCALIZATIONS OF AXIN PROTEIN

Patient no.	Diagnosis	Axin protein	
		Localiza-tion	Expres-sion
1 <sup>1</sup>	Glioblastoma (IV)	C	+
2	Glioblastoma (IV)	N	+++
3	Glioblastoma (IV)	C	++
4	Glioblastoma (IV)	CN	+++
5	Glioblastoma (IV)	C	++
6	Glioblastoma (IV)	CN	+++
7	Glioblastoma (IV)	C	+++
8	Glioblastoma (IV)	CN	+++
9	Glioblastoma (IV)	C	+
10	Glioblastoma (IV)	C	+++
11 <sup>2</sup>	Glioblastoma (IV)	C	++
12 <sup>2</sup>	Glioblastoma (IV)	C	+++
13	Glioblastoma (IV)	C	+++
14	Glioblastoma (IV)	N	+++
15	Glioblastoma (IV)	C	+++
16	Glioblastoma (IV)	CN	++
17	Glioblastoma (IV)	C	++
18	Glioblastoma (IV)	C	+
19 <sup>3</sup>	Glioblastoma (IV)	C	+
20	Glioblastoma (IV)	CN	++
21	Glioblastoma (IV)	C	+
22	Glioblastoma (IV)	C	+++
23	Glioblastoma (IV)	C	++
24	Glioblastoma (IV)	C	++
25	Glioblastoma (IV)	C	+
26 <sup>4</sup>	Glioblastoma (IV)	C	+++
27	Glioblastoma (IV)	N	++
28	Glioblastoma (IV)	C	++
29	Glioblastoma (IV)	CN	+++
30	Glioblastoma (IV)	C	++
31	Glioblastoma (IV)	C	+
32	Glioblastoma (IV)	C	+++
33	Glioblastoma (IV)	CN	+
34	Glioblastoma (IV)	C	+
35	Glioblastoma (IV)	C	+
36	Glioblastoma (IV)	C	+
37	Glioblastoma (IV)	CN	++
38	Glioblastoma (IV)	C	+
39	Glioblastoma (IV)	C	+++
40	Glioblastoma (IV)	CN	+++
41	Glioblastoma (IV)	N	++
42	Glioblastoma (IV)	C	+

+ = weak expression, ++ = moderate expression, +++ = strong expression; M = membranous; C= cytoplasmic; N = nuclear localization.; <sup>1</sup>from anaplastic astrocytoma (GIII); <sup>2</sup>from oligoastrocytoma; <sup>3</sup>from oligodendroglioma; <sup>4</sup>from diffuse astrocytoma (GII)

**TABLE 2**  
COMPARISON OF RELATIVE VALUES FOR AXIN TO CELLULAR LOCALIZATION

Cellular localization	Axinrela*
Cytoplasm	172.3
Nucleus and cytoplasm	164.1
Nucleus	142.0

\* Axinrela= axinpro/axinnv x100; Axinrela represented relative increase or decrease of LP in tumor tissue for axin; axinpro denoted measured LP in tumor tissue; axinnv mean values of LP for axin in normal tissue

Mean values for light permeabilities for axin in normal brain tissue was  $63 \pm 15$ . These numbers enabled us to calculate relative quantities of axin proteins in tumor tissue. We introduced variable relative increase of protein expression in tumor tissue defined with following equations:  $Axinrela = axinpro/axinnv \times 100$ . Axinrela represented relative increase or decrease of LP in tumor tissue for axin; axinpro denoted measured LP in tumor tissue; *axinnv* mean values of LP for axin in normal tissue.

We observed that higher relative levels of axin protein are much more frequent when the distribution of axin was in the nucleus. Also, when relative levels of axin are low the protein is rarely distributed in the nucleus; it is than mainly located in the cytoplasm. This trend, although not statistically relevant, is also reflected on the mean values of relative axin quantities in relation to percent of subcellular axin's localization. Mean values of relative axin's expression obtained by image analysis showed that the highest relative quantity of axin was measured when the protein was in the nucleus and the lowest relative quantity of axin when the protein was localized in the cytoplasm (Table 2). In our analyzed sample we did not observe axin 1 protein expression differences between *de novo* and secondary glioblastomas.

## Discussion and Conclusion

The mechanisms of brain tumor initiation and progression have not yet been completely investigated and elucidated. As with other tumors, the formation of brain tumors is the result of multiple consecutive genetic changes that represent a critical factor in tumor evolution. No consistent genetic abnormalities have been detected that would indicate the genetic profile of glioblastoma<sup>20,23</sup>. Histopathologically, an unambiguous distinction of glioma subtypes has remained elusive, but they clearly evolve through different genetic pathways. It also remains to be shown whether these subtypes differ significantly with respect to the molecular genetic alterations underlying the oncogenesis and progression of glioblastoma. In case of glioblastomas, little is known of genetic alterations of molecules which contribute to activating Wnt signaling pathways. Processes that include cellular adhesion, synaptic rearrangements, embryonic cell patterning, proliferation, differentiation, and apoptosis require the expression of molecular components of the wnt pathway.

Another negative regulator of wnt signaling, APC, shows high expression in the CNS<sup>24</sup>, and is involved in initiation of neuronal differentiation. With this in mind, we investigated a new candidate gene, tumor suppressor gene axin 1, in a set of 42 glioblastomas.

Our first result on downregulation of this tumor suppressor gene expression in 31% of glioblastoma samples may indicate its involvement in tumorigenesis. When wnt signaling functions properly upregulation of axin 1 leads to the phosphorylation and degradation of beta-catenin<sup>13,14</sup>. In the subset of samples we analyzed this degradation might be impaired because of low axin's levels which would lead to beta-catenin's accumulation, stabilization and activation of target genes.

Our investigated sample did not show only lower levels of axin protein expression, but in 38.1% higher levels were observed. It has been reported that physiological concentrations of axin is low in *Xenopus* egg cells<sup>25</sup>. We may speculate that the increase of axin which we observed may once again be the result of deregulation of wnt signaling.

The subcellular location of axin is not well defined in the literature. There are reports on axins levels and locations in *Xenopus* eggs<sup>25</sup>. It has also been shown that it is located in cytoplasmic puncta<sup>26</sup> in living mammalian cells. Wang et al.<sup>27</sup> report that axin 1 is highly co-localized with beta-catenin in the cytoplasm of human cumulus cells and that this localization denotes intact wnt signaling. Our work shows for the first time the subcellular location of axin in normal brain white matter and glioblastoma tissue. The majority of glioblastomas (69.04%) had axin localized in the cytoplasm which is compatible to other reports in normal tissues. Nevertheless, a not insubstantial percent of samples had axin localized in the nucleus.

Our results on axin's different distribution regarding cellular localization are not unusual. Distribution of axin was reported previously by Anderson et al.<sup>28</sup> Although this group was studying distribution of proteins involved in Wnt signaling in neoplastic colon, the obtained data on the subcellular level are very similar to ours.

It is well known that axin is a scaffold protein that can shuttle between the cytoplasm and the nucleus.

Nucleo-cytoplasmatic shuttling under normal circumstances suggests existence of possible »salvage pathway« that would be activated by axin translocation to the nucleus in order to reduce beta-catenin' oncogenic activity by exporting nuclear beta-catenin and degrading it in the cytoplasm. Axin translocation to the nucleus and its interaction with beta-catenin is required for axin induced cytoplasmic shifting of beta-catenin<sup>12</sup>.

The product of the APC gene has a critical function in the turnover of beta-catenin on the axin 1 scaffold protein, and lately it was shown<sup>16</sup> that axin 1 activity includes facilitating c-myc degradation, as well. Our previous results on changes of APC tumor suppressor gene<sup>6,29</sup> revealed the presence of gross deletions of APC gene in 60% of glioblastomas and 20% of astrocytomas. One oligoastrocytoma and one medulloblastoma also showed LOH of APC. Moreover, we also found two glioblastomas with heteroduplexes indicating potential mutations in beta-catenin's exon 3.

Interesting results were obtained by image analysis on axins' levels and locations. Mean values of relative axin's expression obtained by image analysis showed that the highest relative quantity of axin was measured when the protein was in the nucleus and the lowest relative quantity of axin when the protein was localized in the cytoplasm. This finding is also indicative of axin's nucleo-cytoplasmatic shuttling and is in accordance to literature sources on low levels of cytoplasmic axin in normal physiological circumstances. Our study explored axin's existence at the subcellular level in glioblastomas and it suggests that axin's expression and spatial regulation is a dynamic process.

In conclusion we believe that wnt signaling is implicated in development of gliomas. Our findings on changes of protein expression of molecular component of wnt signaling - axin 1, may contribute to better understanding of human glial tumor molecular profile.

## Acknowledgements

This work was supported by grant 108-1081870-1905 from Ministry of Science Sports and Education, Republic of Croatia.

## REFERENCES

- GORDON MD, NUSSE R, *J Biol Chem*, 281 (2006) 22429. — 2. KOCH A, WAHA A, TONN JC, SÖRENSEN N, BERTHOLD F, WOLTER M, REIFENBERGER J, HARTMANN W, FRIEDL W, REIFENBERGER G, WIESTLER OD, PIETSCH T, *Int J Cancer*, 93 (2001) 445. — 3. HOWNG SL, WU CH, CHENG TS, SY WD, LIN PC, WANG C, HONG YR, *Cancer Lett*, 183 (2002) 95. — 4. CARICASOLE A, BAKKER A, COPANI A, NICOLETTI F, GAVIRAGHI G, TERSTAPPEN GC, *Biosci Rep*, 25 (2005) 309. — 5. ELLISON DW, ONILUDE OE, LINDSEY JC, LUSHER ME, WESTON CL, TAYLOR RE, PEARSON AD, CLIFFORD SC, *J Clin Oncol*, 23 (2005) 7951. — 6. NIKUŠEVA MARTIĆ T, BEROŠ V, PEĆINA-ŠLAUS N, PEĆINA HI, BULIĆ-JAKUŠ F, *Pathol Res Pract*, 203 (2007) 779. — 7. PEĆINA-ŠLAUS N, NIKUŠEVA MARTIĆ T, TOMAS D, BEROŠ V, ZELJKO M, ČUPIĆ H, *J Neurooncol*, 87 (2008) 63. — 8. PATAPOUTIAN A, REICHARDT LF, *Curr Opin Neurobiol*, 10 (2000) 392. — 9. YU X, MALENKA RC, *Nature Neurosci*, 6 (2003) 1169. — 10. LIE DC, COLAMARINO SA, SONG HJ, DESIRÉ L, MIRA H, CONSIGLIO A, LEIN ES, JESSBERGER S, LANSFORD H, DEARIE AR, GAGE FH, *Nature*, 437 (2005) 1370. — 11. LI F, CHONG ZZ, MAIESE K, *Histol Histopathol*, 21 (2006) 103. — 12. CONG F, VARMUS H, *Proc Natl Acad Sci, U S A* 101 (2004) 2882. — 13. KIKUCHI A, *Cytokine Growth Factor Rev*, 10 (1999) 255. — 14. LUO W, LIN SC, *Neurosignals*, 13 (2004) 99. — 15. POLAKIS P, *Curr Opin Genet Dev*, 17 (2007) 45. — 16. ARNOLD HK, ZHANG X, DANIEL CJ, TIBBITTS D, ESCAMILA-POWERS J, FARRELL A, TOKARZ S, MORGAN C, SEARS RC, EMBO J, 28 (2009) 500. — 17. ICHIMURA K, OHGAKI H, KLEIHUES P, COLLINS VP, *J Neurooncol*, 70 (2004) 137. — 18. LOUIS DN, OHGAKI H, WIESTLER OD, CAVENEE WK, BURGER PC, JOUVET A, SCHEITHAUER BW, KLEIHUES P, *Acta Neuropathol*, 114 (2007) 97. — 19. HOLLAND E, *Nat Rev Genet*, 2 (2001) 120. — 20. COLLINS VP, *J Neurol Neurosurg Psychiatry*, 75 Suppl 2 (2004) 2. — 21. FUKUSHIMA T, FAVERAUX A, HUANG H, SHIMIZU T, YONEKAWA Y, NAKAZATO Y, OHGAKI H, *J Neuropathol Exp Neurol*, 65 (2006) 12. — 22. PEĆINA-ŠLAUS N, ŽIGMUND M, KUŠEC V, NIKUŠE-



VA MARTIĆ T, ČAČIĆ M, ŠLAUS M, J Cutan Pathol, 34 (2007) 239. — 23. OHGAKI H, KLEIHUES P, Am J Pathol, 170 (2007) 1445. — 24. BRAKEMAN JS, GU SH, WANG XB, DOLIN G, BARABAN JM, Neuroscience, 91 (1999) 661. — 25. LEE E, SALIC A, KRÜGER R, HEINRICH R, KIRSCHNER MW, PLoS Biol E1, (2003) 116. — 26. FAUX MC, COATES JL, CATIMEL B, CODY S, CLAYTON AHA., LAYTON MJ, BURGESS AW, Oncogene, 27 (2008) 5808. — 27. WANG HX, TEKPETEY FR, KID-

DER GM, Mol Hum Reprod, 15 (2009) 11. — 28. ANDERSON CB, NEUFELD KL, WHITE RL, Proc Natl Acad Sci USA, 99 (2002) 8683. — 29. PEĆINA-ŠLAUS N, BEROŠ V, NIKUŠEVA MARTIĆ T, BULIĆ-JAKUŠ F, Genomic Instability of the APC Gene Found in Glioblastoma. In: GLAS-COW EJ (ed) New Research on Genomic Instability (Novascience Publishers, Inc New York, 2007).

*N. Pećina-Šlaus*

*University of Zagreb, School of Medicine, Croatian Institute for Brain Research, Laboratory of Neurooncology, Šalata 12, 10000 Zagreb, Croatia  
e-mail: nina@mef.hr*

## **IZRAŽENOST I SMJEŠTAJ PROTEINA AKSINA U GLIOBLASTOMIMA**

### **SAŽETAK**

Etiologija i patogeneza tumora središnjeg živčanog sustava još uvijek je nedovoljno razjašnjena. U ovoj studiji istraživani su obrasci ekspresije proteina aksina, izuzetno važne molekularne komponente signalnog puta Wnt, u 42 uzorka glioblastoma čovjeka. Imunohistokemijskom metodom i image analizom utvrđena je jačina ekspresije i lokalizacija proteina u stanicama. Smanjena ekspresija ovog tumor supresorskog proteina uočena je u 31% analiziranih tumora usporedbom s razinom ekspresije aksina u normalnom tkivu mozga. U 69% glioblastoma aksin je pronađen u citoplazmi, u 21,4% u jezgri i citoplazmi, dok je u 9,5% glioblastoma lokalizacija bila isključivo u jezgrama. Srednje vrijednosti relativne ekspresije proteina aksina dobivene image analizom pokazuju da je najveća relativna količina aksina izmjerena kada je protein lokaliziran u jezgri, a najmanja relativna količina aksina kada je lokaliziran u citoplazmi. Rezultati istraživanja aksina u glioblastomima na unutarstaničnoj razini pokazuju da je izraženost aksina i njegova prostorna regulacija vrlo dinamičan proces. Unatoč produbljivanju spoznaja o biologiji i genetici glijalnih tumora, saznanja o prognostičkim parametrima za glioblastom još uvijek nisu dostatna. Naši rezultati o razini izraženosti proteina aksina zasigurno će doprinijeti boljem razumijevanju molekularnog profila glioblastoma, te ponuditi potencijalne prognostičke značajke.