

# Symptomatic capillary telangiectasia of the pons and intracerebral developmental venous anomaly - a rare association

---

Šarac, Helena; Telarović, Srđana; Markeljević, Jasenka; Perić, Berislav; Pavliša, Goran; Radoš, Marko

Source / Izvornik: *Collegium Antropologicum*, 2011, 35, 333 - 338

Journal article, Published version

Rad u časopisu, Objavljena verzija rada (izdavačev PDF)

Permanent link / Trajna poveznica: <https://urn.nsk.hr/urn:nbn:hr:105:894773>

Rights / Prava: [In copyright](#) / [Zaštićeno autorskim pravom](#).

Download date / Datum preuzimanja: **2024-08-26**



Repository / Repozitorij:

[Dr Med - University of Zagreb School of Medicine  
Digital Repository](#)



# Symptomatic Capillary Telangiectasia of the Pons and Intracerebral Developmental Venous Anomaly – A Rare Association

Helena Šarac<sup>1</sup>, Srđana Telarović<sup>2</sup>, Jasenka Markeljević<sup>3</sup>, Berislav Perić<sup>4</sup>, Goran Pavliša<sup>5</sup> and Marko Radoš<sup>5</sup>

<sup>1</sup> University of Zagreb, School of Medicine, Zagreb University of Hospital Centre, Department of Neurology and Croatian Institute for Brain Research, »Neuron« Diagnostic Centre, Zagreb, Croatia

<sup>2</sup> University of Zagreb, School of Medicine, Zagreb University Hospital Centre, Department of Neurology, Zagreb, Croatia

<sup>3</sup> University of Zagreb, School of Medicine, Zagreb University Hospital Centre, Department of Internal Medicine, Zagreb, Croatia

<sup>4</sup> University of Zagreb, School of Medicine, Dubrava University Hospital, Department of Maxillofacial Surgery, Zagreb, Croatia

<sup>5</sup> University of Zagreb, School of Medicine, Croatian Institute for Brain Research, Department of Radiology, »Neuron« Diagnostic Centre, Zagreb, Croatia

## ABSTRACT

*Various combinations of vascular malformations of the brain in one lesion have been reported, while others seem to be very rare. In this report, the authors discuss the case of a coexistence of an capillary telangiectasia of the pons and intracerebral venous anomaly. To our knowledge, this is the first report of coexistence of a capillary telangiectasia of the pons and intracerebral venous anomaly apparted from each other. These discrete vascular malformations of the brain raise attention on possible interrelations in the pathogenesis of these entities. We report a case of pontine capillary telangiectasia and intracerebral venous anomaly in a 42-year-old woman with a right side facial palsy. Hight field magnetic resonance imaging suggested presence of a capillary telangiectasia of the pons. Another lesion in the left frontal gyrus was attributable to the venous anomaly. Along with neuroradiological findings, results of the somatosensor evoked potentials, brain stem auditory potentials, laboratory analysis including blood, cerebrospinal fluid and urine investigation are demonstrated. Awareness of the magnetic resonance imaging finding of the capillary telangiectasias and of the venous anomalies may help in defining clinical correlates of this vascular malformations, while the follow up of these malformations might help to asses risk of vascular rupture. We and others previously selects capillary telangiectasia and venous anomaly in two discrete entities. Coexistence of these malformations in the brain apparted from each other appear to be very rare and raise attention on possible interactions in their natural history and pathogenesis.*

**Key words:** capillary telangiectasia, venous malformation, pons, magnetic resonance imaging

## Introduction

Vascular malformations of the central nervous system (CNS) fit into the following categories, in order of decreasing prevalence: developmental venous anomalies (DVA), arteriovenous malformations (AVM), capillary telangiectasias (CT), and cavernous malformation (CM)<sup>1</sup>. As opposed to the more frequent associations of the CT and CM<sup>2,3</sup>, and VM and CM<sup>4</sup>, the association of CT and VM has been reported only twice before exclusively in the posterior fossa<sup>5</sup> and ones in a supratentorial paraventricular location<sup>6</sup>. To our knowledge, the coexistence

of the symptomatic pontine CT and supratentorial DVA in two separated lesions has not been previously reported.

## Case Report

### *Clinical evaluation*

A 42-year-old female presented with a right Bell's palsy which suddenly appeared after stress situation.

Neurological examination detected complete facial palsy of the right side (VI<sup>th</sup> grade by using the House-Brackmann grading scale)<sup>7</sup>, right side brisk deep tendon reflexes and atypical plantar response. Routine blood and cerebrospinal fluid (CSF) laboratory processing were unremarkable. Noncontrast computerized tomography (CT) revealed no appreciable pathologic finding. She was treated with prednisone but the incomplete facial palsy resolution has observed up to grade III according to the House-Brackmann scale in the next two weeks. In the following 20 months, right sided hemifacial spasm has appeared, Bell's palsy remains discrete (III<sup>th</sup> grade). Initial cranial MRI (1.5 T Siemens, Zagreb) in T1-weighted scans has not detected any lesion, but after intravenous administration of gadolinium in T1-weighted MRI, one small dot hyperintensity area has been detected, while T2-scans showed hypointense area the most suggestive to cavernoma. She underwent extensive control examinations three months later. Neurological examination verified discrete residual right sided facial weakness and hemifacial spasm unchanged. Her hearing and taste were normal. Routine laboratory blood results, anti-ANA, anti-DNA, anti-ENA antibodies and coagulation tests were normal. Somatosensory evoked potentials (SSEP) and brain stem auditory evoked potentials (BAEP) showed normal results. Three months later, she underwent subsequent MRI scanning.

### Brain Imaging Studies

The follow up MR investigations were conducted with 2.0 T MR imager (GE Medical Systems) at the Diagnostic Center »Neuron«, Croatian Institute for Brain Research, School of Medicine, University of Zagreb. A brain MRI protocol included the following: a) T1-weighted spin-echo (SE) axial and sagittal image (650/12 with one signal acquired, field of view, 23 cm, imaging matrix, 106

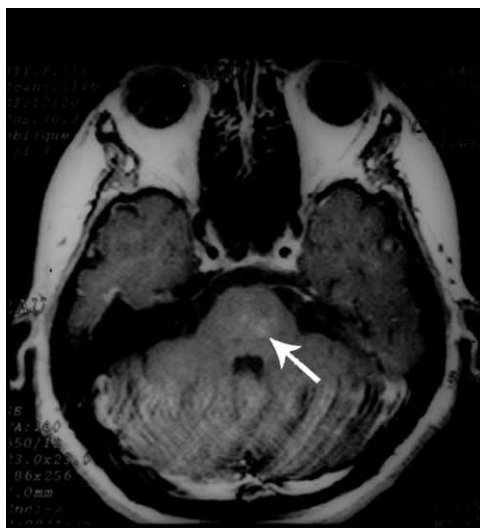

Fig. 1. Unruptured capillary telangiectasia of the brain stem. Axial T1 weighted (650/12 with one signal acquired, field of view 23 cm, imaging matrix 106 x 256, section thickness 5 mm), demonstrates hyperintensity (arrow) in the lower left side of the pons.

x 256, section thickness, 5 mm and b) T2\* axial image (750/15, field of view 19 x 23 cm, imaging matrix 192 x 256, section thickness, 5 mm).

MR images were interpreted by two neuroradiologist (G.P. and M.R.) for the following signs: a) Hyperintensity dot in the pons on axial and sagittal T1 weighted images, b) Hypointensity dot in the pons on axial gradient echo T2\* weighted sequences.

MRI images features in the axial (Figure 1) and sagittal (Figure 2) T1 weighted images detected hyperintensity dot in dorsal lower left side of the pons and additionally smaller one in the middle pons consistent with the hypointensity dots visible in gradient echo T2\* weighted sequence (Figure 3). An iron stain highlighted focal area of hemosiderin deposition and reactive astrogliosis in addition to some recent microhemorrhages. Above all, developmental venous anomaly was seen in inferior left side frontal gyrus in axial T1 weighted images (Figure 4). The both vascular anomalies enhanced after contrast administration. Premature cortical brain atrophy was found.

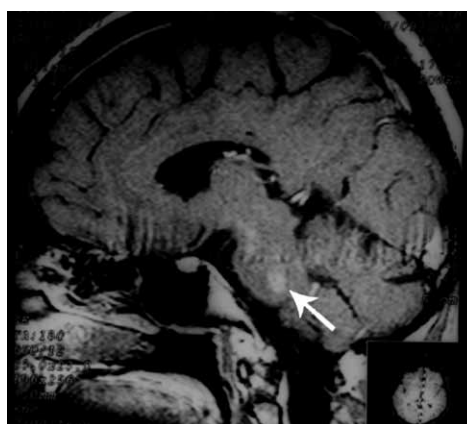


Fig. 2. Sagittal T1 weighted (650/12 with one signal acquired, field of view, 23 cm, imaging matrix, 106 x 256, section thickness, 5 mm), shows hyperintensity (arrow) in the dorsal lower part of the pons.

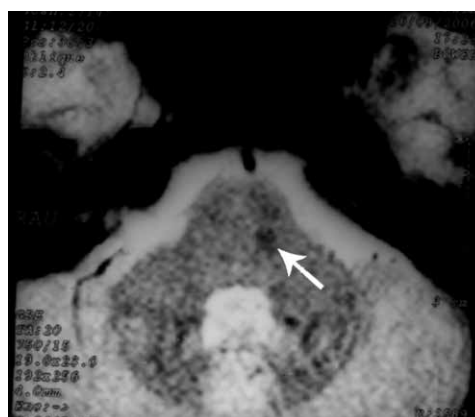


Fig. 3. Axial T2\* weighted image (750/15, field of view 19 x 23 cm, imaging matrix 192 x 256, section thickness 5 mm) demonstrates hypointensity dots in the left side of the pons.

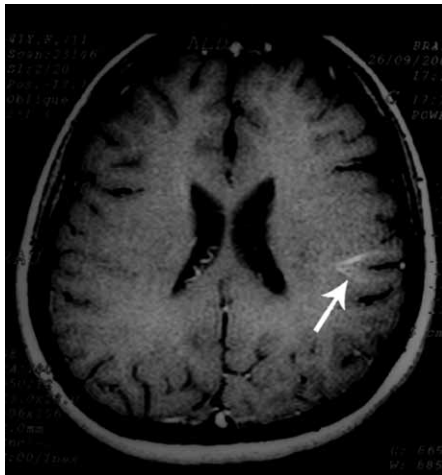


Fig. 4. Axial T1 weighted image (650/12 with one signal acquired, field of view, 23 cm, imaging matrix, 106 x 256, section thickness, 5 mm) shows typical developmental venous anomaly of the frontal lobe. Note umbrella-like enlarged deep white matter veins (arrow) converging on a enlarged deep »collector« vein.

The presence of venous malformation has not been documented by digital subtraction angiography (DSA), as the patient refused her consent. Retrospectively, MRI finding of pontine lesions was consistent with the clinical features of Bell's palsy and hemifacial spasm due to a MRI evidence of recent microhemorrhage. A neurological signs as hemifacial spasm persist up to date. A last MRI control performed three years later, showed that both lesions had not changed in size or shape.

## Discussion

In the case we present, the coexistence of CT and DVA of the brain apart from each other has been demonstrated. This association seems to be extremely rare, and to our knowledge, this study is the first attempt to demonstrate MRI findings, natural history, possible pathogenetic factors, and therapeutic opportunities of the association of an pontine CT and intracerebral DVA. Although mixed vascular malformations have been identified and classified as a specific subset of vascular malformations, this association have a less known pathogenesis, natural history and treatment<sup>8</sup>. The pathophysiology of discrete cerebrovascular malformations is not clearly understood and it is still unknown whether these malformations represent spectra of one nosological entity with unique pathogenesis, or whether their pathogenesis is a result of the various separate vascular subtypes.

Most vascular malformations are believed to have a congenital origin<sup>9,10</sup>. In the 12-weeks embryo venous collectors evolved to the final patterns of the superficial and deep venous drainage<sup>11</sup>. An arrest at this embryological stage of venous development may be responsible for venous malformations<sup>12</sup>.

Capillary telangiectasia may represent a failure of capillary involution during critical phase of development<sup>8</sup>.

However, cerebral CT has also been reported to be acquired by radiation<sup>13</sup>. Cavernous malformations communicate freely with the venous circulation but present pressures is higher than venous pressure<sup>14</sup>. Furthermore, neogenesis of multiple cryptic vascular malformations has been report to occur after the resection of an occult AVM and to be promoted by a venous outflow obstruction<sup>15</sup>. In contrast to this, some authors preferable accepted that all cerebrovascular malformations can be acquired or grow during extrauterine life due to reactive angiogenesis caused by hemodynamic disturbance or vessel fragility<sup>6</sup>. Russel in 1931 suggested that cavernous malformation might be a late stage of the capillary telangiectasia progression<sup>16</sup>. Venous hypertension caused by local stenosis of a draining vein could be dynamic factor associated with induction of an associated vascular malformation, whereby developmental venous anomaly represents primary lesion<sup>14</sup>.

Cerebral CT are typically small vascular malformations which appeared frequently in autopsies 0.15%<sup>1</sup> but they are mostly clinically insignificant. Most cerebral CT are placed in pons and usually found incidentally with specific MRI appearance and negative angiographic findings. The frequency of brain stem CT is unknown. In 1968 McCormick et al. described 27 pontine CT<sup>17</sup> whereas none of these 27 cases were associated with significant haemorrhage. In 1996 Barr et al. described 12 cases of capillary telangiectasias of the pons<sup>18</sup>. In 1997 Lee et al. reported the clinical and MRI features of 15 pontine capillary telangiectasias<sup>19</sup>. Twenty cases from the English literature<sup>18–25</sup> and three new cases have been summarized by Scaglione et al.<sup>20</sup> according to the location and presenting symptoms compatible with lesion and summarized in table 1 which is adopted from Scaglione et al. and our current patient is added. Scaglione et al. has reported 5 more cases including 3 symptomatic cases over a period of 5 years<sup>20</sup>. Cerebral CT are small, dilated capillaries with intervening brain and a dilated efferent system, usually located in pons. Cerebral CT are usually asymptomatic and are frequently associated with cerebral CM. They are diagnosed with MRI, but there is no therapy. Nonhereditary CT are usually solitary, but could exist with CM. The association of CT and DVA is very rare condition and only two reports exist describing both lesions exclusively in the posterior fossa<sup>2,5</sup> and one report in the supratentorial paraventricular location in the mixed lesion<sup>6</sup>. Cerebral CT rarely could be presented with symptomatic, microhaemorrhagic rupture, while, intraparenchymal and subarachnoid haemorrhages have been reported as extremely rare condition. In 1984 Missliwetz et Reiter reported two cases of CT involving large hemorrhages that was lethal<sup>26</sup>. One death in a child resulted from acute cerebellar hemorrhage secondary to capillary telangiectasia in an infant has been reported by Bland et al.<sup>27</sup>. McCormick et al. reported cerebellar hemorrhage associated with CT and DVA<sup>5</sup>. In our findings symptoms related to brain stem lesion involve hemifacial spasm followed behind Bell's palsy and mild right side hemiparesis. The pathophysiology of underlying reccu-

**TABLE 1**  
 PATIENTS PRESENTING WITH SYMPTOMS DUE TO UNRUPTED CAPILLARY TELANGIECTASIA OF THE BRAIN STEM

Patient (ref)	Age	Clinical presentation	Neurological examination	Location of the lesion	Follow up
1 <sup>18</sup>	47 y	Right hearing loss, headache, vertigo	NA	Right midpons	Unchanged 6 months
2 <sup>18</sup>	44 y	Intermittent ataxia	NA	Right rostral pons	Unchanged 3 months
3 <sup>18</sup>	53 y	Vertigo, tinnitus	NA	Left rostral pons	Unchanged 3 y 4 months
4 <sup>18</sup>	69 y	Hearing loss	NA	Left midpons	Unchanged 3 weeks
5 <sup>18</sup>	30 y	Recurrent vertigo, unsteadiness	NA	Right midpons	Unchanged 7 months
6 <sup>18</sup>	63 y	Transient dizziness, diplopia	NA	Midrostral pons	Unchanged 1 month
7 <sup>21</sup>	55 y	Weakness of both legs, slurring speech		Pons and medulla	Intermittent Death
8 <sup>22</sup>	15 months	Deterioration of speech, ataxic gait		Lesion extending from the inferior colliculi through the pons into the upper medulla	Intermittent Death
9 <sup>19</sup>	77 y	Left tinnitus	Decreased pinprick sensation in the left side of the face	Ventral middle part of pons	Unchanged 4 y 1 month
10 <sup>19</sup>	61 y	Diplopia, right ptosis	Diplopia, ptosis	Left parasagittal pars of pons	Unchanged 2 y 1 month
11 <sup>19</sup>	39 y	Paraesthesia in all four limbs, numb tongue	Decreased pinprick sensation in four limbs	Left parasagittal pars of pons	Unchanged 3 y 9 months
12 <sup>19</sup>	42 y	Slurred speech, facial drop	NA	Dorsal middle part of pons	NA
13 <sup>19</sup>	67 y	Left sided weakness, hyperreflexia	NA	Right side of the pons, dorsal left side of pons	10 months
14 <sup>19</sup>	31 y	Dizziness, vertigo, nausea, vomiting, right sided facial weakness	Ataxia, right sided facial weakness	Lower middle part of pons, lower left side of pons	1 y
15 <sup>19</sup>	55 y	Hearing loss greater in right ear than in left ear, tinnitus	Normal	Left middle part of pons	8 months
16 <sup>19</sup>	55 y	Dizziness, dysequilibrium	Ataxia	Left middle part of pons	1 y 2 months
17 <sup>23</sup>	30 y	Diplopia	NA	Quadrigeminal area	Intermittent death
18 <sup>24</sup>	71 y	Diplopia and vertigo	NA	Central pons	Symptoms resolution, death from an unrelated illness
19 <sup>25</sup>	58 y	Dizziness, hearing loss in the right ear	Normal	Lower part of the pons	Unchanged 6 months
20 <sup>25</sup>	62 y	Diplopia	Right facial and abducens nerves paresis	Right pons	NA
Patient 1	28 y	Left ear tinnitus	Right sided weakness, increased muscle tone, and brisk deep tendon reflexes	Central paramedian pons on the left	Unchanged 5 y
Patient 2	30 y	Left lip movements	Normal	Lower paramedian pons on the right	Symptoms resolution Unchanged 1 y
Patient 3	36 y	Right Bell's palsy and gaze palsy	Complete facial palsy of the right side, and inability to gaze toward his right side	Left middle part of pons	Facial weakness resolution in 2 weeks Unchanged 6 months

rent symptoms in patients with CT is not established. The situation of extreme stress to which the patient has been exposed at that time, could explained sudden onset of Bell's palsy as the first symptom in this patient. Neu-

rologic symptoms onset in our patient could be connected with microhaemorrhagic vascular rupture which was overseen at first computerized tomography (CT). Another explanation is involve steroid receptors which have

extensively been stimulated by endogenous steroids. It is known that stimulation of steroid receptors in both muscular and endothelial cells could trigger neurological symptoms through a vasomotor or a haemodynamic mechanism<sup>28</sup>. Affection of the left corticospinal tract and medial longitudinal fasciculus along with vasomotor and haemodynamic mechanisms could explained persistent neurological deficit in our patient.

Cerebral VM represents the most common vascular malformation, usually located in a supratentorial location. Venous malformation appears to represent a pure developmental anomaly<sup>8,15</sup>. Cerebral DVA may be a dilatation of existing pathways and does not consist of abnormally formed vessels. Cerebral VM represent congenital anatomic variant pathways in the normal venous drainage of an area of the brain<sup>16,29</sup>. In spite of its high prevalence in as many as 0.25% autopsies<sup>30</sup>, VM are incidentally found and never show an association between its location and clinical signs, headache and seizures cause. Sporadic reports of hemorrhage, seizure, and infarcts due to thrombosis are described<sup>28</sup>. In a significant proportion of VM, coexisting vascular malformation are found in the central nervous system (eg, AVM, CM, CT). Surgical treatment of venoma is not widespread because the risk of causing iatrogenic venous infarct is very high, but this approach is reserved for associated cavernomas which have bleeding risk of about 1.0 percent *per year*.

Radiographic appearance of CT and DVA is well documented. Preferred examination for CT and DVA is contrast-enhanced MRI. The presence of normal brain tissue between the capillaries distinguishes CT from CM at MRI. CT show enhancement that are dark on gradient-echo images. Angiography is not indicated in CT because the lesions are typically occult in angiograms, while in developmental venous anomaly demonstrating the pathognomonic »caput medusae«, the highest diagnostic finding in identifying DVA. MRI can reveal DVA because of its excellent possibility of detection small vessels and draining vein. MRI should include gradient-echo sequence. Ostertun and Solymosi found enhanced MRI as powerful diagnostic technique in almost all cases of developmental venous anomaly<sup>31</sup>. MRI has great diagnostic value in almost all instances. Intra-arterial angiography is not recommended and is sometimes performed only to exclude the possibility of a small AVM. The veins are small at the periphery and enlarge as they approach a central vein. This appearance has also been referred to as caput medusa. On T2 weighted images, the draining vein may demonstrate increased intensity. The most frequent location is adjacent to the lateral ventricles. Use of gradient-echo or echo-planar imaging adjacent hemosiderin from associated cavernomas is appreciated. Differentiation between AVM and DVA is not problem because AVM have large feeding arteries, tortuous vessels, and abnormal adjacent brain parenchyma. Cavernomas typically appear as focal areas of blood products.

There is no unique explanation on pathogenesis and natural history of an association of two distant, discrete

cerebral malformations. Referring to the previous reports that VMs are pure congenital lesion and all other cerebrovascular malformations are acquired or at least grow during extrauterine life<sup>6,8</sup>, we can conclude therefore, if any type of such cerebral vascular associations contains a VM as one of its components, this should have a high probability of being primary lesion, while any other component, such as PCT could be subsequently acquired. Venous hypertension even in the absence of a VM may cause a grow of an associated vascular malformation<sup>15</sup>.

The authors conclude that an association of an pontine CT and intracerebral DVA is a rare but distinct entity that place CT and DVA within the spectrum of a single disease whereas arrest at the embryological stage of venous development may be responsible for venous malformation<sup>11,12</sup>, while failure of capillary involution during critical phase of development may cause CT<sup>8</sup>, whereas a focal venous outflow obstruction appears also to play important pathogenetic role. Neurohumoral factors, such as stimulation of steroid receptors through vasomotor and haemodynamic mechanisms and local pressure could explained persistent neurological deficit.

In contrast to the more frequent established associations of cerebrovascular malformations, this rare subset of different vascular malformations may contribute to the future discussion on the common pathogenetic factors that may influence development of the cerebral vascular malformation, as well as various factors and mechanisms that cause acute and persistent neurological deficit and therapeutic opportunities.

## Conclusion

The authors conclude that an association of the pontine CT-intracerebral DVA is a rare but distinct entity which evoke reflections on possible interrelations in the pathogenesis of these discrete components. While DVA appears to have pure developmental origin, pontine capillary telangiectasia appear to represent a failure of capillary involution during a critical phase development, but it also may be caused by other pathogenetic cause such as neurohumoral factors, vasomotors mechanisms, hemodynamic disturbance and vessel fragility which result in reactive angiogenesis. Pontine haemorrhagias because of CT must be considered as a rare condition, but attention must be given to these vascular malformation because they can cause various neurological manifestation or could be the cause of an accident or even sudden death. Awareness of the MRI finding of CT and DVA may help in defining clinical correlates of this vascular malformations, while the follow up of these malformations might help to asses risk of vascular rupture. Based on our findings and a review of the literature, we selects pontine CT and supratentorial DVA within rare association which may play the part of a unknown link, that will rise attention on the pathogenesis of cerebrovascular malformations and possibly will contribute to the discussion on therapeutic opportunities of these vascular malformations.

H. Šarac

»Neuron« Diagnostic Centre, Croatian Institute for Brain Research, Šalata 12, 10000 Zagreb  
e-mail: helenasarac@hi.t-com.hr

## REFERENCES

1. COURVILLE CB, Pathology of the central nervous system, 3rd ed. (Mountain View, Pacific Press Publication Association, CA, 1950).
2. DIAMOND C, TORVIK A, AMUNDSEN P, Acta Radiol Diagn, 17 (1976) 281.
3. RIGAMONTI D, JOHNSON PC, SPETZLER RF, HADLEY MN, DRAYER BP, Neurosurgery, 28 (1991) 60.
4. WURM G, SCHNIZE M, FELLNER FA, Neurosurgery, 57 (Suppl 1) (2005) 42.
5. McCORMICK PW, SPETZLER RF, JOHNSON PC, DRAYSER BP, Surg Neurol, 39(6) (1993) 451.
6. ROOST VD, KRISTOF R, WOLF HK, KELLER E, Surg Neurol, 48 (1997) 175.
7. HOUSE JW, BRACKMAN DE, Otolaryngol Head Neck Surg, 93 (1985) 146.
8. AWAD IA, ROBINSON JR Jr, MOHANTY S, ESTES ML, Neurosurgery, 33 (1993) 179.
9. McCORMICK WF, J Neurosurg, 24 (1966) 807.
10. MULLAN S, MOJATAHEDI S, JOHNSON DL, J Neurosurg, 85 (1996) 1.
11. PADGET DH, Contrib Embryol, 36 (1957) 79.
12. SAITO Y, KOBAYASHI N, Radiology, 139 (1981) 87.
13. GAENSLER EH, DILLON WP, EDWARDS MS, LARSON DA, ROSENAU W, WILSON CB, Radiology, 193 (1994) 629.
14. LITTLE JR, AWAD IA, JONES SC, EBRAHIM ZY, J Neurosurg, 73 (1990) 555.
15. CIRICILLO SF, DILLON WP, FINK ME, EDWARDS MSB, J Neurosurg, 81 (1994) 477.
16. RUSSELL DS, RUBINSTEIN LJ, Pathology of tumors of nervous system, 5th ed. (Williams & Wilkins, Baltimore, Hong Kong, London, Sydney, 1989).
17. McCORMICK WF, HARDMAN JM, BOULTE TR, J Neurosurg, 28(3) (1968) 241.
18. BARR RM, DILLON WP, WILSON CB, Am J Neuroradiol, 17 (1996) 71.
19. LEE RR, BECHER MW, BENSON ML, Radiology, 205 (1997) 797.
20. SCAGLIONE C, SALVI F, RIGUZZI P, VERGELLI M, TASSINARI CA, MASCALCHI M, J Neurol Neurosurg Psychiatry, 71 (2001) 390.
21. FARREL DF, FORNO LS, Neurology, 20 (1970) 341.
22. HUDDLE DC, CHALOUPEK JC, SEHGAL V, Am J Neuroradiol, 20 (1999) 1674.
23. STAHL S, JOHNSON KP, MALAMUS N, Arch Neurol, 37 (1980) 25.
24. KUZMA B, GOODMAN JM, BRITT P, Surg Neurol, 48 (1997) 93.
25. KUKER W, NACIMIENTO W, BLOCK F, THRON A, Eur Radiol, 10 (2000) 945.
26. MISSLIWETZT J, REITE C, Z Rechtsmed, 92(1) (1984) 59.
27. BLAND LI, LAPHAM LW, KETONEN L, OKAWARA SH, Arch Neurol, 51(11) (1994) 1151.
28. DITOMMASO L, SCARPELLINI F, SALVI F, Virchows Arch, 436 (2000) 284.
29. HUANG YP, PATEL SC, ROBBINS A, CHAUDHARY M, Cerebral venous malformation. In: KAPP JP, SCHMIDDEK HH (Eds) The cerebral venous system and its disorders (Grune & Stratton, New York, 1984).
30. JELLINGER K, Neurosurg Rev, 9 (1986) 177.
31. OSTERTUN B, SOLYMOSI L, Neuroradiology, 35 (1993) 97.

## SIMPTOMATSKA KAPILARNA TELEANGIEKTAZIJA PONSA I INTRACEREBRALNA RAZVOJNA VENSKA ANOMALIJA: PRIKAZ SLUČAJA

### SAŽETAK

Do sada su opisivane različite kombinacije krvožilnih malformacija mozga unutar jedne lezije, dok su ostale kombinacije vjerojatno vrlo rijetke. U ovom članku, autori raspravljaju primjer koegzistencije kapilarne telangiektazije u ponsu i intracerebralne venske anomalije. Prema našim spoznajama, ovo je prvi slučaj u kojem se opisuje istovremena prisutnost kapilarne telangiektazije i razvojne venske anomalije mozga udaljene jedna od druge. Ove diskretne vaskularne malformacije mozga pobuđuju na razmišljanje o mogućoj povezanosti patogeneza ovih dvaju entiteta. Opisujemo slučaj kapilarne telangiektazije u ponsu i intracerebralne venske anomalije u 42-godišnje bolesnice s paralizom desne polovice lica. Magnetska rezonancija pokazala je kapilarnu telangiektaziju u ponsu, dok druga lezija u lijevom čeonom girusu odgovara razvojnoj venskoj anomaliji. Uz neuroradiološke nalaze, prezentirani su i rezultati somatosenzornih evociranih potencijala (SSEP), auditornih potencijala moždanog debla (BAEP), laboratorijske nalaze krvi, urina i cerebrospinalnog likvora. Prepoznavanje nalaza kapilarne telangiektazije i venske anomalije na magnetskoj rezonanciji može pomoći u definiranju kliničkih poveznica obiju vaskularnih malformacija, dok praćenje ovih malformacija može pomoći u procjeni rizika od vaskularne rupture. Mi i drugi prije nas, izdvajamo kapilarne telangiektazije i razvojne venske anomalije u dva diskretna entiteta. Koegzistencija ovih malformacija u mozgu odvojeno jedna od druge, pobuđuje zanimanje o mogućim interakcijama u njihovom nastanku, patogenezi i terapijskim mogućnostima.