

Ekvivalent: Mikrocistični adneksalni karcinom - dijagnostički kriteriji i terapijske metode: prikaz slučaja i pregled literature

Mamić, Matija

Professional thesis / Završni specijalistički

2022

Degree Grantor / Ustanova koja je dodijelila akademski / stručni stupanj: **University of Zagreb, School of Medicine / Sveučilište u Zagrebu, Medicinski fakultet**

Permanent link / Trajna poveznica: <https://um.nsk.hr/um:nbn:hr:105:363884>

Rights / Prava: [In copyright](#)/[Zaštićeno autorskim pravom.](#)

Download date / Datum preuzimanja: **2025-03-20**



Repository / Repozitorij:

[Dr Med - University of Zagreb School of Medicine Digital Repository](#)



**SVEUČILIŠTE U ZAGREBU
MEDICINSKI FAKULTET**

Matija Mamić

**Mikrocistični adneksalni karcinom –
dijagnostički kriteriji i terapijske metode:
prikaz slučaja i pregled literature**

ZAVRŠNI SPECIJALISTIČKI RAD



Zagreb, 2022.

SVEUČILIŠTE U ZAGREBU
MEDICINSKI FAKULTET

Matija Mamić

**Mikrocistični adneksalni karcinom –
dijagnostički kriteriji i terapijske metode:
prikaz slučaja i pregled literature**

ZAVRŠNI SPECIJALISTIČKI RAD

Zagreb, 2022.

Objavljeni znanstveni rad naslova „*Microcystic adnexal carcinoma diagnostic criteria and therapeutic methods: case report and review of the literature*“ ekvivalent je završnom specijalističkom radu. Rad je objavljen u časopisu „*International Journal of Oral and Maxillofacial Surgery*“, 2018. godine. Rad je izrađen u Klinici za kirurgiju lica, čeljusti i usta Medicinskog fakulteta Sveučilišta u Zagrebu i Kliničkom zavodu za patologiju i citologiju Kliničke bolnice Dubrava u Zagrebu.

Voditelji rada: prof. dr. sc. Ivica Lukšić, dr. med.

SADRŽAJ

1. ABSTRACT	1
2. INTRODUCTION	2
3. CASE REPORT	3
4. DISCUSSION.....	11
5. REFERENCES	17
6. ŽIVOTOPIS.....	23

1. ABSTRACT

Microcystic adnexal carcinoma (MAC) is a rare, infiltrating, locally aggressive cutaneous neoplasm of combined follicular and eccrine/apocrine histogenesis, presenting usually on upper lip or face. Differentiation from other adnexal tumors is very important because the clinical management of these tumors is radically different, and misdiagnosis may lead to incorrect treatment. We present a case of recurrent MAC in the upper lip, treated with multiple excisions and postoperative radiation therapy (PORT). After consecutive reconstructive surgery and PORT, no signs or symptoms of recurrence were noted so far. Based on reports in the literature, although immunohistochemistry can be helpful in distinguishing between MAC and other adnexal tumors, careful pathohistological examination is essential for accurate diagnosis. Perineural and intramuscular invasion strongly suggest the diagnosis of MAC. Its predilection for the facial area often limits the width of surgical excision. In such cases PORT may be considered.

2. INTRODUCTION

Microcystic adnexal carcinoma (MAC) is an uncommon, malignant adnexal tumor, which was first reported as a distinct pathologic entity by Goldstein in 1982¹. Local recurrence has been reported in 40-60% of patients after standard wide local excision²⁻⁵, but this is much less likely if the excision margins are free of tumor in the initial excision. Therefore, accurate diagnosis is essential. Histological overlap with other benign and malignant cutaneous tumors presents the primary diagnostic problem.

Surgical approaches including standard excision and Mohs micrographic surgery technique may require more extensive excision, resulting in a worse functional and/or aesthetic outcome. Possible disfiguring procedures require subsequent reconstructive surgery. Recent reports discuss the role of radiation therapy, either as an adjunct to primary surgical treatment, or as monotherapy⁶⁻¹⁰. Results are controversial due to the rarity of the tumor. Reliable studies with a larger number of samples have not been reported.

3. CASE REPORT

A 74-year-old Caucasian woman with a 10-year-history of recurrent desmoplastic trichoepithelioma (DTE) in the upper lip presented to our institution with a newly formed tumor in the scar area. Clinically, there was a diffuse infiltration measuring 35 x 20 mm, encompassing the left side of the upper lip. The tumor was painless, but she reported a burning sensation. The overlying skin was hyperpigmented. The oral cavity, pharynx and larynx were inconspicuous and there was no lymphadenopathy. Multi-slice computed tomography (MSCT) scans revealed a soft tissue thickening 19 x 8 mm, without visible destruction of the maxilla (**Figure 1**). Initial surgical excision was followed by reconstruction with transposable bilateral local lobes. Pathohistological findings were consistent with recurrent DTE. After the surgery, the patient recovered with good functional and aesthetic results, and was set to follow up.

After a 36-month disease-free period, the patient presented with an upper lip nodule which appeared suddenly two weeks earlier. Fine needle aspiration biopsy also hinted at a possible recurrence of DTE. Cuneiform excision of the upper lip was performed.

Pathohistological analysis revealed tumor tissue composed of numerous small clusters, tubular and cribriform structures of atypical epithelial cells, with low mitotic activity, surrounded by abundant hyaline material. Perineural infiltration was prominent. Some of the tubular structure contained an eosinophilic material. Microcystic adnexal carcinoma (MAC), morpheaform basal

cell carcinoma (mBCC) and malignant cylindroma of the skin were considered in the differential diagnosis.

Pathohistological reevaluation and immunohistochemical analysis of all surgical specimens were performed. A similar histopathological pattern presented in all specimens. The poorly circumscribed tumor invading deeply into the dermis and subcutis was composed of nests of atypical basaloid cells, embedded in the desmoplastic stroma. Some keratinous cysts and cystic glands were visible in the upper dermis (**Figure 2**). Small ductal or glandular structures within a hyalinized stroma were visible in the deep dermis, accompanied by perineural and intramuscular invasion (**Figure 3**). Tumor cells were of bland histological features with little cytologic atypia or mitotic activity. Immunohistochemical analysis (**Table 1**) revealed a strong positive reaction with various cytokeratins (CK7, CK5/6, CKAE1/AE3, CK19) and myoepithelial markers (p63, p40, CD10), and mild positive CEA reaction within keratin-filled cysts and duct lumina. Negative reaction with BerEP4, Androgen and Progesteron receptor as well as with Merkel cell marker CK20 was observed (**Figure 4**). Proliferative activity Ki67 was less than 5%. Histological and immunohistochemical pattern was consistent with MAC.

Due to the positive resection margin and the necessity for more radical intervention, surgical revision treatment was indicated. Resection of the upper lip and reconstruction with bilateral buccal flaps was performed.

The early postoperative recovery period was uneventful. The patient was discharged in good general condition with normal function of the oral sphincter. Because of the diagnosis of MAC, our institutional oncology council decided to continue the treatment with adjuvant postoperative radiation therapy (PORT). The patient was treated with a total dose of 58 Gy in 28 fractions administered to the tumor bed (2 Gy per fraction). During an 18-month follow-up period, no signs or symptoms of recurrence were noted.

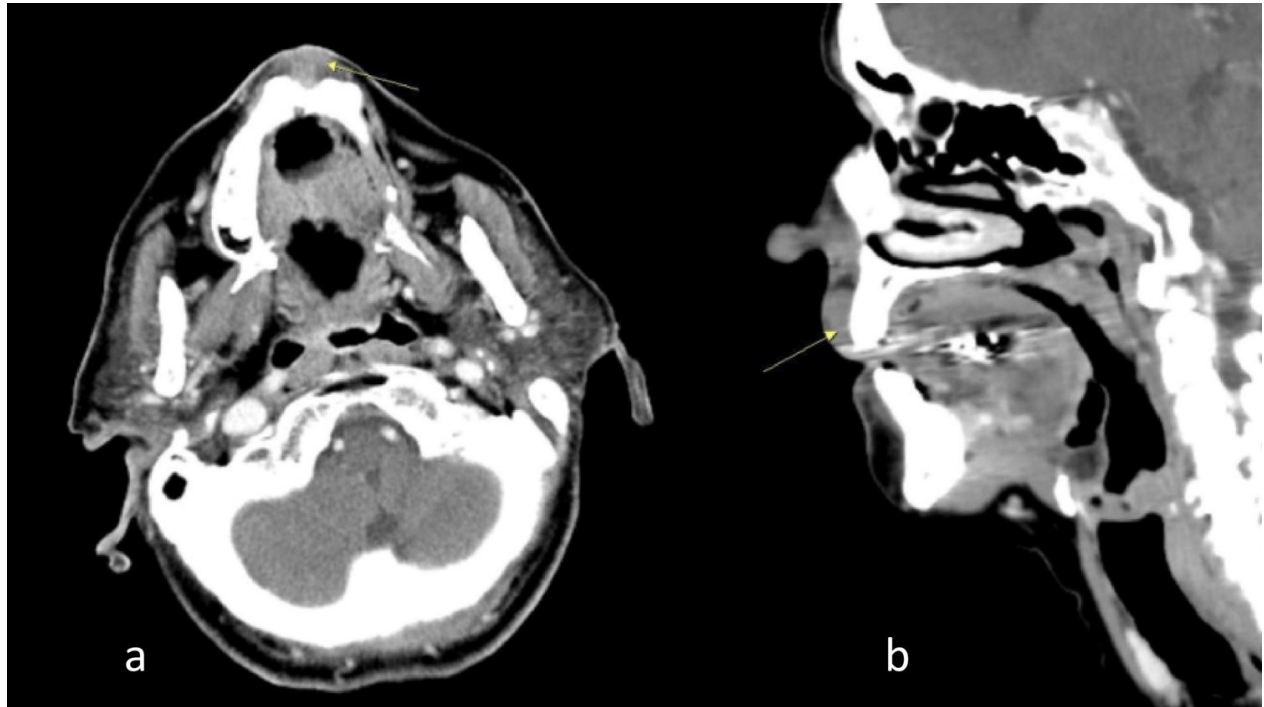


Figure 1. MSCT axial (a) and sagittal (b) reconstructions. Arrows point the lesion.

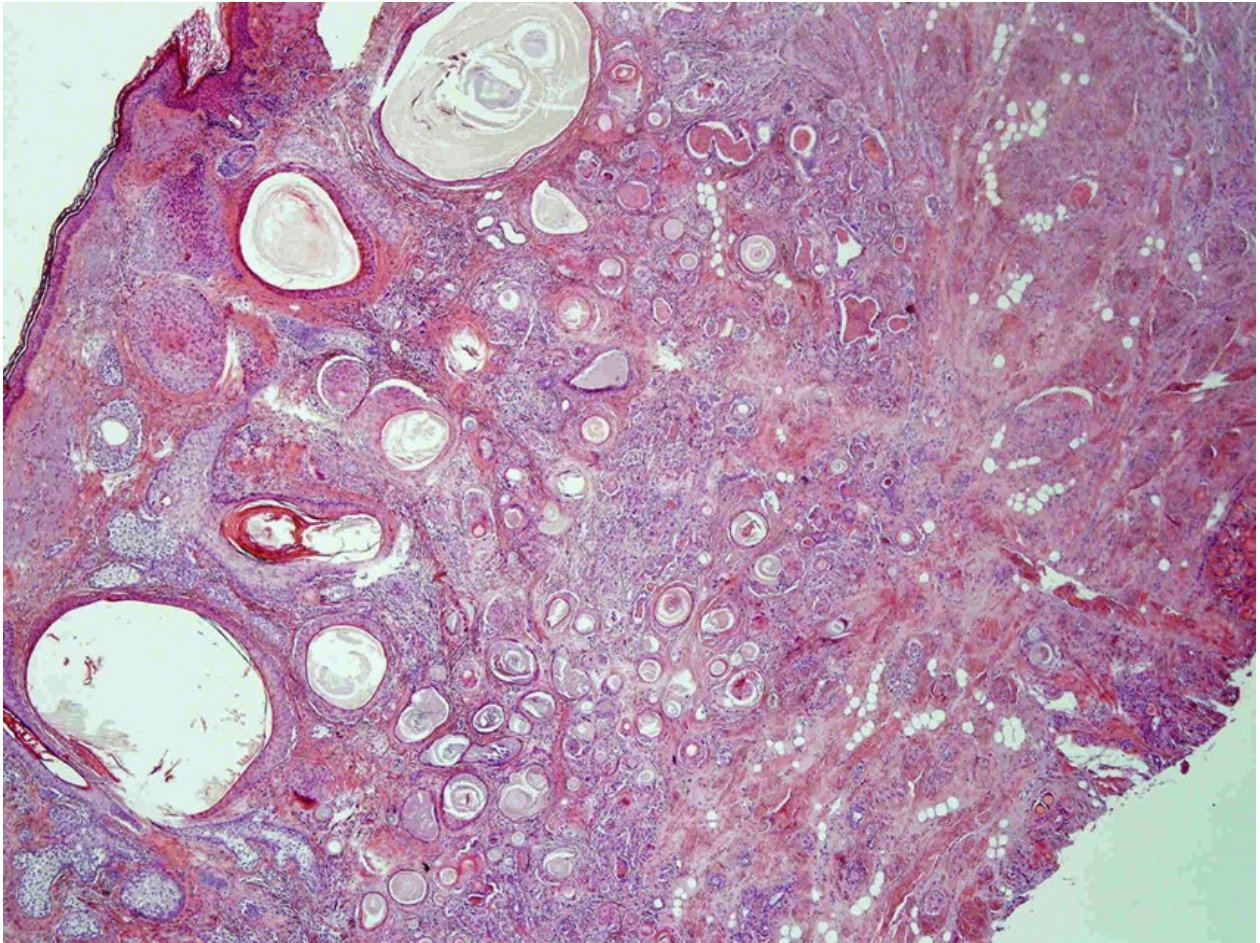


Figure 2. The primary MAC misdiagnosed as a desmoplastic trichoepithelioma (HE x 40).

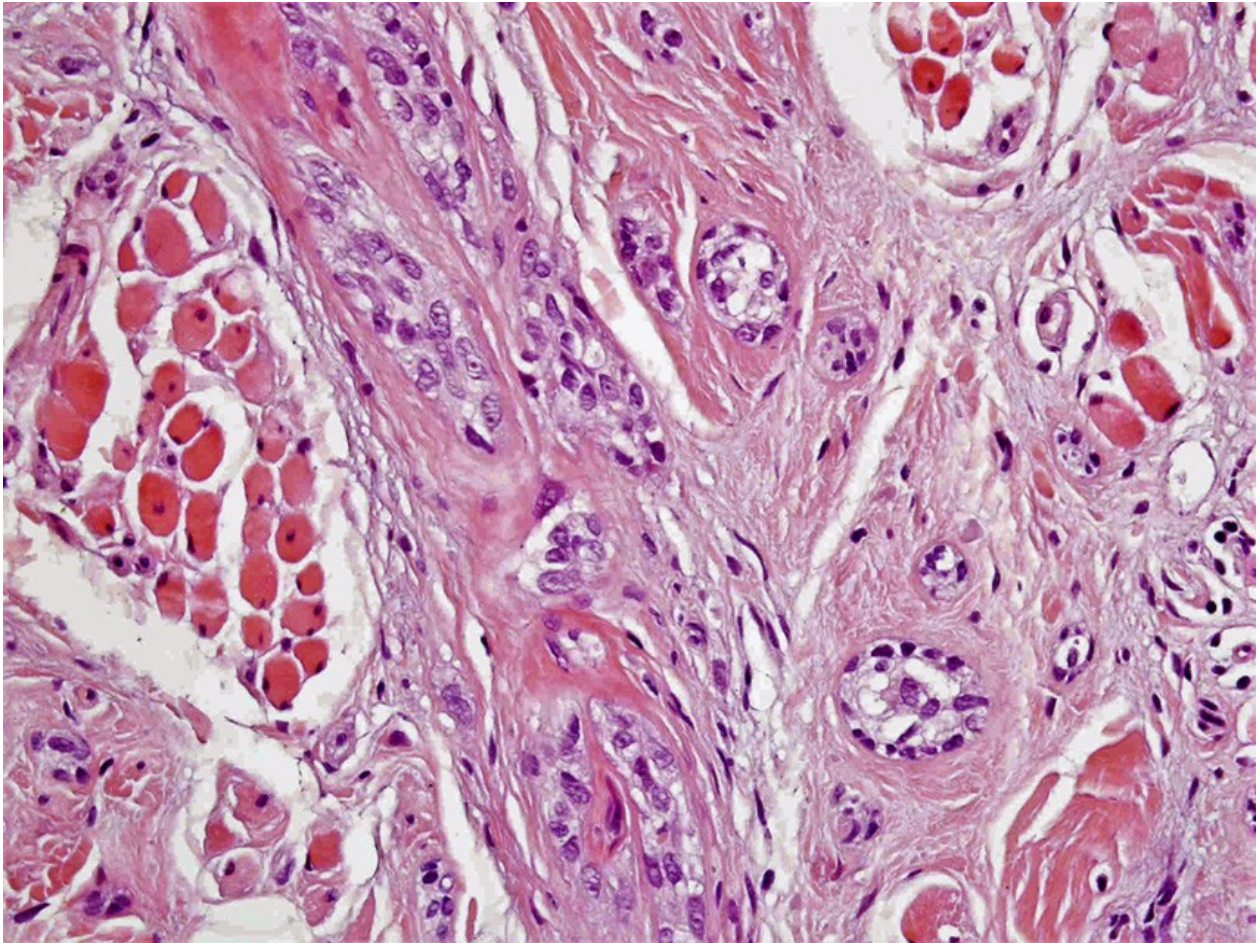


Figure 3. Solid and ductal epithelial strands revealing intramuscular infiltration in the deep portion (HE x 400).

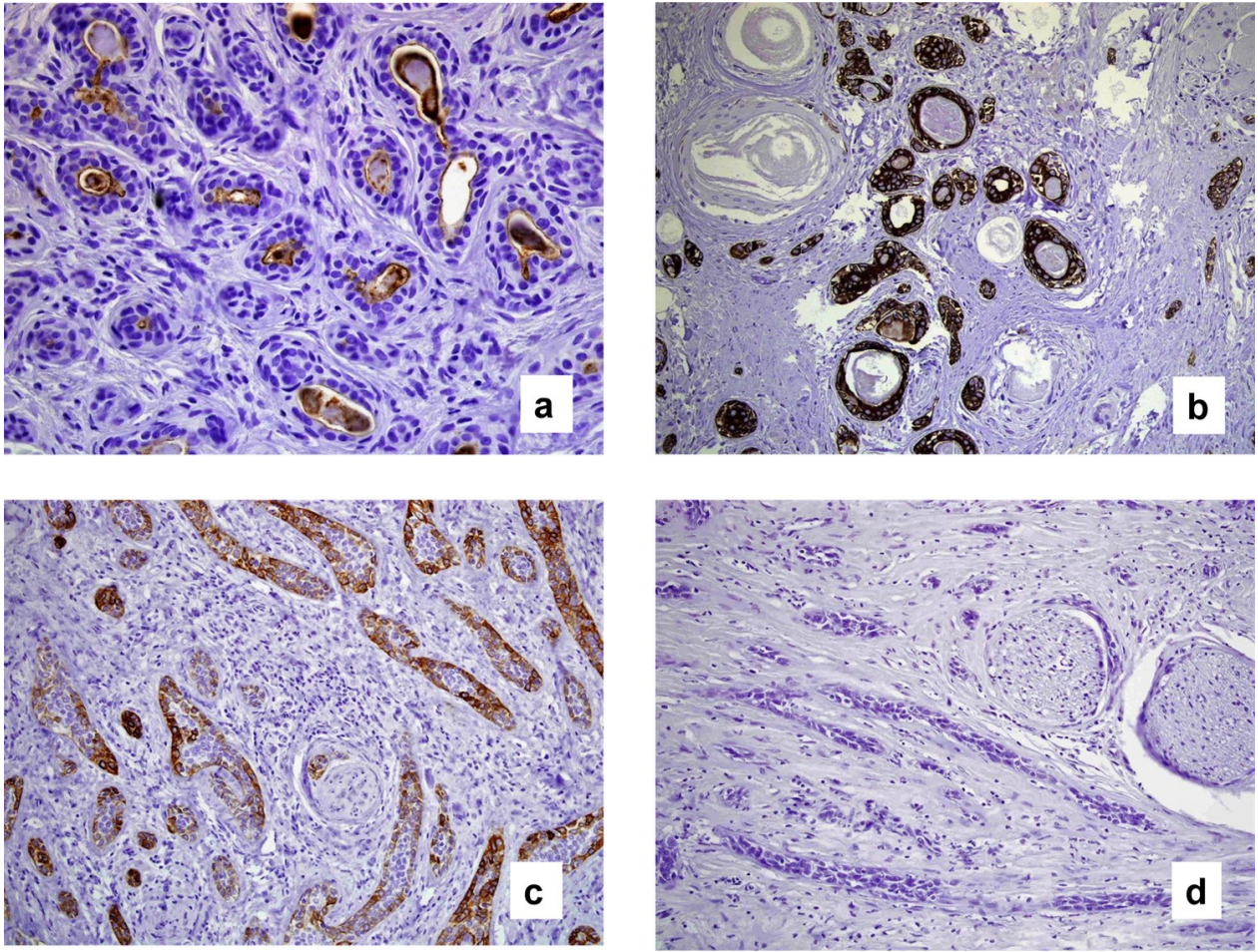


Figure 4. Immunohistochemical analysis revealed a strong positive reaction with CEA (a), CK 19 (b) and CK 7 (c), and negative reaction with BerEP4 (d).

Table 1. Immunohistochemical analysis of the present case.

CK AE1/AE3	+++
CK5/6	+++
CK7	+++
CK 19	+++
CK 20	-
BerEP4	-
p63	+++
p40	+++
CD5	-/+
CD10	++
CD34	stromal +
S100	++
CEA	luminal +
AR	-
PR	-
Ki67	< 5%

-/+ scattered cells

+ up to 25% tumor cells

++ 25%-75% tumor cells

+++ 75%-100% tumor cells

AR Androgen receptor

PR Progesterone receptor

4. DISCUSSION

Despite its consistently reported indolent growth, microcystic adnexal carcinoma (MAC) demonstrates clinically aggressive local infiltration. The histogenesis of MAC is still controversial. It was originally described by Goldstein et al.¹ as a tumor with pilar and eccrine differentiation, but this is at variance with other views that it is of apocrine type. According to Requena et al.¹¹ MAC is a malignant tumor with apocrine, follicular and sebaceous differentiation. The similar histologic pattern and immunoprofile of MAC and other locally aggressive adnexal tumors, has provoked diagnostic confusion. The main differential diagnoses for MAC are desmoplastic trichoepitelioma (DTE) and morpheaform basal cell carcinoma (mBCC). In the published literature, misdiagnosis of MAC as DTE, mBCC, or other aggressive skin neoplasms has been reported in 30–52% of cases^{3,12}. Numerous immunohistochemical analyses have been reported as an attempt to provide a satisfactory algorithm for distinguishing among these tumors, but with conflicting results^{10,12-17}. A panel of cytokeratins including CKAE1/AE3, CK1, CK7, CK8, CK13, CK14, CK15, CK17, CK19, CK20, CK903 have been analyzed in various studies^{12,13}, but the results did not confirm any of these as a reliable marker in differentiating infiltrative skin tumors. CK20 positivity in various studies demonstrates a strong predictive value for DTE. CK20 is usually negative in mBCC and MAC¹⁸. CK19 positivity, on the other hand, suggests MAC and not DTE^{19,20}. CEA is considered to be a marker

of choice in demonstrating ductal differentiation in MAC. This is a marker of eccrine and apocrine ducts, which would favor microcystic adnexal carcinoma¹⁹. Our case revealed CK20 negativity and CK19 and CEA positivity. Different results have been reported regarding the BerEP4 immunoreactivity. Krahl et al.¹⁵ reported the absence of reactivity in all cases of MAC and reactivity in all mBCCs and in 75% of DTEs. Hoang et al.¹² observed BerEP4 positivity in all cases of mBCC, but also in 38% of MACs and in 57% of DTEs, while Smith et al.¹³ reported BerEP4 positivity in glandular areas of their 10 cases of MAC. These results indicate that BerEP4 differentiates between MAC and morpheaform BCC but not between MAC and DTE. In our case, BerEP4 was negative. The staining pattern for CD34 reveals focal stromal cell positivity in DTE, whereas the stromal cells in mBCC and MAC are usually negative¹². However, in our case CD34 showed mild stromal positivity.

The majority of reports consider the advantages of Mohs microsurgery (MMS) over standard excision for fast and secure verification of the resection edges, and ultimately less need for new office visits²¹⁻²³. Chiller et al.³ have shown in a series of 45 MAC cases that 30% of patients treated with the excision at onset, will require at least one other procedure, compared with 0% if initially treated with MMS. In addition, although they were unable to compare post-treatment surgical areas and, therefore, unable to demonstrate the tissue-sparing advantages from one treatment group to another, they supported the use of MMS, as a technique which does not rely on such predicted margins. Despite the popularity of MMS and its benefits, based on suspicion of

occult microscopic metastases, our choice was wide excision. It was extended to accommodate the later issue of defect reconstruction, while respecting strict rules of oncologic surgery. Our defect was 4-fold larger than the size of the tumor, and subsequent histological analysis showed 2cm clean resection margins. Additionally, since the surgical procedure is commonly performed on aesthetically sensitive areas, the extensiveness of the procedure can be as favorable to adjust the subsequent reconstruction²⁴.

Due to MAC infiltrative growth, surgical treatment of aesthetically sensitive areas often carries the possibility of disfigurement, and poses reconstruction dilemmas, especially in the lip region. Reconstruction of a large defect of the upper lip can be performed by a variety of local flaps, or by microvascular free-tissue transfer. In the presented case, a bilateral buccal flap was considered the optimal reconstructive method. Postoperative functional and aesthetic outcomes were satisfactory, avoiding microstomia and additional scars on the lower lip and cheek. Unfortunately, a disadvantage of the performed method was the remaining incompetence of the orbicularis oris muscle, as has been previously reported²⁵. However, the decision for using this technique was based on the optimized size of the defect, and on our clinical experience that the perioral tissue would more easily preserve the sensory and functional role of the upper lip than free flaps could.

Collecting multiple reports of MAC, we found a total of 29 cases treated with radiation therapy (RT)^{6-8,26-30}. RT was performed as adjuvant postoperative therapy (PORT), or as monotherapy. A

total of 25 cases have been treated with PORT^{6,7,26-30}. Indications for PORT are positive sample margins and perineural invasion^{6,26}. The effect of PORT is difficult to assess, because of the short follow-up period, and the various forms used for the purpose of additional treatment throughout the past. Pugh et al.⁶ reported two cases with a longer follow-up period. The first case had no evidence of disease at 30-month follow-up after undergoing PORT with a total dose of 66 Gy at 2 Gy per fraction, delivered to the surgical bed. The second case had no evidence of disease at 26-months of follow-up after receiving a total dose of 60 Gy delivered in standard fractions. So far, only four cases of radiation monotherapy (MRT) have been described^{6,8,9}, but due to a lack of technical details, methods inadequate for today's standards, and the short follow-up, results are controversial. While most authors present MRT as a successful method, Stein et al.⁹ reported clinically less favorable outcome after MRT. Indications for MRT include potentially large, disfiguring defects or cases where the general patient's condition precludes surgical treatment. In our case, after PORT, no signs or symptoms of recurrence were noted.

In our experience, differentiating MAC from BCC is less difficult and bears less consequence, because in both cases, wide surgical excision is the method of choice. However, differentiating MAC from desmoplastic trichoepithelioma (DTE) is highly important because the clinical management of these two tumors is radically different, and misdiagnosis of MAC as DTE leads to incorrect treatment.

Based on our experience and on all the reports in literature, a careful pathohistological examination is still the gold standard for correctly diagnosing MAC. Perineural and intramuscular invasion strongly suggest the diagnosis of MAC. Although the reliable marker for MAC does still not exist, immunohistochemistry can be helpful in distinguishing between these tumors. Immunopositivity for CEA and CK19, and negativity for CK20 can help to distinguish MAC from DTE. Negative reaction with BerEP4 distinguishes MAC from mBCC. It's predilection for the facial area often limits the width of surgical excision, and in such cases adjuvant radiotherapy is indicated.

One of the possible disadvantages of this study is conduction of adjuvant radiotherapy. In general PORT does not warrant for the diagnosis of MAC given the low recurrence rates after excision with clear margins. Also some MAC are radioresistant and several reports of microcystic adnexal carcinoma developing in patients within sites of previous therapeutic irradiation have been described^{31,32}. However, in this particular case, PORT was added as an adjuvant treatment option due to the fact that multiple recurrences occurred after surgery with clear margins. Furthermore, there is no clear evidence that radiotherapy can cause aggressive transformation of this tumor⁷.

Another possible weakness of this Case Report is that we did not use Mohs surgery as an optimal microscopically controlled surgery generally used to treat common types of skin cancer. In this case, it was not used due to the anatomical location of the recurrent tumor. Also, while Mohs

micrographic surgery may be considered the gold standard, wide local excision and adjuvant radiotherapy offer comparable control rates.

5. REFERENCES

1. Goldstein DJ, Barr RJ, Santa Cruz DJ. Microcystic adnexal carcinoma: a distinct clinicopathologic entity. *Cancer* 1982;50:566-572.
2. Cooper PH, Mills SE, Leonard DD, et al. Sclerosing sweat duct (syringomatous) carcinoma. *Am J Surg Pathol* 1985;9:422-433.
3. Chiller K, Passaro D, Scheuller M, Singer M, McCalmont T, Grekin RC. Microcystic Adnexal Carcinoma. Forty-eight cases, their treatment, and their Outcome. *Arch Dermatol* 2000;136:1355-1359.
4. Friedman PM, Friedman RH, Jiang SB, Nouri K, Amonette R, Robins P. Microcystic adnexal carcinoma: collaborative series review and update. *J Am Acad Dermatol* 1999;41:225-231.
5. Lupton GP, McMarlin SL. Microcystic adnexal carcinoma. Report of a case with 30-year follow-up. *Arch Dermatol* 1986;122:286-289.
6. Pugh TJ, Lee NY, Pacheco T, Raben D. Microcystic adnexal carcinoma of the face treated with radiation therapy: a case report and review of the literature. *Head Neck* 2012;34:1045-1050.

7. Baxi S, Deb S, Weedon D, Baumann K, Poulsen M. Microcystic adnexal carcinoma of the skin: the role of adjuvant radiotherapy. *J Med Imaging Radiat Oncol* 2010; 54:477-482.
8. Schipper JH, Holecek BU, Sievers KW. A tumour derived from Ebner's glands: microcystic adnexal carcinoma of the tongue. *J Laryngol Otol* 1995;109:1211-1214.
9. Stein JM, Ormsby A, Esclamado R, Bailin P. The effect of radiation therapy on microcystic adnexal carcinoma: a case report. *Head Neck* 2003;25:251-254.
10. Gordon S, Fischer C, Martin A, Rosman IS, Council ML. Microcystic Adnexal Carcinoma: A Review of the Literature. *Dermatol Surg* 43(8):1012-1016, 2017.
11. Requena L, Kiryu H, Ackerman AB. Neoplasms with apocrine differentiation. Philadelphia: LippincottRaven/Ardor Scribendi 1997.
12. Hoang MP, Dresser KA, Kapur P, High WA, Mahalingam M. Microcystic adnexal carcinoma: an immunohistochemical reappraisal. *Mod Pathol* 2008;21:178-185.
13. Smith KJ, Williams J, Corbett D, Skelton H. Microcystic adnexal carcinoma: an immunohistochemical study including markers of proliferation and apoptosis. *Am J Surg Pathol* 2001;25:464-471.

14. Bogner PN, Su LD, Fullen DR. Cluster designation 5 staining of normal and non-lymphoid neoplastic skin. *J Cutan Pathol* 2005;32:50-54.
15. Krahl D, Sellheyer K. Monoclonal antibody Ber-EP4 reliably discriminates between microcystic adnexal carcinoma and basal cell carcinoma. *J Cutan Pathol* 2007; 34:782-787.
16. Crowson AN, Magro CM, Mihm MC. Malignant adnexal neoplasms. *Mod Pathol* 2006;2:S93-S126.
17. Obaidat NA, Alsaad KO, Ghazarian D. Skin adnexal neoplasms - part 2: An approach to tumours of cutaneous sweat glands. *J Clin Pathol* 2007;60:145-159.
18. Merritt BG, Snow SN, Longley BJ. Desmoplastic Trichoepithelioma, Infiltrative/Morpheaform BCC, and Microcystic Adnexal Carcinoma: Differentiation by Immunohistochemistry and Determining the Need for Mohs Micrographic Surgery. *Cutis*. 2010; 85:254-258.
19. Sellheyer K, Nelson P, Kutzner H, Patel RM. The immunohistochemical differential diagnosis of microcystic adnexal carcinoma, desmoplastic trichoepithelioma and morpheaform basal cell carcinoma using BerEP4 and stem cell markers. *J Cutan Pathol* 2013; 40: 363–70.

20. Tse JY, Nguyen AT, Le LP, Hoang MP. Microcystic adnexal carcinoma versus desmoplastic trichoepithelioma: a comparative study. *Am J Dermatopathol* 2013; 35:50-5.
21. Abbate M, Zeitouni NC, Seyler M, Hicks W, Loree T, Cheney RT. Clinical course, risk factors, and treatment of microcystic adnexal carcinoma: a short series report. *Dermatol Surg* 2003;29:1035-1038.
22. Wetter R, Goldstein GD. Microcystic adnexal carcinoma: a diagnostic and therapeutic challenge. *Dermatol Ther* 2008;21:452-458.
23. Ghareeb ER, Dulmage BO, Vargo JA, Balasubramani GK, Beriwal S. Underutilization of Mohs micrographic surgery for less common cutaneous malignancies in the United States. *Dermatol Surg* 2016;42:653-662.
24. Kang MS, Lee EJ, Kim JS, Yun IS, Byeon HK. Microcystic adnexal carcinoma of the nasal tip treated with surgical excision and rotational forehead skin flap. *J Craniofac Surg* 2016;27:e756-e758.
25. Rustemeyer J, Zwerger S, Pörksen M, Junker K. Microcystic adnexal carcinoma of the upper lip misdiagnosed benign desmoplastic trichoepithelioma. *Oral Maxillofac Surg* 2013;17:141-144.

26. Avraham JB, Villines D, Maker VK, August C, Maker AV. Survival after resection of cutaneous adnexal carcinomas with eccrine differentiation: risk factors and trends in outcomes. *J Surg Oncol* 2013; 108:57-62.
27. Waqas O, Faisal M, Haider I, Amjad A, Jamshed A, Hussain R. Retrospective study of rare cutaneous malignant adnexal tumors of the head and neck in a tertiary care cancer hospital: a case series. *J Med Case Rep* 2017;11:67.
28. Kim LH, Teston L, Sasani S, Henderson C. Microcystic adnexal carcinoma: successful management of a large scalp lesion. *J Plast Surg Hand Surg* 2014;48:158-160.
29. Birkby CS, Argenyi ZB, Whitaker DC. Microcystic adnexal carcinoma with mandibular invasion and bone marrow replacement. *J Dermatol Surg Oncol* 1989;15:308-312.
30. Bier-Laning CM, Hom DB, Gapany M, Manivel JC, Duvall AJ 3rd. Microcystic adnexal carcinoma: management options based on long-term follow-up. *Laryngoscope* 1995;105:1197-1201.
31. Antley CA, Carney M, Smoller BR. Microcystic adnexal carcinoma arising in the setting of previous radiation therapy. *J Cutan Pathol* 1999;26:48-50.

32. Schwarze HP, Loche F, Lamant L, Kuchta J, Bazex J. Microcystic adnexal carcinoma induced by multiple radiation therapy. *Int J Dermatol* 2000;39:369-372.

6. ŽIVOTOPIS

Rođen sam 3. srpnja 1990. godine u Pakracu. Osnovnu školu i opću gimnaziju završio sam u Garešnici gdje sam i odrastao. Diplomirao sam 2015. godine na Medicinskom fakultetu Sveučilišta u Zagrebu. Diplomski rad „Prognostički čimbenici primarnih tumora submandibularne žlijezde“ izrađen je pod mentorstvom prof. dr. sc. Ivice Lukšića. Dobitnik sam Dekanove nagrade za najboljeg studenta 5. godine studija. Na poslijediplomskom doktorskom studiju „Biomedicina i zdravstvo“ Medicinskog fakulteta Sveučilišta u Zagrebu doktorirao sam 2021. godine. Doktorski rad „Prognostički značaj proširenosti ekстранodalnog proboja regionalne metastaze u klinički negativnom vratu oboljelih od planocelularnog karcinoma usne šupljine“ izrađen je pod mentorstvom prof. dr. sc. Ivice Lukšića i doc. dr. sc. Danka Müllera. Specijalizaciju iz maksilofacijalne kirurgije završio sam 2022. godine u Klinici za kirurgiju lica, čeljusti i usta Kliničke bolnice Dubrava. Područja kliničkog interesa su mi onkokirurgija glave i vrata te kirurgija koštanih deformiteta ličnoga skeleta iz kojih sam prošao više edukacija u renomiranim inozemnim ustanovama. Aktivno se bavim znanstvenim radom vezanim uz maksilofacijalnu kirurgiju i onkologiju glave i vrata. Kao autor i koautor objavio sam 16 radova indeksiranih u bazi „Current Contents“. Oženjen sam i otac jednog dječaka. U slobodno vrijeme bavim se sportom i putujem. Aktivno se služim engleskim i njemačkim jezikom.