

Primary undifferentiated carcinoma of rete testis with extensive peritoneal carcinomatosis and fatal outcome: Case report

Petrović, Andreja; Jurković, Ilija; Krušlin, Božo

Source / Izvornik: **Urology Case Reports, 2023, 51**

Journal article, Published version

Rad u časopisu, Objavljena verzija rada (izdavačev PDF)

<https://doi.org/10.1016/j.eucr.2023.102573>

Permanent link / Trajna poveznica: <https://um.nsk.hr/um:nbn:hr:105:964311>

Rights / Prava: [Attribution-NonCommercial-NoDerivatives 4.0 International/Imenovanje-Nekomercijalno-Bez prerada 4.0 međunarodna](#)


Download date / Datum preuzimanja: **2024-08-20**



Repository / Repozitorij:

[Dr Med - University of Zagreb School of Medicine
Digital Repository](#)





Oncology

Primary undifferentiated carcinoma of rete testis with extensive peritoneal carcinomatosis and fatal outcome: Case report

Andreja Petrović^a, Ilija Jurković^b, Božo Krušlin^{c,d,*}

^a Dpt of Pathology and Cytology, Clinical Hospital Merkur, Zagreb, Croatia

^b Dpt of Pathology and Cytology, Dubrovnik General Hospital, Dubrovnik, Croatia

^c Dpt of Pathology and Cytology, Clinical Hospital Center Sestre Milosrdnice, Zagreb, Croatia

^d Dpt of Pathology, School of Medicine, Zagreb, Croatia



ARTICLE INFO

Keywords:

Carcinoma
Rete testis
Primary
Carcinomatosis

ABSTRACT

Carcinoma of rete testis is an extremely rare malignant tumor arising from its epithelium. Prognosis is poor with mean survival of 8 months. Lymph node metastases and the size of the tumor larger than 5 cm are poor prognostic factors. We report a case of primary undifferentiated carcinoma of the rete testis in a 46-year-old man who presented with testicular enlargement without previous trauma or cryptorchidism, and with extensive peritoneal carcinomatosis, retroperitoneal lymph node metastases and fatal outcome. We present this case because of the rarity of the carcinoma of the rete testis and its challenging diagnosis.

1. Introduction

Primary carcinoma of the rete testis is an extremely rare malignant tumor arising from the epithelium of the rete testis.^{1–5} There are a few criteria that need to be fulfilled to diagnose adenocarcinoma of the rete testis: a tumor located in the center of the testicular hilum, the nonexistence of other extrascrotal tumors with similar histology, the morphology of the tumor is incompatible with any other type of testicular or paratesticular tumor, and other primary tumors of this site, such as malignant mesothelioma, papillary serous carcinoma and malignant Sertoli cell tumor, should be excluded.¹ The diagnosis is based on immunohistochemical exclusion of other possibilities, and most importantly the finding of transition from benign to malignant epithelium of the rete testis. Most patients are older adults but a wide age range has been reported (8–90 years old).^{1,4,5} There have been less than 80 cases of adenocarcinoma of the rete testis published to date, but many of them did not include all the strict diagnostic criteria required for diagnosis.⁴ We present a very rare case of primary undifferentiated carcinoma of the rete testis with an extremely aggressive clinical course and fatal outcome in only one month after the diagnosis was established.

2. Case presentation

A 46-year-old male presented with painful testicular enlargement

that he noticed two weeks prior. There was no history of cryptorchidism, abnormal sexual development, trauma in the inguinoscrotal region, or primary tumor in other sites. On examination the testis was firm and painful on palpation. The overlying skin was without any visible changes. There was no palpable lymphadenopathy. Ultrasonography of the scrotum and inguinal region revealed an inhomogeneous mass with necrotic areas and no inguinal lymphadenopathy. Tumor markers were normal with elevated leukocytes and other inflammatory markers. The diagnosis of purulent orchitis was made. Clinical symptoms were deteriorating and orchidectomy was performed. The resected specimen comprised the testis and its appendages, measuring 8.5 cm in diameter with a 7.5 cm resected spermatic cord. On gross examination, a partially solid, gray-white mass with cystic and hemorrhagic areas was found. The tumor measured 6.5 cm in diameter and was invading the spermatic cord, epididymis and testis (Fig. 1a.).

Histopathological examination revealed a solid growth pattern and partially discohesive, pleomorphic malignant tumor cells. The cells were large with eosinophilic cytoplasm, severe nuclear atypia and prominent eosinophilic nucleoli (Fig. 1b, c and d). Frequent mitotic figures were present, of which many were atypical. Cystic and necrotic areas with lymphovascular invasion were observed (Fig. 1c). The tumor had infiltrated the testicular parenchyma between the seminiferous tubules, epididymis and spermatic cord (Fig. 1b and d). Transition from the normal epithelium of the rete testis to a dysplastic and malignant

* Corresponding author. Dpt of Pathology and Cytology, Clinical Hospital Center Sestre Milosrdnice, Zagreb, Croatia.

E-mail addresses: petrovic.andrea@gmail.com (A. Petrović), jajurkovic@gmail.com (I. Jurković), bozo.kruslin@kbcsm.hr (B. Krušlin).

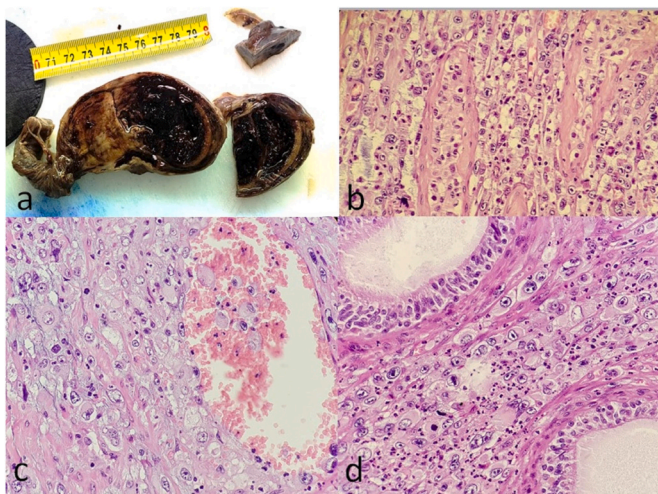


Fig. 1. a) Gross examination showing a partially solid, gray-white mass with cystic and hemorrhagic areas.

Fig. 1 b) The tumor infiltrating the testicular parenchyma between the seminiferous tubules (H and E x 40)

Fig. 1 c) lymphovascular invasion with discohesive malignant cells

Fig. 1 d) infiltration of the epididymal parenchyma (H and E x40).

epithelium was noted (Fig. 2a–b). Extensive immunohistochemical staining was performed. Malignant cells stained positive for CK7 and panCK AE1/AE3 (Fig. 2c–d), but were negative for CD20, CD3, LCA, Inhibin, Calretinin, WT1, GATA-3, and markers for germ cell tumors (PLAP, CD117, AFP and CD30). On the basis of the clinical data, histological examination of serial sections and immunohistochemical results, the diagnosis of undifferentiated carcinoma of the rete testis was made.

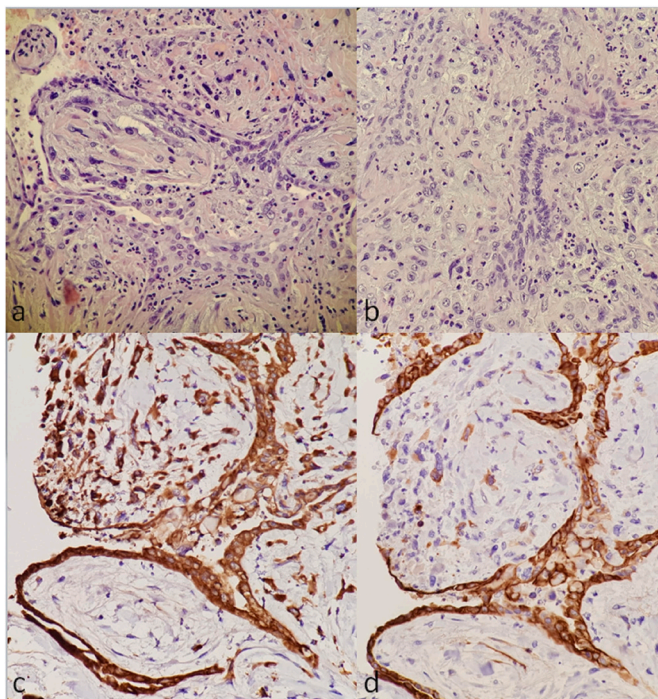


Fig. 2. a) and b) Transition from atypical and dysplastic epithelium of the rete testis to malignant epithelium with an invasive component (H and E x40).

Fig. 2 c) and d) Immunohistochemical studies for keratins revealed that the atypical and dysplastic cells demonstrated strong cytoplasmic staining for pancytokeratin and cytokeratin 7. The invasive component showed strong cytoplasmic staining for pancytokeratin and patchy cytoplasmic staining for cytokeratin 7 (x40 magnification).

At the follow up one month after the orchidectomy, the patient presented with lower back pain and diffuse abdominal pain. Computed tomography revealed an enlarged and necrotic retroperitoneal lymph node conglomerate that measured 9 cm in diameter (Fig. 3). Median laparotomy showed extensive retroperitoneal infiltration and peritoneal carcinomatosis in addition to left inguinal infiltration. Biopsy of the aforementioned infiltration was performed and histopathological examination revealed the metastatic spread of the primary undifferentiated carcinoma of the rete testis (Fig. 4). The patient passed away a few days later. The autopsy was not performed.

3. Discussion

Primary carcinoma of the rete testis is a very rare malignant tumor that predominantly occurs in elderly men. Prognosis is very poor and most patients have developed metastases at the time of diagnosis.^{2–5} The 3- and 5- year disease-free survival rates are 49% and 13% respectively^{5,6} and a median survival time 33 months.⁷ There are no specific clinical symptoms and tumor markers are normal. Patients present with testicular enlargement similar to any other testicular tumor, with or without scrotal pain, and it may often present as a hydrocele.^{2–5} Due to its rarity, the diagnosis is based on detecting the transition from the normal epithelial lining of the rete testis to a dysplastic and malignant epithelial lining, and excluding all differential diagnoses.^{1,4} The most important differential diagnoses are metastatic carcinoma, malignant mesothelioma, ovarian-like tumors of the testis, and malignant Sertoli cell tumor. Transition from benign epithelium to atypical and malignant epithelium of the rete testis favors primary adenocarcinoma of the rete testis over metastatic adenocarcinoma.^{1,4} Additionally, metastatic adenocarcinoma is usually bilateral, and the patient has a clinical history of primary carcinoma.^{1,4} Malignant mesothelioma involves the tunica vaginalis of the testis, and while it can present with the same histological pattern as adenocarcinoma, mesothelial neoplastic cells are WT1 and Calretinin positive. Different imaging appearances of mesothelioma of the tunica vaginalis have been described, however common features on ultrasonography include the presence of a simple or complex hydrocele with nodular or plaque-like masses of either solid or mixed internal structures arising from the wall.^{8,9} These lesions are often hypervascular on Doppler. The tunica vaginalis can also be thickened or hyperemic.⁹ A malignant Sertoli cell tumor is positive for Inhibin and primary adenocarcinoma of the rete testis is negative. In our case, the most important criterion to identify the primary carcinoma of the rete testis was the transition from the normal epithelium of the rete testis to a dysplastic and to malignant epithelial cells, but other previously mentioned criteria were also met. Since we did not observe any signs of glandular differentiation in serial sections, the tumor has been

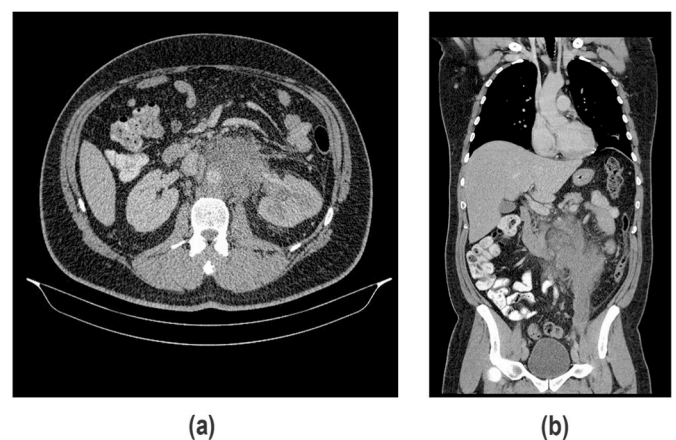


Fig. 3. a) axial and b) coronal CT scan shows enlarged retroperitoneal and inguinal lymph node conglomerate up to 9 cm in largest diameter.

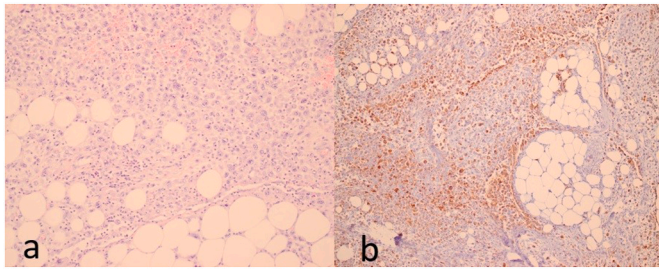


Fig. 4. Biopsy of retroperitoneal infiltration and peritoneal deposits a) solid growth pattern and discohesive, pleomorphic malignant tumor cells infiltrating peritoneal fat tissue (H and E x20). b) Immunohistochemical studies for keratins revealed that the atypical and dysplastic cells demonstrated cytoplasmic staining for pancytokeratin (CKAE1/AE3) (x10 magnification).

diagnosed as undifferentiated carcinoma.

4. Conclusion

We present this case because of the rarity of the carcinoma of the rete testis, very aggressive behavior and its fulminant course. We think it should be considered in the diagnostic work up of primary malignant tumor of the testis and that it would help pathologists who encounter patients with difficult diagnosis. In summary, we believe that this case report will help a better understanding of the diagnostic histological and immunohistochemical approach to the carcinoma of the rete testis.

The patient is sufficiently anonymized according to the ICMJE guidelines.

Declaration of competing interest

The authors declare that they have no conflict of interest.

This research did not receive any specific grant from funding agencies in the public, commercial, or not-for-profit sectors.

References

1. Amin MB. Selected other problematic testicular and paratesticular lesions: rete testis neoplasms and pseudotumors, mesothelial lesions and secondary tumors. *Mod Pathol.* 2005;18(Suppl. 2):S131–S145. <https://doi.org/10.1038/modpathol.3800314>.
2. Maganty A, Fombona A, Bandari J, et al. Aggressive surgical management of adenocarcinoma of the rete testis. *Urol. Case Rep.* 2017 Nov 13;16:72–74. <https://doi.org/10.1016/j.eucr.2017.10.001>.
3. Kitano H, Sentani K, Goto K, et al. Primary adenocarcinoma of the rete testis with elevated serum CA19-9 antigen levels. *Int. Cancer Conf. J.* 2020 Aug 9;9(4):240–243. <https://doi.org/10.1007/s13691-020-00437-z>.
4. Mitchell CF, Pearce S. Adenocarcinoma of the rete testis: a case report. *Cureus.* 2022, February 14;14(2), e22210. <https://doi.org/10.7759/cureus.22210>.
5. Owa S, Sasaki T, Uchida K, et al. A case of adenocarcinoma of the rete testis with durable response to cisplatin-based chemotherapy. *IJU Case Rep.* 2021;4:267–271. <https://doi.org/10.1002/iju5.12298>.
6. Sanchez-Chapado M, Angulo JC, Haas GP. Adenocarcinoma of the rete testis. *Urology.* 1995;46(4):468–475. [https://doi.org/10.1016/s0090-4295\(99\)80257-x](https://doi.org/10.1016/s0090-4295(99)80257-x).
7. Al-Obaidy KI, Idrees MT, Grignon DJ, et al. Adenocarcinoma of the rete testis: clinicopathologic and immunohistochemical characterization of 6 cases and review of the literature. *Am J Surg Pathol.* 2019;43:670–681. <https://doi.org/10.1097/PAS.0000000000001219>.
8. Bertolotto M, Boulay-Coletta I, Butini R. Imaging of mesothelioma of tunica vaginalis testis. *Eur Radiol.* 2016;26(3):631–638. <https://doi.org/10.1007/s00330-015-3887-9>.
9. Hannappel TD, DeVries M, Hansen NJ. Imaging appearance of cystic and solid mesothelioma of the tunica vaginalis. *Radiol. Case Rep.* 2020 Apr 22;15(7):809–811. <https://doi.org/10.1016/j.radcr.2020.04.004>.