

Nintedanib treatment for bleomycin-induced lung injury - First report

Rnjak, Dina; Batarilo Hađar, Martina; Pelicarić, Dubravka; Vukić, Tea; Janković Makek, Mateja; Samaržija, Miroslav; Hećimović, Ana

Source / Izvornik: **Respiratory Medicine Case Reports, 2023, 46**

Journal article, Published version

Rad u časopisu, Objavljena verzija rada (izdavačev PDF)

<https://doi.org/10.1016/j.mcr.2023.101921>

Permanent link / Trajna poveznica: <https://urn.nsk.hr/urn:nbn:hr:105:407335>

Rights / Prava: [Attribution-NonCommercial-NoDerivatives 4.0 International/Imenovanje-Nekomercijalno-Bez prerada 4.0 međunarodna](#)


Download date / Datum preuzimanja: **2024-07-18**



Repository / Repozitorij:

[Dr Med - University of Zagreb School of Medicine Digital Repository](#)





Case Report

Nintedanib treatment for bleomycin-induced lung injury - First report

Dina Rnjak^{a,*}, Martina Batarilo Hađar^a, Dubravka Pelicarić^a, Tea Vukić^a,
Mateja Janković Makek^{a,b}, Miroslav Samaržija^{a,b}, Ana Hećimović^{a,b}

^a University Hospital Zagreb, Clinical Center for Pulmonary Diseases Jordanovac, Jordanovac 104, Zagreb, Croatia

^b University of Zagreb, School of Medicine, Šalata 2, Zagreb, Croatia

ARTICLE INFO

Handling Editor: DR AC Amit Chopra

Keywords:
Nintedanib
Bleomycin
Lungs

ABSTRACT

Although the antineoplastic agent bleomycin is known for more than 50 years, its exact pharmacological and side-effect mechanisms remain incompletely understood. The major limitation of bleomycin therapy is the risk of pulmonary toxicity which can be diverse, and potentially fatal in 10% of patients. The optimal treatment for bleomycin lung toxicity has not been established and no clinical trials have been performed. Here we present first successful case report of nintedanib therapy in a patient with bleomycin-induced lung injury (BILI). The prevention, early diagnosis, and management of bleomycin pulmonary toxicities are essential, clinical trials are needed in this area.

1. Introduction

Antineoplastic agent bleomycin is known for more than 50 years but its exact pharmacological and side-effect mechanisms remain incompletely understood. The basic antitumor activity involves damaging tumor cell deoxyribonucleic acid (DNA) in complicated processes that are activated by ferrous and oxygen radicals [1,2]. According to some data, the generation of oxygen radicals might also induce the immune system's anti-tumor activity through cytokine and T-cell activation [3].

The major limitation of bleomycin is the risk of pulmonary toxicity which can be diverse, and potentially fatal in 10% of patients [2]. The pathogenetic mechanism of bleomycin-induced lung injury (BILI) is, probably, the result of the drug's antitumor activity and patient characteristics [2]. Damage induced by oxidative radicals and cytokines is potentiated by the lung's deficiency of bleomycin metabolizing enzyme-bleomycin hydrolase [4]. Exogenous risk factors are older age, renal insufficiency, higher bleomycin dose (cumulative dose of over 400 units), other chemotherapy, radiotherapy, a high fraction of inspired oxygen, therapy with colony-stimulating factors, and cigarette smoking [5,6].

Although pulmonary fibrosis is the most significant and serious, there are several distinct forms of BILI, including interstitial pneumonitis, organizing pneumonia, and eosinophilic hypersensitivity pneumonitis [7]. The diagnosis of BILI is the diagnosis of exclusion of other pulmonary diseases, the clinical presentation is nonspecific, and symptoms usually occur over days or weeks following bleomycin administration but rarely develop after several months (even years) [7,8]. Typical radiological findings are bilateral opacities, diffuse alveolar, and interstitial infiltrate, consolidation, ground-glass infiltrates, and in later stages honeycombing, traction bronchiectasis, and reticular markings [9]. Laboratory tests and bronchoalveolar lavage (BAL) are also nonspecific, sometimes eosinophilia can be detected, and an increased number of neutrophils, lymphocytes, or eosinophils in BAL [10]. Lung function tests

* Corresponding author. Clinical Hospital for Pulmonary Diseases Jordanovac University Hospital Zagreb Jordanovac 104 Zagreb, 10 000, Croatia.
E-mail address: dina.rnjak@gmail.com (D. Rnjak).

usually reveal restrictive patterns with reduced carbon monoxide diffusion capacity (DLCO) [11]. Most experts suggest spirometry and DLCO assessment before bleomycin induction and at intervals (unknown frequency) during the therapy, DLCO is considered to be a sensitive parameter, but the threshold for bleomycin discontinuation is debatable [11].

The optimal treatment for bleomycin lung toxicity has not been established and no clinical trials have been performed. Here we present the first successful case report of nintedanib therapy in a patient with BILI.

2. Case presentation

A 37-year-old man had a history of arterial hypertension, a mild form of COVID-19, and recently treated testicular carcinoma (stage T2N0M0S1)-orchiectomy was performed followed by chemotherapy (bleomycin-cisplatin-etoposide). Prior to initiation of oncological treatment, chest computed tomography (CT) was performed and no pathomorphological changes were detected. Fifteen days after the third chemotherapy cycle, the patient was admitted to the hospital due to respiratory insufficiency and right-sided hydro-pneumothorax that required thoracic drainage. Chest CT revealed bilateral subpleural consolidates with ground glass opacities (shown in Figs. 1A and 2A). Pleural effusion was eosinophilic (15%) exudate, and microbiological analyses were sterile. In laboratory tests, eosinophilia ($0.5 \times 10^9/L$) and elevated angiotensin-converting enzyme (ACE 828 U/L) were detected; other markers were within normal limits. BILI was suspected and methylprednisolone (1 mg/kg) was initiated along with oxygen and supportive therapy, resulting in transient clinical improvement, and partial radiological regression. Glucocorticoid therapy was gradually tapering and the patient was released from the hospital. Due to severe and progressive dyspnea, the patient was admitted again and transferred to our hospital. Pulmonary embolism was excluded, radiologically there was partial regression of ground-glass infiltrates with the progression of consolidates and traction bronchiectasis. Due to severe respiratory insufficiency and poor general health condition, the patient could not perform lung function tests or bronchoscopy, and cytological sputum analysis was unremarkable. Pulse glucocorticoid therapy with antibiotics (levofloxacin), oxygen therapy, thromboprophylaxis, and pulmonary rehabilitation were induced, but with a poor clinical and radiological response. Due to the radiologic progression and clinical worsening of the patient we decided to induce nintedanib in the daily dose of 300 mg and to gradually discontinue glucocorticoid therapy. After six months of nintedanib monotherapy, there was a clinical improvement, and oxygen therapy was reduced (the patient is using it only during exercise with a significantly lower exercise desaturation-in a 6-min walk test prior to nintedanib desaturation of 31% compared with 18% with nintedanib),

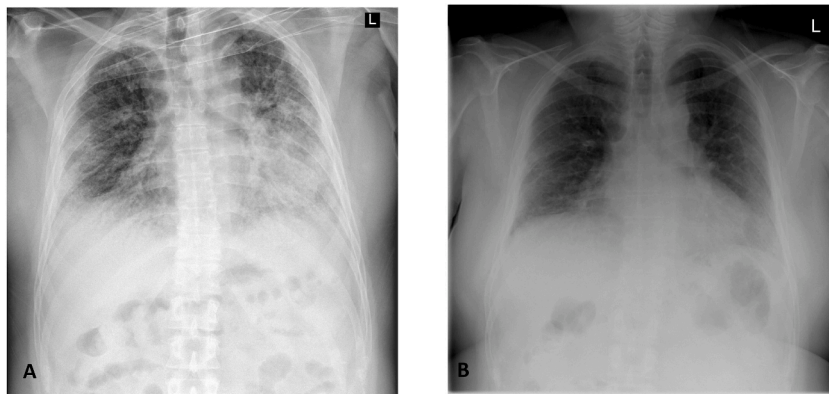


Fig. 1. Chest RTG before (A) and after (B) bleomycin induction.

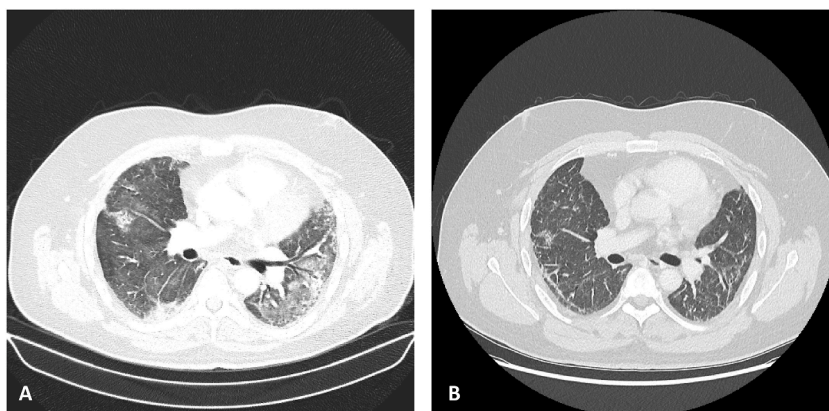


Fig. 2. Chest CT before (A) and after (B) bleomycin induction.

with good radiological regression of ground-glass opacities (shown in Fig. 1B and 2B). Lung function tests revealed restrictive patterns (FVC 43%, 2.25 L, FEV1 43%, 1,83L, FEV1/FVC 0.81, TLC 43.5%, 3.07 L). Diffusion capacity for carbon monoxide (DLCO) is reduced (restrictive type), however, after additional two months of therapy, there was an improvement in the value of DLCO (from 37 to 49%). The patient is still on nintedanib therapy.

3. Discussion

BILI is one of the most challenging pulmonary disorders, patients often present late, treatment algorithms are lacking and there is no proven effective therapy [12]. The best therapy is prevention and prompt bleomycin discontinuation, whether based on symptoms or DLCO decrease.¹ Clinical trials are missing and therapy protocols are based on individual case reports, case series, and animal studies that examine the efficacy of different drugs.

Glucocorticoids are usually initiated, although efficacy data are conflicting, probably due to the timing of initiation, dosing, and different interstitial pattern of BILI [1,13,14]. A Japanese group of authors presented the case of a patient with BILI who was treated early with tacrolimus and glucocorticoids with a favorable outcome [15]. Contrary, infliximab, and imatinib did not prove to be successful in severe, progressive forms of the disease [16,17]. The few reports on pirfenidone are unclear [18], and to our knowledge, our case report is the first about nintedanib therapy for BILI in humans.

The anti-inflammatory and anti-fibrotic effectiveness of nintedanib were mostly studied in in-vitro and animal studies in which bleomycin was given to animals to induce lung fibrosis [19–21]. Bleomycin induces acute alveolar epithelium inflammation followed by fibrosis which is also observed in idiopathic pulmonary fibrosis (IPF), these process includes activation of adaptive and innate immune cells, cytokines, and chemokines [22,23].

Damage to alveolar epithelial cells may result in arachidonic acid oxidation and the release of different mediators, and growth factors that stimulate fibroblast proliferation and fibrosis [24]. Neutrophils seem to be an important part of pathogenesis, due to their ability to release oxidants, proteases, cytokines, and other soluble mediators like neutrophil elastase which was detected in sera and bronchoalveolar lavage (BAL) fluid of patients with IPF [23]. It has been shown that inhibition of neutrophil elastase is associated with the reduction of pulmonary fibrosis [23]. Bleomycin promotes vascular cell adhesion molecule 1 (VCAM-1) expression in pulmonary endothelial cells and helps neutrophil adhesion and migration [23]. Nintedanib is a molecule with the anti-inflammatory and antifibrotic activity which inhibits tyrosine kinase receptors and platelet-derived, fibroblast, and vascular endothelial growth factors [20]. Wollin et al. tested nintedanib in human lung fibroblasts and a mouse model of lung fibrosis (induced with bleomycin), as a preventive and therapeutic regimen, results showed that nintedanib reduces BAL neutrophils and lymphocytes, and histologic analysis revealed decreased lung inflammation, granuloma, and fibrosis formation [21].

Taiwanese group of authors came to similar conclusions studying nintedanib effects in mice lung fibrosis induced by bleomycin, nintedanib therapy significantly reduced fibrosis both according to Ashcroft score and Masson's trichrome staining while immunohistochemistry revealed reduced levels of collagen-1 [20]. Further, nintedanib treatment decreased the VCAM-1 level and upregulated G protein-coupled receptor kinase 2 which prevented neutrophil chemotaxis [20]. European Medicines Agency approved nintedanib for the treatment of idiopathic pulmonary fibrosis, and recently for other fibrosing interstitial lung diseases (ILD), and ILD associated with systemic sclerosis [25].

In our case glucocorticoid monotherapy was not effective enough, the patient had poor, transient clinical improvement which correlated with mild radiological improvement. Contrary, nintedanib monotherapy led to significant regression of consolidates and ground-glass infiltrates which correlated with remarkable clinical improvement, primarily in de-escalation of oxygen therapy and better exercise tolerance. The patient developed steroid diabetes and discontinuation of glucocorticoids was extremely beneficial. One study assessed the effects of nintedanib alone and in combination with methylprednisolone in bleomycin-induced lung fibrosis mice [24]. The results showed that cytokine (interleukin-2, interleukin-4, interferon- γ , tumor necrosis factor α) and oxidants (malondialdehyde) levels were suppressed in methylprednisolone groups but were even more reduced when nintedanib was used, while glutathione (antioxidant) levels increased in both groups, but the most in a group that combined methylprednisolone and nintedanib [24]. However, histological analysis showed that methylprednisolone was not able to reverse the bleomycin-repair impairment, but it actually worsened the bronchiolar epithelial condition causing the bronchiolar passages disorganization and degeneration [24]. Further, nintedanib reduced inflammatory cell infiltration and collagen deposition [24]. It remains unknown whether the glucocorticoid-nintedanib combination would be the most beneficial, however, we can assume that lower doses or avoidance of glucocorticoid therapy would definitely be safer due to many glucocorticoid side effects.

Bleomycin is used for the treatment of neoplasms that commonly affect young patients who have a chance to survive for long periods. The prevention, early diagnosis, and management of bleomycin pulmonary toxicities are essential. Since we still do not have effective second-line treatment for BILI clinical trials are needed in this area [1].

4. Conclusion

- exact pharmacological and side-effect mechanisms of bleomycin remain incompletely understood
- nintedanib is a potential treatment for bleomycin-induced lung injury

Funding sources

None.

Author Contributions

Dina Rnjak- Conceptualization, original writing, reviewing and editing. Martina Batarilo Hadar-reviewing and editing, Reference management. Dubravka Pelicarić-reviewing and editing. Tea Vukić-reviewing and editing. Mateja Janković Makek-reviewing and editing. Miroslav Samaržija-reviewing and editing. Ana Hećimović-reviewing and editing, Supervision.

Declaration of competing interest

None.

Acknowledgement

None.

References

- [1] T. Reinert, C.S. da R. Baldotto, F.A.P. Nunes, A.A. de S. Scheliga, Bleomycin-induced lung injury, *J. Cancer Res.* (2013 Oct 8) 1–9 2013.
- [2] B.I. Sikic, Biochemical and cellular determinants of bleomycin cytotoxicity, *Cancer Surv.* 5 (1) (1986 Jan 1) 81–91.
- [3] H. Bugaut, M. Bruchard, H. Berger, V. Derangère, L. Odoul, R. Euvrard, et al., Bleomycin exerts ambivalent antitumor immune effect by triggering both immunogenic cell death and proliferation of regulatory T cells, *PLoS One* 8 (6) (2013 Jun 7) e65181.
- [4] J.S. Lazo, W.W. Merrill, E.T. Pham, T.J. Lynch, J.D. McCaluster, D.H. Ingbar, Bleomycin Hydrolase Activity in Pulmonary Cells 1, 1984.
- [5] K. Sakamoto, S. Ito, N. Hashimoto, Y. Hasegawa, Pirfenidone as salvage treatment for refractory bleomycin-induced lung injury: a case report of seminoma, *BMC Cancer* 17 (1) (2017 Aug 7) 1–4.
- [6] A.F. Tryka, W.A. Skornik, J.J. Godleski, J.D. Brain, Potentiation of bleomycin-induced lung injury by exposure to 70% oxygen, Morphologic assessment. *Am Rev Respir Dis.* 126 (6) (1982) 1074–1079.
- [7] S. Sleijfer, Bleomycin-induced pneumonitis, *Chest* 120 (2) (2001) 617–624.
- [8] I. Uzel, M. Ozguroglu, B. Uzel, K. Kaynak, O. Demirhan, C. Akman, et al., Delayed onset bleomycin-induced pneumonitis, *Urology* 66 (1) (2005) 195.
- [9] M. De Lena, A. Guzzon, S. Monfardini, Clinical, radiologic, and histopathologic studies on pulmonary toxicity induced by treatment with, *Cancer Chemother reports* 56 (3) (1972) 343–356.
- [10] D.A. White, M.G. Kris, D.E. Stover, Bronchoalveolar lavage cell populations in bleomycin lung toxicity, *Thorax* 42 (7) (1987) 551.
- [11] J. Lauritsen, M. Gry, G. Rigshospitalet, Pulmonary function in patients with germ cell cancer treated with bleomycin, etoposide, and cisplatin radionuclide imaging and treatment of NET view project radium treatment of CRPC view project, *Artic J Clin Oncol* (2016).
- [12] T. Liu, F.G. De Los Santos, S.H. Phan, The bleomycin model of pulmonary fibrosis, in: *Fibrosis*, Springer, 2017, pp. 27–42.
- [13] J. Maher, P.A. Daly, Severe bleomycin lung toxicity: reversal with high dose corticosteroids, *Thorax* 48 (1) (1993 Jan 1) 92–94.
- [14] D.A. White, D.E. Stover, Severe bleomycin-induced pneumonitis: clinical features and response to corticosteroids, *Chest* 86 (5) (1984) 723–728.
- [15] S. Ro, R. Imai, T. Tamura, V.C. The Author, Efficacy of tacrolimus for bleomycin-induced lung injury Learning points for clinicians, *Int. J. Med.* (2020) 807–8.
- [16] V. Ge, I. Banakh, R. Tiruvoipati, K. Haji, Bleomycin-induced pulmonary toxicity and treatment with infliximab: a case report, *Clin Case Reports* 6 (10) (2018 Oct 1) 2011.
- [17] S. Alamro, Z. Zhang, A. Selvaggio, P. Noble, Pirfenidone for treatment of bleomycin-induced lung toxicity, *Chest* 150 (4) (2016) 508A.
- [18] E. Bendstrup, C. Hyldgaard, M. Agerbæk, C.U. Andersen, O. Hilberg, No effect of pirfenidone treatment in fulminant bleomycin-induced pneumonitis, *Respir Med Case Reports* 12 (2014 Jan 1) 47–49.
- [19] L. Wollin, I. Maillet, V. Quesniaux, B. Ryffel, Nintedanib Reduces Bleomycin-Induced Lung Inflammation and Fibrosis in Mice, *Eur Respiratory Soc*, 2013.
- [20] W.C. Chen, N.J. Chen, H.P. Chen, W.K. Yu, V.Y.F. Su, H. Chen, et al., Nintedanib reduces neutrophil chemotaxis via activating GRK2 in bleomycin-induced pulmonary fibrosis, *Int. J. Mol. Sci.* 21 (13) (2020 Jul 2) 4735 2020, Vol 21, Page 4735.
- [21] L. Wollin, I. Maillet, V. Quesniaux, A. Holweg, B. Ryffel, Antifibrotic and anti-inflammatory activity of the tyrosine kinase inhibitor nintedanib in experimental models of lung fibrosis, *J. Pharmacol. Exp. Therapeut.* 349 (2) (2014 May 1) 209–220.
- [22] P. Kruger, M. Saffarzadeh, A.N.R. Weber, N. Rieber, M. Radsak, H. von Bernuth, et al., Neutrophils: between host defence, immune modulation, and tissue injury, *PLoS Pathog.* 11 (3) (2015 Mar 1) e1004651.
- [23] Y. Obayashi, I. Yamadori, J. Fujita, T. Yoshinouchi, N. Ueda, J. Takahara, The role of neutrophils in the pathogenesis of idiopathic pulmonary fibrosis, *Chest* 112 (5) (1997) 1338–1343.
- [24] D. Alghamdi, H. Eweis, Nintedanib Reduces Corticosteroid Resistance Pulmonary Brosis Induced by Bleomycin in Mice by Increasing the Expression of $\beta 3$ & $\beta 6$ Integrins, 2022.
- [25] Ofev | European Medicines Agency [Internet].